UNIVERSITATEA DE ȘTIINȚE AGRICOLE ȘI
MEDICINĂ VETERINARĂ "ION IONESCU DE LA BRAD" IAȘI

LUCRĂRI ȘTIINȚIFICE

VOL. 54

MEDICINĂ VETERINARĂ

NR. 1

EDITURA "ION IONESCU DE LA BRAD" IAȘI 2011

Volumul a fost editat cu sprijinul financiar al Ministerului Educației, Cercetării, Tineretului și Sportului

ISSN: 1454-7406

CUPRINS

NR.1

NR.2

TUBULAR CHOLANGIOCARCINOMA AT DOG MORPHOLOGICAL ASPECTS

OPREAN O.Z., PAȘCA S., LAZĂR M., ROTARU Anca, ANCUȚA Andreea, RAILEANU Gabriela
Faculty of Veterinay Medicine Iasi
passorin@yahoo.com

Abstract
Tubular cholangiocarcinoma, also called tubular cholangiocellular adenocarcinoma, is more frequently encountered in dogs and has a decreasing incidence in cats, cattle and horses. In humans, it is the second most frequent primary hepatic tumour after the hepatoma. It frequently produces metastasis in the spleen, kidneys, lymphnodes, thyroid, adrenal glands, bone marrow, intestin.
Key words: cholangiocarcinoma, metastasis, dog.

MATERIAL AND METHODS

After necropsic examination, organ samples were prelevated for histopathological investigations. Each case was prelevated kidney fragments, as well as fragments of different organs, physiologically closely related (heart, liver, lung, intestine, spleen, etc.).

Organ samples were fixated in formaldehyde 10%, then paraffin - included. The histological sections measuring 5 µm were stained Haematoxilin - Eosin - Methyl Blue (Tricromic - Masson, HEA).

RESULTS AND DISCUSSIONS

Tubular carcinoma was diagnosed following necropsic and histopathological examination of a 10 years old mix-breed female, who died after 3 days of profound coma.

The primary tumour was localised in the liver. Tubular cholangiocarcinoma was surprised in the microscopical examination in all its evolutive stages. Initially, biliary ducts appear dilated. The epitelium is formed of cubic or cylindric cells with big round nuclei, disposed on one or several layers, with papilliffer intratubular prolifferations.

(Fig. 1, 2)

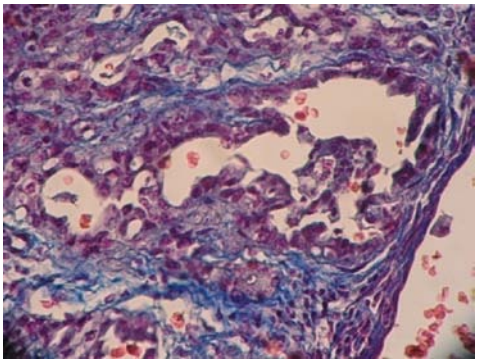

Fig.1. Liver. Primary cholangiocarcinoma. Col. HEA, x400

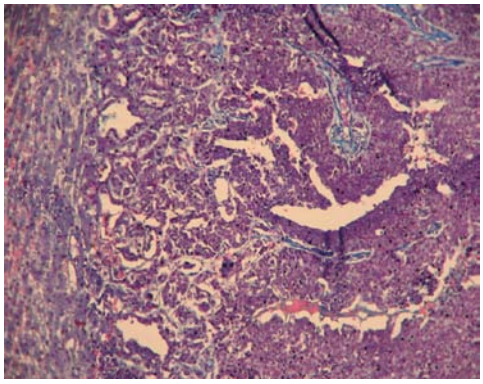

Fig. 2. Liver. Cholangiocarcinoma. Col. HEA, x60

Inside the tumoural nodule, several small channels are found. **(Fig.3)** and wide areas of polymorphic cells, anisokariosys and plenty of mitotic figures. **(Fig.4)**. The connective tissue stroma is well represented and it infiltrates the tumoral mass, delimitationg and grouping neoplasic cells. Tumoural cells may invade the limitroph hepatic tissue and can pass inside the sinusoid capillaries, forming tumoural embols.

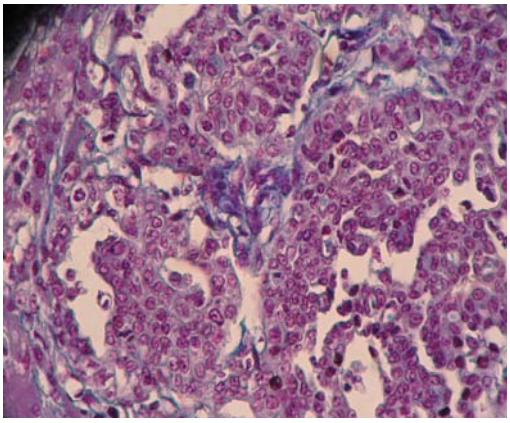

Fig. 3 Liver. Cholangiocarcinoma. Col. HEA, x 400

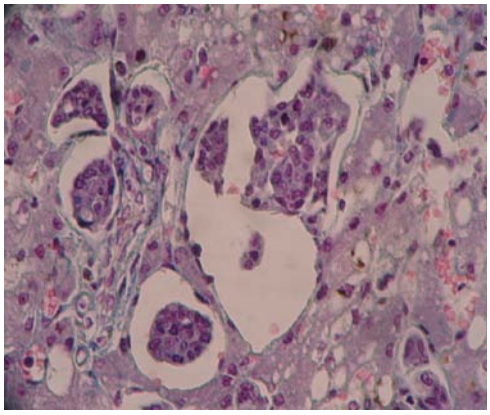

Fig. 4. Liver. Vascular invasion. Col. HEA, x 400

Renal metastasis. Macroscopically, in the kidney, we noticed both in the cortical **(Fig. 5)** ant the medullar, small white foci with a 1 mm diameter.

Fig. 5. Kidney with carcinomatous metastasis

Microscopical examination shows plenty of tumoural embols in glomerular and interstitial capillaries **(Fig. 6, 7)** as well as big, well limited nodules, formed of tubular structures surrounded by a fine fibrous stroma, in the cortical **(Fig. 6)** and medular areas **(Fig. 8, 9)**. Carcinomatous cells are big, pleiomorphic, with big vesiculous nuclei and plenty of mitosis.

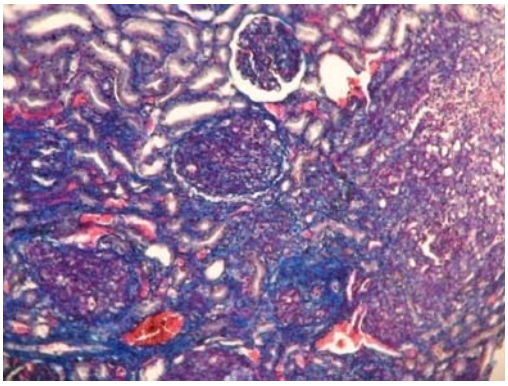

Fig. 6 Kidney. Tumoral emboli in glomerules, carcinomatous nodule in the cortex. Col. HEA, 100

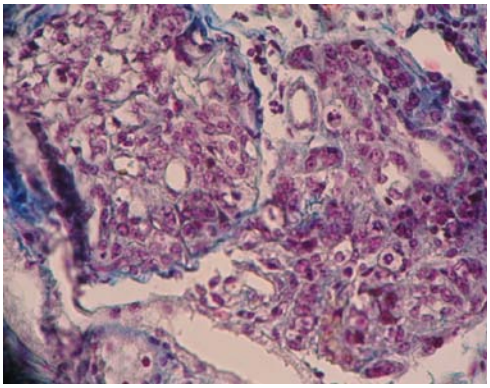

Fig. 7 Kidney. Carcinomatous emboli in glomerular capillaries. Col. HEA, x400

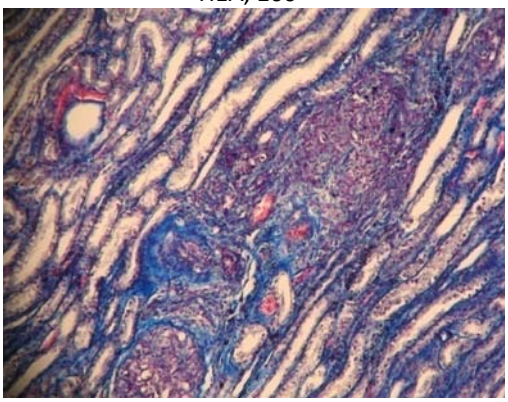

Fig.8 Kidney. Carcinomatous metastasis in medullar. Col. HEA, x100

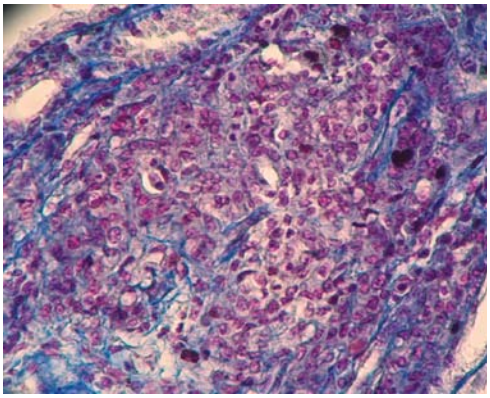

Fig. 9 Kidney. Carcinomatous metastasis in medullar. Col. HEA, x 400

In the lungs wide spread lobular territories with hyperemia show several tumoural emboli in septal capillaries, accompanied by fibrosis and an important decrease of the haematosis surface. **(Fig. 10.).**

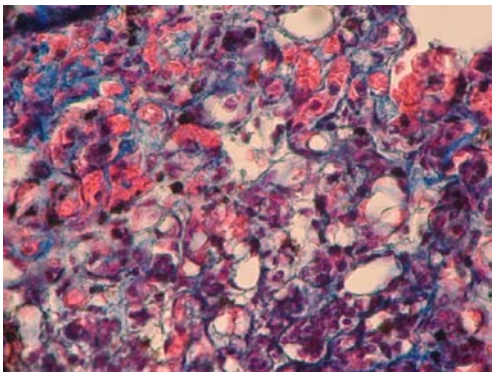

Fig. 10 Lung. Carcinomatous emboli in septal capillaries. Col HEA, x 400

CONCLUSIONS

1. Hepatic cholangiocarcinoma appears in a small number of dogs, the incidence being increased in patients with biliary lithiasis, sclerotic cholangitis, billiary atresia and congenital malformations of billiary ducts.

2. In this particular case, the metastasis of the hepatic tumour is accomplished through the blood stream, phenomena conformed by carcinomatous emboli.

BIBLIOGRAPHY

1. **Reed R.J., Love G.L., Harkin J.C., 1983 –** Clear cell carcinoma. Am. J. Surg. Pathol., 7, p.597-601;
2. **Steffens J. et al., 1990** - Renin-Producing Renal Cell Carcinoma. Eur. Urol. 18:56-60;
3. **Stenzel A., Kernion J.B., 1989** – Pathology, biology and clinical staging of renal cell carcinoma. Sem. Oncol., 16 (Suppl.1, feb.), 3-1;
4. **Tsuda H., Krieg K., 1992** - Neoplastic Lesions in the Kidney. *In*: Pathobiology of the Aging Rat, eds. Mohr U, Dungworth DL, Capen CC, vol. 1, pp. 235-237. ILSI Press, Washington, DC;
5. **Weiss L.M., et al., 1995** - Adult renal epithelial neoplasms. Am J Clin Pathol 103:p.624- 635;

CYTOKINES AND LIPID PEROXIDATION RESPONSES TO CHRONIC TOXOPLASMA GONDII INFECTION IN PREGNANT WOMEN BEFORE AND AFTER SPIRAMYCIN TREATMENT

[1]Afaf, D.., Abd elmageid and [2]Abeer, A. Abd el Aleim.

[1]Biochemistry Dept [2]Physiology Dept Fac. Vet. Med.,
Moshtohor, Benha University,Egypt.

Abstract

Background: It is well established that *T.gondii* infection in pregnant women is highly dangerous, cause abortion and induces a strong cell-mediated immune response.

Aim: The present study aimed to investigate whether the levels of IL8, IL1, leptin , progesterone H and MDA were ameliorated in spiramyin treated women with chronic *T. gondii* infection during early pregnancy compared with control group .

Patients and methods: to carry out this work firstly *T. gondii* total, IgG and IgM antibodies were determined in sera of 82 pregnant women with previous history of abortion. Secondly IL8, IL1, leptin. Progesterone H and MDA concentration were determined in sera of 12 chronic *T. gondii* infected pregnant women before treatment (group1) and after 40 days post treatment with spiramycin (group 2). The same parameters were also estimated in 12 non infected pregnant women at the same period of pregnancy and considered as control healthy group (group 3).

Results: concentrations of IL1, leptin and MDA were significantly increased ($P < 0.05$) in *T. gondii* infected pregnant women. Such increase was modulated toward normal values in spiramycin treated women. There was no significant difference in the mean value of IL-8 in serum of all groups, while, its concentration in spiramycin treated women was higher than other groups. However, Serum progesterone level of pregnant untreated women showed a significant decrease ($P < 0.05$) when compared with healthy control group. Such decrease was slightly ameliorated in spiramycin treated group.

Conclusion: Chronic *T. gondii* infection elevate serum levels of pro-inflammatory IL1, leptin and MDA accompanied with a reduction in progesterone H in pregnant women .However administration of spiramycin ameliorate such changes toward the correct values.

Keywords: *Toxoplasma gondii*, pregnancy, IL8, IL1, leptin, MDA, progesterone, spiramycin.

Introduction

T. gondii is an obligate intracellular protozoan parasite of warm blooded vertebrates. Infection is normally controlled by the host immune system leading to an asymptomatic chronic stage of infection in which a balanced host–parasite interaction assures both survival of the host and maximum chance for transmission of the parasite **(Bartholomäus, 2001).** Pregnant women can be infected through contact with cats and eating raw or undercooked meat **(Süleyman et., 2003).** Furthermore, this parasite can be congenitally transmitted if the mother was infected for the first time during pregnancy (Menzies et al., 2008). In most pregnant women with acute acquired infection, no obvious symptoms or

signs appear **(Sarka and Jaroslav, 2007).** T. gondii infections during pregnancy are most commonly diagnosed by detecting the immunoglobulin IgG and IgM antibodies in the serum samples of the patients using enzyme-linked immunosorbent assay **(ELISA) (Montoya, 2002).**

Pregnancy is a complex process in which cells and molecules of the maternal immune system interact to prevent the rejection of the foetus, thus survival of pregnancy is controlled by the presence of various hormones, such as estrogens and progesterone. Consequently, the elevated levels of progesterone observed during pregnancy possess a number of modulatory functions on cells of the immune system, including macrophages, natural killer (NK) cells, dendritic cells (DCs), T cells and B cells **(Menzies and Henriquez, 2009).** Beside the cytokine environment which is important for a successful pregnancy **(Makhseed et al., 2001)**

IL-8 is a chemokines involved in the activation of neutrophils, and attract other leukocyte populations **(Kunkel et al., 1997).** It is produced by macrophages, epithelial cells and endothelial cells. The Primary function of IL-8 is the induction of chemotaxis in its target cells like neutrophil and granulocytes **(Montaya, 2002),** and innate immune response. It is often associated with inflammation so it has been considered as a pro-inflammatory mediator in Toxoplasmosis **(Tenter et al., 2000).** Similarly, IL-1 which released by lymphocytes may play a significant role in modulating the host's immune defense against *T. gondii* infection **(Chang et al., 1990).** Morever, Leptin is a multifunctional hormone which acts both centrally and peripherally to regulate several metabolic and inflammation-related functions. It influences normal embryo implantation ,pregnancy and immunological processes in various species **(Soad, 2008).** Leptin secretion in pregnant women increased during second trimester of pregnancy **(Lage et al., 1999).**

MDA is widely used as an indicator for lipid oxidation thus its increase has been associated with a variety of chronic diseases which cause serious damage as a result of oxidative stress **(Yazar et al., 2003).**

Spiramycin is an antibiotic, used for treatment of *T. gondi*i infection from the first trimester until delivery It decreases the risk of fetal infection by 60 %. As well as, spiramycin treated women develop lower total *T. gondii* specific IgG antibody level that may be due to reduced parasite load as well as parasite replication is stopped after treatment **(Meroni et al., 2009).**

Thus, the main objective of the present study is to investigate whether the levels of IL-8, IL-1, leptin, progesterone hormone and MDA can be ameliorated in spiramyin treated women with chronic *T. gondii* infection during early pregnancy.

Materials and Methods

1- Determination of *T. gondii* in pregnant women:

During the period of August 2010 to February 2011, 82 blood samples were collected from pregnant women in a rural area belongs to Kalubyia Governorate, Egypt. All women were at the first trimester of pregnancy, aged 24 to 35 years old with a history of previous abortion. Serum samples were analyzed for anti *T. gondii* antibodies (total, IgM and IgG) as

described previously by (**Cheraghipour et al., 2009)** To evaluate the incidence of *T. gondii* among different ages.

Experimental studies:

Blood samples were collected from 12 patients of positive *T.gondii* IgG antibodies before (group 1) and after 40 days treatment with Spiramycin (group 2). Another 12 blood samples were obtained from *T . gondii* IgG negative women, at the first trimester, as a control group (group 3). The collected blood samples were divided into two groups; the first group taken without anticoagulant for serum separation which used to determine IL-8 and IL-1by enzyme linked immunosorbent assay (ELISA) using a diagnostic Biochem Canada inc. kit also serum was used for determination of progesterone **(Ryan et al., 1973)**, MDA spectrophotometrically using thiobarbiyuric acid assay according to **Esterbaur et al., (1982)**. The second group was taken on EDTA then plasma was separated by centrifugation and stored at -20°C for determination of leptin level by ELISA using a diagnostic Biochem. Canada inc. kit (**Chessler et al., 1998).**

Statistical analysis: All data are presented as means ± SE. Statistical analysis was performed using SPSS software package (Version 16.0 for Windows) using one-way analysis of variance (ANOVA), with a post hoc Duncan test. The differences were considered to be statistically significant when $P \leq 0.05$.

Results

Data in table (1) showed that76 out of 82 (92.68%) examined pregnant women with previous history of abortion in rural area in Kalubyia Governorate were seropositive for total T. gondii antibodies. The percentage of infection was higher (96.15%) in women of ages ranged from 24-29years old compared to (86.66%) in older ages(30-35 yearsold). The data showed also that 68 out of 82 investigated samples against T.gondii IgG were seropositive . T. gondii IgM was detected only in 8samples (9.75%). Among the examined 82 samples, while 6 Samples were T. gondii free.

Data in table (2) revealed that, the mean serum concentration of IL-8 in chronic phase of *T.gondii* infection in pregnant women with positive *T.gondii* IgG and that of treated group were 89.06 and 94.76 pg/ml respectively . However, in healthy subjects, the mean value was (71.15 pg/ml). Thus, There was no significant difference in the mean value of IL-8 in serum of all groups . However we demonstrated that the mean level of IL-8 in spiramycin treated pregnant women was higher than other groups

With respect to IL1, Serum concentration of IL-1 were 6.6, 5.9 and 4.6 pg/ml in *T.gondii* infected untreated, spiramycin treated and *T. gondii* free pregnant women respectively. Thus the value of IL-1in patients with chronic infection with *T.gondii* was significantly higher than ($P < 0.05$) in healthy subjects. Such increase reduced significantly in spiramycin treated group. Plasma leptin, level of pregnant untreated women with positive *T.gondii* IgG showed a significant increase ($P < 0.05$) compared to control group. Such increase was reduced significantly in spiramycin treated group

However, Serum progesterone, level of pregnant untreated women with positive T.gondii IgG showed significant decrease ($P < 0.05$) when compared with healthy control group. Such increase was slightly ameliorated in spiramycin treated group

A significant increase in serum MDA levels in pregnant untreated women with positive T.gondii IgG was recorded. Such increase become non significant in spiramycin treated group. Compared to healthy control group.

Table 1: Incidence of *T. gondii* infection among different ages of pregnant women with history of previous abortion in a rural area belongs to Kalubyia Governorate,

	Number of examined samples	Negative		Positive					
		N	%	Total Ab		IgG		IgM	
				N	%	N	%	N	%
From 24 to 29 years	52	2	3.84	50	96.15	44	84	6	11
From 30 to 35 Years	30	4	13.33.	26	86.66	24	80	2	6.67
Total	82	6	7.31	76	92.68	68	82.92	8	9.75

Table 2: Effect of Spiramycin treatment of chronic *T. gondii* infection on IL8, IL1, Leptin, Progesterone and MDA of pregnant women (Mean ±SE):

Group Parameters	Group1 (infected)	Group2 (treated)	Group 3 (Control)
IL-8 (pg/ml)	89.06 ± 7.32[a]	94.76 ± 5.17[a]	71.15 ± 9.43 [a]
IL-1(pg/ml)	6.65 ± 0.39[a]	5.23 ± 0.29[b]	4.03 ± 0.32[c]
Leptin (ng/ml)	35.88 ± 2.48[a]	26.49 ± 2.76[b]	12.59 ± 1.53[c]
Progestrone (ng/ml)	2.50 ± 0.22[b]	3.26 ± 0.30[b]	6.96 ±0.52[a]
MDA (nmol/ml)	26.62 ± 0.83 [a]	24.45 ± 0.55 [a]	9.44 ± 0.75 [b]

Discussion

The protozoan parasite *T. gondii* is a major cause of abortion in pregnant women. Concerning its incidence in pregnant women with previous history of abortion in rural area in Kalubyia Governorate , our results were higher than the results of **Nejad et al ., (2011)** in Iran who recorded chronic *T. gondii* infection in 36.3% and 34.5% in urban and rural areas respectively. Such higher incidence in our study was attributed to the changes in the kind of patients in the two countries, as our study was restricted to pregnant women with previous history of abortion while **Nejad et al., (2011)** carried out their research on random samples of pregnant women.

Both acute invasion and reactivation of latent *T. gondii* infection result in an inflammatory reaction with lymphocytes, macrophages, and neutrophils infiltration. One signal for the cellular infiltrate after *T.gondii* infection is the release of pro-inflammatory chemokines like IL-8 elicited by supernatants or lysates from *T.gondii* infected fibroblasts **(Denney et al., 1999).**

In The present study, the concentrations of IL-8 in patients with serological evidence of chronic infection with *T.gondii* either before or after spiramycin treatment were higher than in control subjects although the differences between groups were not statistically significant. These findings were came in accordance with that of **(Nejad et al., 2011)** who explained that, chemokines response is dependent on invasion of tachyzoites leading to cell lyses, and elicit IL-8 which responsible for activation and recirculation of neutrophils which can phagocytose and inhibit tachyzoites of *Toxoplasma*, thus it has an important role in innate immunity as a response to *toxoplasma* (**Ju et al., 2009)**.

Regarding IL-1, our results revealed that, the concentration of IL-1 in *T.gondii* infected group was significantly ($P \leq 0.05$) higher than in the treated group which in turn were significantly ($P \leq 0.05$) higher than the control group. Such results might be attributed to significant upregulation of steady-state levels of mRNA for IL-1, as the secretion of these molecules may play a critical immuno-regulatory role in the pathophysiological processes associated with *T. gondii*-induced.(**Nagineni etal., 2000)**. Morover, upon deterioration of immunity and reactivation of chronic infection, induction of an inflammatory reaction which capable of lysing parasite infected cell and release cytokines such as IL-1 which released by lymphocytes **(Denney et al., 1999)**, and play a significant role in modulating the host's immune defense against *T. gondii* infection (Chang et **al., 1990)**

The significant increase in leptin level might be due to production of IL-1 and other cytokines that released during inflammation and infection (Lioyd et al., 2001. As well as these findings support the idea of leptin as a factor enhancing the production of proinflammatory factors **(Katriina et al., 2009)**

Levels of sex hormones, mainly progesterone, are vastly increased during pregnancy, this increase occurs initially by the uterus and then by the placenta. The physiological increase in progesterone level protects the developing fetus from the

mother's immune response and to prevent rejection of the fetus, it also has consequences for parasitic infection. The ability of pregnancy to affect the immune system and the immune system to affect pregnancy has two important consequences for *T. gondii* infection. Firstly, pregnancy will favor the survival of the parasite and secondly, parasitic infections induce a strong immune response which adversely affects pregnancy. In the present study, *T. gondii* infection significantly decreased the progesterone concentration in serum of infected women ($P \leq 0.05$) as compared to the control group. The obtained results might be a consequence of the placental damage caused by *T. gondii* infection **(Weissmann., 2003)**.

Lipid peroxidation is a free radical-related process that may occur under enzymatic control (e.g., for the generation of lipid-derived inflammatory mediators) or non enzymatically in biologic systems. The latter form is associated mostly with cellular damage as a result of oxidative stress, which also involves cellular MDA Levels in *Toxoplasma* seropositive patients **Suleyman et al., (2003)**. The recorded significant increase in the lipid peroxidation came in accordance with (**Hany elshikha et al., 2008)**, who reported that *T.gondii* seropositive patient had significantly ($P < 0.001$) higher MDA level paralleled with significant decrease($P < 0.01$) in the level of GSH-Px compared with *T. gondii* negative group . They attributed these result as the parasites induced lipid peroxidation due to increased ROS generation to an extent that overcomes the cellular antioxidants resulted in oxidative stress **Dede *et al.,* (2002),** and increased production of aldehydic compounds such as MDA, which is considered one of the bio-products in lipid peroxidation and a marker of oxidative stress (**Lee *et al*., 2004).**Thus, the significant correlation strongly indicate the occurrence of oxidative stress and lipid peroxidation as a mechanism of tissue damage in cases of chronic toxoplasmosis.

The significant decrease in MDA level in spiramycin treated women following *chronic T. gondii* infection was confirmed by **Meroni et al (2009)** who concluded that , spiramycin treated women develop lower total T. gondi specific IgG antibody level that may be due to reduced parasite load via its action on trophozoites as well as parasite replication is stopped after treatment. The finding also clarify the role of spiramycin as a good prophylactic via its influence on immunosuppresion of pregnant women that seem to be irrevelent .

Conclusion

Spiramycin treatment modulated proinflammatory cytokines and lipid peroxidation parameters to be close to the level of control group in chronic *T. gondii* infection in pregnant women with previous history of abortion but it failed to increase the progesterone concentration in serum .

Acknowledgment : the authors were greatly thanks to Prof. Dr . Mohammed Yousef Ramadan prof. of Parasitology Fac. Of Vet .Med. Benha Univ. for his helps in carrying out the survey in this research.

References

1. Bartholomäus, S. H. F.(2001)*: Toxoplasma gondii* induction of interleukin- 12 is associated with acute virulence in mice and depends on the host genotype. Veterinary Parasitology 100 : 63–74.
2. Chang HJ, Clark RD, Bachman H(1990): The phenotype of 45,X/46,XY mosaicism: an analysis of 92 prenatally diagnosed cases.Department of Pediatrics, Harbor-University of California Los Angeles Medical Center, Torrance 46(1):156-67..
3. Cheraghipour K, Taherkhani H, Fallah M, SheykhianA, Sardarrian KH, Rostami Nejad M, (2009): Seroprevalence study of toxoplasmosis in pregnant women referred to Aleshtar rural and urban health centers in 2008. Yafte Medical Journal 11: 87- 91.
4. Chessler SD, Fujimoto WY, Shofer JB, Boyko EJ, Weigle DS. Increased plasma leptin levels are associated with fat accumulation in Japanese Americans. Diabetes 1998;47:239–43
5. Dede S., Deger, Y., Kahraman, T., Deger, S., Alkan, M. and Cemek, M., (2002): Oxidation products of nitric oxide and the concentrations of antioxidant vitamins in parasitized goats. Acta Vet. Brono (71) 341-345.
6. Denney, C.F.; Eckmann, L. and Reed, S. L. (1999): Chemokine secretion of human cells in response to *Toxoplasma gondii* infection. Infect. Immun. 67: 547-52.
7. Esterbaur. H, Cheeseman. K. H, Danzani. M. U, Poli. G and Slater. T.F (1982): Seperation and characterization of the aldhyde products oflipid peroxidation stimulated by ADP/Fe+2C stimulated lipid peroxidation in rat *liver microsomes. Biochem. J; 208: 129-140.*
8. *Hany M. Elsheikha, Manar. S. Azab, Nashwa K. Abousamra, Mohammad H.Rahbar, Doaa M. Elghannam, Douaa Raafat(2008) :* PREVALENCE OF, RISK FACTORS FOR, AND OXIDATIVE STRESSASSOCIATED WITH TOXOPLASMA GONDII ANTIBODIES AMONGASYMPTOMATIC *BLOOD DONORS IN EGYPT* the Egyptian American scholar 35th annual conference 27-29 Dec.2008
9. Ju, C.H.; Chockalingam, A. and Leifer, C. A. (2009): Early response of mucosal pithelial cells during *Toxoplasma gondii* infection. J Immunol. 183:7420-27.
10. Katriina V., Anna K., Meiju K., Riina, N.,Unto P¨ and Eeva, M.(2009): Leptin Enhances Synthesis of ProinflammatoryMediators in Human Osteoarthritic Cartilage—Mediator Role of NO in Leptin-Induced PGE2, IL-6, and IL-8 Production. Mediators of Inflammation Volume 2009, Article ID 345838, 10 pages
11. Kunkel, S. L., N. W. Lukacs, S. W. Chensue, and R. M. Strieter. (1997): Chemokines and the inflammatory response, p. 121–131. *In* D. G. Luster, A. D. (1997). Chemokines-chemotactic cytokines that mediate inflammation. N. Engl. J. Med. 338:436–445.
12. Lage ,m., Gracia- Mayer , R.V., Tome,M.A., Cordido,F., Valle- InclanF., Considing ,R.V., Caro, J.F., Dieguez,C. and Casanueva, F.F (1999): Serum leptin level in women throughout pregnancy and the post partu7m period and inwome3n suffering spontaneous abortion. Cli. Endocrinol. 50 : 211-216.

13. Lee, J. Y., Lee, S. H., Kim, H.H., Ha, J.M., Lee, S.H. and Ha, B.J.(2004): The preventive inhibition of chondroition sulfate against the CC14-induced oxidative stress of subellular level. Arch. Pharm. Res. 27(3) 340-345.
14. Lioyd R.V., Jin,L., Tsumanu7ma ,I ., Vidal, S., Kovacs,K., Horvath. E, Scheithauer,B.W., Couce ,M.E and Burguera, B. (2001): Leptin and leptin receptor in anterior pituitary function. Pituitary 4: 33-47.
15. Makhseed, M., Raghupathy, R., Azizieh, F., Omu, A., Al-Shamali, E. and Ashkanan, L. (2001): Th1 and Th2 cytokine profiles in recurrent aborters with successful pregnancy and with subsequent abortions. Hum. Reprod 2001; 16: 2219-26.
16. Menzies, F.M. and Henriquez, F.L. (2009): Immunomodulation by the Female Sex Hormones. The Open Infectious Diseases Journal, *3,* 61-72.
17. Menzies FM, Henriquez FL, Roberts CW. Immunological control
18. of congenital toxoplasmosis in the murine model. Immunol Lett
19. 2008; 115: 83-9.
20. Meroni, V., Genco, F., Tinelli, C., Lanzarini, P., Bollani, L., Stronati, M. and Petersen, E.(2009): Spiramycin Treatment of *Toxoplasma gondii* Infection in Pregnant Women Impairs the Production and the Avidity Maturation of *T. gondii*-Specific Immunoglobulin G Antibodies. Clinical and Vaccine Immunology, Vol. 16 (10): 1517-1520
21. Montoya, J. G. (2002): Laboratory diagnosis of *Toxoplasma gondii* infection and toxoplasmosis. J. Infect. Dis. 185: S73-82.
22. Nejad, M.R., Somayeh ,J. S. Mohammad, R.and Mohammad T. F.(2011): The evaluation of interleukin-8 chemokine in chronic and acute *Toxoplasma gondii* infection Gastroenterology and Hepatology From Bed to Bench. *2011; 4(1): 34-37*
23. Nagineni C. N, Detrick B, Hooks. (2000): Toxoplasma gondii infection induces gene expression and secretion of interleukin 1 (IL-1), IL-6, granulocyte-macrophage colony-stimulating factor, and intercellular adhesion molecule 1 by human retinal pigment epithelial cells. Infect Immun. 68:407-10.
24. *Placer, Z. A., Crushman, L. and Johnson, B. C. (1966):* "Estimation of product of lipid peroxidarion" in Biochemical systems. Anal Biochem. 16: 359-64.
25. Ryan, K., Greep R. and Astwood E.(1973): Handbook of physiology vol 11 American physiology society pp285
26. Sarka, K. and Jaroslav, F. (2007): Longer pregnancy and slower fetal development in women with latent "asymptomatic" toxoplasmosis. BMC Infect. Dis.; 4: 114.
27. Soad M. Nasr (2008): Lepin as a marker for health status of animals . The Egyptian American scholar 35th annual conference 27-29 Dec.**2008**
28. Suleyman Yazar, MD, Eser Kilic, Recep Saraymen, Izzet Sahin, (2003):
29. SERUM MALONDIALDEHYDE LEVELS IN *TOXOPLASMA* SEROPOSITIVE PATIENTS, Annal of Saudi medicine vol,23pp413
30. Tenter, A. M.; Heckeroth, A. R. and Weiss, L. M. (2000): *Toxoplasma gondii*: from animals to humans. *Int. J. Parasitol.* 30:1217-1258.
31. Weissmann, J. (2003): Presumptive *Toxoplasma gondii* abortion in a sheep. Can. Vet. J. April; 44(4): 322–324.
32. Yazar, S., Demirta, F., Yalcin, S., Yaman, O., Tokgöz, B., Utas, C. and Sahin, I. (2003). Anti-*Toxoplasma gondii* antibodies in haemodialysis patients with chronic renal failure. *Yonsei. Med. J.* 44, 288–292.

THE CYTOLOGICAL DIAGNOSIS BY FINE NEEDLE ASPIRATION BIOPSY OF DIFFERENT TYPES OF CUTANEOUS AND SUBCUTANEOUS TUMORS ON COMPANY ANIMALS

Ancuța Andreea- Roxana, Dragu Corina-Claudia, Oprean O.Z
Faculty of Veterinary Medicine, Iaşi
E-Mail:anda181184@yahoo.com

Abstract
The cytological examination allows the intravital differential diagnosis of different types of tumors.
We studied 9 cases (7 dogs and 2 cats) of mobile superficial tumors, with diameters ranging between 3 and 15 cm using clinical examination and fine needle aspiration biopsy.
The cytological examination performed by usual May Grumwald Giemsa staining method led to the identification of the following types of tumors: melanoma, lipoma, plasmocytoma, mastocytoma, fibrosarcoma.

Key words: *dog, cat, tumor, cytology*

The cytological examination performed by cutaneous and subcutaneous biopuncture can be determined the nature inflammatory or noninflamatory of a lesion and also the establishment of a differential diagnosis between a benign and malign tumor.(1, 4).

The literature information confirms the presesnce of benign cutaneous and subcutaneous formations in dogs, two times larger than the malign ones. At cats the appearance of malign tumors versus benign ones is in a ratio of 3:1.(2, 3).

One study made by *Goldschmidt N. and Shofer* (2009) quote by *Marignac G.* (2010) shows an incidence of cutaneous tumors of 30% for dogs comparative with 20% cats. The higher frequency of this formations is in both species between 6 and 14 years, excepting histiocitoame and pappilomas wich are more frequent at young dogs. (5, 6).

The cytological examination can be completed with histopatological examination because this can provide information about the infiltration grade of the tumoral process.

MATERIALS AND METHODS

Investigations were made in the Pathology anathomy of Veterinary Faculty Iasi on 9 samples of biological material, provided from 7 dogs and 2 cats. The biological material was prelevated from nodular formations, adhesive or not at the cutaneous and subcutaneous tissue. The fine needle aspiration method was used for the specimens from cutaneous and subcutaneous nodular tissues and the cytological preparetions. The biopsy was realised with or without aspiration,the method is preferred for the vasculated formations. It was used needles of 21-25 Ga attached to 5 ml sirings. They were examinated at fotonic microscopy for the eataleted preparates , fixed and colored by May-Grunwald Giemsa.

While the interpretation was made, the samples were analised under microscopic caractheristics: initial with small objective (x10 , x40) for the large clases of cells (normal, tumor) after that was study every class in particular with the large objective (x90, x100).

The samples were accompanied with the informations about the presumptive diagnostic for the orientation and the interpretation of cytological examination.

RESULTS AND DISCUSSION

From the 9 samples examinated,5 were classified as malign tumors (adenocarcinom, sarcom, fibrosarcom, malign melanoma) and 4 samples-benign tumors (lipoma, mastocitomul, plasmocitoma).

From the malign tumors, adenocarcinoma of the perineal glands represents the tumor of the secretory type epithelial tissue. The sarcoma, fibrosarcoma, lipoma, plasmocitoma, mastocitoma, melanoma are mesenchimatouse tumors whit traditional classifications.(2, 3, 5).

The cytological differentiation criteria between a malign and benign tumor how based on the classification of the examined samples are presented in table 1.

Tabel 1

Cytologic criteria to differentiate between a benign and one malign proces
(after Fournel, 1994)

MALIGN TUMOR	BENIGN TUMOR
Anisocitosis/Anizocariosis	Homogenous core, crhomatine lax
Celular polimorphism	Celular monomorphism
Dense chromatine	Homogenous chromatine
Larger,irregular nucleolus	Single or multiple nucleous, normal size
Growth of the mitotic index	Unchanged mitotic index
Atipical mitosis	Normal mitosis

The perineal glands adenomacarcinama, diagnosed in a dog, presents proliferated cells in microplacard, presenting an advanced aspect of cellular anaplasia, an cellular atipism and gigantism. The core-citoplasmatic ratio is modified in core favour, gigantic core and basofilus citoplasma cell, in which is evidentiated in blue secretory inclusions in coloration MGG.(Fig 1, Fig 2, Fig 3).

Subcutaneous sarcoma was diagnosted and cytological examined in a dog, with left lung localisation, presents fusiform isolated cell or with desorganised aspect and basofilus citoplasmic elongations. The core is excentric, with a densified cromatine and 1-2 nucleous/core.(Fig 4, Fig 5).

The subcutaneous fibrosarcoma, diagnosed at two cats, on the left thorax, is considered to be a ,,soft part sarcoma''.(2)

Made from tumoral fibroblastic cells large, with basophilia citoplasma and extensions, the core is big,round or oval,with lax chromatine,with 1-2 nucleolus.(Fig 6, Fig 7).

The one of “round tumoral cells”-mastocitoma,was diagnosted by cytological examination at 2 dogs.The large mastocites have a 10-40ɥm in diameter,with a ex-centre core,round or oval and presents a large number of coarse grit,metachromatic.(Fig. 8)

In lipoma diagnosed at a 12 years dog, with wright subcutaneous axillary location, cellular proliferation is polymorphic (small to large adipocytes) 20-60ɥm, with a" honeycomb aspect".(Fig 9, Fig 10).

The interdigital cutaneous plasmocitom, only one tumor, diagnosed in a dog, with round and oval cells, with large core and coarse grit.We can observe a small nucleolus, unic, faded basophilia cellular cytoplasm and a small mitotic activity. The mature cells has a perinuclear halo, which reveals the immunoglobulins production.(Fig 11, Fig 12).

After the cytological examination, the malign melanoma-diagnosed on a dog with interdigital location, presents melanocites caractherised by intacitoplasmatic granulations, black or brown. In some cases in the same tumor we observed round cells and fusiform cells. This formationis often found in dogs cases and less in cats cases.(Fig 13, Fig 14).

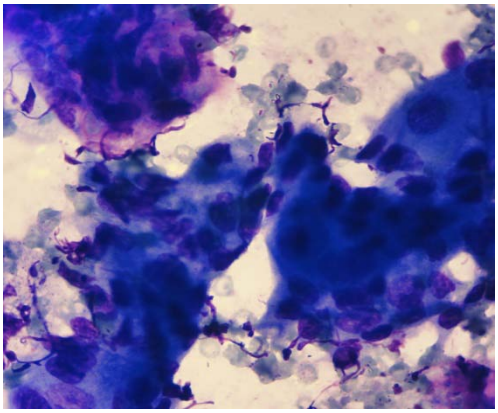

Fig. 1. Dog. Perineal glands. Adenocarcinoma.Posters of epithelial cells with adherent citoplasmas. Col. MGG, x 1000

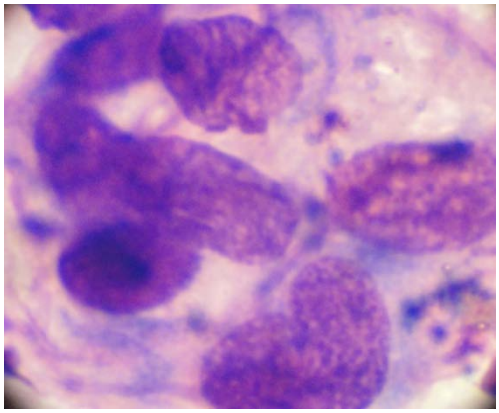

Fig. 2. Dog.. Perineal glands. Adenocarcinoma Epithelial cells secretory type. Core anizocrhomie,Diferent types of nucleolus . Col. MGG, x 1000

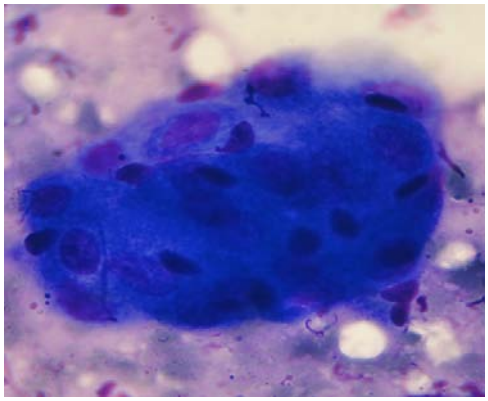

Fig. 3. Dog. Perineal glands Adenocarcinoma. Epithelial cells with anisocytosis, cytoplasmic anizocarioza and hiperbazofilia. Col. MGG, x 1000

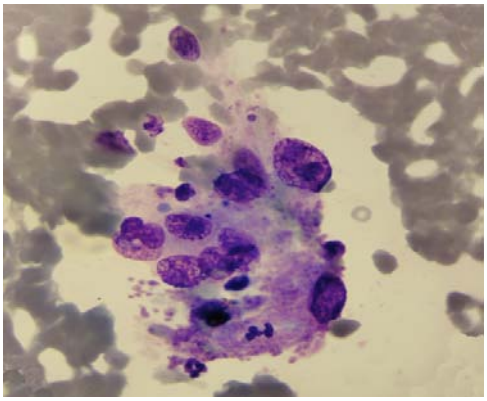

Fig. 4. Dog Subcutaneous sarcoma Fusiform cells, core with ovoid shape and a large nucleolus. Col. MGG, x 1000

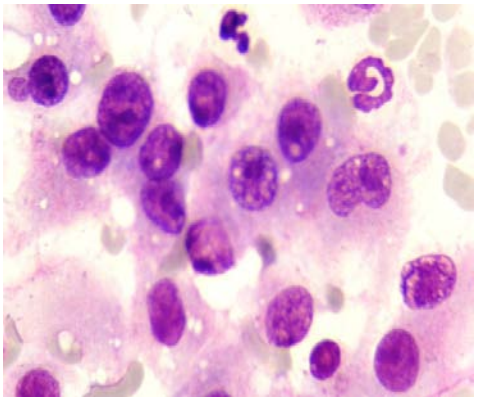

Fig. 5. Dog. Subcutaneous sarcoma. Croweded cells with fusiform (mesenchimatous). Citoplasmatic limits faded.Col. MGG, x 1000

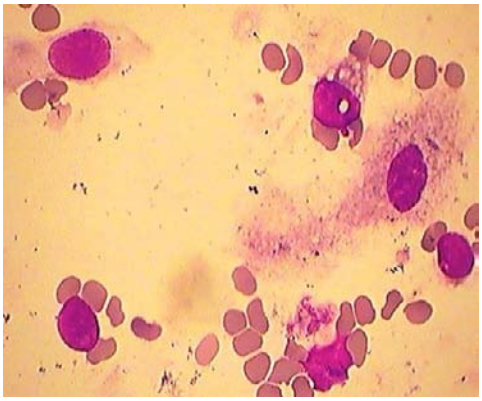

Fig. 6. Cats. Subcutaneous fibrosarcoma. Vacuolar citoplasma,large core,round or oval.lax chromatine. Col. MGG, x 1000

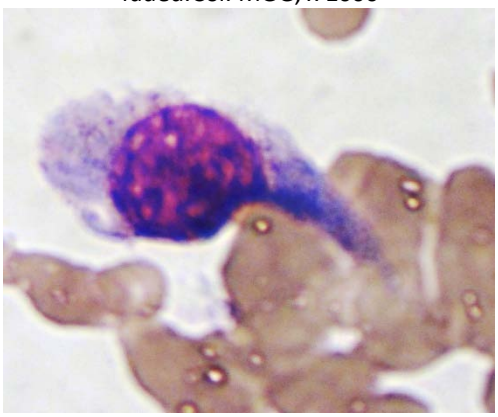

Fig. 7.Cat. Fibrosarcoma. Citological aspects from fibroblastic tumor cells,big size. Cytoplasm and its extensions net basophils. Col. MGG, x 1000

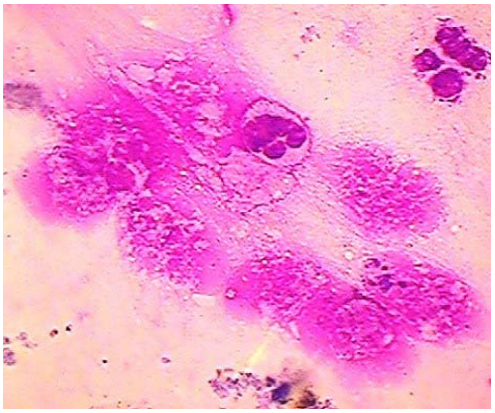

Fig. 8.Dog.–Subcutaneos mastocitoma-Round cells tumora''. Mast cells with variable sized round or oval eccentric core, with specific granulations. Col. MGG, x 1000

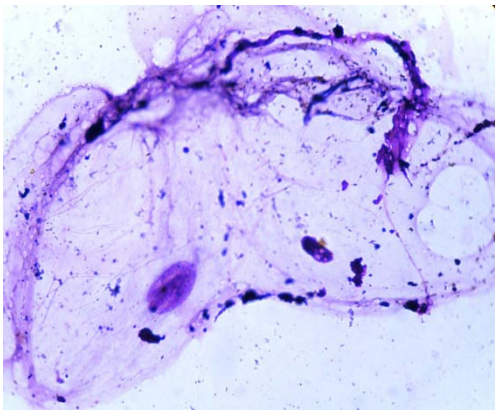

Fig. 9. Dog. Subcutaneous lipoma. Adipocytes with transparent cytoplasm. Col. MGG, x 1000

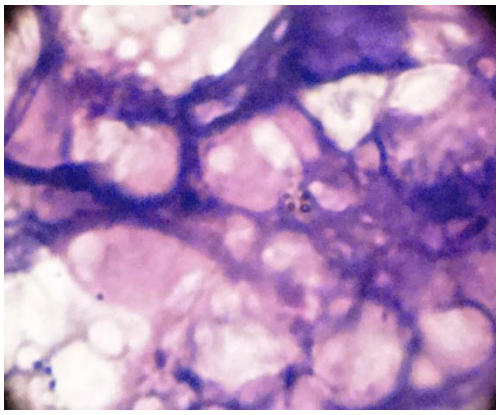

Fig. 10. Dog. Subcutaneous lipoma. Adipocytes and polymorphic cell proliferation. Cytoplasm with the apperance of honeycomb. Col. MGG, x 1000

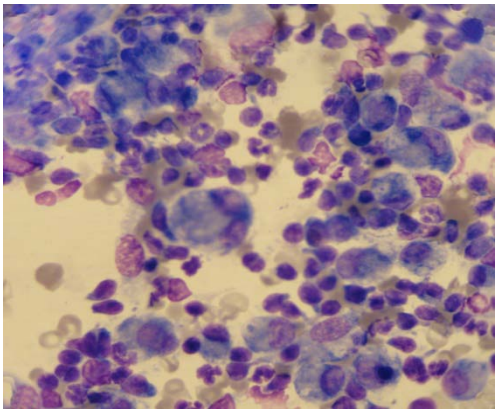

Fig. 11. Dog. Cutaneous plasmocitoma. Perinuclear halo(production imunuglobuline). Col. MGG, x 1000

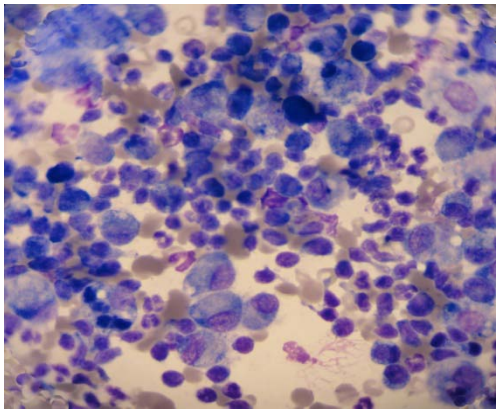

Fig. 12. Dog. Cutaneous plasmocitoma. Plasma round or oval, small, cytoplasmic basophilia. Core with a clear zone.Col. MGG, x 1000

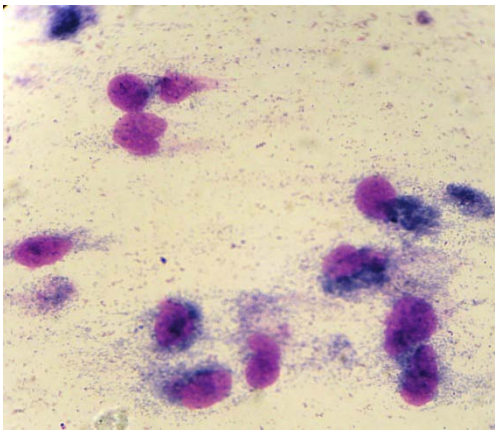

Fig. 13. Dog. Interdigital melanoma. Melanocytes with free granulations. Col. MGG, x 1000

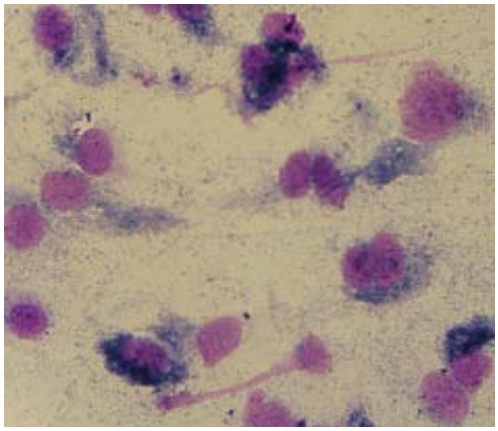

Fig. 14. Dog. Interdigital melanoma. Melanocytes. Intracytoplasmic granulations melanocytes with different shape and size. Col. MGG, x 1000

CONCLUSIONS

1.The citological examination permited the clasification of cutaneous and subcutaneous formations in the main known pathogenic classes : malign and benign tumor.

2.The microscopic examination of the cytological preparations permited the classification of the tumor from the cellular dominant type: in epithelial tumors(adenocarcinoma)and mesenchymal tumor (sarcoma, fibrosarcoma, mastocitoma , lipoma, plasmocitoma, melanoma).

3.Upon the malignity cytological criteria and interdigital location-the melanoma diagnosed on dog is considered to be on malign tumor class.

4.The cytological examination helps us to establish the certitude diagnosis in corroboration with the patient history, clinic examination and complementary examinations.

BIBLIOGRAPHY

1. Baker R., Lumsden J.H. - Atlas de cytology canine et féline, Ed. Masson Paris, 2001, p.7-17;
2. Bernex Florence - Cancerologie fondamentale - Curs de cancérologie, Ecole Nationale Veterinaire d'Alfort, 2009;
3. Cowell R.L., Tyler R.D., Meinkoth J.H. - Guide Pratique de Cytologie et Hematologie du chien et du chat, ed. Med Com, Paris, 2009;
4. Manolescu N., Balint E. - Atlas de oncocitomorfologie la canide şi feline, Ed. Curtea Veche, Bucureşti, 2009.
5. Marignac Geneviève - Introduction a la cancérologie cutanee, Curs de dermatologie, Ecole Nationale Veterinaire d'Alfort, 2010.
6. Ogilvie K.G., Moore S. A. - Manual pratique de cancerologie vétérinaire- Etude Spécifique des tumeurs, ed. Point Vétérinaire, Maison-Alfort, 1997, p.40-51.

HISTOLOGICAL AND SEM STUDIES ON THE OSTRICH'S ESOPHAGUS (STRUTHIO CAMELUS L).

***Attia,H.F; Mazher,K; Al-Kafafy ,M Rashed. R and **Abdel-Aziz,A.**
Taif University- faculty of applied medical sciences
*Histology and Cytology Dept and Anatomy Dept .Faculty of Veterinary medicine. Benha, Beni-Suief and Mineufia Universities. **Zoology Dept. Faculty of science. Cairo University.
corresponding author. drhossam222@hotmail.com

Abstract
The esophagus of 13 mature ostriches was studied using the histological technique and the scanning electron microscopy to clarify the histological structure. The esophagus in cross section appeared as narrow lumen with irregular folds appeared as finger like projections.
Numerous tubular, simple and branched and few tubuloalveolar glands were located in the contour of the lamina propria and empties their secretion into the esophagus lumen. It was strong alcianophilic in reaction. It arranged as row of tubular glands perpendicular to the epithelium
Numerous lymphocytes were distributed in the lamina propria especially around the mucous glands. Some of them arranged as lymph nodules.
The submucosa was less defined than that of the lamina propria; it consists of fibrous CT with blood vessels and nerve plexuses.
The musclosa composed of thick inner circular smooth muscle fibers and irregular thin bands of outer longitudinal smooth muscle fibers. Numerous loose CT fibers were located between the muscle fibers. The musclosa appeared thick opaque in color in comparison to the neighboring structure. The adventitia was consists of loose CT with blood vessels.
Key words. Esophagus-Ostrich-SEM-Histology

Introduction

The ostrich are used principally for the production of meat of high nutritive value, and of low cholesterol level (**Anon, 1998)**. Furthermore ostrich are used for the production of hide and feather (**Horbanczuk, Sales, Cleeda, Konecka, zinab and Kawaka 1998**). The ostrich characterized by being of lesser stature and more fertile than the other subspecies, well-developed plumage structure, docile, and easy breeding farms, character is extremely curious and friendly with humans **(Deeming, 2001**; **Camiruaga, 2004**). Regarding the General anatomical features of the digestive tract, indicate that the ostrich presents similarities and differences, both with other birds, and other herbivores. The comparative analysis with chicken, presents certain anatomical differences, one is not present crop, **Camiruaga & Simonetti, (2003)**. Few papers were dealed with the morphology and SEM of the esophagus of the ostrich as **Bezuidenhout**, **1986** ;**Cooper, & Mahroze 2004** , **Illanes et al., 2006** and **Tivane, 2008** . The aim of the present work was to throw more focus light on the histological and SEM structure of the ostrich's esophagus.

Material and Methods

The samples taken from 13 adult mature ostriches apparent healthy, with a range of 1.5 to 3 years old, from El-Shrouk abattoir in Cairo. The esophagus mainly measured 83 cm from the neck to the beginning of the stomach. It was divided into 8 parts. It fixed in formalin buffered 10 %, followed by the usual procedure of histological technique. The cuts were made 5 µ thick; they were stained with general and histochemical stains (These methods after **Bancroft, Cook, Stirling and Turner (1994**).

Small specimens from the different parts of the esophagus at all ages were fixed in a solution of 2.5 % glutaraldehyde in 0.1-M cacodylate buffer at pH 7.4 for 24 hours. The specimens were washed in two changes of 0.1 cacodylate buffer at pH 7.4, post fixed for 2 hours in 1 % osmium tetroxide in 0.1 M cacodylate buffer at pH 7.4, and washed in the same buffer (3 changes of 15 minutes each). They were then dehydrated in and ascending series of ethanol solutions (15 % - 95 %) and one change in absolute alcohol, and critical-point dried through CO2 (**Caceci, 1984).** Specimens were sputter-coated with gold/palladium for 5.0 minutes and examined with a JEOL JSM-35C at 10 kV scanning electron microscope operating at Al-Azhar University (Central Research unit).

Result

The esophagus in cross section appeared as irregular lumen with different size folds which appeared rough and covered by stratified squamous epithelium non keratinized (Fig.1). These folds were thick at the base and thin at the top and appeared as finger like folds of different size (Fig.2).

The stratified epithelium was appeared rough, flat and crowded. It covered by filamentous fibers of different thickness. Many openings of the glands occupied the sides of the folds. (Fig.3). The core of the folds made up of the lamina propria which was well developed dense fibrous connective tissue mainly cellular and less fibrous and consisted of collagen and few reticular fibers. (Fig. 4 and 5).

Numerous tubular simple and branched and few tubuloalveolar glands were located in the contour of the lamina propria as simple and branched tubular and some what tubuloalveolar glands (Fig.6).

It empties their secretion into the esophagus lumen through the thick stratified squamous epithelium via the excretory ducts which were lined by stratified epithelium and were positive alcian blue (fig.7).

The esophageal glands showed very strong reaction to alcian blue. It arranged as row of tubular glands perpendicular to the epithelium (Fig. 8).

Thin sheet of smooth muscle fibers longitudinally arranged represent the LMM (lamina muscularis mucosae) and separate the propria from the submucosa (Fig. 9)

Numerous lymphocytes were distributed in the lamina propria especially around the mucous glands. Some of them arranged as lymph nodules. This lymph nodule consists of a crypt which start at the bottom of the fold and restricted to the lamina propria (fig. 9).

The submucosa was less defined than that of the lamina propria; it consists of fibrous CT, mainly consisted of collagen fibers with blood vessels and nerve plexuses (Fig.10).

The musclosa composed of thick inner circular smooth muscle fibers and irregular thin bands of outer longitudinal smooth muscle fibers. Numerous loose CT were located between the muscle fibers (Fig.4 &11). The musclosa appeared as thick and opaque in color in comparison to the neighboring structure. The adventitia was consists of loose CT with blood vessels (fig.12).

Discussion

The esophagus mucosa was folded and consists of different size folds of irregular size and finger like in appearance. These results were supported by **Salem (1982)** in duck **; El-Zoghby,2000** in turkey **Olah et al., 2003 in** chicken , **Bayer et al.,(1975)** in chicken **Illanes et al., 2006** in ostrich and **Ahmed et al., 2009** in varanus niloticus esophagus. In the mammals these folds appeared as microridges located on the surface epithelium of the rabbit esophagus **Shasha'a et al.,1993** and in rat esophagus **Aharinejad, 1990.**

The epithelium of the esophageal mucosa in the ostrich is stratified non keratinized, as that described in turkey, which appeared incomplete or non keratinized **(El-Zoghby,2000)** while in immature pigeon, **El-Bahay (1979)** found that, the mucosa of upper esophagus was lined by stratified squamous slightly keratinized epithelium, which showed well-developed papillary bodies and highly keratinized in adults pigeon as mentioned by **Mohamed (1989)** and in ruminants mucosa presents a high degree of keratinization, while, it was mild in the horse (**Stinson & Calhoun, 1993**).

Numerous tubular, simple and branched and few tubuloalveolar glands were located in the contour of the lamina propria and empties their secretion into the esophagus lumen through the numerous ducts opening that pass via the thick stratified epithelium. It arranged as row of tubular glands perpendicular to the epithelium. As that located in the La gallina **(Dieter Dellmann & Eurell, 1998)**. On the other hand, **Delhon et al (1984),** indicate that the shape of these glands is highly variable among various portions of the esophagus. In other species, such as the ruminant horse, pig, the mucosa lacks these glands (**whisker & Wood, 1991**).

It was strong alcianophilic in reaction. Similar findings were reported by **Suganuma, Katsuyama, Tsukahara, Tatematsu, Sakaura, and Murata (1981)**: in the the Japanese quail (Coturnix coturnix japonica), domestic pigeon (Columba livia), grey starling (Sturnus cineraceus), and tree sparrow (Passer montanus), and **El-Zoghby, 2000** in turkey.

The propria consisted of dense CT mainly cellular less fibrous, collagen fibers and few reticular fibers. The CT forms the core of the folds of the esophagus. Similar results were supported by **Illanes et al., 2006** in ostrich. On the other hand the connective tissue interface of the rat esophagus does not have the coiled and branched papillae seen in esophagus of adult humans **(Hull and Warfel 1986).**

Thin sheet of smooth muscle fibers represented the lamina muscularis mucosae in the esophagus of the ostrich in our study. In contrast to this result, **Illanes et al., 2006** detect thick layer of smooth muscle fibers longitudinally arranged in ostrich. In the La gallina and turkey presents two layers, an internal circular arrangement, formed by thin fascicles which are not always visible, and other highly developed longitudinal external (**Delhon et al 1984 and El-Zoghby,2000)**. According to **Dieter Dellmann & Eurell, 1998**, muscle of domestic poultry mucosa is made only by a layer of smooth muscle fibers arranged longitudinally.

The submucosa was less defined than that of the lamina propria; it consists of fibrous CT with blood vessels and nerve plexuses. Similar results were achieved by **Illanes et al., 2006** in ostrich esophagus and in hen **Hodges (1974)** and **Ahmed (1977)**. In the ostrich, esophageal submucosa as in chicken and turkey, lacks glands (**Dieter Dellmann & Eurell, 1998 and El-Zoghby,2000)**, while in the horse and ruminants, these glands are present, but only seen in first part (**Stinson & Calhoun 1993**). These glands occupied the whole submucosa as in dog **(Dieter Dellmann & Eurell, 1998)**

The musclosa composed of thick inner circular smooth muscle fibers and irregular thin bands of outer longitudinal smooth muscle fibers. Numerous loose CT fibers were located

between the muscle fibers. These results were augmented by **(Delhon et al., 1984, Dieter Dellmann & Eurell, 1998** and **Bacha & Wood (1990)**.in hen and **El-zoghby,2000** in turkey. while in the ruminant consists of striated muscle, which extends from the esophagus to the reticulum while in the horse this striated muscles covers two-thirds proximal esophagus, but is gradually changing to smooth muscle in the distal third (**Stinson & Calhoun 1993**).
The male ostrich uses the esophagus to cause a rumbling sound when inflated it with air which subsequently leaves escape (**Association Gemial of breeders of Avestruces of Chile, 2005)**.

Numerous lymphocytes were distributed in the lamina propria especially around the mucous glands. Some of them arranged as lymph nodules. Similar results were detected by **Olah et al., 2003** in chicken **and Illanes et al., 2006** and **on** the other hand **Kitagawa, Hashimoto, Kon and Kudo (1988)** studied the distribution of chicken globule leukocytes detected by anti-thymocyte serum. The esophageal mucosa contained no globule leukocytes.

References

1. **Aharinejad S (1990):**. The morphology of the esophageal mucosa of the rat: a scanning electron microscopic study. Gegenbaurs Morphol Jahrb. 990;136(1):69-73.
2. **Ahmed, H. H. A. (1977):** Studies on digestion in pekin ducks. M. V. Sc. Thesis presented to faculty of Vet. Med. Cairo University.
3. **Ahmed YA, El-Hafez AAE, Zayed AE (2009)**: Histological and Histochemical Studies on the Esophagus, Stomach and Small Intestines of Vara-nus niloticus. j vet anat 10 ,35-48.
4. **Anon, A(1998):** Policy for grading ostrich skins. Ostrimark SA Co-op. Alexandria, South Africa**.**
5. **Association Avestruces** breeders craft of Chile. Anatomy of the ostrich. http://www.acac.cl/fia/fiamain.htm, April, **2005**.
6. **Bancroft, J.D; Cook, H.C; Stirling, R.W and Turner, D.R(1994):** '' Manual of histological techniques and their diagnostic application' .2nd Ed., Churchill Livingstone, Edinburgh, London, New York.
7. **Bacha, W. J. and Wood, L. M. (1990):** Color atlas of veterinary histology. Lea & Febiger ,Philadelphia . London.
8. **Bayer RC, Chawan CB, Bird FH.(1975)**: Scanning electron microscopy of the chicken crop--the avian rumen. Poult Sci. 1975 May;54(3):703-7.
9. **Bezuidenhout, A. J.(1986)**: The topography of the thoraco-abdominal viscera in the ostrich (Struthio camelus). Onderstepoort J Vet Res. 1986 Jun;53(2):111-7.
10. **Caceci, T. (1984) :** A gravimetric formula for Erlandson's Maraglas, D. E. R. 732 embedding medium. TSEM. Journal 15: 26-27.
11. **Camiruaga, M. & Simonetti, C.(2003)**: Avestruces, his food and digestive system. Rev. Agronomy and forestry UC, 12C0:10 - 4, 2003.
12. **Camiruaga, M.(2004):** The ostrich. Production system in Chile. Foundation for agricultural innovation. Santiago, FIA, 9-25, 2004.
13. **Cooper, R & Mahroze, K.(2004)**: Anatomy and physiology of the gastro-intestinal tract and growth curves of the ostrich)(Struthio camelus). Animal Science j., 75:491 - 8, 2004.

14. **Deeming, D. C.(2001)**: Introduction. In: The ostrich: biology, production and health. Zaragoza, Acribia,. pp1-11.
15. **Delhon, G. Fernández-Surribas, j.; Gagna, g.; Lacolla, D. & von Lawzewitsch, I.(1984):**Gut of domestic birds. In: Lessons from veterinary histology. Hemisphere South, Buenos Aires, pp. 45-111.
16. **Dieter Dellmann, H. & Eurell, J (1998):** Textbook of Veterinary histology. 5 th ed. Philadelphia, Lippincott Williams & Wilkins, 1998.
17. **El-Bahay (1979)**: Physiological studies of the digestive system of pigeons. Ph.D. Thesis presented to faculty of Vet. Med. Zagazig University.
18. **El-Zoghby.I.M (2000)**: Histological and histochemical studies on the digestive tract of turkeys at different ages. Ph.D faculty of vet. Med. Zagazig Uni. Benha branch.
19. **Hodges, R. D. (1974):** The histology of fowl. 1st Ed., University of London. Academic Press, London, New York. San Francisco. Pg. 45 - 88.
20. **Horbanczuk, J; Sale, J; Celeda, T; Konecka, A; Zinaba, G and Kawaka, P (1998):** Cholesterol content and fatty acid composition of ostrich meat as influenced by subspecies. Meat Sci., (50): 385-388.
21. **Hull M.T and Warfel K.A (1986):** Basal lamina at the epithelial-connective tissue junction in the rat fore stomach, esophagus, tongue and palate: Scanning electron microscopic study. Scan Electron Microsc. 1986;(Pt 4):1395-401.
22. **Illanes, j; Fertilio, B; Chamblas, M.; Leyton, V. and Executioner, F. (2006)**: Histological description of the different segments of the digestive ostrich apparatus)(Struthio camelus var. domesticus). Int'l. J. Morphol., 24 (2) : 205-214.
23. **Kitagawa, H. Hashimoto, Y Kon Y and N. Kudo (1988)**: distribution of chicken globule leukocytes detected by anti-thymocyte serum. J.Vet.Sc.50:638-647.
24. **Mohamed, S .A. (1989):** Some histological and histochemical studies on the esophagus and stomach of pigeon (Columbia Livea) with reference to age variation. M. V. Sc. Thesis presented to faculty of Vet. Med. Zagazig University.
25. **Olah N; Nagy .A. Magyar and V. Palyat (2003)**: Esophageal tonsil: a novel gut-associated lymphoid organ. Poultry science 82: 767-770.
26. **Salem, H. F. (1982):** Morphological studies of the esophagus and stomach in growing Sudanese ducks. M.V.Sc. Thesis presented to the faculty of Vet. Med., Zagazig University.
27. **Shasha'a S, Dickson GR, Gilmore RS, Crean GC, Butt MM, Carr KE.(1993)**: Rabbit and human non-keratinizing stratified squamous oesophageal epithelium displays similar microridge structure by scanning electron microscopy. Scanning Microsc. 1993 Sep;7(3):953-8; discussion 958-9.
28. **Stinson, a. w. & Calhoun, M. L (1993)** :Digestive system In: Dieter Dellmann, H. histology veterinary. Zaragoza, Acribia . pp. 239-56.
29. **Suganuma, T.; Katsuyama, T. ;Tsukahara, M .; Tatematsu, M. ;Sakaura, Y .; and Murata, F. (1981):** Comparative histochemical study of alimentary tracts with special reference to the mucous neck cells of the stomach. Amer. J. Anat., 161: 219 – 238.
30. **Tivane C., (2008):** A morphological study of the oropharynx and oesophagus of the ostrich (Struthio camelus). MSc dissertation, Faculty of Veterinary Science, University of Pretoria, South Africa.
31. **Whisker w. j. & Wood l. M. (1991)** Apparatus digestive system. In: Atlas histology veterinary color. Good Aires, Inter-Médica, 1991.

List of figures

Fig.1: Esophagus the ostrich showing thick stratified squamous epithelium non keratinized. H&E X 20 bar100 um.

Fig.2: Esophagus the ostrich showing different size finger like folds of the esophagus mucosa, thick at base and thin at top. SEM X25 bar 1um.

Fig.3: Esophagus the ostrich showing the opening of the esophageal gland ducts (arrow). SEM X1800 bar 10um.

Fig.4: Esophagus the ostrich showing the dense fibrous CT of the lamina propria which consists of collagen fibers (c), note submucosa (sm) and musclosa (M) . Crossmon's trichrome, X10 bar 200um.

Fig.5: Esophagus the ostrich showing the dense fibrous CT of the lamina propria which consists of few reticular fibers (R). Gomori reticulin method, X10 bar 200um.

Fig.6: Esophagus the ostrich showing the tubular glands, simple (1) and branched and tubuloalveolar(2) glands . H&E X20 bar 100um.

Fig.7: Esophagus the ostrich showing; strong positive alcian blue reaction in the mucous gland cells and cells of the excretory ducts. Alcian blue X10 bar 200um.

Fig.8: Esophagus the ostrich showing the tubular glands, it appeared perpendicular to the stratified epithelium (Arrow), note lamina propria (LP) and openinings of the excretory ducts (D) . SEM X1300 bar 10um.

Fig.9: Esophagus the ostrich showing the lymph nodule (LY) which consists of a crypt which start at the bottom of the fold, note thin sheet of the of the LMM(Arrow) . H&E X10 bar 200um.

Fig.10: Esophagus the ostrich showing the submucosa , it consists of fibrous CT with blood vessels (BV) and nerve plexuses. SEM X4000 bar 5um.

Fig.11: Esophagus the ostrich showing the tunica musclosa (M), which composed of thick inner circular smooth muscle fibers and irregular thin bands of outer longitudinal smooth muscle fibers. H&E X10 bar 200um

Fig.12: Esophagus the ostrich showing the musclosa (M) which appeared as thick band opaque in color in comparison to the neighboring structure and the tunica adventitia which consists of loose CT (Arrow) . SEM X 350 bar 50um.

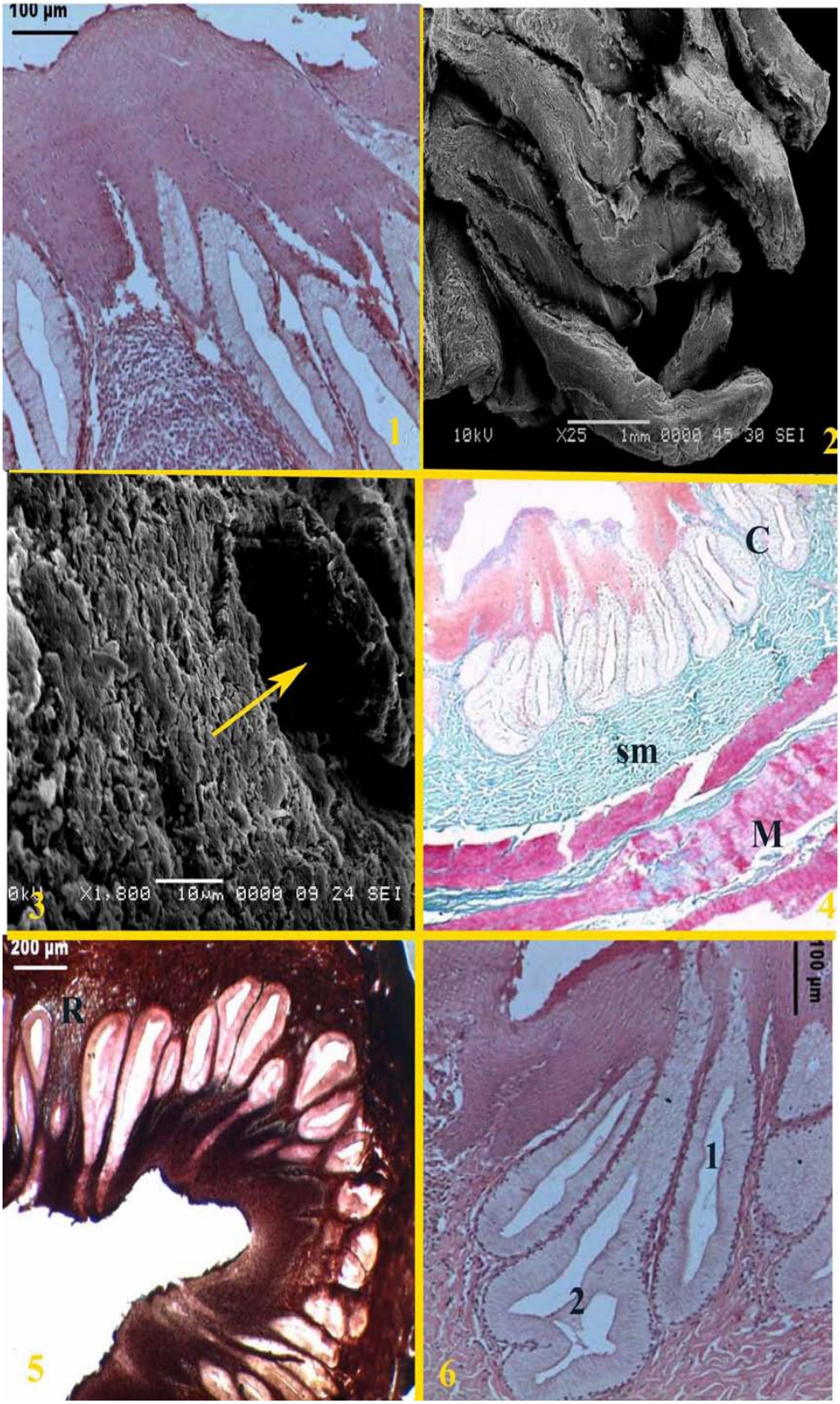
100 µm
1
10kV X25 1mm 0000 45 30 SEI
2
0kV X1,800 10µm 0000 09 24 SEI
3
C
sm
M
4
200 µm
R
5
100 µm
1
2
6

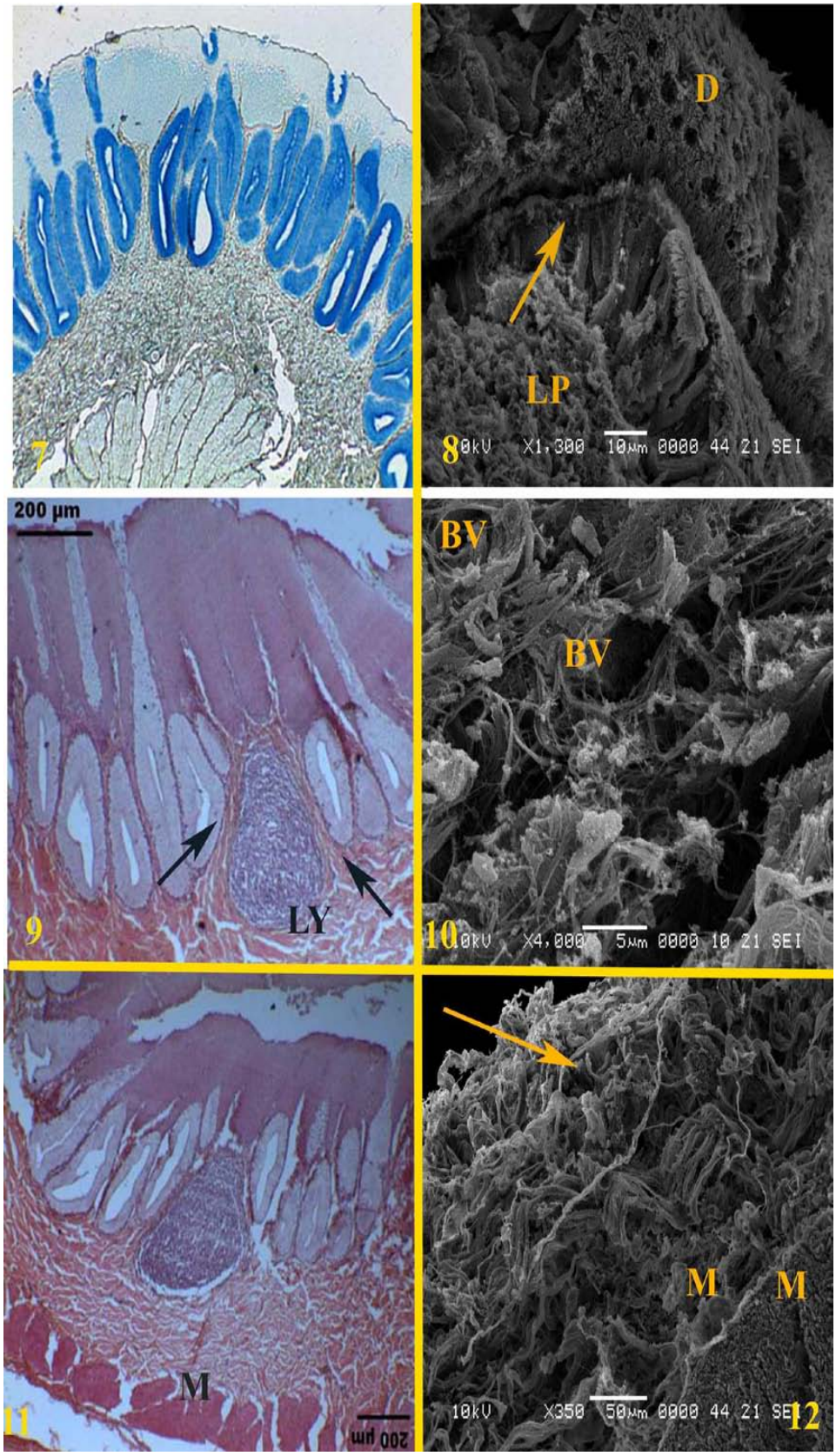
7
D
LP
8
0kV X1,300 10µm 0000 44 21 SEI
200 µm
9
LY
BV
BV
10
0kV X4,000 5µm 0000 10 21 SEI
M
11
200 µm
M
M
10kV X350 50µm 0000 44 21 SEI
12

BONE DEPROTEINIZATION SKIPJACK *(Katsuwonus pelamis* L) WITH NaOH IN CONCENTRATION AND TIME DIFFERENCE HYDROLISIS

Betty BAGAU[1] and Hendronoto Arnoldus W. LENGKEY[2]
[1]Faculty of Animal Husbandry University of Sam Ratulangi Manado, Indonesia
[2]Universitas Padjadjaran, Bandung, Indonesia
E-mail betty_bagau@yahoo.com, hawlengkey@yahoo.com

INTRODUCTION

In tuna fish processing business is handled in large and small scale industrial waste generated both solid waste and liquid waste that has not been fully utilized, and the wastes can cause environmental pollution. Tuna has around 61.79% as edible portion, the part that can be eaten, while the remaining 38.21% are waste including bone parts (Prih *et al.* 1982). According to Lengkey, et al (2011), even there are indicated that skipjack tuna gill meal in ration has no significantly effect on broiler carcass, but it can replace the function of fish meal in the ration.

Tuna fish bone *(Katsuwonus pelamis* L**)** as well as animal bones in general, containing intercellular substance (about 70%) and the 30% remains, as inorganic salts of organic matrix. 95% of the organic component is formed from collagen, the basic substance of the remainder consists of proteoglycan and non-collagen molecules that appear to be involved in the regulation of bone mineralization. Collagen in the bone is approximately half of the total body collagen, and its structure is similar to the collagen in other tissues binder. Almost all of it, is type I fiber. Three-dimensional space on the structure called hole zones, are home to deposits of minerals.

The contribution of the basic substance of proteoglycan in bone has much smaller proportion than in the cartilage, mainly composed of chondroitin sulphate and hyaluronic acid. The basic substances that controlling water content in the bone, and possibly involved in regulating collagen fiber formation. Non-collagen organic material consists of osteocalcin (osla proteins) involved in the binding of calcium during the mineralization process, osteonectin that serves as a bridge between collagen and mineral components, sialoprotein (rich in salicylic acid) and some other proteins. Inorganic matrix is minerals which consists mainly of calcium and phosphate in the form of hydroxyapatite crystals. The crystals are arranged along the collagen fibers. Bone hardness depends on the concentration of inorganic material in the matrix, while the strength depends on the organic materials, particularly collagen fibers.

Collagen is part of the protein fibers or fibrous proteins that have multiple polypeptide chains linked by a variety of crosslinking to form *a triple helix.* Collagen is the protein part of the stromal type. These proteins can not be extracted with water, diluted acid, alkali or salt solution at a concentration 0.01 to 0.1. Collagen can expand because of its molecular tissue structure weakened because of the treatment given when the pH below 4 or increased to 10.

In the manufacture of bone gelatin or the use of bone as a source of minerals then the fat and non-collagen protein should be reduced to the minimum, deproteinization is a process that aims to eliminate or dissolve the protein as much as possible from the substrate, usually done by using a chemical solution that is alkaline (Suryani *et al*., 2005).

MATERIALS AND METHOD

Materials

Materials are solid waste processing tuna fish bone in the form of components, and the chemicals used were NaOH solution. The tools are: scales, knives, waste container.

Research Procedure

Deproteinization carried out with sodium hydroxide solution, at various concentrations and longer processing time. Before deproteinization with NaOH washing, reduction of bone size and cooking in boiling water to facilitate spending on the remnants of meat (non-collagen protein), and the layers that contain fat deposits. Removing of fat from the bone tissue (degreasing), conducted at a temperature between the melting point of fat and bone albumin coagulation (between 32-80^{0}C) to produce an optimum fat solubility (Junianto, *et al*, 2006).

Research Methods

This study uses Factorial Completely Randomized Design Patterns 3 X 4 replications 3 times where the factors are : A = the concentration of alkali (given the symbol K) and B = processing time (given the symbol W). Factor A: the concentration of NaOH (K_1 = 2%, K_2 = 3%; K_3 = 4%) Factor B: Processing Time (W_1 = 12 hours; W_2 = 24 hours; W_3 = 36 hours; W_4 = 48 hours).

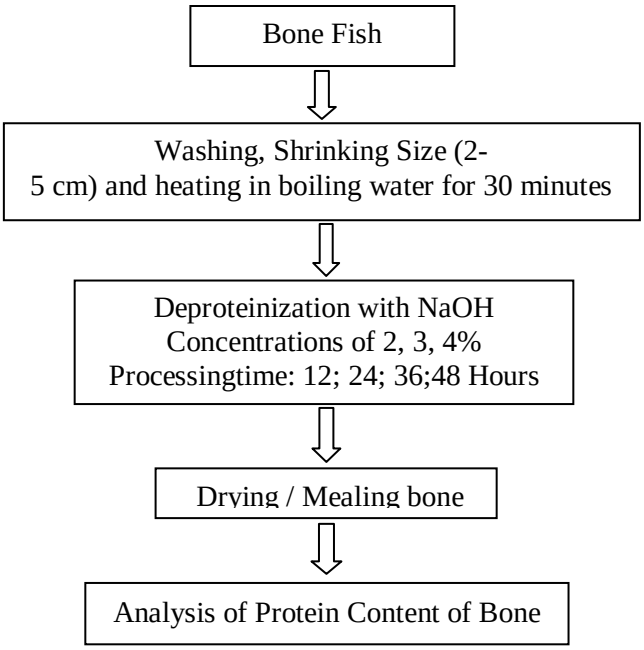

RESULTS AND DISCUSSION

Research on the use of NaOH as a source of lye to changes in bone protein content of tuna *(Katsuwonus Pelamis* L) shown in Figure 1.

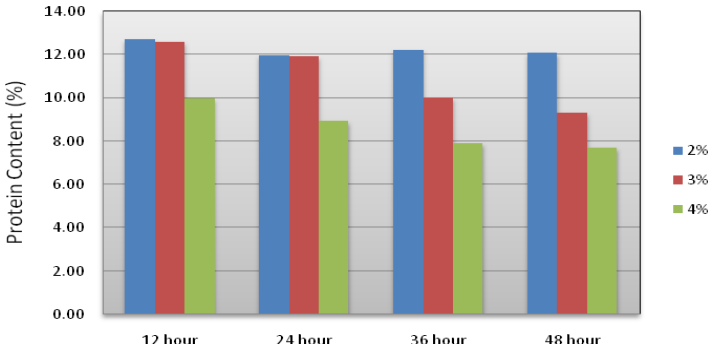

Figure 1. Effect of treatment on protein content (%)Skipjack Bone *(Katsuwonus pelamis* L).

In Table 1, shows that the combination treatment of K_4W_4 (NaOH concentration of 4% with hydrolysis time 48 h) gives the most highly hydrolyzed protein as indicated by the lowest protein content of 7.71%, while the protein hydrolyzed the most. The lowest is a combination treatment of K_1W_1 (concentration of 2% NaOH with hydrolysis time of 12 hours) that still contains the highest protein of 12.70%.

Table 1.Duncan Test Results (Effect of NaOH Concentration on Protein Levels of Bone Skipjack *(Katsuwonus pelamis* L).

Treatment	The average protein content	Significance (0.05)
	… … … ..% … … … ….	
K_1	12:24	a
K_2	10.97	b
K_3	8.64	c

Information.: Different letters indicated significance in columns (P <0.05)
K_1 = Concentration of NaOH 2%, K_2 = concentration of NaOH 3%; K_3 = Concentration of NaOH 4%.

By analysis of variance, showed that the concentration of NaOH and the duration of hydrolysis time, has significant (P <0.01) effect on protein content of tuna fish bone, means that protein content changes because the concentration and the duration of hydrolysis by NaOH. Furthermore, to know the difference between treatments is using Duncan's test, are presented in Table 2.

Based on Duncan's test data in Table 2, K_3 treatment (concentration of NaOH 4%) gives lowest bone protein content (8.64%). This means that the higher concentration of NaOH will cause more hydrolizable Skipjack (*Katsuwonus pelamis* L) bone protein. The results are consistent with the opinion of Stevens and Verhe (2004) that the protein

components in the form of bone collagen will be hydrolyzed if the pH is increased up to pH 10.

Table 2. Duncan Test Results of Hydrolysis Time with NaOH against Skipjack *(Katsuwonus pelamis* L) Bone Protein Levels.

	… … … ..% … … … ….	
W 1	11.76	a
W 2	10.94	a
W 3	10:05	ab
W 4	9.70	b

Information : Different letters indicated significancy in columns (P <0.05)
W_1 = 12 Hours Hydrolysis, W_2 = 24 Hours Hydrolysis, W_3 = 36 Hours Hydrolysis; W_4 = 48 Hours Hydrolysis

In Table 2, according to Duncan test, W_4 (48 hours) has the lowest levels of bone protein (9.70%) this means that the length of hydrolysis time, would result more hydrolizable Skipjack *(Katsuwonus pelamis* L) bone protein. This results are similar with Bagau (2010), that using of 4% NaOH solution concentration for 24 hours at room temperature, dried and milled, processed tuna bone still has 10.29% protein content.

CONCLUSION

Results and discussion indicated, the influence of concentration and time of deproteinization NaOH hydrolysis, as measured by the levels of hydrolizable bone protein, can be concluded that the concentration of NaOH 4% with 48 hours hydrolysis time, give the lowest of bone proteins tuna *(Katsuwonus pelamis* L).

REFERENCES

1. Bagau, B., 2010. Pengolahan Limbah Padat Ikan Cakalang (*Katsuwonus pelamis* L) dengan HCl dan NaOH. UNPAD. Bandung.
2. Junianto, Kiki H, Ine M, 2006. Produksi Gelatin dari Tulang Ikan dan Pemanfaatannya Sebagai Bahan Pembuatan Cangkang Kapsul. Laboran Penelitian Hibah Bersaing. Depatermen Pendidikan Tinggi.
3. Lengkey, Hendronoto A.W., Tuti Widjastuti, Maya Ludong, 2011. Various levels effect of Skipjack tuna gill meal (Katsowunus pelamos L) in ration on broiler carcass and abdominal fat. Lucrari Stiintifice Seria Zootehnie Vol. 55 (16), Editura Ion Ionescu de La Brad, Iasi, Romania. p 237-239.
4. Prih, S., A. Poernomo, D. Suryaningrum dan S, Ilyas, 1982. Evaluasi Kandungan Protein Ikan Indonesia. Laporan Penelitian Teknologi Perikanan DEPTAN. Jakarta.
5. Stevens, C.V and Verhe, R.G. (2004) *Renewable Bioresources, Scope and Modification for Non-Food Applications,* John Wiley & Sons Ltd, Chichester
6. Suryanti, S. Hadi, R. Paranginangin, 2006. Ekstraksi Gelatin dari Tulang Ikan Kakap Merah (*Lutjanus sp*) Secara Asam. Jurnal Pascapanen dan Bioteknologi Kelautan dan Perikanan Vol. 1 No. 1.

MORPHOLOGICAL, HISTOLOGICAL AND CYTOGENETICS ASPECTS IN MALE PSEUDOHERMAPHRODITES DOMESTIC PIGS (*SUS SCROFA DOMESTICA*)

CIORNEI Cristina[1] , COTEA C.V.[1], SOLCAN Carmen[1], BEEK Josine[2], CORNILLIE P.[2]
[1] Department of Preclinics, The Faculty of Veterinary Medicine, Iasi, Romania
ciornei.cristina@gmail.com
[2]Department of Morphology, The Faculty of Veterinary Medicine, UGent, Belgium

Intersexuality has been reported in numerous species including cows, goats, swine and dogs. The present paper is an overview of the variety of anatomical aspects of male pseudohermaphroditism condition in domestic pigs.
An intersex animal can be defined as an individual which possesses gonads of both sexes (ovaries and testis) and presents the genital tract opposite the gonads. But the phenomenon on intersexuality is more complex. For establishing the "sex" of an individual, because of the complex nature of the process, it is required the use of more specific criteria rather than just anatomical ones (macroscopic or microscopic)- such criteria more relevant than the previous ones are the ones that determine the genetic characteristics, hormonal status, but also the behavioral analysis.
Through the chromosomal analysis of somatic cells, the genetic sex of these individuals can be established. The identification of gonads must be done microscopically and macroscopically in order to determine the gonadic sex. From a hormonal point of view, the task is more difficult: as opposed to human medicine where usually the testosterone level is measured, in veterinary medicine we have to consider breed, age, nutrition, fertility treatments and other factors.
The study was conducted on four genital tracts from slaughtered pigs. In order to determine the genetic sex of these individuals, in some of the cases we took vaginal mucosa smears for evidentiation of chromatin X and blood smears for evidentiation of drumstick in neutrophils.
In our four cases the ovaries were replaced by large testicles covered by epidydymis. In all of our cases the testis had a globular shape and in one case, one of the testes was smaller than the other. Male pseudohermaphrodites also presented aspermatogenic testes, and in live animals they were descended into the scrotum.
The junction between the male and the female parts it was made between the epidydymis and the oviduct.
In one case we saw macroscopically structures that looked like male accessory glands, very small as size and histologically it appear to be only the prostate.

Keyword: *male pseudohermaphroditism, swine, testis, ovary, prostate, chromatin X.*

Introduction

Swine husbandry represents the sector with the largest share in both world`s animal husbandry but also in Romania.

The forms of intersexuality in domestic animals, occupies an important role in genital pathology and represents one of the forms of congenital sterility manifestations - the incidence of intersexuality in pigs is higher than in other domestic animals. Intersexuality in pigs is a delicate and complicated problem because of a large number of

phenotypes, but also because in human medicine, the term "hermaphrodite" tends to define any anomaly of any kind of the genital tract.

Intersexuality is a rare congenital abnormality in domestic animals. It can be classified from morphological point of view in true hermaphrodites, male pseudohermaphrodites and female pseudohermaphrodites; but also from genetically point of view in male XX (XX sex reversal), female XY (XY sex reversal), testicular feminization syndrome and freemartinism.

The male pseudohermaphroditism (PHM) characterizes individuals whose gonads are testes, and internal and external genitalia shows an ambiguous differentiation, being more or less oriented towards female gender.

The most important characteristic of PHM is the regression of the penoscrotal organs from the uro-genital membrane and urogenital sinus development predisposition for female gender. (Cîrlan M., 2006)

Matherial and methods

During the period of march - may 2011 in the Department of Preclinics from the Faculty of Veterinary Medicine, USAMV Iasiand the Department of Morphology from Faculty of Veterinary Medicine from University of Gent, Belgium we have examined four cases of male pseudohermaphrodites pigs from different farms or slaughterhouses – pigs which presented anatomical aberrations of the genital tract and the principal aspects and findings will be presented in this paper.

The genital tracts were examined macroscopically and microscopically.

For histological tests, fragments were harvested and fixed in phosphate – buffered 3,5% formaldehyde and Bouin solution for 24 - 48 hours. After fixation, the samples were embedded in paraffin, series sections were made at 8 microns and stained HE, Van Giesson, Masson`s trichrome, Feulgen and Lillie`s reactions for nucleic acids. The sections were analyzed with an Olympus BX 61 light microscope.

The vaginal mucosa smears for chromatin X were stained with cresyl violet and orcein and the blood smears for the drumstick from neutrophils were stained with May-Grümwald Giemsa solution.

Results and discussions

Male pseudohermaphrodites are individuals that posses testis instead of ovaries and the genital tract is characteristic for females

Female pseudohermafrodites are individuals with ovaries instead of testis and the genital tract is orientated towards the male sex – but in three years of pigs intersexuality research we didn`t saw this kind of individuals.

One characteristic of intersex pigs is the enlarged and prominent clitoris and the ventral commissural of the vulva orientated dorsal, which appears to be one characteristic that guides the breeder to realize that he has an intersex animal in herd (Hunter R.H.F., 1982; Hunter R.H.F. et al., 1996; Cornillie P. et al., 2009).

The two alive gilts, beside the female phenotype (through the presence of vulva, vulva orifice and the clitoris), it was also observed, a male characteristic phenotype – scrotum in normal position with a medial line that separated the two testis. (fig.1) (Ciornei Cristina et al., 2009, Ciornei Cristina et al., 2010)

In one of the alive gilts, after slaughter we saw that the genital tract was composed out of two small testis (approximately 50 g each) from which started two thin deferent ducts and they were going to the vaginal vestibule (fig.2). The testes were surrounded by a large epididymis, covering ¾ from the surface of the testis. This was the only case that also had a "heart" shaped gland (fig.3) – microscopically proving to be the prostate (fig.4).

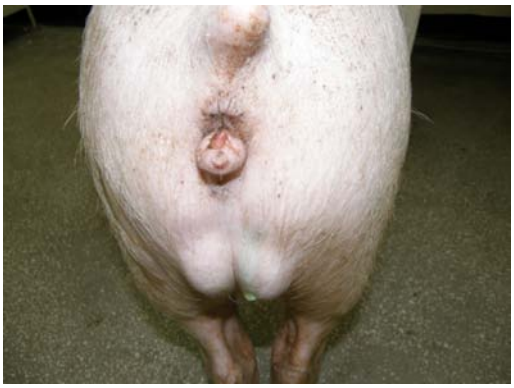

Fig. 1 - Macroscopical appearance of the intersex animal
The presence of the vulvae orifice with a large clitors along with two testicular bags well developed

Fig. 2 - Macroscopical appearance of the genital tract in male pseuhermaphroditism
two small testes with deferent duct, short vagina and prostate gland

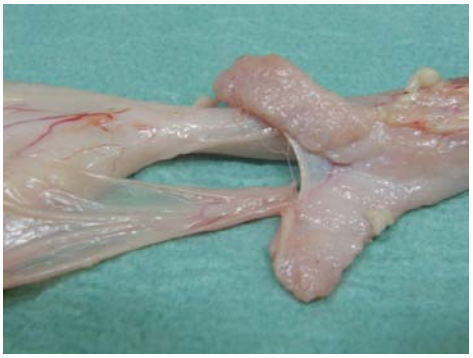

Fig. 3 - Prostate gland –the only case were the glands were macroscopically visible

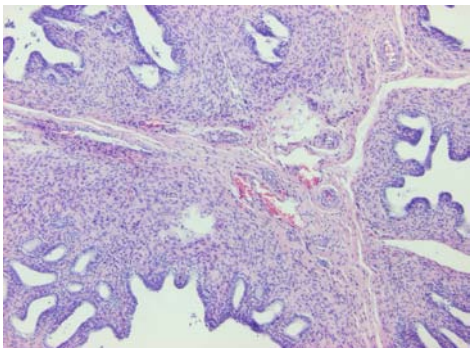

Fig. 4 - Prostate gland
glandular lobules well developed, a wide lumen but with no secretion

The other case alive, had the same anatomical aspect (fig.5) but after slaughter it was noticed that the testis were both in the same testicular bag and that the uterine horns suffer a torsion process for the testis to descend (fig.6), and this is a clue that intersexuality is mainly a developmental problem associated with genetic anomalies or hormonal status.

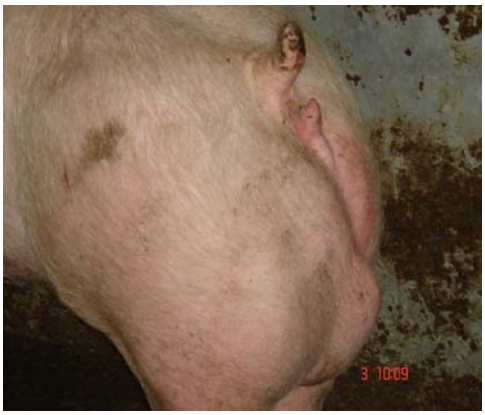

Fig. 5 - Macroscopical appearance of the intersex animal
the presence of the vulvae along with two testicular bags well developed

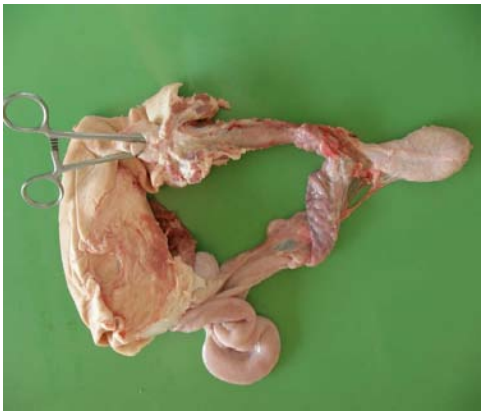

Fig. 6 - Macroscopical appearance of the testises at the end of the uterine horns that descend into the scrotum

In our cases indeed the ovaries were replaced by large testicles coverd by epidydymis. In all of our cases the testis had a globular shape and in one case, one of the testes was smaller than the other.

The other two cases presented testis instead of the ovaries, and the genital tract specific for sows – coiled uterine hornes, uter, corpus cervix and vagina. From these testis, parallel with the uterine horns were the deferent ducts, same as in true hermaphroditism. (fig.7, fig.8)

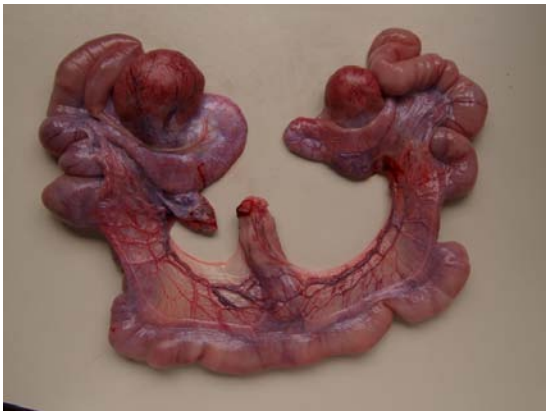

Fig. 7 - Macroscopical appearance of the genital tract in male pseudohermaphrodites
Testis instead of the ovaries

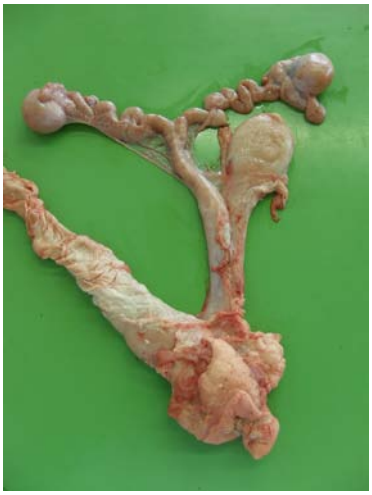

Fig. 8 - Macroscopical appearance of the genital tract in male pseudohermaphrodites
Testis instead of the ovaries

seminiferous tubules, looking polymorphic, presented by various form as “U”, ”V”, “S” shape, but also the endocrine compartment represented by Leydig gland in the connective tissue between the seminiferous tubules, very well developed compared to a normal adult boar.

Structural, seminiferous tubules are surrounded by an own connective tissue layer. Only one single type of cell could be noticed on the surface of basal lamina – the Sertoli cells – with a round or oval nucleus due to the space that exists from the abcense of any spermatogonias. The Sertoli cell nucleus was about 8-12 microns. The same structure of the seminiferous tubules was noticed in the criptorchidic testis (we also used for comparison) (Breewsma A.J., 1968; Hancock J.L.et al., 1981; Hunter R.H.F et al., 1982; Hunter R.H.F et al.1996; Cotea C. 2010; Pinart E., 2001). (fig.9, fig.10, fig.11, fig.12)

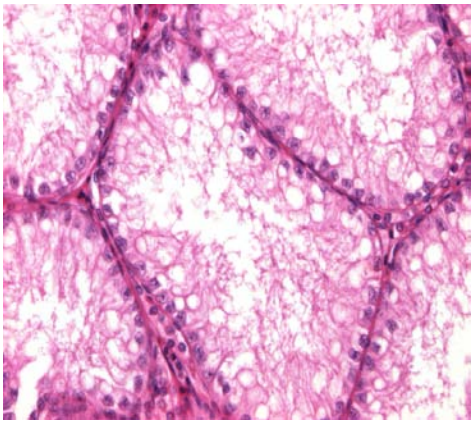

Fig. 9 - Seminiferous tubules surrounded by a thin connective layer, seminiferous epithelium containing only Sertoli cells. HE, x200

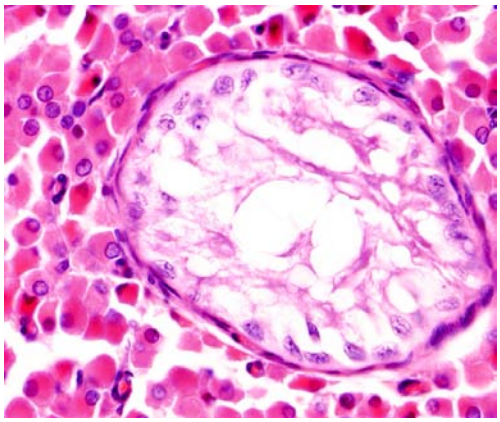

Fig. 10 - Seminiferous tubules surrounded by a thin connective layer, seminiferous epithelium containing only Sertoli cells. HE, x400

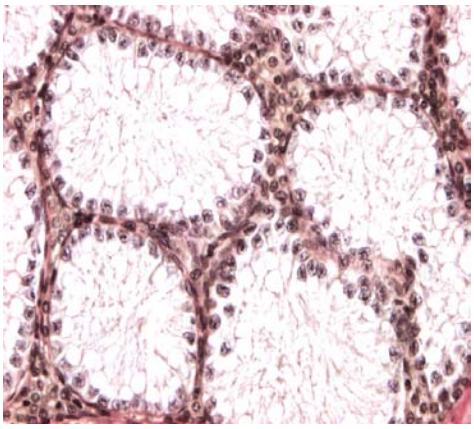

Fig. 11 - Seminiferous tubules surrounded by a thin connective layer, seminiferous epithelium containing only Sertoli cells. Van Giesson, x200

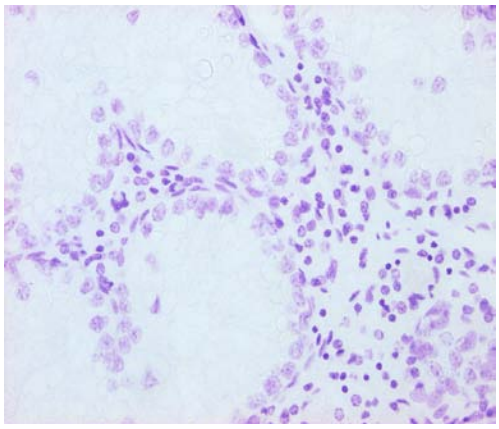

Fig. 12 - Seminiferous tubules surrounded by a thin connective layer, seminiferous epithelium containing only Sertoli cells. Feulgen reaction, x200

The junction between the testis and the uterine horns was made through the epididymis. In cross section, the epididymis channel is structured of a ciliated epithelium with many stereocilia at the apical pole of the cells and it`s lumen were not observed spermatozoa due to the lack of sperm cell line. (fig.13, fig.14) (Ciornei Cristina et al., 2009, Ciornei Cristina et al., 2010)

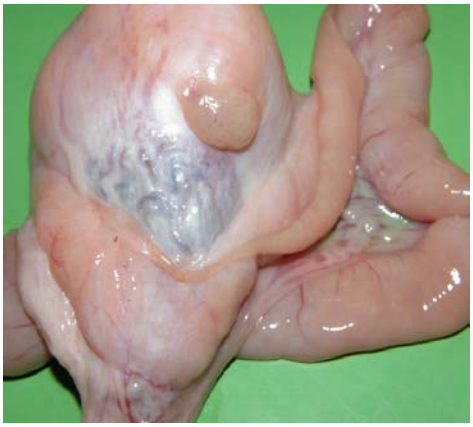

Fig. 13 - Junction between epididymis and oviduct male pseudohermaphrodites

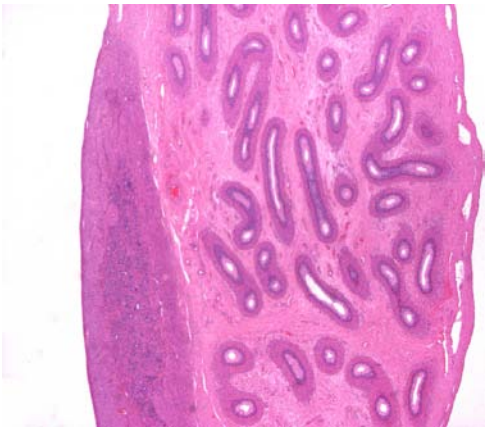

Fig. 14 - Junction between epididymis and oviduct male pseudohermaphrodites. HE, x100

Due to the genital tract anomalies, we were not able to say exactly what is the genetic sex of these individuals, so we tried to determine this by making vaginal smears for detecting the the presence of the chromatin X and where was possible some blood smears for detecting the drumstick in neutrophils. (fig.15, fig.16)

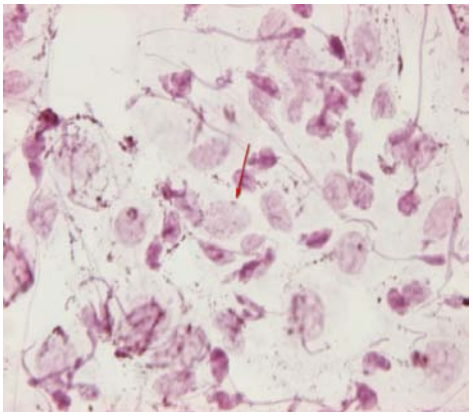

Fig. 15 - Chromatin X. Barr Body. Orcein stain, x1000

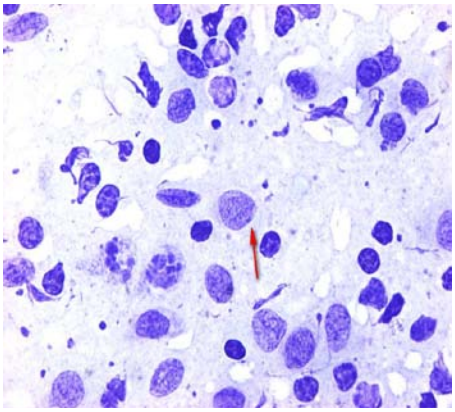

Fig. 16 - Chromatin X. Barr Body. Cresyl Violet stain, x1000

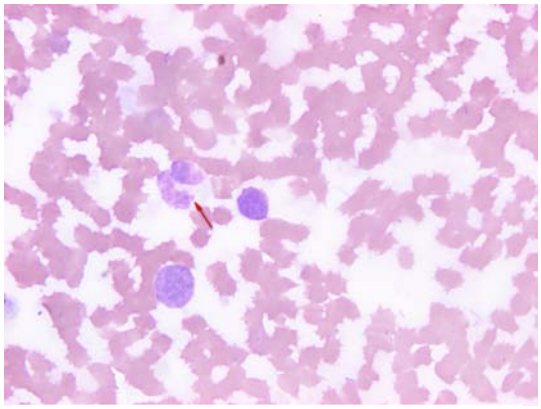

Fig. 17 - Drumstick. Barr Body. MGG, x1000

Conclusions

1. Based on the morphological and histological aspects, the four cases we have analyzed where classified as being *male pseudohermaphrodites.*
2. One characteristic of intersex pigs is the enlarged and prominent clitoris and the ventral commissural of the vulva orientated dorsal.
3. In one of the alive gilts, after slaughter it was noticed that the genital tract was composed out of two small testes from which started two thin deferent ducts and they were going to the vaginal vestibule.
4. The testes were surrounded by a large epididymis, covering ¾ from the surface of the testis and this this was the only case that also had a "heart" shaped gland (fig.3) – microscopically proving to be the prostate.
5. The other case alive, had the same anatomical aspect but after slaughter it was observed that the testis were both in the same testicular bag and that the uterine horns suffer a torsion process for the testis to descend.
6. The other two cases presented testis instead of the ovaries, and the genital tract specific for sows – coiled uterine hornes, uter, corpus cervix and vagina. From this testis, parallel with the uterine horns were the deferent ducts, same as in true hermaphroditism.
7. Microscopically the testes showed both exocrine compartment represented by seminiferous tubules but also the endocrine compartment represented by Leydig gland in the connective tissue between the seminiferous tubules, very well developed compared to a normal adult boar.
8. The junction between the testis and the uterine horns was made through the epididymis.
9. Based on cytogenetic test – by the presence of the Barr body and the drumstick – we conclude that the genetic sex of these individuals is *female.*

References

1. Breeuwsma A.J. (1968) – A case of XXY sex chromosome constitution in an intersex pig. Journal of reproduction and fertility, vol. 14, pag. 119-120.
2. Ciornei Cristina, Cotea C.V., Solcan Carmen, 2010: Histological researches in male pseudohermaphroditism in domestic swines (*Sus scrofa domestica*). Lucrari stiintifice, vol.53 (12), pag. 374-381.
3. Ciornei Cristina, Cotea C.V., Solcan Carmen, 2010: Histological researches in bilateral true hermaphroditism in domestic swines (*Sus scrofa domestica*). Lucrari stiintifice, vol.53 (12), pag. 382-390.
4. Ciornei Cristina, Pavli C. (2009) – Utilizarea diagnosticului ecografic în stabilirea tipului de hermafroditism la suinele domestice (*Sus scrofa domestica*). Lucrări ştiinţifice, vol. 52 (11). Medicină Veterinară. Partea I. Ed. "Ion Ionescu de la Brad" Iaşi, pag. 51-55.
5. Ciornei Cristina, Cotea C., Solcan Carmen (2009) – Cercetări histologice în hermafroditismul bilateral la suine (*Sus scrofa domestica*). Lucrări ştiinţifice, vol. 52 (11). Medicină Veterinară. Partea I. Ed. "Ion Ionescu de la Brad" Iaşi, pag. 44-50.
6. Cîrlan M. (2006) – Genetică animală. Vol I- III. Ed. Alfa, Iaşi.
7. Cornilie P., Mortier V., Verheyden K., Simoens P., De Brabander H.F., Vanhaecke L., 2009: Intersexuality in pigs: Impact on veterinary public health and food safety. Online Journal of veterinary medicine. Vol. 13(1), pag. 63-75.
8. Cotea C. (2010) – Histologie specială. Ed. Tehnopress, Iaşi.
9. Hancock J. L., Daker M.G., 1981: Testicular hypoplasia in a boar with abnormal sex chromosomes constitution (38 XXY). J. Reprod. Fert., 61, 396 – 397.
10. Hunter R.H.F., Baker T.G., Cook B. (1982) - Morphology, histology and steroid hormones of the gonads in intersex pigs. Journal of reproduction and fertility, vol. 64, pag. 217-222.
11. Hunter R. H., Greve T. (1996) – Intersexuality in pigs: clinical, physiological and practical considerations. Acta Veterinaria Scandinavica vol.37, pag. 1-12.
12. Pinart E., Bonet S., Briz M., Pastor L. M., Sancho S., Garcia N., Badia E., Bassols J., 2001: Morphological and histochemical characteristics of the lamina propria in scrotal and abdominal testes from post pubertal boars: correlation with the appearance of the seminiferous epithelium. J. Anat., 99, 435-448.

MORPHOPATHOLOGICAL PECULIARITIES OF NERVES AND ARTERIES INVOLVEMENT IN NECROBACILLARY PODODERMATITIS OF SHEEP

Grigore DUMITRAŞ
State Agrarian University of Moldova
Faculty of Veterinary Medicine
Chisinau, Mircesti street, 42
E-mail: grigore.dumitras@gmail.com

ABSRACT
Necrobacillary pododermatitis of sheep is one of the most widespread animal diseases in the Republic of Moldova. The paper describes pathological changes of soft tissues of ovine limbs affected by necrobacillary pododermatitis. Histopathological examination of dermis and hypodermis of injured zones revealed serous inflammation and infiltration of intercellular space by numerous cells. Reactive changes of nerve fibres and free nerve endings were observed. A compensatory hypertrophy of arterial blood vessels and a narrowing of the arterial lumenus leading to a complete closing of vessels were observed.

Key words: necrobacillary pododermatitis, nerve fibres, arteries

INTRODUCTION

Necrobacillary pododermatitis of sheep is one of the most widespread animal diseases in the Republic of Moldova characterized by a high contagion. The disease begins with entering of infectious agent in interdigital space leading to an inflammatory process of soft tissues of acropodia. As the horn tears away and basal ulcers appear pathological process acquires a chronic evolution with necrosis of skin, subcutaneous tissue, tendons and joints. The aim of the study was to reveal pathological changes of nerves and arteries of acropodia in necrobacillary pododermatitis of sheep.

MATERIAL AND METHODS

We examined 148 thoracic and hind ovine limbs. To study the extent and branching of digital arteries we used the angiography method. As a contrast for angiography an oil-paint with lead was applied. The injection of blood vessels was performed through median artery of the anterior limb and dorsal metatarsal artery of the posterior limb.

To reveal changes of nerves of acropodia soft tissues impregnation of tissues with $AgNO_3$ was used.

RESULTS AND DISCUSSION

Our data demonstrated the presence of reactive changes in nerve fibres and free nerve endings of acropodia soft tissues in necrobacillary pododermatitis. We also observed that incapsulated receptors remained without visible changes. At the same time we revealed a strong silver impregnation of both solitary myelinated fibres and fascicles. In great nerve fibres an increased impregnation, as well as appearance of variceal thickening along them could be seen. At the same time, we found completely intact fibres between

those degenerated. The destruction of the nerve elements progressed as more proximal it was to the focus of inflammation. Thus, different degrees of pathological changes in myelinated and non-myelinated fibres and receptors were revealed.

In moderate-to-severe forms of necrobacillary pododermatitis the spectrum of nerves changes in the region of the halo and interdigital tissue corresponded to Wallerian degeneration including argentophylia, thickening of the axis cylinders, the neuroplasma leakage and fragmentation and granular decomposition of the axis cylinders. A great part of non-incapsulated nerve endings underwent reactive and destructive pathomorphological changes. The lysis of cellular elements of the perineural cuff and myelinated nerve fibres, as well as fragmentation and granular decomposition of preterminal parts of free receptors and fragmentation of their terminal parts were revealed. Simultaneously, changes of the shape of incapsulated receptors and irregularity of their surface were observed.

While nerve fibres and the majority of nerve fascicles from the zone of necrosis of soft tissues of interdigital fissure and the halo were exposed to fragmentation and granular decomposition, in the zone of the sole necrosis all nerve structures were completely destroyed.

The data mentioned above allowed us to affirm that in case of a massive injury of soft tissues of distal segments of ovine limbs, i.e. in a severe form of infectious pododermatitis, the digital nerve structures undergo profound changes. Due to destructive process in nerve fibres and death of receptors, i.e. lack of an afferent element from tissues, severe trophical disturbances occur.

Similar examination was performed regarding changes in the arteries of distal parts of ovine limbs injured by necrobacillary pododermatitis in different stages of evolution. Following the same conditions, the same contrast and pressure, we obtained different histopathological data.

In a mild form of infectious pododermatitis the angiograms of ovine limbs demonstrated great and middle digital arteries forming a reticle of large loops with few lateral ramifications. Small vessels, i.e. arterioles and capillaries, created, in turn, a homogeneous picture of small loops with a very dense distribution.

All arterial vessels were injected profoundly up to the level of the smallest capillaries. The contour of small vessels, as well as of great ones appeared unclear. Intervascular spaces were covered by a slight shadow due to a diffuse distribution and extravasation of the contrast. This fact makes us conclude that the arteries of the 4th, 5th and 6th order enlarge their diameter in the initial stage of the disease.

According to histopathological data a picture of serous inflammation was observed. The dermis and hypodermis were edematiated and infiltrated by numerous cells. There was a serous liquid with a reduced quantity of exfoliated cells in the intercellular space. As infectious pododermatitis progresses the vascular reaction changes. Under the influence of the adjacent pathological process arterioles lose their dynamics, then paresis of vascular wall takes place. As a result, inflammatory vascular hyperemia from the onset of the disease is substituted by a reaction of arteriolar walls. Thus, a compensatory hypertrophy of the involved blood vessels is observed.

A narrowing of the vascular lumenus leading to a complete closing of the former was also revealed. This phenomenon occurred due to hypertrophy of muscular layer of vascular wall. Simultaneously, the architecture of arterioles changed. In blood vessels with a diameter of 100 mkm parietal thrombi were found. In some cases we revealed obliterated vessels with organized thrombi.

Basing on angiography results sinuous and reductive character of small arteries, as well as an irregular narrowing of their lumenus were demonstrated. The arteries of the 5th, 6th and 7th order were reduced partially, that is why the terminal vascular arch of the horn was destroyed. We also observed perivascular sclerosis, hyperelastosis and thickening of the intima. The aforementioned vascular changes were determined by the character, localization and intensity of the pathological process.

CONCLUSIONS

1. In necrobacillary pododermatitis of sheep reactive changes of nerve fibres and free nerve endings were observed.
2. The angiograms of the injured zones revealed sinuous and reductive character of small arteries, as well as an irregular narrowing of their lumenus.

BIBLIOGRAPHY

1. Edwards J.F., Davis D.S., Roffe T.J., et al. (2001) - Fusobacteriosis in captive wild-caught Pronghorns. Vet. Pathol. 38: 549-552.
2. Guertin A.D., Zhang D.P., Mak K.S., et al. (2005) - Microanatomy of axon/glial signaling during Wallerian degeneration. Journal of Neuroscience, 25:3478–3487.
3. Gyles C.L., Prescott J.F., Songer J.G., et al. (2010) – Pathogenesis of bacterial infections in animals. Blackwell Publishing, 643 pp.
4. Jacob W., Schroder H.D., Rudolph M., et al. (2000) - Necrobacilosis in free-living European bison in Poland. J. Wild Dis. 36: 248-256.
5. Nagaraja T.G., Narayanan S.K., Stewart G.G., et al. (2005) – Fusobacterium necrophorum infections in animals: pathogenesis and pathogenetic mechanisms. Anaerobe 11: 239-246.
6. Stoll G., Jandeer S., Myers R.R. (2002) - Degeneration and regeneration of the peripheral nervous system; from Augustus Waller's observations to neuroinflammation. J. Periph. Nerv. Syst. 7: 13-27.
7. Zamani-Ahmadmahmudi M., Mohamadnia A.R., Azarprazhoh S., et al. (2010) - Study of the vascular system of ovine hind limb claw by means of corrosion casting methods. J. Vet. Res. 65 (3): 177-183.

MOUSE MODEL FOR HUMAN PLACENTAL STEM CELLS ENGRAFTMENT

Groza I.Ş, Pall Emoke, Daria Groza, Cenariu M., Ciupe Simona, Morar I.
University of Agricultural Science and Veterinary
Medicine, Cluj-Napoca, 3-5 Manastur street, Cluj-Napoca,
isgroza@yahoo.com

Abstract
The human placenta is an attractive new source of mesenchymal stem cells (MSCs), but the biological characteristics of placenta-derived MSCs have not yet been characterized. In this study, we established a mouse model for in utero transplantation of human placental mesenchymal stem cells (hPMCs) to investigate if these cells would affect long-term, organ-specific engraftment.
To show that hPMCs injected in utero on E13.5 engrafted in fetal organs, we collected fetal organ samples at E20. Most fetal tissues had demonstrable hPMC engraftment at E20. Although the distribution pattern and numbers of cells in individual fetuses varied, hPMCs were detectable in more than 60% of the fetus. The first experiment conducted fetal loss rate was high: 93.75% most likely due to lack of experience in producing labor in utero transplantation. Engraftment analysis was done using FACS Diva software and results are presented as histograms.
Our results show that mesenchymal stem cells are present in the human term placenta and may be a potential source of cells for transplantation therapy. Using routine cell culture techniques, placental derived mesenchymal stem cells can be successfully isolated and expanded in vitro.

KEYWORDS: placenta, mesenchymal stem cells, engraftment, mouse model

The human placenta is a fetomaternal organ, formed by both fetal and maternal tissue (1). Its successful formation is a critical process in embryogenesis, and the normal development and function of the placenta is crucial to the wellbeing of the fetus. This organ is discarded postpartum, after having performed its necessary function of supporting the embryo and fetus (1,4). Stem cells isolated from term, postpartum placenta have a variety of advantages. Although they are unlikely to have the differentiation and proliferative potentials of ESCs, cells derived from the placenta are still of fetal origin and may be superior to ASCs in many aspects. No invasive procedure is necessary to obtain the organ, since the placenta is expelled after the birth of the neonate, and there are no ethical conflicts generated.

In utero therapy of certain fetal diseases have the potential to reduce fetal morbidity and mortality (3, 10). The intrauterine transplantation of stem cells provides in some instances a therapeutic option before definitive organ failure occurs. Clinical experiences show that certain diseases, such as immune deficiencies or inborn errors of metabolism, can be successfully treated using stem cells derived from bone marrow. However, a remaining problem is the low level of engraftment that can be achieved. Efforts

are made in animal models to optimize the graft and study the recipient's microenvironment to increase long-term engraftment levels. It is known that some diseases, such as haemoglobinopathies (Fanconi's anaemia, thalassaemia), immunological defects (SCID) or certain inborn errors of metabolism can be treated by transplantation of stem cells (10). Cells of different origins have been used for *in utero* transplantation in a number of models. Human bone marrow-derived mesenchyamal stem cells have been transplanted into fetal sheep and shown to persist for as long as13 months with multilineage differentiation potential (7).

In this study, we established a mouse model for in utero transplantation of human placental mesenchymal stem cells to investigate if these cells would affect long-term, organ-specific engraftment.

MATERIALS AND METHODS

Term (38–40 weeks' gestation, *n* = 16) placentas from healthy donor mothers were obtained after Cesarean section with informed consent approved according to the procedures of the institutional review board. All experiments were approved by the ethics committee of the University of Medicine and Pharmacy Iuliu Hatieganu, Cluj-Napoca. The harvested pieces of tissue were washed several times in phosphate-buffered saline (PBS) and then mechanically minced and enzymatically digested with 0.25% trypsin-EDTA (Gibco) for 30 min at 37° C. After centrifugation the cell suspension was filtered to eliminate undigested fragments. For lysis the erythrocytes, cells suspensions were treated with FACS Lysing Solution 10x (BD Biosciences) for 15 min. The suspension pelleted by centrifugation (1500 rpm/7 min) and suspended in propagation medium, which consist of Dulbecco's Modified Eagle's medium (Gibco) supplemented by 10 % fetal calf serum (FCS), 100 U/ml penicillin-streptomycin (Gibco).

Cultures were maintained in DMEM with 10% fetal bovine serum (FBS; Hyclone, USA) at 37° C with 5% CO_2. Approximately 2 – 3 weeks later, some colonies consisting of fibroblast-like cells were observed. These cells were trypsinized and replated for expansion. In order to obtain single cell-derived hPMC clones, cells were serially diluted in 96-well culture plates (BD Biosciences) at a final density of 60 cells/ plate. Colonies that grew with homogeneous bipolar morphology were expanded.

Identification of cell phenotypic markers by FACS (Fluorescence-Activated Cell Sorter) passage 5. After the second passage, the cells were trypsinised (0.25% trypsine EDTA), washed twice with PBS and stained according to the recommendation of the manufacturer with the monoclonal antibodies, FITC-CD44, examined with a FACS CantoII Apparatus (Becton–Dickinson). For *in utero* transplantation of mesenchymal stem cells from placentas, were prepared single cell suspensions. On day 13.5 after mating, pregnant mice were anesthetized with 4 mg/kg Kethamine and 40 mg/kg Xylazine cocktail administered by intraperitoneal injection. Under aseptic conditions, the uterine horns were exposed, and donor cells were injected through a glass micropipette (inserted through the uterine wall and into the peritoneal cavity of each fetus under direct visualization. The injection consisted of 1 x 10^6 hPMCs in 5 µl of PBS. The abdominal incision was closed in two layers using 4-0 silk, and the mice were allowed to complete pregnancy to term.

On E20, a low abdominal midline incision was made and the number of live fetuses in each uterine horn was recorded. Then, placenta, fetal blood and fetal organs including brain, heart, lung, liver, spleen and bone marrow were collected. To obtain single cell

suspension as chopped tissues were processed by the Medimachine device. For evidence of placental stem cells in mice organs the samples were treated with 20 µl fluorescent antibody (anti - human CD45 PE-Cy5 antibody (PE-Cy5: phycoerythrin-Cy5), (FITC: fluorescein isothiocyanate), anti – human CD34-FITC antibody (FITC: fluorescein isothiocyanate) and anti- human CD44 antibody). Have prepared two samples for each antibody in the study: a sample and a sample labeled with antibody as blank unmarked. For positive control were used MSCs isolated from placenta and CD34 + cells from cord blood.

RESULTS AND DISCUSSION

In utero stem cell transplantation was performed in 10 mouse carrying a total of 65 fetuses. The first experiment conducted fetal loss rate was high: 93.75% most likely due to lack of experience in producing labor *in utero* transplantation.To show that hPMCs injected in utero on E13.5 engrafted in fetal organs, we collected fetal organ samples at E20. Engraftment analysis was done using FACS Diva software and results are presented as histograms. Most fetal tissues had demonstrable hPMC engraftment at E20. After analyzing the histograms, the total of 16 fetuses examined showed different degrees of grafting,only in seven fetuses. Although the distribution pattern and numbers of cells in individual fetuses varied, hPMCs were detectable in more than 43,75% of the fetus. We assessed the presence of hPMCs in various fetal mouse tissues (fig.1, 2).

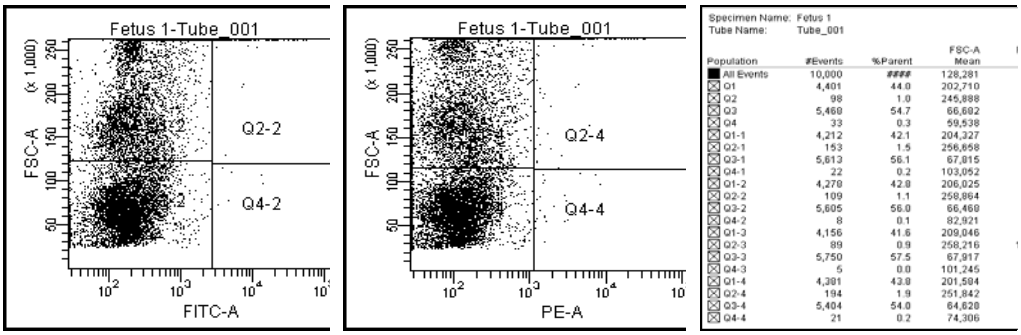

Figure 1 – Flow cytometric analysis of hPMCs in the mouse fetus after in utero transplantation of hPMCs

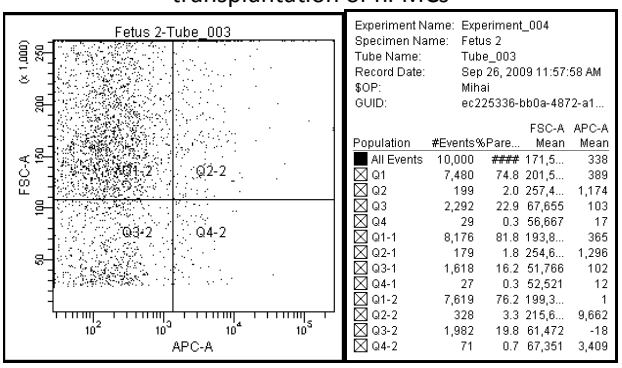

Figure 2 – Histogram representation of engraftment

Grafting percentages shown ranged between 1.2% and 7.2%, a low but consistent with published data in literature. Trans species animal models have been widely used in the study of stem cell migration and engraftment (7,9). It has been shown that human cord blood-derived cells can differentiate into hepatocytes in the mouse liver without evidence of cellular fusion (6). Human microchimerism was observed in various organs and tissues at 4 months after transplan-tation of human amnion and chorion mesenchymal progenitors in neo-natal swine and rats (2). Human mesenchymal stem cells colonized multiple fetal sheep tissues for as long as 13 months after in utero transplantation (7). Differences observed in cell numbers may be due to colonization efficiency in different tissue environments or the rate of cell turnover in each organ (5). Our study adds to this body of work by establishing an *in utero* (E13.5) model of xenogeneic hPMC transplantation in immunocompetent mice.

CONCLUSIONS

Mesenchymal stem cells (MSCs) are widely distributed in a variety of tissues in the adult human body (e.g., bone marrow, kidney, lung, and liver). These cells are also present in the fetal environment (e.g., blood, liver, bone marrow, and kidney). However, MSCs are a rare population in these tissues. The most well studied and accessible source of MSCs is bone marrow, although even in this tissue the cells are present in a low frequency.

The human placenta is an attractive new source of mesenchymal stem cells (MSCs), but the biological characteristics of placenta-derived MSCs have not yet been characterized. Our results show that mesenchymal stem cells are present in the human term placenta and may be a potential source of cells for transplantation therapy. Using routine cell culture techniques, placental derived mesenchymal stem cells can be successfully isolated and expanded in vitro.

Mesenchymal stem cells are mainly derived from bone marrow (8), but it may be difficult to obtain sufficient autologous cells from some patients, particularly those who are older or who have malignancies. Therefore, alternative sources are needed. It appears that hPMCs from an allogeneic donor might constitute such a source. A further potential benefit is the exposure of the fetus to allogeneic cells, inducing tolerance such that future treatment.

BIBLIOGRAPHY

1. B. Linju Yen, Hsing-I Huang, Chih-Cheng Chien, Hsiang-Yiang Jui, Bor-Sheng Ko,, Ming Yao, Chia-Tung Shun, Men-luh Yen, Meng-Chou Lee and Yao-Chang Chen , Isolation of Multipotent Cells from Human Term Placenta, *Stem Cells* 2005;23;3-9.
2. Bailo M, Soncini M, Vertua E, Signoroni PB, Sanzone S, Lombardi G, Arienti D, Calamani F, Zatti D, Paul P et al. Engraftment potential of human amnion and chorion cells derived from term placenta. Transplantation 2004;78:1439 – 1448:
3. Carolyn Troegera, Daniel Surbeka, Andreina Schöberleina, Stephan Schatt, Lisbeth Dudlera, Sinuhe Hahna, Wolfgang Holzgreve, In utero haematopoietic stem cell transplantation, SWISS MED WKLY2006;136:498–503
4. Georgiades P, Ferguson-Smith AC, Burton GJ. Comparative developmental anatomy of the murine and human definitive placentae. Placenta 2002;23:3–19.
5. Krause DS, Theise ND, Collector MI, Henegariu O, Hwang S, Gardner R, Neutzel S, Sharkis SJ. Multi-organ, multi-lineage engraftment by a single bone marrow-derived stem cell. Cell 2001;105:369– 377

6. Liechty KW, MacKenzie TC, Shaaban AF, Radu A, Moseley AM, Deans R, Marshak DR, Flake AW. Human mesenchymal stem cells engraft and demonstrate site-specific differentiation after in utero transplantation in sheep. Nat Med 2000;6:1282 – 1286:
7. Liechty KW,MacKenzie TC,Shaaban AF, Radu A,Moseley AM, Deans R, Marshak DR, Flake AW. Human mesenchymal stem cells engraft and demonstrate site-specific differentiation after in utero transplantation in sheep. NatMed 2000;6:1282–1286.
8. Orlic D, Kajstura J, Chimenti S, Jakoniuk I, Anderson SM, Li B, Pickel J, McKay R, Nadal-Ginard B, Bodine DM et al. Bone marrow cells regenerate infarcted myocardium. Nature 2001;410:701– 705;
9. Saito T, Kuang JQ, Bittira B, Al-Khaldi A, Chiu RC. Xenotransplant cardiac chimera: immune tolerance of adult stem cells. Ann Thorac Surg 2002;74:
10. Shapiro E, Krivit W, Lockman L, et al. Long-term effect of bone-marrow transplantation for childhood-onset cerebral X- linked adreno-leukoldystrophy. Lancet 2000;356:713–8

Acknowledgements
Reserches financed from grant PN2 62-085 by **UEFISCSU**

SERUM BIOCHEMICAL PROFILE AND KIDNEY'S HISTOLOGICAL CHANGES IN DRUG-INDUCED RENAL FAILURE IN EXPERIMENTAL RATS

[1]Nabaa Kamal Al shafei, [2]Afaf Desouky Abd Elmagid , [3]Hussein Abd El-Maksoud, [4]Yakout A. El-senosi, and [5]Abdelfattah Nour

[1]Dept of Biochemistry, Bahr El Ghazal Uni, Faculty of Vet Sci.; Sudan;[2,3,4] Dept .of Biochemistry , Benha University, Egypt; and [5]Dept of Basic Medical Sciences, School of Veterinary Medicine, Purdue University, USA

Abstract:

Kidney failure can be caused by acute or chronic problems, including dehydration, infection, and treatment with drugs, including antibiotics. Drugs are considered to be a major source of acute kidney injury. Kidney failure causes accumulation of toxins in the body and results in health complications, which make renal failure a very serious and fatal disease. The overall objectives of this work are two folds: 1) To determine the effects of drug-induced renal damage on the serum biochemical profile, and the kidneys histopathological changes in experimental rats; 2) To study, in hemodialysis patients suffering from pruritus, the association between antibiotics treatment, renal failure, some of the uremic toxins and allergic factors**.** This paper will concentrate on the first objective and report on the findings when Gentamicin and Cisplatin were used to induce nephrotoxicity and renal failure in experimental rats. Sixty male albino rats, with body weight ranging from 180- 200 gm, were used in the experiment. The rats were housed individually in hygienic metal cages, and were kept in a controlled environment. Experimental rats had free access to water and fed *ad libitum* a nutritionally balanced diet. Rats were randomly divided into three groups, each consists of 20 rats: Control normal group (1), Cisplatin- induced renal failure group (2), and Gentamicin-induced renal failure group (3). Animals in experimental Group (2) were injected intraperitoneal (IP) with Cisplatin once, at a dose of 6mg/kg. On the other hand, Group (3) received daily IP injections of Gentamicin at the rate of 80 mg/kg (20mg) for eight days. Four animals from each group were humanely sacrificed and dissected at 48 hours intervals till the end of experiment (day3, 5, 7, 9 and 11) for the Cisplatin group; and at the 7th and 9th day for the Gentamicin group. Blood samples were collected for serum chemistry analysis. The two kidneys were collected and processed for histological and hisypathological examinations. All sera were subjected to appropriate chemical analysis procedures to determine urea, uric acid, creatinine, potassium, calcium, sodium, and phosphorus. This paper summarizes the serum biochemical profile and the kidney's histopathological changes in drug-induced renal failure in experimental rats. This study showed that that the histopathological changes in renal tissues in Cisplatin and Gentamicin-induced renal failure appeared in early stage of renal dysfunction in comparison to the changes in serum levels of traditional biomarkers, such as urea and creatinine. Therefore, more studies are needed to determine the correlations between biochemical markers and histopathological changes that may be used in prediction equations to assess earlier drug-induced insults to the kidneys before renal failure progresses.

Key words: Experimental rats, Renal failure, Gentamicin, Cisplatin, serum biochemical profile, kidney's histopathological changes

Introduction

The Kidneys are important for the maintenance of the ionic composition and volume of extracellular fluids, and pH for optimal functioning of body cells. They do that through the regulation of urinary excretion of water, hydrogen, and electrolytes to match the intake and output. The kidneys are able to adjust tubular reabsorption and secretion of substances such as sodium, potassium, and hydrogen. Thus it maintains the ionic composition and pH of extracellular fluid **(Lesley, et al., 2010).** The role of the kidneys in calcium homeostasis has been known for years. In addition, the kidneys excrete waste products of metabolism such as urea, creatinine and uric acid. Expectedly, when the kidneys fail, toxins accumulate of in the body and result in serious health complications as a result of their effect on the blood, brain and heart. These complications make renal failure a very serious and fatal disease if neglected (**Wisegeek, 2010).**

Several factors, such as antibiotics and a variety of other pharmaceutical agents, are known to be toxic to the kidneys. Renal toxicity commonly occurs after administration of these nephrotoxic agents. The process is typically initiated either by a toxic injury to tubular epithelial cells in various nephron segments, or by injury to specific cell types in the glomerulus **(Toback, 1992).** Though some antibiotics are known to be nephrotoxic, gentamicin was originally thought to be non-toxic. Recently, nephrotoxicity has been listed as one of the major side effects of the drug. Gentamicin's plasma half life is increased when the glomerular filtration rate is low. Higher dosage of Gentamicin produced the expected severe renal injury as evidenced by the marked increase in BUN and creatinine. **Rupesh et al., (2004)** documented that Gentamicin injury included degeneration of some proximal convoluted tubules, and resulted in apoptosis (cell death), tubular basophilia, tubular casts, increased mitotic figures, and mononuclear cellular infiltrates. On the other hand, Cisplatin is chemotherapeutic drug used widely for of treatment of many cancers because of its ability to cause apoptosis of cancerous cells **(Stordal, et al., 2007)**. The drug is usually administered in saline solution intravenously. The major side effect of concern is that the drug causes renal damage and results in renal failure. The durg also causes hypocalcaemia, hypomagnesaemia, and a decreased potassium serum levels **(Wikipedia (2011)**. Cisplatin as an antineoplastic agent is widely prescribed for a variety of solid tumors, such as lung, testis, ovary, bladder, head, and neck cancer. However, a single dose Cisplatin injection may cause impairment of renal functions and cause severe histopathological injury, that would lead to the development of renal failure. Cisplatin treatment increased both tubular injury and hyalin cast formation. **Secil., (2007)** found that Cisplatin treatment increased serum urea and creatinine levels significantly, indicating renal failure development.

The overall objectives of this work are two folds: 1) To determine the effects of drug-induced renal damage on the serum biochemical profile, and kidneys histopathological changes in experimental rats; 2) To study, in hemodialysis patients suffering from pruritus, the association between antibiotics treatment, renal failure, some of the uremic toxins and allergic factors**.** The goal of this research is to find correlations between the biochemical parameters, hiosopathological changes and allergic factors to better understand renal failure and what patients undergoing hemodialysis are going through**.** This paper will concentrate on the first objective and give a preliminary report on the findings when Gentamicin and Cisplatin were used to induce nephrotoxicity and renal failure in experimental rats. This paper will present the biochemical and histopathological changes in early stages of Cisplatin and Gentamicin drug-induced renal damage in experimental rats.

Materials and methods

Experimental animals:

Sixty healthy male albino rats, weighing 180-200 gm were used in this investigation. Animals were purchased from the Animal Lab Center of the Faculty of Veterinary Medicine, Benha University, Cairo. All animals were healthy and free from clinical evidence of any disease. Animals were housed in hygienic metal cages that were kept in a clean well ventilated room and under the optimal nutritional conditions throughout the period of experiment. Experimental rats were kept for two weeks for acclimatization before the beginning of experiment. Rats were fed *ad libitum* on nutritionally-balanced pelleted diet throughout the course of the experiment, and had free access to water.

Study design and dosage: -

Experimental rats were randomly assigned to one of three groups, 20 for each:

1- group (1): normal non-medicated rats, which were used as a control group
2- Group (2): were injected with Cisplatin (Cis Group), once at a dose of 6mg/kg **(Bagnis et al., 2001).**
3- Group (3): Animals received daily intraperitoneal (IP) injections of Gentamicin (Genta Group) at a dose (20mg)/kg for eight days as described by **Abdel-Gayoum et al., (1994)** for chemical induction of renal failure.

EXPERIMENTAL DESIGN

Four animals from each group were sacrificed and dissected at 48 hours intervals till the end of experiment. Following as institutionally approved procedures for humane handling of experimental animals, animals were sacrificed at sampling time, and blood was collected in clean test tubes. Care was taken not inflict undue stress on the rats, or contaminate the samples. From each rat, the two kidneys were carefully dissected, and samples from each of the two kidneys were collected and processed for histopathological examinations.

a. Blood samples:

Blood samples were allowed to coagulate at room temperature for 30 minutes, then centrifuged at 3000 revolutions per minute (RPM) for 10 minutes. The clean clear serum from each sample were aspirated carefully by a pasture pipette, and transferred into a dry, sterile, and labeled glass vials. The sera then were kept in a deep freezer at -20°C till biochemical analysis of the samples was performed.

All sera were subjected to appropriate analytical procedure to determinate different biochemical parameters. Urea was determined by using the urease- modified Berthelot enzymatical reaction following the procedure outlined by **Patton and Crouch (1977).** Uric acid was determined enzymatically by the quantitative determination of uric acid according to the procedure described by **Schultz. et al. (1984).** Creatinine was determined using Jaffe Colorometric End point method as outlined by **Heingard andTiderstrom, (1973) and Houot, (1995).** On other hand, serum calcium was determined by the Photometric Test CPC method according to the procedure described by **Gitelman (1967).** The concentration of the inorganic phosphorus in serum sample was determined by the photometric UV Test method (**Henry, 1964).** Serum sodium was determined colormetrically according to the

method of **Trender (1951).** Serum potassium was determined colorimetrically using the turbidmetric method according to the procedure described by **Terri, et al. (1958)**

b. Tissue specimens:

Immediately after the rats were sacrificed and dissected, the two kidneys were isolated, washed with saline and blotted between filter papers. A half from each of the two kidneys were preserved in 10% neutral formalin in separate labeled jars for histopathological examinations. Samples dehydrated through ascending grades of ethanol, cleared in xylene, embedded in paraffin wax and sectioned at 4 - 5 µ thick. The sections were stained with Haematoxylin and Eosin, for general histopathological examination as described by **Bancroft and Stevens (1977).** Crossman stain was used following the procedures described by **Gray (1954)**

Statistical analysis was performed using SPSS-version 15 software (2010). Parametric data were expressed as means ± SEs. Statistical differences between the groups were evaluated by unpaired Student's *t*-test, and the differences within each group by paired *t*-test. Differences yielding *P*-values <0.05 were considered statistically significant.

Results

The results of the serum biochemical profile are presented in tables (1) and (2) and in figures 1 through 4. Figures 5A and 5B present the normal histology of the rat's kidneys. Figures 6 A, B, C, D, E, and F provide the histopathological changes that occurred in the kidneys following the Cisplatin injections. Figures 7 A, B, C, D illustrates the histopathological changes that occurred in the kidneys as the result of Gentamicin-induced renal damage.

Serum Urea:

Table (1) shows the means (± standard error) for serum urea, uric acid and creatinine levels (mg/dl) obtained from the Cisplatin and Gentamicin- induced renal failure groups at different days post drug injections. From this table, it could be observed, in the Cisplatin group 2, that there was overall significant increase in serum urea levels, compared with the control group. However, within this experimental group, urea levels increased sharply at day 5 and started to decrease. This increase became highly significant at day 5 and day 7 in comparison with control ($p < 0.05$) and days 3, 9 and 11. However, rats in group three (Gentamicin group), there was a significant increase in urea level in day 7 and 9 as compared with control group ($p < 0.05$). There is was no difference in urea level between day 7 and 9.

Serum uric acid:

Figure (1) shows the relationship between uric acid and creatinine in Cisplatin group at different days post drug injection. As shown in table (1) and depicted in figure 1, that Group 2 serum uric acid level in day 3 increased significantly ($p < 0.05$) where at day 5, 7, 9 and 11 the value revealed no significant change in comparison with control group. Furthermore, the administration of Gentamicin to normal rats did not result in an increase in the uric acid level in day 7, however uric acid significantly increased in day 9 in comparison with control value. from this figure, it can be also observed that uric acid and creatinine recorded significant increased in day 3 and 5, respectively. The relationship between uric acid and creatinine in the control group and at different days of the experiment in the Gentamicin group is illustrated in figure 2, that shows a conspicuous

increase in uric acid serum level in the Gentamicin group was evident in day 7 of the experiment.

Serum creatinine:

Administration of Cisplatin to normal rats resulted in a highly significant increase of creatinine level ($P < 0.05$) in day 5, and significant increase in day 3, 7, 9 and 11 in comparison to control group (Table 1, figure 1). The most significant increase occurred at day 5 (Figure 1). On the other hand, administration of Gentamicin revealed high significant increase in creatinine levels in day 7 and 9 compared to the control. With the Gentimicin group, the difference between day 7 and 9 in creatinine levels was not significant.

Serum sodium:

Table 2 presents the mean value (± standard error) of sodium, potassium, calcium, and phosphorus levels (mg/dl) in Cisplatin and Gentamicin groups. The relationship between potassium, calcium and phosphorus levels and the different days in the experiment as compared to the control is illustrated in figures 3 and 4 for the Cisplatin and Gentamicin group, respectively. From table 2 and figures 3 and 4 it could be observed that the mean value of serum sodium concentration in group two (Cisplatin group) were found to be non-significantly
different ($P > 0.05$) from that obtained from rats in the control group. However, the Gentamicin group showed that significant decrease in serum sodium level in day 7 and high significant decrease in day 9 when compared to control.

Table (1): Mean values (± standard error)[a] of serum urea, uric acid and creatinine levels (mg/dl) in Cisplatin and Gentamicin induced renal failure

	control	Cisplatin days					Gentamicin days	
		3rd	5th	7th	9th	11th	7th	9th
Urea	**41.06[b] ±3.76**	**66.26[c] ± 10.97**	**258.20[a] ± 33.67**	**151.23[a] ± 37.36**	**47.91[c] ± 16.05**	**60.97[c] ± 1.46**	**340.73[a] ±39.55**	**422.30[a] ±75.24**
Uric acid	**1.98[a] ±0.19**	**2.63[a] ± 0.43**	**1.81[c,b] ± 0.40**	**1.32[c] ± 0.11**	**1.89[c,b] ± 0.16**	**1.81[c,b] ± 0.13**	**1.59[a] ±0.29**	**2.24[a] ±0.25**
Creatinine	**1.06[c] ±0.32**	**1.07[b] ± 0.15**	**2.75[a] ± 0.53**	**1.67[b] ± 0.23**	**1.32[b] ± 0.10**	**1.36[b] ± 0.16**	**4.26[a] ± 0.24**	**3.34[b] ±0.25**

[a]**Means in the same row with different superscripts are different (P<0.05)**

Cisplatin group:

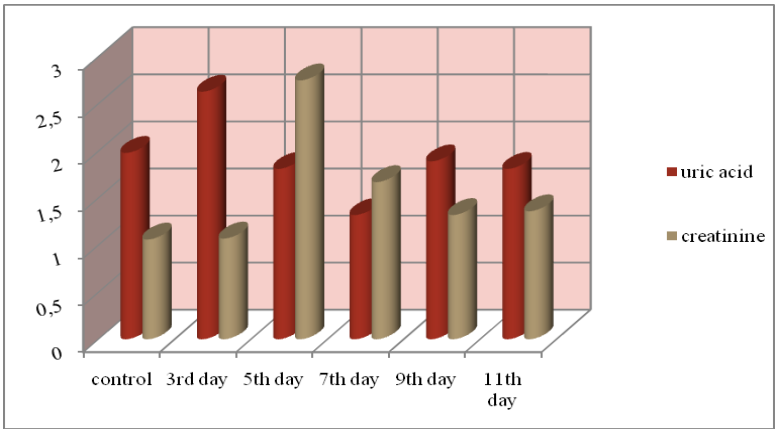

Figure1. The relationship between uric acid and creatinine in the control group at different days in the experiment in the cisplatin group

Genta-group:

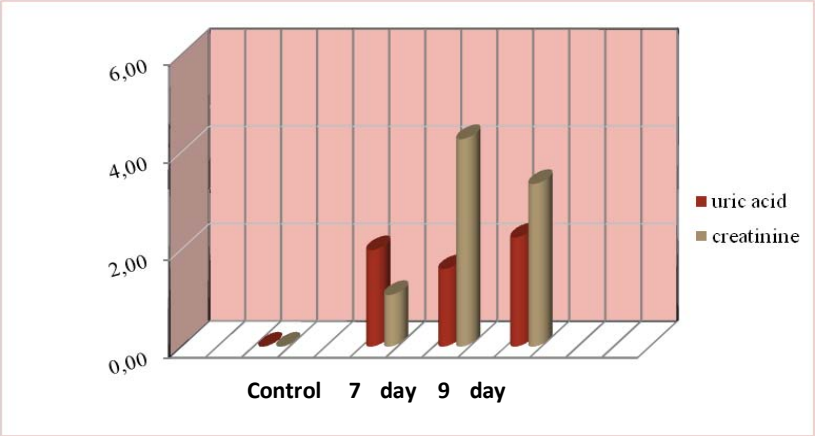

Figure 2. The relationship between uric acid and creatinine in the control group and at different days of the experiment in the gentamicin group

Serum Potassium:

In Cisplatin group (Table 2, Figures 3, and 4) there was a high significant increase ($p < 0.05$) in serum potassium in day 3 and 5. This increase became significant in day 7, 9 and 11 as compared with control. The most significant increase occurred at day 7. On the other hand, serum potassium level in the Gentamicin group) showed significant increase in day 9 as compared to healthy control group.

Serum Calcium:

Table 2 and figures 3 and 4 revealed that there was no significant change of serum calcium in all days of the experiment in either the Cisplatin or the Gentamicin groups in comparison to the control group.

Cis-group:

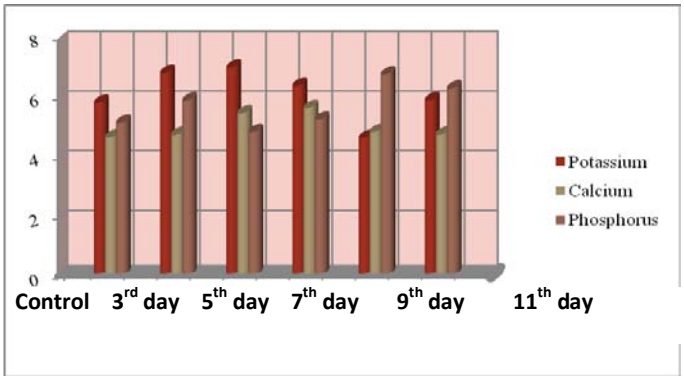

Fig (3): The relationship between potassium, calcium and phosphorus levels and the different days in the experiment as compared to the control

Serum Phosphorus:

As shown in table 2 and illustrated in figure 3, it is clear that in Cisplatin group there were significant increase ($p < 0.05$) in serum phosphorus value in day 3, 5, and 7 and significant increase in day 9 and 11, when compared with control value. On the other hand, the data obtained from the Gentamicin group showed that the serum phosphorus concentration increased significantly in day 7 and day 9 as compared with control value. However, within the Gentamicin group the difference between phosphorus levels in day 7 and 9 were not statistically significant (P >.05).

Table (2): Mean values (± standard error)[a] of sodium, potassium, calcium, and phosphorus creatinine levels (mg/dl) in Cisplatin and Gentamicin groups

	control	Cisplatin days					Gentamicin days	
		3rd	5th	7th	9th	11th	7th	9th
Sodium	143.95a ± 1.02	143.15a ± 2.42	140.62a ± 3.41	142.91a ± 2.77	143.98a ± 3.16	140.56a ± 5.15	133.16a,b ±7.08	115.32b ±8.47
Potassium	5.89a,b ± 0.46	6.89a ± 0.47	7.07a ± 0.69	6.46a,b ± 0.79	4.71b ± 0.30	5.98a,b ± 0.46	7.08a,b ±0.98	8.52a ±o.26
Calcium	4.73a ± 0.28	4.82a ± 0.27	5.54a ± 0.55	5.71a ± 0.51	4.92a ± 0.32	4.83a ± 0.15	4.35a ±0.50	5.34a ±0.30
Phosphorus	5.23c ±0.47	5.97c,b ± 0.17	4.91c ± 0.54	5.33c,b ± 0.40	6.84a,b ± 0.36	6.37c,b ± 0.77	15.96a ±0.36	9.22b ±0.68

[a]**Means in the same row with different superscripts are different (P<0.05)**

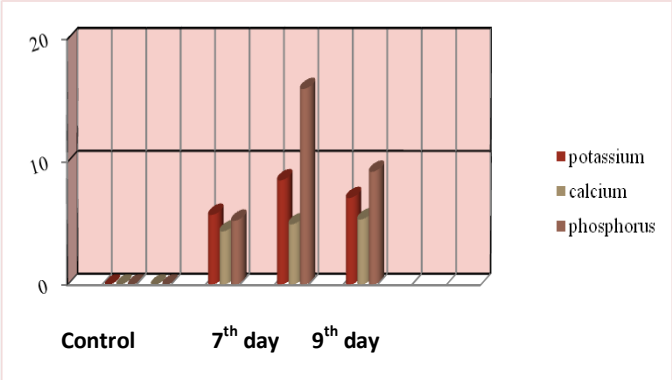

Fig (4): The relationship between potassium, calcium and phosphorus levels and the different days in the experiment in the gentamicin group as compared to the control

Histopathological changes

Macroscopic and microscopic appearance:

The kidneys were enlarged in size, pale in color, and edematous or soft in consistency. The cut section also was pale in color. Microscopically, the kidneys obtained from the control groups (Figures 5A and 5B) show a normal histological structure

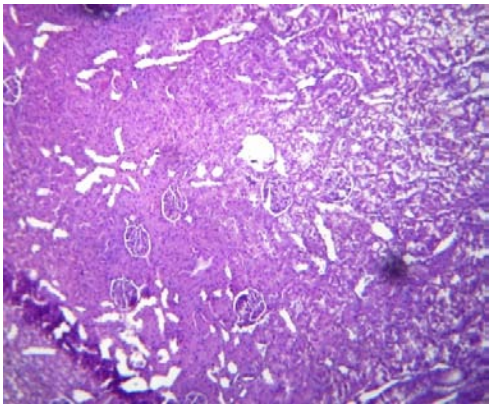

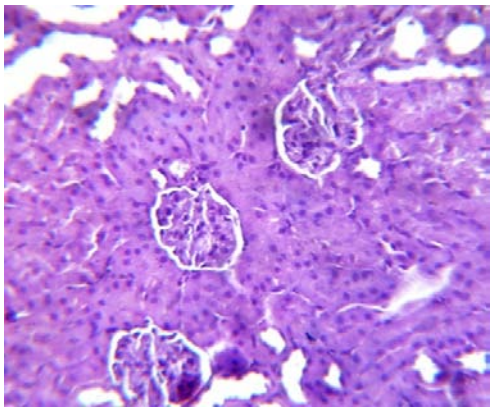

Fig 5 A(Control group): Kidney showed normal histological structure H & E x 100

Fig 5 B (Control group): Kidney showed normal histological structure H & E x 100

a) Cisplatin group

Figure 6A (day 3) depicts renal tubules with a high eosinophilic cytoplasm and with pyknotic nuclei for rats in the day following the Cisplatin administration. Also, the kidney sections showed hyaline casts in their Lumina (Figure 6B, day 3). Some renal tubules appeared to have pyknotic nuclei with cytoplasm vascular degeneration (day 5, figure 6C1). In some renal tubules, there were necrotic cellular debris in their lumina, and others contained albuminous granules (day 7, figure 6D), while some showed cloudy swelling (Day 7, figure

6E). Interstitial fibrous issue (greenish color) with congestion in the inter-tubular blood vesicles was evident (Day 11, figures 6F1, 6F2).

b) Gentamicin group

The hyaline cast the in lumina of renal tubules in shown in figure 7A for kidneys obtained from rats at day 7 post drug injection. Also shown, is the cell infiltration and vacuolation in their cytoplasm (Day 7, figure 7B). At the 9th day (Figure 7C and D) the kidneys showed hyaline cast in the lumina of the renal tubules together with infiltrating cells.

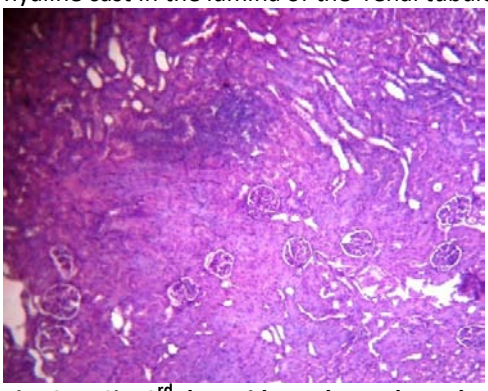

Fig. 6A - Cis- 3rd day: Kidney showed renal tubules high eosinophilic cytoplasm, necrosis and pyknotic. H&E x100

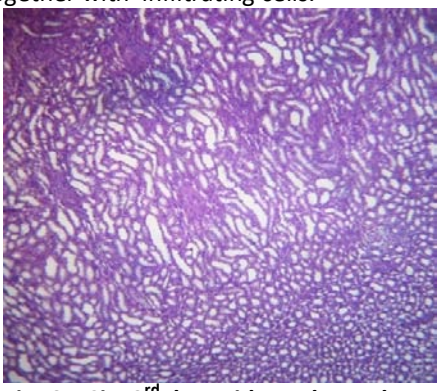

Fig. 6B-Cis- 3rd day: Kidney showed hyaline cast in their Lumina. H&E x 100

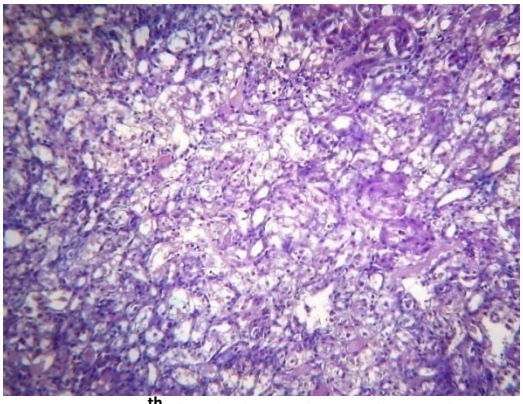

Fig 6C1- Cis 5th day kidney showed: renal tubules showed eosinophilic cast in Lumina, some renal tubules showed pyknotic nuclei with cytoplasm vascular degeneration. H&E x100

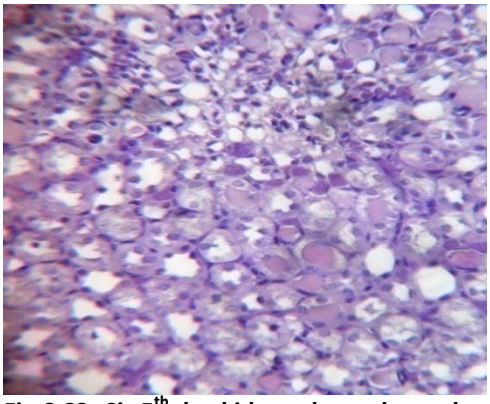

Fig 6 C2- Cis 5th day kidney showed: renal tubules hyaline cast in their lumens H&E x 400

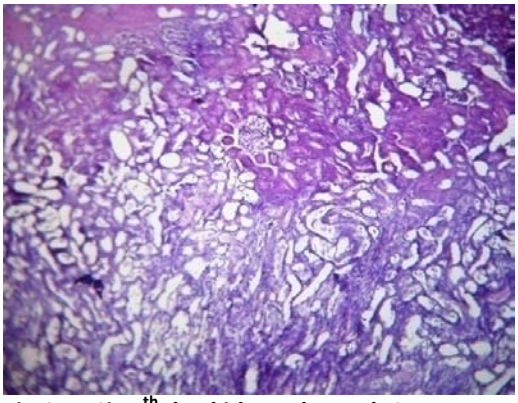

Fig 6 D- Cis 7th day kidney showed: Some renal tubules contain necrotic cellular debris in their Lumina and other contains albuminous granules. H&E x 100

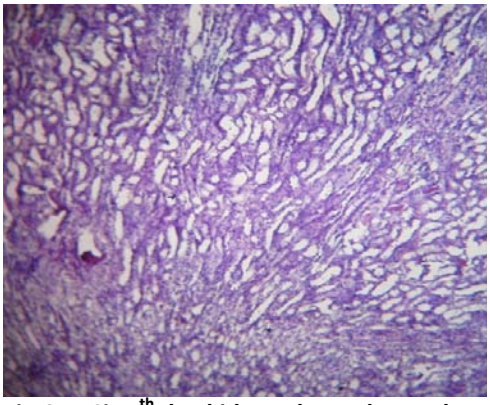

Fig 6 E- Cis 7th day kidney showed: Renal tubules contain hyaline cast and some showed cloudy swelling. H&E 100

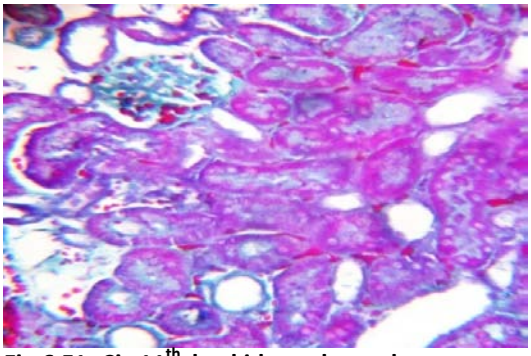

Fig 6 F1- Cis 11th day kidney showed: Interstitial fibrous tissue with congestion in inter tubular blood vesicles. crossman x400

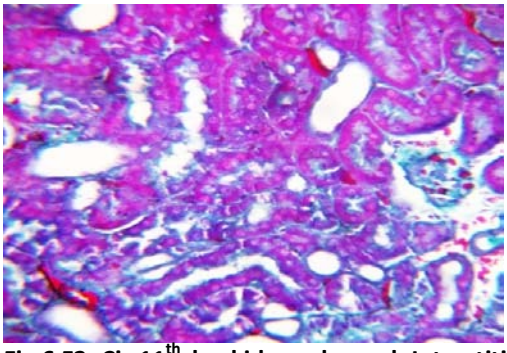

Fig 6 F2- Cis 11th day kidney showed: Interstitial fibrous (greenish color) with congestion in inter tubular blood vesicles. crossman x400

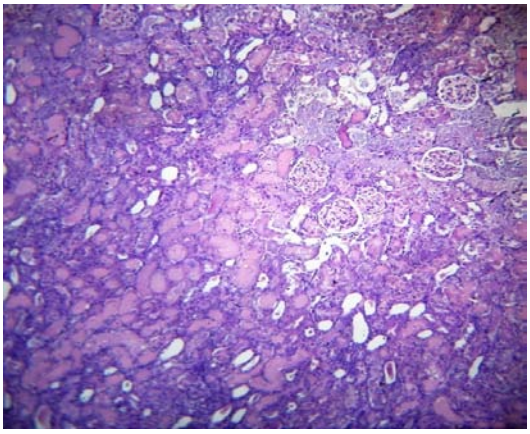

Fig 7A- Genta 7th day kidney showed: hyaline cast in renal tubules in their Lumina. H& Ex 100

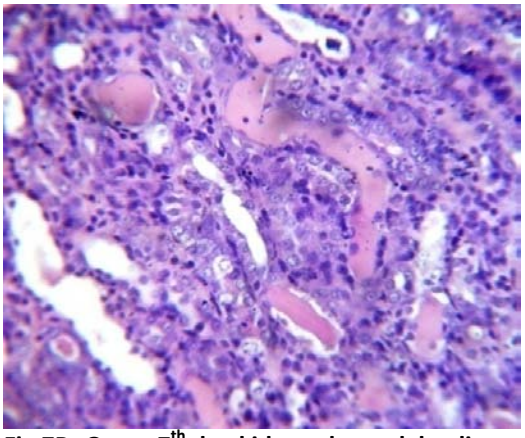

Fig 7B- Genta 7th day kidney showed: hyaline cast in renal tubules in their Lumina + infiltration cell+ vacuolation in their cytoplasm. H&E x 400

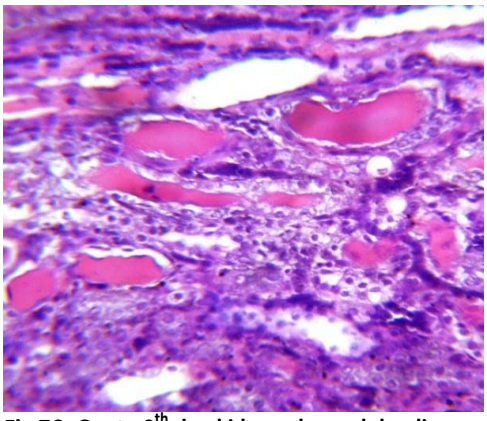

Fig 7C- Genta 9th day kidney showed: hyaline cast in renal tubules in their Lumina + infiltration cell. H&E x 400

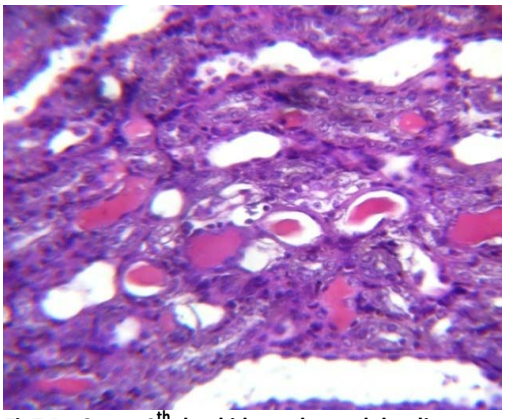

Fig7 D- Genta 9th day kidney showed: hyaline cast in renal tubules in their Lumina + infiltration cell. H&E x 400

DISCUSSION

In present study, the occurrence of renal failure was proved in the Cisplatin and Gentamicin groups by many criteria including: significant number of death cases among the rats during the period of experiment, 65% (13 rats out of 20 in Gentamicin group); and the significant increase (P<0.05) in serum creatinine and potassium levels. This agreed with **Daniel (1998)** who concluded that the increased death rate in case of Gentamicin treated rats is due to uraemia, hyperkalemia, septicemia, and gastrointestinal haemorrage which is due to reduced mucosal cell turnover. In the present study, we did not examine the gastrointestinal tracts for presence or absence of hemorrhage.

The significant increase ($p < 0.05$) in urea, uric acid and creatinine levels observed in experimental groups compared to the control group was similar to that documented by **Secil Aydinoz el al., (2007),** who explained that Cisplatin treatment significantly increased serum urea and creatinine levels, and that indicated development of renal failure. Also, **Secil Aydinoz el al. (2007)** had reported that a single dose Cisplatin injection impaired renal functions and caused severe histopathological injury. This also observed in this study. Marked increase in blood urea and creatinine levels were also noted in the Gentamicin treated group compared to the control rats **Kumar et al., (1999).** Along the same lines**, Schumacher et al. (1990)** reported that aminoglycoside, or Gentamicin, significantly increase both serum urea and creatinine levels. The serum uric acid increase in this study is in agreement with findings of **Kumar and Pandy (1994),** who recorded an increase in serum uric acid with gentamicin injections in goats. The increase that was attributed to the progression of renal failure in experimental groups, might be related to the increased serum xanthine oxidase enzyme, the key enzyme in biosynthesis of uric acid, that followed the uremia **Zager & Gnur (1989).**

Cisplatin treatment increased serum urea and creatinine levels significantly ($p < 0.05$), indicating development of renal failure, as suggested by **Secil Aydinoz el al. (2007)**. Although the underlying mechanisms for this increase are not clear, recent evidence

suggests that reactive oxygen species and the renal antioxidant defense system are involved in cisplatin-induced nephrotoxicity **Conklin (2000).**

The data of the present investigation for the Cisplatin group (Table 2) revealed that the serum sodium level in rats in experimental renal failure showed no significant change. However, in the gentamicin group, sodium level decreased at day 7 and 9th after the drug injection, and this is not similar to the results obtained by **Ruth Bier., et al (1982). Ruth Bier., et al (1982)** stated that the mean plasma sodium concentration in Gentamicin-induced renal failure was within the normal range in the Sprague-Dawley animals. The discrepancy may be due to the different experimental condition of the experimental animals or laboratory procedures.

The increase in serum potassium level observed in experimental group two (Table 2) and three are consistent with the findings of **Marshal (1988),** who documented a hyperkalaemia after the progression of renal failure in the experimental groups. **Marshal (1988)** indicated that this could be attributed to the a decreased excretion of potassium. This decrease might have been coupled with both the loss of intracellular potassium to extracellular fluid (due to tissues break down) and the intracellular buffering of retained hydrogen ions.

In our study, the increase in serum inorganic phosphorus (Table 2) with the progression of renal failure in an agreement with the findings of **EL-Sayed(1990)** who observed in uremic patients a hyperphosphatemia in the uremic patients. In addition, the increased levels of organic phosphorus after development of renal failure in the experimental group might be attributed to the increased catabolism of protein **Abbas (1990)**. Furthermore, the highly significant increase in serum organic phosphorus after the progression of renal failure in experimental groups might be due severity of secondary hyperparathyroidism and skeletal phosphate released by osteoplatic and osteolysis (**Szabo., et al., 1990).**

Histopathology:

The kidney is one of the organs routinely assessed in preclinical drug safety evaluations. It is susceptible to cell damage by xenobiotics due primarily to high blood flow, xenobiotic metabolism, drug clearance, and during the processes of urine formation. Therefore, epithelial cells lining the nephrons, as well as glomerular cells, are often exposed, more than other organs of the body to the insult of the higher levels of drugs, compounds obtained from the environment, and/or reactive metabolites **Werner et al., (1995).** These insults will result in histopathological changes such as those observed in this study. Early damage that eventually lead to renal failure was also proved by the histopathological changes observed in this study. These histopathological changes revealed the kidney damage, and the changes in the tubular structures of renal specimens stained with haemotoxylin- eosin and Crossman stain.

The histopathological changes observed in the renal tissues in 3rd day had occurred before the increase in serum creatinine, and that agreed with **Rupesh (2004),** who recognized that creatinine and BUN are relatively insensitive marker of early glomerular injury, as typically up to 75% of nephrons have to be nonfunctional before there are significant elevations in serum levels of BUN or creatinine. Further, in this study, it was

evident that tubular necrosis was the most characteristic lesion, together with cloudy swelling, hyaline and granular casts with necrosis, and the high eosinophilic cytoplasm. These findings were similar to the results of **Racusen (1997),** who found that the causes of interstitial nephritis included infection and immune-mediated reactions. With infection, polymorphonuclear leukocytes may be seen in tubules as well as in interstitium. On the other hand, inflammatory infiltrates observed in hypersensitivity reactions might have been due to drug exposure, featured by the increased presence of eosinophils as observed in this study. The renal epithelial cell injury is often produced by inflammatory processes, such as those induced by drugs. This change in the tubules could be attributed to renal ischemia and accumulation of waste products in the congested capillaries, and resulted in the change observed in this study, which are similar to those found by **Pastoriza et al., (1979). Pastoriza et al., (1979)** argued that "because gentamicin uptake by the proximal tubule appears to be load dependent (absolute absorption increasing with enhanced tubular gentamicin load) it is conceivable that animals with a higher GFR may accumulate more of the aminoglycoside because of a higher filtered load enhancing the possibility of toxicity". On the other hand, **Loeb (1998)** indicated that it is also possible that with continuous drug administration, a lower fraction of the filtered load might be reabsorbed. Administration of Gentamicin, the prototype aminoglycoside antibiotic, induces proximal tubular necrosis in rodents **Houghton, et al., (1986).** It is generally agreed that similar to cisplatin, gentamicin accumulates in proximal tubule cells via an energy-dependent transport. Once inside the cell, the cell lysosomes take up gentamicin, which will eventually cause a lysosomal storage disorder called phospholipidosis that is evidenced by increased accumulation of phospholipids in tissues.

Our findings agree with **Secil Aydinoz el al. (2007)** in that the Cisplatin treatment increased both tubular injury and hyalin cast formation compared to the control. **Huang et al., (2001)** documented that single dose of cisplatin injection impaired renal functions and caused severe histopathological injury, indicating the development of renal failure. They indicated that cisplatin tends to accumulate, via probenecid-inhibitable organic ion transporters, in increased amounts in epithelial cells that line the S3 segment of the proximal tubule. There it depletes glutathione, resulting in oxidative stress-induced cell death.

Loeb (1998) indicated that in preclinical models and also in the clinical settings, the damage that occurs to the kidneys is often not easy to assess, because of the additional functional capacity of the kidneys. In most instances, a large part of the kidney must be damaged before an alteration in renal function can be observed. The accepted biomarkers of nephrotoxicity, such as BUN and creatinine, are not reliable diagnostic markers that can predict an earlier or minor damage to the functional capacity of the kidneys. Understandably, direct measurements of renal function, and increases in serum concentrations of these biomarkers occur only after substantial renal injury.

In conclusion, traditional measures of renal damage, creatinine and elevated BUN, usually occur after significant kidney damage has occurred. This study showed that the histopathological changes in renal tissues in Cisplatin and Gentamicin-induced renal failure appeared in early stage of renal dysfunction in comparison to the changes in serum levels of traditional biomarkers such as urea and creatinine. Therefore, more studies are needed to determine the correlations between biochemical markers and histopathological changes

that may be used in prediction equations to assess earlier drug-induced insults to the kidneys before renal failure progresses.

Acknowledgment: The authors were greatly thankful to Prof. Dr. Ihab M. A. El Zoghbi, and Dr. Mona of the Department of Histology, Faculty of Veterinary Medicine, Benha University for their help with the processing of the kidney specimens for the histological evaluations. Thanks are also due to Dr. Said Mohammed Alshafae of the Department of Pathology, Faculty of Veterinary Medicine, Benha University for the histopathological evaluations. We appreciate the support extended for us by the Faculty of Veterinary Medicine, Benha University, that allowed us to conduct this research.

References:

1- Abbas, A. E. (1990): Studies of calcium and phosphorus levels in renal failure. M. Sc. Thesis, Fac. Med. Tanta University, Egypt.

2- Abdel-Gayoum, A. A; Ali B. H; Abdel Razig K. M, Bashir, A. A, Ghywarsua, K. Effect of gentamicin-induced nephrotoxicity on some carbohydrate metabolism pathways in the rat renal cortex. Arch Toxicol 1994;68:643-7.

3-Bagnis C; Beaufils H; Jacquiaus C; Adobra Y; and Jouanneau C. (2001). Erythropoietin enhances recovery after cisplatin-induced acut renal failure in the rat. Nephrol. Dial. Transplant.16:932-938.

4-Bancroft JD and Stevens A., (1977). Theory and practice of histologigal technique. 3rd edition. Churchill· Livingstone, New York. Pages 89-90.

5-Chambers and Hadley W. K. (2001). Aminoglycosides and spectinomycine. In Basic and Clinical Pharmacology 8thed By Katzung BG (eds), Lang medical books, Mc Graw-Hill, New York,:786-789.

6- Conklin K.A. (2000). Dietary antioxidants during cancer chemotherapy: impact on chemotherapeutic effectiveness and development of side effects. Nutr Cancer.; 37: 1–18

7- Daniel H (1998): Acute renal failure. In the Washington Manual Of Modern Therapeutic 29th ed.: 227- 243

8- EL.Sayed, S. M. (1990). Study of some aspects of rennin-angiotensin-aldosterone system in chronic renal failure. Ph. D Thesis, Fac. Med. Alex. University, Egypt.

9- Gitelman, H., (1967) Clinical Chemistry-Calcium-O-Cresolpthalein complexone method: Anal biochemistry 20, 521

10- Gray, Peter. (1954). The Microtomist's Formulary and Guide. Originally published by*:* – The Blakiston *Co.* Republished by*:*– Robert E. Krieger Publishing Co.

11- Heingard and Tiderstrom K, (1973). Determination of serum creatinine by direct colorimetric method. Clin Chem Acta, 43: 305-310.

12- Henry, J.R., (1964) Clinical Chemistry, Harper and Row, Puplisher, New York 415

13- Houghton DC, Lee D, Gilbert DN, Bennett WM (986). Chronic gentamicin nephrotoxicity. Continued tubular injury with preserved glomerular filtration. American Journal of Pathology, Vol 123: 183-194,

14- Houort R. L (1985). The estimation of plasma creatinine. Annual Biochem. 53: 36-49.

15- Huang Q, Dunn RT, Jayadev S (2001) Assessment of cisplatin-induced nephrotoxicity by microarray technology. Toxicol. Sci. 63(2).

16- Kumar, R. and Pandy, N. N. (1994): "Biomedical profile of Gentamicin intoxication in goats." Indian J. Animal sciences, 64 (11): 1147- 1150.

17- Kumar, K.vijay M.U.R. Naidu, Anwar A. Shifow, K.S. Ratnakar (1999). Lacidipine protects against cyclosporine- induced nephrotoxicity in rat. Central Research Laboratory, Department of Clinical Pharmacology and Therapeutics, Punjagutta, Hyderabad, India Jan;81(1):60-6

18-Lesley Stevens, MD,Ronald D Perrone, MD, Richard H Sterns, MD,Theodore W Post, MD, Assessment of kidney function: Serum creatinine; BUN; and GFR,last literature review version 18.1.2010.

19- Loeb W. F (1998): The measurement of renal injury. Toxicol. Patho. l26 (1):26-28

20- Marshal, J. W (1988); In Illustrated text book of clinical biochemistry. 1st edition. Grower, Publishing, (34- 42) cleveland St. London, W. I. P.; 5 FB, England PP. 11- 17.

21-Mellitis, J., longstreth, and P. S. Leitman (1980). Double-blind comparison of the nephrotoxicity and auditory toxicity of Gentamicin and tobramycin. N. EngZ. J. Med. 302: 1106-1119,

22- Pastoriza-Munoz E, Bowman RL, Kaloyanides GJ (1979). Renal tubular transport of Gentamicin in the rat. Kidney, 16:440—450,

23- Patton C. J and Crouch, S. R. (1977). Spectrophotometric and kinetics. Anal. Chem. 49 :464-469.

24- Phosphorus imbalance. Faqs.org
http://www.faqs.org/health/topics/97/Phosphorus-imbalance.html last accessed April 2010

25- Racusen LC (1997): Pathology of acute renal failure: Structure/function correlations. Advances in Renal Replacement Therapy, 4 (Suppl. 2): 3–16.

26-Rodriguez-Barbero **A,** Bosque E. Rivas-Cabaiiero L, Arevalo **h1.** Lopez-Novoa JM (1992). Effect of platelet activating factor antagonist treatment on Gentamicin nephrotoxicity. *Mrdiat InJammat,* 1 :23-26,.

27- Roodhoof, H.; Van- hoeck, K. and Vanacken. R. (1990): Hypophosphatemia in infants on continuous ambulatory peritoneal dialysis ". Clin. Nephrol. Sept. 34 (3) : (131 – 135).

28- Rupesh P. Amin; Alison E. Vickers; Frank Sistare; Karol L. Thompson; Richard J. Roman; Michael Lawton; Jeffrey Kramer; Hisham K. Hamadeh; Jennifer Collins; Sherry Grissom; Lee Bennett; C. Jeffrey Tucker; Stacie Wild; Clive Kind; Victor Oreffo; John W. Davis II; Sandra Curtiss; Jorge M. Naciff; Michael Cunningham; Raymond Tennant; James Stevens; Bruce Car; Timothy A. Bertram; Cynthia A. Afshari (2004). Identification of Putative Gene-Based Markers of Renal Toxicity. Environmental Health Perspectives. 112(4):465–479.

29- Ruth bier telxei1ta, Jan Kelley, Helen Alpert, vic toria N0 Pardo, and Carlos A (1982),. Vaamonde: Complete protection from Gentamicin-induced acute renal failure in the diabetes mellitus rat . Kidney International, Vol. 21pp. 600—612

30- Secil Aydinoz, Gunalp Uzun, Hakan Cermik, Enes Murat Atasoyu, Senol Yildiz, Bulent Karagoz and Rifki Evrenkaya (2007). Effects of Different Doses of Hyperbaric Oxygen on Cisplatin-Induced Nephrotoxicity, Renal failure Journal. Vol. 29, No. 3 , Pages 257-263

31- Schultz A (1984). Uric acid. In Clinical Chemistry. Kaplan A et al. (Editors). The C.V. Mosby Co. St Louis. Toronto. Princeton. Pages: 1261-1266, and 418.

32- Schumacher, J.; R. C.; Spano, J. S.; Hammond, L. S.; McGuire, J.; Duran, SH.; Kemppainen, R.J. and Hughes, F. E. (1990). Effect of diet on Gentamicin induced nephrotoxicosis in horses. Am. J Vet. Res; 52 (8): 1274- 1278.

33-Stordal B, Davey M (2007). Understanding Cisplatin resistance using cellular models. IUBMB Life 59 (11): 696–9.

34- Szabo, R.; Sollay, S. and Taus. Q. (1990). The serum hormone levels, phosphate complex concentrations and enzyme activities in hemodialysed and kidney transplanted children". Acta- paediatr., Hung. 30 (1): 73-88.
35- Trinder, P (1951). Photometric determination of serum sodium: Analyst, 76:596,
36- Terri, A. E. and Sesin, P.G. (1958), Determination of serum potassium by using sodium tetraphenylboron. Am. J. Clin. Path., 29:86- 90.
37- Toback F. G: (1992) Regeneration after acute tubular necrosis. Kidney Int'l. 41:226–246
38- Werner M, Costa MJ, Mitchell LG, Nayarr (1995) Nephrotoxicity of xenobiotics. Clin. Chim. Acta 237(1-2):107-154
39- Wikipedia, (2011). Potassium http://en.wikipedia.org/wiki/Potassium. Last accessed June, 2011
40- WiseGeek, what is renal failure? http://www.wisegeek.com/what-is-renal-failure.htm, last accessed May, 15th, 2010.
41- Zager, M. and Gmur., 1989: "The effect of exanthine oxidase inhibition on ischemic acute renal failure in the rats". Am. J. Physiology. Dec., 257 (6P7.2), F. (953-958).

IMMUNOSUPRESSANT ACTION OF AFLATOXIN B1 ON PRIMARY LYMPHOID ORGANS IN DUCKLINGS

Carmen Solcan, Cotea C., Panagachi Gogu Mihaela, Gh. Solcan
Faculty of Veterinary Medicine Iasi
carmensolcan@yahoo.com

Abstract
Aflatoxins are potent hepatotoxins, immunosuppressant, mutagens and carcinogens. The study aimed to prove the immunosuppressant action of aflatoxin B1 (AFB1) in ducklings experimentally treated each day, from the 7th day of life, using 2 dosages 1mg/kg b.w in E1 group and 9mg/kg b.w in E2 group for 21 days. Histopathology and electronomicroscopy of studies of thymus and bursa of Fabricius were made on 7th , 14th and 21th days of experiment . In E1 group (tratead with 1mg/kg b.w) hidropic degeneration, necrotic foci and moderate lymphoid depletion was observed after the 14th day of poisoning. In E2 group (treated with 9mg/kg b.w) small lesions of thymus were observed even after 7th day of poisoning but intense lesions were observed after 21st day, consisting in marked proliferation of non-epithelial cells in the reticulum network, in medulla zone and presence of mucous cells and small mucous cysts.
Lymphoid depletion of Fabricii bursa appeared from the begining and persisted during the from recovery phase of experimental aflatoxicosis. After 3 weeks of exposure bursa of Fabricius revealed a lack of cortico-medulary differentiation, lymphoid depletion and necrosis. Ultrastructurally the thymus showed condensation of cromatina, partial lysis, disorganization of RER and loss of ribosomes, proliferation of SER dependent of AFB dose, suddesting that membrane are the major targets of AFB1.
Keywords: aflatoxin B1, ducklings, immunosupression

Aflatoxins, on a worldwide scale, are important mycotoxins in human foods and animal feedstuffs (Williams *et al.*, 2004). Health effects occur in companion animals, livestock, poultry and humans because aflatoxins are potent hepatotoxins, immunosuppressant, and mutagens and carcinogens (Gupta, 2007). Bursa of Fabricius and thymus are susceptible to aflatoxicosis. The bursa Fabricius contrary to the other organs, decreased in weight with incresead aflatoxin (Kubena et al.1990).

Micotoxins of economic importance in poultry production are mainly produced by *Aspergillus*, Penicillium and Fusarium. fungi. Aflatoxins B_1, B_2, G_1, and G_2 are mycotoxins that may be produced by three moulds of the *Aspergillus* species: *A. flavus, A. parasiticus* and *A. nomius,* which contaminate plants and plant products. Cytotoxic effects through interaction of the AFB1 metabolite, AFB1-8-9-epoxie with the nucleophilic sites in macromolecular components forming AFB1-DNA adducts (Sur and Celik, 2003). Inhibition of RNA, DNA and protein synthesis through various toxicity mechanism, however, might influence the immunosuppressive effects of these fungal metabolites (Lawson el al. 2006). Aflatoxin B1 (50 µg/Kg BW) increased the levels of caspase–3 (apoptotic marker) activity, tissue levels of lipid peroxides, nitric oxide, and reduced the levels of antioxidants. Therefore, an increase in the levels of intracellular free radicals and reduction in antioxidant levels could contribute to various deleterious clinical signs associated with aflatoxicosis. Apoptosis, increased colonization of pathogenic microorganism, cytotoxicity and oxidative

stress, inhibition of protein synthesis and lipid peroxidation are characteristic of toxic effects.

A decrease in total protein levels would lead to decreased efficiency of the immune system since the key mechanisms of some immune responses are the production of factors that kill pathogens, such as antimicrobial peptides and proteins (Yarru 2009).

Apoptosis may be induced by xenobiotics due to oxidative stress (Hiroshima et al 2002), decrease in apoptotic suppressors, or enhanced expression of apoptosis genes (Upadhyay et al. 2008). Necrosis is the predominant form of cell death in most toxic insults. The term "necrotic" is used to describe "dead and dying" cells which are often identified. Degenerative changes may precede necrosis. Altered macrophage function might contribute to problems associated with antigen processing and presentation. Reduction in the reactive oxygen intermediates reflects the suppression of intracytoplasmatic antigen degradation.

Materials and methods

Animals and protocols

Experiment were used 45 ducklings, which after a period of one week of accommodation to living conditions provided, were randomly divided in 3 groups: two experimental (E) and control (C). Ducklings were reared on sawdust litter, were provided specific microclimate conditions for age, room temperature gradually decreasing from 32 ° C, to 18 ° C. Commercial-type food, free of AFB1was administered ad libitum. E group received daily by gavage aflatoxins B1 (AFB1-Sigma Chemicals Co.) eluted in sterilized sunflower oil at a dosed 1mg/ kg b.w (LE1) and 9 mg/kg b.w AFB1 (LE2) at the beginning of the experiment, then decreased proportionally with increasing of ducks weight, so the end of the experiment. The control group received only eluent (sterilized sunflower oil). At the end of each week during the experiment, chicks were individually weighed. Five ducks were selected by random from each group and were killed at 7th, 14th and 21st day of the experiment.

Histopathology was performed in thymus and bursa Fabricius fragments fixed in 10% formalin solution, embedded in paraffin, sectioned at 5µm and stained by HEA, PAS and prepared for metods electronomicroscopic investigations. Electronomicroscopic investigations were carried out with transmission electron microscope TESLA BS 500. The method involved the following steps: harvest, prefixing (with 2% glutaraldehyde in PBS, 2 hours at 40°C), washing, fixation (with 2% osmium tetraoxide), washing, drying, staining the ground with uranyl acetate and fosfotungstic acid infiltration, EPONE impregnation, polymerization, ultramicrotom sectioning (sections of 60-150nm), deposition on grids, staining the ground with uranyl acetate and Reynolds solution.

Results and discussions

After 1st week of AFB1 poisoning, E1 group, the lesions of thymus were not evident, a clear distinction between cortex and medulla being observed. After 2 week of poisoning the thymus cortex and medula become less atrophic (fig.1a), with hydropic degeneration of residual cells and necrotic foci. Moderate lymphoid depletion is seen in the thymus starting with the cortical lymphocytes, but stroma cells are not affected. Stroma cells were proliferated (fig. 1b).

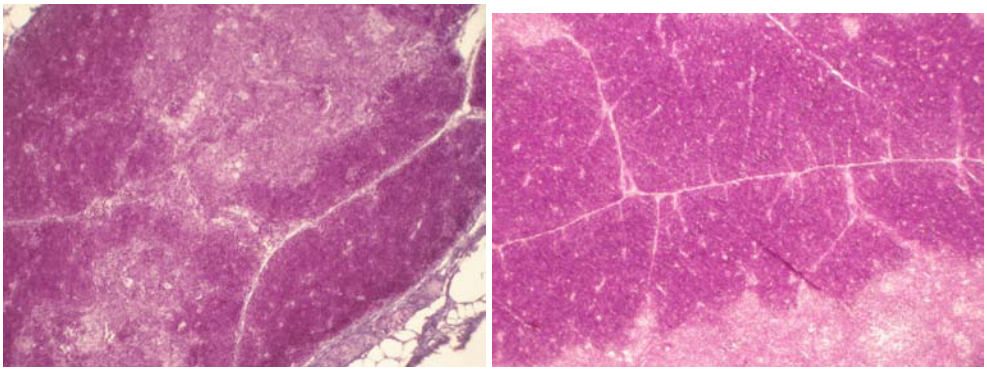

Fig. 1. Thymus after 2 week after experimentaly intoxication with AFB1. The lesions of thymus were not evident, a clear distinction between cortex and medulla being observed.

In E2 group small lesions were observed after first week of exposure, consisting in reduction of cortical zone and agglomerations of reticular cells into the medular zone. After 2 weeks of exposure to AFB1 the limit between cortical and medular zone is indistinguisted reticular cells from medular zone became secretory and also into this zone small PAS positive zones consisting from colloid secretory reticular cells. Lymph cells into this region are reduced (fig. 2a, b).

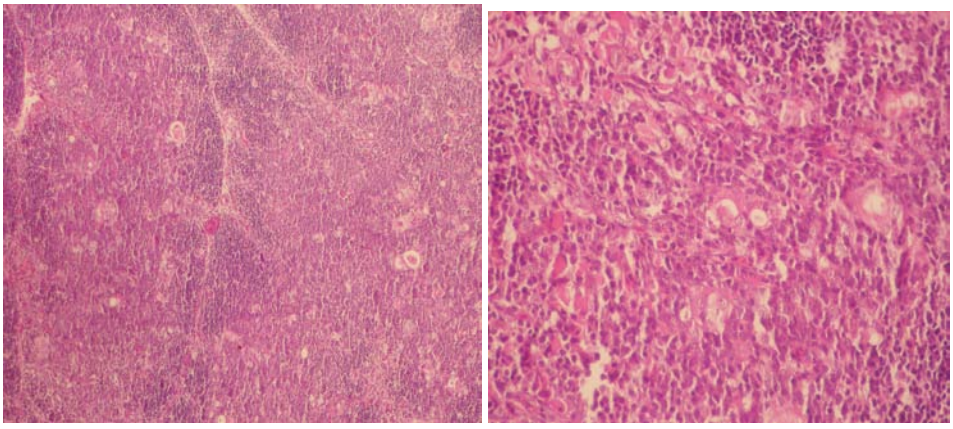

Fig.2a. Histochemical staining HEA. Thymus 2 weeks after experimentaly intoxication with AFB1.a. The cortical shows atrophy and small necrotic foci (b).

Thymic intense histological lesions appeared at 3 weeks (LE2) after experimentaly intoxication and involved a marked proliferation of non-epithelial cells in the reticulum network, in medulla zone (fig.3a), the presence of mucous cells and more small mucous cysts (fig.3b).

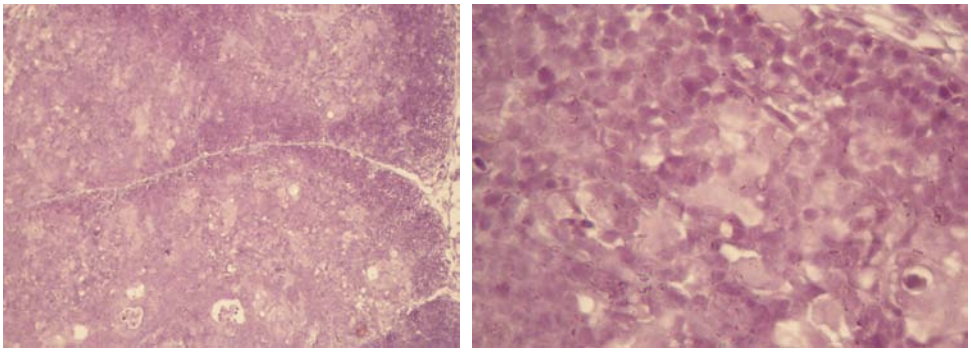

Fig.3. Histochemical staining HEA. Thymus 2 weeks after experimentaly intoxication with AFB1 (a). The cortical shows atrophy and small necrotic foci (b).

Normally the thymus has distinct cortical and medullary regions that demonstrate thymocytes at serial stages of maturation. Thymocytes undergo positive and negative selection on the basis of their T-cell receptor specificities and the majority of cortical thymocytes die by apoptosis. The mature thymocytes that survive accumulate in the medulla (Eguchi *.et al. 1992*). Lymphoid depletion and increased number of reticulum cell hyperplasia was observed in all trated chickens.

In our study cellular depletion in the folicle medulla of the bursa Fabricii appeared from the begining and persisted during the recovery phase in experimental aflatoxicosis. Bursa Fabricius after 2 and 3 weeks of exposure to AFB1 showed mild to severe atrophy of the lymphoid follicles with small necrotic foci, infolded epithelium, hydropic epithelial degeneration, and proliferation of reticular cells (fig.4a). Fibrous tissue gradually increased, and large mucoid cysts were evident (fig. 4b).

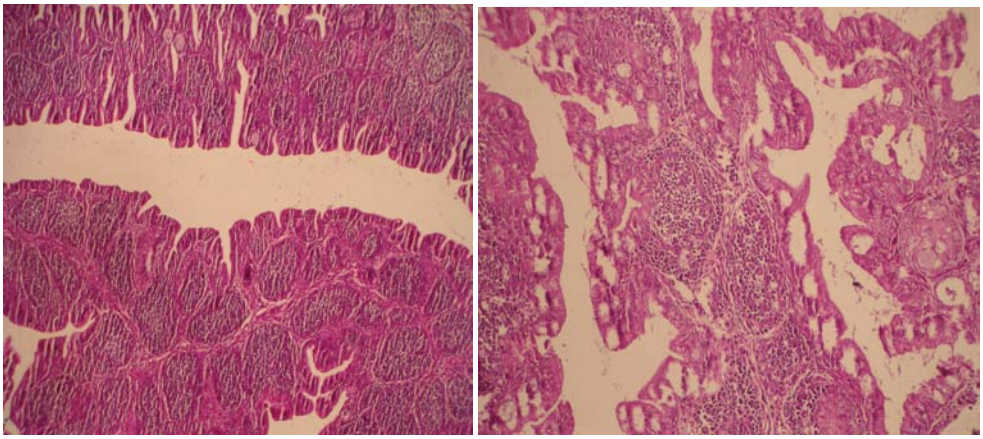

Fig.4. Bursa Fabricius after 2 weeks of exposure to AFB1(a), nonlymphoid cells from interfollicular and epithelium associated to proliferated follicle and cysts formed by epithelial cells and (b)

After 3 weeks of exposure the bursa of Fabricius in AFB treated group revealed a lack of cortico-medularry differentiation and generalized lymphoid depletion and necrosis(fig.5a). Bursal follicles have a reduced cortical zone in which necrotic foci may be seen. Folicle associated epithelium is folded and consists from 2 layers of cells, showing numerous necrotic foci (fig.5b)

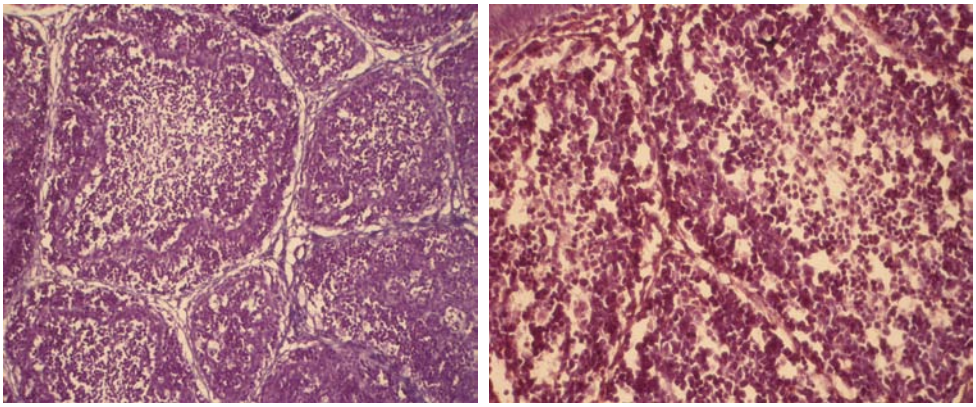

Fig.5. After 3 weeks of exposure AFB1 Depletion of lymphocytes from the medullary region of bursal follicles. Necrosis area in cortical and medulary zones. Epithelium associated to folicle proliferated. Hematoxilin-eosin stain (b).

The germinal center of the lymphoid follicles appears to provide a microenvironment for the generation of memory B and plasma cells. Following stimulation with antigen, B-cell blasts seed the primary follicle wich matures to a secondary germinal center with well defined anatomic zones. Ultrastructural study of the thymus showed marked changes of cell nuclei from focal condensation of chromatin to partial lysis (fig. 6a). Disorganization of ruguous endoplasmic reticulum (RER) with dilatation, cisternal irregularity and loss of ribosomes attached to the membrane surface was observed. Later fragmentation of RER was observed. There were varying amount of proliferation of smooth endoplasmic reticulum depending on the dose of AFB1. Focal membrane degeneration and rupture of the lymphocytes were often observed (fig. 6b). In some of the cells there was a paucity of specialized cytoplasmic organelles and a decrease in the electron density of the cytoplasm giving the cells a pale appearance. The nucleus showed changes from focal condensation of chromatin to partial lysis. Degenerative changes of endoplasmic reticulum (ER) seem to suggest that the membranes per se are the major targets of AFB1 injury. A lymphocite with apoptotic changes; vacuolae, cysterns of endoplasmic reticulum dilated and fragmented. It is clear that disorganization of RER is consistent with the reported decrease in protein synthesis in AFB1 administration.

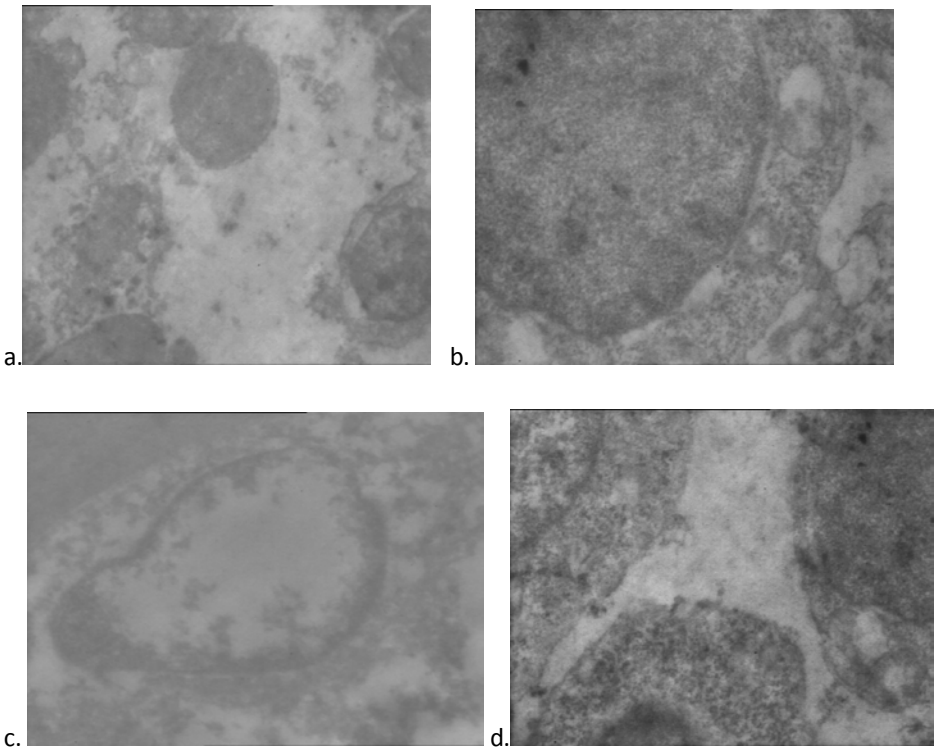

Fig. 4 Lymphocytes with reduced cytoplasma and dilated cysterns (a). A lymphocite with apoptotic changes; vacuolae, cysterns of endoplasmic reticulum dilated and fragmented: 3k4M (b). Thymus lymphocyte with chromatolysis, condensed heterocromatine, lipidic droples in perinuclear cysterne shows lysis zones; 8k7M. c. A lymphocite with apoptotic changes; 2K4M (d).

Ultrastructural study of the bursa Fabricius showed lymphocyte with cysterns of endoplasmic reticulum dilated and fragmentated, intracitoplasmatic lipidic vacuolae (5a,b). Activated reticular cell with well developed ruguous endoplasmic reticulum, dilated cysterns and free ribosomes (5c). Nuclei showed corticala hyperchromatosis and lipidic inclusions betwen the two layers of nuclear membrane, looking as vesicles attached to the nuclei (fig5a,c)

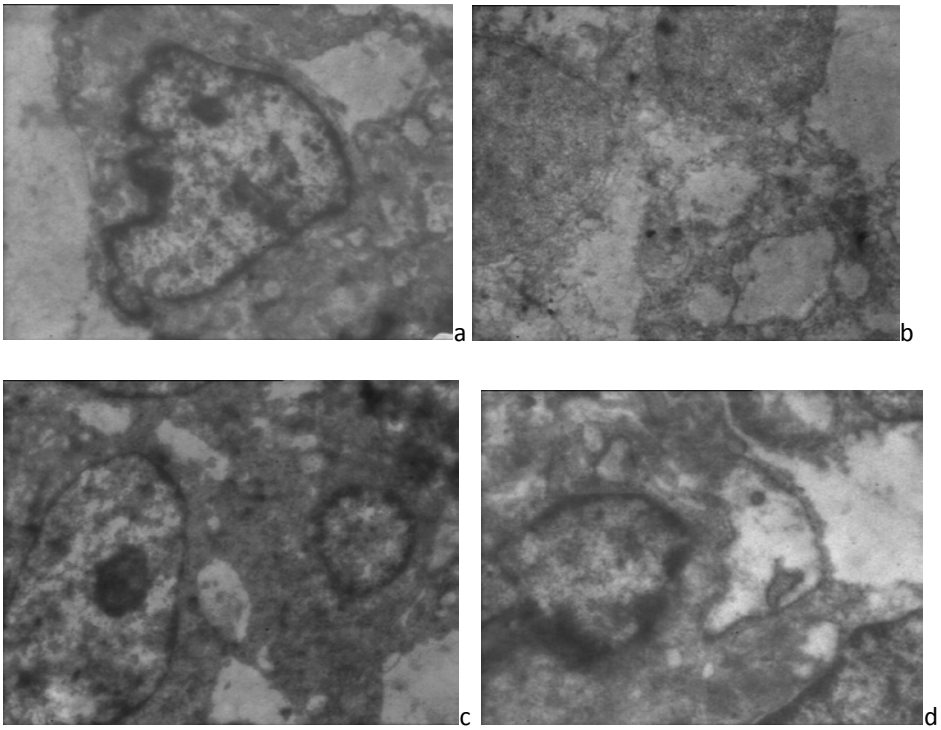

Fig. 5. Bursa Fabricius. Lymphocyte with cysterns of endoplasmic reticulum dilated and fragmentated. Intracitoplasmatic lipidic vacuolae, 6k2M.
b. A lymphocite with apoptotic changes, 2K4M
c. Activated reticular cell with well developed ruguous endoplasmic reticulum, dilated cysterns and free ribosomes, 8k7M.

Discussions

A significant reduction in the body weight and absolute weight of liver, bursa of Fabricius, spleen and thyroid gland was observed in the higher dose treated group. Atrophy and lymphoid depletion were seen in the thymus and bursa of Fabricius from chicken fed AFB1. Jakhar et al. 2004 conducted an experiment upon feeding of AFB1 at rate of 1ppm to 2 week old Japanese quail for a period of 8 weeks produced mild depletion of lymphocytes, cystic degeneration and fibrous tissue proliferation in bursa of Fabricius. Ortatatli et al. 2005 conducted an experiment to evaluate the pathological changes in broilers fed a diet containing a low level of AFB1 and clinoptiolite until 42 days of age.

In the long-term trials, which were the other parts of this study, an intermediate amelioration was observed in the adverse effects of low AF levels (100 ppb) on growth inhibitory and immunotoxic effects (Oguz et al.2003 of AF in broilers by dietary clinoptilolite (15 g kg -1).

It has been reported that follicle associated epithelium (FAE) of bursal follicles are the major antigen presenting cells to the lymphoid cell population and an impairement in its structure and function might severely affect both cellular and antibody responsiveness of the chicken immune system (Sur et.al., 2003). The reduction in the mitotic index may be atritubable to protein syntesis imhibition.

De Recondo et all. 1966 demonstrated that aflatoxin acts directly on the DNA molecule and inhibits its ability to act as a primer for DNA synthesis. A single dose (3 mg/kg) of toxin caused marked reduction in the mitosis and DNA synthesis. Aflatoxin was shown to inhibit RNA polymerase activity and prevented DNA dependent RNA synthesis. The inhibition of RNA synthesis leads to inhibition of protein synthesis. Extensive studies have been carried out on the metabolism of aflatoxin. The toxin has to be bioactivated before manifests its biological effects. Epoxidation of AFB1 by liver microsomal enzymes is an important step and this epoxide is carcinogenic. The type of metabolic product varies with the species.

Aflatoxin inhibits the histological development and functional maturation of lymphoid organs. A significant reduction of the peripheral T-lymphocytes counts in thymus in AFB1 treated birds was observed. Lymphoid cell depletion in cortical and medullary areas of thymuses and bursal follicles were predominantely observed in AFB1 treated birds. Such birds showed flattened and degenerative reticular cells and blood vessels in thymic medulla (Sur et al 2003).

Immunosuppression is an important effect of aflatoxin (Verma.J. *et al*. 2004. Aflatoxin causes impaired immunogenesis in livestock and leads to various disease outbreaks, some times even after vaccination (Gallikeev, K.H.L. 1968) . Thaxton et al. 1974 observed depression of agglutinin titre to sheep erythrocytes in chicks trated aflatoxin. Aflatoxin affects cell mediated immunity response (CMI) also. Macrophages were found to be less phagocytic in aflatoxicosis (Michael, G.Y. and colab., 1973 Richard, J. L. et al 1975). There was also reduction in the graft-versus-host response in chicken given aflatoxin (Giambrone JJ, et al 1978). Generally, aflatoxin causes suppression of humoral and CMI, inhibits phagocytosis by macrophages and induces thymic aplasia (Robens et al. ,1992). It affects more severely the CMI and the complement system. Experimental data indicated that aflatoxin causes defective protein synthesis, atrophy of the bursa of Fabricius, lymphocytopaenia and depression of the complements (Campbell Jr ML et al 1983).

Mycotoxin induce immunosuppression in poultry may be express as decrease antibody production to antigens an impaired delayed hypersensivity response in bacterial *(Salmonella, Brucella, Listeria and Escherichia*), lymphocyte proliferation (response to mitogens) macrophages phagocytotic ability, an alterations in CD4/CD8/ratio, immune organweight (spleen, thymus an bursa of Fabricius) an histologicalchanges (lymphocyte depletion, degeneration and necrosis).

5.Conclusions:

1. Thymic and bursa Fabricius intense histological modifications appeared at 3 weeks after experimentaly intoxication. Reticular cell hyperplasia is severe following lymphocyte necrosis.
2. Cells reticular, non-lymphoide, probably AFB1 induces reticuloendothelial hyperplasia.
3. Ultrastructuraly lymphocytes in the tymus and bursa Fabricius showed RER dilatation, cisternal irregularity and loss of ribosomes attached to the membrane surface.

Many lymphocytes showed apoptotic sign. The nucleus show changes from focal condensation of chromatin to partial lysis.

Aknowledgements

Researches finnanced from grant PN II IDEI 1118/2009 by National Council for Universitary Research (CNCSIS/ UEFISCSU)

References

1. Campbell Jr ML, May JD, Huff WE, Doerr JA (1983)- Evaluation of immunity of young broiler chickens during simultaneous aflatoxicosis and ochratoxicosis. Poult Sci 62: 2138-40
2. De Recondo, A. M., Frayssinet, C., Lafarge, C., Le Breton, E., (1966) Action de l'Aflatoxine sur le Metabolisme du DNA au Cours de l'Hypertrophie Compensatrice du Foie apres Hepatectomie Partielle. Biochim. Biophys. Acta, 119: 322-330,
3. Eguchi, Y., D.L. Ewert, Y. Tsujimoto (1992). Isolation and characterization of the chicken Bcl_2 gene: expression in a variety of tissues including lymphoid and neuronal organs in adult and embryo. Nucl. Acids Res., 20 (Suppl.16): 4187-4192.
4. Gallikeev, K.H.L., Raipov, O.R., Manyasheva, R.A. (1968) Effect onaflatoxin on dynamics of antibody formation (Tr). Biulleten' eksperimental noi biologii I meditsiny (USSR) 65, 88-90
5. Giambrone JJ, Ewert DL, Wyatt RD, Eidson CS. (1978) Effect of aflatoxins on the humoral and cell-mediated immune systems of the chickens. Am J Vet Res;39:305-8
6. R.C.Gupta (2007)- Veterinary toxicology: basic and clinical principles, Elseviers.
7. Jakhar KK and JR Sadana, (2004). Sequential pathology of experimental aflatoxicosis in quail and the effect of selenium supplementation in modifying the disease process. Mycopathologia, 157: 99-109
8. Kenzo Hiroshima, M.D., Akira Iyoda, M.D., Tetsuya Toyozaki, M.D., Yana Supriatna, M.D., Kiyoshi Shibuya, M.D., Fumihiko Shimamura, M.D., Yukiko Haga, M.D., Shigetoshi Yoshida, M.D., Takehiko Fujisawa, M.D., Hidemi Ohwada, M.D. (2002) Proliferative Activity and Apoptosis in Thymic Epithelial Neoplasms. Pathology, Inc. VOL. 15, NO. 12, P. 1326, Printed in the U.S.
9. Kubena, L.F., R.B. Harvey, W.E. Huff, D.E. Corrier, T.D. Phillips and G.E. Rottinghaus. (1990). Efficacy of a hydrated sodium calcium aluminosilicate to reduce the toxicity of aflatoxin and T-2 toxin. Poultry Sci. 69:1078-1086
10. B. Lawson, S. MacDonald, T. Howard, S.K. Macgregor, A.A. Cunningham (2006) Exposure of garden birds to aflatoxins in BritainScience of the Total Environment 361 124– 131
11. Michael, G. Y., J. P. Thaxton, and P. B. Hamilton, (1973). Impairment of the reticuloendothelial system of chickens during aflatoxicosis. Poult. Sci. 52:1206 - 1207.
12. H. Oguz, H.H. Hadimli, V. Kurtoglu and O. Erganis, (2003) Evaluation of humoral immunity of broilers during chronic aflatoxin (50 and 100 ppb) and clinoptilolite exposure, *Revue de Medicine Veterinaire* 154, pp. 483–486
13. Ortatatli M, H Oguz, F Hatipoglu and M Karaman, (2005). Evaluation of pathological changes in broilers duringchronic aflatoxin (50 and 100µg/Kg) and clinoptilolite exposure. Res Vet Sci, 78: 61-68.
14. J. Richard, J. R. Thurston, and A. C. Pier, (1978) "Effects of mycotoxins on immunity," in *Toxins: Animal, Plant and Microbial*, P. Rosenberg, Ed., pp. 801–817, Pergamon Press, New York, NY, USA,.
15. Richard, J.L. and Thurstn , J.R. (1975) – Effect of Aflatoxin on Phagocytosis of Aspergillus fumigatus Spores by Rabbit Alveolar macrophages, Appl Environ Microbiol. 1975 July; 30(1): 44-47
16. Robens J F and Richard J L (1992)- Aflatoxins in animal and human health. Revue of Environment Contamination and Toxicology 127: 69-94.

17. E. Sur and I. Celik, (2003). Effects of aflatoxin B_1 on the development of bursa of Fabricius and blood lymphocyte acid phosphatase of the chicken, *British Poultry Science* 44, pp. 558–566.
18. Thaxton, J. P., H. T. Tung, and P. B. Hamilton. (1974). Immunosuppression in chickens by aflatoxin. Poult. Sci. 53:721-725.
19. Ghanshyam Upadhyay**,** Anand Kumar Singh**,** Abhai Kumar**,** Om Prakash**,** Mahendra Pratap Singh (2008) Resveratrol modulates pyrogallol-induced changes in hepatic toxicity markers, xenobiotic metabolizing enzymes and oxidative stress European Journal of Pharmacology, Volume 596, Issues 1-3, 31, Pages 146-152
20. Verma J., Johri, T.S., Swain B.K &AmeenaS (2004). Effect of graded levels of aflatoxin, ochratoxin and their combination on the performance and immune response of broilers. British Poultry Science, 45, 512-518.
21. Williams et al., 2004: Williams JH, Phillips TD., Jolly PE, Stiles JK, Jolly CM, Aggarwal D. (2004) Human aflatoxicosis in developing countries: a review of toxicology, exposure, potential health consequences, and interventions. *Am J Clin Nutr.*; 80(5): 1106 - 1122.
22. L. P. Yarru, R. S. Settivari, E. Antoniou, D. R. Ledoux, G. E. Rottinghaus (2009)Toxicological and gene expression analysis of the impact of aflatoxin B_1 on hepatic function of male broiler chicks. Poult Sci. 88:360-371

BOVINE ADIPONECTIN: EXPRESSION AND REGULATION IN DIFFERENTIATED BOVINE ADIPOCYTES

Mohamed Mohamed Soliman[1,2], Tamer Ahmed Ismaeil[1,3], Hossam Fouad Attia[1,4], Omayma Ahmed Ragab[2]

Medical Laboratories Department[1], College of Applied Medical Sciences, Turabah, Taif University, Saudi Arabia.
Departments of Biochemistry[2] and Histology[4], Faculty of Veterinary Medicine, Benha University, Moshtohor, P.O. 13736 Egypt.
Departments of Physiology[3], Faculty of Veterinary Medicine, Zagazig University, Egypt.

*Correspondence to: Mohamed Mohamed Soliman, Department of Biochemistry, Faculty of Veterinary Medicine, Benha University, Moshtohor, P.O. 13736 Egypt.
Phone: 00966561839933 (Saudi Arabia) and 002012-3722404 (Egypt).
E-mail: mohamedsoliman8896@yahoo.com

ABSTRACT

Adiponectin is an adipocytokine produced mainly from adipose tissue and expressed in various tissues with multifunctional effects. Little is known about adiponectin expression and regulation in cattle and that is the purpose of this study. Using northern blot analysis analysis, adiponectin expression was confirmed in mature differentiated bovine adipocytes but not in stromal vascular cells. When differentiated mature cells incubated with short chain fatty acids (SCFA), (Acetate, Butyrate and Propionate) in a dose of 1mM for 48 hr, adiponectin expression was significantly increased. Medium and long chain fatty acids (MCFA & LCFA respectively) decreased adiponectin expression. Co-treatment of LCFA with acetate inhibited acetate induced adiponectin expression. The down-regulation of LCFA is PPAR–γ dependent pathway. Moreover, insulin, dexamethasone, noradrenaline, tri-iodothyronin (T3), and tumor necrosis factor-α (TNF-α) significantly down-regulated adiponectin expression. Estrogen has no effect but troglitazone upregulated adiponectin expression in bovine adipocytes. The results clearly show that adiponectin is an adipokine secreted from bovine mature adipocytes to act in response to nutritional factors and host defensive response of cattle.

Key words: Adipocytes, bovine adiponectin, expression, regulation

INTRODUCTION

White adipose tissue (WAT) is an endocrine organ producing numerous proteins with broad biological activity as well as a relatively passive site of energy storage. This energy is accumulated in the form of triglycerides during periods of excess food consumption and mobilized when calorie intake is inadequate. The secretory products of WAT, collectively known as ‘adipocytokines’, include leptin, adiponectin (insulin sensitizing protein), tumor necrosis factor-α (TNF-α), interleukin 6 (IL-6) and many other proteins. The adipokines play an important autocrine

role in WAT physiology and are involved in obesity-associated complications, such as insulin resistance, endothelial dysfunction, arterial hypertension and atherosclerosis (Trayhurn *et al.*, 2001). Adiponectin is a member of the soluble defense collagen superfamily, and its plasma concentrations and mRNA expression have been shown to be decreased in murine and human obesity and insulin resistance (Brun *et al.*, 2003; Tataranni, 2001). Fruebis *et al.*, (2001) showed that a proteolytic cleavage product of adiponectin increased fatty acid oxidation in muscle and caused weight loss in mice. It stimulates fatty acids oxidation, decreases plasma triglycerides, and improves glucose metabolism by increasing insulin sensitivity in adipose tissue (Combs *et al.*, 2004), skeletal muscle and liver (Yamauchi *et al.*, 2001 & 2003). Obesity is associated with an increased risk of coronary heart disease, stroke, hypertension, T2D, dyslipidemia and all cause mortality (Stevens *et al.*, 1998; Weyer *et al.*, 2001). Adiponectin actions are mediated by its cloned adiponectin receptors known as AdipoR1 and AdipoR2 which expressed in various cells (Yamauchi *et al.*, 2003).

Adiponectin enters the brain and regulates energy expenditure through central mechanisms (Qi *et al.*, 2004). Adiponectin inhibits the inflammatory process and possibly atherogenesis by suppressing the migration of monocytes/macrophages and their transformation into foam cells. In adipocytes and adipose tissue, adiponectin may act as local regulator of inflammation via its regulation of the NF - kB and PPAR-γ2 transcription factors (Ajuwon and Spurlock, 2005).

Fatty acids may play a number of key roles in metabolism as a major metabolic fuel (storage and transport of energy), and as ligands for transcription factors (Rustan and Drevon, 2000). In addition, dietary lipids provide polyunsaturated fatty acids that are precursors of powerful locally acting metabolites, like eicosanoids and acyl CoA that may interact with nuclear receptor proteins and bind to certain regulatory regions of DNA and thereby alter transcription of the target genes (Rustan and Drevon, 2000).

As well known, cattle depend mainly on the production of short chain fatty acids (SCFA), known as volatile fatty acids by the act of bacterial fermentation in the rumen as principle energy source. Therefore, to establish the role of fatty acids in the regulation of adiponectin expression in bovine adipocytes, we examined the direct effect of various chain fatty acids on adiponectin expression in differentiated bovine adipocytes and also the effect of some regulators such as insulin, TNF-α and PPAR-γ to out line adiponectin regulation in such species.

MATERIALS AND METHODS

Materials

Dulbecco's modified Eagles's medium (DMEM, DMEM/F12, and DMEM without glucose), Hank's balanced salt solution, bovine serum albumin (BSA), bovine insulin, isobutylmethylxanthine (IBMX), various chain fatty acids (sodium form) and all regulators written in fig.6 were bought from Sigma–Aldrich Fine Chemical (St. Louis, MO, USA). Collagenase, dexamethasone, and troglitazone were purchased from Wako Pure Chemicals Co. (Osaka, Japan), Fetal calf serum (FCS) was from Trace Scientific Ltd. (Melbourne, Australia). Pertussis toxin (PTX) was from List Biological Laboratories (Campell, CA, USA).

Isolation of stromal vascular cells from bovine subcutaneous adipose tissue

Subcutaneous adipose tissue was obtained from five non-pregnant, non-lactating Holstein cows (2–3 years old) and dissected into small pieces in Hank's balanced salt solution containing 2mg/ml collagenase and 0.1% BSA in sterile 50ml plastic tube. Following digestion at 37 °C for 90 min with gentle shaking, the solution was filtered through sterile nylon mesh with 80 μm pores. The filtrate

was centrifuged at 1000×g for 5min at room temperature. The collected cells mainly consisting of stromal vascular cells were treated with an erythrocyte lysis buffer (154mM NH4Cl, 10mM KHCO3, and 1mM
EDTA) for 5min and washed twice with DMEM containing 10%FCS, 100U/ml penicillin, and 100μg/ml streptomycin. The cells were cultured in DMEM (2.5mM glucose) containing 10%FCS on collagen-coated dishes and media were changed every 2 days. The cells between third and fifth passages were used for experiments.

Differentiation of stromal vascular cells to adipocytes and treatments with various fatty acids and various regulators

When stromal vascular cells reached confluency (referred to day 0), the cells were further cultured in DMEM/F12 (17.5mM glucose) containing 1.5% FCS, 0.5mM IBMX, 1μM dexamethasone, and 10μg/ml insulin for 2 days, and subsequently in fresh DMEM/F12 containing 1.5%FCS, 10μM troglitazone, and 10μg/ml insulin every 2 days for 16 days to achieve cell differentiation to adipocytes. At day 16, the cells were cultured in DMEM with 2.5mM glucose containing 0.1%BSA (control) in the absence or presence of increasing concentrations of acetate, butyrate, propionate, caprylate, stearate, and linoleate. In some experiments, cells were treated with either 100 ng/ml PTX for 2 h, before the addition of acetate, stearate and linoleate. In other series of experiments, cells were treated with various doses of regulators (Fig.6) and incubated for 48 hrs then RNA was extracted for northern blot analysis.

Northern blot analysis

Reverse transcription mix was amplified for adiponectin and G3PDH as followings: for adiponectin, forward primer was 5'-GCCGCTTATGTGTATCGCTCAG-3', and reverse primer was 5;-TGCATAGACCCCATTGTGATTT-3' to amplify a 360-bp fragment to be used as a probe for adiponectin mRNA. For PPAR-γ forward primer: 5'-CGCACTGGAATTAGATGACAGC-3' and for Reverse primer: 5' -CACAATCTGTCTGAGGTCTGTC-3' to amplify a 214-bp fragment to be used as a probe for PPAR-γ mRNA. For G3PDH, Forward primer: 5'-ACCACTGTCCACGCCATCAC-3' Reverse primer: 5'-TCCACCACCCTGTTTGCTGTA-3' to amplify 453-bp product that used as a probe. The mRNA of adiponectin, PPAR-γ and G3PDH were amplified from total RNA of bovine subcutaneous adipose tissue by RT-PCR and sub-cloned into pGEM®-T Easy vector (Promega; Madison, WI, USA). The nucleotide sequence of each cDNA was confirmed and the cDNAs were used as probes for Northern bolt. Total RNA (20μg) was resolved on 1% agarose-formaldehyde gel, transferred onto a nylon membrane (Hybond-N+; Amersham Pharmaceutical Biotec., Buckinghamshire, UK) and cross-linked under UV light for 2 min. Both prehybridization and hybridization were performed at 65 °C for 2 h and overnight, respectively, in a buffer containing 7% SDS, 0.5 M Church's phosphate buffer, pH 7.2, 1 mM EDTA, and 0.5 mg/ml salmon sperm DNA. After prehybridization, the membrane was sequentially hybridized with a cDNA probe encoding bovine adiponectin and G3PDH as internal control for loading. The probe was labeled with [α-^{32}P] dCTP using Megaprime™ DNA labeling systems (Amersham) according to the instructions provided. After hybridization, the membrane was stringently washed for 20 min twice with 2× SSC and 0.1% SDS, and once with 0.1× SSC and 0.1% SDS at 65 °C before exposure onto a phospho-imaging plate overnight. Detection and quantification of the hybridization signals were carried out using a phospho-image analyzer (BAS 2500, FUJIFILM, Tokyo, Japan). After detection the membranes were re-probed hyperdized for G3PDH signaling.

Statistical analysis

Results are expressed as means ± S.E. of independent experiments. Statistical analysis was done using ANOVA and Fischer's post hoc test, with $p < 0.05$ being considered as statistically significant.

RESULTS

To test the effect of nutritional factors on adiponectin expression, immature preadpocytes were differentiated into mature cells. In short, bovine preadipocytes were grown in collagen coated dishes and after confluence subjected to differentiation using DMEM media containing insulin, dexamethasone and troglitazone for 16 days. As seen in fig.1. Cells started to accumulate lipids at day 8 and increased at day 16 and became more round. Next to confirm adiponectin expression in mature adipocytes, RNA was extracted at different days of cell differentiation and northern blot analysis was performed. Adiponectin was not expressed in immature adipocytes and started to express at day 9 and increased with time. Adiponectin expression showed 3 transcripts with 2.5, 1.8 and 1.3 Kb.

To test the effect of short and medium chain fatty acids on adiponectin expression in bovine adipocytes, cells were incubated with various doses of SCFA within physiological concentrations. Fig.2 shows that volatile short chain fatty acids at dose 1 mM induced significant ($p< 0.05$) increase in adiponectin expression. Unlike SCFA, octanoate dose dependently inhibited adiponectin expression. Those findings pushed us to test the effect of SCFA alone or in combination with LCFA (Stearate and linoleate) for 48 h on adiponectin expression. Incubation of cell with SCFA for 48 h (Fig.3) induced clear stimulatory expression on adiponectin mRNA but that effect was abolished in presence of LCFA. Because stearate and linoleate inhibited acetate induced adiponectin expression, we examined the possible signaling pathway that might be involved in adiponectin expression. Fig.4A shows that pretreatment of cells with pertusis toxin (PTX), G-protein coupled receptors antagonist, for 2 h then acetate for 48 h inhibited acetate induced adiponectin expression. Unlike SCFA effect, LCFA inhibited adiponectin expression through PTX independent pathway (Fig.4 B). Those results confirmed that acetate stimulated adiponectin expression through the G- protein coupled receptors and the inhibitory effect of LCFA is independent of that signaling pathway.

To confirm the signaling pathway used by LCFA to inhibit adiponectin expression, we tested peroxisome proliferator activated receptor gamma (PPAR-γ) expression after stimulation of cells by acetate alone or together with stearate and linoleate. As seen in fig.5, acetate did not affect PPAR-γ expression but addition of stearate and / or linoleate up-regulated expression of PPAR-γ as a transcriptional factor.

Finally, we tested the effect of different regulators on bovine adiponectin expression**.** As seen in fig. 6, insulin, dexamethasone, nor epinephrine, T3 and TNF-α down-regulated adiponectin expression in bovine adipocytes while troglitazone significantly up-regulated adiponectin expression. The overall response of adiponectin expression seemed to be dose dependent.

DISCUSSION

These results are the first to show that effect of various chain fatty acids on adiponectin expression. Fatty acids may play a number of key roles in metabolism as a major metabolic and as ligands for transcription factors (Rustan and Drevon, 2000). Moreover, dietary lipids provide polyunsaturated fatty acids that are precursors of powerful locally acting metabolites, like the eicosanoids. These fatty acids or their derivatives (acyl–CoA or eicosanoids) may interact with nuclear receptor proteins that bind to certain regulatory regions of DNA and thereby alter transcription of the target genes. The exact mechanism of adiponectin stimulation by volatile fatty

acids is not clear but one possible signaling is the involvement of G-protein coupled receptors. That postulation was confirmed by pre-treatment of cells by PTX for 2 h. Moreover, addition of LCFA inhibited adiponectin expression through G-protein coupled receptor independent pathway and the nuclear transcriptional factor PPAR-γ is involved in such regulation (Fig. 5). Adiponectin is well documented to reduce plasma concentration of fatty acids and triglycerides in mice models of obesity and hyperlipidemia (Yamauchi *et al.*, 2001). The effect is mediated by acceleration of fatty acid oxidation in muscle cells, which leads to decreased cellular triglyceride content (Fruebis *et al.*, 2001). In skeletal muscle, adiponectin increases expression of the proteins involved in fatty acid metabolism, such as acyl-CoA oxidase and uncoupling protein-2 (UCP-2) and increases body temperature, suggesting a stimulatory effect on energy expenditure (Fruebis *et al.*, 2001). Also adiponectin has no effect on adipose tissue hormone-sensitive lipase, indicating that reduction of plasma fatty acids results from accelerated tissue uptake rather than inhibition of lipolysis (Combs *et al.*, 2001; Fruebis *et al.*, 2001).

TNF-α is a cytokine produced by white adipose tissue and markedly up-regulated in obesity and contributes to insulin resistance by interfering with insulin receptor signaling (Hotamisligil and Spiegelman 1994). This cytokine suppresses adiponectin expression in WAT (Maeda *et al.*, 2001; Kappes and Loffler, 2000), whereas thiazolidinediones prevent this inhibitory effect of TNF-α (Maeda *et al.*, 2001; Moore et al., 2001). Thus, insulin resistance induced by TNF-α may be partially explained by the inhibition of adiponectin secretion, and reversal of the effect of TNF-α by thiazolidinediones may contribute to the insulin-sensitizing action of these drugs (Goldstein, 1999). There is an inverse association between TNF and adiponectin expression in vitro, so effects of TNF may be mediated partly by an autocrine or paracrine inhibition of adiponectin, because both adiponectin and TNF are produced and released from adipose tissue (Fasshauer *et al.*, 2002). Moreover, TNF-α is increased with adiposity and insulin sensitivity and is of importance as a marker of general activation of the cytokine system through activation of NF-kB (Brand *et al.*, 1996). Thus the results could suggest that TNF-α production by adipocytes may directly inhibit the local production of adiponectin and the inverse relationship between plasma adiponectin and cytokines suggests that endogenous cytokines may inhibit adiponectin. This could be of importance for the association between cytokines (as IL-6), insulin resistance and atherosclerosis. Therefore, adiponectin may be a local regulator for inflammation in the adipocytes and adipose tissue via its regulation of TNF, NF-kB and PPAR-γ2 transcriptional factors expression (Ajuwon and Spurlock, 2005; Yamauchi *et al.*, 2001).

FIGURE LEGENDS

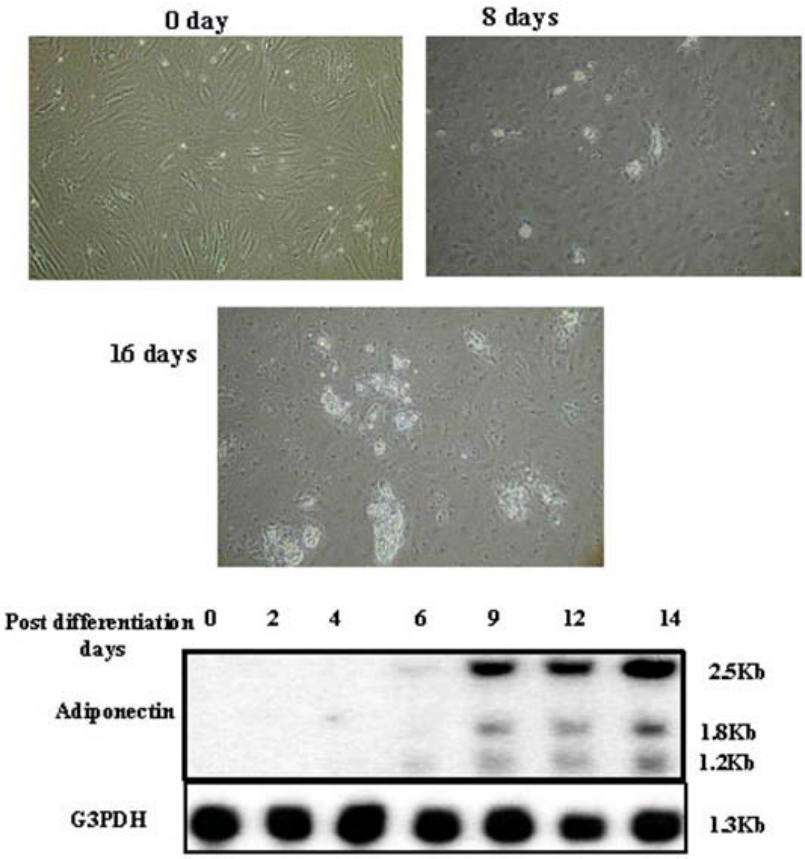

Fig.1. Time dependent increase in lipids accumulation (A) and adiponectin expression (B) in mature differentiated adipocytes. A), Electron microscope photo shows an increase in lipids inside cells and became more round at day 16. B); Northern blot analysis show time dependent increase in adiponectin mRNA expression which is increased with cell maturation.

Glucocorticoids have been demonstrated to cause insulin resistance in vivo (Andrews and Walker, 1999) and negatively regulated adiponectin expression (Halleux *et al.,* 2001). Here, dexamethasone potentially inhibited adiponectin gene expression. These findings indicate that adiponectin down-regulation may be one mechanism by which glucocorticoids impair insulin sensitivity and more studies are needed to outline this relation (Fasshauer *et al.,* 2002). The effect of T3 on adiponectin expression is not clear and with tendency to decrease adiponectin mRNA expression. The same was found in study of Cabanelas *et al.,* (2010) in separated WAT from subcutaneous adipose tissue without unclear explanation. Further studies are needed to examine the effect of thuroid hormones and adiponectin expression. Estrogen is the female sex hormone that regulates reproductive function and increased with the degree of adiposity in mammals. Adiponectin is not affected by sex steroids as shown by Horenburg *et al.,* (2008), although adiponectin expression is higher in females than males and that coincided with our findings.

In conclusion, the results showed that bovine adiponectin is expressed in differentiated adipocytes and acts as late differentiation marker. Moreover the regulation of adiponectin expression by various factors among which nutrients, cytokines confirmed its multifunctional role in the body during health and/or disease. The mechanism of the inhibitory effect of LCFA on acetate induced adiponectin expression in bovine adipocytes is still obscure, but the induction of PPAR-γ expression may be involved.

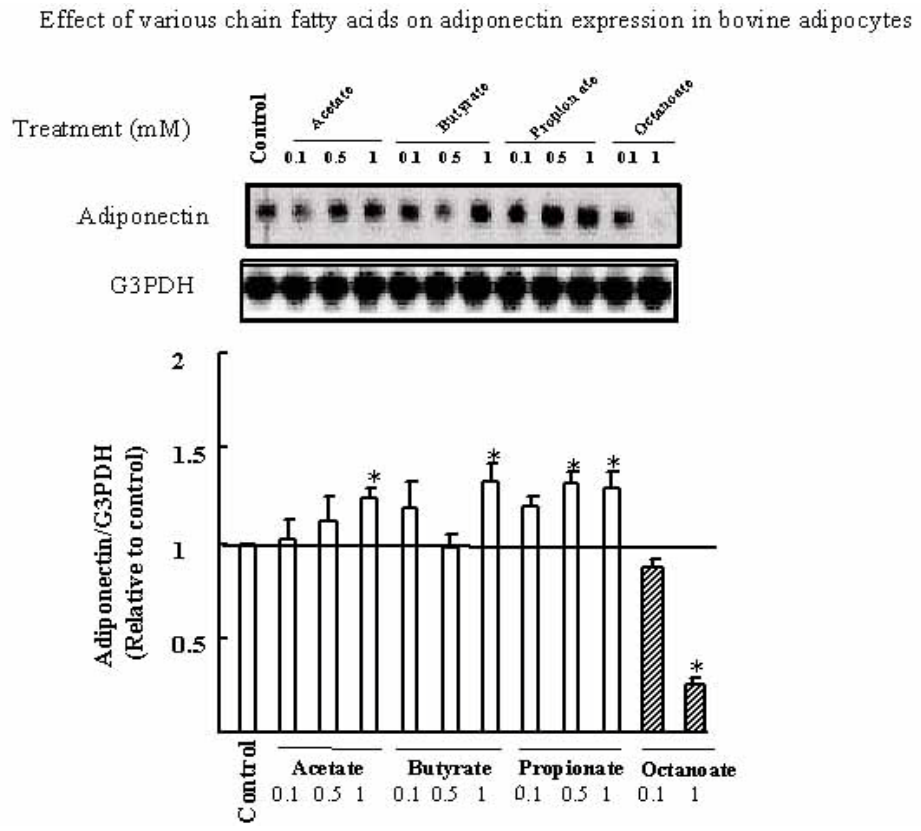

Fig.2. Effect of short and medium chain fatty acids on adiponectin mRNA expression. Differentiated mature adipocytes were incubated with acetate, butyrate, propionate and octanoate in various doses for 24 h. RNA (20 μg/lane) was extracted and subjected to northern blot analysis to detect expression of adiponectin and G3PDH genes. Representative blots and densitometric analyses of bands expressed relative to control are shown. Values are means ± S.E. of 4 independent experiments. *$p < 0.05$ vs. control.

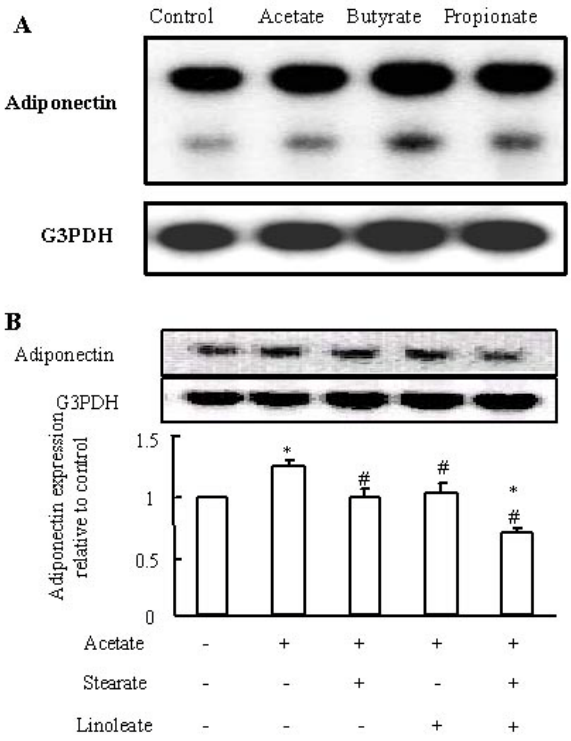

Fig.3. Effect of 1 mM acetate, butyrate, and propionate for 48 h on adiponectin mRNA expression (A) and effect of long chain fatty acids (0.3mM) on acetate induced adiponectin expreesion (B). Differentiated mature adipocytes were incubated with acetate, butyrate, propionate and octanoate in dose 1mM for 48 h. RNA (20 μg/lane) was extracted and subjected to northern blot analysis to detect expression of adiponectin and G3PDH genes. Representative blots and densitometric analyses of bands expressed relative to control are shown. Values are means ± S.E. of 3 independent experiments. *$p < 0.05$ vs. control.

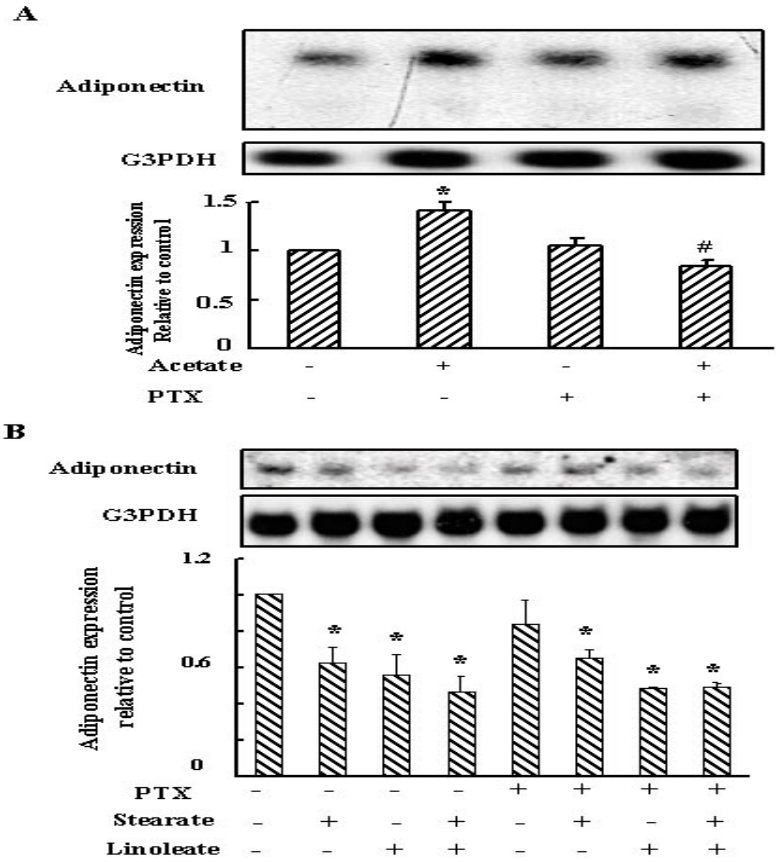

Fig.4. Effect of pertusis toxin on acetate induced (A) and LCFA inhibited (B) adiponectin expression. Differentiated mature adipocytes were pre-treated with PTX (100ng/ml) for 2 h then with acetate (1mM), stearate (0.3 mM) and linoleate (0.3 mM) alone or together for 48 h. RNA (20 μg/lane) was extracted and subjected to northern blot analysis to detect expression of adiponectin and G3PDH genes. Representative blots and densitometric analyses of bands expressed relative to control are shown. Values are means ± S.E. of 3 independent experiments. *$p < 0.05$ vs. control.

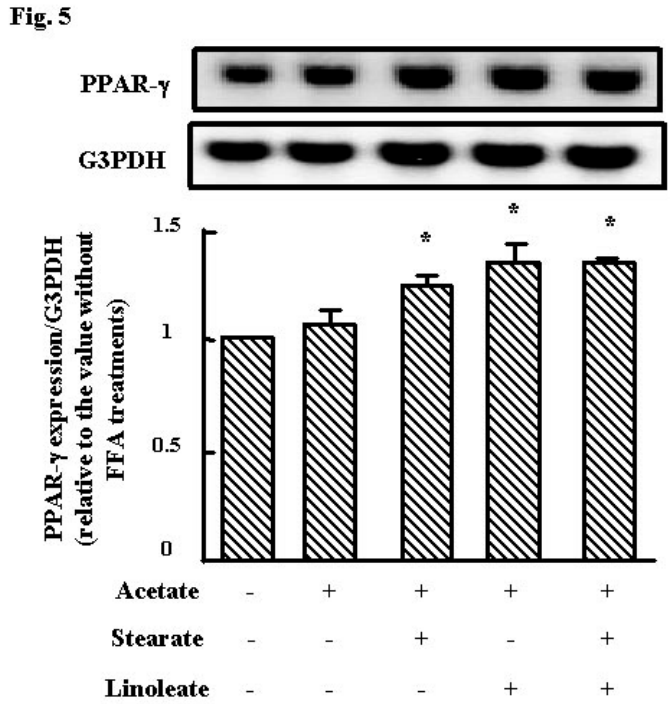

Fig. 5. Effect of acetate alone or together with LCFA on PPAR-γ expression in bovine adipocytes. Mature differentiated adipocytes were treated in the absence (-) or presence (+) of acetate (1mM) for 48 h. In some preparations, cells were treated with stearate and linoleate together with acetate for 48 h. Total RNA was extracted and Northern blot analysis (20μg/lane) was performed to detect expression of PPAR-γ and G3PDH genes. Representative blots and densitometric analyses of bands expressed relative to control are shown. Values are means ± S.E. of 3 independent experiments. *p < 0.05 vs. control and acetate alone.

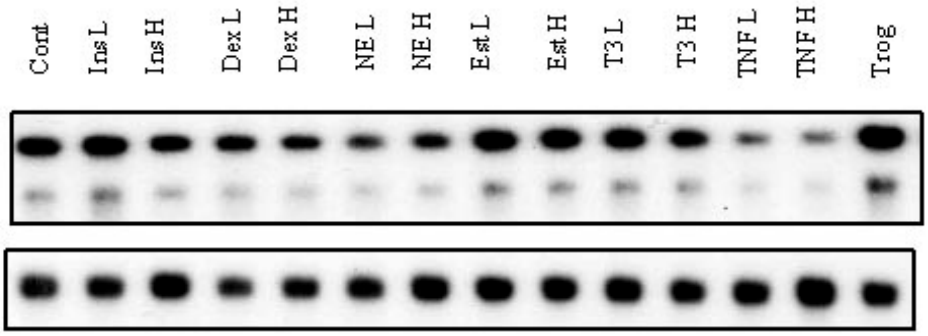

Fig. 6. Effect of various regulators on adiponectin mRNA expression in differentiated adipocytes. Mature differentiated adipocytes were treated for 48 h with written regulators in various doses. RNA (20μg/lane) was extracted and subjected to northern blot analysis. **Ins L&H:** Insulin low (1

nM) and high (100nM) respectively; **Dex L & H:** Dexamethasone (1 nM) and high 100nM respectively**; NE L & H:** Nor-epinephrine low (1 µM) and high (10 µM) respectively : **Est L&H:** estrogen (10 nM) and high (100nM) respectively; **T3 L & H:** tri-iodothyronine low (1 nM) and high (50 nM) respectively; **TNF L&H:** Tumor necrosis factor alpha low (10 ng/ml) and high (50ng/ml) and **Trog:** troglitazone (10µM).

REFERENCES

1. Ajuwon, M. K., Spurlock, M. E., 2005. Adiponectin inhibits LPS-induced NF-kB activation and IL-6 production and increases PPAR-γ2 expression in adipocytes. Am. J. Physiol. Regul. Integr. Comp. Physiol., 288, R1220-R1225.
2. Andrews, R. C., Walker, B. R., 1999. Glucocorticoids and insulin resistance: Old hormones, new targets. Clin. Sci. 96, 513–523.
3. Brand, K., Page, S., Rogler, G., Bartsch, A., Brandl, R., Knuechel, R., Page, M., Kaltschmidt, C., Baeuerle, P.A., Neumeier, D., 1996. Activated transcription factor nuclear factor-kappa B is present in the atherosclerotic lesion. J. Clin. Invest. 97, 1715–1722.
4. Brun, J.M., Lihn, A.S., Verdich, C., Pedersen, S.B., Toubro, S., Astrup, A., Richelsen, B., 2003. Regulation of adiponectin by adipose tissue-derived cytokines: in vivo and in vitro investigations in humans. Am. J. Physiol. Endocrinol. Metab. 285, E527–E533.
5. Cabanelas, A., Cordeiro, A., Santos Almeida, N.A., Monteiro de Paula, G.S., Coelho, V.M., Ortiga-Carvalho, T.M., Pazos-Moura, C. C., 2010. Effect of triiodothyronine on adiponectin expression and leptin release by white adipose tissue of normal rats. Horm. Metab. Res. 42,254-260.
6. Combs, T.P., Berg, A.H., Obici, S., Scherer, P.E., Rossetti, L., 2001. Endogenous glucose production is inhibited by the adipose-derived protein Acrp30. J. Clin. Invest. 108, 1875–1881.
7. Combs, T.P., Pajvani, U.B., Berg, A.H., Lin, Y., Jelicks, L.A., Laplante, M., Nawrocki, A.R., Rajala, M.W., Parlow, A.F., Cheeseboro. L., Ding, Y.Y., Russell, R.G., Lindemann, D., Hartley, A., Baker, G.R., Obici, S., Deshaies, Y., Ludgate, M., Rossetti, L., Scherer, P.E., 2004. A transgenic mouse with a deletion in the collagenous domain of adiponectin displays elevated circulating adiponectin and improved insulin sensitivity. Endocrinology 145, 367–383.
8. Fasshauer, M., Klein, J., Neumann, S., Eszlinger, M., Paschke, R., 2002. Hormonal Regulation of Adiponectin Gene Expression in 3T3-L1 Adipocytes. Biochem. Biophys. Res. Commun. 290, 1084–1089.
9. Fruebis, J., Tsao, T.S., Javorschi, S., Ebbets-Reed, D., Erickson, M.R.S., Yen, F.T., Bihain, B.E., Lodish, H.F., 2001. Proteolytic cleavage product of 30-kDa adipocyte complement-related protein increases fatty acid oxidation in muscle and causes weight loss in mice. Proc. Natl. Acad. Sci. USA. 98, 2005–2010.
10. Goldstein, B.J., 1999. Current views on the mechanism of action of thiazolidinedione insulin sensitizers. Diabetes Technol Ther 1, 267–275.
11. Halleux, C.M., Takahashi, M., Delporte, M.L., Detry, R., Funahashi, T., Matsuzawa, Y., Brichard, S.M., 2001. Secretion of adiponectin and regulation of apM1 gene expression in human visceral adipose tissue. Biochem. Biophys. Res. Commun. 288, 1102–1107.
12. Hotamisligil, G.S., Spiegelman, B.M., 1994. Tumor necrosis factor-alpha: a key component of the obesity-diabetes link. Diabetes 43, 1271-1278.

13. Horenburg, S., Fischer-Posovszky, P., Debatin, K.M., Wabitsch, M., 2008. Influence of sex hormones on adiponectin expression in human adipocytes. Horm. Metab. Res. 40, 779-786.
14. Kappes, A., Loffler, G., 2000. Influences of ionomycin, dibutyryl-cycloAMP and tumour necrosis factor-alpha on intracellular amount and secretion of apM1 in differentiating primary human preadipocytes. Horm. Metab. Res. 32, 548-554
15. Maeda, N., Takahashi, M., Funahashi, T., Kihara, S., Nishizawa, H., Kishida, K., Nagaretani, H., Matsuda, M., Komuro, R., Ouchi, N., Kuriyama, H., Hotta, K., Nakamura, T., Shimomura, I., Matsuzawa, Y., 2001. PPARγ ligands increase expression and plasma concentrations of adiponectin, an adipose-derived protein. Diabetes 50:2094–2099.
16. Moore, G.B., Chapman, H., Holder, J.C., Lister, C.A., Piercy, V., Smith, S.A., Clapham, J.C., 2001. Differential regulation of adipocytokine mRNAs by rosiglitazone in db/db mice. Biochem. Biophys. Res. Commun. 286, 735–741.
17. Qi, Y., Takahashi, N., Hileman, S.M., Patel, H.R., Berg, A.H., Pajvani, U.B., Scherer, P.E., Ahima, R.S., 2004. Adiponectin acts in the brain to decrease body weight. Nat. Med. 10, 524–529.
18. Rustan, A.C., Drevon, C.A., 2000. Fatty Acids: Structures and Properties. Encyclopedia of Life Sciences, Nature Publishing, London. http://www.els.net.
19. Stevens, J., Cai, J., Pamuk, E.R., Williamson, D.F., Thun, M.J., Wood, J.L., 1998. The effect of age on the association between body-mass index and mortality. N. Engl. J. Med. 338: 1–7.
20. Trayhurn, P., Beattie, J.H., 2001. Physiological role of adipose tissue: white adipose tissue as an endocrine and secretory organ. Proc. Nutr. Soc. 60, 329-339.
21. Weyer, C., Funahashi, T., Tanaka, S., Hotta, K., Matsuzawa, Y., Pratley, R. E., and Tataranni, P. A., 2001. Hypoadiponectinemia in obesity and type 2 diabetes: Close association with insulin resistance and hyperinsulinemia. J. Clin. Endocrinol.Metab. 86, 1930–1935.
22. Yamauchi, T., Kamon, J., Ito, Y., Tsuchida, A., Yokomizo, T., Kita, S., Sugiyama, T, Miyagishi, M., Hara, K., Tsunoda, M., Murakami, K., Ohteki, T., Uchida, S., Takekawa, S.,Waki, H., Tsuno, N.H., Shibata, Y., Terauchi, Y., Froguel. P., Tobe, K., Koyasu, S., Taira, K., Kitamura, T., Shimizu, T., Nagai, R., Kadowaki, T., 2003. Cloning of adiponectin receptors that mediate antidiabetic metabolic effects. Nature 423, 762–769.
23. Yamauchi, T., Kamon, J.,Waki, H., Terauchi, Y., Kubota, N., Hara, K., Mori, Y., Ide, T., Murakami, K., Tsuboyama-Kasaoka, N., Ezaki, O., Akanuma, Y., Gavrilova, O., Vinson, C., Reitman, M.L., Kagechika, H., Shudo, K., Yoda, M., Nakano, Y., Tobe, K., Nagai, R., Kimura, S., Tomita, M., Froguel, P., Kadowaki T., 2001. The fat-derived hormone adiponectin reverses insulin resistance associated with both lipoatrophy and obesity. Nat. Med. 7, 941–946.

EFFECT OF LACTOBACILLUS FERMENTED WHEAT BRAN ON RAT LIPID METABOLISM FED CHOLESTEROL ENRICHED DIET

LUCIA CARMEN TRINCA, MIRELA ADINA CAPRARIU

**University of Agricultural Sciences and Veterinary Medicine, M. Sadoveanu, Nr.3, Iaşi, 6600, Romania, email :lctrinca @yahoo.com*

The goal of the present work was the evaluation of the effect of Lactobacillus fermented wheat bran supplement in an experiment on rats to whom three different diets were given: standard diet to the M lot (control), atherogenic diet to the L_1 lot and Lactobacillus naturraly fermented wheat bran-supplemented atherogenic diet to the L_2 lot. Biochemical investigations of the seric cholesterol(Ch), HDL-cholesterol(HDL-Ch), free fatty acids(FFA), triacilglycerols(TG), phospholipids(PhL) and total lipids(TL) showed significantly increased values in subjects of the L_1 lot as compared to those of the L_2 lot and to those of the control. Thus, subjects of the L_1 lot showed significantly higher ($p<0,001$) seric levels of T-Ch, FFA, PhL, TG, and TL compared to the control (39,8%, 48,3 %, 9,6%, 57,3% and 62,6%) associated with a significantly lower of the antiatherogenic fraction, that is HDL-Ch (46,1 % lower as compared to the control). Subjects in the L_2 lot showed significantly higher ($p<0,001$) seric levels of Ch, FFA, PhL, TG and TL compared to the control (23,4%, 22,4 %, 5,9%, 39,8% and 42,9% respectively) associated with a somewhat smaller decrease (27,6 % lower as compared to M lot) of the antiatheromatous HDL-Ch fraction, though statistically significant ($p<0,01$).The experimental results proved that Lactobacillus fermented wheat bran supplement minimised the lipid metabolism unbalance during the atheromatous process in rats by hypolipidemic, hypocholesterolemic and hypotriacylglycerolemic effects.

Keywords: Lactobacillus fermented wheat bran, rats, lipid

INTRODUCTION

Atherosclerosis (ATS) is a metabolic disease of the whole body that develops on a predisposed genetic background which consists in local metabolic disturbances of the arterial wall (2). ATS is a complex, multifactorial disease that primarily affects large-and medium-size arteries (11)**.**

Epidemiological studies unanimously accept hypertension, smoking, diabetes and hypercholesterolemia as main modifyible risk factors (15).

Disturbances in seric lipid fraction levels cause homeostatic disturbances of the whole body that result in both general and local arterial metabolic changes(2,13).

The antiatheromatous effect of lactic fermented wheat bran has still remained an incompletely elucidated process (6), though the researches of the last ten years revealed some implications of *Lactobacillus fermented wheat bran* in protection against atherogenesis in both humans(1,3,4,6,7) and animals (8,9,10,14).

The goal of the present work was to experimentally induce atherogenesis in rats by diet manipulation and to evaluate the influence of the naturally *Lactobacillus fermented* wheat bran supplement to the atherogenic diet upon the blood lipidic picture of the experimental animals.

MATHERIALS AND METHODS

24 Wistar healthy rats were divided into three lots, to whom differentiated diets were given, as follows:

- **Standard diet**: balanced semisynthetic diet, containing 19% crude protein and 1% fats for the *control lot(M)*;
- **Atherogenic diet**: standard diet supplemented with 40% sunflower seed oil, 2% cholesterol for the L_1 *lot* ;
- **Silicon supplemented atherogenic diet**: standard diet supplemented with 40% sunflower seed oil, 2% cholesterol and 10% *Lactobacillus naturally fermented* wheat bran for the L_2 *lot* ;

During the eight-week experimental period, subjects in all lots were fed and watered *ad libitum*.

At the end of the experimental period subjects in all lots were painlessly slaughtered and blood samples were collected for the evaluation of the seric lipid picture: cholesterol (Ch), HDL-cholesterol (HDL-Ch), triacylglicerols (TG), free fatty acids (FFA), phospholipid (PhL) and total lipid(TL).

Quantitation of each lipid fraction was done by usual biochemical methods: the colorimetric method for TL and PhL (12) and standard diagnostic "UNITEST" method for Ch, HDL-Ch, TG and FFA.

Results were expressed as mean values (X) ± standard error deviation (SED) and were statistically processed by the "t" Student test.

RESULTS AND DISCUSIONS

Tab.1 shows the mean values of the lipid fractions in rats at the end of the eight-week experimental period of feeding on the *Lactobacillus fermented* wheat bran-supplemented atherogenic diet.

Table 1:

Mean values of lipidic fractions in rats fed on a supplemented atherogenic diet

Lotul	Ch (mg/100 ml)	HDL-Ch (mg/100 ml)	FFA (mEq/l)	PhL (mg/100 ml)	TG (mg/100 ml)	TL (mg/100 ml)
L1	102,560±6,99	22,792±0,52	0,436±0,007	105,760±4,42	162,248±6,61	448,280±12,44
L2	90,560±4,99	30,618±0,70	0,360±0,060	102,200±3,53	144,136±3,25	398,760±11,90
M	73,400±3,41	42,310±1,02	0,294±0,004	96,520±2,61	103,080±1,59	275,640±10,27
Statistical Significance	M/L_1: p<0,001	$M//L_1$:p<0,001	M/L_1: p<0,001	M/L_1: p<0,001	M/L_1: p<0,001	M/L_1:p<0,001
	M/L_2: p<0,001	$M//L_2$:p<0,001	M/L_2: p<0,001	M/L_2: p<0,01	M/L_2: p<0,001	M/L_2:p<0,01
	L_1/L_2:p<0,001	L_1/L_2:p<0,01	L_1/L_2: p>0,01	L_1/L_2: p>0,4	L_1/L_2: p<0,001	L_1/L_2: p<0,001

In general, the variation of seric concentration values was significant in both experimental lots (L_1 and L_2) as compared to the M lot, that confirmed the atherogenic effect of the diets fed to those lots. Thus, subjects of the L_1 lot showed significantly higher (p<0,001) seric levels of T-Ch, FFA, PhL, TG, and TL compared to the control (39,8%, 48,3 %, 9,6%, 57,3% and 62,6%) associated with a significantly lower of the antiatherogenic fraction, that is HDL-Ch (46,1 % lower as compared to the control). Subjects in the L_2 lot showed significantly higher (p<0,001) seric levels of Ch, FFA, PhL, TG and TL compared to the control (23,4%, 22,4 %, 5,9%, 39,8% and 42,9%) associated with a somewhat smaller decrease (27,6 % lower as compared to M lot) of the antiatheromatous HDL-Ch fraction, though statistically significant (p<0,01).The seric concentration values of FFA and PhL showed in tab. 1 indicated the parallelism in variation of the two experimental lots, that suggested that the atherogenic diet fed on rats caused significant irreversible disturbances of the aforementioned lipid fractions, that, in turn, triggered other metabolic disturbances associated with the atherogenic process.

Analysis of the lipid fractions variation in the two experimental lots indicated significant increases in the seric concentration values of Ch, TG and TL associated with the decrease of the antiatherogenous HDL-Ch fraction in the L_1 lot, fed on the atherogenic diet, as compared to L_2 lot whose subjects were given *Lactobacillus naturally fermented* wheat bran supplemented atherogenic diet.

Hypocholesterolemic potential of fermented cereals was notice by other in vivo evidence. In a randomized, placebo-controlled study, Wang *et al.* found that ten male hypercholesterolemic Wistar rats (7-week-old; mean body weight of 210 ± 20 g) fed with a starch from Chinese yam (*Dioscorea opposita*) for eight weeks showed a significantly lower plasma total cholesterol, LDL-cholesterol and triglyceride ($P < 0.05$) than the control (32,8%, 27,5% and 46,2% lower, respectively). Favier *et al* evaluated the hypocholesterolemic effects of β- cyclodextrin in a randomized, placebo-controlled and parallel design trial involving ten male Wistar rats (mean body weight of 150 g). In this 21-day trial, the authors found that daily consumption of 25 g/kg of β-cyclodextrin significantly ($P < 0,05$) reduced plasma cholesterol and triacylglycerols by25,9% and 35,0%, respectively, compared to the control group.

The experimental results confirm previous reports (5,10,14) that the protective antiatheromatous effect of the *Lactobacillus fermented* wheat bran supplement to the atherogenic diet minimisie the lipid unbalance in rats, proved by a definite hypolipidemic effect, in general, and a hypocholesterolemic and hypotrigliceridemic effect, in particular.

CONCLUSIONS

1. The administration of the atherogenic diet to rats in the L_1 lot caused significant increase of the lipidic fractions implicated in atherogenesis: Ch, FFA, PhL, TG and TL.
2. The atherogenic diet, *per se* or supplemented with *Lactobacillus naturally fermented* wheat bran, caused significant decrease of the antiatherogenic HDL-Ch fraction levels in both experimental L_1 and L_2 lots.
3. The experimental data of the present work suggest that the dietary Lactobacillus naturally fermented wheat bran supplemented to the atherogenic diet minimised the lipidic metabolism disturbances during the atherogenic process.

BIBLIOGRAPHY

1. Brighenti, F.; Casiraghi, M.C.; Canzi, E.; Ferrari, A., **1999,** Effect of Consumption of a Ready-to-Eat Breakfast Cereal Containing Inulin on the Intestinal Milieu and Blood Lipids in Healthy Male Volunteers. *Eur. J. Clin. Nutr*, *53*, 726-733
2. Buers I,Hofnagel O,Ruebel A,Severs NJ,Robenek H, **2011**,Lipid droplet associated proteins: an emerging role in atherogenesis, *Histol Histopathol*, 26/5, :631-42
3. Causey, J.L.; Feirtag, J.M.; Gallaher, D.D.,**2000** Effects of Dietary Inulin on Serum Lipids, Blood Glucose and Gastrointestinal Environment in Hypercholesterolemic Men. *Nutr. Res*., *20*, 191-201
4. Favier, M.-L.; Moundras, C.; Demigné, C.; Rémésy, C.,**1995**, Fermentable Carbohydrates Exert a More Potent Cholesterol-Lowering Effect than Cholestyramine. *Biochim. Biophys. Acta 1258*, 15-121
5. Gallaher, C.M.; Munion, J.; Hesslink, R.; Wise, J.; Gallaher, D.D.,**2000** Cholesterol Reduction by Glucomannan and Chitosan is Mediated by Changes in Cholesterol Absorption and Bile Acid and Fat Excretion Iin Rats. *J. Nutr*. *130*, 2753-2759
6. Lay-Gaik Ooi and Min-Tze Liong, **2011**, Cholesterol-Lowering Effects of Probiotics and Prebiotics: A Review of *in Vivo* and *in Vitro* Findings *Int. J. Mol. Sci.* 2010, *11*, 2499-2522;,
7. Letexier, D.; Diraison, F.; Beylot, M., **2003** Addition of Inulin to a Moderately High-Carbohydrate Diet Reduces Hepatic Lipogenesis and Plasma Triacylglycerol Concentrations in Humans. *Am. J. Clin. Nutr.* **2003**, *77*, 559-564.
8. Madsen, C.S.; Janovitz, E.; Zhang, R.; Nguyen-Tran, V.; Ryan, C.S.; Yin, X.-H.; Stein, P.D. , **2007**, The Guinea Pig as a Preclinical Model for Demonstrating the Efficacy and Safety of Statins. *J. Pharmacol. Exp. Ther.* 2007, *324*, 576-586,
9. Patterson, J.K.; Lei, X.G.; Miller, D.D. The Pig as an Experimental Model for Elucidating the Mechanisms Governing Dietary Influence on Mineral Absorption. *Exp. Biol. Med.* 2008, *233*, 651-664.
10. Shinnick, F.L.; Longacre, M.J.; Ink, S.L.; Maelett, J.A., **1988**, Oat Fiber: Composition *Versus* Physiological Function in Rats. *J. Nutr*, *118*, 144-151
11. Tikhonov DG,Nikolaev VP,Sedalishchev VI, **2011,** Some problems of pathogenesis and clinical symptoms of atherosclerosis, Ter Arkh, 83(1): 63-9.
12. Trinca L., Ivas E, Cura Fl., **2003**, Tehnici de laborator in biochimia animala, Ed. Pim, 49-60.
13. Vinik AI.,**2005**, The metabolic basis of atherogenic dyslipidemia., Clin Cornerstone;7(2-3):27-35.
14. Wang, S.J.; Yu, J.L.; Liu, H.Y.; Chen, W.P. **2008**, Characterisation and Preliminary Lipid-Lowering valuation of Starch from Chinese Yam. *Food Chem*., *108*, 176-181.
15. WHO. **2003***, Diet, Nutrition and Prevention of Chronic Diseases*; Report of a Joint WHO/FAO ExpertConsultation, Geneva, Switzerland.

HISTOLOGICAL AND HISTOCHEMICAL STUDY ON THE OVARY OF THE NILE TILAPIA (*OREOCHROMIS NILOTICUS*) IN REFERENCE TO THE AGE

[1]EL-Zoghby, I .M.A.; [2]Mohammed, R. B. Y; [3]Shaheen, A.A.A and [4]Abdelfattah, N.
[1]Histology & Cytology ; [3]Fish Management &Diseases Dept. Vet. Med. Benha Uni., Egypt.
[2]Histology & Cytology Bahr Al Gazal Uni., Sudan.
[4]Basic Medical Sci., Dept., Vet. Med. Purdue Uni., U.S.A
[1]*Corresponding author:* Histology & Cytology Department
Faculty of Veterinary Medicine, Benha University, Egypt
E-mail: ihabyara@yahoo.com, ehab.alzaghaby@fvtm.bu.edu.eg

Abstract:
Histological studies of Gonads morphology have focused on a restricted set of commercial or recreational fish species such as salmonid, tilapia and carp. Various phases of gonadal development of fishes have been studied to clarify the dynamics and regulation of oogenesis. This paper deal with the histological and histochemical aspects of the ovarian development in the Oreochromis niloticus. Nile tilapia is the main fish of the genus tilapia (family: Cichlidae) that is native to Africa. Recently Nile tilapia (Oreochromis niloticus) has been widely distributed and acquired great importance in aquaculture a process which is largely dependent on the reproductive performance of the fish. A total number of 96 fish were used in this study. The fish age were ranged from one to seven months. The fish were reared normally at the department of Fish Management and Diseases at the Faculty of Veterinary Medicine of Benha University during the period from May to December. The ovaries of Nile tilapia were located at the posterior-dorsal part of the celomic cavity, ventral to the kidneys and the swim bladder, to which it was attached by the mesovary originating from the peritoneum. The mesovary is covered with a thin capsule of fibrous connective tissue, the tunica albuginea, which internally separates the ovigerous lamella. The microscopic analyses revealed five stages of ovarian development involving five phases. These were phases I (chromatin nucleolus stage) and II (perinucleolar stage), phases III (cortical alveoli) (corresponding to the immature stage of development) and IV (vitellogenic) (corresponding to the maturing stage), and phase V (ripe stage) (corresponding to the mature stage), and the partially spent stage with some empty follicles, mature oocytes in re-absorption, and large numbers of immature and maturing oocytes. The ovaries of the mature females showed all the different phases of oocyte development, indicating the multiple spawning habit of this species.

Introduction:

Nile tilapia (*Oreochromis niloticus*) has been widely distributed and acquired great importance in aquaculture (**Young and Muir, 2002**). In the tropics, tilapia fingerlings become sexually mature at about 4-5 months of age (**Angienda, Aketch and Waindi, 2010**).

The ovarian histological pattern of teleosts was described according to the division of ovarian tissues into seven or eight stages of maturity based upon the dominant gametogenic cell type present (**Crim and Glebe, 1990**). Ovarian tissue of Nile tilapia consisted of various stages of oocyte development including the small size, chromatin

nucleolar oocyte and perinucleolar oocyte; the medium size, cortical alveolar oocyte and vitellogenic oocyte with yolk granules incorporation; the large size, ripe oocyte which indicates maturation and imminent spawning. (**Hussain, Penman and Mc Andrew, 1996; Srijunngam and Wattanasirmkit, 2001**). **El-Sayed and Moharram (2007)** described the vitellogenic follicles as containing yolk granules (protein yolk) and large vacuoles (fatty yolk). In The ovaries of Nile tilapia the, fish that reached the age of 5 months were found to contain all of these oocytes in different stages (**Srijunngam, and Wattanasirmkit, 2001**). Few data are available about gametogenesis in Oreochromis niloticus (**Alves et. al., 1983; Nakamura et. al., 1993; Francolini et. al., 2003**); hence the aim of the present study on histology of the ovary of *O. niloticus* is to pertain basic information about the reproductive pattern of the fish which will be useful for further applications.

Material and methods:

A total number of 96 fish were used in this study. The fish age were ranged from one to seven months. The fish were reared normally at the department of Fish Management and Diseases at the Faculty of Veterinary Medicine of Benha University during the period from May to December 2010. At the two first month of age the whole larvae were processed for routine histological preparation each second day and from the third month onwards the ovaries were dissected and fixed in Bouin's fluid. After fixation, the specimens were dehydrated in ascending grades of ethanol, cleared in xylene, sectioned at a thickness of 5-7 µ, and picked up on clean slides. Tissue sections were stained with H&E stain for general histological observations. Crossmon's trichrome and Orcein stain were used for the differentiation between the tissue fibers. PAS method was used for the demonstration of the neutral polysaccharides (**Bancroft and Stevens, 1996**).

Results:

The ovary of one month old larvae was found to sandwiched between the kidney and the swim bladder dorsally and the stomach and the intestine ventrally. It was suspended in the abdominal cavity by the mesovarian which is attached to the peritoneum (Fig 1). The ovary was enclosed by a very thin capsule consisted of collagen fibers. From the capsule, thin trabecular ovigerous lamellae were extended to the lumen and containing the germinal epithelial cells. The germinal cells at this stage accommodated the oogonia and the chromatin nucleolar oocytes (Fig 2). The oogonia were small cells with light cytoplasm and very small nucleus, whereas the chromatin nucleolus oocytes were relatively larger with thin dense basophilic cytoplasm and larger pale nucleus that contained one or sometimes more than one nucleolus and fine chromatin meshwork. The chromatin nucleolar follicles were surrounded by single layer of flat follicular cells. With advancing age, the number of ovarian follicles gradually increased (Fig 3).

At 50 day of age there was a conspicuous increase in the fibrous components of the interstitium which was predominately collagenous at the expense of the cellular components (Fig 4). Elastic fibers were noted beneath the capsule and around the follicles (Fig 5). There was remarkable incensement in the ovarian size due to the ovarian follicles growth and oogonial proliferation. The oocytes at this stage reached the perinucleolar stage as had been evident by the peripheral arrangement of the nucleoli at the inner side of the nuclear membrane.

At the end of the third month of age, there were no marked variances in the ovarian structure except for progressive development of the ovarian follicles associated

with looseness of the interstial tissue and appearance of adipose cells. The cortical alveoli follicles were recognized. They were characterized by the presence of few small yolk vesicles at the peripheral zone of the follicles (Fig 6). With the continued development of the follicle the numbers and sizes of these vesicles were increased.

From the beginning of the four month of age onward, the ovary was tended to possess nearly all the developmental stages of the ovarian follicles (Fig 7). Oogonia were seen either singly distributed or in small cysts located mostly near the periphery of the ovarian lamellae. Chromatin nucleolar follicles were well defined. Perinucleolar follicles surrounded by squamous follicular cells were abundant. Cortical alveoli follicles were relatively large in size and bounded with a continuous layer of simple squamous follicular cells. At this stage the nucleus was started to convolute and their peripheral nuclei were still intact with the nuclear envelop (Fig 8).

Later in follicular development the cortical alveoli follicles developed a clear zona radiata (Fig 9) associated with an increase in the height of the follicular cells till it became columnar follicular cells. The theca cells were consisted of stratified squamous layer.

The vitellogenic stage were more numerous in this age and were characterized by the accumulation of yolk granules in the cytoplasm as eosinophilic infiltration started from out side to inside concomitant with decrease in the granular size more centrally. The nuclei were still recognizable and the nucleoli were very clear. The follicular wall was trilaminar consisting of deeply eosinophilic non-cellular zona radiata, columnar to cuboidal follicular cells and a stratified thecal layer (Figs 10 & 11).

By the end of the fourth month of age few ripe follicles were evident and their cytoplasm contained large yolk globules. Their follicular cells were consisted of low columnar or cuboidal follicular cells and a mono layered thecal cells. With the development of the vitellogenic follicles to ripe or mature follicles the yolk granules enlarged and aggregates in rosette shape filling the cytoplasm of the follicle. At the same time the yolk vesicle coalesced forming large cavities incorporating the cytoplasm (Fig 12). The ovarian capsule was remained thin during this period and the interstitial cells were numerous arranged either in short cords or in small groups.

At five month of age, the ovary size was relatively enlarged and it was found to contain numerous ripe follicles with dark eosinophilic yolk globules. The nuclei of the follicles were gradually disappeared although some of them were still remarkable. The interstitial tissue was predominately adipose tissue (Fig 13). The capsule was very thin and was firmly attached to the interstitium. With progressing development the amount of the adipose tissue and the extra-follicular deposition of the yolk granules were increased (Fig 14). The number of mature or ripe follicles also increased with noticeable enlargement of the yolk vesicles and fusion of them forming large intermingled cavities in the cytoplasm. The follicular wall of the ripe follicle showed decrease in height of the follicular cells being cuboidal or even low cuboidal and the number of the theca layer was reduced into single layer of flattened cells. The infiltration of the interstitial tissue with the yolk granules was progressively increased (Fig 15).

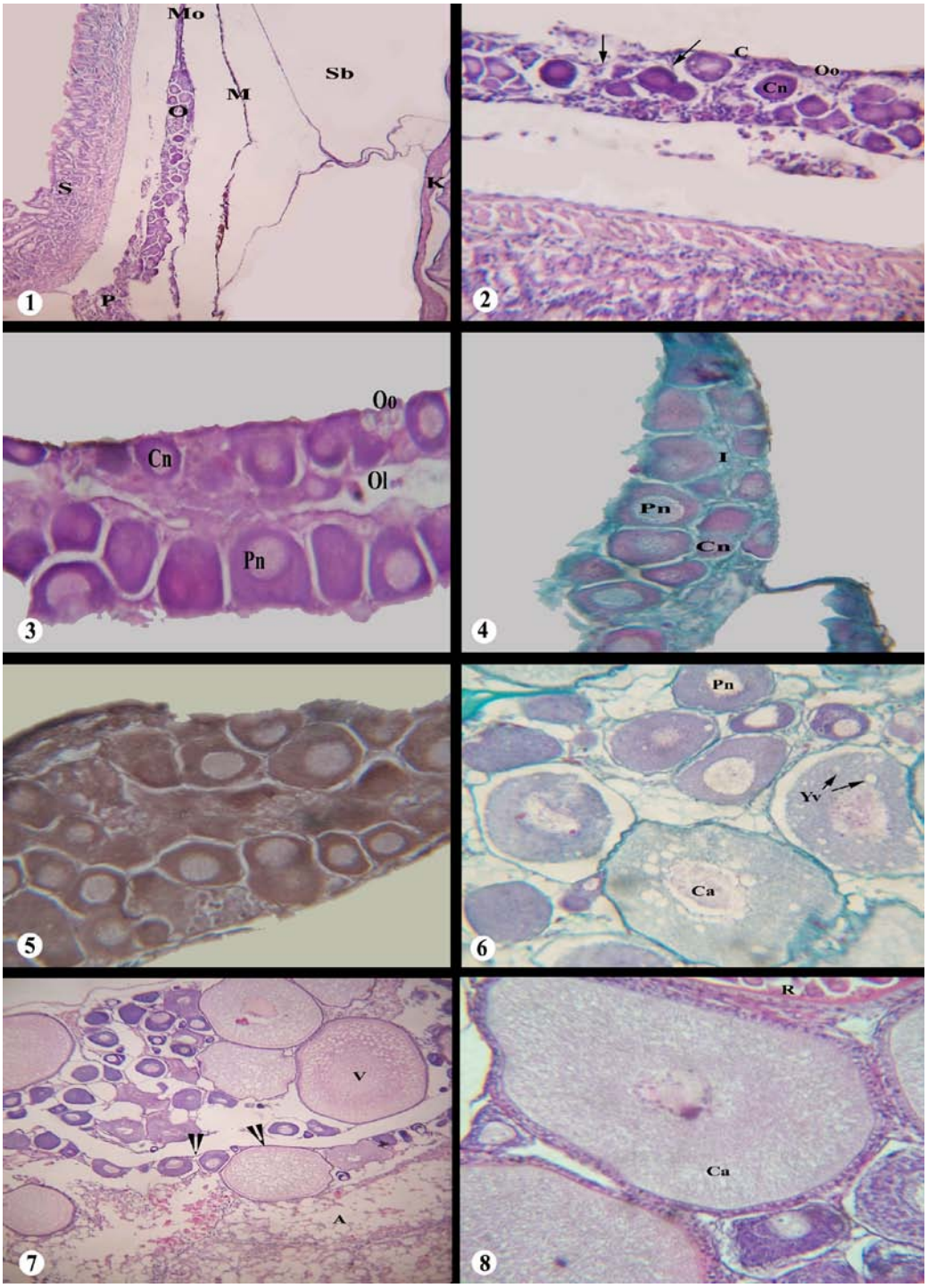
1
Mo
Sb
M
Q
S
K
P
2
C
Oo
Cn
3
Oo
Cn
Ol
Pn
4
I
Pn
Cn
5
6
Pn
Yv
Ca
7
V
A
8
R
Ca

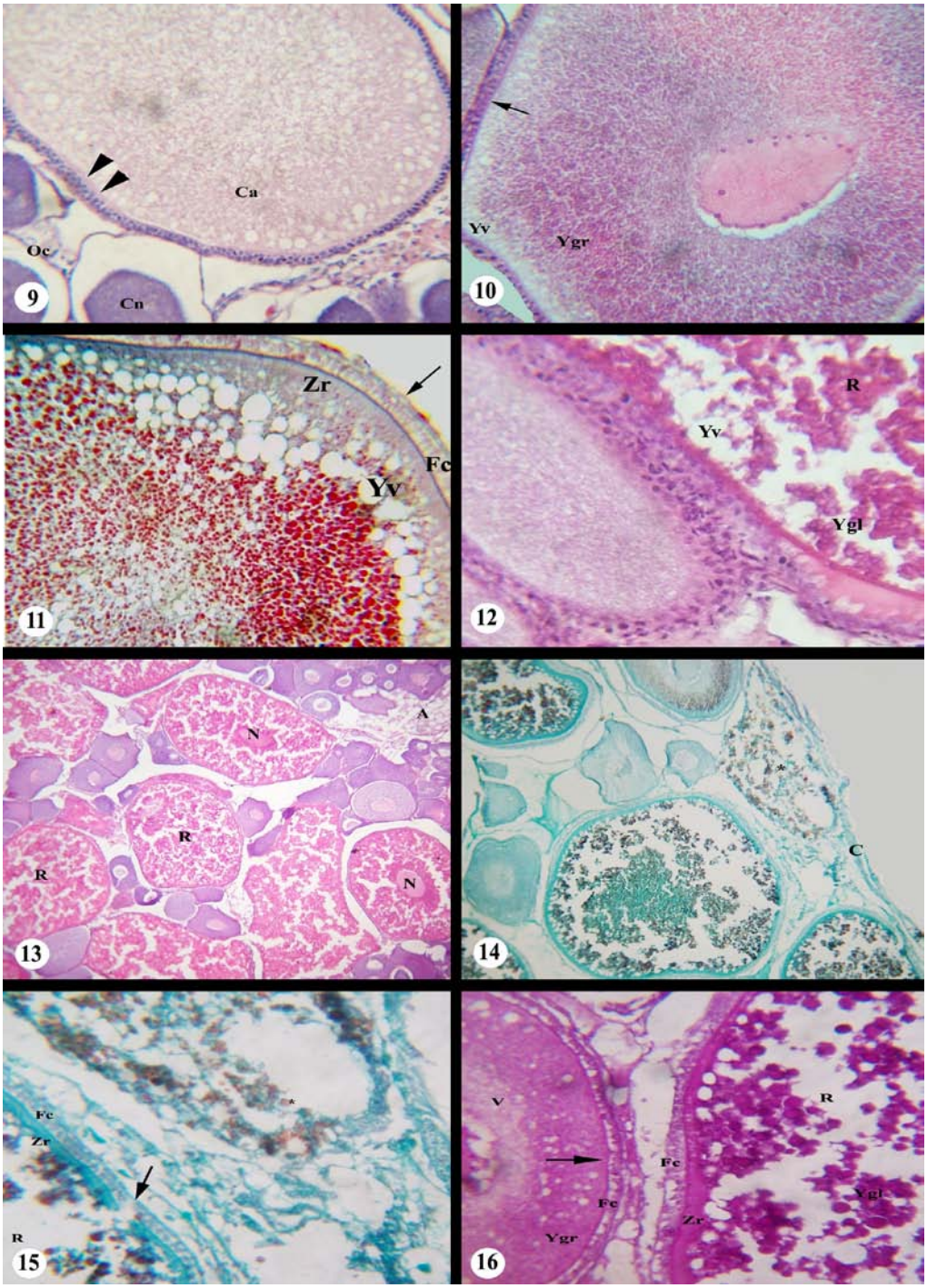
Ca
Oc
Cn
9
Yv
Ygr
10
Zr
Fc
Yv
11
R
Yv
Ygl
12
A
N
R
R
N
13
C
14
Fc
Zr
R
15
V
R
Fc
Fc
Ygl
Zr
Ygr
16

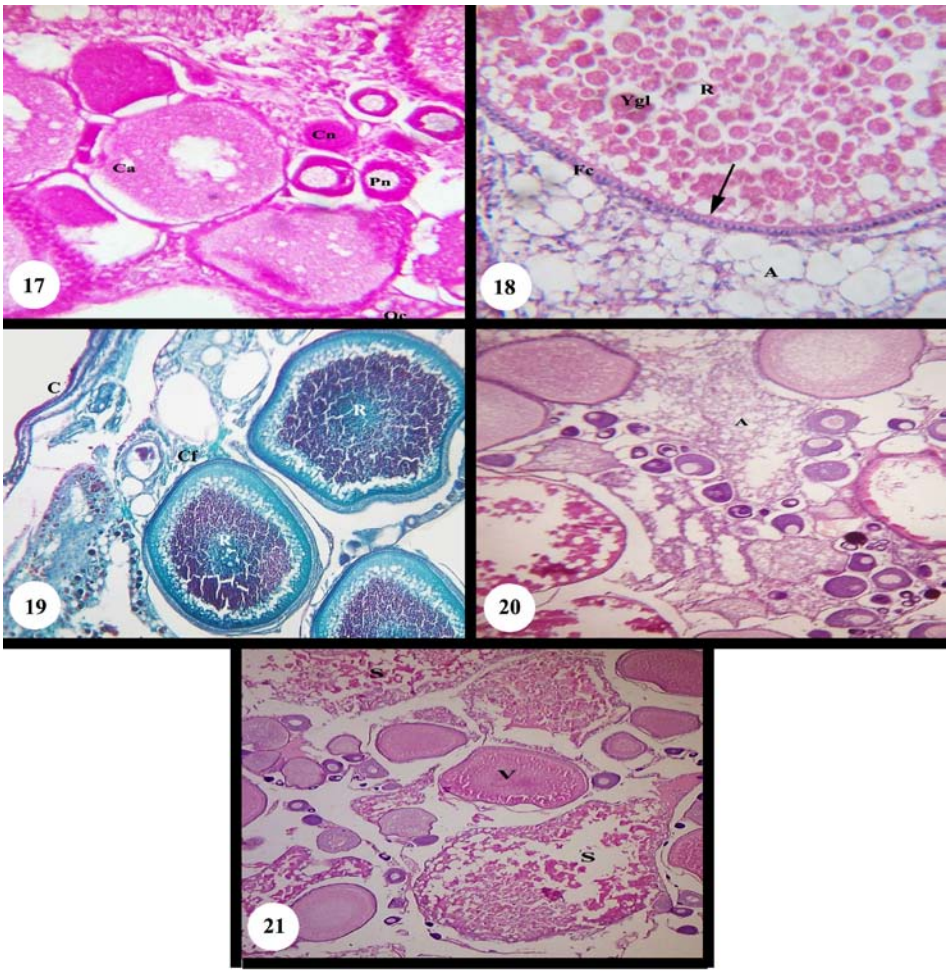

The ripe follicles of the ovary at five months of age and above showed strong PAS reactivity. The reaction was more obvious in the yolk globules and zona radiata. The zona radiata and the yolk granules of the vitellogenic follicles possessed fairly moderate reactivity whereas the follicular cells of both follicles and the interstitial tissue were negatively reacted to PAS stain (Fig 16). The chromatin nucleolus and perinucleolar follicles were strongly reacted to PAS stain. The reaction was confined to the cytoplasm. The cortical alveoli follicles possessed positive reactivity exclusively in the follicular wall. The oogonia and the interstitial tissue showed moderate reactivity to PAS stain (17).

By the mid of the fifth month of age the ovary contained all the follicular developmental stages, with the predominance of the late stages of follicular development mainly the cortical alveoli, vitellogenic and ripe follicles. The number of the ripe follicle continued to increase and their cytoplasm was distended with the yolk globules and consequently the follicular wall was thinner and the follicular cells became cuboidal or low cuboidal with a marked reduction in the thickness of zona radiata and the thecal layer became single layer. The interstitium was almost highly vascularized adipose tissue (Fig 18). The extra follicular deposition of the yolk was continued throughout this period. The tunica albuginea was thin.

At sixth month of age, the ovarian capsule was thin and made up of collagenous fibers. Large blood vessels were present in the interstitium just beneath the capsule (Fig 19). All the follicular stages of development were clearly identified (Fig 20).

The most characteristic features of the ovary from the sixth month of age onward was the presence of spawned or ruptured follicles (Fig 21) which represent folded wall consisted of enlarged follicular cells with piknotic nuclei and theca cells and surrounded by capillary network.

List of Figures:

Fig (1): A photomicrograph of one month Nile tilapia larva showing that the ovary (O) positioned between the kidney (K) and swim bladder (Sb) superiorly and the stomach (S) inferiorly. Diffuse pancreatic acini (P) are seen beside. Note; that the ovary suspended in the cleome by the mesovarium (Mo) which is an extension from the mesentery (M). H & E stain. X40.

Fig (2): A higher magnification of the ovary shown in figure (1) demonstrating a very thin capsule (C) and delicate lamellae (arrows) which containing the ovarian follicles at the chromatin nucleolar (Cn) stage and small oogonia (Oo) next to the capsule. H & E stain. X100.

Fig (3): A longitudinal section of the ovary at 35 day of age indicating two ovarian lamellae. Ovarian lumen (Ol), chromatin nucleolar oocyte (Cn), perinucleolar oocyte (Pn), oogonia (Oo). H & E Stain. X400

Fig (4): A photomicrograph of the ovary of 50 day old fry illustrating a relatively increase in the amount of the fibrous interstitial tissue (I) which is predominately collagenous. The germinal epithelium consists of chromatin nucleolus oocytes (Cn), perinucleolar oocyte (Pn). Crossmon's trichrome. X400

Fig (5): A longitudinal section though the ovary of about two month old fry, showing the distribution of elastic fibers below the capsule and around the follicles. Orcein's stain. X100

Fig (6): A photomicrogrph of the ovary at the end of the third month showing perinucleolar follicles (Pn) with numerous peripheral nucleoli and cortical alveoli follicles (Ca) with large yolk vesicles (Yv). Crossmon's stain. X400

Fig (7): A photomicrograph of the ovary at the fourth month showing the ovarian lamellae (Arrow heads) and vitellogenic follicles (V). Note the presence of adipose tissue (A). H & E stain. X100

Fig (8): A photomicrograph of the tilapia ovary at the end of the fourth month of age representing all the follicular developmental stages, cortical alveoli stage (Ca) with corrugated nucleus and peripheral nucleoli and trilaminar follicular wall. Ripe stage (R) with yolk globules. H & E stain. X 400.

Fig (9): A photomicrograph showing cortical alveoli follicle (Ca). The follicular wall starts to develop zona radiata (head arrows). Many chromatin nucleolar (Cn) follicles are present in addition to oogonial cyst (Oc). H & E stain. X400.

Fig (10): A photomicrograph demonstrating vitellogenic follicle with the yolk granules (Ygr) incorporating the cytoplasm. Note: the peripheral zone of the yolk vesicles (Yv) and the follicular wall (arrow) with a thin zona radiata and cuboidal follicular cells. H & E stain. X 400.

Fig (11): A photomicrograph of a vitellogenic follicle illustrating the centripetal distribution of the yolk granules associated with decrease in the granules size from outward to inward. Yolk vesicles (Yv), zona radiata (Zr), follicular cells (Fc) and theca cells (Arrows). Crossmon'a trichrome stain. X400.

Fig (12): A photomicrograph showing the presence of ripe follicle (R) with rosette-shaped aggregates of large yolk globules (Ygl) intermingled with the coalescent yolk vesicles (Yv). H & E stain. X 400.
Fig (13): A photomicrograph of the ovary at 5 month of age illustrating the predominance of ripe follicles (R) which is distended with yolk globules and some of these follicles possess nuclei (N). The amount of the adipose tissue (A) is increased. H & E stain. X 100.
Fig (14): A photomicrograph of 5 month old Nile tilapia showing the very thin capsule (C). Note the yolk deposition in the interstitial tissue (*). Crossmon's trichrome stain. X 100.
Fig (15): A photomicrograph showing part of ripe follicle (R) with yolk globules, thick zona radiata (Zr), cuboidal follicular cells (Fc) and squamous thecal cells (arrow). Note the profuse extra follicular deposition of the yolk granules (*). Crossmon's trichrome stain. X100.
Fig (16): A photomicrograph demonstrating strong PAS positive reaction in the yolk globules (Ygl) and the zona radiata (Zr) of a ripe follicle (R), whereas the yolk granules (Ygr) and zona radiata (arrow) of the vitellogenic follicle (V) showing moderate reactivity. The follicular cells (Fc) of both follicles and the interstitial tissue are negatively reacted. PAS stain. X400.
Fig (17): A photomicrograph showing a strong PAS positive material in the cytoplasm of the chromatin nucleolar (Cn), perinucleolar follicles (Pn) and in the follicular wall of the cortical alveoli follicles (Ca). Note: oogonial cyst (Oc) with moderate reactivity. PAS stain. X100
Fig (18): A higher magnification of ripe follicle (R) distended with yolk globules (Ygl). The follicular wall consists of thin zona radiata (arrow) and low cuboidal follicular cells (Fc) with the absence of the thecal layer. Note the highly vascularized interstitial tissue with large adipocytes (A). H & E stain. X400.
Fig (19): A photomicrograph of the ovary of 6 month old Nile tilapia showing the ovarian capsule (C) and the underlying interstitial tissue consisting of collagen fibers (Cf). Ripe follicles (R). Crossmon's trichrome stain. X400.
Fig (20): A photomicrograph of tilapia ovary at 6 months of age showing all the developmental stages of the germinal epithelium embedded in a stroma with abundant adipose tissue (A). H & E stain. X100.
Fig (21): A Transverse section through the ovary at the end of the 6 month of age indicating many spawned (ruptured) follicles (S) and vitellogenic follicles (V). H & E stain. X40.

Discussion:

Previous studies concerning ovarian development and folliculogenesis have been made for many species of teleost fish (**Grier, 2000; Ravaglia and Maggese, 2002; Meijide, Lo Nostro, and Guerrero, 2005; Grier, Uribe and Patin˜, 2009**). These studies showed that the presence of gonadal structures (i.e. formation of ovarian cavity), difference in germ cells number, and female earlier meiosis are valid criteria to determine gonadal sex at early phases in development.

The position of the developed ovary in the peritoneal cavity dorsal to the gut and ventral to the developing kidney and its attachment to the mesentery through the mesovarian has been noticed in many fish species including *Cichlasoma dimerus* (**Meijide, *et.al.* 2005**), rosy barb (**Çek, 2006)**. Nile tilapia in the present study was no exception.
In Cyprinus caprio the developing ovary remains compact for the first 90 days post fertilization. Then, small invaginations start to form along its ventral region to form the ovigerous lamellae **(Mazzoni, Grier and Quagio-Grassiotto, 2010)**. Ovigerous lamellae in developing Nile tilapia ovary in this study were seen earlier by the end of the first month.

Liu and de Mitcheson (2009) divided the grouper ovary into three developmental ovarian-phases which were Ov-1 with the formation of the ovarian lumen, Ov-2 with the occurrence of gonial meiosis concomitantly with the development of ovarian lumen and Ov-3 with the development of cortical alveolus stage oocytes. With the application of the previous classification on Nile tilapia in the present investigation, the first stage was completed by the end of the first month, the second stage could be equivalent to the period up to the middle of the third month and the third stage from nearly the end of the third month were cortical alveoli were evident for the first time.

The establishment of ovarian follicles in medaka was noted by 20 day post fertilization (**Shinomiya, Hamaguchi, and Shibata, 2001),** similarly the chromatin nucleolus follicles in tilapia were distinguished earlier before the completion of the first month of age when the chromatin nucleolus oocytes were surrounded by a single layer of follicular cells. The cytoplasm of the oocyte at this stage was highly basophilic**. Selman and Wallace, (1989)** have attributed the cytoplasmic basophilia to the accumulation of cytoplasmic mRNA.

Later in tilapia development, at about 50 day post hatching, the chromatin nucleolus follicles reached the perinucleolar stage in which the nucleo-cytoplasmic ratio decreased and multiple nucleoli in the peripheral region of the oocyte nucleus were clearly observed. In *Odontesthes bonariensis* (**Striissmann, Takashima and Toda, 1996**) and in *Cichlasoma dimerus* (**Meijide, Lo Nostro, and Guerrero, 2005)** the presence of perinucleolar follicles were obvious after 119 and 100 day post hatching respectively, whereas in bluegill sunfish **(Gao, Wang, Rapp, Bryant, Wallat, Wang, Yao, Tiu and MacDonald, 2009)** they were noticed earlier about 60 days post hatching. The appearance of multiple peripheral nucleoli of the oocyte nucleus indicates an intense transcription of ribosomal mRNA **(Selman and Wallace, 1989)**.

The presences of the cortical alveoli stage in the ovary of Nile tilapia were evident lately in development in fish older than three months. This finding was in accordance with that of **(Striissmann, Takashima and Toda, 1996)** in *Odontesthes bonariensis* in which the cortical alveoli were not recognizable until after 140 day post hatching. Contrary to them, **Uchida, Yamashita, Kitano and Iguchi1 (2002)** in zeprafish identified perinucleolar oocytes and cortical alveolar oocytes together at 50 day old onward.

Many terms have been applied to the structures that accumulate in oocyte cytoplasm at the cortical alveoli stage: intravesicular yolk, endogenous yolk, cortical vesicles, and cortical alveoli **(Selman and Wallace, 1989; Wallace and Selman, 1990)**. The development of the follicular wall into zona radiata, follicular cells and thecal cells with progressing development of the follicle is identical with that reported by **Srijunngam and Wattanasirmkit (2001**) in the same species. It has been established that somatic cells from the ovarian stroma of the common snook *Centropomus undecimalis* **(Grier, 2000)** and the swamp eel *Synbranchus marmoratus* **(Ravaglia and Maggese, 2002)** become distributed around follicle cells and form the theca.

The accumulation of yolk granules in the cytoplasm of the oocyte indicating the beginning of the vitellogenic stage (**El-Sayed, and Moharram, 2007**). The yolk materials are of hepatic origin and are transported via blood circulation and formed into yolk granules in the inter follicular spaces, and then into the oocyte by pinocytotic uptake (**Srijunngam, and Wattanasirmkit, 2001**). This could be an explanation of the accumulation of the yolk material in the ovarian interstitial tissue and the centripetal distribution of the yolk granules in the ooplasm noted in the present study.

In the present study the ovary of Nile tilapia at five month of age possessed all follicular developmental stages. This was in agreement with the findings of (**Srijunngam, and Wattanasirmkit, 2001)** in the same species.

The present study on ovarian histology of *O. niloticus* revealed the basic histological architecture and identified the oocytes found within the ovary during its development from one to seven month of age which provides a basic knowledge for other studies such as reproductive biology.

References:

Alves, M. M.; Dos Santos, H. S.; Lopes, R. A.; Petnusci, S. O. and Haiyashi, C. (1983): Rhythm of development in the oocyte of the tilapia *Oreochromis niloticus* L. (Pisces: Cichlidae); a morphometric and histochemical study. Gegenbaurs Morph Jahrb 129:575–592

Angienda, P. O.; Aketch, B. O. and Waindi, E. N. (2010): Development of all-male fingerlings by heat treatment and the genetic mechanism of heat induced sex determination in Nile tilapia (*Oreochromis niloticus* L). International Journal of Biological and Life Sciences. 6(1): 38-43

Bancroft, J. D. and Stevens, S. A. (1996): Theory and practice of Histological Techniques 4th Ed. Churchill Livingstone, Medical Division of Pearson Professional Ltd.

Crim, L. W. and Glebe, B. D. (1990): Reproduction. In: C. B. Schreck and P. B. Moyle (eds.), Methods for Fish Biology, 529-553. American Fisheries Society, Bethesda.

Çek, S.¸E. (2006): Early gonadal development and sex differentiation in rosy barb (*Puntius conchonius*). Animal Biology. 56 (3): 335-350

El-Sayed, H. K. H. A. and Moharram, S. G. (2007): Reproductive biology of Tilapia zillii (GERV, 1848) from Abu Qir bay, Egypt. Egyptian Journal of Aquatic Research. 33(1): 379-394.

Francolini, M.; Lora Lamia, C.; Bonsignorio, D. and Cotelli, F. (2003): Oocyte development and egg envelope formation in *Oreochromis niloticus*, a mouth-brooding cichlid fish. J Sub-microsc Cytol Pathol 35:49–60.

Gao, Z.; Wang, H.; Rapp, D.; O'Bryant, P.; Wallat, G.; Wang, W.; Yao, H.;Tiu, L. and MacDonald, R. (2009): Gonadal sex differentiation in the bluegill sunfish Lepomis macrochirus and its relation to fish size and age. Aquaculture. 294: 138-146

Grier, H. J. (2000): Ovarian germinal epithelium and folliculogenesis in the Common Snook, *Centropomus undecimalis* (Teleostei: Cen-tropomidae). J Morphol 243:265–281

Grier, J. H.; Uribe, M. C. and Patin˜o, R. (2009). The ovary, folliculogenesis and oogenesis in teleosts. In: Jamieson BGM, editor. Reproductive biology and phylogeny of fishes (Agnathans and Bony Fishes) phylogeny reproductive system viviparity spermatozoa. Enfield: Science Publishers. 25–84.

Hussain, M. G.; Penman D. J. and McAndrew, B. J. (1996): Effects of triploidy on sexual maturation and reproduction in Nile tilapia, *Oreochromis niloticus* L. Proceedings of the Third International Symposium on Tilapia in Aquaculture 3: 320-325.

Liu, M. and de Mitcheson, Y. S. (2009): Gonad development during sexual differentiation in hatchery-produced orange-spotted grouper (Epinephelus coioides) and humpback grouper (Cromileptes altivelis) (Pisces: Serranidae, Epinephelinae). Aquaculture. 287:191-202.

Mazzoni, T. S.; Grier, H. J. and Quagio-Grassiotto, I. (2010): germline cysts and the formation of the germinal epithelium during the female gonadal morphogenesis in Cyprinus carpio (Teleostei: Ostariophysi:Cypriniformes). The anatomical record. 293: 1581-1606

Meijide, F. J.; Lo Nostro, F. L. and Guerrero, G. A. (2005): Gonadal Development and Sex Differentiation in the Cichlid Fish *Cichlasoma dimerus* (Teleostei, Perciformes): A Light- and Electron-Microscopic Study. J. Morphol. 264: 191-210

Nakamura, M.; Specker, J. L. and Nagahama, Y. (1993): Ultrastructural analysis of the developing follicle during early vitellogenesis in tilapia, *Oreochromis niloticus*, with special reference to the steroid-producing cells. Cell Tissue Res. 272:33–39.

Ravaglia, M. A. and Maggese, M. C. (2002): Oogenesis in the swamp eel *Synbranchus marmoratus* (Bloch, 1795) (Teleostei; Synbranchidae). Ovarian anatomy, stages of oocyte development and micropyle structure. Biocell 26:325–337.

Selman, K. and Wallace, R. A. (1989): Cellular aspects of oocyte growth in teleosts. Zool Sci 6:211–231.

Shinomiya, A. I.; Hamaguchi, S. and Shibata, N. (2001): Sexual Differentiation of Germ Cell Deficient Gonads in the Medaka, Oryzias latipes. Journal of Experimental Zoology. 290: 402-410

Srijunngam, J. and Wattanasirmkit, K. (2001): Histological structures of Nile Tilapia *Oreochromis niloticus* Linn. Ovary. The Natural History Journal of Chulalongkorn Uni.

Striissmann, C. A.;Takashima, F. and Toda, K. (1996). Sex differentiation and hormonal feminization in pejerrey *Odontesthes bonariensis*. Aquaculture. 139:31-45.

Uchida, D.; Yamashita, M.; Kitano, T. and Iguchi, T. (2002). Oocyte apoptosis during the transition from ovary-like tissue to testes during sex differentiation of juvenile zebrafish. The Journal of Experimental Biology. 205: 711-718

Wallace, R. A. and Selman, K. (1990): Ultrastructural aspects of oogenesis and oocyte growth in fish and amphibians. J Electron Micr Tech 16:175–201.

Young, J. A. and Muir, J. F. (2002): Tilapia: Both fish and fowl? Mar Resour Econ 17:163–173.

HISTOLOGICAL AND IMMUNOHISTOCHEMICAL STUDIES ON THE CLITORIS OF THE DROMEDARY SHE-CAMEL *(CAMELUS DROMEDARIUS)*

***EL-Zoghby, I. M. A. and Emam, M. A.**
***Corresponding author:** Histology & Cytology Department
Faculty of Veterinary Medicine, Benha University, Egypt
E-mail: ihabyara@yahoo.com, ehab.alzaghaby@fvtm.bu.edu.eg

Abstract

Thirty dromedary she-camels at different ages ranging from 2 to 15 years were used to study the histological and histochemical structure of the clitoris during different ages. Immunolocalization of estrogen receptors in the clitoris were also done to better define the role of estrogen hormones in the reproductive functions of she-camels. The histological and histochemical results showed that the clitoris of the she-camels is surrounded externally by pigmented prepuce and internally by very dense collagenous tunica albuginea clitoridis. The structure of the clitoral core differs according to the age of she-camel. The clitoral core of the young she-camel has many cavernous tissue and nerve bundles while, by increase the age, the clitoral core has cartilaginous and ossified part. The immunohistochemical results identified estrogen receptors in the prepuce and the nerve bundles of the she-camel clitoris.

Keywords: Histology, Immunohistochemistry, Estrogen receptor, Clitoris and She-camel

Introduction

Camel (Camelus dromedarius) is an important livestock species uniquely adapted to hot and arid environments. Humans depend on camel not just for meat, milk and skin but also as one of the most important mode of transportation especially in the desert and is recognized as the "Ship of the desert". Puberty of the she-camel is reached at 3-4 years of age **Shwartz, (1992)** and **Musa et al., (1993**). Full reproductive capacity of the female camel is reached at 6 years **Singh (1966)** and **Khetami (1970)**, but it can be bred at 3-5 years of age **Williamson and Payne (1978)**.

Most of the available literature dealt with the histology of the female genital organs of any animal including camels were concentrated on the ovary, uterine tube, uterus, cervix and vagina such as **Abdalla (1965,1967&1968), El-Hag Mousa (1969), Bezrukov & Smidt (1970), El-Wishy and El-Sawaf (1971), Nayak (1977), Ewais et al. (1979a&b), Skidomore et al., (1995)** and **Singh et al., (2005)**, yet now the histological studies on the clitoris of the she-camels were done in a very narrow scale **Awad et al., (1982)** while, the clitoris of buffalo was studied by **Mobarak (1968), Bareedy (1977) and Badawy et al., (1978)** and the clitoris of the cow by **Raghavan and Kachroo (1964) and Hafez (1974).**

Localization of steroid hormone receptors in the reproductive organs have been reported in human, **Hodgins et al., (1998)** and **Pelletier and El-Alfy (2000),** in human and mouse, **Teilmann et al., (2006)** and in rat, **Ohta et al., (1993)** and **Kuiper et al., (1996).** No available literature about localization of estrogen receptors in the clitoris of the she-camels.

Material and methods

A- Samples collection

A total of 30 female genital tracts of dromedary she-camels were collected from El-Basatin, El-Warrak and Toukh abattoirs in Cairo, Giza and Kalyobyia Governorates respectively. The age of the she-camels were ranging from 2 to 15 years to be representative to young and adult ages. The age of these animals were determined according to **Williamson and Payne (1978)**. Immediately after slaughter, the female genital tracts of the she camels were opened by median incision from the dorsal commissure of the vulva to the beginning of the vagina. Different parts from the body of the clitoris of each female tract were collected.

B- Histology

All specimens used for histological studies were immediately fixed in 10% formaldehyde solution buffered with phosphate buffer (pH 7.4), dehydrated through ascending grades of ethanol, cleared in xylene, embedded in paraffin wax and sectioned at 4 - 5 µ thick. The sections were stained with Haematoxylin and Eosin, Periodic acid Schiff (PAS), Alcian blue, Gomeri's reticulin, and Orcein technique. The fixative and staining methods were used as outlined **Bancroft, Cook, Stirling and Turner (1994)**.

C- Immunohistochemistry

Paraffin sections (5 µm) of adult she-camel's clitoris were collected on positive charged microscope slides. Immunohistochemical localization of estrogen receptors (ER) were performed by using an indirect immunohistochemical technique using monoclonal antibodies raised against rabbit (ER).

Result

Clitoris of she-camels is covered by a prepuce which is a continuation from the mucous membrane of the vulva (Fig.1). This prepuce is consisted of a pigmented stratified epithelium (Fig.2). The basal pigmented layer of the preputeal epithelium shows positive reaction for sliver in Gomori's reticulin technique (Fig.3) as well, the preputeal epithelium shows positive reaction for PAS technique that increase in its intensity toward the superficial layer, in addition to that the preputeal epithelium is supplied by genital corpuscle (Fig.4).The preputeal epithelium encloses a layer of fibrous connective tissue (Fig.2) which is rich in elastic fibers (Fig.5), few reticular fibers (Fig.6), highly supplied by many blood vessels with presence of some fat cells (Fig.7), highly innervated by longitudinally and circularly arranged nerve bundles (Figs.8, 9) as well, this connective tissue layer shows Alcian blue reaction (Fig.10).

The core of the she-camel's clitoris is surrounded by very dense sheath of collagenous tunica albuginea and underlying nerve bundles (Fig.11). The structure of the clitoral core differs depending on age of the she-camel. In young she-camel, the clitoral core

is consisted mainly of a network of longitudinally arranged nerve bundles and cavernous tissues and contains some blood vessels (Fig.12). The cavernous tissues appeared as irregular slit-like spaces embedded in highly cellular connective tissue (Fig.13). In early matured she-camels, the clitoral core contains cartilaginous parts which are present at the periphery of the core enclosing fibrous connective tissue in the center (Fig.14). The intracellular matrix of this cartilaginous part shows strong positive reactions for PAS (Fig.15) and for Alcian blue (Fig.16). The fibrous connective tissue in the center of the clitoral core is rich in blood vessels with predominance of collagen fibers (Fig.17), and few fat cells are also present (Fig.18). In late matured she-camels, the clitoral core is characterized by presence of cartilaginous and ossified parts (Fig.19). The cartilage is present as a complete ring that shows strong positive PAS reaction and surrounded by thick tunica albuginea showing negative reaction for PAS (Fig.20).The ossified part is larger than cartilaginous part and shows positive reaction for both PAS (Fig.21) and Alcian blue (Fig.22).

Immunohistochemical results show that the clitoral prepuce of the she-camels has receptors for estrogen hormones, where these receptors are seen in the basal, suprabasal and most superficial cells of the preputeal epithelium (Figs.23, 24). As well, the immunolocalization of the estrogen receptors can be detected in the nerve bundles (Figs.25, 26).

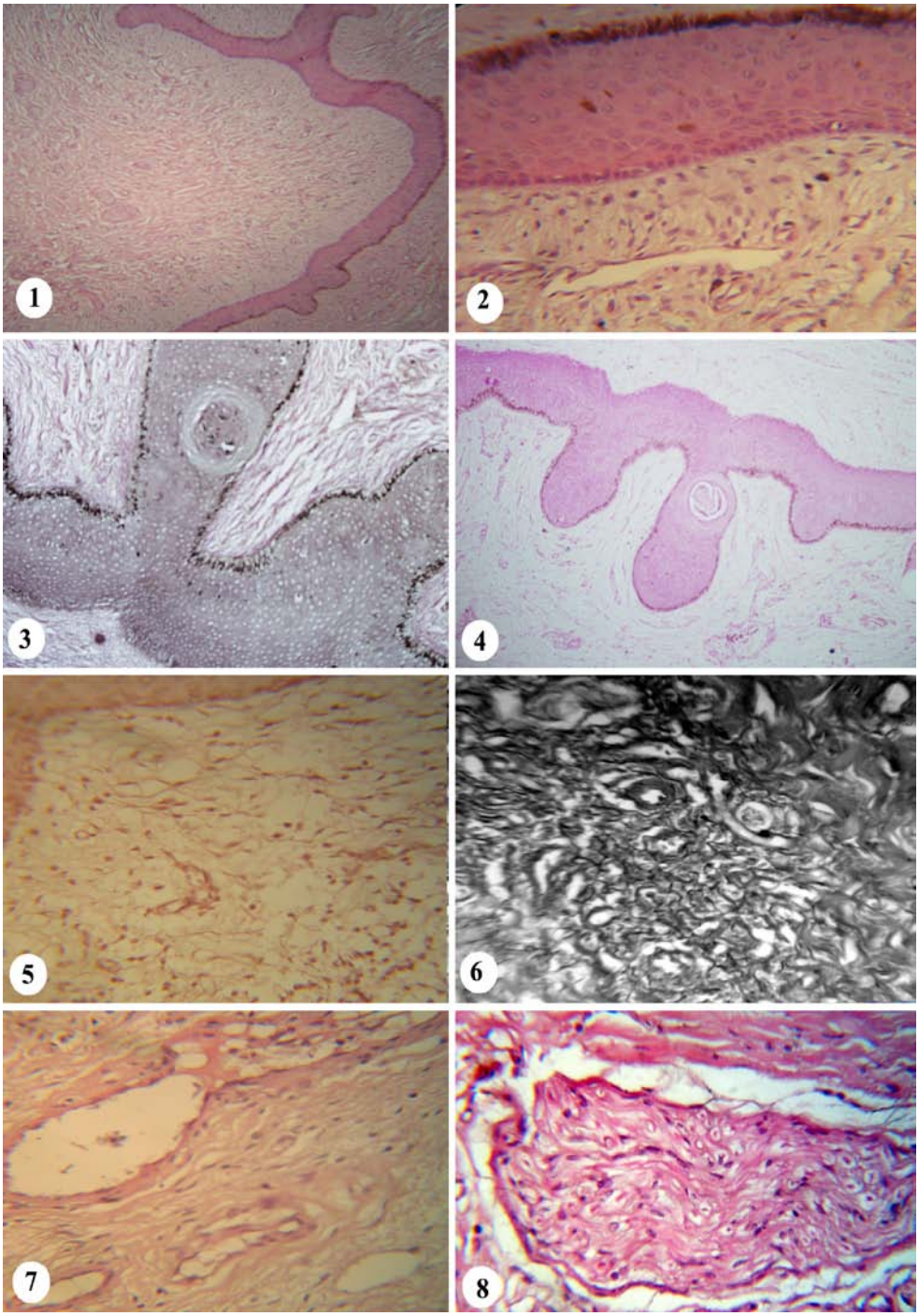
1
2
3
4
5
6
7
8

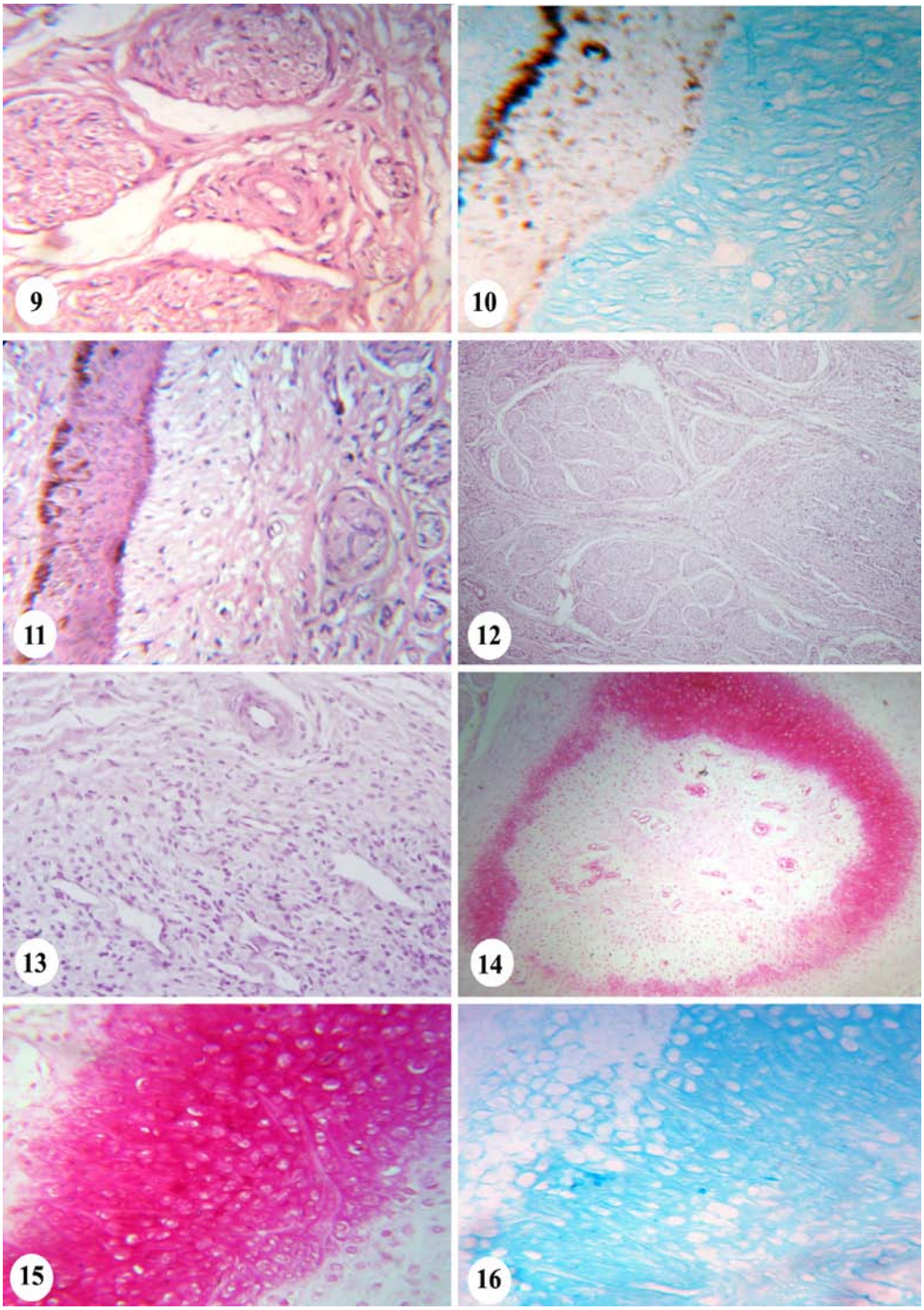
9
10
11
12
13
14
15
16

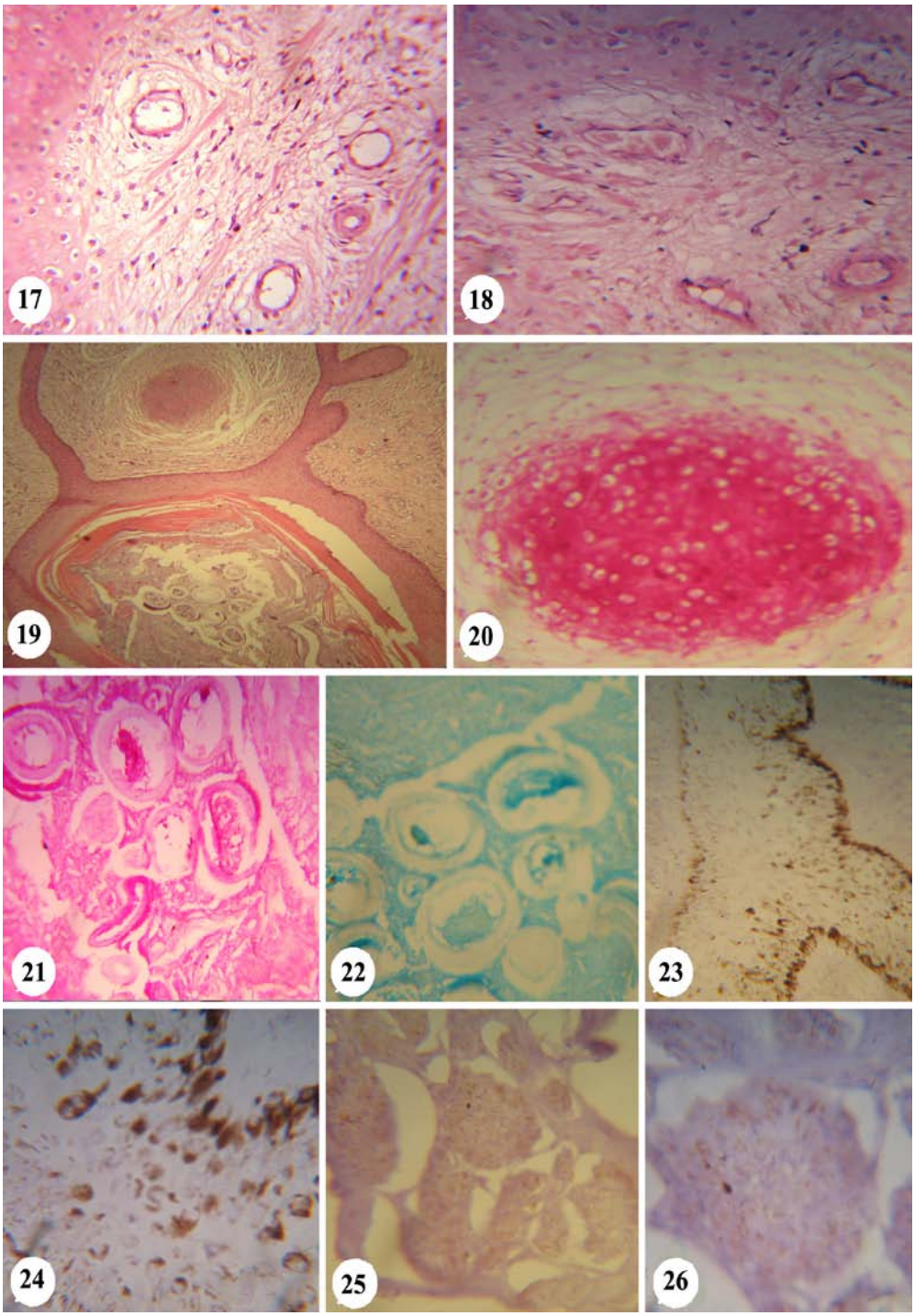

List of figures

Fig. (1): Cross section of clitoris of she-camel showing, the clitorial prepuce that surrounds the clitoris externally. H&E (X40).

Fig. (2): Cross section of clitoris of she-camel showing, that the clitorial prepuce is consisted of a pigmented stratified squamous epithelium. H&E (X400).

Fig. (3): Cross section of clitoris of she-camel showing, positive reaction basal pigmented layer of the preputeal epithelium. Gomori's reticulin (X400).

Fig. (4): Cross section of clitoris of she-camel showing, PAS positive reaction in the preputeal epithelium and presence of genital corpuscle. PAS technique (X200).

Fig. (5): Cross section of clitoris of she-camel showing, presence of many elastic fibers in the connective tissue underlying to the prepuce. Orcien technique (X400).

Fig. (6): Cross section of clitoris of she-camel showing, presence of few reticular fibers in the connective tissue underlying to the prepuce. Gomori's reticulin (X400).

Fig. (7): Cross section of clitoris of she-camel showing, presence of many blood vessels with some fat cells H&E (X400).

Fig. (8): Cross section of clitoris of she-camel showing, presence of nerve bundles arranged circularly H&E (X400).

Fig. (9): Cross section of clitoris of she-camel showing, presence of nerve bundles arranged longitudinally H&E (X400).

Fig. (10): Cross section of clitoris of she-camel showing, Alcian blue positive reaction in the connective tissue underlying to the prepuce. Alcian blue stain PH 2.5 X400.

Fig. (11): Cross section of the core of the she-camel clitoris showing, very dense sheath of collagenous tunica albuginea with underlying nerve bundles H&E (X400).

Fig. (12): Cross section of clitoral core of young aged she-camel showing, many nerve bundles with cavernous tissue H&E (X100).

Fig. (13): A high magnification of figure (12) to show the appearance of the cavernous tissue as irregular slit-like spaces H&E (X400).

Fig. (14): Cross section of clitoral core of mature she-camel showing, the cartilaginous part at the periphery of the clitoral core enclosing fibrous center PAS (X100).

Fig. (15): Cross section of clitoral core of mature she-camel showing, the PAS positive intracellular matrix of the cartilaginous part PAS (X400).

Fig. (16): Cross section of clitoral core of mature she-camel showing, the Acian blue positive intracellular matrix of the cartilaginous part Acian blue PH2.5 (X400).

Fig. (17): Cross section of clitoral core of mature she-camel showing, the cartilaginous part at the periphery of the clitoral core with predominance of collagen fibers and blood vessels in the center of the core H&E (X400).

Fig. (18): Cross section of clitoral core of mature she-camel showing, the cartilaginous part at the periphery of the clitoral core with presence of few fat cells in the core H&E (X400).

Fig. (19): Cross section of clitoral core of adult she-camel showing, presence of both cartilaginous and ossified parts H&E (X100).

Fig. (20): Cross section of clitoral core of adult she-camel showing, PAS positive complete cartilaginous ring and negative PAS tunica albuginea PAS technique (X400).

Fig. (21): Cross section of clitoral core of adult she-camel showing, ossified part with PAS positive reaction PAS technique (X400).

Fig. (22): Cross section of clitoral core of adult she-camel showing, ossified part with Alcian blue positive reaction Alcian blue PH2.5 (X400).

Fig. (23): A section of clitoris she-camel showing, presence of estrogen receptors in preputeal epithelium. Indirect immunoperoxidase technique. (X400).

(X400).

Fig. (24): A higher magnification of figure (23) show estrogen receptors in the basal, suprabasal and most superficial cells of the preputeal epithelium. Indirect immunoperoxidase technique. (X1000).

Fig. (25): A section of clitoris she-camel showing, presence of estrogen receptors the nerve bundles of the clitoris. Indirect immunoperoxidase technique. (X400).

(X400).

Fig. (26): A higher magnification of figure (25) show estrogen receptors in the nerve bundles of the clitoris. Indirect immunoperoxidase technique. (X1000).

Discussion

Our study revealed that the clitoris of the she-camels is covered by a prepuce as all other animal species. The clitoral prepuce of she-camels is considered as a continuation from the mucous membrane of the pigmented stratified epithelium of the vulva that resemble the clitoral prepuce of the mare **Getty (1975)**, but differed with **Mobarak (1968), Bareedy (1977)** and **Badawy et al., (1978)** as they found that the clitoris of buffalo is covered by a prepuce continued from stratified squamous epithelium of the vaginal vestibule. The basal pigmented layer of the preputeal epithelium of the she-camel showed positive reaction for sliver technique that indicated presence of melanin pigement in this prepuce. Our result about the positive reaction of the preputeal epithelium for PAS technique agreed with **Bareedy (1977) and Badawy et al., (1978)**. Our result identified presence of genital corpuscle in the clitoral prepuce of the she-camel that is supported by the result of **Hafez (1974)** in cow, **Miller et al., (1964)** in bitch and **Corona et al., (1991)** in sow. As well, **Trautmann and Fiebiger (1957)** and **Getty (1975)** identified pacinian and genital corpuscles in the visceral layer of the clitoral prepuce. The she-camels clitoral prepuce is inclosing vascular connective tissue core rich in elastic fibers and few reticular fibers that agreed with **Awad et al., (1982)** and **Chhieng and Hui (2011)**. This connective tissue layer showed Alcian blue reaction. A extensive network of longitudinally and circularly arranged nerve bundles were present next to the clitoral prepuce of the she-camels that supports the initiation of sexual arousal by tactile stimuli. The highly innervated clitoral structure was agreed with **Trautmann and Fiebiger (1957), Baskin et al., (1999), Corona et al., (1991), O'Connell et al., (2005)** and **Martin-Alguacil et al, (2008)**, but **Awad et al., (1982)** in she-camel and **Mobarak (1968), Bareedy (1977)** and **Badawy et al., (1978**) in buffalo did not concern with this area.

The core of the she-camel's clitoris is surrounded by very dense sheath of collagenous tunica albuginea similar to that obtained in she-camels by **Awad et al., (1982)**, in buffaloes by **Bareedy (1977) and Badawy et al., (1978)** and in cow by **Trautmann and Fiebiger (1957)** and **Hafez (1974)**. The structure of the clitoral core differs depending on age

of the she-camel. In young aged she-camel, the clitoral core is consisted mainly of cavernous tissues appeared as irregular slit-like spaces embedded in highly cellular connective tissue that is similar to that mentioned in buffalo by **Mobarak (1968), Bareedy (1977)** and **Badawy et al., (1978)** and in cow by **Trautmann and Fiebiger (1957)** and **Hafez (1974),** while in mare, **Trautmann and Fiebiger (1957), Dellmann (1971)** and **Getty (1975)** stated that the clitoris is composed of erectile tissue similar to corpus cavernousum penis. On the contrary, in bitch, **Trautmann and Fiebiger (1957)** and **Getty (1975)** concluded that the corpus clitoridis is non erectile as it has large amount of adipose tissue. The clitoris of she-camels has some fat cells that similar to those in bitch and sow that mentioned by **Trautmann and Fiebiger (1957)** and **Dellmann (1971)** while, **Bareedy (1977)** denied the presence of fat cells are in the clitoris of the calves but he found that the fat cells increase by age to be located in the most caudal part of the clitoris of adult buffaloes.

As **Awad et al., (1982)** mentioned that the corpus clitoridis of she-camels has cartilaginous and ossified parts, our results also found that but, in early matured she-camels, the clitoral core contained cartilaginous parts only which enclose fibrous connective tissue in its center, while in later maturity, and we found both cartilaginous and ossified parts. At this stage, cartilaginous parts appeared as a complete ring and not hollow as in early maturity. Both cartilaginous and ossified part show strong positive reactions for PAS and Alcian blue. However, **El-Hariri et al., (1988)** stated that the clitoris of camel fetuses had no cartilages or osseous tissue but it has more erectile tissue. In mice, **Yanga et al., (2010**) identified bone in XTfm/Y mice and cartilage in αERKO mice while, in rat, **Murakami and Mizuno (1984)** stated that the normal females have neither cartilages nor bones in the clitoris.

Our immunohistochemical results showed that the clitoral prepuce of the she-camels has receptors for estrogen hormones, where these receptors are seen in the basal, suprabasal and most superficial cells of the preputeal epithelium as well, and the immuno-localization of the estrogen receptors can be detected in the nerve bundles. No available literature on the immuno-localization of estrogen receptors in the clitoris of the she-camel or any other species but, the available literatures were vagina and vulva.

MacLean et al., (1990) and **Hodgins et al., (1998)** demonstrated estrogen receptors in the basal and suprabasal cells of vaginal epithelium and epidermal keratinocytes of the vulva and perineum while, **Wolf et al., (1991)** demonstrated nuclear estrogen receptors in the smooth muscle of the trigone and the posterior part of the bladder neck and vagina of women. In dog, **Vermeirsch et al., (2002)** observed nuclear staining for ERalpha, in the surface epithelium, stromal and smooth muscle cells of the vagina and the vulva.

References

Abdalla, O. (1965): Anatomical study of the female genital system of the one-humped camel (Camelus dromedarius). I. The ovaries. Sud. J. Vet. Sci. Anim. Husb., 6, 41-52.

Abdalla, O. (1967): Anatomical study of the female crenital system of the one-humped camel (Camelus dromedaries). 11. The oviducts. Sud. J. Vet. Sci. Anim. H., 8, (2) , 67-77.

Abdalla, O. (1968): Anatomical study of the female genital system of the one-humped camel (Camelus dromedaries). III. The uterus and placenta. S.J. Vet. Sci. Anim. Husb. 9: 477.

Awad H. H., El-Hariri M. N. and Bareedy M. H. (1982): Macro-and Micromorphological study of the female copulatory organs of the one-humped camel (camelus dromedarius). Egypt. J. Histo., 5 (1): 85-94.

Badawy,Y.H., Ewais, M.S., Mahmoud, S.A. and Bareedy M.H. (1978): A Micromorphological Study of the female Copulatory Organs of Buffaloes in Egypt (Bos bubalus L.). Gegenbaurs Morph. Jahrb., Leipzig 124 (5): 663-679.

Bancroft, J. D.; Cook, H.C.; Stirling, R.W. and Turner, D.R. (1994): Manual of histological Techniques and their diagnostic application. 2nd Ed., Churchill Livingston, Edinburgh, London, Madrid, Melbourne, New York and Tokyo.

Bareedy, M. H. (1977): Some micromorphological studies of the female copulatory organs of buffaloes in Egypt (Bos bubalis L.) with reference to the vestibular glands. Master thesis, Faculty of Veterinary Medicine, Zagazig University.

Baskin, L.S.; Erol, A.; Li, Y.W.; Liu, W.H.; Kurzrock, E. and Cunha, G.R. (1999): Anatomical studies of the human clitoris. J. Urology, 162 (3):1015-1020.

Bezrukov, N.I. and Smidt, G.A. (1970): Some aye and functional chanqes in the ovaries and uterus of Bactrian camels. Arkh. Anat. Histol. Embriol., 58, (l) , 64-73.

Chhieng, D. and Hui, P. (2011): Cytology and Surgical Pathology of Gynecologic Neoplasms. Chapter (1): Normal Histology of Female Genital Organs. 1st Ed., Humana Press. Page: 1-13.

Corona, M.; Scala, G.; Budetta, G.C. and Crasto, A. (1991): The sensitive nerve endings of the clitoris of the sow (Sus scrofa domesticus). Anat. Histol. Embryol., 20(4):369-77.

Dellmann, H.D. (1971): Veterinary histology, an outline text and atlas, Lea and Febiger, Philadelphia, USA.

El-Hag Mousa, B. (1969): A study of some aspects of the reproduction in the female camel (Camelus dromedaries). Thesis, Fac. Vet. Med., Khartum, Sudan.

El-Hariri, M.N., Bareedy, M.H., Salem, H.F., Balah, A.M., Edaroos, A. and Awad, H.H. (1988): Pre-natal development of the copulatory organs of she-camel (Camelus dromedarius). Zagazig Vet. J. Vol. 16 (3): 250-264.

El-Wishy, A.B. and El-Sawaf, S.A. (1971): Functional activity of the ovaries and uterine horns in fat-tailed sheep and camels (Camelus dromedarius). Fortpflanzung. Besamung und Aufzucht der Haustiere, 7 (3): 181-187.

Ewais, M.S.S.; El-Hariri, M.N.; Yousef, H.I.; Affiefy, M.M. and Omar, M.A. (1979a): Cyclic variation in the structure of the cervix of the she-camel (Camelus dromedaries). Egypt. Vet. Med. J. Vet. Sci.; 27: 183.

Ewais, M.S.S.; Yousef, H.I.; Affiefy, M.M. and Abu-El- Fadle, W.S. (1979b): Some macro and micromorphlogical studies on the uterine tube of the camel (Camelus dromedaries) in different phases of the estrous cycle and pregnancy. Egypt. Vet. Med. J. Vet. Sci.; 27: 202.

Getty, R. (1975): The anatomy of the domestic animals, volume I and II ,5th Ed. W. B. Saunders Comp. Philadelphia, London, Toronto, Mexico city, Rio de Janeiro, Sydney and Tokyo.

Hafez, E. S. E. (1974): Reproduction in farm animals, 3rd Ed., Lea and Febiger, U.S.A.

Hodgins, M.B.; Spike, R.C.; Mackie, R.M. and MacLean, A.B. (1998): An immunohistochemical study of androgen, oestrogen and progesterone receptors in the vulva and vagina. Br. J. Obstet. Gynaecol. 105(2):216-222.

Khetami, K. (1970): Camel meat: a promising new approach to the solution of meat and protein in the arid and semi-arid countries of the world. Ministry of Agriculture report. Tahran, Iran.

Kuiper, G.G.J.M.; Enmark, E.; Puelto-Huiko, M.; Nilsson, S. and Gustafsson, J.A. (1996): Cloning of a novel estrogen receptor expressed in rat prostate and ovary. Proc. Natl. Acad. Sci. USA. 93:2925–2930.

MacLean, A.B.; Nicol, L.A and. Hodgins, M.B. (1990): Immunohistochemical localization of estrogen receptors in the vulva and vagina. J. Reprod. Med.;35(11):1015-1026.

Martin-Alguacila, N.; Schobera, J. M.; Sengelaubd, D. R.; Pfaffa, D. W. and Shelleya, D. N. (2008): Clitoral Sexual Arousal: Neuronal Tracing Study From the Clitoris Through the Spinal Tracts. J. Urology, 180, (4):1241-1248.

Miller, M. E. ; Christensen, G. and Evan, H. (1964): Anatomy of the dog, W. B. Saunders Comp. Philadelphia and London.

Mobarak, A.M. (1968): Anatomical studies of the female genitalia of buffaloes. M.D.V. Thesis, Cairo University, Egypt.

Murakami, R. and Mizuno, T. (1984): Histogenesis of the os penis and os clitoridis in rats. Develop. Growth and Differ., 26 (5), 419-426.

Musa, B., Sieme, H., Merkt, H., Hago, B., Cooper, M., Allen, W. and Jochle, W. (1993): Manipulation of reproductive functions in male and female camels. Animal Reproduction Science, 33,:289-306.

Nayak, R.K. (1977): Scanning electron microscopy of the camel uterine tube (Oviduct). American Journal of Veterinary Research, 38, 7, 1049-1054.

O'Connell, H.E.; Sanjeevan, K.V. and Hutson, J.M. (2005): Anatomy of the clitoris. J. Urol., 174(4 Pt 1):1189-95.

Ohta, Y.; Sato, T and Iguchi, T. (1993): Immunocytochemical Localization of Progesterone Receptor in the reproductive of adult female rats. Biology of reproduction, 48, 205-213.

Pelletier, G. and El-Alfy, M. (2000): Immunocytochemical localization of estrogen receptors α and ß in the human reproductive organs. J. Clinic. Endocrinol. & Metabolism, 85(12): 4835-4840.

Raghavan, D. and Kachroo, P. (1964): Anatomy of the ox. 1st Ed., Indian Council of Agricultural research, New Delhi.

Shwartz, H.J. (1992): Productive performance and productivity of dromedaries (Camelus dromedarius). Animal Research and Development, 35, 86-98.

Singh, G., Nagpal, S. K. and Kumar, S. (2005): Scanning electron microscopic studies on the female genitalia of camel (Camelus dromedarius). Journal of Camel Practice and Research.12: 1, 21-25.

Singh, H. (1966): Handbook of animal husbandry for extension workers .Ministry of food and Agriculture, Directorate of Extension, Ministry of Food and Agriculture. New Delhi. p 162.

Skidomore, J.A.; Billah, M. and Allen, W.R. (1995): The ovarian follicular wave pattern in the mated and non mated dromedary camel (Camel dromedarius). J. Reprod. Fertil. Suppl. 49: 454-458.

Teilmann, S.C.; Clement, C.A.; Thorup, J.; Anne Grete Byskov, A.G. and Christensen, S.T. (2006): Expression and localization of the progesterone receptor in mouse and human reproductive organs. J. Endocrinology,191, 525-535.

Trautmann, A. and Fiebiger, J. (1957): Fundamentals of the Histology of domestic animals, 4th Ed., Ithaca, New York, Comstock.

Vermeirsch, H.; Van den Broeck, W. and Simoens, P. (2002): Immunolocalization of sex steroid hormone receptors in canine vaginal and vulvar tissue and their relation to sex steroid hormone concentrations. Reprod. Fertil. Dev.;14(3-4):251-258.

Williamson, G. and Payne, W.J.A., (1978): An Introduction to Animal Husbandry in the Tropics. 3rd ed. England and New York.

Wolf, H.; Wandt, H. and Jonat, W. (1991): Immunohistochemical evidence of estrogen and progesterone receptors in the female lower urinary tract and comparison with the vagina. Gynecol Obstet. Invest.; 32(4):227-31.

Yanga, J.H.; Menshenina, J.; Cunhaa, G.R.; Placea, N. and Baskin, L.S. (2010): Morphology of mouse external genitalia: Implications for a Role of Estrogen in Sexual Dimorphism of the mouse genital tubercle. J. Urology, 184(4): 1604-1609.

NEUROLOGICAL DEFICITS AND CHANGES IN THE BRAINSTEM AUDITORY EVOKED POTENTIALS IN THE CENTRAL VESTIBULAR SYSTEM DISORDERS

Armașu Mihaela, Musteață M., Zbângu Adina, Solcan Gh.
F.M.V. Iași, 8 , Mihail Sadoveanu Alley
armasumihaela@yahoo.com

Abstract
The study was conducted on five dogs that were presented for consultation at the FMV Medical Clinic and were evaluated by clinical, neurological and BAER tests. Vestibular syndrome was clinically diagnosed in 4 dogs based on torticollis, head tilt and vestibular ataxia, and in the 5th pacient neurological diagnosis was attributed to positional strabismus.
For a more accurate neurolocalization and for the determination of the degree of damage extension in the central vestibular system, a brainstem auditory evoked potential (BAER) test was performed. In this test was mainly observed the modification of wave III latency, demonstrating that the biggest changes in the central vestibular system damage are in the posterior brainstem. Wave V latency was normal, so at the level of inferior colliculi were observed no changes in speed of transmission of auditory information, this being due to crossing fibers leading auditory information at this level. Also the high correlation degree (r^2> 0.9) between wave III amplitude of the healthy ear and diseased one shows the influence the contralateral ear in the acoustic stimulus transmission.
In conclusion we say that BAER test has high accuracy in determining which components of the vestibular system is affected and the gives us information about the extension of the lesion.
Keywords: *brainstem auditory evoked potential, BAER, central vestibular system, dog*

Introduction

Vestibular system is the main component of the nervous system with role in maintaining balance and coordination of head movements according to eye, trunk and limbs positions. It also detects static acceleration, deceleration and rotational movement of the head. (de Lahunta A., 2009)

Neuroanatomic, vestibular system can be divided into a peripheral component (which consist of the vestibular division of cranial nerve VIII and vestibular receptors) and a central one (composed of 4 vestibular nuclei on either side of the bulb, the fastigial nucleus and floculonodular lobe of the cerebellum) (Kent M., 2009).

Peripheral vestibular system disorders must be distinguished from pathological processes that affect the central vestibular system in order to establish the methodology of the further investigations. The most common diseases that affect the peripheral vestibular system have better prognosis and the treatment is easier than those affecting the central component (Lorenz D.M, 2004).

Between the means of investigating the vestibular system, BAER test is a very accurate method in discrimination of peripheral segment pathology and / or central one, in determining the exact location and the degree of extension of the lesion (Poncelet L., 2004).

Materials and method

The study was performed on 5 dogs which were presented to Internal Clinic of Faculty of Veterinary Medicine Iasi. The dogs were submitted to clinical and neurologic exams. For each patient BAER test was performed (as previously described technique by Musteaţă M. in 2009). Statistical significance of results was verified by paired Student t test and the Pearson correlation test.

Results and discussions

Clinical signs of patients included in the study, investigation means and diagnosis techniques used are described in Table 1.

Table 1 Signalments, clinical signs, investigation techniques and patient diagnosis

Patient	Signalments	Clinical signs	Investigation techniques	Diagnosis
C01	Caniche, male, 10 years 19 kg	Depression, falls, broad-based stance, ataxia, circling, forelimbs dismetria, conscious proprioception zero on left pelvic limb, hopping reactions on the thoracic limbs diminished, patellar reflex bilateral exaggerated, carpal extensor reflex exaggerated on left leg	Clinic and neurologic signs, Baer test	Right central vestibular syndrome
C02	Pekinez, 8 years, male, 11,5 Kg	Depression, broad-based stance,falls, circling in the right side, right head tilt, ataxia, , hopping reaction on the right thoracic limb diminished, positional right strabismus.	Clinic and neurologic signs, Baer test	Right central vestibular syndrome
C03	Crossbreed, female, 10 years, 8 Kg	Depression, left head tilt, circling in the left side, broad-based stance, falls, hopping reaction on the thoracic limbs diminished.	Clinic and neurologic signs, Baer test	Left central vestibular syndrome
C04	Crossbreed, male, 3 years, 11,5 Kg	Depression, falls, circling in the left side, broad-based stance, left head tilt, rolling, intention tremor, hopping reactions on the thoracic limb diminished, absence of menace in the right eye.	Clinic and neurologic signs, Baer test	**B**ilateral central vestibular syndrome

C05	Bucovina Shepherd, 6 months, 35 Kg	Positional right strabismus, patellar reflexes diminished, flexion reactions on thoracic and pelvic limbs diminished, conscious proprioception on pelvic limbs zero.	Clinic and neurologic signs, Baer test	**B**ilateral central vestibular syndrome

Vestibular syndrome was clinically diagnosed in 4 dogs based on torticollis, head tilt and vestibular ataxia, and in the 5th pacient (C05) neurological diagnosis was attributed to positional strabismus.

Torticollis was observed in 3 of 5 dogs and range from a few degrees to 45 degrees, being caused by the loss of the anti-gravity muscle tone of the neck on the same side as the lesion (RS Platt R.S., 2004) This has created difficulty to keep the animal's position. C04 patient also experienced episodes of rolling, that could be due to damage of middle cerebellar peduncles or the cerebellum.

Falling and the head tilt were seen in 4 cases. After Kent M. (2009), they are caused by damage of the lateral vestibular nucleus ipsilateral to the lesion which transmits wrong information to the vestibulospinal tract the same defective part. This leads to loss of ipsilateral extensor muscle tone which no longer antagonize the contralateral extensor muscle tone.

In the case of four patients, central vestibular system damage was not difficult to diagnose after neurological examination, due to alteration of consciousness and proprioceptive sensitivity of the forelimbs. Cortical depression has been interpreted with caution, it may be due to damage to ascending reticular system (M. Kent, 2009). After Garosi L. (2006) vestibular nuclei transmitted from vestibulo-thalamic tracts information to thalamus (subcortical integration center of the information). So that depression may occur without affecting the ascending reticular system, but secondary to maltransmission of the information from affected vestibular nuclei to the thalamus.

4 of patients have experienced a decrease unconscious proprioception in forelimbs. In the patient C02, it provided information on lateralization of the lesion into the brainstem.

The signs of damage the cerebellum in the vestibular syndrome were: forelimbs dismetria (the dog C01), intention tremor and the absence of menace in the right eye (the patient C04).

BAER test was performed in every patient to achieve a more accurate neurolocalization and for establish the extending of the lesion from the brainstem.In this test, it were measured latencies and amplitudes of waves I, III and V and the interwaves intervals I-III, III-V and I-V at an intensity of 90 dB of the acoustic stimulus (Fig.1).

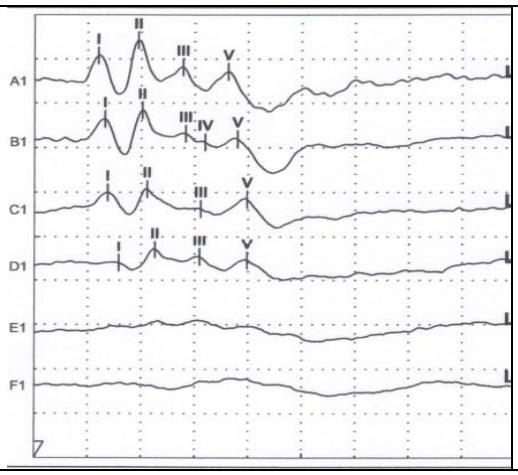

Fig.1 BAER test in a dog with central vestibular syndrome. Waves III with increased latency and waves V with descreased amplitude in the affected ear.

The mean of latencies and amplitudes of waves I, III and V and the intervals I-III, III-V and IV at a stimulus intensity of 90 dB are shown in Table 2

Table 2 Mean latencies and amplitudes of waves I, III and V and the intervals I-III, III-V, IV ± standard deviation in healthy and diseased ears of dogs studied.

	HEALTHY EAR			DISEASED EAR		
LATENCY	I	III	V	I	III	V
	1,156± 0,037	2,806± 0,064	3,773± 0,124	1,226± 0,172	3,042± 0,063	3,946± 0,166
AMPLITUDE	I	III	V	I	III	V
	2,513± 0,557	1,316± 0,240	1,936± 0,575	2,123± 1,418	1,377± 1,003	1,793± 0,461
INTERVAL	I-III	III-V	I-V	I-III	III-V	I-V
	1,65± 0,081	0,966± 0,115	2,616± 0,161	1,813± 0,175	0,903± 0,126	2,72± 0,287

In the dogs examined it were not found statistically significant differences between waves I, III and V in the healthy ear in terms of latencies, amplitudes and intervals ($p > 0.05$) the group examined being with a high degree of homogeneity.

Contrary to the results of Steiss (1994), that in the central vestibular system disorders she found increased latency of all waves in the affected ear, in all the 5 patients take in the study statistically significant differences ($p > 0.05$) were found only for wave III latencies between the healthy and sick ear. Also Myers (1986), in central vestibular syndrome found an increase in the intervals between the all waves which was not observed by us. For patients investigated we found no statistically significant differences between the intervals I-III, III-V and I-V to the sick and healthy ear. This demonstrates that brain stem lesions caused change in speed of transmission of auditory information in its caudal portion (III wave generator is superior olivary complex of the pons). Wave V latency was normal, so

at the level of the inferior colliculi (V wave generator is inferior colliculus from the mid-brain) were observed no changes in speed of transmission of auditory information. This is due to crossing fibers leading acoustic information at inferior colliculi.

However, due to statistical differences observed only for wave III latency between sick and the healthy ear, we can say that in the central vestibular syndrome, the most affected wave latency was the wave III . This finding shows that the segment mainly affected was in the caudal portion of brainstem, contrary to the results of Steiss (1994). She noted that the most affected wave was the wave V latency, indicating the predominant portion of skull injurious brainstem. We also observed correlation between the amplitude of wave III of the healthy and diseased ear, which shows crossing fibers of transmission of the auditory information at the level of the superior olivary complex, the amplitude of wave III of the healthy ear influencing the amplitude of wave III of the diseasead ear.

Conclusions

In our case, in the BAER test was observed only the modification of wave III latency, demonstrating that the biggest changes in the central vestibular system damage are in the posterior brainstem. Normal wave V latency shows that at the level of inferior colliculi were observed no changes in speed of transmission of auditory information, this being due to crossing fibers leading auditory information at this level. Also the high correlation degree (r2> 0.9) between wave III amplitude of the healthy and diseased ear shows the influence the contralateral ear in the acoustic stimulus transmission.

References

1. De Lahunta A., 2009 - Veterinary neuroanatomy and clinical neurology , Third edition, W.B. Saunders Company, Philadelphia pg 319-347
2. Garosi L, McConnell JF, Platt SR, Barone G, Baron JC, de Lahunta A, Schatzberg SJ., 2006 - Clinical and topographic magnetic resonance characteristics of suspected brain infarction in 40 dogs, J Vet Intern Med. Mar-Apr;20(2):311-21.
3. Kent M., Platt S. R., Schatzberg S. J., 2009 - The neurology of balance: Function and dysfunction of the vestibular system in dogs and cats, The Veterinary Journal, doi:10.1016/j.tvjl.2009.10.029
4. Lorenz D.M., Kornegay N.J., 2004 - Handbook of veterinary neurology, Fourth edition,. Ed.Sounders, Philadelphia pg 219-245
5. Musteaţă M., Neculae Irina, Solcan Gh., 2009 A study of brainstem auditory evoked potentials (BAER) in cats, Scientific Works, C series, Veterinary Medicine, USAMV Bucure şti, LV III, pg.184
6. Myers L.J., Redding W.R., Wilson Sharon, 1986, Abnormalities of the brainstem auditory response of the dog associated with equilibrium deficit and seizure, Veterinary Research Communications, Volume 10, Number 1, pg. 73-78
7. Platt R.S., Olby J. Natasha, 2004 – Canine and feline neurology, 3rd , British Small Veterinary Assoc., pg 155-172
8. Poncelet L., 2004 - Electrophysiology. In PLATT S., OLBY N.J. BSAVA Manual of Canine and Feline Neurology 3rd ed., BSAVA, Gloucester, p. 64-66

9. Steiss E. Janet, Cox R. Nancy, Hathcock T. J., 1994, Brain Stem Auditory-Evoked Response Abnormalities in 14 Dogs With Confirmed Central Nervous System Lesions , Journal of Veterinary Internal Medicine DOI: 10.1111/j.1939-1676.1994.tb03236.x

INVESTIGATIONS OF BIO-MOS EFFECT ON INDEX NUMBERS OF PRODUCTION AND HEMATOLOGICAL INDEXES IN PIGLETS AND SOWS

BALANESCU S.
Agrarian State University of Moldova
savva-balanescu@mail.ru

Abstract. In this study the action of the Bio-Mos product was investigated by adding it in the combined forage for sows and suckling piglets. 50 gestating sows and 474 piglets of 1-45 were monitoring during the survey.
It was found out that the Bio-Mos addition to the basic diet has a favorable effect on piglet's growth and development, that can be confirmed by following data:
- mortality and neonatal diarrhea reduction, increase of weight of 0.7 kg in sows which were given Bio-Mos (P<0,05)
- significant increase of the total amount of T-lymphocytes (P<0,02), the subpopulation of active T-lymphocytes (P<0,01) and B-lymphocytes (P<0,05).

Key words: Bio-Mos, Neonatal diarrhea, Prophylaxis, Suckling piglet.

INTRODUCTION

Previous investigations conducted in the Republic of Moldova in particular at the Internal Medicine Department of the Faculty of Veterinary Medicine showed that the interconnection between achievement of the high productive results and artificial conditions of upkeep, increase of infection influence and nutritional imbalance increased significantly the mortality and morbidity rate. According to D. Holban, DVM (1982) at some farms gastrointestinal emergencies make up 71-77% of total amount of internal diseases.

In accordance with previous statements the application of new conceptions of etiological diagnosis, prophylaxis, metaphylaxis in gastrointestinal diseases of piglets should be developed to prevent economic losses in this area.

During previous ten years the antibiotics were commonly used as the preventive care and treatment to compensate the technological and nutritional which may lead to hard diseases (S. Balanescu, D. Parii, 1985, HoreaSarandan, 2007).

Antibiotics were used in subtherapeutical doses as the growth promoters. Nowadays, doses and costs of antibiotics are progressively increasing; however their efficacy is decreasing (H. Barza, 2000). Since January 1, 2006 at the EU level it was decided that the antibiotics which were used as growth promoters are required to be replaced by other product which wouldn't affect consumer's health and in the same time it needs to be at least the same efficacy as antibiotics (Pearse Lyons T., 2007).

The goal of this work is to study Bio-Mos effects on deep-gestating sows, lactating sows and their progeny.

MATERIALS AND METHODS

The survey was carried out on 50 2 to 3 year old deep-gestating sows which were kept in industrial conditions and their progeny. The animals were divided into 2 groups: control group I consisted of 25 sows and experimental group consisted with the same amount of saws. Animals were fed with combined forage according their category: lactating saws, suckling piglets, respecting the average structure and basic parameters recommended in specific literature.

The sows from both groups were fed twice a day with 5 kg of combined forage daily.

The only difference between two groups was that sows from the experimental group were added Bio-Mos in their ration in amount of 2 kilos per ton of combined forage. Combined forage introduction into the diet of suckling piglets was performed after the first week of their life. Bio-Mos was added as the supplement in proportion of 2g per 1kg of combined forage.

The prolificacy of the sows, the amount and body weight of the piglets were determined during the farrow process. Next time the same parameters of the piglets were observed at 15th and 45th day of life to trace their growth rate and body weight by performing individual weighing.

Bio-Mos action in sows and suckling piglets was tested by clinical status appreciation (body temperature, pulse, breathing, general condition, morbidity and mortality, total amount of combined forage, some hematological parameters: red blood cell count, hemoglobin, white blood cell count, WBC, T- and B-lymphocytes).

Blood samples were taken 8 days before farrow, 4-5 and 40 days after it.

RESULTS AND DISCUSSIONS

According to studies performed, Bio-Mos doesn't affect animals' health, opposite this it manifests properties of stimulation of immune response and reduce pathological agents impact which is confirmed by maintaining the major functions (body temperature, pulse, respiration) which in it turn reflects normal general condition and general effect in rising efficacy and reducing morbidity.

Results obtained in our study demonstrate that the sows from both groups farrowed in a 2 to 3 days period. The duration of gestation makes up 192,5±8,55 minutes (Lim 115-285 min) and 143,0±7,33 min (Lim 98.5-195,6 min) in sows included in the I group - control and II group – experimental respectively.

The dates which are given in the Table, 1 attest evolution of the body weight in piglets from both groups: I group - control and II group – experimental. Cases of retention of fetal membranes, stillbirth, and mummification haven't been registered in sows from the II group – experimental.

The total amount of newborn piglets was 242 with average bodyweight of one piglet 1,22±0,09 kg (Lim 1,0-1,3 kg). In I control group there were 232 piglets born, among them 3 dead as a result of asphyxia (dystocia), with average bodyweight 1,11±0,05 kg (Lim 1,0-1,2 kg). Further each piglet was weighted at 15 and 45 day to highlight their speed of growth. It was established that daily amount of growth during 2-15 days was the same, 4,6±0,46 kg and 4,7±0,83 kg in control and experimental groups, respectively. At the end of experiment (45th day) the average bodyweight in control group was 9,7±0,25 kg (Lim 8,3-

10,0 kg), while descendants of sows treated with Bio-Mos was 10,4±0,18 kg (Lim 10,1-10,8 kg). This was 0,7 kg more, at the same time significant differences were recorded ($P_{1,2}$<0,05).

The table 2 presents data regarding the survival of sucking piglets in the period of 1-45 days. During all this time the survival rate in the control group was 89,2% and in the experimental group – 95,5%. These parameters are totally normal relative to pig-breeding complexes. Also it was revealed that the morbidity rate in control group was 14,7%, higher than in experimental one (3,72%). Lethality rate was 10,76% and 4,59%, respectively.

Table 1.

Evolution of piglets' bodyweight in control and experimental groups.

Group	Statistical data	Bodyweight (Kg)		
		1-2 days	15 day	45 day
I Control	M±m Lim	1,11±0,05 1,0-1,2	4,61±0,46 2,1-6,0	9,7±0,25 8,3-10,0
II Experimental	M±m Lim	1,22±0,09 1,0-1,3	4,7±0,83 2,2-7,4	10,4±0,18 10,1-10,8
		$P_{1,2}$>0,05	$P_{1,2}$>0,05	$P_{1,2}$<0,05

Table 2.

Morbidity and mortality rates at suckling piglets.

Group	Num. of sows	Piglets born	Diarrhea (n,%)	Died		Saved (n,%)
				from diarrhea (n,%)	other infections (n,%)	
I Control	25	232	34 14,7	16 6,89	9 3,87	207/89,2
II Experimental	25	242	9 3,72	4 1,7	7 2,89	231/95,5

The positive effect of Bio-Mos on growth and development of piglets is also confirmed by the blood tests, which were taken from sows 8th days before farrow, at 4-5th and 45th day after farrow. They have certainly shown than the haemoglobin rate and the number of erythrocytes are much higher in the experimental group (P<0,05), whose ration was supplemented with Bio-Mos. This proves the positive effect of the product on haemopoiesis.

It should be mentioned that the dynamic of T-cells (key-cells of immune system) in second blood-test (4-5 days after farrow) of sows from the experimental group is represented by considerable growth ($P_{1,2}$<0,02). At the same time the total growth of lymphocytes was revealed from 31,2±1,7% (4-5th day after farrow) to 36,0±0,64% (40th day after farrow)($P_{1,2}$<0,01).

Concerning the dynamic of active T-cells a high growth was revealed with a high level of authenticity $P_{1,2}$<0,05 at 4-5th day and $P_{1,2}$<0,01 at 40th day after farrow at sows from experimental group.

Also the growth of B-cells amount was established from 28,6±1,52% on 5th day after farrow to 33,0±0,75% on 40th day ($P_{1,2}$<0,05).

Based on these studies we can conclude that Bio-Mos product derived from cell wall of yeast Saccharomyces cerevisiae given to sows and piglets in 1-45 day period has a

good impact represented by productivity improvement of lactation and increase of survival rate of piglets from sows in experimental group.

Basic composition of yeast's cell wall includes mannan (30%), glucan (30%), and protein (12,5%).

Nevertheless main action consists of supporting the natural defense system of body preventing invasion, multiplication and affixion of pathogenic bacteria in gastrointestinal tract of piglets during first 3 weeks after birth.

The same positive results were obtained by other authors who watched the effect of Bio-Mos administration at sows during pregnancy and lactation (Peter Spring, 2006).

Bio-Mos is widely used in EU-countries to manipulate with gut organisms and immune answer to reduce pathogenic impact and antibiotic use. General effect is efficiency growth and morbidity decrease (Dawson K et al, 2007; Savage T.F. et a. 1996).

Till June, 2009 Bio-Mos product has been registered by the Drug committee of Republic of Moldova and was recommended to be used in veterinary practice.

CONCLUSIONS

Supplementation of sow's basic ration during 8-10 days before farrow and 45 days after and piglet's ration in first 3 weeks after birth with Bio-Mos (2 kg/ton of mixed fodder) has a positive effect on growing and development of piglets in first 1-45 days of living.

From birth till weaning mortality rate in experimental group was much lower than in control one, 4,59% and 10,76%, respectively.

Body weight of 45-day piglets was 9,7±0,25 kg in control group and 10,4±0,18 kg in experimental one, so the difference was significant ($P_{1,2}$<0,05).

Dynamic of total T-cells ($P_{1,2}$<0,02) and of active lymphocytes subpopulation manifested in a significant growth ($P_{1,2}$<0,01).

BIBLIOGRAPHY

1. Barză H., Popovici A., Sofia, Coman. ț. Intervenții -profilactice în gastroenteropatiile suinelor. Analele Universității Spiru Haret. Seria Medicină Veterinară anul 1, 2007, nr. 1, București, p. 169-179.
2. Karl Dawson. Glicobiologie în sistemele de producție zootehnică: Definirea noilor roluri funcționale ale carbohidraților. Turneu de conferințe pentru Europa, Orientul Mijlociu și Africa de Nord, 2007, Alltech, București, p. 51-66.
3. Pearse Lyons, T. Calea spre viitor. Nutriția și gena. Performanța. Profitabilitate. Turneu de conferințe, Alltech, 2007, p. 13-21.
4. Savage T.F., Cotter P.F., Zakrzewska E.I. The effect of funding mannanoligosaccharide immunoglobulins, plasma IgG and bile IgA, of Wrolsted MW male turkeys. Poultry science, 1996, p.143.
5. Spring, Peter. Glycomics-supars as feed additives. Feed MI the International Journal of Feed, Nutrition and Technology. 2003, volume 11, number 4, p.26-28.
6. Spring, Peter. Creșterea rezistenței antiinfecțioase la nivel intestinal. Rolul glicobiologiei în optimizarea sănătății intestinale. Viitorul promotorilor de creștere. European Lector Tour, 2006, 13 februarie - 5 martie 2006, p.89-102.
7. Баланеску С., Парий Б. Сравнительная эффективность физиологически активных препаратов при лечении поросят больных интоксикационным гастроэнтеритом. Физиологические основы профилактики и терапии незаразных болезней животных. Сб.науч.тр. Кишинев, 1985, с.19-27.

CLINICAL, PARACLINICAL, ECHOGRAPHICAL AND ELECTROCARDIOGRAPHICAL ASPECTS IN ISCHEMIC CARDIOMYOPATHY OF DOG

V.BOGHIAN, Diana Mocanu, S.I.Be șchea-Chiriac,
Luminita Diana Hrițcu, Gh. Solcan
Faculty of Veterinary Medicine Ia și
Aleea M. Sadoveanu, nr. 8
vboghian@yahoo.com

Abstarct
In eight dogs of different ages and breeds diagnosed with cardiac ischemia by clinical examination was found abnormal heart rhythm (cardiac contraction duplication of the first sound), palpitation, dyspnea mixed (inspiratory and expiratory) without physical pulmonary signs, cyanosis and fatigue during effort.
On examination electrocardiography (EKG) showed low amplitude (0.5mV) and appearance of the bicuspid R wave, supra ventricular single extrasystoles and couplets, with hight freqence then sinusal complex, large QRS complex, iregular R-R distance, hight T weave with approximative equal amplitude.
Ultrasound exam evidence interventricular wall thickening and papillary muscles, looking hyperecougenous, and the small volume of the heart relative to body size, discrete muscle hypertrophy and cardiac hypokinesia - shorter fraction (FS) = 23%.
Hemoleucogram performed in dogs with a diagnosis of cardiac ischemia allowed hypochromic anemia, microcytic, aregenerative, with a tendency to leucocytosis with neutrophilia and blood biochemical profile parameters were the mean value were within the reference limits.
Key words: ischemic cardiomyopathy, echocardiography, electrocardiography

Cardiomyopathy ischemia is the result of decreased blood flow to the myocardium. Appears circulatory disorders consecutive coronary arteries. Sudden obstruction of a major branch of blood the heart leads to myocardial infarction with severe consequences on the recovery of cardiac function or sudden death.

Materials and methods

The research was carried out on eight dogs of different age and breed. By clinical examination they were diagnosed with signs of cardiac ischemia.

Later, special investigations were performed by cardiac ultrasound (EcoCord) and electrocardiographic examination (EKG). For ultrasound examination was used EcoCord Vet Aquilla and 5 and 7.5 MHz probes and was used for EKG electrocardiograph examination Delta 1 Plus.

Hemoleucograma was performed with automated hematology analyzer Vet ABC and blood biochemical profile parameters were determined with the spectrophotometer automatically Cormay Accent 200.

Results and discussion

Results of clinical exam, electrocardiography (EKG) and ultrasound (EcoCord) performed in these patients are shown in fig. no. 1, fig. no. 2, fig. no. 3, fig. no. 4, fig. no. 5 and fig. no. 6.

On examination of the heart were detected arrhythmia (duplication of the first sound of heart contraction), palpitation, dyspnea mixed (inspiratory and expiratory) without physical signs of pulmonary mucous membrane cyanosis and fatigue during exercise (fig. no. 1).

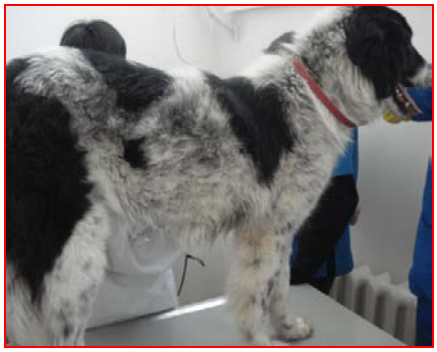

Fig. no. 1. **Ischemic cardiomyophaty** dyspnea, cyanosis

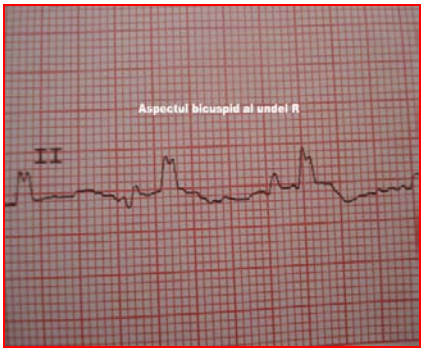

Fig. no. 2. EKG – **Ischemic cardiomyophaty** (bicuspid appearance of R wave and amplitude low - 0.5 mV)

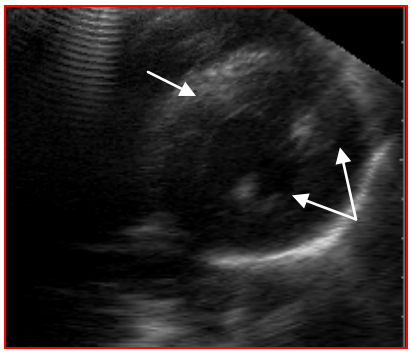

Fig. no.3. Ultrasound – **Ischemic cardiomyophaty** (interventricular wall thickening)

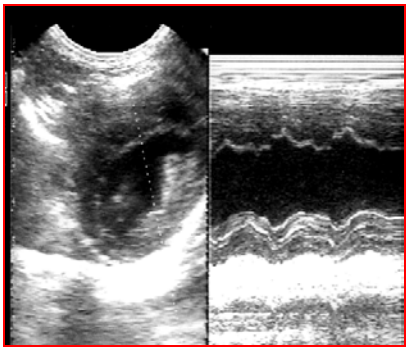

Fig. no. 4. Ultrasound B/M-mode – **Left ventricular myocardial ischemia**

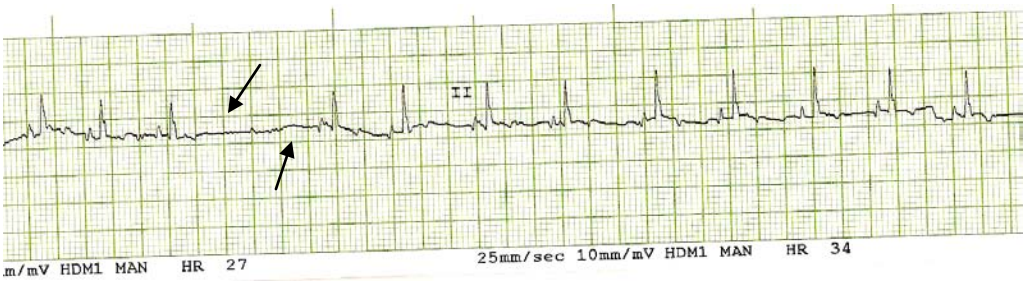

Fig. no. 5

EKG – Ischemic cardiomyophaty
(bicusp aspect of small-amplitude R wave 1.3 mv
P wave amplitude and short duration, areas of asystole)

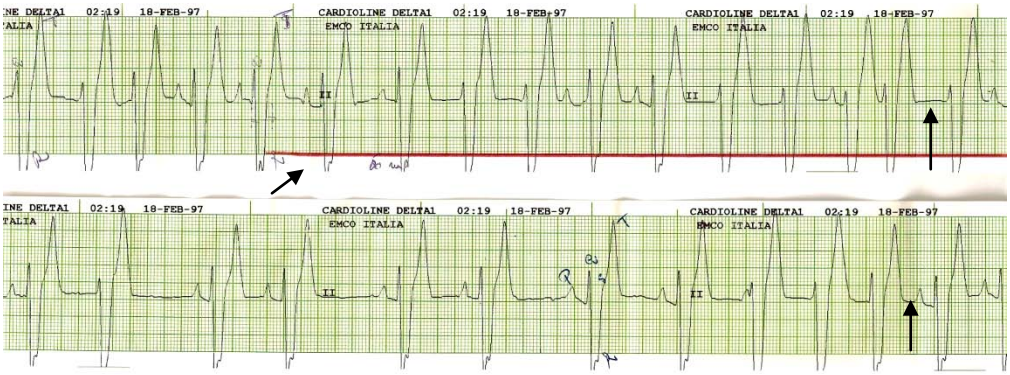

Fig. no. 6

EKG – Ischemic cardiomyophaty
(right branch block: left single supraventricular extrasystoles and couplets,
complexes with greater frequency than sinus)

Ultrasonography examination (B-mode) has highlighted the areas heavily hyperecougenous interventricular septum and papillary muscles which means their thickening (fig. no. 3). Carried ultrasound cross section B/M-mode showed the cardiac apex and left ventricular muscle hiperecogenitatea papillary muscle hypertrophy and hypokinesia with a discreet - with fraction shortening (FS) 23% (fig. no. 4). Shortening fraction is the difference between the diameter in diastole (Dd) and diameter in systole (Ds) reported left ventricular diameter in diastole (Dd) (FS = Dd - Ds / Dd x 100) and has an over 30% physiological. FS is an index of cardiac inotropic function which decreases myocardial ischemia.

EKG exam showed bicuspid appearance of small-amplitude R wave (1.3 mV), P wave amplitude and short duration, areas of asystole and bradycardia (fig. no. 5). Also met and right branch block with left single supraventricular extrasystoles in couplets and, with greater frequency than sinus complexes, and biscupidă negative R wave, wide QRS complexes, the distances RR irregular waves with high amplitude T waves approximately equal to R and the presence of Q wave (fig. no. 6). This indicates a route EKG myocardial ischemia to the right heart.

Hematological examination results are presented in Tables no.1 and no.2.

Table 1

Hemoleucograma in dogs with cardiac ischemia

Parametrul hematologic	Nr. H	Hb	Ht	Nr. L	Leucograma				
					N	E	B	M	L
Unități de măsură	mil/µl	g/dl	%	mii/µl	%	%	%	%	%
Valori medii de referință	5,4-7,8	13,0-19,0	37,0-54,0	6,0-17,0	30-75	62-83	0-3	3-10	12-30
Câini cu ischemie cardiacă (n=8)	**5,5± 2,1**	**10,3± 2,3**	**33,6± 3,2**	**16,8± 2,6**	**83± 1,7**	**64± 1,0**	**1,3± 0,4**	**5,0± 0,6**	**15,0± 1,3**

Table 2

Haematological calculate parameters in dogs with cardiac ischemia

Parametrul hematologic	VEM	HEM	CHEM
Unități de măsură	μ^3	picograme (pg)	g/dl
Valori medii de referin ță	64,0-74,0	22,0-27,0	34,0-36,0
Câini cu ischemie cardiacă (n=8)	**61,1±2,5**	**18,7±2,9**	**30,6±2,6**

From Tables 1 and 2 shows that in dogs with cardiac ischemia were obtained averages lower than average reference values, hemoglobin (Hb=10.3±2.3 g/dl) and hematocrit (Ht=33,6±3.2 %). Under these conditions and calculate the average values of hematological parameters were lower compared with the average mean reference values, namely mean corpuscular volume (MCV=61.1±2.5 µ3), mean erythrocyte hemoglobin (HEM=18.7±2.9 pg) and mean erythrocyte hemoglobin concentration (MCHC=30.6±2.6 g/dl). These values indicate anemia hypochromic, microcytic, aregenerativă.

At the same time, the mean number of red blood cells (NoH=5.5±2.1 million/ml) and leukocytes (No.L=16.8±2.6 thousand/ml) obtained from dogs of cardiac ischemia were included within the reference average values, but with a tendency to leucocytosis (NoL=16.8±2.6 thousand/ml) with neutrophilia (N=83±1.7 %).

Biochemical blood examination results are presented in Table. 3.

Table 3

Blood biochemical profile in dogs with cardiac ischemia

Parametrul biochimic	**TP**	**AST**	**ALT**	**BUN**	**CRTN**	**Ca**	**P**
Unități de măsură	g/dl	UI/L	UI/L	mg/dl	mg/dl	mg/dl	mg/dl
Valori medii de referință	5,5-7,5	8,9-49,0	8,2-57,0	8,8-26	0,5-1,6	8,7-11,8	2,9-6,2
Câini cu ischemie cardiacă (n=8)	**6,4± 0,4**	**25,8± 3,1**	**28,3± 3,0**	**23,2± 1,6**	**1,2± 0,7**	**9,8± 1,1**	**5,0± 0,6**

From Table 3, that, in dogs with cardiac ischemia, blood biochemical profile parameters were the mean value fell within the limits of reference, as follows: aspartate aminotransferase (AST=25.8 ±3.1 IU/L) alanine aminotransferase (ALT=28.3±3.0 IU/L), serum total protein (TP=6.4±0.4 g/dl), blood urea nitrogen (BUN=23.2±1.6 mg/dl), creatinine (CRTN=1.2±0.7 mg/dl), calcium (Ca=9.8±1.1 mg/dl), phosphorus (P=5.0±0.6 mg/dl). This means that the blood biochemical profile is not influenced by cardiac ischemia.

Conclusions

1. On examination of the heart were found duplication of the first sound of contraction in heart palpitations, shortness of breath mixed mucous membrane cyanosis and fatigue during exercise.
2. EcoCord examination revealed intense areas hyperecougenous interventricular septum and the papillary muscles, with hypertrophy and hypokinesia discreet - with fraction shortening (FS) 23%.
3. EKG exam showed bicuspid appearance of small-amplitude R wave (1.3 mV), P wave amplitude and short duration, areas of asystole and bradycardia, right bundle-branch block with left single and supraventricular extrasystoles in couplets, with greater frequency than sinus complexes, the distances RR irregular waves with high amplitude T waves approximately equal to R and Q wave presence.
4. Hemoleucograma in dogs with cardiac ischemia showed a hypochromic anemia, microcytic, aregenerativă: Hb=10.3±2.3 g/dl, Ht=33.6±3.2 %, MCV=61.1±2.5 μ^3, HEM=18.7±2.9 pg and MCHC=30.6±2.6 g/dl, with a tendency to leucocytosis: NoL=16.8±2.6 thousand/ml with neutrophilia: N=83±1.7 %.
5. Biochemical blood profile parameters determined in dogs with cardiac ischemia were the mean value fell within the limits of reference: AST=25.8±3.1 IU/L, ALT=28.3±3.0 IU/L, TP=6.4±0.4 g/dl, BUN=23.2±1.6 mg/dl, CRTN=1.2±0.7 mg/dl, Ca=9.8±1.1 mg/dl, P=5.0±0.6 mg/dl.

Bibliography

1. **Boghian V**. (2007), *Terapeutică medicală veterinară*, Ed. Ion Ionescu de la Brad, Iaşi.
2. **Brăslaşu M.C., A. Popescu** (2001), *Urgenţe cardiovasculare in Medicina Veterinară*, Ed. Adprint, Bucureşti.
3. **Chetboul Valerie, J.L. Pouchelon, Dominique Tessier-Vetzel, Sophie Bureau-Amaglio, S. Blot, J.P. Cotard, M. Simon, D. Tainturier** (2005), *Echographie et Doppler du Chien et du Chat, Atlas en couleur*, Ed. Masson, Paris.
4. **Chetboul Valerie, Lefebvre H.P., Tessier D., Pouchelon J.L.** (2004), *Therapeutique cardiovasculaire du chien et du chat*, Ed. Masson, Paris.
5. **Mocanu Diana, N. Hagiu** (2009), *Diagnosticul ecografic al endocardiozei valvulare la cainii metisi ai raselor de talie mica*, Iaşi, Lucr. Şt. Med. Vet., vol. 52 partea a doua, p. 671.

MILK QUALITY AS AFFECTED BY MILKING MACHINE

Cristina BULBAŞA (PANAITE)[1], Ch. HANZEN[2], L. THERON[2], D. DRUGOCIU[1]
[1]Facultatea de Medicină Veterinară Iaşi,
[2]Facultatea de Medicină Veterinară Liege, Belgia
cri8stina@yahoo.com

Milking machine is the most important device in the dairy farm, because it replaces hand milking, reducing farmers' work. Using milking machine, milk is removed due to pressure differences between the liner and mammary gland (2). If this pressure would be constant, blood and lymph would accumulate in this area of the mammary gland. For this reason, the milking machine was developed so that the removal of the milk is stoped by rhythmic periods, following closing and opening of the liner. Thus, the teat is subjected to a massage, which reduces the risk of congestion at this level (6, 7).
The purpose of this study was based on analysis the milking machine, in order to correlate mechanical milking with milk quality (compared to the number of somatic cells) and mammary gland health. Improper operation of milking machine is the main reason for changing the appearance of the teat after milking: color changes, the appearance of the teat compression ring, edema, teat channel opening, injuries or hyperkeratosis. Extended milking time and milking too fast can have adverse effects on mammary glands' health, facilitating teat lesions or the teat hyperkeratosis, which can allow pathogen to penetrate (5).

Key words: milking machine, mastitis, somatic cells, milk quality

MATERIALS AND METHODS

The study sites are located in Wallonia, South of Belgium. Data field was collected in 315 dairy farms, from January 2006 to December 2007. Data consist in a total number of 15767 cows from all the 315 farms, with an average of 50 milking cows per farm. The age average for the cows in this study was 4 years. Calving interval differed, from 311 to 557 days, with an average of 417 days.

Data was collected through milk meters and reporting softwares. Milk quota had different values, from 173 liters to 1380000 liters, with an average of 365845 liters. Total number of somatic cells registered also variable values, with an average for these 2 years of 284 cells. Official statistical measurements of the milking machine parameters were analysed and processed by AWE (Association Wallonne de l'Elevage), conforming to ISO standards. All those information were then received by the Faculty of Veterinary Medicine, Liege, in term of a month from the farm visit. All the data was collected, organized and analyzed. Logistic regression (SAS) was used at the Faculty of Veterinary Medicine, Liege to investigate the relationship between 40 variables (about milk, milking practice, milking system) and somatic cells.

RESULTS AND DISCUSSIONS

Our goal was to identify milking parameters in order to correlate them with mastitis occurrence in 315 dairy farms (Table 1).

Table 1. Milking parameter values of belgium dairy farms

Milking parameter	No. dairy farms	% conform	Average	Minimum	Maximum	Standard deviation
Normal aspect of the liner	314	92				
Frequency of replacing the liner (months)	305		15	6	72	8.3
Air entering into the cup	315	93				
% wet teats	288	83	0.2	0%	80%	0.2
% teat hyperkeratosis	314	82	18	0%	66.70%	22.5
Desinfection after milking	314	32				

Liner is the only piece of the milking machine that comes into direct contact with the teat, so it can become a germ vector if the hygiene is not appropiate. Normal aspect of the liner was observed in 92% of farms.

In this 315 dairy farms, 275 farms used rubber lines and 40 farms used silicone lines. The line has a limited useful life of six month, but the average in this belgium farms was 15 months. This can explain the occurrence of high somatic cells ($p>0.0054$) in milk. Liner must be designed to provide an optimum fit on the teat, in order to minimize liner slips and cluster fall off, but 7% of this farms showed air entering into the cup.

Most of the research activities indicate that washing the cluster after milking influence the number of somatic cells ($0.05<p<0.10$). This is the single most effective procedure to prevent the cow to cow spread of contagious mastitis organisms.

Milking time in this farms is related to the number of somatic cells in milk (linear = 0.0197; $p>0.0002$). Overmilking can correlate to the occurrence of wet teats (linear = 0.0028; $p> 0.0069$) and to teat end hyperkeratosis (linear=0.0021; $p>0.0011$). When teat end hyperkeratosis occures, the number of somatic cells increases in milk (Fig. 1).

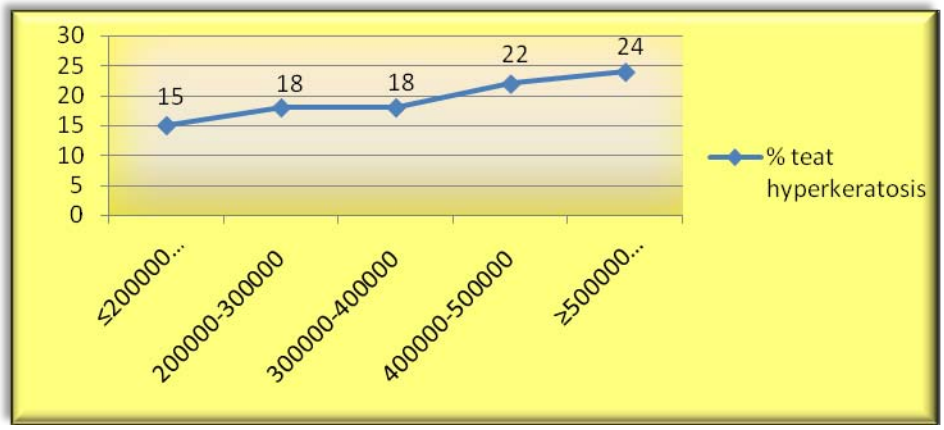

Fig. 1. Papillary duct hyperkeratosis influence on somatic cell count

Farms that had high number of somatic cells in milk (≥500000/ml) had also 24% of the cows with teat end hyperkeratosis. It can be seen from the results included in Fig. 1 that the higher the number of somatic cells is, the greater is the incidence of teat hyperkeratosis.

CONCLUSIONS

1. Many pathogens multiply in teat sores and are spread during milking, either during udder preparation or on hands, so the hygiene of the milking unit is required. Washing the cluster after milking influence the number of somatic cells ($0.05<p<0.10$).
2. Frequency of replacing the liner is very important for milk quality ($p>0.0054$). When renewing liners, all four liners within a cluster have to be changed to maintain similar milking characteristics between the four teatcups.
3. Penetration with germ of the teat duct can occur during milking, by using inappropriate designed milking equipment which gives reverse flow of milk during milking or air entering.
4. There is also a relationship between the milking time and the number of somatic cells in milk (linear = 0.0197; $p>0.0002$). Overmilking may promote the occurrence of subclinical mastitis in cows, by increasing the incidence of hyperkeratosis (linear = 0.0021; $p>0.0011$) and also to wet teats (linear = 0.0028; $p> 0.0069$).

BIBLIOGRAPHY

1. Don Calhoun, 2001. Efficient Milking. DeLaval Holding.
2. Drugociu D., 2009 - Bolile obstetrical -ginecologice la animale, ediţia a II-a, editura ”Ion Ionescu De La Brad” Iaşi.
3. Graeme Mein, Douglas Reinemann, Norman Schuring, Ian Ohnstad, 2004 - Milking Machines and Mastitis Risk: A Storm in a Teatcup. National Mastitis Council.
4. Hanzen, C., 2007 - Quand suspecter la machine à traire lors de mammites. L'Hebdo vétérinaire, vol. 206, p. 24-26.
5. Hillerton, J.E., Pankey, J.W. & Pankey, P. 2002- Effect of over-milking on teat condition. J. Dairy Res. 69: 81-84.
6. Mein, G.A., E. O'Callaghan, D.J. Reinemann, and I. Ohnstad. 2003 - Pulsators and liners: where the rubber meets the teat. Proc. IDF Centenary Seminar, Belgium, "100 years with liners and pulsators in machine milking".

OBSERVATIONS REGARDING THE CLINICAL ASPECTS AND COMPLICATIONS OF ANTERIOR UVEITIS IN DOGS AND CATS

Ioana BURCOVEANU, I. BURTAN, Roxana TOPALĂ, L.C. BURTAN, M. FÂNTÂNARIU, S. CIOBANU
Facultatea de Medicină Veterinară, aleea M. Sadoveanu, nr.8, Iaşi
ioana.burcoveanu@gmail.com

A farely large part of ophthalmological pathology in small animals is represented by uveitis, which are painfull diseases with serious consequences, being able to sometimes lead to blindness.
This paper resumes the clinical signs and complications of canine and feline anterior uveitis, exemplifying this clinical diversity in images.
Key words: anterior uvea, aetiology, simptoms, complications, carnivores

The inflammation of the uveal tract is called **uveitis.** Anatomically speaking, we can classify it in anterior, posterior uveitis or panuveitis. **Anterior uveitis**, the inflammation of the iris and ciliary body, includes **iritis** (inflammation of the iris), **iridocyclitis** (inflammation of the iris and ciliary body) and **cyclitis** (inflammation of the ciliary body). **Posterior uveitis** defines the inflammation of the choroid (**choroiditis**). **Panuveitis** represents the inflammation of the entire uveal tract. (*1, 2, 3, 4, 7, 8, 9, 10, 13, 15*)

Intraocular inflammation appears after the blood-ocular barriers have been damaged, and also after the intervention of the inflammatory factors and immune reactions. (*7, 8, 10, 11, 13, 14*)

Uveitis can be classified into many categories, according to: anatomical location: anterior or posterior uveitis; evolution: acute or chronic uveitis; type of inflammation: suppurative or non-suppurative uveitis; aetiology: traumatic, secondary (when other structures of the eye are inflammed) or symptomatic (in systemic diseases, such as pyometra), immune-mediated or neoplastic (limphosarcoma, acute limphoblastic leukemia, uveal metastasis of a nailbed melanoma in a dog). (*4, 5, 6, 7, 9, 12, 13, 14, 15*).

General signs of ocular disconfort are pain (may manifest as anorexia or depression), blepharospasm, photophobia, epiphora, chemosis. (1, 2, 7, 9, 10).

Clinical signs specific for uveitis are as follows: episcleral vascular injection or ciliary flush, corneal edema, hypopyon or hyphema, presence of inflammatory cells in the anterior chamber or adherent to the corneal endothelium, forming the keratic precipitates, miosis, rubeosis iridis, anterior or posterior synechia, lowered intraocular pressure. (4, 6, 7, 8, 9, 10, 11, 13, 14, 15)

The present paper presents the results obtained regarding the clinical aspects and complications (sequelae) of anterior uveitis in dogs and cats.

MATERIAL AND METHOD

Between 2007-2011, research has been made on the cases presented to the Surgical Clinic at the Faculty of Veterinary Medicine in Iaşi. From the total number of

domestic carnivores brought in for consultations, we focused on those presenting an ophthalmological problem, especially those with uveal tract pathology. A relevant and thorough history, completed by an orderly and extended ocular examination, gave a correct diagnosis and the possibility of successful therapeutical results.

RESULTS AND DISCUSSIONS

Traumatic uveitis is usually seen in one eye, and may be caused by blunt or sharp trauma to the globe (cat claw scratches, foreign bodies, accidents), or may occur after intraocular surgical procedures. Simptoms of traumatic uveitis are hyphema, iris prolapse or staphyloma (the uveal tissue protrudes from inside after a penetrating corneal injury). Infections like pyometra, tooth abcess, prostatitis can cause uveitis, which reveals the importance of a thorough clinical examination. Other causes of uveitis are: bacteria (Leptospira spp., Bartonella spp., tuberculosis, Brucella spp.), viruses (Canine adenovirus type 1 and 2, Canine distemper virus, Coronavirus – feline infectious peritonitis, Feline leukemia virus, Feline immunodeficiency virus), metabolic diseases (diabetes mellitus, systemic hypertension, hyperlipidemia), immune-mediated (cataracts – lens induced uveitis, lens trauma – phacoclastic uveitis, uveodermatologic syndrome - Vogt-Koyanagi-Harada like syndrome). Nevertheless, 70 % of canine uveitis and 60-70% of feline uveitis rest idiopathic.

Among the variety of *clinical signs* characteristic of uveal tissue inflammation, we observed **ciliary flush** and **episcleral vascular injection**, **corneal oedema** (fig. 2, 8), alterations of transparency of the aqueous humor, with formation of a white layer of inflammatory cells, called **hyopyon** (fig. 4), or red blood cells, called **hyphema** (fig. 3). Inflammatory cells can adhere to the corneal posterior epithelium, forming **keratic precipitates** (fig. 1). They appear to be small and scattered in feline infectious peritonitis, or large and yellow (mutton fat keratic precipitates) in granulomatous diseases.

Miosis may be due to iridal edema or spasm of the iridial sphincter muscle (fig. 2, 4), and the iris appears modified by edema and congestion of blood vesseles – **rubeosis iridis** (fig. 1, 2, 3), with the anterior face irregularly shaped, with a pale colour or it can appear flattened and hyperpigmented, in facolitic uveitis (fig. 5, 6). As the inflammation subsides, synechia may form, causing an irregularly shaped pupil. **Anterior synechia** appears after the iris adheres to the corneal endothelium, **posterior synechia** occur when fibrinous adhesions form between the lens and the iris (when the entire circumference of the pupil is adherent to the lens, aqueous flow is prevented and iris bombe occurs).

Intraocular pressure is usually lowered in uveitis - **hypotony**, due to inflammation of the ciliary body, which produces less aqueous humor, and also to endogenous prostaglandins, which eases the drainage at the irido-corneal angle.

Among the *sequelae of anterior uveitis*, we can see anterior or posterior synechia. Posterior synechia appear after fibrinous inflammation developed, with fibrovascular organization occuring later. Thus, the iris adheres to the anterior capsule of the lens. If synechia form all around the iris, iris bombe occurs, with accumulation of the aqueous humor and secondary glaucoma. An irregularly shaped pupil – **dyscoria** is frequently caused by synechia (fig. 7).

Cataract (opacity of the lens) appears frequently after uveitis, especially in cats (fig. 8). It is supposed to be caused by alteration in composition of the aqueous humor, from which the lens takes its nutrients. In cats, uveitis is the main cause of cataract and lens

luxation, but not the same happens in dogs. When an animal is presented with signs of uveitis and cataract, we must determine which is the primary disease (the cataract caused the uveitis or the uveitis caused the cataract?).

Glaucoma is due to an obstacle in drainage of the aqueous humor, at the irido-corneal angle or between the iris and the lens. If the intraocular pressure is normal or elevated in the presence of acute iridal inflammation, then the irido-corneal angle can be obstructed by inflammatory cells, fibrovascular membranes, or by formation of anterior or posterior synechia. Cataract with secondary uveitis, complicated with a glaucoma is a well-known pathology in dogs.

Iris atrophy appears after anterior uveitis. The stroma is replaced by fibrous tissue. Defects may appear in the iris. Atrophy of the ciliary body causes hypotony. In severe cases, the entire globe may shrink, the condition being called *phtisis bulbi.*

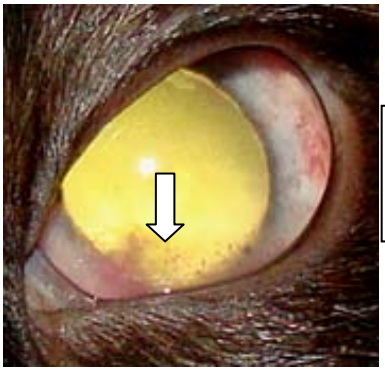

Fig.1 – 11 year old Siamese female cat. Symptomatic uveitis (pyometra) (OS).
Mutton fat keratic precipitates. Rubeosis iridis, with alterations of iris color (discolored). (*original*)

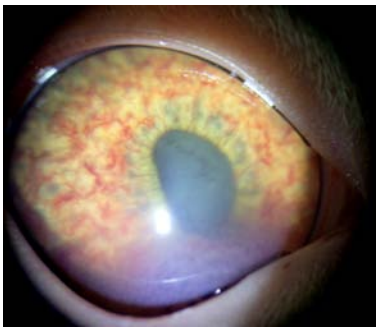

Fig. 2 – 3 year old European female cat. Idiopathic uveitis (OD). Miosis. Ventral corneal edema. Keratic precipitates. Iris congestion – rubeosis iridis. (*original*)

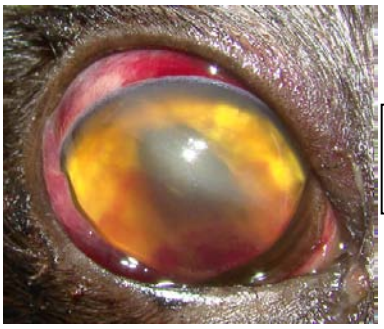

Fig. 3 – 9 year old European male cat. Traumatic uveitis (OD) Conjunctival haemorrhage. Hyphema. Congestion of the iris. (*original*)

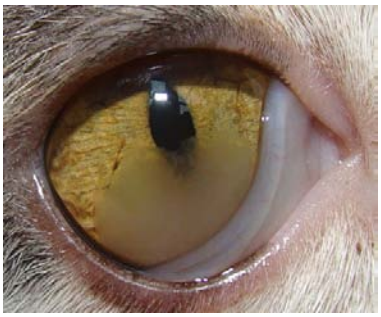

Fig. 4 - 8 month old male cat. Idiopathic uveitis (OD).
Miosis. Hypopyon. (*original*)

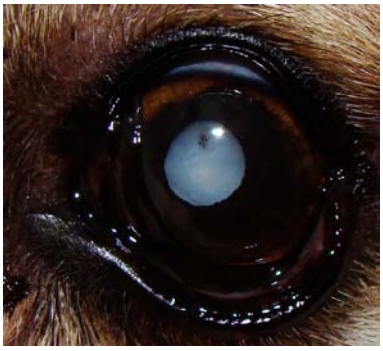

Fig. 5 – 5 year old Labrador retriever male dog.
Complications of a phacolitic uveitis (unilateral traumatic uveitis – OS): hyperpigmentation of the iris, presence of pigment on the anterior capsule of the lens, increase of the depth of the anterior chamber (*original*)

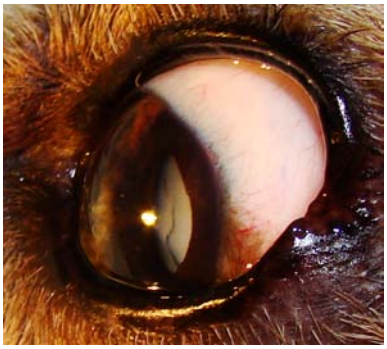

Fig. 6 – Same case as in fig. 5. Lateral view.
hyperpigmentation of the iris, presence of pigment on the anterior capsule of the lens, increase of the depth of the anterior chamber. (*original*)

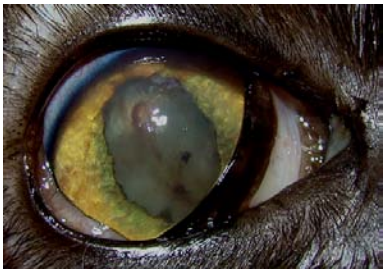

Fig. 7 – Same case as in fig. 3. Discorya (OD). (*original*)

Fig. 8 – 6 year old female Siamese cat. Complications of an anterior idiopathic uveitis (OU).
Diffuse corneal edema. Discoloration of the iris. Bilateral mature cataract (*original*)

CONCLUSIONS

1. General signs of ocular disconfort are pain, blepharospasm, photophobia, epiphora, chemosis.
2. Clinical signs specific for uveitis are as follows: episcleral vascular injection or ciliary flush, corneal edema, hypopyon or hyphema, miosis, keratic precipitates, lowered intraocular pressure.
3. Keratic precipitates appear to be small and scattered in feline infectious peritonitis, or large and yellow (*mutton fat* keratic precipitates) in granulomatous diseases.
4. Among the *sequelae of anterior uveitis* we can see anterior and posterior synechia, cataract, glaucoma, iris atrophy.
5. In cats, uveitis is the main cause of cataract and lens luxation, but not the same happens in dogs.
6. Cataract may be caused by alteration in composition of the aqueous humor, from which the lens takes its nutrients.
7. Glaucoma is due to an obstacle in drainage of the aqueous humor, at the irido-corneal angle or between the iris and the lens.
8. Iris atrophy appears after anterior uveitis, when the stroma is replaced by fibrous tissue. In severe cases, the entire globe may shrink, the condition being called *phtisis bulbi.*

BIBLIOGRAPHY

1. **Barnett K.C., Sansom J., Heinrich C., 2002** - *Canine Ophthalmology, an atlas and text*, WB Saunders, Philadelphia, 127-146;
2. **Barnett K.C., Crispin M. Sheila, 2005** – *Feline Ophthalmology*, Saunders Elsevier Ltd;
3. **Bouhanna L., 2005-** *Vadémecum d'ophtalmologie vétérinaire*; 2e edition, Ed. Med'Com, France, 195-196;
4. **Burtan I., 2000**- *Chirurgie veterinară regională*, ed. Ion Ionescu de la Brad, Iaşi, 149-187;
5. **Déan E., 2004** - *Traumatismes de l'oeil chez le chien et le chat,* EMC-Vétérinaire 1, pg. 199-229;
6. **Esson D., Fahrer S. Christin, Zarfoss K. Mitzi, Dubielzig R.R., 2007** - *Suspected uveal metastasis of a nail bed melanoma in a dog- case report*, Veterinary Ophthalmology 10, 4, 262-266, available on-line at http://onlinelibrary.wiley.com;
7. **Gelatt K.N., 2007** – *Veterinary Ophthalmolog, 2 volume set*, Blackwell Publishing, Iowa;
8. **Hendrix V.H. Diane, 2008** – *Diseases and Surgery of the Canine Anterior Uvea chapter*, in Gelatt K.N. Essentials of Veterinary Ophthalmology, 2nd edition, Blackwell Publishing, Iowa;
9. **Ionaşcu Iuliana, Miclăuş I., 2009** - Cap. 87 - *Oftalmologie veterinară*, din Tratat de Medicină Veterinară, vol V, coordonator Constantin N., ed. Tehnică, Bucureşti
10. **Maggs D., Miller P., Ofri R., 2008** – *Slatter's Fundamentals of Veterinary Medicine,* 4th edition, Saunders Elsevier, Missouri

11. **Maggs D., 2009** – *Feline uveitis, an "intraocular lymphadenopathy"*, Journal of Feline Medicine and Surgery, 11, 167-182
12. **Massa L. Kathleen, Gilger C. B., Miller L. Tammy, Davidson G. M., 2002** – *Causes of uveitis in dogs: 102 cases (1989-2000)*, Veterinary Ophthalmology, 5, 2, 93-98, available on-line at http://onlinelibrary.wiley.com;
13. **Roze M., 1997**- *Les uveites*, Pratique Medicale et Chirurgicale de l'Animal de Compagnie, 32 (supplement): 129-147;
14. **Wassik B., Adkins Elizabeth, 2010** – *Canine anterior uveitis*, Compendium: Continuing Education for Veterinarians, available online at www.vetlearn.com;
15. **Simon M., 1993** – *Affections de l'uvee des carnivores*, Encyclopedie Veterinaire, Paris.

EPIDEMIOLOGY OF DICROCELIOSIS AND CHANGES IN SOME CHEMICAL INDICES OF MUSCULAR TISSUE AND LIVER OF CATTLE IN THE REPUBLIC OF MOLDOVA

D. Erhan[1] , Ş. Rusu[1], P. Pavaliuc[2], O. Chihai[1], Maria Zamornea[1], V. Buza[1], T. Anghel[1], G. Cilipic[1]
[1]Institute of Zoology of Academy of Sciences of Moldova
[2] The Institute of Physiology and Sanocreatology
1, Academiei str., MD-2028, Chisinau, Republic of Moldova,
E-mail: dumitruerhan@yahoo.com

Abstract
The study of the parasitological invasions with Dicrocoelium lanceolatum in about 8000 cattle have been carried out in different time periods (1981-1982, 2001-2002) in private farms, family household and specialized in milk and beef production farming sectors with different maintenance technologies from the Republic of Moldova. The results of the parasitological research carried out in 1981-1982 have revealed the 22,3-33,5% incidence of dicroceliosis in adult cattle from farming sectors, 42,6-51,4% incidence in farms and 63,5-68,3% in cattle from family households; the incidence figures related to bull-calves population (as of 23-25 months) were 10,5-17,2%, 23,5-30,4% and 35,6-44,7% correspondingly.
During 2001-2002 (a period just after the crucial changes happen in the zoo technical sector) the carried investigations show that 78,6% of adult cattle and 74,5% of bull-calves populations have been found infested. Comparatively to situation researched in 1981-1982, the level of invasion has increased by 31,0% in adult cattle and by 47,1% in bull-calves that demonstrates the existance of various locus of parasitary agents (definitive and complimentary hosts) as a result of the absence or irregular dehelminthizations.
It was determined that the infested with dicroceliosis cattle produce less meat and eatable by-products. Moreover, the content of some vitamins (A, E, B_1, B_2, C), micro-, macroelements (Ca, Mg, Na, K, Fe, P), chemical indicies (humidity, dry solid matter, proteins, fat, ashes) in muscular and liver tussues proved to be considerably changed influencing considerably the animal products' nutrition value.
Key words: extensivity and intensivity of dicroceliosis, vitamins, micro-, macroelements, nutrition value.

INTRODUCTION

During the last years there is an evident increase of factors that influence the infestation of domestic and wild animals with endo- and ectoparasites. It should be noted that the anthropogenic factor is the dominant one in this process. It manifests itself via radical changes that happen in the past and continuously taking part in the present time in the veterinary medicine field as well as in the agriculture and zootechology. The majority of livestock breeding complexes and big livestock farms have been disestablished followed by the considerable increase of number of animals kept in the private sector. As soon as the lands became the property of the farmers the biggest part of the gardens, vine lands, forest belts etc. have been disturbed. Consequently, the way of soil dressing and protection also have been changed. The anthropogenic as well as the natural factors have influenced directly or indirectly the specific and numeric composition of the vertebrate animal fauna

that serves as the main hosts for non - vertebrate, temporal or permanent, endo- and ectoparasites belonging to different groups and various biotopes of Moldova [3,4,6].

The limited spaces for pasturage of animals of different species and age probably also have contributed to prosperity of the parasite fauna [2].

E.Bagut and C.Catoi [1] while researching histo-pathological characters in sheep and goats infested with fasciolasis, dicrocelium and echinoccoccus in form of mono- and poliinvasions have revealed the following irregularities: hemorrhagic-necrotic acute or non/acute hepatitis, chronic traumatic hepatitis, perihepatitis, biliary dyskinesia, steatosys and hepaticas cirrhosis.

The aim of the scientific research was to determinate in dynamics the level of invasion with dicrocelium of the cattle related to different applied maintenance techniques as well as their impact on some chemical indexes, content of vitamins (A, E, B_1, B_2, C), micro- and macroelements (Ca, Mg, Na, K, Fe, P) of the cattle muscular tissue and liver.

MATERIAL AND METHODS

The parasitological research have been carried out in about 8 thousand of cattle of different age purchased from the private and public households with various maintenance technologies and from different regions of Moldova and slaughtered in the meat processing plant during 1981-2002.

The content of micro- and macroelements have been determined by use of the photoelectric colorimetry methods, and the composition of the vitamins have been defined using the spectrophotometric methods. In view of this 30 probes of muscular tissue as well as liver have been collected from healthy cattle and cattle infested with dicrocelium.

RESULTS AND DISCUSSIONS

The reforms that took part in the animal production field of Republic of Moldova in the last 15-20 years have lead to quantitative changes in the population of livestock: this have been reduced two times and a half as many compared to 1990. The ratio of the animals from the private sector vis-à-vis the public one has been continuously in increase. Given that in 1990 the number of cattle in the private sector accounted up to 16,2% of the total number of the livestock population then already in 2008 this was increased up to 93,1%. There were described about 1200 species of parasites in the Republic of Moldova and above 100 among them are pathogenic for the animals. Due to the fact that the animal fauna of Republic of Moldova is apparently reach and the climate facilitates development of the various species of the parasites especially of helminthes, the study of such is essential for the monitoring of the sanitary, veterinary and epidemiological situation.

Thus, in order to organize the complex program of prophylaxis measures as well as treatment of parasitic invasions in animals its necessary, besides knowledge on etiology, pathogenesis, clinical status and treatment measures, to have data on the level of spreading of the various species of parasites related to animal age, its maintenance technologies, seasons etc. In this regard, the parasitological study carried out in dynamics seems to be important and have additional value.

The study of the dicrocelium spreading in cattle have been carried out in different periods (1981-1982, 2001-2002) and regions of the Republic, in the specialized farm households, private sector and diary and steers farms.

The results of the parasitological research obtained in 1981-1982 proves that the most often the dicrocelium is diagnostic ted in animals from family households (63,5% in North region, 66,8% in Central part and 68,3% on the South) and less frequently is observed in the animals from the farms (22,3% in the North region, 30,6% in Central part and 33,5% in the South part of the Republic). In steers (aged 23-25 months) dicrocelium have been identified more frequently in the households from the South (44,7% in private sector, 28,8% in farms and 17,2% in farm complexes) and less frequently – in households of the Nothern part of Republic (35,6% in private sector, 23,5% in farms and 10,5% in complexes) (See Table 1).

Although the adult cattle and steers from farms and private sector of the North were correspondingly 1,9-2,9 and 2,2-3,4 , in the Center - from 1,7-2,2 and 2,4-3,4 and in the South 1,5-2,0 and 1,7-2,6 times more frequently infested with dicrocellium comparatively to those from the farm complexes.

The high level of infestation with dicrocellium of the adult cattle and steers from complexes was probably caused by the selection of young cattle from all these geographical zones that facilitated the extensively of animals invasion.

It is also presents the interest from the comparative point of view the parasitological studies of adult (4-6 years) and steers (23-25 months) infestation picture in 2001-2002 reported to restructures taken place in zootechnical sector followed by the re-dislocation of animals from complexes and farms to private sector.

The research conducted 2 years later related to adult cattle (4-6 y.o.) and steers (23-25 months) purchased from different localities of Republic and slaughtered in the meat-processing plant from Chişinău city shows that the reorganizations that took part in the zoo technical sector have lead to invasion of the adult cattle with dicrocelium in 78,6% adult cattle and in 74,5% cases of researched steers.

The obtained results reveal that the increased extensivity of invasion with dicrocellium in 2001-2002 comparatively to 1981-1982: the level of invasion of the adult cattle have increased in average by 31,0% and 47,1% that actually demonstrates the existence of the various focuses of parasitological agents (definitive and complementary hosts), as well as the absence or irregular measures for parasite control.

Table 1.

The level of invasion of adult (4-6 years) cattle and steers (23 – 25 months) with dicrocellium from different zones of Moldova and different maintenance technologies in 1981-1982

Animals age	Zones								
	North			Center			South		
	Compexes, %	Farms, %	Private sector, %	Compexes, %	Farms, %	Private sector, %	Compexes, %	Farms, %	Private sector, %
Adult cattle	22,3	42,6	63,5	30,6	51,4	66,8	33,5	48,9	68,3
Steers	10,5	23,5	35,6	12,6	30,4	42,8	17,2	28,8	44,7

While performing the sanitary and veterinary expertise of carcasses and organs of the animal sit is recommended to determ (in regard to the intensivity of invasion with dicrocelium) three levels of infestation: low, medium and high.

At the low level of infestation the liver does not expose some visible pathological changes either on surface nor in section. Due to the small dimensions and transparent status of dicrocelium it is hardly observable on the phone of the liver; that is why as to identify the dicrocelium it is recommended to sweep with blunt part of the knife on the obliquely side of the liver. Usually this level of infestation is characteristic for young cattle aged 1-2 years (20-25%).

At the medium level of infestation the liver is slightly enlarged, in section the paries of the biliary tracts are visibly enlarged. Dicrocelium masses are elimined from tracts along with yellow-brown liquid. The morpho-patological changes in lever are especially observed in the surroundings of biliary tracts with 2-3 cm diameter yet the parenchyma in other parts does not reveal any changes. Usually the most affected are animals aged 2-3 years (30-35%).

The high level of infestation is characterized by the enlarged liver up to 1,5-2 times; some white winding formations are observed in the capsule, the paries of the biliary tracts are dilated. The parenchyma in section is filled in with connective tissue and a yellow-brown liquid containing dicrocelium is eliminated from the tracts. The high level of infestation is observed in animals aged 4-5 years and upwards (15-20%).

Presently the facilities processing meat in the Republic purchase the cattle with low and medium levels of invasion. In this case, usually the low level of infestation is observed in young cattle and the high level is characteristic for adult animals.

The spread of dicrocelium preponderates in the whole structure of the parasite diseases in animals and causes the worsening of quality of animal products [5]. There were determined the content of the vitamins A, E, B_1, B_2, C and micro- and macroelements - Ca, Mg, Na, K, Fe, P as to establish the nutrition value of muscular tissue and liver in cattle infested with dicrocelium (Table 2 and 3).

Table 2

The content of vitamins in liver and muscular tissue in cattle infested with dicrocelium *(mkg/g)*

The researched material in cattle	A	E	B_1	B_2	C
Liver:					
- healthy	0,14	0,35	1,16	1,23	24,5
- infested	0,05	0,11	**0,63**	0,86	12,6
Muscular tissue:					
- healthy	0,11	0,20	1,17	1,47	16,8
- infested	0,04	0,10	0,83	0,84	9,4

It was established that the content of the Vitamine A in the liver of infested with dicrocelium cattle have decreased 2,8 times, Vitamine E – 3,18 times B_1 and Vitamine B_2 - 1,84 and 1,43 times correspondingly, Vitamine C - 1,94 times, ferrrum - 1,89 times, phosphorus- 2,08 times, calcium – 1,04 times, and the concentration of Mg, Na and K have increased by 1,15, 4,81 and 1,48 times correspondingly as compared to the non-infested animals.

Table 3

The content of micro- and macroelements in liver and muscular tissue in cattle infested with dicrocelium *(g/100 g of mineral substance)*

The researched material in cattle	Calcium	Magne sium	Natrium	Kalium	Ferrum, (mg/100g)	Phosphorum, (%)
Liver:						
- healthy	1,17	1,21	1,30	9,38	752,50	2,50
- infested	1,13	1,39	6,25	13,88	397,50	1,20
Muscular tissue:						
- healthy	1,23	1,12	1,18	10,75	86,00	1,05
- infested	0,68	1,70	1,65	16,25	275,00	1,30

The content study of Vitamine A level in the meat provides that is was 2,75 times lower, of Vitamine E – 2,0 times, B_1 - 1,41, B_2 - 1,75, Vitamine C -1,79 and Calcium -1,81 times lower levels while the concentration of phosphorus, magnesium, natrium, calium and ferrum was higher - 1,24, 1,52, 1,40, 1,51 and 3,20 times correspondingly in the healthy animals.

The dicrocelium in cattle contributes to decrease of the production of the meat and comestible specialty meats (Table 4).

The obtained results show that the production of meat as of young cattle infested with dicrocelium was decreased by 10,9%, production of fat – by 8,9%, and of the specialty meats such as liver – by 72,7%, lights – by 100%, and in adult cattle by 20,6%, 15,8%, 84,6% and 100% correspondingly.

Table 4

The production of meat and comestible specialty meats of the first category as of the cattle infested with dicrocelium

Age category	Lot	Production level calculated at slaughtering, kg			
		meat	fat	lever	lights
Young cattle	- healthy	279,3	7,9	3,3	2,3
	- infested	248,8	7,2	0,9	-
Adult cattle	- healthy	222,5	9,5	3,9	3,1
	- infested	176,6	8,0	0,6	-

The aim of the research was to establish the content of some chemical indices in the muscular tissue and liver related to the intensivity of invasion with dicrocelium (Table 5). The obtained results show that in the cattle with low level of infestation with dicrocelium the humidity level of muscular tissue is increased by 1,1%, medium – by 4,2%, and 5,2% in cattle with high level of infestation, and in liver – by 2,9%, 5,7% and 9,5% correspondingly.

Table 5

The chemical indexes of muscular tissue and lever in infested with dicrocelium cattle

The researched material in cattle	Intensity of invasion	Humidity	Dry substance	Proteins	Lipids	Mineral substances
Muscular tissue	healthy	73,4±0,10	26,6±0,12	21,7±0,15	3,7±0,10	1,2±0,06
	small	74,2±0,10	25,8±0,1	20,1±0,10	2,7±0,10	1,0±0,10
	medium	76,5±0,10	23,5±0,06	20,0±0,12	2,5±0,10	1,0±0,0
	high	77,2±0,15	22,8±0,15	20,0±0,15	1,8±0,10	0,9±0,06
Liver	healthy	69,8±0,12	30,2±0,15	23,3±0,12	4,4±0,23	1,4±0,10
	small	71,8±0,10	28,1±0,10	21,8±0,12	4,1±0,10	1,3±0,06
	medium	73,8±0,06	26,2±0,10	20,9±0,10	3,1±0,06	1,2±0,10
	high	76,4±0,10	23,3±0,15	19,1±0,10	2,0±0,06	1,0±0,06

The cattle with low level of infestation intensity the content of the dry substance in the muscular tissue have been decreased by 3,0%, medium – by 11,7%, high – by 14,3%, and in lever -by 7,0%, 13,3% and 22,9% correspondingly.

The quantity of proteins in muscular tissues of cattle with low level of infestation intensity have been decreased by 7,4%, medium and high – by 7,8% and in lever- by 6,4%, 10,3% and 18,0% correspondingly.

The cattle with low intensity of invasion the content of fats in the muscular tissue have been decreased by 27,0%, with medium – cu 32,4% and with high level – by 51,4%, and in liver – by 6,8%, 29,5% and 54,5% correspondingly.

The cattle with low and medium level of infestation the quantity of mineral substances in the muscular tissue have been decreased by 16,7%, and in those with high level of infestation have been decreased by 25%. This index related to the quantity of mineral substances in liver of cattle with low level of intensity of invasion have been lower by 7,1%, with medium level –by 14,3%, and in those with high intensity invasion – by 28,6%.

During the sanitary and veterinary examination of the carcasses and organs of animals while identifying the organs affected with different parasites agents that could not be directly transmitted to the humans these are partially or totally eliminated, and those non-affected as well as the healthy ones are processed for further consumption without any restriction.

Thus, the changes that took place in the zootechnical sector, redislocation of animals from complexes and farms in individual sector and their pasturing on the limited spaces common for various species of animals and of different age have essentially contributed to increase of dicrocellium invasion extensivity.

Thus, the dicrocelium proved to be a frequent parasite agent in cattle of different age and as of different maintenance technology, it provokes significant decrease in gaining weight, modification in chemical composition of the muscular tissue and comestible specialty meats and reduces its nutrition value. Thence, it is necessary to improve the system of evaluation of animals status, meat and comestible specialty meats originated from the infested animals.

CONCLUSIONS

1. There were established the high level of infestation of cattle with *Dicrocelium* - 78,6% in adult cattle and 74,5% in steers (23-25 months).

2. The high level of infestation with *Dicrocelium* is most probably explained by continuous contact of cattle with definitive hosts, limited space for pasturing of animals of different species and age, lack or irregular measures for parasite control.

3. In cattle infested with *Dicrocelium* the content of vitamins (A, E, B_1, B_2, C), micro- and macroelements (Ca, Mg, Na, K, Fe, P) and of chemical indexes (humidity, dry substance, proteins, lipids, mineral substances) in muscular tissue and liver have been changed that influences considerably the nutrition value.

4. While commercializing the meat it is necessary to take into consideration the intensity of infestation of cattle with *Dicrocelium*. The meat and specialty meats without *Dicrocelium* should be used depending on its nutritional value: in case of the low invasion – without restrictions, in case of medium invasion –only with due industrial processing (producing of sausages, cans etc.) and in case of high level of infestation – the industrial processing should be done only under the due bacteriological control.

5. The calculations with economic agents that supply live cattle, carcasses and comestible specialty meats should be done taking into consideration the animals' level of infestation with *Dicrocelium*.

BIBLIOGRAPHY

1. Băguţ E. T., Cătoi C. Aspecte anatomopatologice în hepatitele parazitare la rumegătoarele mici. Revista Română de Parazitologie. 2008, vol. XVIII, Supliment, p. 8-9.

2. Erhan D. Epizootologia mono- şi poliinvaziilor la bovine în Republica Moldova în funcţie de zonă, vârstă şi tehnologia de întreţinere. Revista Mediul Ambiant. Chişinău, 2009, nr.5(46), p.37-41.

3. Erhan D., Luncaşu M., Grati N. et.al. Rolul factorilor antropogeni şi naturali la infestarea animalelor sălbatice şi domestice cu endo- şi ectoparaziţi în Republica Moldova. Materialele Conferinţei a IV-a a Zoologilor din Republica Moldova cu participare Internaţională "Diversitatea, valorificarea raţională şi protecţia lumii animale". Chişinău, 2001, p. 15-21.

4. Olteanu Gh., Panaitescu D., Gherman I. et. al. Poliparazitismul la om, animale, plante şi mediu. Bucureşti, 2001, 812 p.

5. Şindilar E., Stratan N. Expertiza sanitar-veterinară a alimentelor de origine animală. Chişinău, Tipografia Centrală, 1996, vol.1, 325 p.

6. Городович Н. М. Ликвидация гельминтозов – дополнительный резерв увеличения продукции животноводства. Научное обеспечение агропромышленного комплекса Дального Востока. Материалы научной сесии. Усурийск, 18-20 августа, 1993, с. 267-273.

H.M. Gorodovich. Eradication of helminthoses as an additional reserve for animal production growing. The use of scientific approach in the agro-industrial complex of the Far East. Ussuriisk, August 18-20, 1993. P.267-273.

IMPACT OF SOME ORGANOPHOSPHORUS INSECTICIDES ON GROWTH PERFORMANCE, FECUNDITY AND SEMEN CHARACTERISTICS IN NILE TILAPIA (*OREOCHROMIS NILOTICUS*)

[1]Eman A. Abd El-Gawad; [2]Mohamed M.M. Kandiel;
[1]Amany A. Abbass; and [1]Adel A. Shaheen
[1]Dept. of Fish Diseases and Management, of Veterinary Medicine, Benha University, Egypt
[2] Dept. of Theriogenology, Faculty of Veterinary Medicine, Benha University, Egypt

Abstract
The present study was conducted to determine the effect of some organophosphorus insecticides (dimethoate and malathion) on the reproductive performance and growth performance of the female and male Nile Tilapia; *Oreochromis niloticus*. The experimental fish were fed a diet containing dimethoate and malathion at concentration 1.6 and 0.17 mg/kg, respectively for 120 days. Treatment with dimethoate and malathion resulted in a significant ($P < 0.05$) decrease in absolute fecundity, sperm motility, live-dead ratio and increased sperm abnormalities compared to the control. On the other hand, there was not a significant effect neither on semen pH, sperm cell concentration or growth performance; condition factor (K). Gonadosomatic index (GSI) was significantly ($P < 0.05$) decreased in both dimethoate and malathion male treated groups. On the other hand, GSI treated was significantly ($P < 0.05$) low in female tilapia fed a diet containing dimethoate. Although dimethoate noticeably increased plasma testosterone and estradiol 17β hormones, malathion decreased both sex steroids in treated male tilapia than control. Histopathological examination revealed testicular degeneration, pyknosis of spermatocytes nuclei and complete absence of germ cells lining seminiferous tubules. The ovaries showed presence of multiple atretic oocytes with oocyte necrosis embedded in the ovarian interstitial tissues and decrease of vitellogenic oocytes. From these results we can conclude that, even dimethoate and malathion has no effect on the growth performance of *O. niloticus*, but have endocrine disrupting effect on fecundity and semen quality through alteration in sex steroid hormones and the degenerative changes in gonads resulted in decreased gonadosomatic index.
Key words: Organophosphorus insecticides, Nile Tilapia, Growth Performance, Fecundity and Semen Characteristics, histopathology

1. Introduction

Malathion and dimethoate; an organophosphorous insecticides more frequently used due to their highly effectiveness for controlling agriculture pest of (cotton, rice, fruit, olives and potatoes), flies in home garden and on livestock and also its low persistent in the aquatic environment (**Srivastava *et al*. 2010**). Fish exposed to pesticides present in the ecosystem which receives it from agriculture runoff and industrial wastes, exhibited a variety of reproductive problems such as reducing number of sperm, abnormal gamete, reducing fecundity **(Patyna *et al*., 1999)**, sex reversal (**Mills and Chichester, 2005**), low hatching rate and survivability **(Mlambo *et al*., 2009**). Dimethoate was found to cause an endocrine disruption by acting as an estrogen mimic and modifying feedback on the hypothalamo-pituitary axis in *Oncorhynchus mykiss* (**Dogan and Can, 2011).** Whereas, malathion causes an endocrine disruption through interfering with aromatase enzyme and reducing estradiol (E2) hormone in eel; *Monopterus albus* (**Singh, 1993).**

In fish, many biomarkers or indicators of endocrine disruption of reproduction have been used such as measuring sex steroid hormones (testosterone and 17β-estradiol), vitellogenin in mature male fish upon exposure to estrogenic chemicals (**Rodas-Ortíz *et al*., 2008**), viability of the gametes **(Kime and Nash, 1999),** Gonadosomatic index; GSI **(Di Giulio and Hinto, 2008)**. Besides, gonads; primary organs of reproduction; are mirror reflect any disturbance in the hypothalamo-pituitary gonadal axis and their histopathology is considered an endpoint for assessing endocrine disrupting effect in fish.

The present study was set up to determine the effect of dimethoate and malathion on the reproductive (GSI, semen picture and plasma sex steroid; testosterone and 17β-estradiol) and growth performance (condition K factor) as well as gonadal morphophysiology in *O.niloticus* to enhance the understanding of the endocrine disrupting effect of organophosphorus compounds in *O.niloticus*.

2. Material and methods:

2.1. Experimental fish:

Nile Tilapia; *O. niloticus* with a mean body weight and total length 29.93±0.44 gm and 12.8±0.12 cm and 33.56±0.93 gm and 13.33±0.17 cm for female and male, respectively were obtained from private fish hatchery in Kafer El-Sheikh, Egypt. The fish were transported in double skinned polyethylene bag to wet lab. Faculty of Veterinary Medicine, Benha University, Egypt. The experimental fish were kept in well prepared fiberglass tank (110×90×40 cm).The fish were left for 7 days to acclimate the laboratory conditions at temperature 27±1°C. Both control and treated fish were fed daily on diet at a rate of 3 percent of body weight. About 50% of tank water was daily exchanged.

2.2. Chemicals and feed:

The O,O-dimethyl S-(N-methylcarbamoylmethyl) phosphorodithioate (Dimethoate) and The O,O-dimethyl-S-(1, 2 dicarbethoxy) ethylphosphorodithioate (Malathion) (**Sigma Aldrich Chemical, USA)**. 100 mg of dimethoate and malthion standard were dissolved in 15.6 ml and 36.1 ml cod liver oil, respectively to form two separate stock solution. 1 ml of the dimethoate stock solution (contain 1.6 mg/kg) and 0.25 ml of the malathion stock solution (contain 0.17 mg/kg) were incorporated separately into 3600 gm of dry food, mixed well in a blender, packed in clean plastic jar and kept in refrigerator at 4 ºC until use.

2.3. Experimental design:

300 apparently healthy *O.niloticus* were divided into three groups (n= 100 fish/group); control, dimethoate and malathion groups were fed a diet containing no chemicals, 1.6 and 0.17 mg/kg, respectively for 120 days. Blood samples were collected from 6 male and female each at the end of experimental period. Fish total lengths (TL) were measured from the tip of the mouth to the tip of the caudal fin using graduated ruler to the nearest centimeter and weighed (W) using a portable digital scale to the nearest 0.1 gram.

2.4. Determination of fecundity:

The total number of ripened eggs in the ovaries per female (absolute fecundity) was counted immediately after dissection by the gravimetric method according to **Kolding *et al*. (2008).** Relative fecundity (i.e. the number of eggs per length (cm) or body weight (g) were calculated according to **Bagenal (1967)**.

2.5. Semen analysis:

Semen quality was determined at the end of the experiment. 6 males of fish per group, randomly selected from each treatment, sacrificed and the testes removed for analysis.

2.5.1. Semen collection

The semen was by squeezing the testes on clean glass slide. The collected semen was transferred to a clean eppendroff tube for analysis.

2.5.2. Semen evaluation

2.5.2.1. Semen hydrogen ion concentration (pH)

The pH of semen samples was evaluated by using pH indicator papers (range of 6-8, sensitivity nearest to 0.2).

2.5.2.2. Sperm motility:

The individual motility of sperm was recorded according to **Morita *et al*. (2003)**; approximately 5 µl of semen were immediately diluted into 45 µl of activating solution; 0.1% NaCl solution; on a glass slide with fine glass capillary tube, and covered with a coverslip. Sperm were counted as motile if they either exhibited progressive movement or spontaneous flagellar beating (if the sperm head was attached to the glass slide) and the percentage motility was calculated by grading the percentage motile cells.

2.5.2.3. Sperm viability:

The percentage of live spermatozoa were counted by differential coloration according to **Crespo Garcia (1991)** after staining by eosin 5% and contrast staining with nigrosin 10% based on the principle that only the dead cells become permeable to the eosin dye and become pink in color. An analysis was conducted under a microscope (×100) by the arbitrary counting of 200 cells on the slide.

2.5.2.4. Sperm cell concentration

Seminal fluid was diluted 400 fold in an immobilizing solution; colored sodium chloride 0.3%. Sperm count was made by using a hemocytometer. Sperm count was estimated as described by **Tvedt *et al*. (2001)**. Briefly, 10 µl of diluted samples were pipetted to the underneath of cover slip of Neubauer's chamber, left to stand for a few minutes to settle down and two counts of 0.2 mm^2 were conducted under microscope (×40).The number of spermatozoa (cell/ml) was determined for each sample by using the following formula: Sperm density = n× r×10,000; where n= average cells count and r= dilution rate.

2.5.2.5. Sperm cell morphology

The percentage of abnormal spermatozoa was counted according to **Musa (2010)**. The normal *O. niloticus* spermatozoa are uniflagellate with clearly differentiated oval-shaped head, mid-piece and flagellum. All abnormalities on any spermatozoon observed in eosin-nigrosin stained smears were counted and then were divided into 2 groups that is normal spermatozoa and abnormal spermatozoa (abnormalities of sperm head and acrosome, coiled sperm tail, etc.). Morphological abnormalities were expressed as a percentage of the total number of all counted spermatozoa.

2.6. Determination of growth performance and gonadosomatic index:

Gonads of both male and female Nile tilapia were excised from euthanized fish, weighed to the nearest 0.01 gram for determination the gonadosomatic indexes (GSI) of both sexes as GSI (%) =GW ×100/BW; where GW=gonad weight (g) and BW=body weight (g)

and the growth performance was calculated based on condition (K) factor according to the formula: $K=W\times100/L^3$; where W= body weight (gm) and L=total length in (cm) (**Kolding *et al*., 2008)**.

2.7. Blood sampling and sex steroid hormonal assay:

Blood samples were collected from the heart with 3 ml plastic syringe, fitted with 20 gauge hypodermic needle, pooled into 5 ml lithium heparinized tubes, centrifuged at 3600 rpm for 5 minute (**Özcan Oruc, 2010**) and the separated plasma were kept at -20 °C until assayed for estradiol 17β (E2) and total testosterone (T) hormone using radioimmunoassay (RIA) kits **(Siemens Healthcare Diagnostics Inc, USA).**

2.8. Tissue sampling, preparation and histopathological examination:

Tissue section from gonads of experimentally treated *O. niloticus* were taken at the end of experimental period (120 days), fixed in 10% buffered formalin, dehydrated in ascending grades of alcohol, cleared by xylene and bedded in paraffin, sectioned at 5-6 µm in thickness, stained with Hematoxylin and eosin, and analyzed under a light microscope according to **Zaroogian *et al.* (2001).**

2.9. Statistical analysis:

Data obtained from the current experiment were expressed as mean (±S.E.M) and were statistically analyzed by one-way analysis of variance (ANOVA) and Duncan's multiple range tests to determine significant difference between groups with Statistical Package for the Social Sciences (SPSS) software (version 16.0). A value of $P<0.05$ was considered significant.

3. Results

3.1. Effect of insecticides on fecundity:

Treatment with dimethoate and malathion significantly ($P<0.05$) decreased the ovarian activity and lower the reproductivity of females *O. niloticus* as compared to control group. The absolute fecundity was significantly decreased in dimethoate and malathion treated groups compared to the control (117.86±23.69 and 156.59±32.78 vs. 245.25±22.62 eggs/female, respectively). Moreover, the relative fecundity to TL or BW was significantly decreased in dimethoate and malathion treated groups (Table 1).

3.2. Effect of insecticides on semen characteristics:

Although treatment with insecticides did not show any effect on seminal fluid pH, a significant alternation in semen quality has been observed in response to treatment with insecticides (Table 2). A lower sperm cell concentration ($6.16\pm1.32\times10^9$/ml and $5.66\pm0.95\times10^9$/ml vs. $15.84\pm6.3\times10^9$/ml), a depression of sperm progressive motility (24.17±4.55 and 21.67±3.80 vs. 60.83±0.83%) and a reduction in the live sperm percentage (50.07±3.7 and 46.32±2.18 vs. 73.48±0.88%) have been recorded in dimethoate and malathion groups as compared with control one, respectively. In addition, the sperm normality was significantly decreased (26.81±4.30 and 37.78±2.00 vs. 57.92±3.51%) with a high percentage of tail deformity (57.93±4.78 and 48.6±3.39 vs. 28.81±2.38%) and no change in the percentage of head deformity (15.16±1.90 and 13.27±3.06 vs. 13.27±3.06%).

3.3. Effect of insecticides on gonadosomatic index and growth performance:

Effect of insecticides on gonadosomatic index (GSI) illustrated in fig. 1 showed that while the female GSI significantly ($P<0.05$) decreased with dimethoate (0.44±0.07), malathion had no effect as compared to control group (1.11±0.34 vs. 2.15±0.52,

respectively). GSI index in male *O. niloticus* treated with dimethoate and malathion showed a significant decrease compared to control one (0.34±0.05 and 0.41±0.08 vs. 1.03±0.33, respectively).Growth performance condition (K) factor showed no significant difference for both dimethoate and malathion female and male treated fish as compared with control (Fig. 2).

3.5. Effect of insecticides on plasma sex steroid (Testosterone and estradiol 17β):

The plasma sex steroid hormone in male dimethoate treated group showed high level of testosterone and E2 than control. While, with malathion lower level of T and E2 was recorded. Female treated either with dimethaote or malathion revealed lower plasma E2 and high T hormone than control.

3.4. Histopathological examination of gonads:

Examination of the testis of dimethoate treated group showed the presence of necrosis and degeneration of seminiferous tubules with complete absence of the lining germ cells and pyknosis of spermatocytes nucleus (Fig, 3B). Yet, treatment with malathion induced degenerative changes in seminiferous tubules with pyknosis of spermatocytes nucleus (Fig, 3C). Histopathological examination of the ovary revealed presence of multiple atretic oocytes with oocyte necrosis embedded in the ovarian interstitial tissues and decrease of vitellogenic oocytes in both dimethoate and malathion treatment groups (Fig, 3E& 3F).

4. Discussion:

Insecticides have been observed as environmental pollutant in many areas. Their potential to cause adverse effects on human and wildlife populations has been the subject of intense study. Moreover, insecticides are one of endocrine disrupting chemicals that can affect on the fecundity and semen characteristics of fish. There was a significant decrease in the absolute and relative fecundity of female *O. niloticus* treated with dimethoate and malathion compared to control. These results disagree with that obtained by **Mlambo *et al*. (2009)** who found that the exposure to DDT had no significant effect on the fecundity of *O. massambicus*. This difference might be due the difference of pesticides used or the period of exposure (40 days). The lower fecundity may be due to impaired vitellogenesis and high rate of oocyte atresia (**Ankley *et al*., 2002**).

The current results showed that the seminal fluid pH was around 7.1 and there was none significant difference between treated and control groups. These results agreed with earlier study demonstrated that the pH of the seminal fluid in *O. niloticus* subjected to environmentally relevant pollutants such as cadmium, malathion or rotenone was 7.4±2.0 **(Musa, 2010)**. Sperm motility with dimethoate and malathion were highly significant decrease. This may be due to the effect of organophosphorus pesticides on mitochondria and alter ATP production **(Massicotte *et al*., 2005)** or due to oxidative stress which lead to production of lipid peroxidation in spermatozoa affecting its motility (**Piña-Guzmán *et al*., 2006**).

Referring to the semen quality, the present study showed a significant decrease in the percent of live sperms with high deformity in sperm tail and no effect on head abnormalities in both dimethoate and malathion treated *O. niloticus* groups. An increase in the tail deformity may result from a decrease in acetylcholinesterase inhibitors activity, impaired function of caput of epididymis or pathological alternation in the testicles associated with organophosphorus pesticides treatment (**Okamura *et al*., 2009**). Studying the effect of malathion on sperm morphology and head abnormalities leaded to diverse results i.e. while some studies (**Giri *et al*., 2002)** showed an increase in the sperm head

deformity upon malathion exposure, others (**Musa, 2010)** revealed that malathion has no effect on sperm morphology in *O.niloticus*.

Most biomarkers for assessment of fish sperm quality are associated with fertilization rate and include sperm cell density. The sperm cell concentration in this study significantly differed in the groups treated with dimethoate and malathion in comparison to control, and this may be due to pathological alternation in testicular tissue characterized by degenerative changes and lacking of germ cell lining to seminiferous tubules after treatment with insecticides. Similarly, male *O.massambicus* exposed to DDT for 40 days showed disorganization of sperm cysts, loss of sertoli cells, pyknosis and testicular hemorrhagic necrosis (**Mlambo *et al*., 2009)**. These results indicated that dimethoate and malathion can act as endocrine modulators in the *O. niloticus*.

In the present study, GSI for both male and female were significantly decreased with dimethoate. Conversely, male *O. niloticus* treated with malathion showed a significant decrease in GSI without affecting on that of the female. This reduction in GSI may be attributed to the degenerative changes in gonads (**Scholz and Gutzeit, 2000**). Nevertheless, **Dogan and Can (2011)** indicated that the male *Oncorhynchus mykiss* exposed to dimethoate showed no significant difference in GSI and malathion caused a significant reduction in the GSI in female *Sarotherodon massombicus* (**Shukla *et al.*, 1984)**. The difference perhaps due to impairment of lipid metabolism or restriction their mobilization to the gonads during exposure to pesticides (**Singh, 1993**), that could be compensated during short period and highlights the fact that at short-term exposures the nonlethal levels of pesticides have no inhibitory effect while at long-term exposure, the pesticides have potent inhibitory effect on the reproduction of fish (**Choudhury *et al.,* 1993)**.

The present results showed that the growth performance for dimethoate and malathion *O. niloticus* groups denoted by condition (K) factor was not significantly different from that of the control. Likewise treatment with organochlorine pesticides did not affect K factor in largemouth bass, *Micropterus salmoides* (**Muller *et al*., 2004)**.

Concerning to, the plasma T and E2 in male treated with dimethoate was higher than control. The results nearly similar to **Dogan and Can (2011)** who found that male *Oncorhynchus mykiss* treated with dimethoate increase the serum level of E2 while T level not changed. The author explains the increase in E2 due to estrogenic activity of dimethoate by acting as estrogen mimic. On the other hand, male treated with malathion decrease the plasma level of T and E2 than control. These results finding came in a partial agreement with (**Spanò *et al*., 2004)** who recorded that male *Carassius auratus* treated with atrazine, the plasma estradiol and testosterone decrease due the stimulatory effect of atrazine on aromatase enzyme which convert testosterone to estradiol, and by (**Leaños-Castañeda *et al*., 2007**) in male *O.niloticus* treated *o,p*- DDT. Plasma estradiol in female treated either with dimethaote or malathion was lower than control. These results came in the same manner with *O.niloticus* exposed to chlorpyrifos (**Özcan Oruc, 2010).** The decline in sex steroid hormone in fish treated with pesticides may also due to their rapid metabolic clearance by the liver through Mixed Function Oxidase (MFO) (**Sijm and Opperhuizen, 1989).**

Histopathological examination revealed degeneration of seminephrous tubules with pyknosis of nucleus of spermatocytes with complete absence of germ cells in the testis of male treated with malathion and dimethoate. The ovary of *O.niloticus* revealed necrotic oocytes and atresia with both treatments compared to the normal histological structure of

testis and ovary. The freshwater fish, *Ophiocephalus punctatus* exposed to sublethal concentration of malathion 14µl/l for 7 days showed reduced oocytes, yolk granules disappeared and atretic oocytes **(Pugazhvendan *et al*., 2009).** The relative increase in atretic follicles and decrease of vitellogenic oocytes may be due to estrogenic effect (**Van den Belt *et al*., 2002**). In the same manner *O.massambicus* exposed to 5µg/l DDT for 40 days revealed oocyst artesia, with presence of vitollogenic fluid in the ovarian parenchyma and necrosis of primary oocytes and testes showed disorganization of cysts, loss of supporting sertoli cells, pyknosis and testicular hemorrhagic necrosis **(Mlambo *et al*., 2009)**. In conclusion, effect of dimethoate and malathion on reproductive and endocrine function in *O.niloticus* were clearly observed after 120 days causing decreases in fecundity, reduce sperm motility, sperm viability and sperm normality may be owing to low estradiol and testosterone hormone and the degenerative changes in gonads which lead to decrease in GSI. Moreover, dimethaote and malathion have endocrine disrupting action in male and female *O.niloticus*.

5. References:

1. **Ankley, G.T.; Kahl, M.D.; Jensen, K.M.; Hornung, M.W.; Korte, J.J., Makynen, E.A. and Leino, R.L. (2002):** Evaluation of the aromatase inhibitor fadrozole in a short-term reproduction assay with the fathead minnow (*Pimephales promelas*). Toxicol. Sci. 67:121-130.
2. **Bagenal, T.B. (1967):** A short review of fish fecundity. In "The biological Basis of Freshwater Fish Production"; S.D.Gerking (ed). Edinburgh, Blackwell Scientific Publications, Oxford, England. Pp: 89-111.
3. **Choudhury, C., Ray, A.K., Bhattacharya, S. and Bhattacharya, S. (1993)**: Non lethal concentrations of pesticide impair ovarian function in the freshwater perch, *Anabas testudineus*. Environ. Biol. Fish. 36: 319-324.
4. **Crespo Garcia, J. (1991):** Determination of living and dead spermatozoa in semen. Rev. Partonato Biol. Anim. 2:23-51.
5. **Di Giulio, R.T. and Hinton, D.E. (2008):** The Toxicology of Fishes, CRC Press, Taylor and Francis Group, Boca Raton. Pp:1071.
6. **Dogan, D. and Can, C. (2011):** Endocrine disruption and altered biochemical indices in male *Oncorhynchus mykiss* in response to dimethoate. Pest. Biochem. Physiol. 99: 157-161.
7. **Giri, S.; Prasad, S.B.; Giri, A. and Sharma, G.D. (2002):** Genotoxic effects of malathion: an organophosphorus insecticide, using three mammalian bioassays in vivo. Mutat. Res. 514: 223-231.
8. **Kime, D.E. and Nash, J.P. (1999).** Gamete viability as an indicator of reproductive endocrine disruption in fish. Sci. Total Environ**.** 233: 123-129.
9. **Kolding, J. Haug, L. and Stefansson, S. (2008)**: Effect of ambient oxygen on growth and reproduction in Nile tilapia (*Oreochromis niloticus*). Can. J. Fish. Aquat. Sci. 65: 1413-1424
10. **Leaños-Castañeda, O.; van der Kraak, G.; Rodríguez-Canul, R. and Gold, G. (2007):** Endocrine disruption mechanism of o,p' -DDT in mature male tilapia (*Oreochromis niloticus*). Toxicol. Appl. Pharmacol.221: 158-167.

11. **Massicotte, C., Knight, K., Van der Schyf, C.J., Jortner, B.S. and Ehrich, M. (2005):** Effects of organophosphorus compounds on ATP production and mitochondrial integrity in cultured cells. Neurotox. Res.7: 203-217.
12. **Mills, L.J. and Chichester, C. (2005):** Review of evidence: are endocrine-disrupting chemicals in the aquatic environment impacting fish population?. Sci. Total. Environ. 343: 1-34 (Review).
13. **Mlambo, S.S., Van Vuren, J.H.J., Barnhoorn, I.E.J. and Bornman, M.S. (2009):** Histopathological changes in the reproductive system (ovaries and testes) of *Oreochromis mossambicus* following exposure to DDT. Environ. Toxicol. Phar. 28: 133-139.
14. **Morita, M., Takemura, A. and Okuno, M. (2003)**: Requirement of Ca^{2+} on activation of sperm motility in euryhaline tilapia *Oreochromis mossambicus*. J. Exp. Biol. 206: 913-921.
15. **Muller, J.K., Johnson, K.G., Sepulveda, M.S., Borgert, C.J., Gross, T.S. (2004)**: Accumulation of dietary DDE and dieldrin by largemouth bass, *Micropterus salmoides floridanus*. Bull. Environ. Contam. Toxicol. 73:1078-1085.
16. **Musa, N. (2010):** Sperm activation in Nile Tilapia *Oreochromis niloticus* and the effects of environmentally relevant pollutants on sperm fitness. Ph.D. Institute of aquaculture. Stirling University, Scotland [http://hdl.handle.net/1893/2310].
17. **Okamura, A., Kamijima, M., Ohtani, K., Yamanoshita, O., Nakamura, D., Ito, Y., Miyata, M., Ueyama, J., Suzuki, T., Imai, R., Takagi, K., Nakajima, T. (2009)**. Broken sperm, cytoplasmic droplets and reduced sperm motility are principal markers of decreased sperm quality due to organophosphorus pesticides in rats. J. Occup. Health. 51: 478-487.
18. **Özcan Oruc, E. (2010):** Oxidative stress, steroid hormone concentration and acetylcholinesterase activity in *Oreochromis niloticus* exposed to chlorpyrifos. Pesticide Biochemistry and Physiology 96:160-166.
19. **Patyna, P.J., Davi, R.A., Parkerton, T.F., Brown, R.P. and Cooper, K.R. (1999):** A proposed multigeneration protocol for Japanese medaka (*Oryzias latipes*) to evaluate effects of endocrine disruptors. Sci. Total Environ. 233: 211-220.
20. **Piña-Guzmán, B., Solís-Heredia, M.J., Rojas-García, A.E., Urióstegui-Acosta, M. and Quintanilla-Vega, B. (2006).** Genetic damage caused by methyl-parathion in mouse spermatozoa is related to oxidative stress. Toxicol. Appl. Pharmacol. 216: 216-224.
21. **Pugazhvendan, S.R., Jothi Narendiran, N., Kumaran, R.G., Kumaran, S. and Alagappan, K.M. (2009):** Effect of malathion toxicity in the freshwater fish *Ophiocephalus punctatus*- A Histological and histochemical study. World J. fish Mar. Sci. 1: 218-224.
22. **Rodas-Ortíz, J.P.; Ceja-Moreno, V.; Chan-Cocom, M.E. and Gold-Bouchot, G.(2008):** Vitellogenin induction and increased plasma 17ß- estradiol concentration in male Nile tilapia, *Oreochromis niloticus*, exposed to organochlorine pollutants and polycyclic aromatic hydrocarbons. Bull. Environ. Contam. Toxicol. 81:543-547.
23. **Scholz, S. and Gutzeit, H.O. (2000):** 17-Alpha-ethinylestradiol affects reproduction, sexual reproduction, sexual differentiation aromatase gene expression of the medaka (*Oryzias latipes*). Aquat. Toxicol. 50: 363-373.

24. **Sijm, D.T.H.M. and Opperhuizen, A. (1989):** Biotransformation of organic chemicals by fish: Enzyme activities and reactions, In: Hutzinger, O. editor. Handbook of environmental chemistry, 2E. Berlin, Springer. 160-235.
25. **Singh, H. (1993):** Effect of malathion on steroidogenesis and sex reversal in *Monopterus albus.* Mar. Environ. Res. 35: 159-164.
26. **Skula, L., Merwani, D., Shrivastava, A. and Pandey, A.K. (1984)**. Effect of sublethal malathion on oogenesis in *Sarotherodon massombicus*. Comp. Physiol. Ecol. 7: 15-18.
27. **Spanò, L., Tyler, C.R., Van Aerle, R., Devos, P., Mandiki, S.N., Silvestre, F., Thomé, J.P. and Kestemont, P. (2004):** Effects of atrazine on sex steroid dynamics, plasma vitellogenin concentration and gonad development in adult goldfish (*Carassius auratus*). Aquat. Toxicol. 66: 369-379.
28. **Srivastava, A.K., Mirshra, D., Shrivastava, S., Srivastav, S.K. and Srivastav, A.K. (2010):** Acute toxicity and behavioural responses of *Heteropneustes fossilis* to an organophosphate insecticide, dimethoate. Int. J. Pharma Bio Sci. 1: 359-363.
29. **Tvedt, H.B., Benfey, T.J., Martin-Robichaud, D.J. and Power, J. (2001):** The relationship between sperm density, spermatocrit, sperm motility and fertilization success in Atlantic halibut, *Hippoglossus hippoglossus*. Aquaculture 194: 191–200.
30. **Van den Belt, K.; Wester, P.W.; Van der Ven, L.T.; Verheyen, R. and Witters, H. (2002):** Time- dependent effects of ethynylestradiol on the reproductive physiology in zebrafish (*Danio rerio*). Environ. Toxicol. Chem. 21: 767-775.
31. **Zaroogian, G., Gardner, G., Horowitz, D.B., Gutjahr-Gobell, R., Haebler, R. and Mills, L. (2001):** Effect of 17β-estratiol, O,p'-DDT, octylphenol and p,p' -DDE on gonadal development and liver and kidney pathology in Juvenile male summer flounder (*Paralichthys dentatus*). Aquat. Toxicol. 54: 101-112.

Figure 1: Gonadosomatic (GSI) index in control, dimethoate and malathion treated groups. GSI values were presented as mean ±S.E.M. Values with different small and capital letters of

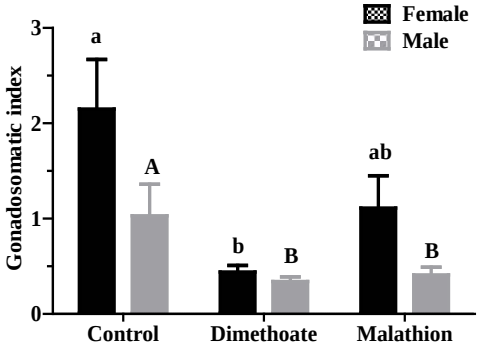

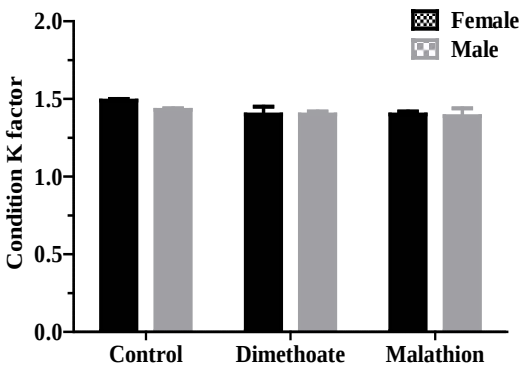

female (■) and male (□) *O. niloticus*, respectively were significantly different (P<0.05).

Figure 1

Figure 2

Figure 2: Growth performance represented by condition (K) factor of female (■) and male (□) *O.niloticus* in control, dimethoate and malathion treated groups. Condition (K) factor values were presented as mean ±S.E.M.

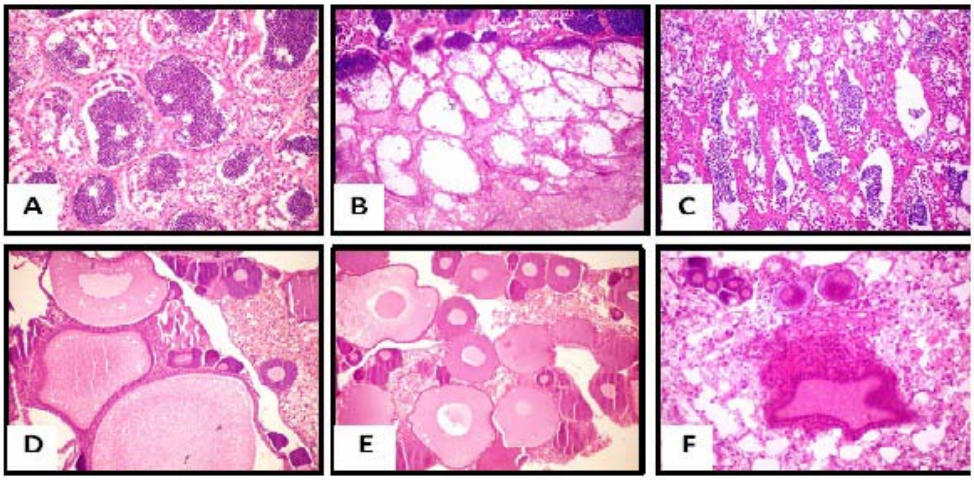

Figure 3: Histopathological pictures of the gonads of the control, dimethoate and malathion treated groups stained with haematoxylin and eosin. A): Testis of control *O. niloticus* showed all stages of germ cell development spermatocytes and spermatides (×40). B): Testis of dimethoate *O. niloticus* showed marked necrosis and complete absence of germ cells lining seminiferous tubules (×40). C): Testis of malathion *O. niloticus* showed degeneration and pyknosis of spermatocytes nuclei (×40). D): Ovary of control *O. niloticus* showed normal architecture and different stages of oocyte development (×20). E): Ovary of *O. niloticus* exposed to dimethoate showed atretic and destroyed oocytes (×20). F): Ovary of *O. niloticus* exposed to malathion showed oocyte atresia and necrotic oocytes (×20).

Table (1): Changes in the absolute and relative fecundity of *O. niloticus* treated with dimethoate and malathion for 120 days

	Control	Dimethoate	Malathion
Total length (cm)	16.13±0.16[a]	15.50±0.13[b]	15.45±0.26[b]
Body weight (gm)	62.87±1.78[a]	52.15±1.71[b]	51.85±1.98[b]
Absolute fecundity	245.25±23.69[a]	117.86±23.69[b]	156.59±32.78[b]
Relative fecundity			
In relation to length	665.89±7.82[a]	634.28±6.41[b]	631.88±13.10[b]
In relation to weight	729.80±2.12[a]	684.47±7.58[b]	683.01±8.77[b]

Mean values (±S.E.M) within the same raw with different superscript letters are significantly different ($p<0.05$).

Table (2): Semen characteristics in *O. niloticus* treated with dimethoate and malathion for 120 day.

	Control	Dimethoate	Malathion
Semen hydrogen ion conc. (pH)	7.13±0.07[a]	7.05±0.05[a]	7.10±0.09[a]
Sperm motility (%)	60.83±0.83[a]	24.17±4.55[b]	21.67±3.80[b]
Live/dead %			
Live sperm	73.48±0.88[a]	50.07±3.70[b]	46.32±2.18[b]
Dead sperm	26.52±0.88[b]	49.60±3.70[a]	53.68±2.18[a]
Sperm cell conc.($\times 10^9$/ml)	15.84±6.30[a]	6.16±1.32[a]	5.66±0.95[a]
Sperm abnormalities (%)			
Normal sperm	57.92±3.51[a]	26.81±4.30[c]	37.78±2.00[b]
Tail deformity	28.81±2.28[c]	57.93±4.78[a]	48.60±3.39[b]
Head deformity	13.27±3.06[a]	15.16±1.90[a]	13.62±2.43[a]

Mean values (±S.E.M) within the same raw with different superscript letters are significantly different ($p<0.05$).

DETERMINING OF TOXOPLASMOSIS SEROPREVALENCE, BY ELISA, IN LAMBS IN TIMIS COUNTY

Ionela Hotea, Marius Ilie, Mirela Imre, Denisa Sorescu, Gheorghe Dărăbuş
Faculty of Veterinary Medicine, No. 119, Calea Aradului, Timisoara, Romania
gheorghe.darabus@yahoo.com

Abstarct
To determine the seroprevalence of Toxoplasma gondii infection in lambs in Timis County, 200 serological samples were processed by ELISA.
The lambs were aged between 35 and 55 days and came from four localities from Timis County. From each locality were randomly collected 50 samples. 134 of the lambs were males and 66 were females. Those 200 serological samples were collected from slaughterhouses, in slaughter lambs period.
The seropositivity of Toxoplasma gondii infection in lambs was 6.5% with variations between 0 and 12%.
Key words: *toxoplasmosis, lambs, ELISA, Timis County*

Toxoplasmosis is a parasitical infection, common to several species of animals and human transmissible under natural conditions in various ways. It is one of the most widespread parasitic zoonoses in the world. It is estimated that one third of the world's human population has been or is exposed to this parasite, but there are wide variations in each country, in each group population from a geographical area (Cosoroabă, 2005).

Among livestock, sheep are considered the most susceptible species. *Toxoplasma gondii* is one of the common causes of abortion in sheep and goats and thus a big problem for lamb production (Dumetre et al., 2006). If in a flock appear more abortions, means that animals have access to an important source of oocysts. Sheep develop a strong immunity after an abortion (Dărăbuş et al., 2006). Diagnosis of *Toxoplasma* infection, after abortion, can be made based on antibodies in fetal fluids by modified agglutination test (Dubey et al., 2008).

Lamb and sheep uncooked meat is an important source of transmission of infection in humans (Weiss and Kim, 2007). Because of this and because of a small number of bibliographic data about toxoplasmosis in animals from Romania, this study has attempted to establish the seroprevalence of *Toxoplasma gondii* infection in lambs in the Timis County.

Materials and methods

To determine the prevalence of toxoplasmosis in Timis County 200 serological samples were collected from lambs.

Blood was collected during the Easter holidays in April 2009. The lambs were aged between 35 and 55 days and came from four localities from Timis County. 134 of the lambs were males and 66 were females. Those 200 serological samples were collected from slaughterhouses, in slaughter lambs period.

Collected blood was left to settle for the expression of serum, and the serum was kept in a freezer (-20 º C) until samples were processed in the laboratory of Parasitology and Parasitic Diseases Faculty of Veterinary Medicine from Timisoara.

Serum samples were examined by indirect ELISA using CHEKIT TOXOTEST (IDEXX Laboratories, Switzerland). The test identifies IgG anti-*Toxoplasma* antibodies. The kit is specific for analysis of samples from small ruminants. ELISA plate is dusted with *Toxoplasma gondii* antigen. The peroxidase-linked conjugate stabilized the formed antigen-antibody complex. After addition of substrate the positive samples are evidenced by a blue color. Color reaction is stopped by adding stop solution.

Optical densities were interpreted by the following formula: Antibody titers = [(OD sample - OD neg.) / (OD pos. - OD neg.)] x 100. Values above 100% were considered strong positive, values between 30 and 100% weak positive, those between 20 and 30% uncertain, and values below 20% were considered negative.

Results and discussion

In Timis County 200 serological samples collected from lambs were tested by ELISA. Of the 200 samples, only 13 (6.5%) were positive for *T. gondii* infection (table 1, fig. 1).

Table 1

The seroprevalence of *Toxoplasma gondii* infection in lambs in Timis County

Locality	No. of samples	Positive samples
L1- Uivar	50	6 (12%)
L2 - Pischia	50	0 (0%)
L3 - Buzias	50	5 (10%)
L4 - Gataia	50	2 (4%)
Total	**200**	**13 (6,5%)**

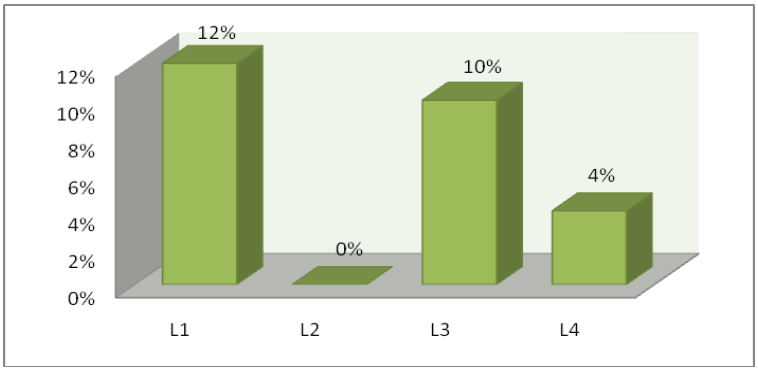

Legend: L – locality

Fig. 1 Graphical representation of the toxoplasmosis seroprevalence in lambs in Timis County

The minimum and maximum limits of antibody titers are presented in table 2.

Table 2

The values of anti-*Toxoplasma* antibody titers in lambs in Timis County

Locality	**The antibody titers values**							
Interpretation	**Strong positive > 100%**	**No. of samples**	**Weak positive 30 – 100%**	**No. of samples**	**Uncertain samples 20 – 30%**	**No. of samples**	**Negative samples < 20%**	**No. of samples**
L1- Uivar	-	0/50	34.43-75.51	6/50	22.23-27.28	3/50	0.21-15.92	41/50
L2 - Pischia	-	0/50	-	0/50	-	0/50	0.07-16.2	50/50
L3 - Buzias	171.74 – 243.62	2/50	31.91 - 65,71	3/50	24.89-26.34	2/50	0.07-12.27	43/50
L4 - Gataia	123.66	1/50	52.89	1/50	-	0/50	0.09 – 4.42	48/50

Low prevalence obtained in lambs may be due to too young age of animals. Lambs had access to pasture for a short time. This thing limits the contact with potential sources of infection.

In the world the results are most diverse. In England, Mason et al., 2010, identified a prevalence of 9% of newborn lambs and 7.6% for those aged 4 months (PCR).

In America, Dubey et al., 2008, established a prevalence of 27.1% (MAT technique) and Silva et al., 2006, in Brazil, identifying a prevalence of 18.3% in lambs less than three months. Dumetre et al., in Haute-Vienne, France, obtaining a seroprevalence of 22% in lambs and 65.6% in sheep.

In Romania, Titilincu et al., in 2009, examined the serological samples from 1570 sheep (1453 sheep and 117 lambs), in the central and north-west of the country. The authors found a prevalence of 64.34% in sheep, 25.23% in lambs, aged between 6 months and 1 year and 50% (5/10) in one month old lambs. The technique used was ELISA (Chekit Toxotest). The seroprevalence obtain in this study, in lambs (6.5%) was much lower than that obtained by Titilincu et al., 2009, 25.23% and 50% respectively.

Infections with *Toxoplasma gondii* are important because of economic losses due to abortions and births occurring in the viable products. Also, knowledge of epidemiological data on *Toxoplasma gondii* infection in these species is important because of the risk of disease transmission to humans or carnivorous species, by eating poorly cooked meat.

Conclusions

- The average prevalence of *Toxoplasma gondii* infection in lambs in Timis County was 6.5%, with variations between 0 and 12%.
- From 134 males, 5 (3.73%) were positive, and from 66 females, 8 (12.12%) were positive.

Acknowledgments

This work was supported by CNCSIS, Bd, grant No. 87/2008 obtained by Ionela Hotea and by CNMP, grant PC No. 51-013/2007.

References:

1. Cosoroabă, I. (2005) – Zoonoze parazitare. Ed. First/Artpress., Timişoara.
2. Dărăbuş, GH., Oprescu, I., Morariu, S., Mederle, Narcisa (2006) – Parazitologie şi boli parazitare, Ed. Mirton, Timişoara.
3. Dubey, J.P., Sundar, N., Hill, D., Velmurugan, G.V., Bandini, L.A., Kwok, O.C.H., Majumdar, D., Su, C. (2008) – High prevalence and abundant atypical genotypes of *Toxoplasma gondii* isolated from lambs destined for human consumption in the USA, Intl. J. Parasitol., 38, 999 – 1006.
4. Dumetre, A., Ajzenberg, D., Rozette, L., Mercier, A., Dardé, M.L. (2006) – *Toxoplasma gondii* infection in sheep from Haute-Vienne, France: Seroprevalence and isolate genotyping by microsatellite analysis, Vet. Parasitol., 142, 376 – 379.
5. Mason, S., Quinnell, R.J., Smith, J.E. (2010) - Detection of *Toxoplasma gondii* in lambs via PCR screening and serological follow-up, Vet. Parasitol., 169, 258-63.
6. Silva, K.L.M.de.V., Rue, M.L.de L.A. (2006) – Possibility of congenital transmission of *Toxoplasma gondii* in sheep demonstrated by serological follow-up in Rosário do Sul county, RS, Brazil, Ciênc. Rural, 36, 892-897.
7. Weiss, L.M., Kami, Kim (2007) - *Toxoplasma gondii* – The model apicomplexan: perspectives and methods, Ed. Academic Press, Elsevier, London, UK.
8. Titilincu, Adriana, Mircean, Viorica, Iovu, Anamaria, Blaga, R., Onac, Diana, Cozma, V. (2009) – Seroprevalence of *Toxoplasma gondii* infection in small ruminants from Romania, World Association for the Advancement of Veterinary Parasitology, Canada, Abstracts PO1.26, 126.

FOLLICULAR DYNAMICS AND UTERINE STATUS AFTER SYNCHRONIZATION OF OVULATION IN EARLY POST-PARTURIENT BUFFALO COWS

Sosa, G.A.; Kandiel, M.M. ; Gad, B.A. and El-Azab, A.I.
Dept. Theriogenology, Fac. Vet. Med., Benha univ., Egypt
E-mail: gamal_sosa@yahoo.com

The present study aimed at instigating the buffalo ovarian and uterine response to ovsynch protocol when initiated 21 days postpartum (pp). Animals were arranged into treated (n=3) and control (n=3) groups. The treated group was given 1st dose of GnRH on day 0 (day 21 pp) followed by PGF2 alpha on day 7 and 2nd dose of GnRH on day 9. All animals were allowed a daily ultrasound examination from day-1 to day 9 and then after every 12 hrs until detection of ovulation. The ovarian response of the treated group clearly showed the organized events of follicular growth ended by ovulation in one animal (33.3%) of the treated group; the changes in the small, medium, large and total follicle population and area did not differ significantly between the two groups; luteinization of the dominant follicle following the first GnRH injection in two animals (66.6%) indicated the reliability of ovsynch strategy to improve the ovarian function; the uterine response was clearly evidenced by increasing the uterine wall homogeneity, decreasing the uterine lumen (less than 0.3cm) and clearing contents by day 7 - 8 in the treated group. In conclusion, the ovsynch protocol has a beneficial effect on the ovarian function and uterine involution when applied 21 days pp in buffaloes.

Key word: Buffaloes, Ovary, Ovsynch, Postpartum, Ultrasound.

INTRODUCTION

Control of the interval from parturition to subsequent conception is important to optimize the reproductive rate of a species. Buffaloes are characterized by their low reproductive efficiency as expressed by long calving interval; exceeding 500 days (Merty et al, 1994), mostly due to the lowered ovarian activity (El-Wishy, 2007). In general, the ovarian response of buffaloes to stimulatory treatment seemed to be less than that reported in cattle (Totey et al., 1991; Singh et al, 2000). In buffaloes, the lowered availability of anovulatory follicle results in producing few and poor quality embryos (Madan et al., 1996 and Misra, et al, 1988).

In dairy cows, the postpartum anovulatory anestrus in dairy cows was attributed not only to a lack of follicular development, but also to the failure of a dominant follicle to ovulate (Roche et al., 2000); usage of GnRH in a single injection causes an increase in the LH surge and ovulation during postpartum between days 10 – 18 in dairy (Schallenberger et al., 1984) and days 21 - 31 in beef (Troxel and Kesler, 1984) cattle. A three injection schedule (GnRH-PGF2α-GnRH), named Ovsynch, was successfully implicated for synchronization of ovulation in cattle (Pursley et al (1995) and buffaloes (Paul and Prakash, 2005).

In the mean time of approving that the ovsynch protocol effectively induces ovulation in dairy cows as early as 21 days postpartum (Amaya-Montoya et al, 2007), there is no available information on its usage during an early postpartum stage in buffaloes. The present study was designed to evaluate the ovarian response and uterine changes following synchronization of ovulation by ovsynch protocol applied earlier after calving as a point of

economic value in promoting the productive and reproductive potentials of buffaloes..

Materials and Methods

The present study was carried out on a total number of six newly parturient, lactating buffalo cows, kept in the Educational Farm, Faculty of Veterinary Medicine, Benha Univ. during the period from April to August 2009.All animals were housed in a free-stall barn, offered 4 kg of mixed ration for lactation (consisted of cotton seed cack, line seed cack, yellow corn, bran, molasses, lime and NaCl) once daily, and suckled twice daily (0600 and 1800 h), and the average milk yield was approximately 2-3 kg/day.

All animals were examined ultrasonographically before the start of treatment for identifying the state of ovulation and presence of corpus luteum on the ovary. Animals were randomly allocated in nearly two similar groups for treatment and control, each of which was 3 buffalo cows.

Animals in the treated group (n=3) were treated with the ovsynch protocol (Figure, 1) according to Pursley et al. (1995); all animals received 20 µg i .m. injection of Buserelin acetate as GnRH analogue (Receptal®, Intervet International B.V.; equal 5ml) on day 0 (day 21 PP) followed by 500 µg i.m. injection of synthetic PGF2α; Cloprostenol (Estrumate ®; Schering-Plough Animal health, equal 2ml) on day 7 then by second i.m. injection of 20 µg GnRH analogue on day 9. In the control group, all animals were injected by saline comparable to the dose and time of the hormonal treatment.

By using transrectal ultrasonography (PieMedical 240, 6-8MHz linear array probe), ovarian morphology was monitored daily starting from the day before the first to the second GnRH injection thence after twice daily (08.00 and 20.00 h) till occurrence of ovulation and re-examined after 10 days to confirm ovulation and occurrence of the CL. To analyze the changes in follicular dynamics after GnRH treatment, all antral follicles (≥2 mm) were counted and measured. The observed follicles were classified into small (<0.5 cm), medium (0.5-1.0 cm) and large≥(1.0 cm) sizes . Diameters and volumes (cm3) of luteal structures and cavities were determined. The transverse diameter of the anterior 1/3 section of both uterine horns and the progression of uterine involution were evaluated. Animals were observed twice daily for at least 30 min before milking by experienced person to detect signs of estrus and to be bred naturally (Figure, 2).

The obtained data was tabulated and statistically computed, where appropriate, by the linear regression analysis using a Microsoft Excel computer program according to Awasthi et al (2006).

Results:

1- Ovarian findings

1.1-. Follicular dynamics

As shown in figures (3, 4, 5 and 6), the changes in the number and area of small, medium and large follicular size (<0.5cm, 0.5- 1.0 cm and >1.0 cm diameter, respectively) and whole follicular population in the treated and control groups did not show any significant variation along the experiment period. Moreover, the characteristics of follicular waves (table 1) showed a similar pattern in the two groups except for the diameter of the dominant follicle at 1st GnRH treatment, which was significantly larger prior to luteinization (1.38±0.12 Vs 0.98±0.06 cm, P<0.05).

1.2- Ovulatory response

As shown from figures (7& 8), there was an occurrence of luteinization of the dominant follicle (LF) after first GnRH injection in 2 out of 3 treated animals (66.67%) and

failure of ovulation or CL development. luteinization of the largest follicle was evident ultrasonographically in 2 responded buffaloes by thickening in the wall (1.05 cm width) and increasing the echogenicity of the follicular wall one day after first GnRH treatment, reached its maximum diameter (2.69 cm) on day 2; regression of the luteal structure started by decreasing the echogenicity, the diameter and collapsing the cavity area from day 3, and became ultrasonographically difficult to be detectable by day 5 - 6 before PGF2α treatment. Out of three treated animals, there was one buffalo cow showed (33.3%) and ovulation 24-36 hrs after the second GnRH injection.

2- Uterine findings:

The dorsal uterine diameter (Fig. 9A) did not differ between the treated (y=-0.05x + 2.90, R2 = 0.69) and control (y = -0.06x + 2.97, R2 = 0.82) groups except on day 1 where it showed a significant decrease (p<0.001) in the treated group. The ventral diameter of the uterus (Fig. 9B) showed a significant (p<0.05) decrease on day 4 and 7, followed by a significant (p<0.05) increase on day 9 in the treated group; both groups were negatively correlated with days post-treatment(y = -0.07x + 3.52, R2 = 0.78 and y=- 8 0.08x + 3.75, R2 = 0.81, respect.). the cranial diameter (Fig. 9C) showed a significant increase on day 8 and 9; both treated and control groups were negatively correlated with days post-treatment (y =-0.07x + 3.99, R2 = 0.81 and y = -0.06x +3.88, R2 = 0.76, respect.). The transverse diameter in the treated group (Fig. 10A) showed significant (P < 0.05) decrease on day 1, 3, and 10, but significant (P < 0.05) increase on day 9 when compared to that in the control group (y = -0.11x + 6.28, R2 = 0.75 and y = -0.15x + 6.71, R2 = 0.87, respect). The uterine lumen (Fig. 10B) revealed highly significant (P < 0.05) decrease along the days of the experiment in the treated group when compared with control (y=-0.02x +0.45, R2 = 0.84 and y = -0.02x + 0.59, R2 = 0.73, respect.)

Discussion

The present study revealed that the ovsynch protocol applied at an early postpartum period (day 21) precisely synchronized ovulation within 24-36 h after the second-GnRH treatment in 1/3 (33.3%) buffaloes and induced early clearance of uterine secretion as evidenced by reducing the uterine lumen diameter. However, the changes in the total follicular population and/or area were not significantly different between the treated and the control groups. The poor ovarian response in the treated group to the first GnRH basically might be attributed either to the little population of FSH-dependant follicles, the low LH secretion from pituitary in response to GnRH injection or the low GnRH receptors in pituitary gland . This finding came in association with some previous reports ((Dufour and Roy, 1985; Lucy et al., 1991; Pursley et al., 1995; Walters et al, 2008) indicating that the high rates of ovulation after GnRH injection are due to the presence of potentially ovulatory follicle (>9.0mm); the early postpartum period is characterized by reduction in the number of small sized follicles as the number of days postpartum increases (Lucy et al., 1991; El-Wishy, 2007).

The present results revealed luteinization of the dominant follicle following the first GnRH injection in the treated group, a finding which emphasized occurrence of ovulation in response to GnRH treatment during the postpartum period for 60%buffaloes (Baruselli et al., 2003) and 85% cattle (Wiltbank, 1997). Follicle luteinization was detected in 37.5% non-cyclic buffaloes synchronized by ovsynch 96-118 days postpartum (Ali and Fahmy, 2007).

The present study indicated occurrence of ovulation in one case of the treated group (33.3%), 24-36h after the second GnRH injection. This finding came in consistent with that reported earlier in cows (Demüral et al, 2006) and buffaloes (Warriach et al., 2008) assuming that ovsynch protocol for estrus synchronization has potential application for improvement of fertility in anestrous buffaloes during early postpartum period even during extreme summer months through suppression of prolactin secretion (Roy and Prakash, 2009).

Following GnRH injection, low intensity of estrus was detected, a finding which came in accordance with some previous studies (Pattabiraman et al., 1986; Barkawi et al. (1995) indicating the presence of poor signs of heat in GnRH treated buffaloes.

The present study showed fluctuation in thickness of the uterus, but was negatively correlated with the day postpartum. The treated group showed a prominant clearance of the uterine lumen as indicated from the noticeable decrease of the uterine lumen echogenicity and diameter comparable to the control one. This might be attributed to the increased ovarian estradiol secretion by large follicle (s) that has a local effect to increase the rate of uterine involution (Sheldon and Dobson, 2000; Sheldon et al, 2003). The ultrasonographic pattern of decreasing the uterine diameter by increasing time after parturition came in accordance with some previous studies (Okano and Tomizuka, 1987; Tian and Noakes, 1991; Kamimura et al, 1993; Sheldon et al, 2003). Besides, the transverse uterine diameter recorded in the present study for the treated and control groups came in inconsistent with previous reports in buffaloes (Usmani et al. 2001; Lohan, et al, 2004; Khasatiya et al, 2006).

From the present study, it can be concluded that the ovsynch protocol is potentially able to improve the ovarian and uterine function when applied during early postpartum in buffaloes, a finding which needs to be confirmed in further study on a bigger number of postparturent buffalo cows.

References:

1. Ali, A; Fahmy, S. 2007: Ovarian dynamics and milk progesterone concentrations in cycling and non-cycling buffalo-cows (Bubalus bubalis) during Ovsynch program. Theriogenology 68: 23-28
2. Amaya-Montoya C, Matsui M, Kawashima C, Hayashi KG, Matsuda G, Kaneko E, Kida K, Miyamoto A, Miyake Y 2007 Induction of ovulation with GnRH and PGF(2 alpha) at two different stages during the early postpartum period in dairy cows:ovarian response and changes in hormone concentrations.J Reprod Dev. 53: 867-875.
3. Awasthi MK ; Khare Abhishek ; Kavani FS ; Siddiquee GM; panchal MT ; shah RR 2006 ; is one-wave follicular growth during the estrous cycle a usual phenomenon in water buffaloes (bubalus bubalis). Animal Reproduction Science 92: 241-253.
4. Barkawi AH, Farghaly HM, El-Borady AM 1995 Effect of treatment with GnRH analogue on postpartum reproductive performance of suckling Egyptian buffalo cows. Buffalo J 11 117-23
5. Baruselli, P. S., E. H. Madureira, V. H. Banarbe R. C. Barnarbe and R. Cassimiro, 2003. Evaluation of synchronization of ovulation for fixed time insemination. Brazilian J. Vet. Res. Anim. Sci.,40 431-442.
6. Demüral, O, -N M, Abay M, Bekyürek T, ضztürk A 2006. The Effectiveness of Cosynch Protocol in Dairy Heifers and Multiparous Cows. Turk J Vet Anim Sci 30 213-217

7. Dufour JJ and Roy GL 1985. Distribution of ovarian follicular populations in the dairy cow within 35 days after parturition. J. Reprod. Fertil. 73:229.
8. El-Wishy AB 2007 The postpartum buffalo: I. Endocrinological changes and uterine involution. Anim Reprod Sci. 97: 201-215.
9. Kamimura S, Ohagi T, Takahashi M, Tsukamoto T 1993 Postpartum resumption of ovarian activity and uterine involution monitored by ultrasography in Holstein cows. J Vet Med Sci 55 643-647
10. Khasatiya CT, Kavani FS, Dhami AJ, Derashri HJ, Panchal MT, Desai PM 2006 studies on puerperal events and reproductive efficiency following hormone therapy at day 42 postpartum in surti buffaloes international journal of agriculture & biology 8 132-137
11. Lohan IS特 Malik RK特 Kaker ML 2004 Uterine involution and ovarian follicular growth during early postpartum period of Murrah buffaloes (Bubalus bubalis). Asian-Australasian Journal of Animal Sciences 17
12. Lucy MC, Staples CR, Michel FM, Thatcher WW, Bolt DJ 1991 Effect of feeding calcium soaps to early postpartum dairy cows on plasma prostaglandin F2 alpha, luteinizing hormone and follicular growth. J. Dairy Sci. 74:483.
13. Madan, M.L., S.K. Das and P. Palta. 1996. Application of reproductive technology to buffalo. Anim. Reprod. Sci., 42: 299-306.
14. Metry, G.H., Wilk, J.K., McDowell, R.E., El-Rigalaty, H.A., 1994. Factors affecting the performance of Egyptian buffalo. Agric. Sci. Moshtohor 32: 775-785.
15. Misra, A.K., M.C. Yadav, and K.T. Motwani. 1988. Successful embryo transfer in a buffalo (Bubalus bubalis).In Proc. of the Second World Buffalo Congress, New Delhi, India, I: 56.
16. Okano A and Tomizuka T 1987 Ultrasonic observation of postpartum uterine involution in the cow. Theriogenology 27 369-376
17. Pattabiraman SR, Veerapandian C, Quayam SA 1986 Effects of Receptal treatment in anoestrus and early postpartum cows and buffaloes. Indian Vet J 63 409-413
18. Paul V, Prakash BS. 2005 Efficacy of the Ovsynch protocol for synchronization of ovulation and fixed-time artificial insemination in Murrah buffaloes(Bubalus bubalis).Theriogenology. 64:1049-1060.
19. Pursley JR, Mee MO, Wiltbank MC 1995 Synchronization of ovulation in dairy cows using PGF2alpha and GnRH. Theriogenology 44:915-923.
20. Roche JF, Mackey D, Diskin MD 2000. Reproductive management of postpartum cows. Anim Reprod Sci. 60-61:703-712 (Review).
21. Roy KS and Prakash BS 2009. Changes in endocrine profiles during ovsynch and ovsynch plus norprolac treatment in Murrah buffalo heifers at hot summer season. Tropical Animal Health and Production 41 677-687
22. Schallenberger E, Schams D, Bullermann B, Walters DL. 1984 Pulsatile secretion of gonadotrophins, ovarian steroids and ovarian oxytocin during prostaglandin-induced regression of the corpus luteum in the cow. J Reprod Fertil. 71:493-501.
23. Sheldon IM, Dobson H 2000. Effect of administration of eCG to postpartum cows on folliculogenesis in the ovary ipsilateral to the previously gravid uterine horn and uterine involution. J Reprod Fert 119 157-163
24. Sheldon IM, Noakes DE, Rycroft AN, Dobson H 2003. The effect of intrauterine administration of estradiol on postpartum uterine involution in cattle. Theriogenology 59:1357-1371

25. Singh J, Nanda AS & Adams GP 2000 The reproductive pattern and efficiency of female buffaloes. Animal Reproduction Science 60 593-604
26. Tian W and Noakes DE 1991 Effect of four hormone treatments after calving on uterine and cervical involution and ovarian activity in cows. Vet Rec 128 566-569.
27. Totey, S.M., G. Singh, M. Taneja and G.P. Talwar.1991. In vitro maturation and fertilization of follicular oocytes from buffalo.Theriogenology, 35: 284.
28. Troxel TR, Kesler DJ. 1984 The effect of progestin and GnRH treatments on ovarian function and reproductive hormone secretions of anestrous postpartum suckled beef cows.Theriogenology. 21:699-711.
29. Usmani RH, Ahmad N, Shafiq P, Mirza MA 2001 Effect of subclinical uterine infection on cervical and uterine involution, estrous activity and fertility in postpartum buffaloes. Theriogenology 55 563-571.
30. Walters AH, Bailey TL, Pearson RE, Gwazdauskasn FC 2008 Parity-Related Changes in Bovine Follicle and Oocyte Populations, Oocyte Quality, and Hormones to 90 Days Postpartum. J Dairy Sci 85 824-832.
31. Warriach HM, Channa AA, Ahmad N 2008. Effect of oestrus synchronization methods on oestrus behaviour, timing of ovulation and pregnancy rate during the breeding and low breeding seasons in Nili-Ravi buffaloes. Anim Reprod Sci. 107 62- 67
32. Wiltbank, M. C., 1997. How information on hormonal regulation of the ovary has improved understanding of the timed breeding programs. In: Proceed. Annual Meeting of Society for Theriogenology, Montereal, Canada, pp: 83-97.

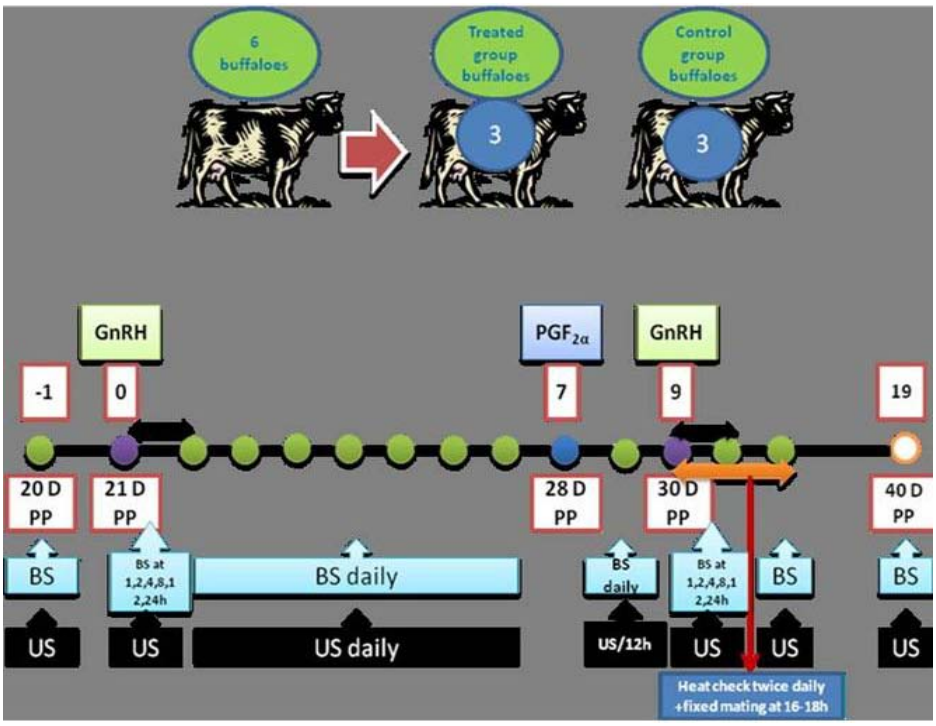

Figure (1): Diagrammatic scheme of ovsynch regimen and protocol of work. US: ultrasound examination; PP: postpartum; GnRH: gonadotrophin releasing hormone; PGF2α: prostaglandin F2α

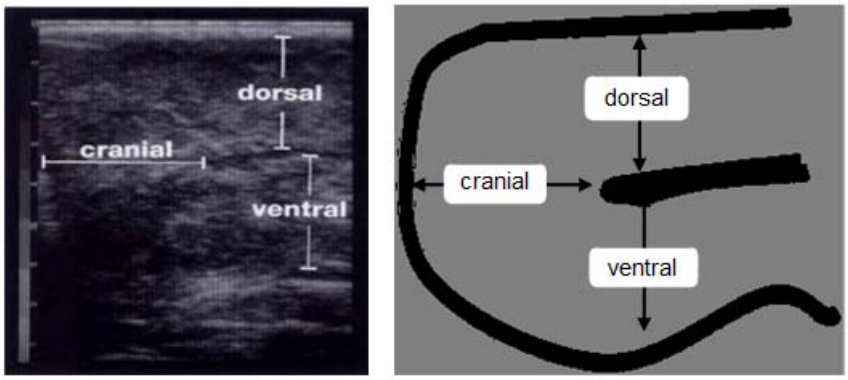

Figure (2): Ultrasonographic measuring of the dorsal, cranial, and ventral diameters of a uterine horn(1)

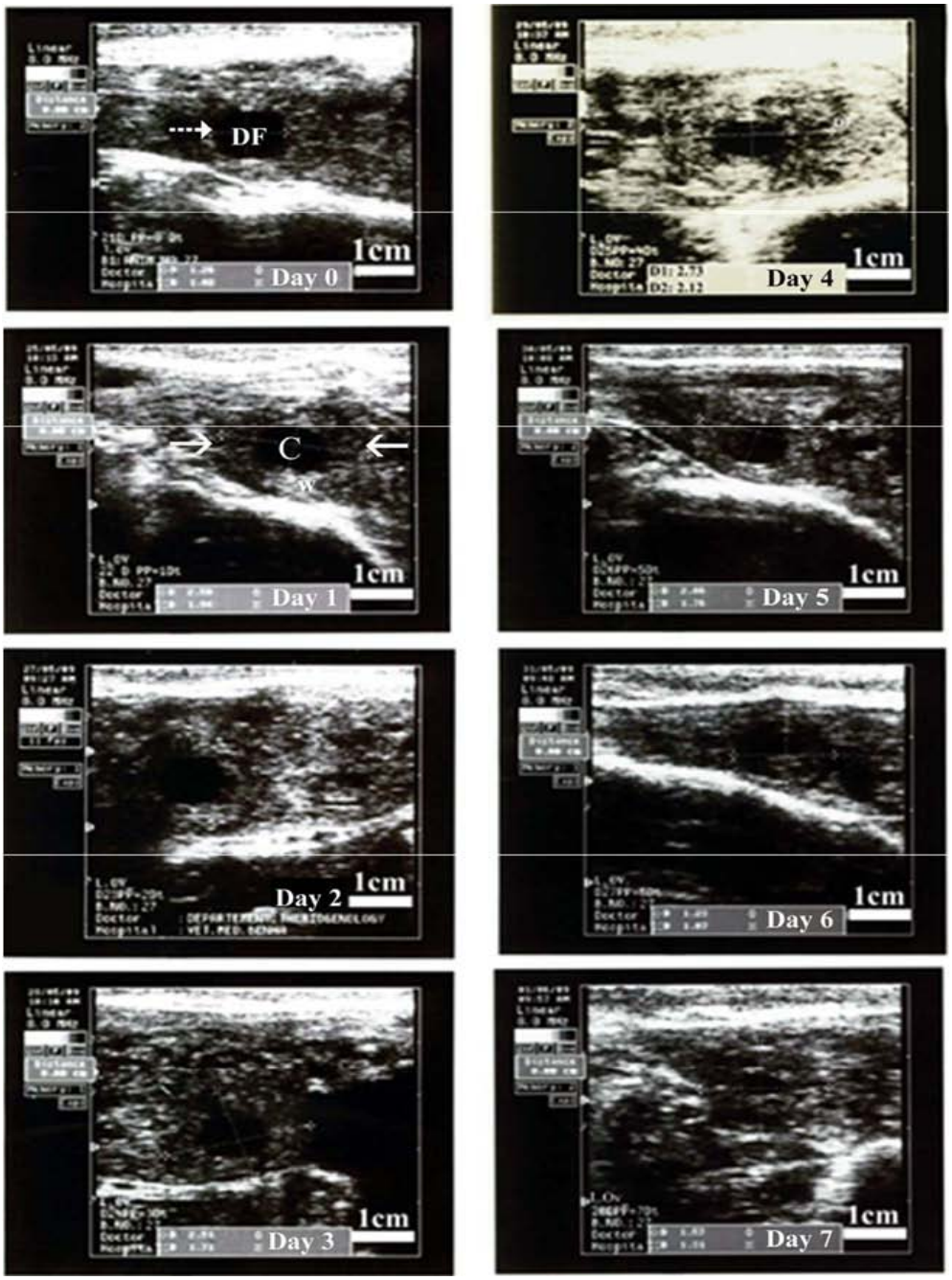

Figure (3): Changes in the characteristics of small follicle population (<0.5cm) in the buffaloes treated and control groups following ovsynch (GnRH-PGF2α-GnRH) protocol started on day 21 days postpartum .Both follicular number)A (and area)B (did not differ significantly between the two groups along the monitored period .Values presented were means.

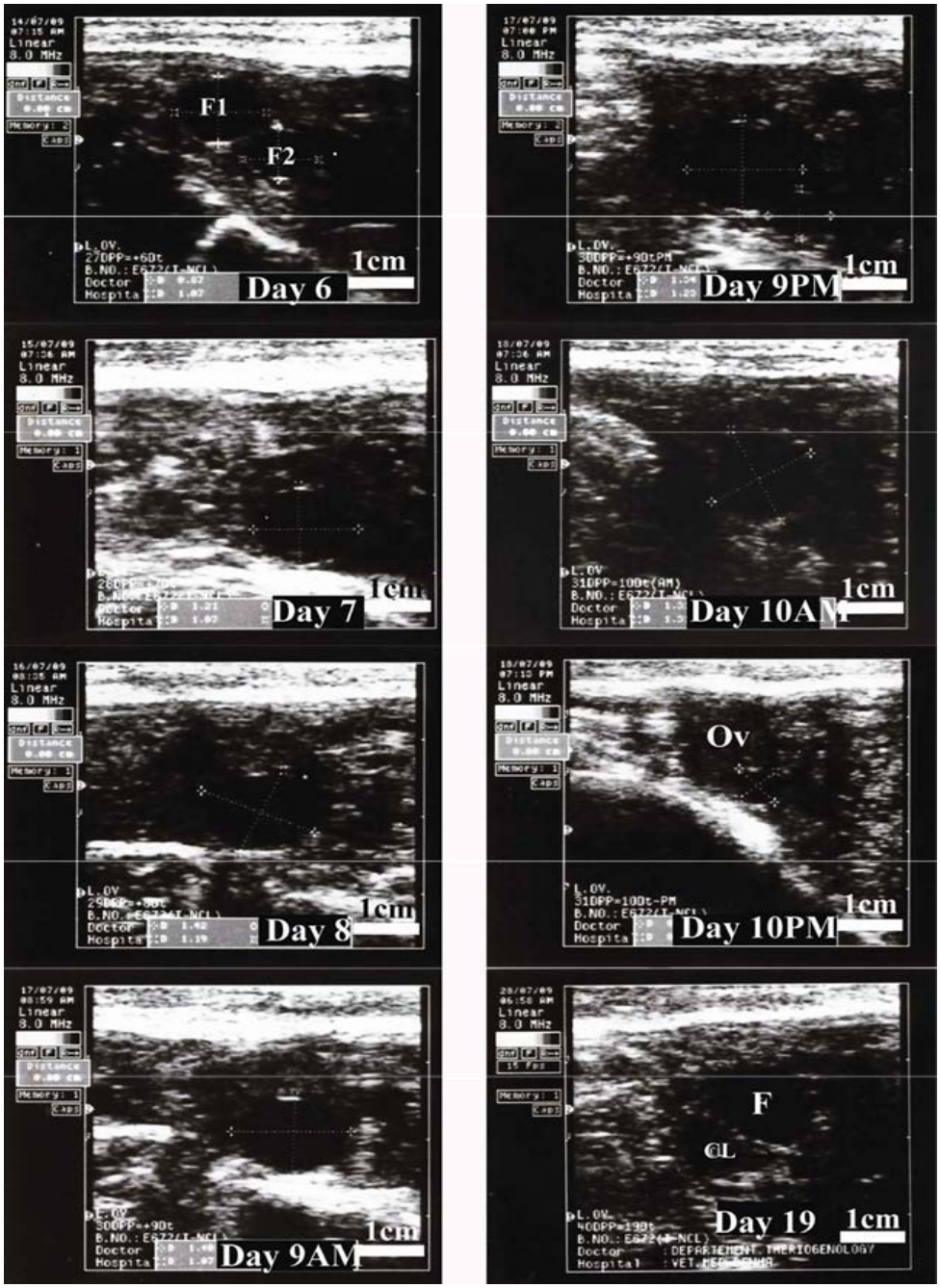

Figure (4): Changes in the characteristics of medium follicle population (0.5-1.0 cm) in the buffaloes treated and control groups following ovsynch)GnRH-PGF2α-GnRH (protocol started on day 21 days postpartum .Both follicular number)A (and area)B (did not differ significantly between the two groups along the monitored period .Values presented were means.

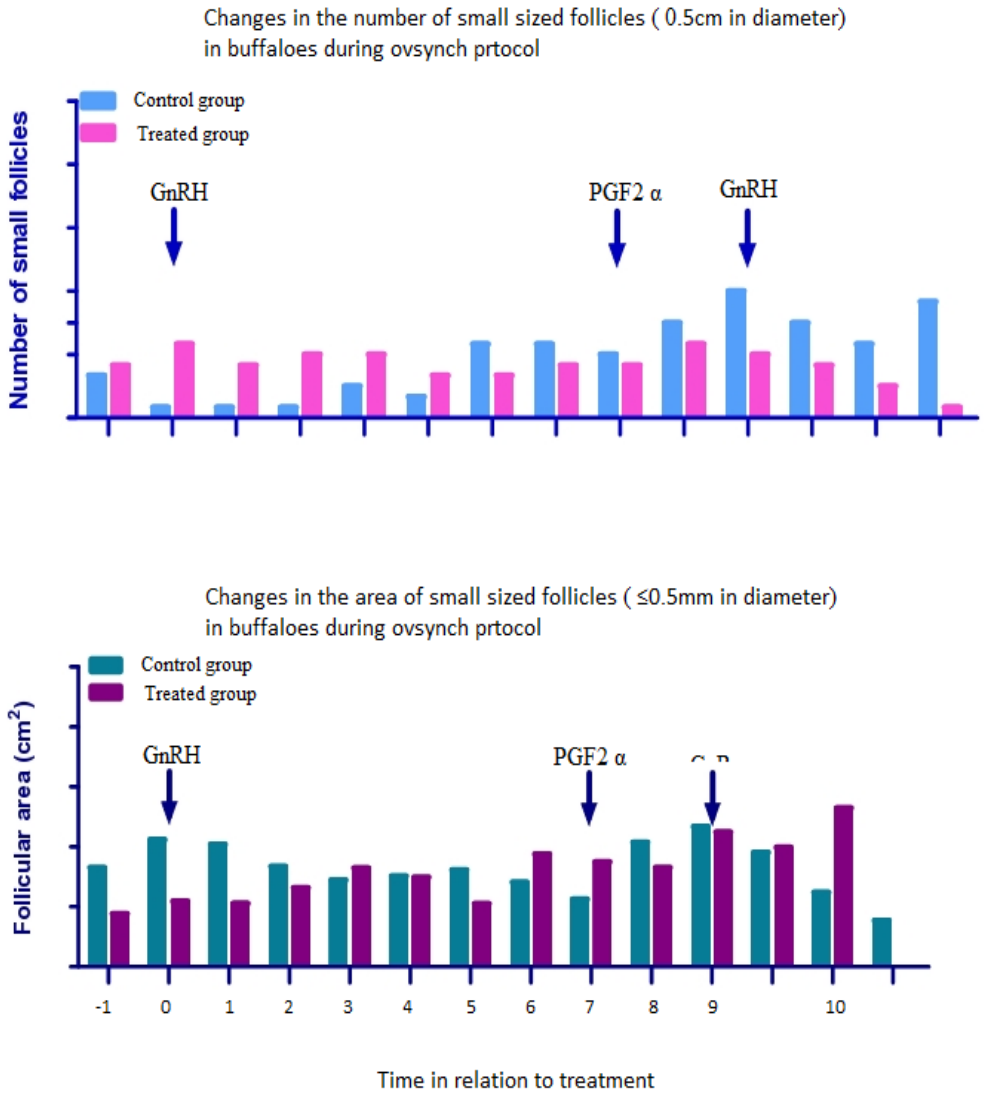

Figure (5): Changes in the characteristics of large follicle population (>1.0cm) in the buffaloes treated and control groups following ovsynch (GnRH-PGF2α-GnRH) protocol started on day 21 days postpartum . Both follicular number (A) and area (B) did not differ significantly between the two groups along the monitored period .Values presented were means

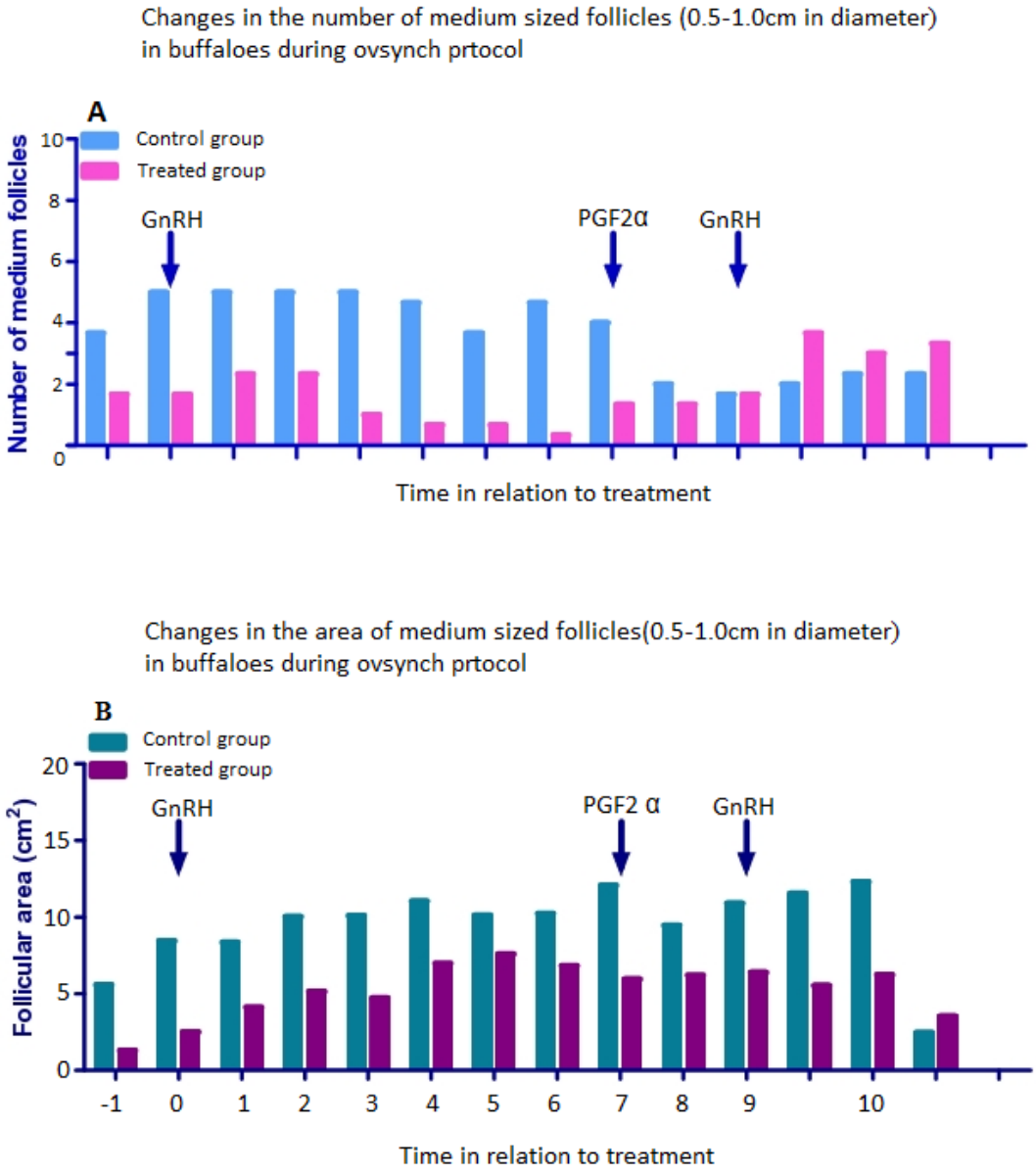

Figure (6): Changes in the characteristics of total follicle population (> 0.2cm) in the buffaloes treated and control groups following ovsynch (GnRH-PGF2α-GnRH) protocol started on day 21 days postpartum . Both follicular number (A) and area (B) did not differ significantly between the two groups along the monitored period .Values presented were means.

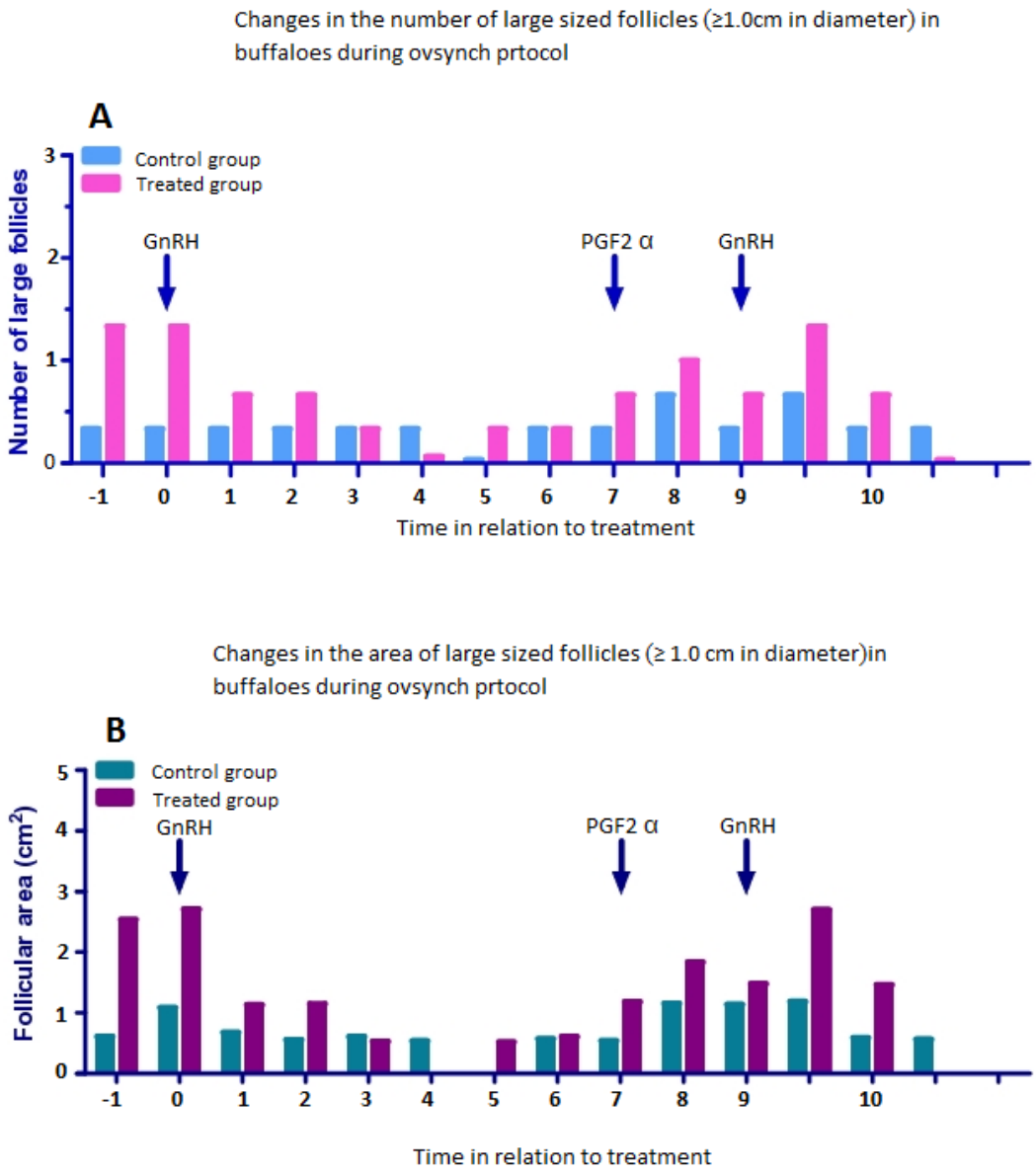

Figure (7): Representative patterns of follicular growth and regression on the ovary of buffaloes treated with ovsynch protocol 21 days postpartum .The largest follicle in the treated group showed a unique pattern of growth that ended by ovulation in one buffalo while regressed in the other two animals .Dotted and dashed lines refer to timing of GnRH and PGF2α treatment, respectively .Lut :luteinization; Ov :ovulation.

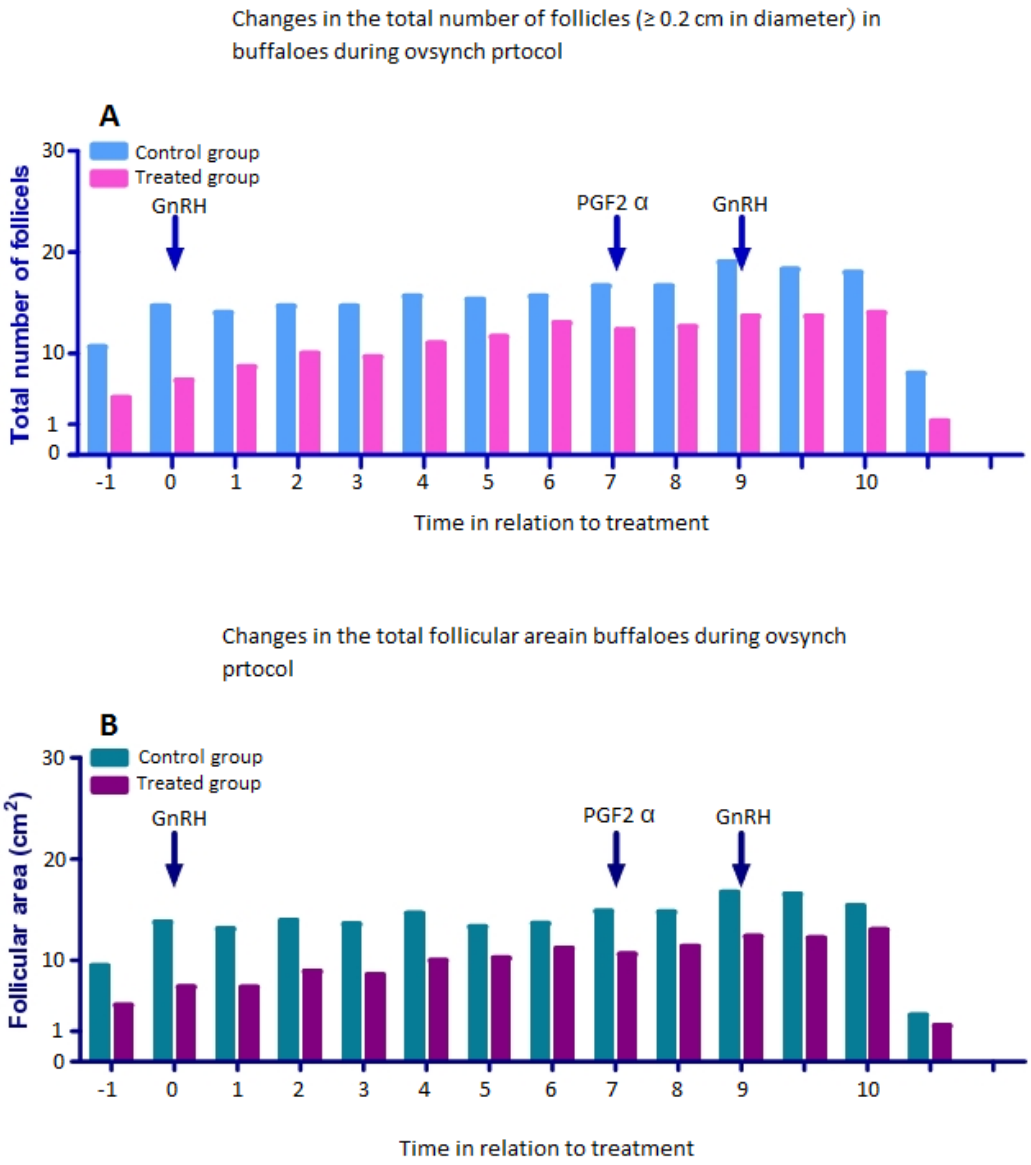

Figure (8): The pattern of induce luteal tissue development and regression on the ovary of 8treated buffaloes with ovsynch protocol 21days postpartum. The luteinization of dominant follicle started on Day 1 .The luteal tissue volume showed a rapid decrease per unit of time as compared with luteal tissue diameter

Table 7: Characteristics (Mean ± S.E.M) of the ovarian waves in Egyptian Buffalo cows treated with ovsynch during early postpartum period

parameters	Treated group		Control group		P-value	
	Mean	±SEM	Mean	±SEM	F-test	t-test
Diameter of dominant at start of treatment (cm)	1.38a	0.12	0.98b	0.06	0.360	0.039
Max .follicle diameter after treatment (cm)	1.38	0.18	1.01	0.10	0.462	0.139
Growth rate of the dominant follicle (mm/d)	1.49	0.07	1.65	0.17	0.243	0.453
Length of growth phase (days)	8.00	1.53	5.67	0.67	0.320	0.234
Range	5 – 10 days		5 – 7 days			
Day of emergence of the dominant follicle	2.33	1.45	2.67	2.03	0.679	0.900
Range	2 – 5 days		1 – 6 days			
Beginning diameter (cm)	0.45	0.06	0.43	0.03	0.316	0.813
Day of maximum diam. of the dominant follicle	9.33	0.33	6.33	1.45	0.100	0.114
Range	9 – 10 days		4 – 9 days			
Day of emergence of the 1st wave after treatment	2.33	0.33	4.33	0.88	0.250	0.101
Range	2 – 3 days		3 – 6 days			
Linear growth rate of the dominant follicle	0.40	0.09	0.29	0.19	0.339	0.637
max diameter of 2nd largest follicle	1.00	0.02	0.88	0.16	0.044	0.520
Day of deviation	6.67	1.20	4.33	0.67	0.471	0.165
Range	5 – 9 days		3 – 5 days			

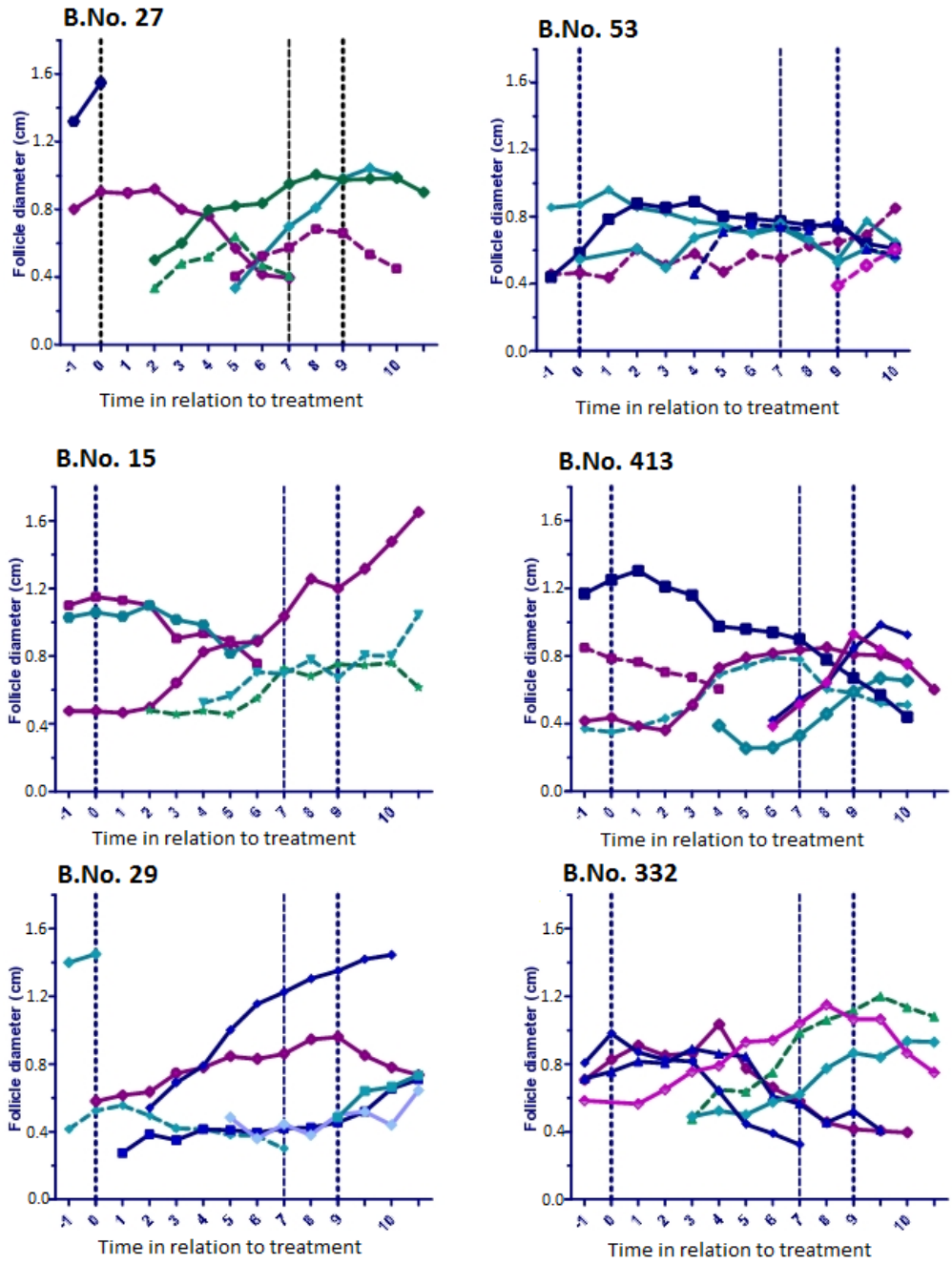

Figure (9): A representative ultrasonographic pictures of the uterus on Day 0, 2, 7, 10 in the treated (right side panel) and control (left side panel) buffaloes with ovsynch protocol started on Day 21 postpartum. The homogencity of the uterine wall increased, while the lumen diameter and echogenicity decreased in the treated group compared with control . The arrow refers to the detectable uterine lumen in the control group on Day 10.

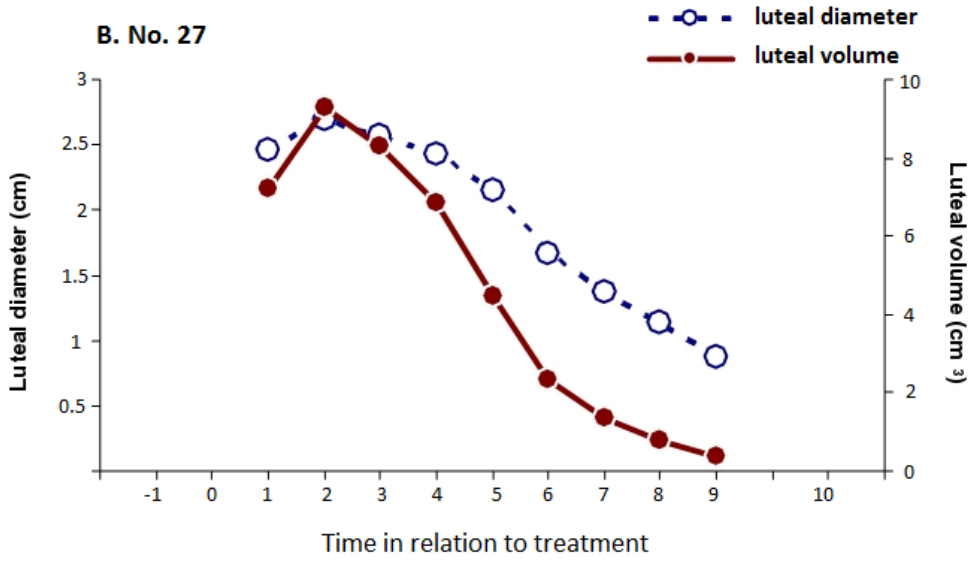

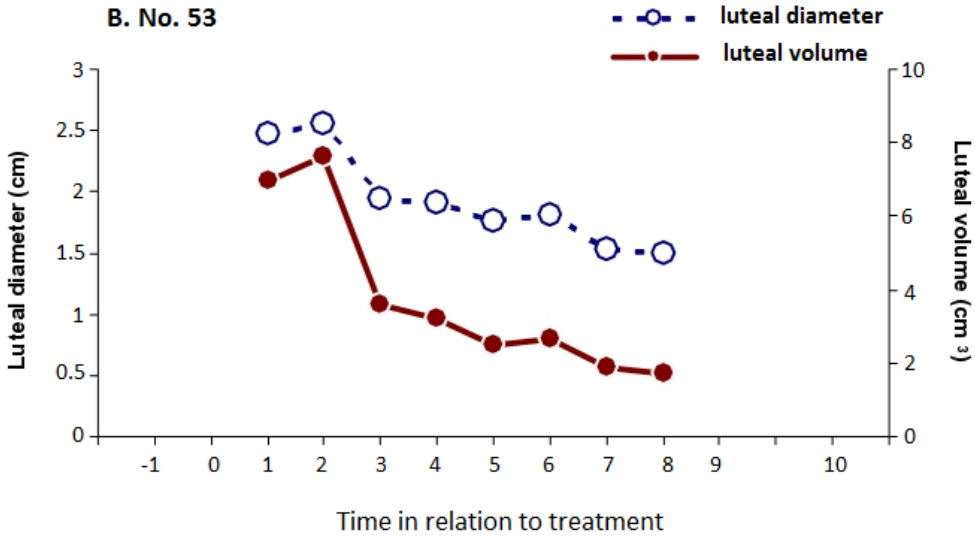

Figure (10): Changes in the uterine dorsal (A), cranial (B) and ventral diameter of the uterine wall in the treated and control groups treated with ovsynch protocol started on Day 21 postpartum. The cranial and ventral diameter of uterine horn (s) increased significantly in the treated group due to the increase in vascularity accompanying the onset of estrus .Values presented are mean ± SEM * .P<0.05, **P<0.001.

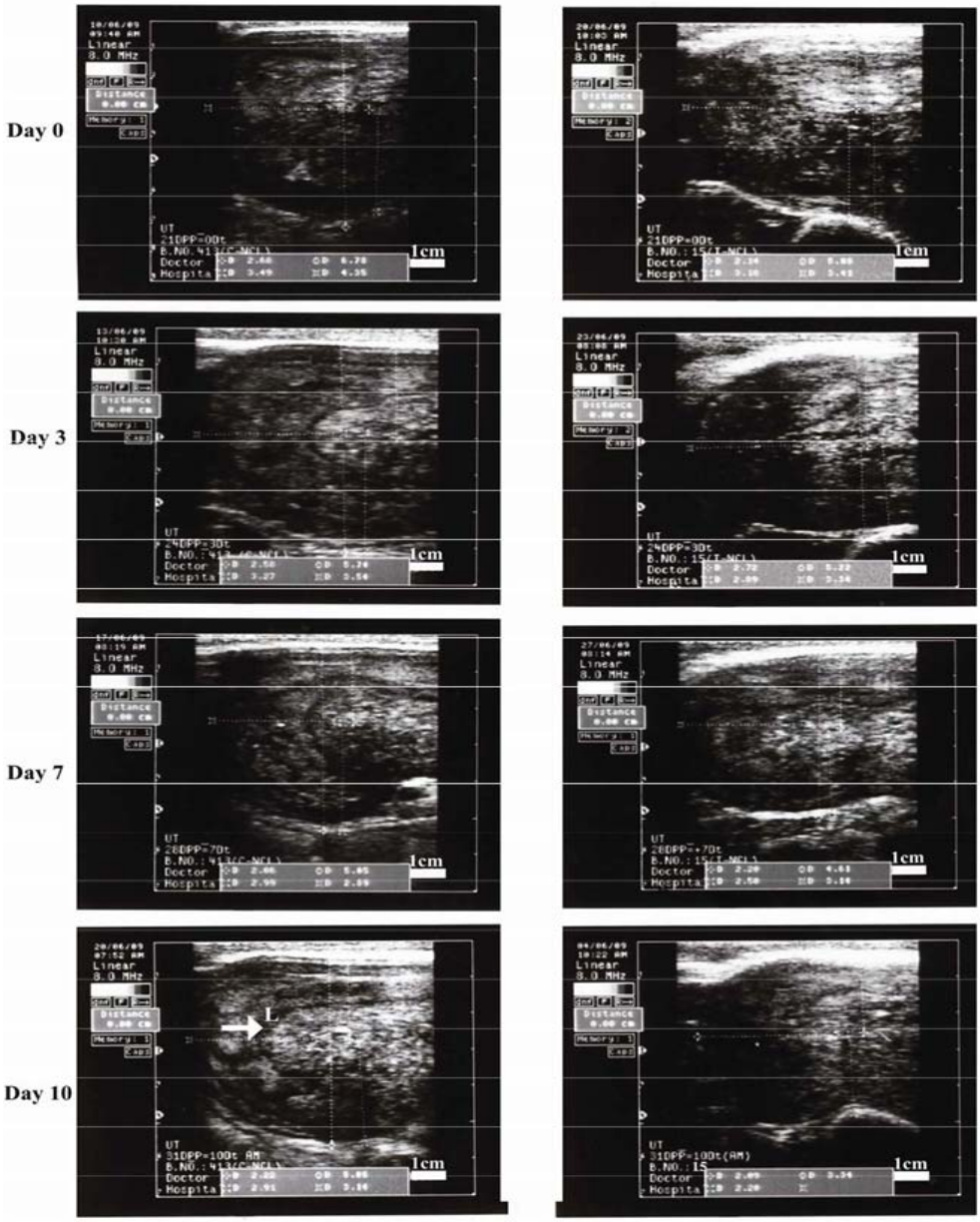

Figure (11): Changes in the transverse uterine diameter (A) and lumen (B) in the treated and control groups treated with ovsynch protocol started on Day 21 postpartum. If the diameter taken as a guide to confirm the uterine involution (<3cm), it did not complete neither in treated nor in control groups .If the lumen diameter used as a guide (<0.3cm), the uterus of treated animals involuted by Day 7(i.e .28 days PP). The uterine lumen showed a progressive and significant decrease in the treated animals compared with the control group. Values presented are mean ± SEM * .P<0.05, **P<0.001.

THE DIAGNOSTIC AND PROGNOSTIC VALUE OF PERITONEAL FLUID ANALYSIS IN COLIC IN ARABIAN HORSE

Wael M. EL-Deeb and Taha A. Fouda
Department of clinical studies, college of Veterinary Medicine and Animal Resources King Faisal University, Saudi Arabia
drwaeleldeeb@yahoo.com

ABSTRACT

This study was carried out on 50 horse (40 suffered abdominal pain and 10 clinically healthy) 4-7 years old. The selected horses were categorized into five equal groups depending on the clinical and laboratory examination. The 1st group (control group), the 2nd group suffered spasmodic colic, the 3rd group suffered flatulent colic, the 4th group suffered large intestinal impaction, and 5th group suffered obstructive colic. Two blood samples were obtained from each horse. The first sample was whole blood and the second blood samples were used for obtaining blood sera for estimation of selected parameters. Moreover peritoneal fluid samples were obtained from all horses. Clinical examination of all horses were done and recording of all clinical signs in all groups. The obtained results of laboratory analysis of the 2nd, 3rd and 4th group revealed non significant changes in blood, and peritoneal fluid analysis while there was a significant decrease in glucose level followed by significant increase toward normal levels following treatment. In addition to significant decrease in bicarbonate levels with a significant increase in lactate levels before treatment with a significant increase in bicarbonate levels and significant decrease in lactate levels toward the normal levels after treatment in group 4. The 5th group revealed a significant increase in PCV, TCO_2 with significant decrease in total leucocytic count and bicarbonate levels before and after treatment. The serum analysis of glucose revealed a high significant increase in glucose levels before and after treatment. The plasma analysis for lactate revealed a significant increase in lactate levels before and after treatment. The peritoneal fluid analysis revealed pink colored peritoneal fluid tends to clotted with a significant increase in total protein, T. RBCs and T. WBCs before and after treatment. In addition to a high significant increase in lactate levels before and after treatment. From this study I could be concluded that blood and peritoneal fluid parameters can be used as prognostic parameters in horses with colic, particularly the changes in peritoneal fluid picture and lactate levels as the peritoneal fluid lactate occur more obvious than that of plasma lactate

Key words: Horses, peritoneal fluid, colic, blood gases, lactate

INTRODUCTION

Colic is known as the number one cause of equine death. This is a scary statistic, but if you know what to do to prevent the affliction as well as the common symptoms, the danger is less severe. Most horses can survive if they get the proper help soon enough ***(Tony and Marcy, 1996)***. On the other side ***Germain and Phillp, (2001)*** reported that colic is

one of the most frequent problem encountered by equine veterinarian & there are numerous causes and types of equine colic.

From another point of view ***Pascoe et al., (1990)*** declared that the cost of treating a horse with colic, where surgical or intensive medical management are necessary can be very high. The owner is usually concerned about the prognosis for the horse and would like to understood the risks involved in such expensive treatment.

Changes in the composition of peritoneal fluid reflect changes occurring at the peritoneal surfaces of organs within the abdominal cavity. The analysis of peritoneal fluid is most useful in monitoring the progression of persistent, intractable colics and identifying peritonitis ***(Taylor and Hillyer, 1997 and Delesalle et al., 2007)***

The capacity of peritoneal fluid analysis was consider of great important in equine colic branch in diagnostic decision rule for support in clinical assessment of the need for surgical intervention in horses with acute abdominal pain ***(Martin et al., 2003).***

The estimation of blood gases was considered the corner stone in the diagnosis and prognosis of horses with abdominal pain ***(Malley, 1990, Stamplfi and Carlson 2001 and Radostistis et al., 2007).***

This study was designed in order to investigate the role of blood and peritoneal fluid analysis as a diagnostic and prognostic tool in cases of equine colic.

MATERIALS AND METHODS

ANIMALS

A total number of 50 horse (40 suffered abdominal pain and 10 clinically healthy) 4-7 years old had been subjected to this study. The selected horses were categorized into five groups depending on the clinical and laboratory examination. The 1st group (control group) included 10 horses, the 2nd group includes 10 horses suffered spasmodic colic, the 3rd group includes 10 horses suffered flatulent colic, the 4th group includes 10 horses suffered large intestinal impaction, and 5th group includes 10 horses suffered obstructive colic.

Sampling protocol:

A) Two blood samples were collected from each horse by arterial (common carotid artery) & venous puncture. The arterial blood sample was used for the estimation of blood gases and bicarbonate levels. While the venous sample (jugular vein) was divided into two samples the 1st was used for estimation of PCV, TLC and separation of plasma which used for estimation of lactate levels and the 2nd samples were obtained on non heparinized tubes for obtaining serum which used for estimation of glucose and lactate levels respectively. Blood samples had been obtained from diseased horse in two occasions, one before treatment and second after treatment.

B) Peritoneal fluid samples.

Adopted methods

a) Total leucocytic count:

Total leucocytic count(X10^3) was carried out using hemocytometer ***(Coles, 1986)***

b) PCV: The PCV was carried out according to the method described by ***Coles, (1986)***

c) Blood gases: The estimation of blood gases and bicarbonate levels were carried out according to the method described by ***Reeves et al., (1989*)**.

d) Biochemical analysis of blood sera samples: Biochemical analysis of blood sera samples for glucose levels was carried out according to the method described by ***Trinder (1969)***

The estmation of lactate in plasma and peritoneal fluid was carried out using enzymatic colorimetric method using commercially available test kits according to the method described by ***Donawick et al., (1974) and Delesalle et al., (2007)***

e) Peritoneal fluid analysis: The Peritoneal fluid analysis was carried out according to the method described by ***Taylor et al., (1997).***

f) Treatment trials

The 2ndgroup was treated by Buscopan compositium (N-butylescopolammonium bromide, Dipyrone) at a dose rate of 0.2mg/kg B. Wt. and 20mg/kgm B. Wt respectively by I/V injection., nasogastric intubations of liquid paraffin in a dose of 3-5 liters ,rectal enema with warm water and saline solution. The 3rd group was treated by liquid paraffin in a dose of 3-5 liters, flunixine meglumine (1.1 mg/kg B.wt every 12 hours), and bloatzal at a dose rate of 100ml /head through nasogastric tube, rectal enema and saline solution. The 4th group was treated by liquid paraffin in a dose of 3-5 liters, flunixine meglumine (1.1 mg/kg B.wt every 12 hours), and isotonic sodium bicarbonate solution 1.3% and sodium sulphate in a dose rate of 1gm /kg body weight by nasogastric intubations. The 5th group was treated by flunixine meglumine (1.1 mg/kg B.wt every 12 hours).

Statistical analysis

The obtained data were statistically analyzed for means and significance between the groups using **ANOVA** according to ***Snedecor and Cochran (1982)*** by using ***SPSS*** computerized system.

RESULTS

The clinical examination of the horses in the 2nd group revealed anorexia, intermittent abdominal pain manifested by lying down vigoursly and getting up, patchy sweating and increased intestinal borborygomi in auscultation. From another side, horses of the 3rd group showed moderate, continuous abdominal pain, lying down very carefully, and sluggish intestinal peristalsis on auscultation. The horses of the 4th group revealed moderate abdominal pain, decreased fecal output, the feces was hard, dry and mucous covered, anorexia, decreased water intake, decreased intestinal sound on auscultation, horses stretches and looks at its flank, and distended cecum and colon on rectal examination. Finally horses in 5th group revealed sever continuous abdominal pain, excessive sweating, absence of defecation, clean rectum with sever intestinal distension on rectal examination, elevated pulse rate (102±1.2), and cyanotic mucous membrane.

The obtained results of laboratory analysis of the 2nd, 3rd and 4th group revealed non significant changes in blood, and peritoneal fluid analysis while there was significant decrease in glucose level followed by significant increase toward normal levels following treatment. Moreover there was a significant decrease in bicarbonate levels with a significant increase in lactate levels in the 4th group only followed by a significant increase in bicarbonate and significant decrease in lactate levels toward the normal levels following treatment.

The 5th group revealed a significant increase in PCV, TCO_2 with significant decrease in total leucocytic count and bicarbonate levels before and after treatment. The serum analysis of glucose revealed a high significant increase in glucose level before and after treatment. The serum analysis of lactate revealed a significant increase before and after treatment. From another side the peritoneal fluid analysis revealed pink colored peritoneal

fluid tends to clotted with a significant increase in total protein, T. RBCs and T. WBCs with high significant increase in lactate levels before and after treatment.

Discussion

Several studies indicate that blood and peritoneal fluid analysis can be used as prognostic parameters in horses with colic ***(*Delesalle et al., 2007).**

The obtained results revealed that group 2 showed anorexia, intermittent abdominal pain manifested by lying down vigoursly and getting up, patchy sweating and increased intestinal borborygomi in auscultation. These results were in concern with those obtained by ***Parry, (1986)**, **Kamphues and Schad, (1992) and Radostits et al., (2007)**.*

The result of abdominal pain was attributed to stimulation of nociceptor in the intestine as a result of increased peristalsis ***(Radostits et al., 2007)**.*

The obtained results of group 3 there was moderate, continuous abdominal pain, lying down very carefully, and sluggish intestinal peristalsis on auscultation. These results were in concurrence with those obtained by ***Jack, and Sharon, (1997)*** *and* ***OGilivie, (1998)**.*

The result of abdominal pain was attributed to stimulation of nociceptor in the intestine as a result of intestinal distension and stretching of the intestinal mucosa which consequently leading to sluggish intestinal motility ***(Michael, (1999) and Radostits et al., (2007)**.*

The obtained results revealed that group 4 showed mild abdominal pain, dry hard fecal balls and decreased intestinal peristalsis on auscultation. These results were in harmony with those obtained by **OGilivie, (1998)**, ***Noah and Kenneth, (1999)*** and ***EL-Ghareib and Nasser, (2003)**.*

The abdominal pain in such clinical cases was attributed to stimulation of nociceptor in the intestine as a result of distension. While hard fecal balls were attributed to stagnation of intestinal peristalsis and lack of fluid content ***(Smith, 1996, Tony and Marcy, 1996 and Beyer et al., 1999).***

Regarding the laboratory results of the 2nd, 3rd and 4th groups there were non significant changes in blood, and peritoneal fluid analysis, while there was significant decrease in glucose level followed by significant increase toward normal levels following treatment. Moreover there were a significant decrease in bicarbonate levels with a significant increase in lactate levels in the 4th group only with a significant increase in bicarbonate levels and significant decrease in lactate levels toward the normal levels following treatment. These results were in agreement with those obtained by ***Smith, (1996)**, **Norbert, (1996), Taylor and Hillyer (1997), Reuben and Devid (1998), Lobes et al., (2002), Delesalle et al., (2007) and Radostits et al., (2007)**.*

The reduction in glucose levels were attributed to anorexia and exhaustion which accompanied the colicy pain ***(Ismail, 1995, and Attia, 2000).*** While the decreased levels of bicarbonate and increased levels of lactate in the 4th group was attributed to the metabolic acidosis resulting from the rapid fermentation of ingested concentrate and increased the biosyntheses of L. isomer of lactic acid (**William et al., 1997).**

Concerning the clinical examination of the 5th group there was sever continuous abdominal pain, excessive sweating, absence of defecation, clean rectum with sever intestinal distension on rectal examination, elevated pulse rate (102±1.2), and cyanotic mucous membrane. These results were in consensus with those obtained by ***White, (1990), Smith, (1996), Tony and Marcy, (1996) and Beyer et al., (1999), Delesalle et al., (2007) and Radostits et al., (2007)**.*

Severe abdominal pain was attributed sever abdominal distension with over stretching of the intestine making sever stimulation of nociceptors ***(Taylor and Hillyer, 1997 and Attia, 2000)***. The absence of intestinal peristalsis with absence of defecation and high pulse rate are cardinal signs of intestinal obstruction (***Susan and Denise, 1997 and Stephen, 1999)***.

The obtained results of laboratory analysis revealed a significant increase in PCV and leucopenia. These results were in harmony with those obtained by ***Robin et al., (1995), Ajdart et al., (1997) and Susan and Denise, (1997).***

The increased PCV was attributed to hypovolemia and low tissue perfusion, while leucopenia was attributed to endotoxemia from the devitalized part of the intestine ***(Doran, 1993, Noah and Keneth 1999 and Radostits et al., 2007).***

Furthermore there was a significant increase in glucose, lactate and TCO_2 levels with a significant decrease in bicarbonate levels before and after treatment. These results were in concern with those obtained by ***Robin et al., (1995) and Ajdart et al., (1997).***

The significant increases in TCO2 were attributed to the endotoxemic state and failure of compensatory mechanisms of the lung and kidney to compensate metabolic acidosis, while the significant increase in lactate with the significant decrease in bicarbonate was attributed to sever metabolic acidosis and anaerobic glycolysis metabolism of skeletal muscles ***(Germain and Philip, 2001 and Delesalle et al., 2007).*** In addition hyperglycemia was attributed to stress of endotoxemia ***(Noah and Keneth 1999)***.

Interestingly, peritoneal fluid changes revealed significant changes in the color and composition as there were significant increase in total protein, RBCs count and WBCs count. Moreover there was a high significant increase of lactate levels in peritoneal fluid which was more obvious than plasma lactate levels. These results were in agreement with those obtained by ***Taylor et al., (1997), Noah and Keneth (1999) and Radostits et al., (2007).***The dramatic changes in the peritoneal fluid analysis were attributed to severe peritonitis which resulted from endotoxemia. While the increased lactate levels was attributed to sever metabolic acidosis and the anaerobic glycolysis which resulted from inadequate intestinal perfusion and ischemia. ***(Norbert, 1996, Tim et al., 1998, Kenneth, 1999, and Delesalle et al., 2007).***

After treatment there was a significant improvement in the clinical and laboratory picture in all cases of group 2, 3 & 4.

From this study it could be concluded that blood and peritoneal fluid parameters can be used as prognostic parameters in horses with colic, particularly the changes in peritoneal fluid picture and lactate levels as the changes in peritoneal fluid lactate occurs more obvious than that of plasma lactate

Table (1): The selected blood, plasma and serum changes in controls and horses with colic

Item	Group(1) (Control)	Group(2) Before treatment	Group(2) After treatment
PCV%	37.8±0.74 [a]	37.9±0.73 [a]	37.7±0.44 [a]
TLC (x 10^9/l)	8.42±0.42 [a]	8.47±0.32 [a]	8.44±0.56 [a]
TCO2 (mmHg)	33.5±0.64 [a]	31.2±0.33 [a]	32.4±0.55 [a]
Bicarbonate (mmol/l)	27.4±0.56 [a]	27.1±0.23 [a]	27.5±0.43 [a]
Glucose (mg/dl)	62.45±0.66 [a]	58.44±0.73 [b]	60.5±0.45 [a]
Lactate (mmol/l)	1.1±0.04 [a]	1.13±0.05 [a]	1.14±0.02 [a]

The different superscript within the column is significantly differ; while the same superscript within the column is none significantly differ. P<o.o5

Table (2). The selected blood, plasma and serum changes in controls and horses with colic

Item	Group(1) (Control)	Group(3) Before treatment	Group(3) After treatment
PCV%	37.8±0.74[a]	37.2±0.73[a]	37.6±0.44[a]
TLC (x 10^9/l)	8.42±0.42[a]	8.41±0.32[a]	8.49±0.56[a]
TCO2 (mmHg)	33.5±0.64[a]	32.9±0.33[a]	32.9±0.55[a]
Bicarbonate (mmol/l)	27.4±0.56	27.3±0.24[a]	27.2±0.44[a]
Glucose (mg/dl)	62.45±0.66[a]	58.44±0.73[b]	60.5±0.45[a]
Lactate (mmol/l)	1.1±0.04[a]	1.1±0.05[a]	1.21±0.03[a]

The different superscript within the column is significantly differ; while the same superscript within the column is none significantly differ. P<o.o5

Table (3). The selected blood and serum changes in controls and horses with colic

Item	Group(1) (Control)	Group(4) Before treatment	Group(4) After treatment
PCV%	37.8±0.74[a]	37.9±0.73[a]	37.8±0.44[a]
TLC (x 10^9/l)	8.42±0.42[a]	8.44±0.32[a]	8.41±0.56[a]
TCO2 (mmHg)	33.5±0.64[a]	33.2±0.33[a]	33.4±0.55[a]
Bicarbonate (mmol/l)	27.4±0.56	21.3±0.24[a]	26.2±0.44
Glucose (mg/dl)	62.45±0.66[a]	58.44±0.73[b]	60.5±0.45[a]
Lactate (mmol/l)	1.1±0.04[a]	1.9±0.05[b]	1.2±0.03[a]

The different superscript within the column is significantly differ; while the same superscript within the column is none significantly differ. P<o.o5

Table (4). The selected blood and serum changes in controls and horses with colic

Item	Group(1) (Control)	Group(5) Before treatment	Group(5) After treatment
PCV%	37.8±0.74[a]	48.5±o.45[b]	54.6±0.67[b]
TLC (x 10^9/l)	8.42±0.42[a]	7.68±0.34[a]	7.34±0.45[b]
TCO2 (mmHg)	33.5±0.64[a]	33.33±0.36[b]	33.66±33[b]
Bicarbonate (mmol/l)	27.4±0.56[a]	21.3±0.24[b]	21.2±0.44[b]
Glucose (mg/dl)	62.450.66[a]	55.44±0.55[b]	190.4±1.3[c]
Lactate (mmol/l)	1.1±0.04[a]	4.9±0.5[b]	5.1±0.6[b]

The different superscript within the column is significantly differ; while the same superscript within the column is none significantly differ. P< o.o5

Table (5). Comparisons of peritoneal fluid analysis in controls and horses with colic

Item	Group1 (Control)	Group2 Before treatment	Group2 After treatment
Color	Pale yellow, clear	Pale yellow, clear	Pale yellow, clear
Total protein gm/dl	1.23± 0.01 [a]	1.24± 0.02 [a]	1.1±0.02 [a]
RBCs X10^6 /ul	-	-	-
T. WBCsX10^6 /ul	2.45± 0.34 [a]	2.67± 0.73 [a]	2.34± 0.44 [a]
Lactate (mmol/l)	1.4±0.4 [a]	1.5±0.3 [a]	1.3±0.2 [a]

The different superscript within the column is significantly differ; while the same superscript within the column is none significantly differ. P<o.o5

Table (6). Comparisons of peritoneal fluid analysis in controls and horses with colic

Item	Group1 (Control)	Group3 Before treatment	Group3 After treatment
Color	Pale yellow, clear	Pale yellow, clear	Pale yellow, clear
Total protein gm/dl	1.23± 0.01 [a]	1.14± 0.03 [a]	1.1±0.02 [a]
RBCs X10^6 /ul	-	-	-
T. WBCsX10^6 /ul	2.45± 0.34 [a]	2.57± 0.73 [a]	2.44± 0.44 [a]
Lactate (mmol/l)	1.4±0.4 [a]	1.3±0.3 [a]	1.4±0.2 [a]

The different superscript within the column is significantly differ; while the same superscript within the column is none significantly differ. P<o.o5

Table (7). Comparisons of peritoneal fluid analysis in controls and horses with colic

Item	Group1 (Control)	Group4 Before treatment	Group4 After treatment
Color	Pale yellow, clear	Pale yellow, clear	Pale yellow, clear
Total protein gm/dl	1.23± 0.01 [a]	1.24± 0.02 [a]	1.2±0.02 [a]
RBCs X10^6 /ul	-	-	-
T. WBCsX10^6 /ul	2.45± 0.34 [a]	2.55± 0.73 [a]	2.54± 0.44 [a]
Lactate (mmol/l)	1.4±0.4 [a]	2.4±0.3 [b]	1.5±0.1 [a]

The different superscript within the column is significantly differ; while the same superscript within the column is none significantly differ. P<o.o5

Table (8). Comparisons of peritoneal fluid analysis in controls and horses with colic

Item	Group1 (Control)	Group 5 Before treatment	Group 5 After treatment
Color	Pale yellow, clear	Pink color	Pink color, turbid
Total protein	1.23± 0.01 [a]	2.66± 0.1 [b]	3.45± 0.44 [b]
RBCs	-	1.1± 0.02	1.2±0.045 [b]
T. WBCs	2.45± 0.34 [a]	30.4± 0.33 [b]	45.44± 0.58 [b]
Lactate (mmol/l)	1.4±0.42 [a]	10.3±0.32 [b]	12.5±0.56 [b]

The different superscript within the column is significantly differ; while the same superscript within the column is none significantly differ. P<o.o5.

REFERENCES

Ajdart, D. R. ; Hodgson and Snyder, G. R. (1997): Caecal disease in equids. Aust. Vet. J. 1997; 75: 552-557.

Attia, (2000): Clinical, hematological and biochemical studies on equine colic. Suez Canal Vet. Med. Journal, III (1): 337-346.

Beyer, T. D.; Hunt, R. J. and Hagyard, D. M. (1999): 4250 Iron works pike, Lexington ky USA, 40511. Beyer TD. Proceedings 17th Bain-Fallon Memorial lecures, 27-33.

Campbell, M. L, Colhan, P. C, Brown, M. P. (1984): Cecal impaction in the horse. J. Am Vet Med Assoc; 184: 950-952.

Delesalle, C., Jeron, D., Romain, A., Lefebvre J., Joachim, P., Laurence, L., and Piet, D. (2007): *Determiunation of lactate concentrations in blood plasma and peritoneal fluid in horses with colic by an accusport analyzer.* J., Vet. Intern. Med, 21: 293-301.

D'Mello and JPF (2000): Farm animal metabolism and nutrition. CABI publishing, Biddles Ltd, Guildford and King's lynn, New York, sUSA**.**

Cohen N. D., Matejka P. L. and Honnas, C. M. (1995): Case-control study of mangment factors associated with equine colic. J. Am. Vet. Med. Assoc. 206:667-673.

Coles, (1986): Veterinary clinical pathology. 4th Ed., W. B Saunders company, Philadelphia, London and Toronto.

Donawick W. J., Rambreg C. F. and Paul S. R. (1975): the diagnostic and prognostic value of lactate determination in horses with acute in horses with acute abdominal crises. J. S. Afr. Vet. Ass 46: 127.

Doran, R. (1993): Field mangement of simple intestinal obstruction in horses. Compend Contin Educ Practice Vet 15: 463-471.

EL-Ghareib, S. A. and Nasser, M. H. (2003): Large Colon Impaction: Field Mangement And Prognostic Parameters. Kafr EL-Sheikh Vet. Med. J. No. 1, 889-906.

Germain, N. and Philip, J. J. (2001): Determination of the acid-base status in 50 horses admitted with colic between December 1998 and may 1999. Can. Vet. J. Vol 42, 703-707.

Givens, D. I., Owen, E., Axford, R. F. E., and Omed, H. M. (2000): Forage evaluation in ruminant nutrition. CABI publishing. Printed and bound in the UK by Biddles Ltd, Guildford and King's Lynn

Ismail, S. M. (1995): Some studies on intestinal disturbances in equines. M. V. Sc. Thesis, Fac. Vet. Zag. Univ.

Jack, R. S. and Sharon, J. S. (1997): Disorders causing colic in Smith edition in a large Animal Internal Medicine. 2nd Ed. The C. V. Mosby Company, Philadelphia.

Kamphues, J. and Schad, D. (1992): Obstructive colic in horses fed hay prepared from loose silky bent grass (Apera spicaveni) Pferdeheilkunde, Sonderausgabe, 213-215.

Lopes, M. A.; Walkerm B. L.; White, N.A. and Ward, D. L. (2002): Treatments to promote colonic hydration: enteral fluid therapy versus intravenous fluid therapy and magnesium sulphate. Equine Vet J. Jul; 34(5):505-9.

Mally, W. J. (1990): Clinical Blood Gases: Application And Non Invasisve Alternative. Copyright by W. B. Saunders Company. USA.

Martin, B., T., Bjarne, K. E., Nicolai, J. and Michael, H. (2003): Diagnostic decision rule for support in clinical assessment of the need for surgical intervention in horses with acute abdominal pain. Can. J. Vet. Res. 67(1) 20-29.

Michael, W. R. (1999): Diseases of the cecum. Manual of equine medicine and surgery. 1st Ed. The C. V Mosby company, Philadelphia, 211-213.

Noah, D. C. and Kenneth, E. S. (1999): Diseases of large colon. Manual of equine medicine and surgery.1st Ed. 213-215. The C. V. Mosby Company, Philadelphia.

\Norbert, K. (1996): Rectal examination of colic patient. In: Smith, B. P. Large Animal Internal Medicine. 2nd Ed. Portland, Oregon, Mosby publishing.

OGlivie, T. H. (1998): Large Animal Internal Medicine. 1st Ed., Williams and Wikins Company. Philadelphia, London, Paris, 19-26.

Parry, B. W. (1986): Prognostic evaluation of equine colic cases. Copmend Contint Educ Pract Vet ; 8:98-104

Pascoe P. J., Ducharme, G. R. and Lumsden, J. H. (1990): A Computer-derived protocol using recursive partitioning to aid in estimating prognosis of horses with abdominal pain in referral hospitals. Can. J. Vet. Res., 54: 373-378.

Radostits, O. M.; Blood, D. C. and Gay, C. C. (2007): Vetrinary Medicine, A Textbook of disease of cattle, sheep, pigs, goat and horses.8th Ed. Bailliere, Tindall , London, Philadelphia.

Reuben, J. and David, R. (1998): Manual of Equine Practice. 2nd Ed. W. B. Saunders Company, Philadelphia, London, Toronto, Sydney, Tokyo.

Reeves, M. J. Curtis, C. R., Salman, M. D. and Hilbert, B. J. (1989): prognosis in equine colic patients using multivariable analysis. Can. J. Vet. Res, 53: 87-94.

Robin, M. Dabareiner, DVM, MS, and Nathaniel A. White, DVM. MS (1995): Large colon impaction in horses 147 cases (1985- 1991). JAVAMA, Vol 206, No.5, 679-685.

Smith, B. P. (1996): Large Animal Internal Medicine. 2nd Ed. Portland, Oregon, Mosby publishing.

Snedecor, G. W. and Cochran, W. C. (1982): Statistical methods 17th Ed., The Lowa Univ. press, Amea Low, USA.

Stephen, B. A. (1999): Examination of alimentary system. Manual of Equine Medicine and Surgery. 1st Ed. Mosby Company, Philadelphia, 182-183.

Susan, C. E. and Denise, I. B. (1997): Laboratory profiles of equine disease. Department of large animal medicine and pathology. College of Veterinary Medicine of Georgia, Athens, Georgia.

Stampfli, H. R., and Carlson, G. P. (2001) : How to use the routine serum biochemical profile to understand and interpret acid base disorders in the horse. AAEP Proceeding/Vol. 47 PP: 257-261.

Taylor and Hillyer M. H. (1997): Diagnostic techniques in equine medicine. University of Bristol. U. K., Saunders Company Ltd. 46-59.

Tim, M. Sandy, L. Jim, S. And Elaine, W. (1998): Equine Medicine, Surgery and Reproduction, 1st Ed. WB Saunders comp. LTD London, Philadelphia, Toronto, Sydney, Tokyo. Printed in Great Britain.

Tony, P. and Marcy R. (1996): The complete equine. Vet. Manual: 90, 140.

Trinder, P. (1969): Enzymatic colorimetric method for determination of glucose. Ann. Clin. Bioch., 6:24.

White, N. A. (1990): Epidemiology and etiology of colic. In: White NA, Ed. The equine acute abdomen. Philadelphia: Lea &Febiger, 53-63.

William J., Malley, M. S., R.R.T and C.P.F.T (1990): Clinical blood gases. 1st Ed. W, B. Saunders Company. Philadelphia, London, Toronto, Sydney, Tokyo