UNIVERSITATEA DE ȘTIINȚE AGRICOLE
ȘI MEDICINĂ VETERINARĂ
"ION IONESCU DE LA BRAD" IAȘI

LUCRĂRI ȘTIINȚIFICE

VOL. 53 (12)

MEDICINĂ VETERINARĂ

PARTEA 3

Lucrările Simpozionului
"PROGRESS AND PERSPECTIVES IN
VETERINARY MEDICINE"
Iași, June 10th-11th 2010

EDITURA "ION IONESCU DE LA BRAD"
IAȘI 2010

COLEGIUL DE REDACȚIE

Redactor responsabil:
Prof. univ. dr. Gheorghe SOLCAN

Redactor adjunct:
Prof. univ. dr. Octavian Zaharie OPREAN

Membri:
Prof. univ. dr. Corneliu COTEA
Prof. univ. dr. Vasile VULPE
Prof. univ. dr. Mihai CARP-CĂRARE
Prof. univ. dr. Dan DRUGOCIU

COMISIA DE REFERENȚI ȘTIINȚIFICI

Prof. univ. dr. Octavian Zaharie OPREAN
Prof. univ. dr. Abdelfatah NOUR – Universitatea Pudue, SUA
Prof. univ. dr. H.C. Francois CRESPEAU – ENV Alfort, France
Prof. univ. dr. Gheorghe SOLCAN
Prof. univ. dr. Liviu MIRON
Prof. univ. dr. Gheorghe SĂVUȚA
Prof. univ. dr. Gabriel PREDOI – FMV București
Prof. univ. dr. Ioan Ștefan GROZA – FMV Cluj Napoca
Prof. univ. dr. Gheorghe DĂRĂBUȘ - FMV Timișoara
Prof. univ. dr. Corneliu COTEA
Prof. univ. dr. Mihai CARP-CĂRARE
Conf. univ. dr. Șerban MOROȘAN – INSERM Paris
Prof. univ. dr. H.C. Liviu RUNCEANU
Prof. univ. dr. Tudor PERIANU
Prof. univ. dr. Ioan COMAN
Prof. univ. dr. Elena VELESCU

Volumul a fost editat cu sprijinul financiar al
Ministerului Educației, Cercetării, Tineretului și Sportului

ISSN: 1454-7406

CUPRINS

PARTEA 3

PRECLINICS 339

DETERMINATION OF TESTOSTERONE PLASMA LEVELS IN RAMS BY GAS CHROMATOGRAPHY 341
Sanda ANDREI, BOGDAN L., FOCSANEANU V., GROZA I., Diana CRAINIC, AnaMaria PETREAN

EVALUATION OF OXIDATIVE CHANGES INDUCED BY SUBCLINICAL MASTITIS IN COWS ON MILK LIPIDS 346
Sanda ANDREI, Pintea Adela, Groza I., Crainic Diana, Matei Sorana, Ciupe Simona, Bogdan Sidonia

THE IMMUNOSTIMULATORY EFFECT OF THE LEPTIN ON THE MESENTERIC LYMPHNODE IN WISTAR RAT 353
G.R. BOTEZATU , C.COMAN , Manuella MILITARU , N.CONSTANTIN

THE DYNAMICS OF THE SHELL MEMBRANES FORMATION IN THE ISTHMUS OF THE LOHMANN BROWN LAYING HENS 360
C. TODIREANU, C. COTEA, Carmen SOLCAN

THE MORPHOLOGY AND HISTOCHEMISTRY OF THE MAGNUM DURING THE EGG PASSAGE THROUGH THE OVIDUCT, IN HENS DURING THE LAYING CYCLE 367
C. TODIREANU, C. COTEA, Carmen SOLCAN

HISTOLOGICAL RESEARCHES IN MALE PSEUDOHERMAPHRODITISM IN DOMESTIC SWINES (SUS SCROFA DOMESTICA) 374
CIORNEI Cristina, COTEA C.V., SOLCAN Carmen

HISTOLOGYCAL RESEARCHES OF TRUE BILATERAL HERMAPHRODITISM IN DOMESTIC SWINES (SUS SCROFA DOMESTICA) 382
CIORNEI Cristina, COTEA C.V., SOLCAN Carmen

COMPUTERIZED MICROSCOPY RESEARCH ON STRUCTURAL BIOLOGY OF THE SEMINIFEROUS TUBULES AND INTERSTITIAL GLAND AT THE COCKS 60-90 DAYS OLD 391
Valerica DĂNACU, N .CORNILĂ, Nicoleta MOCANU, Ştefania PREDOI, M.CORNILĂ.

COMPARATIVE STUDY OF THE THORACIC LIMB SKELETON IN THE LION (PANTHERA LEO) AND IN THE TIGER (PANTHERA TIGRIS) 398
C. DEZDROBITU, Melania CRIŞAN, Al. GUDEA, A. DAMIAN, Fl. STAN, Ioana CHIRILEAN, Fl. TUNS, Irina IRIMESCU

ANTIOXIDANT ACTIVITY OF WILD PANSY (VIOLA TRICOLOR) AND BLESSED THISTLE (CNICUS BENEDICTUS) EXTRACTS ON LINOLEIC ACID SISTEM 405
Corina DURDUN, Maria CRIVINEANU, V. NICORESCU

ORGANOGENESIS OF THE HARDERIAN GLAND IN RABBITS (ORYCTOLAGUS CUNICULUS) 411
Elena Cătălina FLOREA, C. V. COTEA, Carmen SOLCAN

RESEARCH ON THE MORPHOLOGY OF THE CAROTID ARTERY AT GOAT (CAPRA HIRCUS) 418
B. GEORGESCU, G. PREDOI, C. BELU, N. CORNILĂ, I. DUMITRESCU, Petronela ROŞU, Carmen BIȚOIU, Anca ŞEICARU

THE INFLUENCE OF REMEDY BIOR ON PROTEIN METABOLISM IN YOUNG RABBITS 422
Natalia IACUB

EFFECTS OF THE REMEDY BIOR ON CERTAIN HEPATIC INDEXES IN YOUNG RABBITS 425
V. MACARI, Natalia IACUB , D. MAȚENCU, Ana MACARI , Natalia PAVLICENCO

MANIFESTATIONS OF ALKALINE PHOSPHATASE IN BLOOD SERUM OF BROILER CHICKS TREATED WITH THE BIOR REMEDY 430
V. MACARI, V. PUTIN, Cristina GAVRIL, Ana MACARI, A. POPESCO

MACROSCOPIC ANATOMOPATHOLOGICAL CHANGES IN NATURAL INFESTATION WITH ARGAS PERSICUS 434
S. MORARIU, Gh. DĂRĂBUȘ, P. BRĂILĂ, M. ILIE, Florica MORARIU, M. CÎRSTEA,

SPONTANEOUS CASES OF CHRONIC HEPATOPATHIES IN DOGS 438
NAGY A.L., C. CĂTOI, A. GAL, P. BOLFĂ, M. TAULESCU, F. TĂBĂRAN, COSMINA CUC, G. BORZA, R. MOUSSA

USE OF BLOOD PARAMETERS IN HEMATOLOGY AND CYTOLOGY HEALTH CRECK CARPS (CYPRINUS CARPIO) REARED IN SYSTEM SEMI-INTENSIVE 442
L. OGNEAN , Ani Alina Rodica, Cristina CERNEA, M. CERNEA, C. PESTEAN, Meda Maria MOLDOVAN

THE USE OF SOME QUICK TESTS FOR BLOOD TYPING IN DOGS AND CATS 448
L. OGNEAN, S. HABAGO, Meda MOLDOVAN, I. MORAR

MORPHOPATHOLOGICAL CHANGES IN AVIAN INFECTIOUS BRONCHITIS, IN THE RESPIRATORY FORM , IN CHICKENS AND ASPECTS OF HISTOPATOLOGICAL DIAGNOSIS OF DISEASE 453
A. OLARIU JURCA, M. COMAN, I. OLARIU-JURCA, A. STANCU, A. LAZĂU, E. AVRAM

POTASSIUM DICHROMATE IMPACT ON SOME BIOMARKERS OF FEMALE PHYSICAL DEVELOPMENT (VAGINAL OPENING) IN RATS (THREE GENERATION STUDY) 457
Snejana PETROVICI, Alexandra TRIF, Muselin, F., Cristina, R. T., Milca PETROVICI

CONSEQUENCES OF POTASSIUM DICHROMATE INTAKE ON ENERGETIC PROFILE IN FEMALE RATS (SIX MONTHS EXPOSURE) 461
Snejana PETROVICI, Alexandra TRIF, Eugenia DUMITRESCU, Milca PETROVICI Camelia TULCAN

MORPHOLOGICAL OBSERVATIONS OF NEURONS IN THE SPINAL NUCLEUS BULB AT SHEEP 465
Alina POPA, C. V. COTEA, Carmen SOLCAN, Stefania ANDERCO

THE FORM AND THE LOCATION OF NUCLEI OF THE RAHIDIAN BULB AT SHEEP 471
Alina Coralia POPA, Corneliu V.COTEA, Mihaela SPATARU

HEPATIC LESIONS IN DOLPHINS STRANDED FROM THE ROMANIAN BLACK SEA COAST 478
Oana Melania POPA, M. COMAN, Alexandra TRIF, A. STANCU, Diana ARGHERIE

MONITORING THE ANTITOXIC EFFECT OF SOME GLUTATHIONE RICH VEGETAL PRODUCTS 484
Cornelia PRISĂCARU

STUDY OF SOME OXIDATIVE STRESS PARAMETERS DYNAMICS UNDER THE INFLUENCE OF THE EXOGEN ASCORBIC ACID CONTRIBUTION IN SUBACUTE ACRYLAMIDE INTOXICATION 489
Anca Irina PRISĂCARU, Cornelia PRISĂCARU

EFFECTS OF THE REMEDY BIOR DRUG ON THE TRYPSIN-ANTITRYPSIN SYSTEM IN BROILER 495
Chicks V. PUTIN

CLINICAL, ANATOMOPATHOLOGICAL AND HISTOLOGICAL ASPECTS IN GUINEA PIGS SENSITIZED WITH M. bovis AN, USED TO BOVINE PPD STANDARDIZATION 498
Maria-Mioara RĂDUȚĂ, P. ŞTIUBE, Viorica CHIURCIU, Şt. POPESCU

THE CONSEQUENCES OF HEXAVALENT CHROMIUM COMPOUND SIX MONTHS EXPOSURE ON SOME MORPHOLOGICAL BIOMARKERS IN MALE RATS 504
Jelena RANKOV, Alexandra TRIF

SIX MONTHS EXPOSURE TO POTASSIUM DICHROMATE OUTCOMES ON HISTOARCHITECTURE OF GENITAL ORGANS AND SEXUAL ACCESSORY GLANDS IN MALE RATS 509
Jelena RANKOV, Alexandra TRIF, Diana BREZOVAN

THE PECULIARITIES OF THE PELVIC LIMB MUSCLES IN RED SQUIRREL (SCIURUS VULGARIS) 514
Mihaela SPATARU, C. SPATARU, V. COTOFAN, M. LAZAR, A. MUNTEANU

MORPHO-FUNCTIONAL PARTICULARITIES OF THE AXIAL SKELETON AT RED SQUIRREL (SCIURUS VULGARIS) 519
C. SPATARU, Mihaela SPATARU, V. COTOFAN, V. VULPE, M. LAZAR, A. MUNTEANU

MORPHO-FUNCTIONAL PECULIARITIES OF THE THORACIC LIMB JOINTS AT RED SQUIRREL (SCIURUS VULGARIS) 525
C. SPATARU, Mihaela SPATARU, M. LAZAR, A. MUNTEANU

CLINICS 529

A NEOPLASIC ENCEPHALOPATHY IN DOG-CASE REPORT 531
Mihaela ARMAȘU, M. MUSTEAȚĂ, Carmen SOLCAN, Gh. SOLCAN

RESEARCH REGARDING THE INCIDENCE, DIAGNOSIS AND TREATMENT OF RETAINED PLACENTA IN AUSTRIAN BROWN COWS 535
L. BOGDAN, I.S. GROZA, Simona CIUPE, M. CENARIU, I. PAŞCA, Sanda ANDREI, Anamaria PETREAN, Sorana MATEI, Sidonia BOGDAN

DIETARY, MAINTENANCE AND PHYSIOPATHOLOGY FACTORS INVOLVED IN THE ETIOLOGY OF KETOSIS IN DAIRY COWS 541
V. BOGHIAN

CORRELATION BETWEEN MORPHOPATHOLOGICAL EXAM AND EVOLUTIVE STAGE IN NATURAL INFECTION WITH EQUINE INFECTIOUS ANEMIA VIRUS 547
P. BOLFĂ , C. CĂTOI, M. TAULESCU, A. GAL, Cosmina CUC, R. MOUSSA, F. TĂBĂRAN, A. NAGY , G. BORZA , C. MUREŞAN , Marina SPÎNU

USING NUTRITIONAL-METABOLIC PROFILE AS A TOOL FOR PROGNOSIS GROUP OF DAIRY COWS IN FARM 553
S.I. BORŞ, L. RUNCEANU, Gh. SOLCAN, D. DRUGOCIU, P. ROŞCA, R.MĂLĂNCUŞ

RESEARCH ABOUT MORPHOLOGICAL ASPECTS WITH A BACTERIAL INFECTION ON BROILERS RAISED ON GROUND 560
Oana BUSUIOC

THE EFFICACY OF MACROCYCLIC LACTONES AND BENZIMIDAZOLES COMBINATION IN EQUINE STRONGYLIDOSIS 562
Laura Cristina CERNEA, M. CERNEA, L. OGNEAN, V. NĂSTASA, Ş. RĂILEANU, M. MAREŞ, Anca CHEREJI L. M. Madeira de CARVALHO

THE EFFICACY OF TETRAHYDROPYRIMIDINES AND BENZIMIDAZOLES COMBINATION IN EQUINE STRONGYLIDOSIS 566
Laura Cristina CERNEA, M. CERNEA, L. OGNEAN, V. NĂSTASA, Ş. RĂILEANU, M. MAREŞ, Anca CHEREJI L. M. Madeira de CARVALHO

BIOLOGICAL CONTROL OF PASTURES INFESTED WITH EQUINE STRONGYLS LARVAE 571
M. CERNEA, Laura Cristina CERNEA, Ş. RĂILEANU, V. NĂSTASA, M. MAREŞ, L. OGNEAN, L. M. Madeira de CARVALHO

THE EFFICACY OF HERBAL EXTRACT ON EQUINE STRONGYLIDOSIS 575
M. CERNEA, Laura Cristina CERNEA, Ş. RĂILEANU, V. NĂSTASA, M. MAREŞ, L.ț OGNEAN, L. M. Madeira de CARVALHO

CONTRIBUTIONS TO THE STUDY OF ECTOPARASITES DEMODEX CANIS LOCALIZATION ON DOGS` BODY SURFACE 582
Al. D. CHESLER, M.D. CODREANU, Iuliana CODREANU, D. CRÂNGANU, A. BÎLBĂ

INVESTIGATION CONCERNING THE INFLUENCE OF BIOTIC AND ABIOTIC FACTORS ON THE INCIDENCE AND PREVALENCE OF CANINE DEMODICOSIS 587
Al. D. CHESLER, M.D. CODREANU, I. DUCA, Iuliana CODREANU, A. BÎLBĂ,

RESEARCH ON EFFICIENCY OF " PRESYNCH-OVSYNCH" PROTOCOL ON COWS FROM HOLSTEIN BREED 592
C.A. CHIRUȚĂ,

DIROFILARIA REPENS INFECTION PREVALENCE IN HUNEDOARA COUNTY 597
Roberta CIOCAN, Gh. DĂRĂBUŞ, M.S. Ilie, Mirela IMRE, Ionela HOTEA

SALPINX DISORDERS AS A FACTOR OF INFERTILITY IN COWS FOR MILK PRODUCTION 601
Şt. Gr. CIORNEI , L. RUNCEANU , D. DRUGOCIU , P. ROŞCA , V.D. PĂDURARU , C . BĂLU , GALAN C. , I. DOROBANȚU

BIOTECHNOLOGY RESEARCH ON RECOVERY, MORPHOLOGICAL ASSESSMENT AND VIABILITY TESTING OF CAT OOCYTES BEFORE AND AFTER "IN VITRO" MATURATION 607
Maria Simona CIUPE, I. Şt. GROZA, L. BOGDAN, Emoke PALL, Al. POP, Anamaria PETREAN, Sanda ANDREI, Sorana MATEI, Andrea CRIŞAN

CORRELATION BETWEEN THE CLINICAL AND EVOLUTIVE EXPRESSION AND TYPE OF ULTRASOUND CHANGES IN THE DIAGNOSIS OF CAVITARY ORGANS` DISEASES IN DOG 612
M. CODREANU, Cristina FERNOAGĂ, M.CORNILĂ, Iuliana CODREANU, D. CRÂNGANU, M. TURCITU

STUDY REGARDING THE CORRELATION BETWEEN THE CLINICAL FEATURES AND/OR THE TYPE OF ULTRASOUND CHANGES IN THE DIAGNOSIS OF THE PARENCHYMATOUS DISEASES IN DOG 619
M. CODREANU, Cristina FERNOAGĂ, M.CORNILĂ, Iuliana CODREANU, C. ŞERDEAN, M. TURCITU,

PROFILACTICO-THERAPEUTIC STRATEGIES IN THE DOG DISORDERS MALIGNANT PROSTATE 624
D.CRINGANU, Manuela MILITARU, M. CODREANU, Al. DIACONESCU, Cristina PREDA, Bogdan GHEONGHEOS

THE DIAGNOSTIC AND THERAPY APPROACH IN THE URINARY TUMORAL PROCESSES IN DOG 635
D. CRÎNGANU, Cristina PREDA, M. CODREANU, Raluca CRÎNGANU, V. NICORESCU

FREE RADICALS SCAVENGING ACTIVITY OF SOME HYDRO-ALCOHOLIC PHYTOCOMPOUNDS 639
Maria CRIVINEANU, Camelia PAPUC, Corina DURDUN, V. NICORESCU

THE EFFECTS OF THIAMPHENICOL ADMINISTRATION UPON KIDNEYS IN RATS 644
Maria CRIVINEANU, V. NICORESCU, Camelia PAPUC, Maria VOICU (MIU), Elena ROTARU

MORPHOLOGICAL ASPETCS OF THE MAJOR SALIVARY GLANDS IN THE RAT 649
A. DAMIAN, V. MICLĂUŞ, I. PAPUC

EYE FUNDUS VASCULAR PATTERN IN SOME DOMESTIC ANIMALS 654
Alina DONISA, A.MUSTE, I.PAPUC , F.BETEG, M.MUSTE

MORPHOLOGYCAL ASPECTS OF THE EYE FUNDUS IN DOMESTIC RABBIT(ORYCTOLAGUS CUNICULUS DOMESTICUS) 658
Alina DONISA, A.MUSTE, F.BETEG, A.KRUPACi, M.MUSTE

MEDICINES FOR BEES- CURRENT SITUATION AND FUTURE ASPECTS, AN IMPORTANT SUBJECT DEBATED AT EUROPEAN LEVEL 662
Alina Karina DRAGHICI , Anca BITOIU, Lollita TABAN

ANTIHELMINTICS RESISTANCE IN CATTLE- A NATIONAL AND EUROPEAN PROBLEM 665
Alina Karina DRAGHICI, I. DUCA, Mirela PREDA, D. PREDA

RESEARCH REGARDING THE EFFICIENCY OF ROMFENBENDAZOL 0% SUSPENSION TREATMENT IN SOME HELMINTOSIS IN SHEEP 668
Elena DRAGOSTIN, C. TUDORAN, C-tin CHIURCIU, I. IACOB

OBSERVATION REGARDING OVARIAN DISORDES AT DAIRY COWS AND THEIR INFLUENCE ON REPRODUCTIVE FUNCTION 672
Dana-Simona DRUGOCIU, Alin BIRȚOIU, Cristina Loredana PANAITE, M. Fl. FOICA , Manuela STĂNESCU,

LEAD ACETATE IMPACT ON FUNDAMENTAL BIOMARKERS OF REPRODUCTIVE FUNCTIONALITY IN FEMALE RATS (IN UTERO EXPOSURE) 678
Eugenia DUMITRESCU, Alexandra TRIF, R. T. CRISTINA,Fl. Muselin,

INDEX OF PARASITIC IMPACT UPON THE PHYSIOLOGIC INDICES IN BOVINES 683
D.ERHAN, Ol. CHIHAI,Galina MELNIC, Şt. RUSU, Maria ZAMORNEA, Nina TĂLĂMBUȚĂ, V. BUZA, T. ANGHEL

ANTIBACTERIAL AND PROTECTIVE EFFECT OF ALLIUM SATIVUM ON INTESTINAL FLORA IN RATS (RATTUS NORVEGICUS) 688
N. FIȚ, Fl. CHIRILĂ, G. NADĂŞ, Adriana CRISTE

STUDIES ABOUT MICROBIAL ETIOLOGY AND ANTIBIOTIC RESISTANCE IN SUBCLINICAL MASTITIS IN COWS 693
N. FIȚ, F. CHIRILĂ, S. RĂPUNTEAN, G. NADĂŞ, Sanda ANDREI, Sorana Teodora MATEI

RESEARCH ON AVIAN COLIBACILLOSIS IN THE CASE OF INTENSIVE BREEDING 698
Diana GALAȚANU, T. PERIANU, Oana TĂNASE

CLINICAL ASPECTS OF SOME PODAL DISEASES IN BOVINE FROM DIFFERENT BREEDING SYSTEMS 703
Dan GÎSCĂ,

INSULIN DETERMINATION IN CATS WITH DIABETES MELLITUS 708
Luminita Diana HRIȚCU

NEBULISATION - COMPLEMENTARY THERAPY FOR RESPIRATORY DISEASES IN CATS 712
Luminita Diana Hrițcu

PERCUTANEOUS NORMOGRADE INTRAMEDULLARY PINNING OF FELINE FEMUR FRACTURES 716
C. IGNA , Larisa SCHUSZLER, Roxana DASCĂLU, M. SABĂU, C. LUCA

OSTEOGENESIS CAPACITY OF FREE VASCULARIZED CORTICOPERIOSTEAL FLAP IN DOGS 720
C.IGNA , C. LUCA, Roxana DASCĂLU, Larisa SCHUSZLER, M. SABĂU

RFID TECHNOLOGY USED FOR MONITORING ESTRUS TEMPERATURE IN COW 726
Fl. IONESCU, R. HUȚU , A. CIMPONERIU, M. CHILINȚAN R. URIAN, I. HUȚU

VENTRAL OSTEOTOMY IN THE TREATMENT OF OTITIS MEDIA IN DOG 733
Andrei KRUPACI, Aurel MUSTE, Florin BETEG, Radu LACATUS, Alina DONISA, Florina-Alexandra KRUPACI

EXPERIMENTAL PERFORATOR DORSAL TEGUMENTARY PIG COETANEOUS PEEL BY USING NON IONIC CONTRAST MEDIA 737
R. LĂCĂTUŞ, I. PAPUC, A. MUSTE, B. CHIROIU, Ileana MATEI, F. ARDELEAN, R. C. PURDOIU, Alexandra Nicoleta PĂVĂLOIU

USAGE OF NONIONIC CONTRAST MEDIA FOR THE IDENTIFICATION OF PERFORATING CUTANEOUS ARTERIES IN RATS WITH APPLICATIONS IN PLASTIC SURGERY 743
R. LĂCĂTUŞ, I. PAPUC, F. ARDELEAN, B. CHIROIU, Ileana MATEI, A. MUSTE, R. C. PURDOIU, Alexandra Nicoleta PĂVĂLOIU

ENDOSCOPICAL AND SURGYCAL COMPLEX TECHNIQUES FOR THE DIAGNOSTIC AND TREATMENT OF BONEY FOREIGN BODY RETAINED IN THORACIC ESOPHAGEAL SEGMENT 753
D.C. LESCAI, F. DUMITRESCU, ADELA MENDEA, L. HARBUZ, I. BURTAN

OBSERVATIONS ON THE ELECTROTHERAPY USE FOR THE POSTOPERATIVE FRACTURE RECOVERY IN DOG 757
LAURA LIVITCHI, A. MUSTE, F. BETEG, I. SCURTU

THE USE OF ULTRASONOGRAPHY IN GASTROINTESTINAL DISEASE IN DOGS 762
R. N. MĂLĂNCUŞ, Gh. SOLCAN, Cristina TOFAN (MALANCUS)

IMPORTANCE OF DIAGNOSTIC IMAGING IN HYDRONEPHROTIC KIDNEY SURGERY 768
ADELA MENDEA, N. HAGIU

COMPARATIVE CHARACTERISTICS OF DUROC AND WHITE LARGE DILUTED BOAR SEMEN STORED FOR FIVE DAYS AT 7°C IN RELATION TO FERTILITY 772
C. MIRCU, Violeta IGNA, Camelia TULCAN, H.CERNESCU, Anca LELESCU , Simona ZARCULA, R.I. URIAN-SUESCA, G.OTAVA, V.ARDELEAN, Gh.BONCA

DENTAL FRACTURE IN DOGS: INCIDENCE, CLINICAL AND THERAPEUTICALLY ASPECTS 779
A. MUSTE, FL. BETEG, I. PAPUC, ALINA DONISA, R. LACATUS, M. MUSTE

SURGICAL PROTOCOL IN DOG PERINEAL HERNIA 783
A. MUSTE, BETEG FL., TĂNASE A., DONISĂ ALINA, MUSTE M.

SOME OBSERVATIONS REGARDING STANDING CASTRATION IN HORSES 787
L. OANA, C. OBER, C. PESTEAN, V. MICLAUS, A. N. OROS, O. NEGREA, Daniela OROS

ASPECTS REGARDING THE TECHNIQUE OF ORCHIECTOMY IN ROOSTERS (GALLUS GALLUS) 792
L. OANA, C. OBER, C. PEŞTEAN, V. MICLĂUŞ, O. NEGREA, A. N. OROS, L. OGNEAN, Daniela OROS

THE CORRELATION BETWEEN THE PROGESTERONE LEVELS 6-7 DAYS POST INSEMINATION AND THE PREGNANCY LOSS IN COWS 798
G. OTAVA

CORELATIONS BETWEEN BIOLOGICAL VALUE AND FERTILITY IN BEEF BULL BREEDS 802
V. D. PĂDURARU, D. DRUGOCIU, D. ALEXA, M. GRIGORAŞ, C O. A. OJOCARU

HEMATOLOGICAL AND BIOCHEMICAL MODIFICATIONS OF BLOOD AND CEREBRAL SPINAL FLUID IN DOG MYELOGRAPHY USING NON IONIC CONTRAST SUBSTANCES OPTIRAY 0 AND ULTRAVIST 70 **808**
I. PAPUC, R. LĂCĂTUŞ, A. MUSTE, R. C. PURDOIU, S. BORBIL, Alexandra Nicoleta PĂVĂLOIU

CLINICAL AND PARACLINICAL DIAGNOSIS IN SPINAL CHORD CONDITIONS IN DOGS **817**
I. PAPUC, R. LĂCĂTUŞ, C. MUREŞAN, Alexandra Nicoleta PĂVĂLOIU, R. C. PURDOIU

ADVANCED BIOTECHNOLOGIES APPLIED IN CARNIVORE'S REPRODUCTION IN ORDER TO IMPROVE FERTILITY **826**
C. PAVLI, Oana TANASE

PROSTATE PATHOLOGY IN DOG, DIFFERENTIAL DIAGNOSTIC BETWEEN CYSTS, ABSCESS AND NEOPLASM **830**
Constantin PAVLI, Oana TANASE

GONIOSCOPY WITH IMAGE ACQUISITION AT DOGS AND CATS **835**
B. Ş. RUGINĂ, I. BURTAN , L. C. BURTAN, Diana IAMANDI

STUDIES REGARDING THE PREVALENCE AND DETERMINANT FACTORS OF THE MAIN DISEAS ES IN DAIRY COWS **841**
Elena RUGINOSU, Şt. CREANGĂ, Anca PLĂVĂNESCU, L. DASCĂLU D. ANIȚĂ, Adriana ANIȚĂ, Cr istina REBEGEA, Gh. SOLCAN

THE ROLE OF LIDOCAINE CONTINUOUS INFUSION IN PAIN CONTROL AFTER ORTHOPEDIC SURGERY **849**
Larisa SCHUSZLER, C. IGNA, M. SABĂU, Roxana DASCĂLU, A. SALA, C. LUCA

ATTEMPT TO INDUCE IMMUNOTOLERANCE IN XENOTRANSPLANT USING SKIN CELLS **853**
Monica ŞEREŞ, E. TÎRZIU, Ileana NICHITA, C. CUMPĂNĂŞOIU, D. CIOCA

NEW AND IMPROVED OSTEOSYNTHESIS TECHNIQUES USED IN FOREARM FRACTURE **858**
V. ȘINDILAR E, V. VULPE, S. PAȘCA, S. GRĂMADĂ

RESTORATIVE MODERN MATERIALS USED IN VETERINARY DENTAL MEDICINE **860**
V.ȘINDILAR E, S. GRĂMADĂ

AGE-DEPENDENT EFFECTS OF CERTAIN VEGETAL EXTRACTS ON THE INNATE CELL-MEDIATED IMMUNITY IN CHICKENS **863**
Marina SPINU, Carmen SANDRU, Gh.F. Brudaşcă, Mihaela NICULAE, D. CADAR, Krisztina RINDT, Timea KISS, Armela BORDEANU, Florina-Alexandra KRUPACI, Silvana POPESCU, R. ŞTEFAN

VEGETAL EXTRACTS INTERACT WITH PHYSIOLOGICAL CELL-MEDIATED IMMUNE ACTIVITY IN FARMED HERBIVORES **868**
Marina SPINU, Carmen SANDRU, Gh.F. Brudaşcă, Silvana POPESCU, Mihaela NICULAE, D. CADAR, Krisztina RINDT, Timea KISS, Florina-Alexandra KRUPACI, Armela BORDEANU, R. ŞTEFAN

FREQUENCY AND ETIOPATHOGENESIS OF HIP DYSPLASIA IN DOGS **874**
R.E. STECYK, L.C. BURTAN, Ioana BURCOVEANU

RESEARCH OF NEGATIVE ENERGY BALANCE AND ITS INFLUENCE ON THE REPRODUCTION FUNCTION IN DAIRY COWS **879**
Cristina Maria TOFAN (MĂLĂNCUȘ), D. Gh. DRUGOCIU

PARACLINICAL DIAGNOSIS OF HEPATIC DISEASE IN CATTLE **882**
Cristina TOFAN (MĂLĂNCUȘ) , Gh. SOLCAN, D. DRUGOCIU, R.N. MĂLĂNCUȘ

ULTRASOUND DIAGNOSIS IN EARLY PREGNANCY TO BUFFALO **887**
G. TOMAI , I. MORAR, I. St. GROZA

PARTEA 4

INCIDENCE OF HUMAN CRYPTOSPORIDIOSIS IN BUCHAREST BETWEEN 2000 – 2005 PERIOD **909**
Adriana AMFIM, Monica PÂRVU, Violeta –Elena SIMION

EPIDEMIOLOGICAL RESEARCH ON OUTBREAKS OF AVIAN INFLUENZA IN LETEA AND PLAUR FROM TULCEA COUNTY **916**
M. ARSENE, ARSENE Marinela,TERTIS Marinela, P. BRIA, D. MAFTEI , Laurenta BOICIUC

ETIOLOGY AND PATHOLOGY IN PORCINE RESPIRATORY DISEASE COMPLEX (PRDC) IN FINISHING PIGS **920**
S. BĂRĂITĂREANU , Mihaela BEZMAN, S. MARINACHE, D COBZARIU, Gabriela BAGRINOVSCHI, Maria OȚELEA, M. V. CÂMPEANU, Simona IVANA, Doina DANEŞ

SIGNS AND LESIONS OF THE SPONTANEOUS ACUTE PNEUMONIC PASTEURELLOSIS IN PET RABBITS **927**
S.BĂRĂITĂREANU , D. COBZARIU, Maria OȚELEA, M. V. CÂMPEANU, Simona IVANA, Doina DANEŞ

TREATMENT EFFICACY IN UDDER LOCALISATION OF CONTAGIOUS ECTHYMA IN SHEEP AND GOATS **931**
R. BIȚA, G. RĂPUNTEAN, S. RĂPUNTEAN

EFFECTIVENESS OF TREATMENT FORMULA IN CONTAGIOUS ECTHYMA IN LAMBS FROM INTENSIVE BREEDING SYSTEM **937**
R. BIȚA, S. RĂPUNTEAN, G. RĂPUNTEAN

CLINICAL AND ANATOMOPATHOLOGICAL RESEARCH IN PORCINE CIRCOVIRUS TYPE INFECTION IN YOUNG SWINE **943**
N. CĂTANA, V. HERMAN, Ionica FODOR, V. PETRUSE

SEROLOGICAL AND PCR RESEARCH DIAGNOSIS OF THE INFECTION WITH PORCINE CIRCOVIR US TYPE IN YOUNG SWINE **947**
N. CĂTANA, VIRGILIA POPA, V. HERMAN, Ionica FODOR

RESEARCH CONCERNING THE ANTIBACTERIAL ACTIVITY OF HONEY AGAINST COAGULASE-NEGATIVE STAPHYLOCOCCI WITH USE IN VETERINARY MEDICINE 950
C.CEAUŞI, I. ȚOGOE, ANCA MARIA GALIŞ, L. TUDOR, I.L. ILIE,

RESEARCHES REGARDING THE EFFICIENCY OF PLANTS ESSENTIAL OILS EXTRACTS ON SOME BACTERIAL STRAINS ISOLATED FROM MASTITIS COW MILK 954
F. CHIRILĂ, N. FIȚ, S. RAPUNTEAN, G. NADĂŞ, O. NEGREA

RESEARCH ON THE FREQUENCY OF BACILLUS CEREUS IN MILK AS RAW MATERIAL 959
C. CIOTĂU, E.V. ŞINDILAR

OBSERVATIONS REGARDING THE HISTOLOGICAL STRUCTURE OF THE FOOT MUSCLE OF THE FOOD SNAIL H. pomatia 965
Andreea-Flavia CIRLAN, E. SINDILAR,

OBSERVATIONS REGARDING THE HISTOLOGICAL STRUCTURE OF THE GENITAL SYSTEM OF THE GARDEN SNAIL H. POMATIA 969
Andreea-Flavia CIRLAN, E. SINDILAR,

THE CONCORDANCE BETWEEN THE TOTAL GERMS NUMBER (TGN) FROM THE SHELL AND THE TOTAL GERMS NUMBER FROM THE FOOT OF THE FOOD SNAIL HELIX POMATIA 973
Andreea-Flavia CIRLAN, E SINDILAR,

MAIN ANTIBIOTICS USED IN THE TREATMENT OF UDDER INFECTIONS IN HUMAN CONSUMPTION MILK SUPPLIER ANIMAL SPECIES FROM SOUTH-EASTERN SIBIU COUNTY 977
M. CÎRSTEA, R. TRIF, S. MORARIU, Florica MORARIU

PREVALENCE OF MASTITIS IN COWS, SHEEP AND BUFFALOES IN FIVE LOCALITIES FROM SIBIU COUNTY 980
M. CÎRSTEA, R. TRIF, S. MORARIU, Florica MORARIU

RESEARCH RELATED TO THE REFINEMENENT OF THE POULTRY AS PRODUCTS WITHOUT PROTECTIVE MEMBRANE 983
Lilica COCLEA, Angela GAVRILAŞ, D. SIMEANU, Cristina SIMEANU

RESEARCH RELATED TO THE REFINEMENENT OF THE POULTRY AS PRODUCTS WITH PROTECTIVE MEMBRANE 991
Lilica COCLEA, Angela GAVRILAŞ, D. SIMEANU, Cristina SIMEANU

IN VITRO ACTIVITY OF SOME NATURAL ESSENTIAL OILS AGAINST THE YEAST- LIKE ALGA PROTOTHECA 997
Cosmina BOUARI (CUC),
Gh. RĂPUNTEAN, C. CĂTOI, N. FIȚ, G.NADĂŞ, P. BOLFĂ, M. TAULESCU, A.GAL, R. Moussa, A. NAGY, F. TĂBĂRAN

ORGANOLEPTIC RESEARCH OF SALAMI DURING THE VALIDITY PERIOD (FOOD DETERIORATION) 1003
F. M. FOICA , M. CARP-CĂRARE , Dana-Simona DRUGOCIU

RESEARCH CONCERNING DIARY COWS' WELFARE IN A FARM NEAR BUCHAREST **1011**
F. FURNARIS, Elena MITRANESCU, L. TUDOR, Violeta SIMION, C. TOGAN, B. TASBAC, S. BUSTANI

RESEARCHES REGARDING AIR QUALITY IN NEAMT COUNTY **1017**
F. FURNARIS, Elena MITRANESCU, Catalina LALA, L. TUDOR, Magdalena GONCEAROV, Mariana ŢERBEA, L. I. ILIE

RESEARCH ON AVIAN COLIBACILLOSIS CONDITIONS IN INTENSIVE REARING **1021**
Diana GALAŢANU, T. PERIANU, Oana TĂNASE

RESEARCH CONCERNING THE INFLUENCE OF THERMAL TREATMENT ON THE QUALITY OF FLORAL HONEY PRODUCED IN ROMANIA **1026**
ANCA MARIA GALIŞ, I. ŢOGOE, L. TUDOR, I.L. ILIE, MITRĂNESCU Elena

RESEARCH CONCERNING THE MOISTURE CONTENT AND VISCOSITY OF ROMANIAN HONEY STORED AT DIFFERENT TEMPERATURES **1031**
ANCA MARIA GALIŞ, I. ŢOGOE, L. TUDOR, I.L. ILIE, MITRĂNESCU Elena

AUDIT-SYSTEMATIC AND INDEPENDENT EXAMINATION OF EFFECTIVE IMPLEMENTATION OF SANITATION PROGRAMS **1035**
MAGDA GONCIAROV, R. POPA, L. TUDOR, DOINA LUPU, ELENA MITRĂNESCU

OFFICIAL CONTROL-CONTROL METHOD FOR CHECKING COMPLIANCE WITH FOOD LAW **1039**
MAGDA GONCIAROV, R. POPA, L. TUDOR, DOINA LUPU, ELENA MITRĂNESCU

ANTIMICROBIAL SENSITIVITY OF E. COLI STRAINS ISOLATED FROM PIG SEPTICEMIC COLIBACILOSIS **1043**
V. HERMAN, Corina PASCU, Luminiţa COSTINAR, B. FAUR, Ioana VĂDUVA, Anca SURPAT, Sorin a IRIMIE

STUDY CONCERNING THE SEASONAL VARIATION OF CATTLE MILK PH VALUES AND THE OVERALL INFLUENCE ON MILK QUALITY **1046**
L.I. ILIE, L. TUDOR, Anca-Maria GALIŞ, Elena MITRĂNESCU, R.F. POPA

RESEARCH CONCERNING THE SEASONAL VARIATION OF CATTLE MILK DENSITY VALUES **1054**
L.I. ILIE, L. TUDOR, Anca-Maria GALIŞ, Elena MITRĂNESCU, F. FURNARIS

A STUDY ON THE BEHAVIOR OF BROWN BEAR (URSUS ARCTOS) FROM ZOOLOGICAL GARDEN TIMISOARA **1062**
C. Fl. LĂZĂRESCU, Adina BAIAS, M. AFRENIE

RESEARCHES REGARDING IMPLEMENTATION OF A COMPUTERIZED SURVEILLANCE PROGRAM OF MAMMARY GLAND IN A DAIRY COW FARM **1066**
Sorana Teodora MATEI, I. GROZA, L. BOGDAN, Simona CIUPE, Anamaria PETREAN, Sanda ANDREI

SPECTROPHOTOMETRIC DETERMINATION OF NITRITE AND NITRATE IN MEAT PRODUCTS **1072**
Mirela MICLEAN, Cecilia ROMAN, Laura PARLAPAN, Ioan Stefan GROZA

STUDIES CONCERNING LEPTIN'S INFLUENCE ON THE SCC IN BUFFALO MILK **1077**
M.MIHAIU, Alexandra LAPUSAN, , Crina Teodora CARSAI , Carmen JECAN, Romolica MIHAIU , S.D. DAN

STUDY CONCERNING MOLDOVA RIVER WATER QUALITY IN NEAMT COUNTY **1082**
Elena MITRANESCU, Catalina LALA, F. FURNARIS, L. TUDOR, Mariana ȚERBEA, D. MITRĂNESCU , Violeta SIMION

RESEARCHES CONCERNING FISH WELFARE IN A FARM FROM SOUTHERN AREA OF ROMANIA **1088**
Elena MITRANESCU, F. FURNARIS, L. TUDOR, Magda GONCIAROV, Violeta SIMION, S. BUSTANI, Adriana ORASANU

RESEARCHES REGARDING THE SENSITIVITY TO ANTIBIOTICS OF SOME BACTERIAL STRAINS ISOLATED FROM MASTITIS COW MILK **1093**
G. C. NADĂȘ, N. Fiț, F. CHIRILĂ, S. RĂPUNTEAN, V. RUS

EVALUATION OF PHOSPHORUS LEVELS IN LAMB BY LUCERNE HAY FEEDING TESTS **1096**
Aritina NEAGU, V.CRIVINEANU, G.V. GORAN

SOME INVESTIGATIONS IN CONSUMPTION SEA FISH (HERRING, MACKEREL) **1102**
O. NEGREA , Camelia RADUCU, L. OANA, Vioara MIRESAN, Z. MARCHIS, Gh. MIHAI, F.CHIRILA, Ancuța ROTAR

ASPECTS REGARDING EPIZOOTIC METALINGUATULOSA IN MAIN DOMESTIC RUMINANT SPECIES **1106**
O. NEGREA , Camelia RADUCU, L. OANA, Vioara MIRESAN, Z. MARCHIS, V. MICLAUS, F.CHIRILA, Ancuța ROTAR

APPLICATIONS OF BIOMEDICAL INFORMATICS AND TELEMEDICINE **1111**
T. NICA, V. CRIVINEANU

BUILDING AND MANAGING AN ONLINE DATABASE OF THE MOST IMPORTANT TOXICOSES IN VETERINARY MEDICINE **1116**
T. NICA, V. CRIVINEANU

ANTIMICROBIAL RESISTANCE OF CAMPYLOBACTER JEJUNI AND CAMPYLOBACTER COLI STRAINS ISOLATED FROM BROILERS SKIN **1120**
Isabela NICORESCU, Maria CRIVINEANU

INCIDENCE OF SALMONELLA SPP. IN A POULTRY SLAUGHTERING UNIT **1125**
M.OBADĂ, Alina VLAD SABIE, M. CARP- CARARE

THE PROTECTING EFFECT OF A POLYPHENOLIC EXTRACT OBTAINED FROM SEA BUCKTHORN (HIPPOPHAE RHAMNOIDES) FRUITS AGAINST PHOTO-OXIDATION OF DIFFERENT VEGETAL OILS **1130**
Camelia PAPUC, V. NICORESCU, Corina DURDUN, Gh. GORAN, Carmen CRIVINEANU

OBSERVATIONS ON AVIAN INFLUENZA **1135**
T.C. PATACHE,M. ARSENE, ARSENE MARINELA

MORPHOLOGICAL QUALITY INFLUENCE OF SHEEP OOCYTES ON IN VITRO MATURATION **1138**
Anamaria Petrean, I. Groza, L. Bogdan, Simona Ciupe, Sorana Matei, AL. Pop

CREATING BEST PRACTICE GUIDES-BASIC REQUIREMENT FOR ACHIEVING SAFE AND HEALTHY FOOD **1144**
R. POPA, MAGDA GONCIAROV, L. TUDOR , DOINA LUPU

STUDY ON THE RISK ANALYSIS (IDENTIFICATION OF HAZARDS, THEIR EVALUATION, IDENTIFYING PREVENTIVE MEASURES TO CONTROL RISK) **1147**
RAREŞ POPA, MAGDA GONCIAROV, LAURENȚIU TUDOR , DOINA LUPU

THE ASSESSMENT OF HYGIENE IN DAIRY COWSHEDS WITH TIE–STALLS IN TRANSYLVANIA **1151**
Silvana POPESCU, Cristin BORDA, Marina SPINU, R. STEFAN, Carmen D. SANDRU, Eva A. LAZAR

THE LEVEL OF MICROCLIMATE PARAMETERS IN DAIRY CATTLE BARNS WITH TIE STALLS **1158**
Silvana POPESCU, Cristin BORDA, Iuliana C HEGEDUS, R. STEFAN, Eva A. LAZAR

STUDIES CONCERNING HYGIENIC BODY SCORES AND THE RISK OF INTRAMAMMARY INFECTIONS IN COW **1164**
Elena ROTARU, B. TAŞBAC, Elena MITRĂNESCU, Maria CRIVINEANU, V. NICORESCU, Magda G ONCIAROV

KEY BIOCHEMICAL PARAMETERS CHANGES OF THE APIS MELLIFERA CARPATHICA BEE IN STRESSFUL CONDITIONS **1169**
Şapcaliu Agripina, I.Rădoi , Tudor Poliana, Tutunaru Alexandru, Măgdici Maria, Căuia Eliza , N. Tudor

THE EFFECT OF XAGO(-X)[BOCAOPO] OXIDE POWDERS ON GRAM POSITIVE BACTERIA **1175**
R. STEFAN, Silvana POPESCU, Marina SPINU, N. FIT, A. MACRI, G. NADAS

THE ANTIBACTERIAL EFFECT OF SILVER CONTAINING BO-CAO-PO GLAS MATRIX ON GRAM NEGATIVE BACTERIA **1180**
R. STEFAN, Marina SPINU, Silvana POPESCU, N. FIT, Maria BINDEA, Flore CHIRILA

MANGANESE IMPACT ON MALE REPRODUCTIVE SYSTEM INTEGRITY AND PERFORMANCES BIOMARKERS **1184**
Nicoleta-Simona Steliac (Munteanu), Alexandra Trif

ANATOMOPATHOLOGICAL AND EPIDEMIOLOGICAL STUDY OF VISCERAL AND NONVISCERAL HEMANGIOSARCOMA IN DOGS **1190**
TĂBĂRAN A.F., C. CĂTOI, A. GAL, P. BOLFĂ, M. TAULESCU, A.L. NAGY, COSMINA CUC, G. BORZA, R. MOUSSA

ARGULUS SPP. (FISH LOUSE) INFECTION IN A COMMON CARP (CYPRINUS CARPIO) FROM A FISH FARM IN CLUJ COUNTY **1196**
M. TAULESCU, C. CĂTOI, G. BORZA, P. BOLFĂ, A. NAGY, A. GAL, F. TABARAN, COSMINA CUC, R. MOUSSA, A. BARBU

LOSS OF BODY WEIGHT AS AN INDICATOR FOR EVALUATING LAMBS WELFARE DURING TRA NSPORTATION **1200**
Mariana Ţerbea , Elena Mitrănescu

COMPARATION OF TWO METHODS FOR DETERMINING SALMONELLA spp. **1204**
I. ŢIBRU,SORINA MARIA IRIMIE

THE DETERMINATION OF COLISTIN RESIDUES FROM PORK MEAT AND ORGANS USING MICROBIOLOGICAL AND HPLC ANALYSIS **1207**
V. TRIFAN, Maria CRIVINEANU, A.i OANCEA, C. LUPESCU, V. NICORESCU

RESEARCH CONCERNING THE EXTRACTION METHODS FOR PATHOGENIC YERSINIA ENTEROCOLITICA FROM PORK MEAT **1211**
La. TUDOR, I. ŢOGOE, I.L. ILIE, ANCA MARIA GALIŞ, ANETA LAURA TUDOR

RESEARCH CONCERNING THE IDENTIFICATION OF SEROTYPE O:9 OF YERSINIA ENTEROCOLITICA FROM MEAT **1215**
L. TUDOR, I. ŢOGOE, I.L. ILIE, ANETA LAURA TUDOR, ANCA MARIA GALIŞ

***DIROFILARIA IMMITIS* INFECTION – A NEW CHALLENGE FOR VETERINARY PRACTITIONERS IN IASI COUNTY** **1219**
D. ACATRINEI, L. MIRON, Simona DIMITRIU, Ana MUSTEA, Larisa PARASCA, Ramona ŞORIC

STUDIES CONCERNING THE HUMORAL IMMUNE RESPONSE AT GOATS AFTER VACCINATION AGAINST GANGRENOUS MASTITIS **1224**
A. Tudose, Turcu D., T. Perianu, Mariana Oporanu, P. Grigorescu, D. Condur, T. Petruţ

THE EVOLUTION OF RABIES IN THE NEIGHBORING COUNTRIES OF ROMANIA IN THE PERIOD 2005-2 008 **1232**
Iulia Adelina TURIAC , F. MAZDRAG, C. VASIU.

RESEARCH ON RABIES EPIDEMIOLOGY OF ANIMALS IN MUNTENIA, DURING 2005 - 2009 **1240**
Iulia Adelina TURIAC , C. VASIU , F. MAZDRAG

PRECLINICS

DETERMINATION OF TESTOSTERONE PLASMA LEVELS IN RAMS BY GAS CHROMATOGRAPHY

Sanda ANDREI, BOGDAN L., FOCSANEANU V., GROZA I., Diana CRAINIC, AnaMaria PETREAN

University of Agricultural Sciences and Veterinary Medicine Cluj-Napoca,
Faculty of Veterinary Medicine, Str. Mănăştur no. 3-5, Cluj-Napoca, Romania,
Email: sanda_m_andrei@yahoo.com

ABSTRACT:

The aim of this paper was to test a new gas chromatography method for determination of testosterone plasma concentrations in rams and to establish correlations that exist between hormones concentration and age of the rams. In order to evaluate the method of separation, purification and derivatization of testosterone in blood plasma was used internal standard procedure. Efficiency of recovery of internal standard (progesterone) had an average value of 64, 86 % which allows us to say that the method used allows a good quantification of hormones in blood plasma.
Plasma testosterone varies depending on animal age. In the samples from rams aged 2 and 3 years, there were no significant differences regarding the concentration of testosterone, the average for rams aged 2 years was 1.36 ± 0.79 ng / ml, while for those aged 3 years the average value obtained was 1.82 ± 0.83 ng / ml. Instead, in samples from rams aged 5 years have seen a sharp increase of testosterone, that reaching an average concentration of 9.63 ± 3.35 ng / ml.

Key words: testosterone, ram, plasma, gas chromatography

INTRODUCTION

The main androgen, specifically males, is testosterone, secreted by interstitial cells of the testicle. Biosynthesis of this hormone occurs from cholesterol, in two ways: one is principally located in the Leydig cells of the testicles and a secondary route that takes place in adrenal. Testosterone is the hormone responsible for the appearance of primary and secondary sexual characters and male sexual function. They can indirectly stimulate sperm maturation. Testosterone is critical for the expression of masculine sexual behaviors in mammals. Minimal concentrations of testosterone are required for expression of heterosexual mating behavior in male sheep [Roselli et al., 2002]. Testosterone secretion is correlated to external stimulants such as behavior of ewes, odor and estrous manifestation of ewes. Both sexual and pheromone production are dependent on the action of androgens [Kishk, 2008; Walkden-Brown et al., 1999]. A large variety of methods have been developed for determining concentrations of steroid hormones in biological samples. Biological tests and thin-layer chromatography were developed some time ago. More recently, in vitro tests with cell lines sensitive to hormones and immunochemistry methods were used to determine concentrations of steroid hormones. Gas chromatography and gas chromatography coupled with mass spectrometry methods were also used to detect low levels of hormones [Andrei et

al. 2009; Noppe at al., 2008]. In this study we followed, on the one hand, testing a gas-chromatographic method for determining the concentration of testosterone in plasma collected from rams, and determining the relationship that exists between this concentration and age of rams.

MATERIAL AND METHODS

Animals:
The study was conducted in a farm located in Cluj County, representing a total of 25 rams of the breed Turcana Alba, aged between 2 and 5 years. Samples of blood were collected from the jugular vein of rams, without anticoagulant, in order to separate the blood plasma. Blood plasma was then analyzed according to the following protocol.
H*ormones extraction:*
Extraction of hormones was performed in methanol, in several stages. Thus, 10ml blood plasma was added to 10 ml methanol and internal standards. Were prepared methanol standard solutions corresponding to 1 g/ml testosterone respectively 1 g/ml progesterone. Obtained suspension was maintained in an ice bath for 10 minutes and was added 10 ml distilled water. Was homogenized again, after which the samples were passed in a hot water bath at 60°C for 15 minutes. After cooling to room temperature, the mixture was centrifuge for 10 minutes at 6000 rpm. Separate liquid phase was treated, twice with hexane to remove lipids. Aqueous methanol phase was then passed into a 50 ml vial and methanol removed by evaporation (45°C) using liquid concentrator (Eppendorf Concentrator PLUS). Aqueous extract thus obtained was further separated and purified.
Purification and derivatization:
Column purification Varian C8-SPE was conditioned previously with 2 ml methanol and 3 ml distilled water. Aqueous extract was passed through the column and hormones were elute with 2 ml of methanol, were collected in another tube, after which solvents were removed by evaporation at 45°C. The derivatization reactions was performed directly into tubes which were collected extracts purified, by adding 480 l mixture BSTFA (bis-trimethylsilyl-trifluoroacetamide) - TMCS (trimethylclorosilan) in relative volumes of 2:1. Samples were kept for 2 hours at 60ºC. The solutions thus obtained were directly injected to gas chromatograph (injection volume was 2 l).
Gas chromatographic analysis: Gas chromatography separation was performed using a GC-FID system (Shimadzu GC-2010), using the following conditions: Capillary column Varian CP-Sil 5CB, 25mx0,25mm, 0,12 m; carrier gas - helium (purity 5.0), flow: 1.1 ml/min; the temperature program - 130°C (3 minutes) to 290ºC, 10°C/minute, 5 minutes isothermal; temperature of injection - 260ºC; detector temperature - 290ºC.

RESULTS AND DISCUSSION

To assess chromatograms reproducibility has made two series of injections / same sample thus determining the average error. Prior injection, under the same conditions of analysis, of a mixture of standards has allowed us to identify the separated components by comparing the retention time. In Figure 1, is shown chromatogram obtained from separation of hormones in the plasma sample collected from rams. Retention time of testosterone in plasma samples was 17.8 minutes. For progesterone the retention time was 19.1 minutes. Retention times are the same as those obtained when separating mixtures of standard solutions, progesterone and testosterone.

Figure 1: *Chromatogram obtained from plasma samples collected from rams*

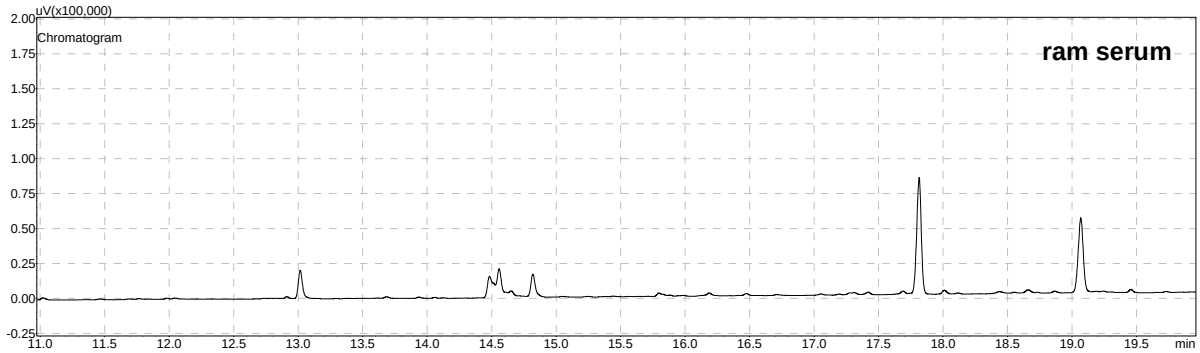

Using internal standards of precisely known concentration allows quantification of separate components by comparing the signal area with internal standards drop area. A more accurate quantitative analysis was based on the use of two standard curves. These were obtained with methanol solutions of progesterone and testosterone, having concentrations ranging from 0.01 μg / ml to 2.0 μg / ml. Equation obtained for testosterone standard curve was y = 875184x + 88948 with coefficient of linear correlation (R) of 0.993. For progesterone, the equation obtained was y = 768586x + 83584 and the coefficient R = 0.984.

In order to evaluate the method of separation, purification and derivatization of progesterone in blood plasma was used internal standard procedure. Standard used was progesterone which was added in plasma samples at the beginning of the analysis, the initial concentrations being 1 μg / sample. After GC separation, the final concentration of progesterone was determined using the standard curve. Starting from the concentration found in the end, it was calculated the percentage of progesterone recovery. This was between 38, 10% and 89.50%, the average being 64, 86 %. Yields obtained for each sample in part were used in order to calculate the concentration of testosterone; the values obtained for each sample are presented in Table 1.

No. sample	Age (years)	Testosterone (ng/ml)
1	2	0.66
2	2	1.24
3	2	0.66
4	2	2.84
5	2	1.93
6	2	0.86
Average and standard deviation		1.36±0.79
1	3	3.06
2	3	2.36
3	3	0.93
4	3	1.02
5	3	3.12
6	3	2.54
7	3	1.19
8	3	0.87
9	3	1.33
10	3	1.84
Average and standard deviation		1.82±0.83

1	5	15.74
2	5	10.19
3	5	5.48
4	5	12.31
5	5	9.34
6	5	8.06
7	5	13.13
8	5	7.03
9	5	5.43
Average and standard deviation		9.63±3.35

Table 1: *Concentration of testosterone in rams plasma*

According to Zamiri and Khodaei (2005), ram blood testosterone levels vary according to breed, nutrition level, season and age. Plasma testosterone concentrations decreased in spring (non-breeding season) and were highest at the peak of breeding season. In the current study, the samples from rams aged 2 and 3 years, there were no significant differences regarding the concentration of testosterone. As shown in Table 1, the average for rams aged 2 years was 1.36 ± 0.79 ng / ml, while for those aged 3 years the average value obtained was 1.82 ± 0.83 ng / ml. The results are consistent with those presented in the literature. In the study published by Field et al. (1989), have followed the changes occurring in rams plasma testosterone levels at average ages of 1, 1,5 and 2 years. Testosterone concentration was low values at 1 year old rams and began to grow at the age of 1.5 years. After this, the concentration does not change significantly until the age of 2 years. Moreover, increasing the concentration in the first period was correlated with the appearance of secondary sexual characteristics in ram's lambs. In samples from rams aged 5 years have seen a sharp increase of testosterone, that reaching an average concentration of 9.63 ± 3.35 ng / ml, the maximum being 15.74 ng / ml. Determination of plasma levels of testosterone, according to animal age and season, is important because the direct relationship existing between this hormone concentration, semen quality and reproductive capacity. According to data presented by Tajangookeh and colab. (2007) serum testosterone level is high for rams aged 3-4 years, reaching the maximum level in late summer. At the beginning of October, the scrotal circumference attained its maximum size, corresponding to the highest serum testosterone level. This relationship indicate that the better quality of semen and the higher reproductive capacity observed during the breeding season may be related to high levels of testosterone secretion. Inversely, the decrease in pulsatily of these hormones may contribute to the low efficiency of spermatogenesis observed in spring.

CONCLUSIONS

► We tested a gas chromatography method in order to determine concentrations of testosterone in ram plasma. In order to evaluate the method of separation, purification and derivatization of testosterone was used internal standard procedure. Efficiency of recovery of internal standard (progesterone) had an average value of 64, 86 % which allows us to say that the method used allows a good quantification of hormones in blood plasma.

► Plasma levels of testosterone, as measured by gas chromatography method proposed, are similar to those presented in the literature, so this method allows a good quantification of this hormone.

► Plasma level of testosterone is dependent on animal age. For rams aged 2 to 3 years, there were no significant variations in serum testosterone. Instead, for rams aged 5 years, has seen an increase of the concentration of this hormone.

BIBLIOGRAPHY

1. ANDREI SANDA, GROZA I., PIVARIU I., DIANA CRAINIC, SIMONA CIUPE., 2009, *Gas chromatographic determination of plasma progesterone levels in cows during the puerperal period*, Lucrări Ştiinţifice Universitatea de Ştiinţe Agricole şi Medicină Veterinară "Ion Ionescu de la Brad" Iaşi, vol. 52 seria Medicină Veterinară: 7 - 12
2. FIELD R.A., HO L., RUSSEL W, RILEY M., MURDOCH E., VAN KIRK E., ERCANBRACK S., WILLIAMS F., 1989, *Influence of age and testosterone levels on masculine development in rams,* J.Anim.Sci., 67:2943-2949
3. KISHK W.H., 2008, *Interrelationship between ram plasma testosterone level and some semen characteristics,* Slovak J.Anim.Sci., 2:67-71
4. NOPPE H., LEBIZEC B., VERHEYDEN K., DEBRABANDER H., 2008, Novel analytical methods for the determination of steroid hormones in edible matrices, Analytica Chimica Acta, 611: 10-16
5. ROSELLI C.E., STORMSHAK F., STELLFLUG J., RESKO J., 2002, *Relationship of plasma testosterone concentration to mate preferences in rams*, Biology of Reproduction 67, 263-268
6. TAJANGOOKEH H., SHAHNEH A., SHARABABAK M., SHAKERI M., 2007, *Monthly variation of plasma concentrations of testosterone and thyroid hormones and reproductive characteristics in three breeds of Iranian fat-tailed rams through one year,* Pak.J.Biol.Sci., 10(19): 3420-3424
7. WALKDEN-BROWN SW, MARTIN GB, RESTALL BJ, 1999, *Role of male-female interaction in regulating reproduction in sheep and goats*, Journal of Reproduction and Fertility (Supplement 52), 243-257
8. ZAMIRI M.G., KHODAEI, H., 2005, Seasonal thyroidal activity and reproductive characteristics of Iranian fat-tailed rams, Animal Reproduction Science, 88: 245-255

EVALUATION OF OXIDATIVE CHANGES INDUCED BY SUBCLINICAL MASTITIS IN COWS ON MILK LIPIDS

Andrei Sanda, Pintea Adela, Groza I., Crainic Diana, Matei Sorana, Ciupe Simona, Bogdan Sidonia

University of Agricultural Sciences and Veterinary Medicine Cluj-Napoca,
Faculty of Veterinary Medicine, Str. Mănăştur no. 3-5, Cluj-Napoca, Romania,
Email: sanda_m_andrei@yahoo.com

ABSTRACT:

The purpose of this paper was to highlight some changes relating to the composition of fatty acids and cholesterol in subclinical mastitis milk. Subclinical mastitis diagnose was realized using electrical conductivity method and also by determining the number of somatic cells in milk. Next, using gas chromatograph, we conducted a comparative study of fatty acids and cholesterol profile in milk from cows diagnosed with sub clinical mastitis and milk from healthy cows. In parallel we determined the oxidative degradation of lipids, using classical test based on the determination of malonyldialdehyde.
Mastitis milk contains higher proportions of short chain saturated fatty acids C10 - C14 and stearic acid. Instead we observed a lower proportion of unsaturated acids. In mastitis milk was seen as a high level of somatic cells can be correlated with an increase in the concentration of MDA, so with increased lipid peroxidation processes and decrease the proportion of unsaturated fatty acids. Cholesterol content in normal milk has a range between 10.49 and 11.89 mg/100ml milk (similar to data presented in the literature). Lowering cholesterol concentrations in samples of mastitis milk is accompanied by the appearance of oxidation products of cholesterol.

Key words: milk, mastitis, fatty acids, cholesterol, lipids peroxidation

INTRODUCTION

Numerous studies, especially for cow's milk, indicate that changes in the number of somatic cells are related to changes in the composition of milk. These changes may appear due to injurious processes mammary cells, which reduces the synthesis of milk constituents in the gland. Another explanation is the change in membrane and interstitial spaces permeability, which increases the passage of the components of blood in milk. Effect of mastitis on lipid content is not yet fully understood and known literature articles presenting contradictory data. It is known that lipids present in mastitis milk, are easily susceptible to the action of lipases produced by leukocytes that occur in the mammary gland in response to inflammation. The action of these enzymes causes a decrease in triglyceride levels with a concomitant increase in peroxidation processes in the fatty acids. Milk with higher content of somatic cells is more susceptible to spontaneous lipolysis processes [Pterovski, 2006].
The purpose of this paper was to highlight some changes relating to the composition of fatty acids and cholesterol in mastitis milk. The first step was to diagnose mastitis, using electrical conductivity as a diagnostic method and number of somatic cells in milk. Next, we conducted a

comparative study of fatty acids and cholesterol profile in milk from cows diagnosed with sub clinical mastitis and milk from healthy cows. In parallel we determined the oxidative degradation of lipids, using classical test based on the determination of malonyldialdehyde. By attending these goals we wanted to obtain new information about mastitis induced oxidative stress and how it works in the lipids and lipid components in milk mastitis.

MATERIAL AND METHODS

Sampling of milk and mastitis diagnosis

The research was conducted during January 2009 - March 2009 in a farm in Cluj County. Currently the farm has a herd of 120 cows. Mastitis diagnosis was made by Waikato mastitis indicator, a physical method for determining the quality of milk based on its electrical conductivity. Determination of milk somatic cell count was done automatically, using MT-04 device.

Analysis of fatty acids and cholesterol in milk

Analysis of fatty acids and cholesterol was performed on total lipid extracts obtained in methanol and chloroform, classical Folch method [Andrei and colab., 2001].

Analysis of fatty acids in total lipid extracts was performed in two stages. In the first step was performed methylation of fatty acids (using a solution of BF_3 in methanol) and in the next step methyl esters were separated by gas chromatography (GC) [Andrei and colab., 2001]. It was used a Shimadzu GC - 2010 gas chromatograph, with FID detector, equipped with a capillary column ALLTECH FAME AT-CP-SIL 5 CB (column length is 30 m, diameter 0.25 mm and 0.25 m film thickness). Separation program used was as follows: injector and detector temperature of 260°C and 290 ˚C; program column - 3 minutes at 40 C, temperature gradient of 15°C per minute up to 200°C and hold 3 min, temperature gradient of 20°C per minute up to 240°C and hold 5 min; helium flow rate of 1.9 ml per second, the injection volume was 2 l sample. Identification of methyl esters was done by comparison with retention time of standards (FAME from Sigma), separated under the same conditions. To check the reproducibility analysis were carried out two series of injections for each sample, thus determining the standard error.

Analysis of total cholesterol present in lipid extracts from milk was performed in two stages - cholesterol derivatization followed by gas chromatographic analysis. First, we measured 1 ml total lipid extract and evaporated to dryness. To achieve derivatization reaction were added to 480 l mixture BSTFA (bis-trimethylsilyl-trifluoroacetamide) - TMCS (trimethylchlorosilane) in 2:1 volume ratio. Samples were maintained 120 minutes at 60°C. The solution thus obtained was directly injected into gas chromatograph (injection volume was 2 l).

Separation of cholesterol was performed with a Shimadzu GC 2010 gas chromatograph - equipped with capillary column Varian CP-Sil 5CB (column length is 25 m, diameter 0.25 mm and 0.12 m film thickness). Separation program was used in the gradient, as follows: 3 minutes at the initial temperature of 130°C, gradient of 10°C per minute up to 290°C and 5 min Injector and FID detector temperature of 260°C and 290˚C and helium flow of 1.1 ml/second.

Assay of cholesterol present in the samples was performed using internal standard. This method allows accurate determination of individual cholesterol in milk samples by comparing the signal area in the chromatogram obtained with signal area obtained when cholesterol concentration exactly known. For greater accuracy, in this case has been used a standard curve obtained with standard solutions with concentrations between 0.05 g / ml and 4.0 g / ml (Figure 1).

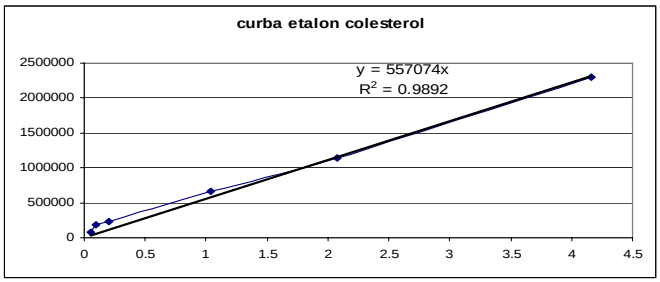

Figure 1: *Cholesterol standard curve*

Determining the level of lipid peroxidation was realized by photometric method based on reaction thiobarbituric acid (TBA). It reacts in acid medium, with malonyl dialdehyde resulting from peroxidation processes, forming a red colored compound which was dosed photometrical at 535nm using UV-Vis spectrophotometer Jenway 6315. For calculation we used the MDA standard curve obtained by acid hydrolysis of 1,1,3,3-tetramethoxypropane (TMP) [Andrei and colab., 2008].

RESULTS AND DISCUSSION

Diagnosis of mastitis milk samples

After analyzing samples from a total of 120 cows, with Waikato indicator, we diagnosed a total of 12 cows as positive. Upon determination by MT-04 device in the 12 samples diagnosed positive, we obtained values above normal somatic cells allowed, with values ranging between 500,000 and 1,200,000 cells/ ml.

Fatty acids analysis

Identification of fatty acids was achieved by comparing the chromatograms obtained with those achieved with standard mixtures of fatty acids in the same chromatographic analysis. Figure 2 shows chromatograms obtained for separation of fatty acids in normal milk samples compared to mastitis milk.

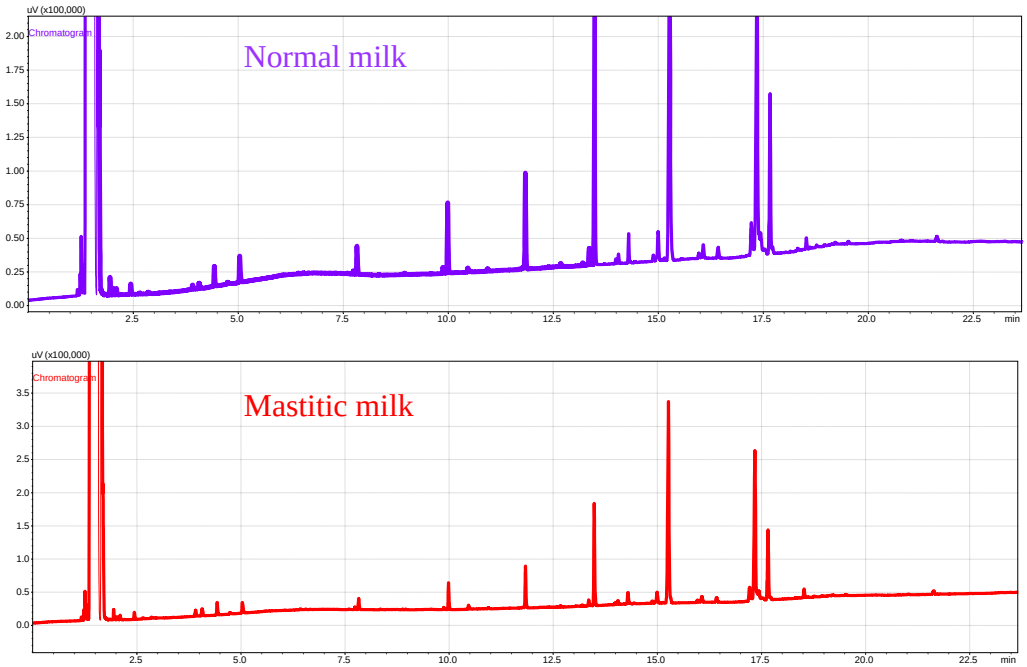

Figure 2: *Fatty acids chromatograms*

Major components of the lipophilic fraction of milk, are fatty acids. It should be noted that in cow's milk have been identified 406 fatty acids, but only 12 of them are in percentages higher than 1% of total [Jensen, 2002].

Table 2 contains the results obtained in the analysis of fatty acids (FA) in normal and mastitis milk. Results are expressed as % of total fatty acids separated. For a better interpretation of results, table 2 shows the contents of total lipid extracts in different classes of FA: saturated fatty acids (SFA), monounsaturated fatty acids (MUFA) and polyunsaturated fatty acids (PUFA).

A comparative analysis of the fatty acid composition in normal and mastitis milk, it is apparent that they contain the same major fatty acids. The most important fatty acids in both samples are in order: palmitic acid, oleic acid, linoleic acid, stearic acid and myristic acid. They represent about 90% of total fatty acids. From table 2 we see also that mastitis milk contains higher proportions of short chain saturated fatty acids C10 - C14 and stearic acid. Instead we observed a lower proportion of unsaturated acids.

Most important substrate of peroxidation is the polyunsaturated fatty acids. Moreover, the lipid peroxidation process can be followed by determination of the PUFA, it is actually decreasing consequently the degree of peroxidation [Andrei and colab., 2008]. We consider the results obtained in the analysis of fatty acids in mastitis milk as extremely important, because until now no specific studies have been published showing the relationship between fatty acid profile of milk and subclinical mastitis. Also, data obtained in the determination of fatty acids can be correlated with those obtained for the lipid peroxidation - MDA test.

Fatty acid symbol	% FA	
	Normal milk	Mastitis milk
8:0	1,27	1,27
10:0	1,18	1,58
12:0	2,37	2,56
14:0	8,55	8,38
16:0	36,87	36,39
18:0	10,45	16,67
Total SFA	60,69	66,85
16:1	1,95	1,01
18:1	26,95	23,14
Total MUFA	28,9	24,24
18:2	9,8	8,6
18:3	0,59	0,3
Total PUFA	10,39	8,9

Table 2: *Fatty acid composition of total lipids in normal and mastitis milk*

Evaluation of lipid peroxidation levels

Malonyldialdehyde (MDA), one of the products resulting from peroxidation of unsaturated fatty acids, is frequently used as a marker of peroxidation [DelRio and colab., 2005]. The results obtained in the determination of malonyldialdehyde in the samples analyzed in this study are presented in Table 3. In mastitis milk was seen as a high level of somatic cells can be correlated with an increase in the concentration of MDA, so with increased lipid peroxidation processes.

Sample	MDA nmoli/ml milk	Cholesterol mg / 100ml milk
Normal milk	14,62±4,91	11,04±0,66
Mastitis milk	26,7±12,77	7,28±2,07

Table 3: *Malonyldialdehyde (MDA) and cholesterol concentrations in milk samples*

Cholesterol analysis

For identification and determination of cholesterol present in milk samples were previously injected standard solutions of exactly known cholesterol concentration and comparing the corresponding retention times. As can be seen from Figure 3, retention time value (corresponding cholesterol) was 22.4 minutes in all samples.

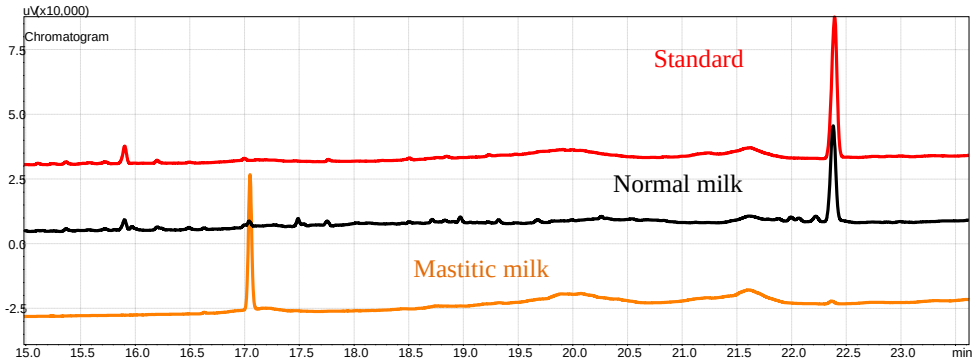

Figure 3: *Chromatograms obtained in the separation of cholesterol*

Cholesterol content in milk normally has a range between 10.49 and 11.89, are similar to data presented in the literature (table 3). Cholesterol concentration in milk varies between 10-20 mg/100 ml; the quantity is directly proportional to fat content, representing approximately 0.3% of total lipids present in milk [Grundy, 1999; Taylor and MacGibbon, 2004]. In milk samples from cows with subclinical mastitis was observed that lowering cholesterol occurs by averages of 7.28 mg / 100 ml milk. Be noted however that the results of table-related mastitis milk, represent the average of 7 samples. In case of 3 mastitis milk samples, cholesterol was very low, below detection limit. In these samples (as can be seen from Figure 3), while the sharp decrease in the signal corresponding cholesterol, there is another signal (the retention time of 17 minutes). We suppose that this signal could correspond to products result from cholesterol oxidation, further studies are needed for exact identification of them. Also note that no data were identified in the literature to study the link between cholesterol and products of oxidation in oxidative stress-induced mastitis.

Cholesterol is easily oxidized leading to the formation of various peroxides and hydro peroxides. Thus, by oxidation, 5 and 7 hydroperoxycholesterol are formed and also various decomposition compounds as 7 and 25 hydroxycholesterol, 7 ketocholesterol and colestan 3,5,6 triol. The probability that these oxidation products to form in normal milk is very low because, on the one hand it is a liquid medium with a low oxygen content and on the other hand the polyunsaturated fatty acids and pro-oxidant factors (such as copper or iron ions) are also very low [Sieber, 2005]. In another study, conducted by Jensen and Clark (1998), it is noted that compounds derived from oxidation of sterols occur in raw milk in concentrations of 2 ppm and 0.2 mg / 100 ml milk and are very difficult to detect.

In the milk collected from cows with subclinical mastitis, the probability of occurrence of cholesterol oxidation products is higher. Polimorphonuclear neutrophiles (PMN) are the main

components involved in cellular immune response against infection; these cells are those who migrate to infection site to destroy the bacteria. Antibacterial neutrophils activity is mediated in large part through reactive oxygen species (ROS) [Andrei et al., 2009]. Various infectious diseases of farm animals, such as pneumonia, enteritis, mastitis are associated with oxidative stress. Although essential to the body, an excess of oxidative reactions in the antibacterial processes can cause damage to the tissues. An excess of ROS and the absence of optimal amounts of antioxidants resulting emergence as oxidative stress.

From toxicological point of view, consumption of foods containing products derived from oxidation of cholesterol should be avoided because they have various adverse biological effects. Thus, these oxidation products are considered cytotoxic and even mutagenic and carcinogenic [Sieber, 2005].

CONCLUSIONS

Research conducted on the diagnosis of sub clinical mastitis shows that the Waikato method presents a good precision. Data obtained by this method were correlated with those obtained in determining the number of somatic cells with the MT-04. Thus, cows diagnosed positive with the Waikato in an increasing number of somatic cells beyond the normal allowance.

Correlations were established between oxidative stress induced mastitis and fatty acid profile and cholesterol in milk that lipid peroxidation level present in milk.

► Profile of fatty acids in milk collected from healthy cows is within the range of literature data. Mastitis milk contains higher proportions of short chain saturated fatty acids C10 - C14, and stearic acid and a lower proportion of monounsaturated and polyunsaturated fatty.

► Cholesterol content in normal milk has a range between 10.49 and 11.89 mg/100ml milk

(similar to data presented in the literature). Lowering cholesterol concentrations in samples of mastitis milk is accompanied by the appearance of oxidation products of cholesterol.

► In milk samples with a high number of somatic cells cholesterol concentrations was extremely low, below detection limit.

► Increased high milk somatic cells is correlated with an increase in the concentration of MDA, thus with an increase of lipid peroxidation processes.

This work was supported by research program PN II "IDEI", 1482/2009.

BIBLIOGRAPHY

1. ANDREI SANDA, PINTEA A., VARGA A., CĂTOI C., BABA A.I., Determination of lipids and fatty acids in spontaneous tumors, *Bulletin USAMV Cluj-Napoca, Series Medicine Veterinary,* 55-56, 219, 2001
1. ANDREI SANDA**,** PINTEA ADELA, BUNEA ANDREA, Influenţa metodelor de procesare asupra activităţii antioxidante a laptelui, *Lucrări Ştiinţifice Universitatea de Ştiinţe Agricole şi Medicină Veterinară "Ion Ionescu de la Brad" Iaşi*, vol. 51(10) seria Medicină Veterinară: 585-590,2008
2. ANDREI SANDA, ADELA PINTEA, ANDREA BUNEA, GROZA I., BOGDAN L., SORANA MATEI, SIMONA CIUPE, Diana Crainic, Non-enzymatic antioxidants concentration and lipids peroxidation level in milk from cows with subclinical mastitis, *Bulletin USAMV series Veterinary Medicine* 66(1): 196-202, 2009
3. DELRIO D., AMANDA J. STEWART , PELLEGRINI N., A review of recent studies on malondialdehyde as toxic molecule and biological marker of oxidative stress*, Nutrition, Metabolism & Cardiovascular Diseases,* 15: 316-328, 2005

4. GRUNDY S.M., Cholesterol, factors determining levels in blood, *Encyclopedia of Dairy Sciences*, 1604-1611, 2004

5. JENSEN R.G. and CLARK R.W., Lipid composition and properties. In: Wong NP, Jenness R, Keeney M and Marth EH (eds.) *Fundamentals of Dairy Chemistry*, 3rd edn, pp. 171-213. New York: Van Nostrand, 1998

6. JENSEN R.G., The Composition of Bovine Milk Lipids: January 1995 to December 2000, *Journal of Dairy Science*, 85:295–350, 2002

7. PETROVSKI K.R., Milk composition changes during mastitis, *Dairy Vets Newsletter*, 23: 7-10, 2006

8. SIEBER R., Oxidised cholesterol in milk and dairy products, *International Dairy Journal* 15:191–206, 2005

9. TAYLOR M. W., MACGIBBON A. , *Triacylglycerols* Vol. 3. Elsevier Science Ltd., London, UK, 2002

THE IMMUNOSTIMULATORY EFFECT OF THE LEPTIN ON THE MESENTERIC LYMPHNODE IN WISTAR RAT

G.R. BOTEZATU [1], C.COMAN [2], Manuella MILITARU [1], N.CONSTANTIN [1]
[1] Facultatea de Medicina Veterinara Bucuresti
[2] INCD Cantacuzino Bucuresti

ABSTRACT

The functional correlations of the leptin to the immune system component parts, both at humans and animals, were not elucidated enough.During this experiment, we studied the effects of the leptin on lymphocytes at Wistar rats. We compared these effects with Cantastim a product having doubtless stimulating effects (cantastim).The obtained results emphasize the fact that the leptin stimulates the respective cells in a way similar to Cantastim. These data indicate the necessity of deeper researches regarding the leptin effects upon the components of the immune system.In the context of this reality, the study of the functional relations of the leptin to the cellular components of the immune system can be justified and represents a new approach in biology and medicine.Consequently, the present paper deals with the research on the reactivity degree of the components of the secondary lymph system (mesenteric lymph node), as a result of the leptin action, at Wistar rats. In order to evaluate the effects of the leptin, we compared them to the effects of the Cantastim. The use of Cantastim is based on the known effect of this product on the modulation of the immune system components, both at the animals from laboratory and humans.Normal lymph nodes characteristically have a heterogeneous population of lymphoid and non lymphoid cells within a clear background. The lymphoid cells are predominantly small, well-differentiated lymphocytes with nuclear diameters equivalent to one red blood cell. There are low numbers of medium –sized lymphocytes, or centrocytes, and rarer immature cells, or centroblast.

Key words: leptin, cantastim, immune system

MATERIAL AND METHOD

The researches were performed on a number of 30 adult male Wistar SPF rats that were kept in conventional conditions. They were divided into 3 groups:

- **Group 1** (witness) - 10 rats that have been given 0.2ml of physiological serum subcutaneously (s.c.), daily, for 7 consecutive days.
- **Group 2** – 10 rats that have been given 0.1ml of leptin s.c., daily, for 7 consecutive days
- **Group 3 –** 10 rats that have been given 0.2 ml of Cantastim s.c., daily, for 7 consecutive days.

The experiment (groups of animals, treatments, animals ‘immolation) was performed at Cantacuzino Institute Animal Facility- Bucharest and it keeps to the laws of the researches.
We used the following preparations: Cantastim produced by INCD- Cantacuzino, Bucharest and leptin produced by Sigma company (leptin fragment 93-105).

The sampling was performed 7 days after the inoculation at the witness group, on a number of 5 animals and on 5 animals each, at groups 2 and 3 (these groups had been identified with 1.1; 2.1; 3.1). The other 5 animals were inoculated after 14 days (identified with groups 1.2; 2.1; 3.2) (Table 1)

Table 1- The group distribution of the animals

Subcutaneously administered product	**Group**	**Sampling after 7 days**	**Sampling after 14 days**
Physiological serum	**Group 1(witness)**	Group1.1 – 5 rats	Group 1.2 – 5 rats
Leptin	**Group 2**	Group2.1 - 5 rats	Group2.2 – 5 rats
Cantastim	**Group 3**	Group 3.1 – 5 rats	Group 3.2 – 5 rats

A mesenteric lymph node had been sampled after the euthanasia and weighing of each rat. This lymph node has been weighed and then, we took samples for the cytological and histological exam. The samples have been processed and analyzed at the laboratory of Pathological Anatomy belonging to the Faculty of Veterinary Medicine, Bucharest. The cytological preparations performed through stamp have been dried and colored using May-Grunwald-Giemsa method. The examination of the smears was made using an Olympus CX 21 microscope, provided with digital equipment in order to take the microscopic pictures. For the histological exam, the samples were hitched in a solution of formaldehyde, introduced in paraffin, divided with the microtome and then colored using Masson trichromic method.

RESULTS

The results of the investigations on the studied groups were presented synthetically in tables 2,3 and 4 and in graphic 1 and pictures 1-9.

Table 2- The gravimetric aspects of the lymph node (**Ln**) and the animals used in this experiment.

No.	**Group**	**The (average) weight of Wistar rats after immolation(grams)**	**The (average) weight of mesenteric lymph node (grams)**	**The percentage of the Ln weight related to the animals' weight (%)**
1	Group 1.1	139	1,8	1,3
2	Group 2.1	144	2,4	1,7
3	Group 3.1	141	2,1	1,5
4	Group 1.2	165	2,8	1,7
5	Group 2.2	172	4,8	2,8
6	Group 3.2	169	4,1	2,4

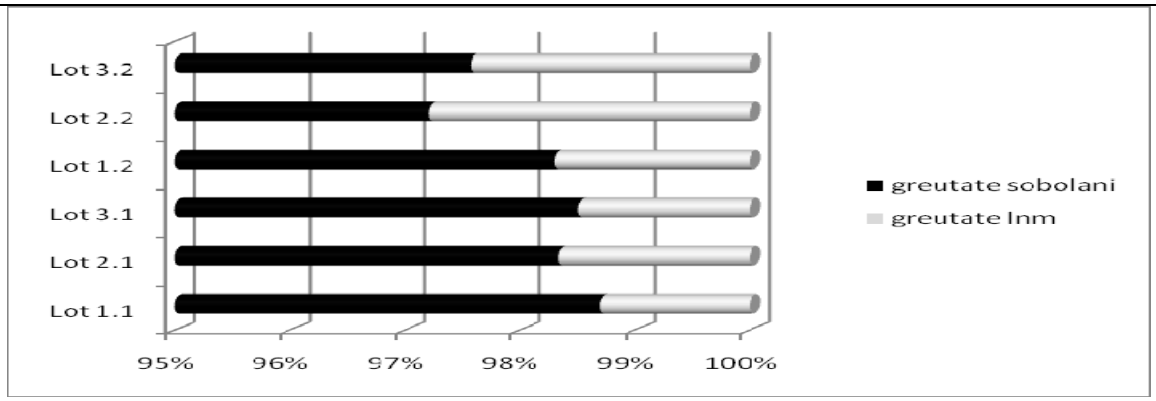

Graphic 1 The mesenteric lymph node weight related to the animals' weight-percentage

Table 3- The adenogram of the Wistar rats used in the experiment

No.	Group	Types of emphasized cells
1	1.1 and 1.2	The cellular population is dominated by little lymphocytes with hiperchrome nucleus and rare medium lymphocytes with euchromatic nucleus and chromo centers.
2	2.1	The cellular population is represented by little and medium lymphocytes and rare big lymphocytes with euchromatic nucleus. We notice a slight process of lymphocitary activation.
3	3.1	The cellular population is similar to that of 1.2 group. We notice a slight process of lymphocytary activation.
4	2.2	The dense cellularity; dominated by medium and big lymphocytes with euchromatic nucleus and centroblasts; we notice a process of obvious immunological stimulations
5	3.2	Cellular population dominated by medium and big lymphocytes, a less number of lymphocytes than 2.2.group; it shows a process of obvious lymphocytary activation.

Tabel 4-The histological aspects of mesenteric lymph nodes

No	Group	The histological features of lnm
1	1.1 and 1.2	The sub capsular sinuses lack lymphocytes, the medullar sinuses with rare lymphocytes, the lymph nodes are little without signs of activation, and the paracortical zone is less represented.
2	2.1	Subcapsular and medullar sinuses with medium cellularity, well represented, activated lymph nodes with germinative center, the paracortical zone is less represented.
3	3.1	Histological image comparable to that of the 2.1 group
4	2.2	Subcapsular and medulary sinuses with high cellularity, activated lymph nodes with well represented germinative center well represented paracortical zone. We notice a strong process of immunological activation.
5	3.2	Subcapsulary and medulary sinuses with well represented cellularity, lymph nodes with obvious germinative center, well represented paracortical zone. We notice a process of immunological activation.

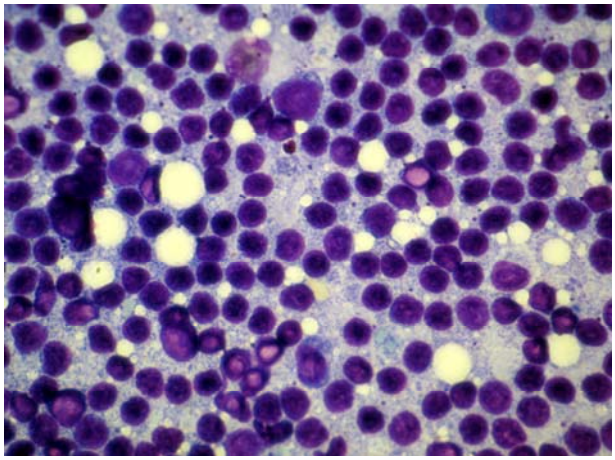

Picture 1. Mesenteric lymph node- Wistar rat, group 1.1. Little non-stimulated lymphocytes (MGG x1000 colouring)

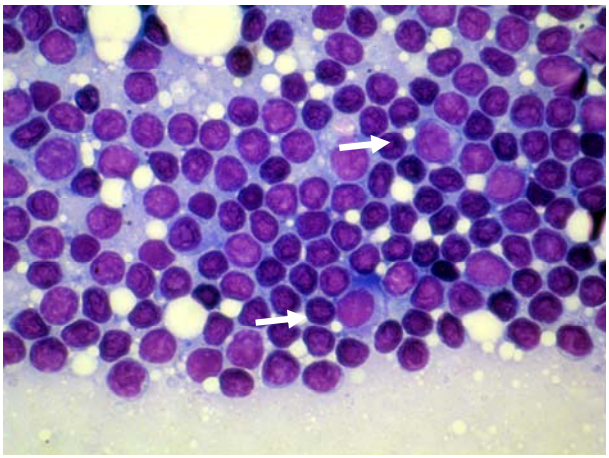

Picture 2. Mesenteric lymph node- Wistar rat, group 2.1. Little and medium (arrow) lymphocytes (MGG x1000 colouring)

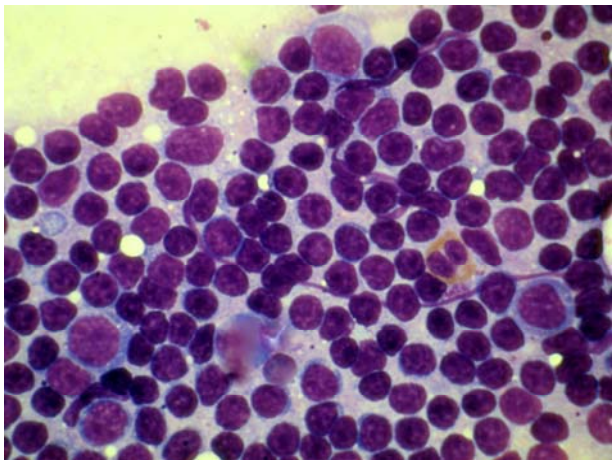

Picture 3. Mesenteric lymph node- Wistar rat, group 3.1. Rare lymphoblasts (MGG x1000 colouring)

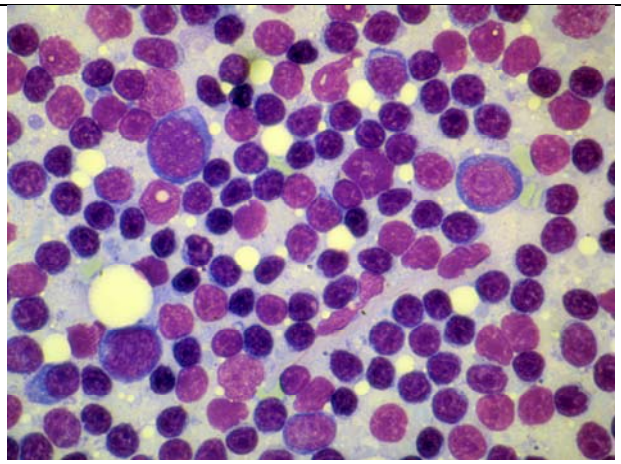

Picture 4. Mesenteric lymph node- Wistar rat, group 2.2. Little and medium lymphocytes(lymphoblasts/centroblasts)- reactive lymph node (MGG x1000 colouring)

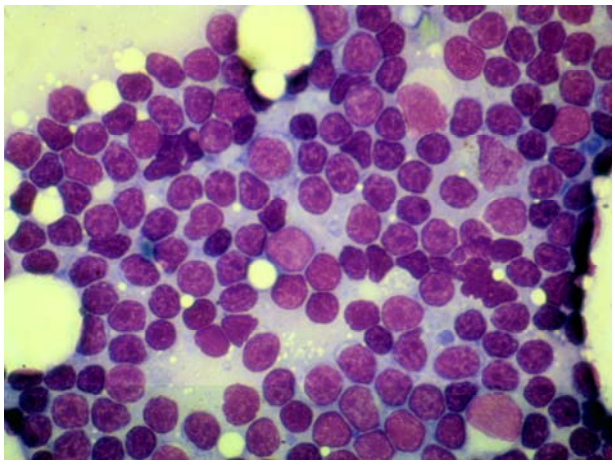

Picture 5. Mesenteric lymph node- Wistar rat, group 3.2. Little and medium lymphocytes-reactive lymph node (MGG x1000 colouring)

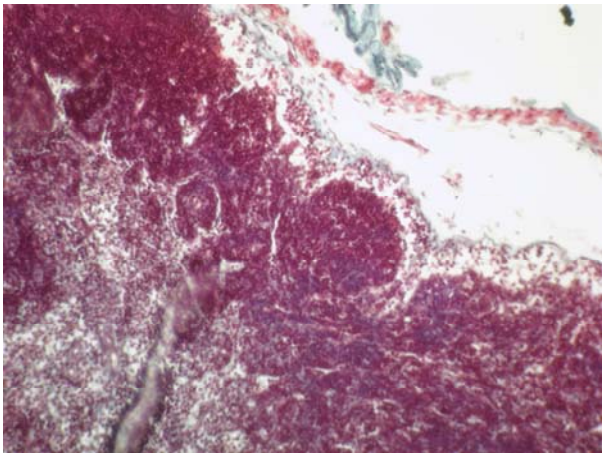

Picture 6. Mesenteric lymph node-Wistar rat, 2.1 group. Obvious lymph nodes, medium cellularity in subcapsular and medullar sinuses (trichromic colouring Masson, x 100)

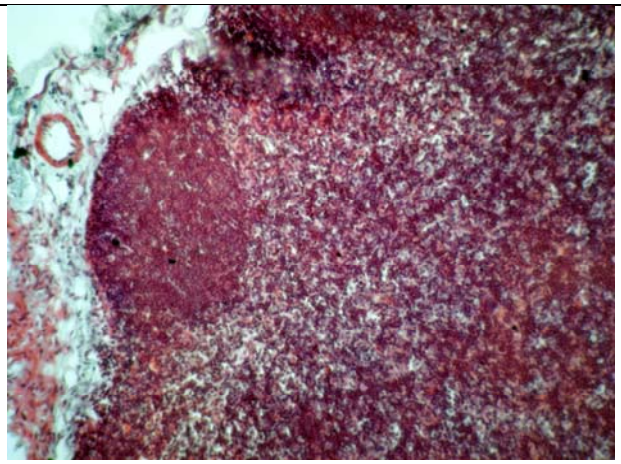

Picture 7. Mesenteric lymph node-Wistar rat, 3.1 group. Obvious lymph nodes (trichromic colouring Masson, x 100)

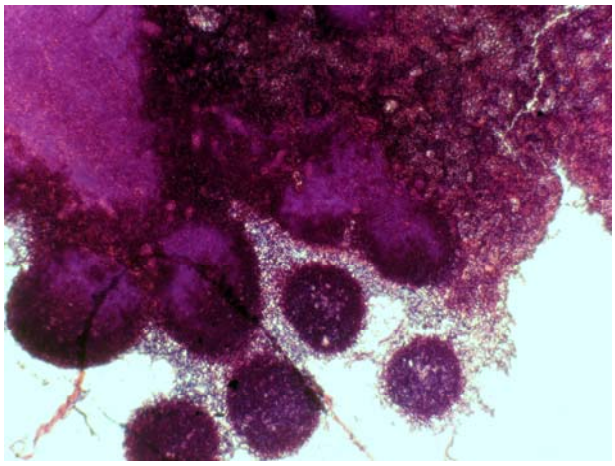

Picture 8. Mesenteric lymph node-Wistar rat, 2.2 group. Nodes with germinative centers (trichromic colouring Masson, x 100)

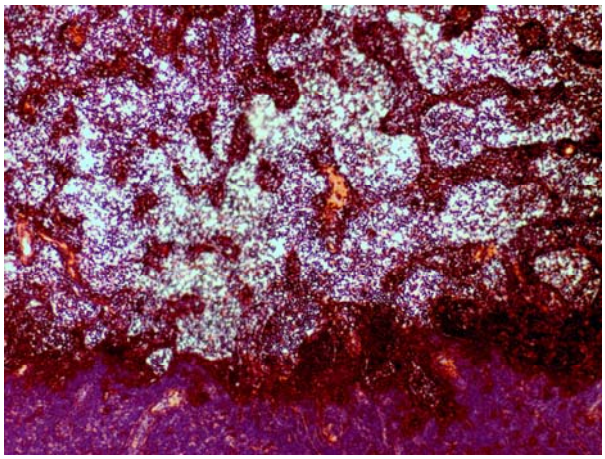

Picture 9. Mesenteric lymph node-Wistar rat, 3.2 group. Numerous lymphocytes in the medullar sinus (trichromic colouring Masson, x 100)

DISCUSSIONS

At the level of the witness group, we notice a steady lymphocitary population, obviously antigenic inactivated. The administration of the leptin and Cantastim determines an obvious antigenic stimulation. From the cytological point of reference, at the groups that were

administrated with leptin and Cantastim and immolated after 7 days since their last inoculation, we notice a similar number of little and medium lymphocytes, medium lymphocytes with little chromocenters. We also observe an incipient process of immunological activation. From the cytological point of reference, at the groups that were administrated with leptin and Cantastim and immolated after 14 days since their last inoculation, we notice a big number of medium lymphocytes, a few little lymphocytes; big lymphocytes whose nucleus has centrometers. These images suggest an important immunological activation. The percentage of medium and big lymphocytes is bigger at the group that received leptin than at the one that received Cantastim. From the histological point of reference, at the witness group we don't notice the presence of the lymphocytes at the level of the medullar and subcapsular sinuses, the lymph nodes are little, non-activated, without germinative center and the paracortical zone is less represented. At the groups that were administrated with leptin and Cantastim and have been immolated after 7 days since their inoculation, we notice a relatively little cellular population at the level of medullar and subcapsular sinuses. The lymph nodes are well delimited, bigger than the ones belonging to the witness group. The paracortical zone is less represented. At the groups that were administrated with leptin and Cantastim and were immolated after 14 days since their last inoculation, at the histological exam, we notice a rich cellular population at the level of medullar and subcapsular sinuses. The lymph nodes are activated, with a germinative center and paracortical zone that are well represented. When comparing the weight of the mesenteric lymph node to the weight at the moment of immolation, we notice a gradual increase of its mass. The most significant is the one belonging to the group that was administered with leptin and was immolated after 14 days since their last inoculation. Its weight grew from 1.7% to 2.8%.

CONCLUSIONS

1. The leptin induces stimulating effects on the lymphocytes, similar to the Cantastim. This fact emphasizes the statement that the leptin has stimulating effects on the respective cells.
2. The stimulating effect of the leptin is intensely presented at the level of mesenteric lymph node after 14 days since its last administration, being compared to the Cantastim.
3. The present experiment emphasizes the fact the stimulating effects of the leptin on the immune system were not enough studied in the specialized literature. These actions need detailed explanations and thorough future researches.

REFERENCE

1. Salageanu Aurora, G.Szegli - *„Experimental studies on bacterial immunomodulator CANTASTIM I. Modulation of TNF alpha production"*- Rom.Arch.Microbiol.Immunol. T53, 4, 254-265, 1994
2. Baker Rebecca, J. H. Lumsden. - *Color Atlas of Cytology of the Dog and Cat*, Elsevier, 2008
3. Dellmann D. H., Johnn Eurell-*Textbook of Veterinary Histology*- vol V, Ed. Lippincott Williams and Wilkins, Philadelphia, Baltimore, New York- London, 1998
4. Dardenne M., Bazin H., Guenet J.L.-*Immunologie des rongeurs* -Paris, 1992
5. Weiss L.-*Cell and Tissue Biology*- Sixth Edition, Urban and Schwarzenberg, Inc.,1988
6. Waelput W, Brouckaert P, Broekaert D, Tavernier J. - "*A role for leptin in the systemic inflammatory response syndrome (SIRS) and in immune response.*". Current drug targets. Inflammation and allergy 1 (3): 277–89, 2003
7. Fernandez-Riejos, Patricia; Gonzalez-Yanes, Carmen; Najib, S.; Martin-Romero, Consuelo; Santos-Alvarez, J.; Sanchez-Margalet, V., Role of Leptin in the Immune System, Current Immunology Reviews, Volume 4, Number 4, pp. 230-234(5), November 2008

THE DYNAMICS OF THE SHELL MEMBRANES FORMATION IN THE ISTHMUS OF THE LOHMANN BROWN LAYING HENS

C. TODIREANU, C. COTEA, Carmen SOLCAN
Faculty of Veterinary Medicine, Iași

ABSTRACT

The present study elucidates the morphology and histochemistry of the isthmus of 12 Lohmann brown laying hens aged between 40 and 47 weeks; and also the dynamics of the shell membranes formation. The samples were taken from the two segments (anterior and posterior) of the isthmus, fixed in 10% formalin, Orth and Carnoy; included in parrafin, and sectioned at the size of 5 µm. The samples were stained HEA, PAS, Alcian blue, Papanicolau, Novelli and Gomori. At the surface epithelium level, there are proteoglycans - secreting cells and ciliated cells. In the lamina propria there are numerous tubular glands that elaborate the protein secretion that structures the shell membrane. This secretion appears in the lumen under the shape of filaments or matrix, which is the main component of the shell membranes.
The tunica muscularis is structured from two layers of smooth muscle: the inner layer, measuring 150–200 µm, and the outer layer, measuring 200–225 µm.

Key words: morphology, histology, isthmus, hen

This research has been focused on the isthmus of the Lohmann brown chickens, in the peak of the laying period, because of the lack of data in the literature about the morphology and histochemistry of the isthmus of this hybrid, specialized in egg production. This study also elucidates the dynamics of the shell membranes formation in the isthmus of the hen because this segment of the oviduct contributes to the defining of the egg in the shortest time.
The Lohmann brown hybrid has been chosen because it is one of the best hybrids specialized in egg production from both the quality and quantity point of view.
It is considered that each segment of the oviduct contributes to this performance of the hybrid, and so does the isthmus through it's secretion that materializes in the formation of the shell membranes.

MATERIAL AND METHOD

We studied 12 Lohmann brown chickens, at the peak of the laying period, between 40 and 47 weeks of age, a hybrid which is specialized in the egg-production.
The birds were slaughtered and their isthmus prelevated and fixed in 10% formalin (fig. 1, fig. 2). The isthmus was divided into 2 areas: anterior and posterior, from which we prelevated a sample, chiseled it, and refixed in formalin 10%, Orth or Carnoy. After the fixing, the samples were included in parrafin, sectioned at 5 µm, stained in H.E.A., PAS, Gomori, Papanicolau, Alcian blue and Novelli.

RESULTS AND DISCUSSIONS

The isthmus is a segment of the oviduct which is delimitated clearly from the magnum by a transparent band and from the uterus by the lack of the folds (7). The length of this segment is

8 to 9 cm and the thickness is 2 to 3 cm and has the function of elaborating the shell membranes of the egg (8), (fig. 3, fig. 4).

The main histological structures of the isthmus of the Lohmann brown hens that were studied are presented in Table 1, with their size is expressed in micrometers (µm).

Table 1

The size in "µm" of the main histological structures of the two segments of the isthmus of the Lohmann brown hens that were studied

The area of the isthmus / The structure	Anterior isthmus	Posterior isthmus
The prime fold	1800–2000	2000–2500
The surface epithelium	20–22	20–23
The cytoplasm granules	1,5–2	1,5–2
The cilia	4–5	4–5
The nucleus	6–7	6–7
The nucleolus	1,5–2	1,5 –2
The tubular glands	40–50	40–55
The lumen of the gland	7	7
The height of the cells	15–20	15–20
The nucleus of the gland cells	5	5
The secretion granules	1,5–2	1,5–2
Tunica muscularis–the inner-circular layer	150– 200	150–200
Tunica muscularis–the outer layer	200–225	200–225

The isthmus is structured from a tunica mucosa made of a surface epithelium and a lamina propria with numerous glands; a thin tunica submucosa made of a delicate conjunctive tissue; a tunica muscularis structured in two layers of smooth muscle separated by a delicate conjunctive tissue and a tunica serosa which is the visceral peritoneum (1, 3). The mucosa is folded, these folds are arranged parallel and longitudinal, and measure between 1800 and 2500 µm (fig. 23, fig. 24). There are prime, secondary and tertiary folds, which enlarge the surface of secretion (fig. 5, fig. 8, fig. 13). The surface epithelium is formed of ciliated cells and proteoglycans-secreting cells (6), (fig. 6, fig. 10, fig. 17, fig. 18). In the lamina propria there are numerous tubular glands (fig. 7, fig. 9, fig. 21, fig. 22). The apical pole of the glandular cells consists of numerous secretion granules with sulphate proteoglycans (fig. 12, fig. 14). The secretion of the tubular glands appears in the shape of filaments or long rows of granules (fig. 11). From the secretory activity of these glands the inner and outer shell membranes are created (2, 5). This elaboration takes an hour (4). The tunica muscularis is structured from two layers of smooth muscle: the inner layer, measuring 150–200 µm, and the outer layer, measuring 200–225 µm (fig. 15, fig. 16, fig. 19, fig. 20).

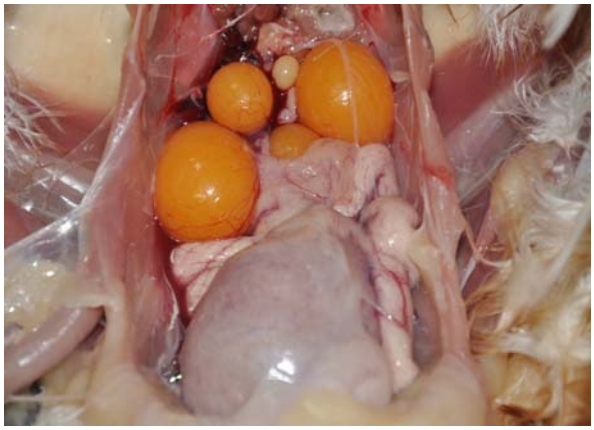

Fig. 1. The female reproductive sistem of the layer hen with the egg in the uterus.

Fig. 2. The ovary and oviduct of a 40 weeks old Lohmann Brown layer

Fig. 3. The ovary and the oviduct with the five segments: Infundibulum, magnum, isthmus, uterus and the vagina

Fig. 4. The mucosa of the five segments of the oviduct and the position of the egg in the posterior third of the magnum

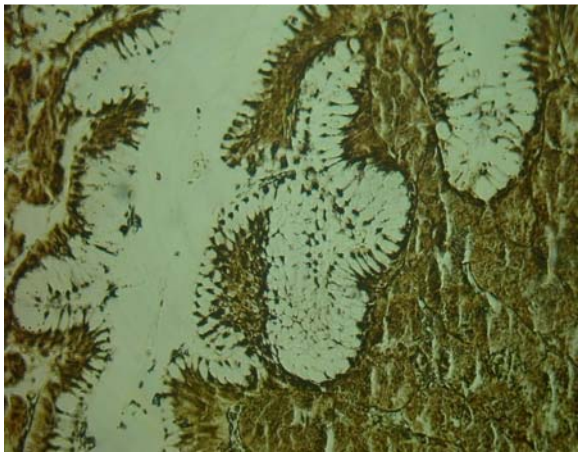

Fig. 5. The anterior zone of the isthmus. The secondary folds of the mucosa. Gomori stain; x 200

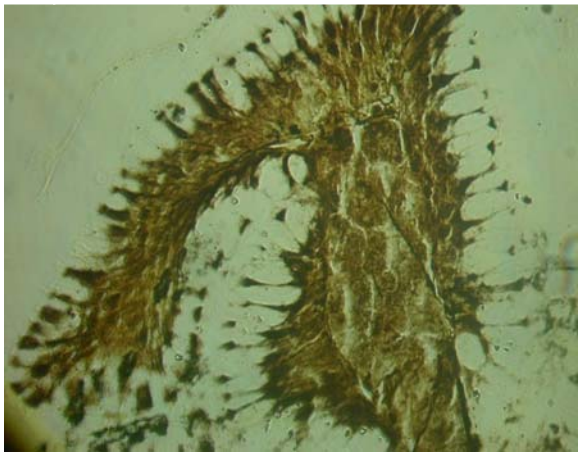

Fig. 6. The anterior zone of the isthmus. The secondary fold with the simple ciliated prismatic epithelium.Gomori stain; x 400

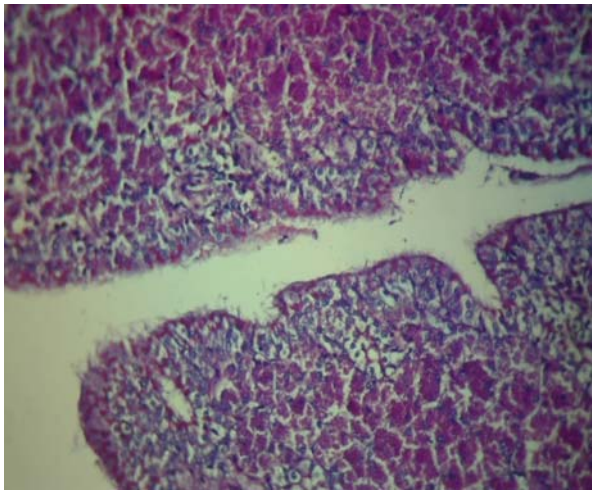

Fig. 7. The anterior zone of the isthmus. The prime fold and the presence of glands in the lamina propria.PAS stain; x 200

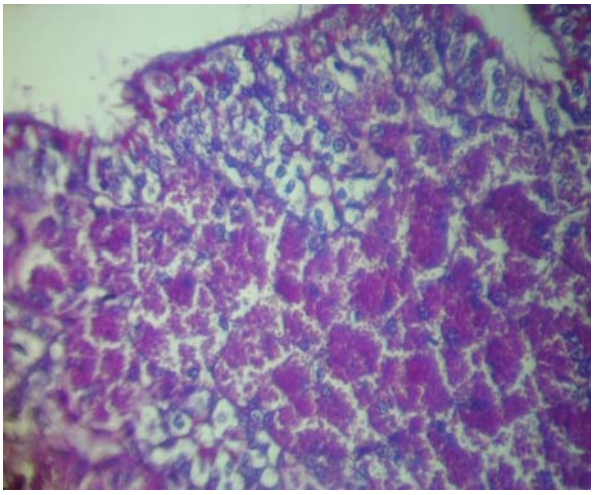

Fig. 8. The anterior zone of the isthmus. The prime fold and the presence of glands in the lamina propria.PAS stain; x 400

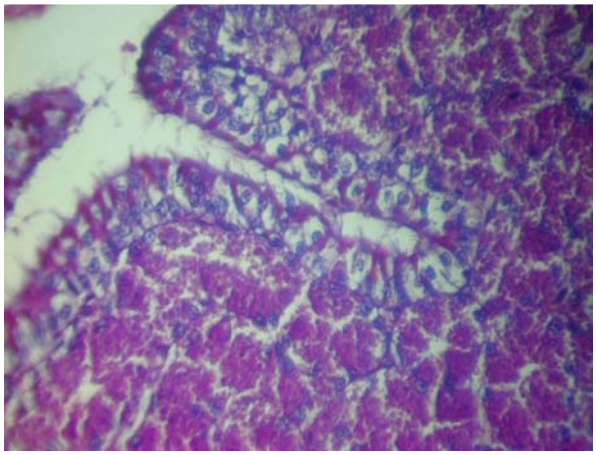

Fig. 9. The anterior zone of the isthmus. Glands in the lamina propria of the mucosa. PAS stain; x 400

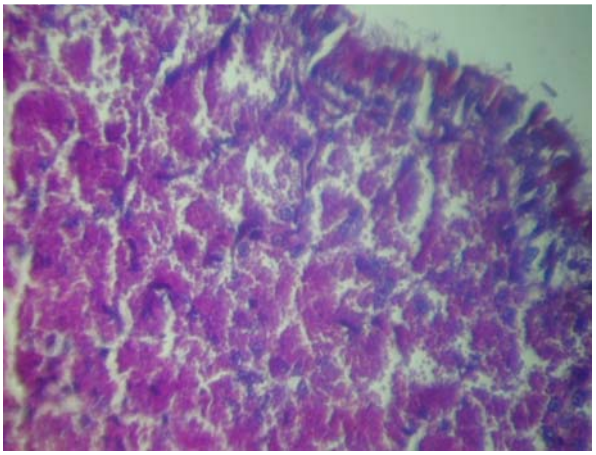

Fig. 10. The anterior zone of the isthmus. The luminal ciliated epithelium and glands in the lamina propria.PAS stain; x 400

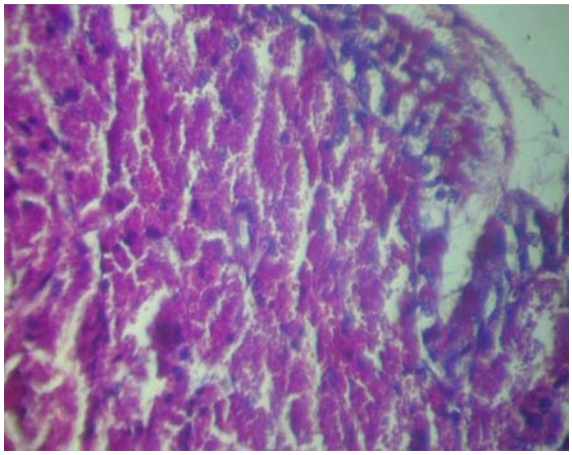

Fig. 11. The anterior zone of the isthmus. The separation of the proteic secretion shaped as filaments.PAS stain; x 400

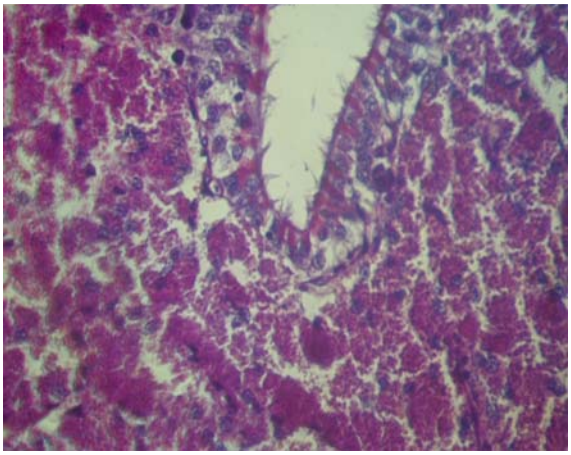

Fig. 12. The anterior zone of the isthmus. The luminal epithelium with ciliated cells and tubular glands with an abundent secretion. PAS stain; x 400

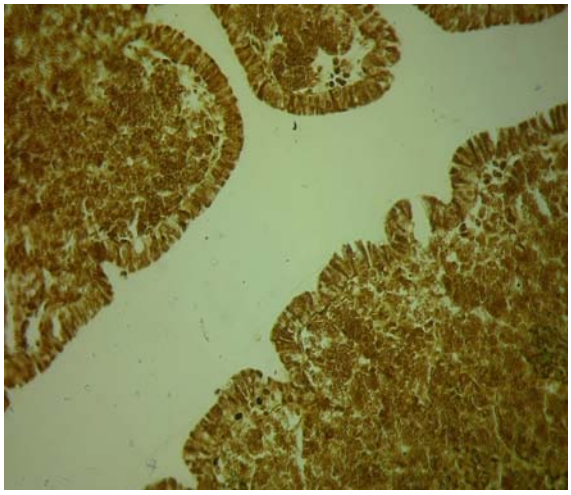

Fig. 13. The posterior zone of the isthmus. The prime fold of the mucosa. Gomori stain; x 200

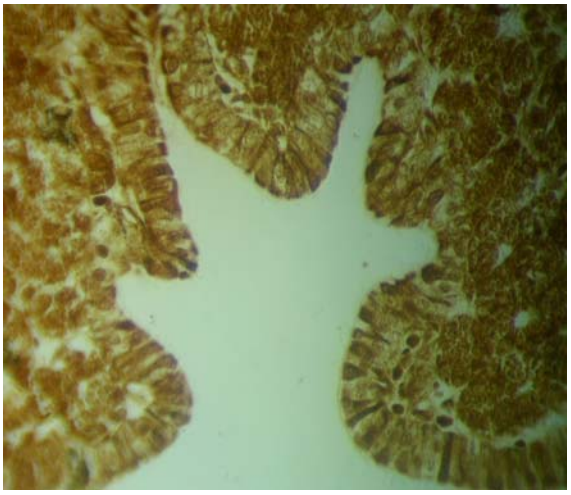

Fig. 14. The posterior zone of the isthmus. The prime fold of the mucosa. Gomori stain; x 400

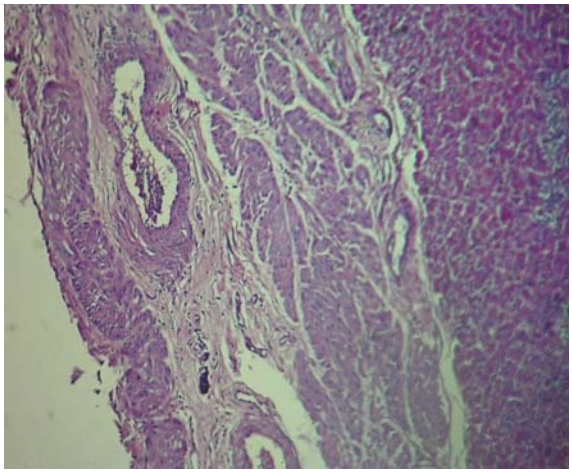

Fig. 15. The posterior zone of the isthmus. The intense vascularity of the musculosa and the presence of the tunica serosa. PAS stain;x 200

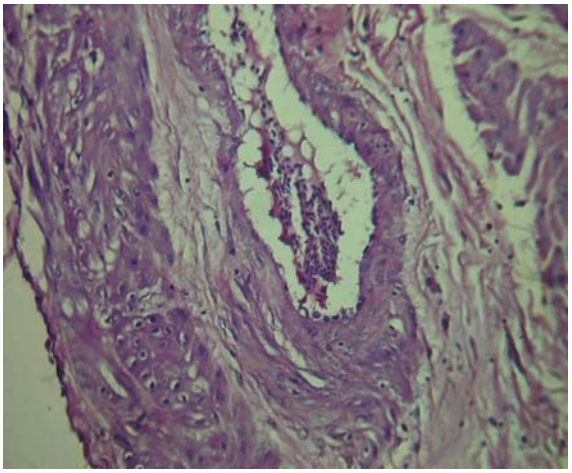

Fig. 16. The posterior zone of the isthmus. The intense vascularity of the musculosa and the presence of the tunica serosa. PAS stain;x 400

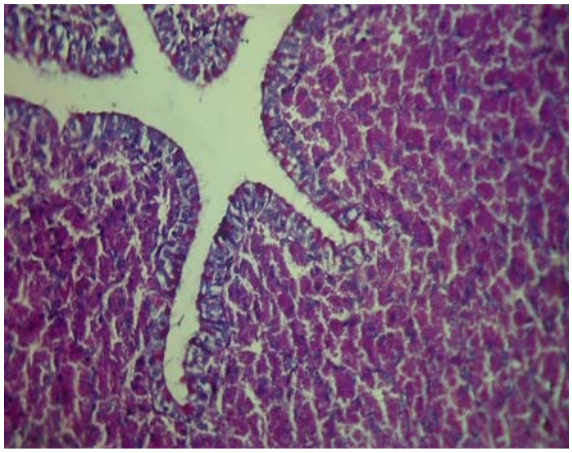

Fig. 17. The posterior zone of the isthmus. The luminal epithelium and glands in the lamina propria. PAS stain; x 200

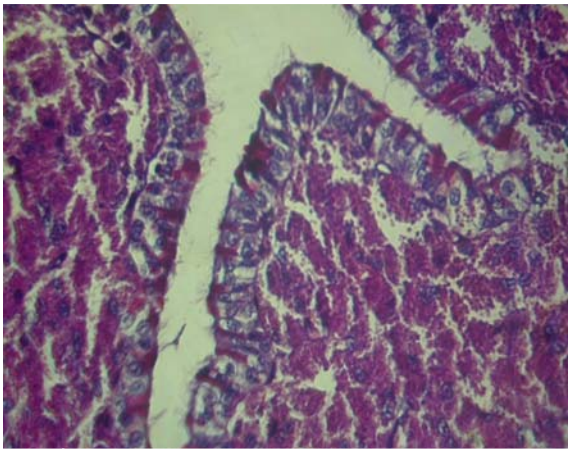

Fig. 18. The posterior zone of the isthmus. The luminal epithelium and glands in the lamina propria.PAS stain; x 400

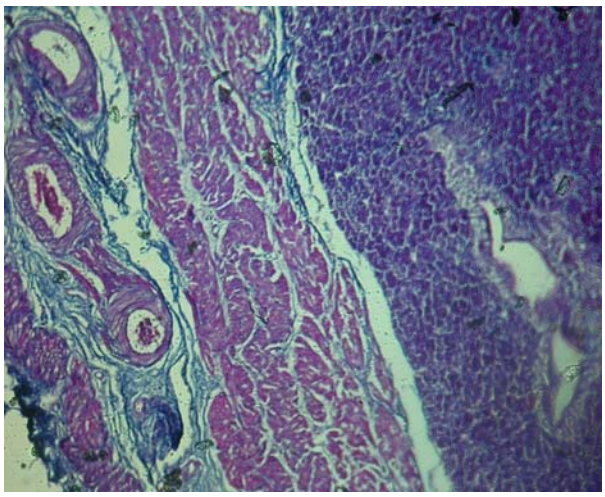

Fig. 19. The posterior zone of the isthmus. The presence of many arterioles between the inner-circular and outer-longitudinal layer of the musculosa. Novelli stain; x 200

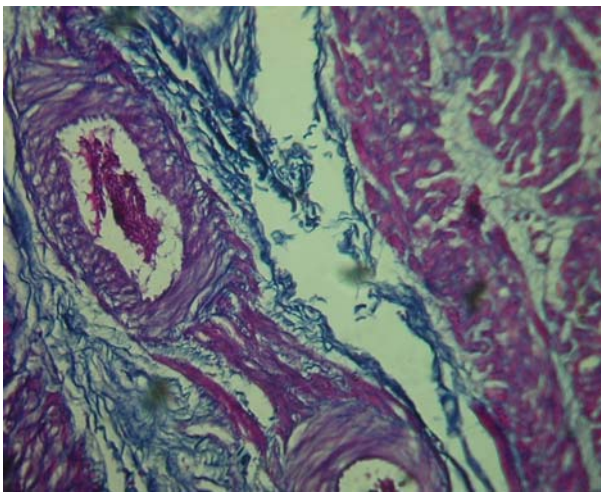

Fig. 20. The posterior zone of the isthmus. The presence of many arterioles between the inner-circular and outer-longitudinal layer of the musculosa. PAS stain; x 400

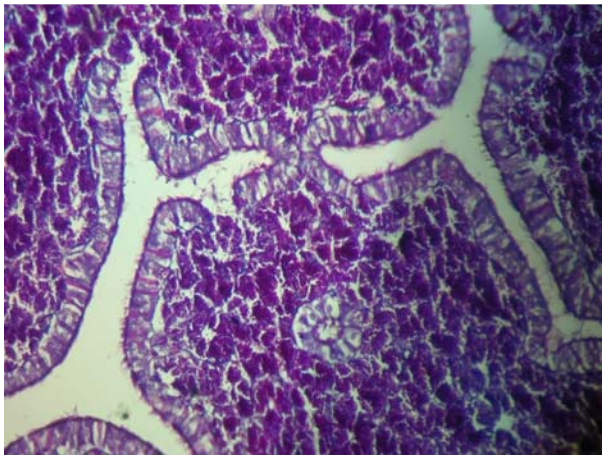

Fig. 21. The posterior zone of the isthmus. The luminal epithelium and glands in the lamina propria. Novelli stain; x 200

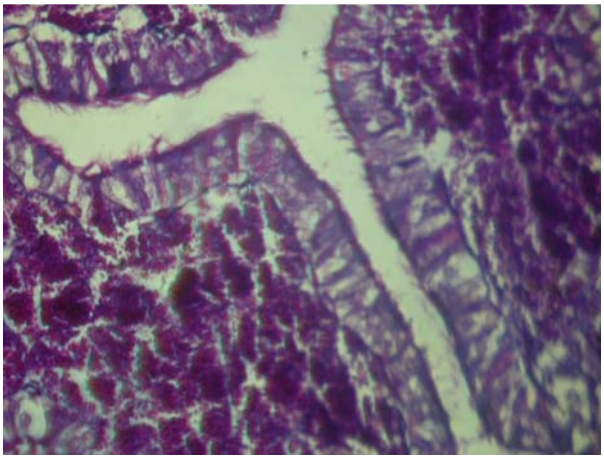

Fig. 22. The posterior zone of the isthmus. The luminal epithelium and glands in the lamina propria. Novelli stain; x 400

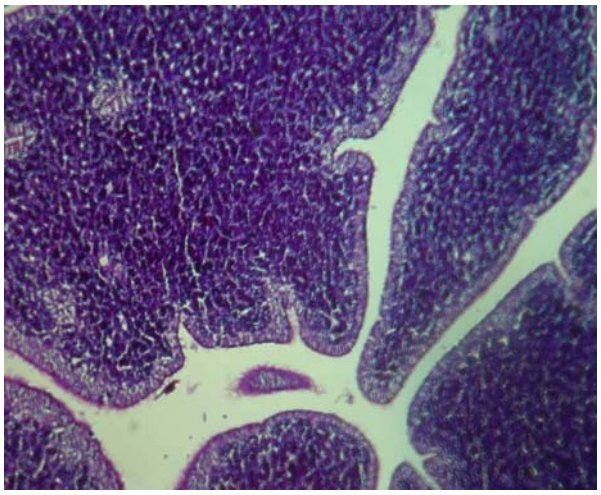

Fig. 23. The posterior zone of the isthmus. The prime folds of the mucosa. Novelli stain; x 80

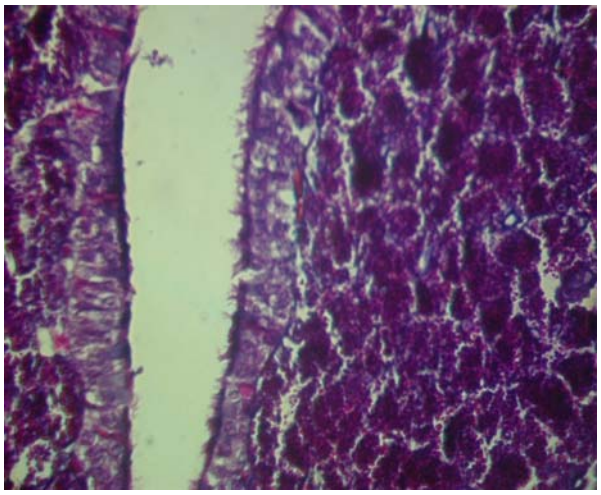

Fig. 24. The posterior zone of the isthmus. The prime folds of the mucosa. Novelli stain; x 400

CONCLUSIONS

- The isthmus of the Lohmann brown chickens has a length of 8–9 cm and a thickness of
  2–3 cm;
- The isthmus is structured from the tunica mucosa, the tunica submucosa, the tunica muscularis and the tunica serosa;
- The tunica mucosa appears folded, the folds measuring 1800–2500 µm, and being arranged parallel and longitudinal;
- In the surface epithelium (measuring 20–23 µm) there are ciliated and secretory cells, that elaborate proteoglycans;
- In the lamina propria of the mucosa folds there are numerous tubular glands with the size varying between 40–55 µm;
- The secretion of the tubular glands is observed in the shape of filaments or matrix;
- The tunica muscularis is structured from two layers of smooth muscle: the inner layer, measuring 150–200 µm, and the outer layer, measuring 200–225 µm.

REFERENCES

1. **Chousalkar K.** (2008) – Ultrastructural changes in the oviduct of the laying hen during the laying cycle, Cell Tissue Res 332: 349-358;
2. **Candlish, J. K.** (1972). The role of the shell membranes in the functional integrity of the egg. In ‘‘Egg Formation and Production’’. British Poultry Science**;**
3. **Cotea C.** (2003)– Histologie specială, Ed. Tehnopress, Iaşi;
4. **Marquardt R.** (1973) – Development, Cellular Growth, and function of the Avian Oviduct, Biology of reproduction 8, 283-298;
5. **Oppel S.** (2009) - Using eggshell membranes as a non-invasive tool to investigate the source of nutrients in avian eggs, J. Ornithol 150: 109-115;
6. **Ozen A.** (2009) – Light and electron microscopic studies on the oviduct epithelium of the Pekin duck (*Anas platyrhynchos*);
7. **Vacaru-Opriș** (2002) – Tratat de avicultură II, ed. Ceres, Iași;
8. **Whittow C.** (2000) – Sturkie’s Avian Physiology (Fifth edition) Elsevier.

THE MORPHOLOGY AND HISTOCHEMISTRY OF THE MAGNUM DURING THE EGG PASSAGE THROUGH THE OVIDUCT, IN HENS DURING THE LAYING CYCLE

C. TODIREANU, C. COTEA, Carmen SOLCAN
Faculty of Veterinary Medicine, Iași

ABSTRACT

The present study was conducted to determine the morphology and histochemistry of the magnum of twelve Lohmann brown chickens, between 40 and 47 weeks of age, during the laying period, raised in an intensive regime. The birds were slaughtered so that the egg would be present in each segment of the oviduct. The fragments, 36, from the three areas of the magnum (anterior, middle, posterior) were fixed in10% formalin, Otrh and Carnoy, included in parrafin and sectioned at the size of 5 µm.The colorations used were: HEA, PAS, Alcian blue, Gomori, Papanicolau and Novelli.The surface epithelium is structured of ciliated and secretory cells, that are cup - shaped, and alternate so that before the yolk passes through the magnum the secretory cells are thick with secretion granules and appear to have majority, subsequantly, after eliminating the secretory content, they are masked by the ciliated cells.
In the lamina propria of the mucosa there are tubular glands, with the opening on the surface of the mucosa. At the apical pole of the glandular epithelial cells there are numerous PAS-positive, dense granules, the size of 1,5-2 µm. The tunica muscularis appears more developed, specially the outer-longitudinal layer, organized in bands of circular-oriented muscular fibers that facilitate the movement of the albumen and the chalazae formation.

Key words: morphology, histochemistry, magnum, hen

Considering the fact that the egg-laying hybrids of chicken certainly have a greater egg production and of superior quality than the average hen; and the lack of research on such hybrids, we've undertaken the present study to elucidate the morphology and histochemistry of the magnum of the laying hybrids. So, we have chosen the magnum, as it is the main segment of the chicken's oviduct, in which the albumen is elaborated, a major component within the structure of egg; and a hybrid which is well-known for it's egg production-Lohmann brown.

MATERIAL AND METHOD

The study was conducted on 12 Lohmann brown chickens, hybrid which is specialized in egg production. The chickens were at the peak of the laying period, and were 40 to 47 weeks old.
The birds were slaughtered and their magnum has been prelevated, and fixed in 10% formalin (fig. 1, fig. 2). The magnum was divided into 3 areas: anterior, middle and posterior, and from each area we prelevated a sample, that was chiseled and refixed in 10% formalin, Orth or Carnoy (fig. 3, fig. 4). After the fixation, the samples were included in parrafin, sectioned at 5 µm and stained H.E.A., PAS, Gomori, Papanicolau, Alcian blue and Novelli.

RESULTS AND DISCUSSIONS

The magnum is the longest segment of the oviduct, measuring 38 to 42 cm (8). This segment continues the infundibulum without a clear delimitation except for the mucosa folds. Also, this segment is continued by the isthmus, from which it is separated by a transparent band (7).

The main function of the magnum is the elaboration of the albumen, process that takes about 3 hours, while the ovule crosses through this portion, on all it's length (fig. 21, fig. 24). The diameter of the magnum raises starting with the neck of the infundibulum, reaches a maximum on the middle third and then decreases towards the isthmus.

The magnum is structured from the tunica mucosa, the submucosa, the tunica muscularis and the tunica serosa (1).

The main histological structures of the magnum of the Lohmann brown hens that were studied are presented in Table 1, and their size is expressed in micrometers (µm).

Table 1

The size in µm of the main histological structures of the magnum of the Lohmann brown hens that were studied

The magnum area / The structure	Anterior magnum	Middle magnum	Posterior magnum
The prime fold	1000–1200	1200–1300	2000–2500
The surface epithelium	20–22	20–23	20–25
The cytoplasm granules	1–1,5	1,5–2	1,5–2
The cilia	4–5	4–5	4–5
The nucleus	6–6,5	6–6,5	6–6,5
The nucleolus	1,5–2	1,5–2	1,5–2
The tubular glands	50–60	50–60	55–65
The lumen of the gland	6,5	6,5	6,5
The height of the cells	15	15–16	15–16
The nucleus of the gland cells	5	5	5
The secretion granules	1,5–2	1,5–2	1,5–2
Tunica muscularis–the inner-circular layer	175–200	175–200	175–200
Tunica muscularis–the outer-longitudinal layer	200–250	200–250	200–250

The mucosa is very developed, folded, having 20-22 primary folds, measuring 1000-2500 µm, and numerous secondary and tertiary folds. The role of these folds is to enlarge the secretory surface of the glandular cells (fig. 5, fig. 6, fig. 12). In the surface epithelium there are ciliated cells, and cup-shaped secretory cells (5) (fig. 7, fig. 13, fig. 23). The ciliated cells are narrow, 20-25 µm high, and have cilia, with the size of 4-5 µm, at the apical pole (fig. 10, fig. 17). The cup-shaped secretory cells have a discoid nucleus at the base pole and numerous secretion granules at the apical pole (fig. 8, fig. 11). The two types of cells alternate. The magnum of the chickens which were slaughtered when the ovule was either in the posterior third of the magnum or in the other posterior segments of the oviduct has the secretory cells masked by the ciliated cells, while the magnum from the chicken with the ovule in the infundibulum or in the anterior part of the magnum, has enlarged secretory cells by the secretion and apparently predominate in the epithelium (fig. 9, fig. 14). In the lamina propria there are numerous glands that open on the surface of the mucosa folds, although they appear more developed and thicker at the base (fig. 16, fig. 22).The glands are tubular, the size of 50-65 µm, branched and

have a sinuous trajectory, transforming the lamina propria in a glandular layer. The secretory cells of the tubular glands are prismatic, 15-16 µm high, have a nucleated, vesicular nucleus situated at the basal pole; and a narrow apical surface (4). These cells elaborate the ovalbumine, which is the main component of the albumen (3) (fig. 19, fig. 20). The tunica submucosa is thin and is structured from a delicate conjunctive tissue (2).
The tunica muscularis is well developed and structured in two layers of smooth muscle, inner-circular (175-200 µm), and outer-longitudinal (200-250 µm), which is more developed and organized in bands of parallel muscular fibers, with spiral direction, which implies the egg advancing in the magnum in a spiraled manner, rendering the secretion from the surface of the epithelium for the albumen and the chalazae formation (6), (fig. 15, fig. 18).

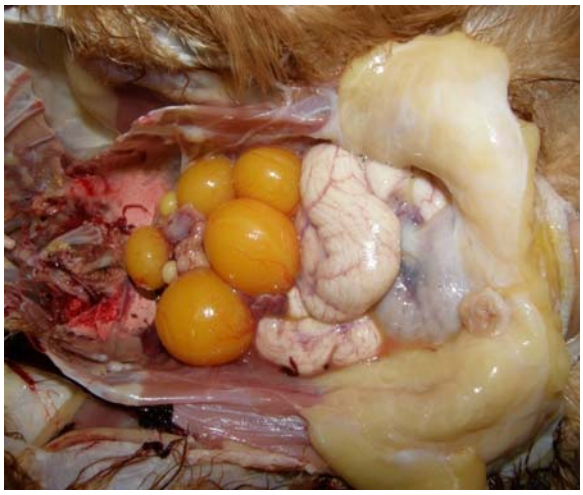

Fig. 1. The female reproductive system of the Lohmann Brown layer

Fig. 2. The ovary and oviduct of a 44 weeks old layer hen

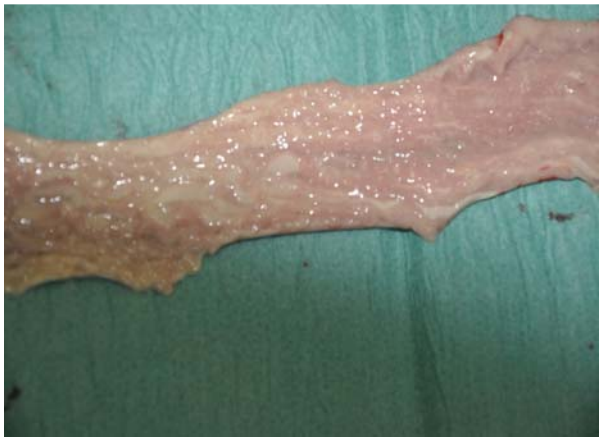

Fig. 3. The mucosa of the middle third of the magnum.

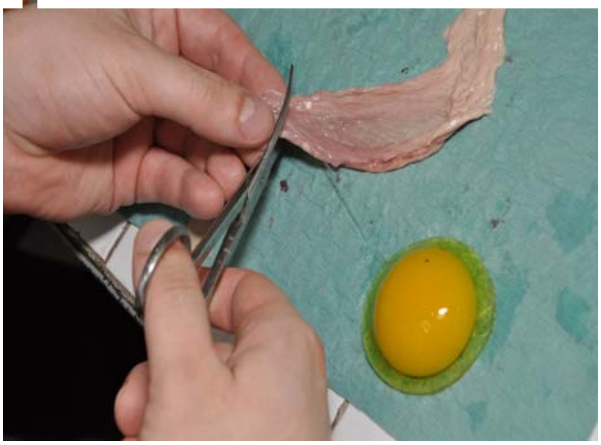

Fig. 4. Tissue sampling from the posterior third of the magnum.

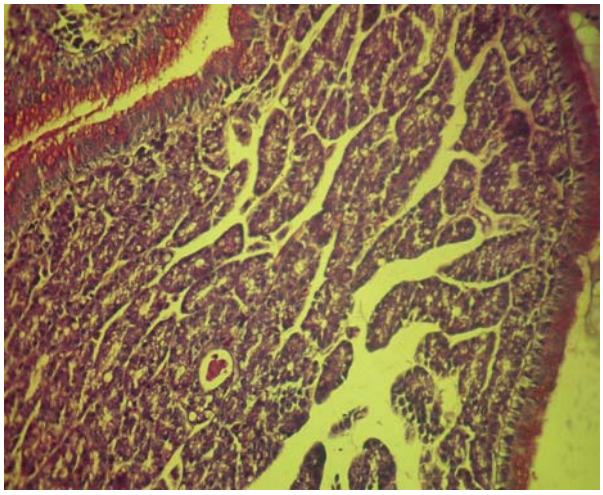

Fig. 5. The anterior third of the magnum. The mucosa with folds. PAS stain; x 200

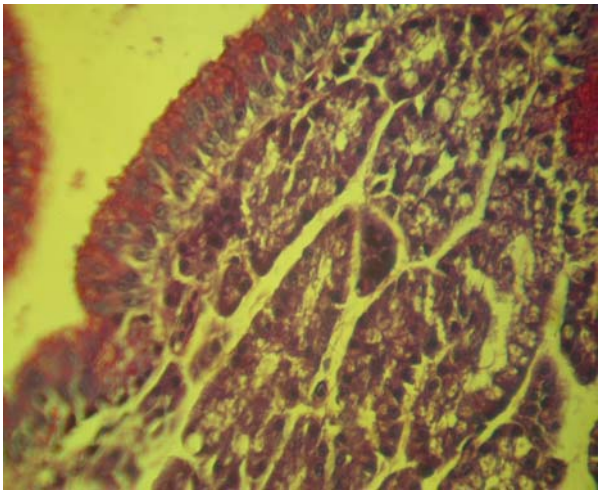

Fig. 6. The anterior third of the magnum.

The mucosa with folds. PAS stain; x 400

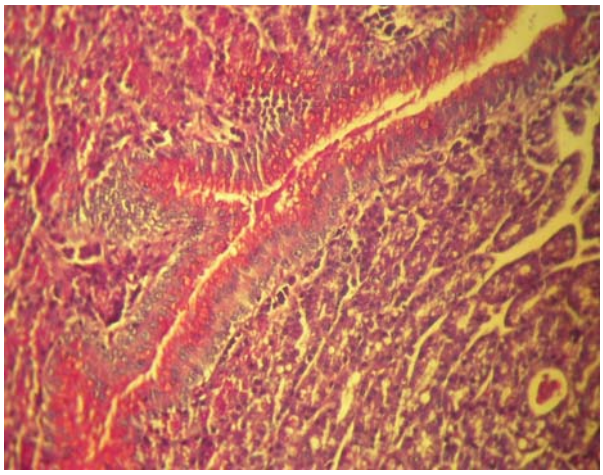

Fig. 7. The anterior third of the magnum. The luminal epithelium with secretion cells loaded with granules. PAS stain; x 200

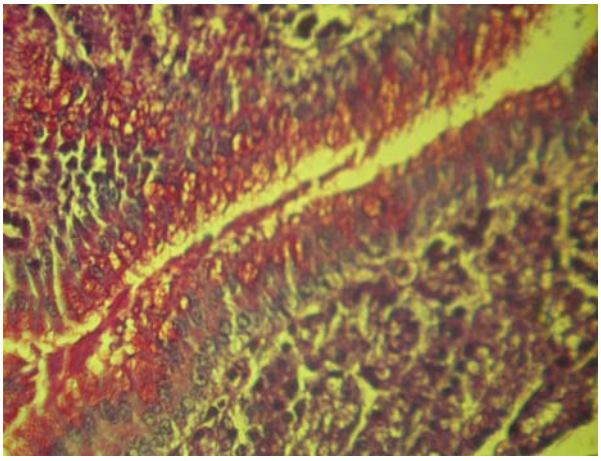

Fig. 8. The anterior third of the magnum. The luminal epithelium with secretion cells loaded with granules. PAS stain; x 400

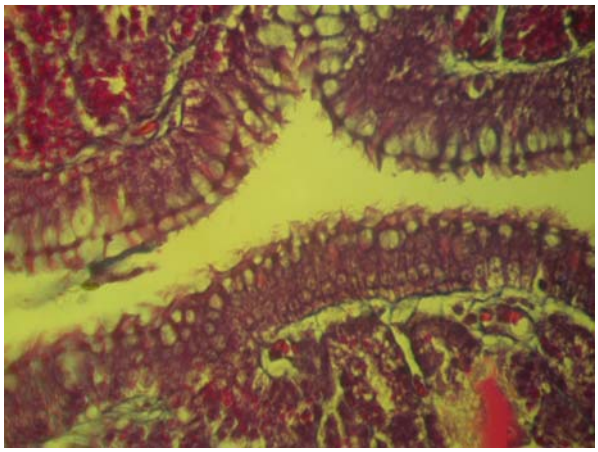

Fig. 9. The anterior third of the magnum. The epithelium with many cilliated cells. Novelli stain; x 400

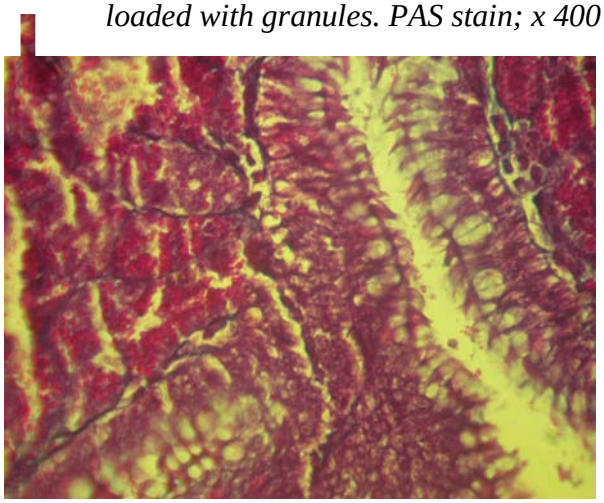

Fig. 10. The anterior third of the magnum. The presence of many cilliated cells in the luminal epithelium. Novelli stain; x 400

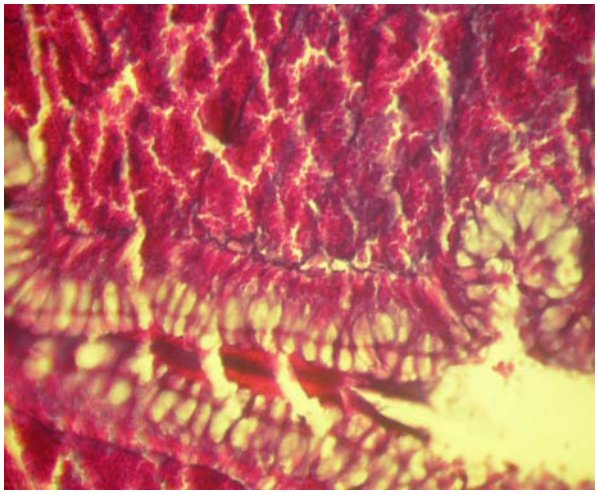

Fig. 11. The anterior third of the magnum. Albumen secretion in the lumen. Novelli stain; x 400

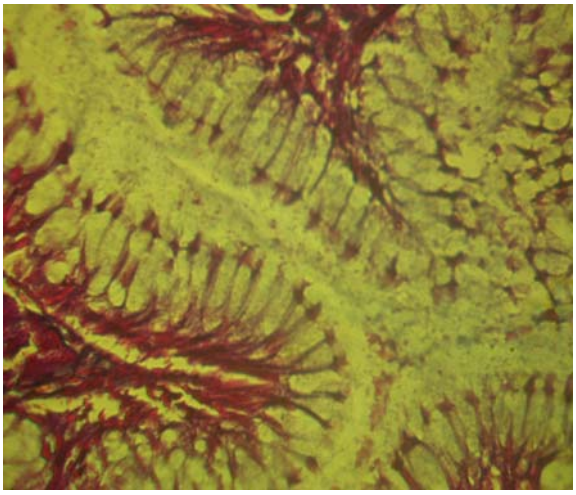

Fig. 12. The anterior third of the magnum. The mucosa folds. Novelli stain; x 400

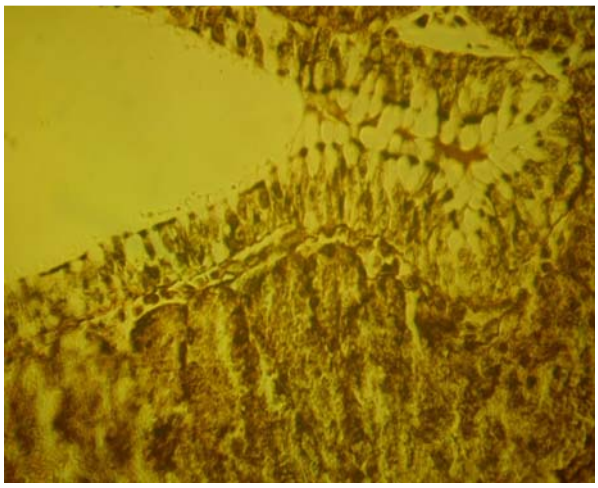

Fig. 13. The middle third of the magnum. The presence of many ciliated cells in the luminal epithelium. Gomori stain; x 400

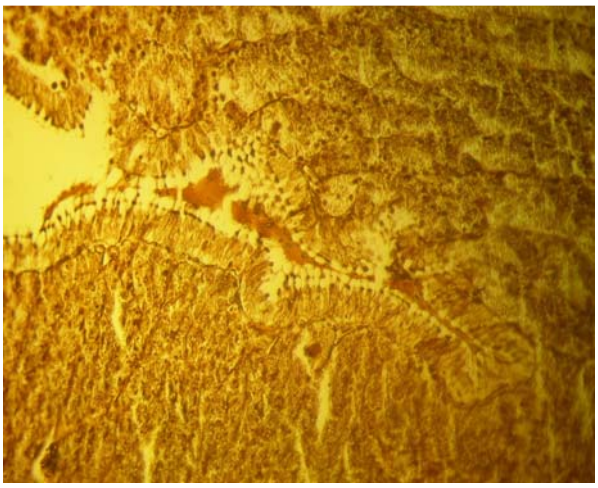

Fig. 14. The middle third of the magnum. The presence of many ciliated cells in the luminal epithelium. Gomori stain; x 200

Fig. 15. The middle third of the magnum. The musculosa with the presence of many arterioles and venules between the inner-circular and outer-longitudinal layer. Novelli stain; x 200

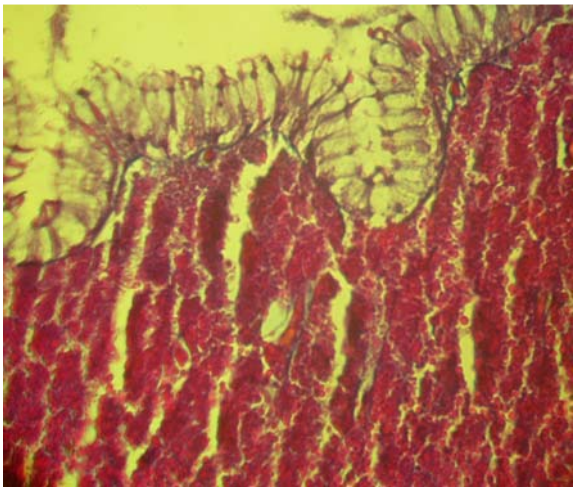

Fig. 16. The middle third of the magnum. Cells from the lamina propria of the mucosa. Novelli stain; x 200

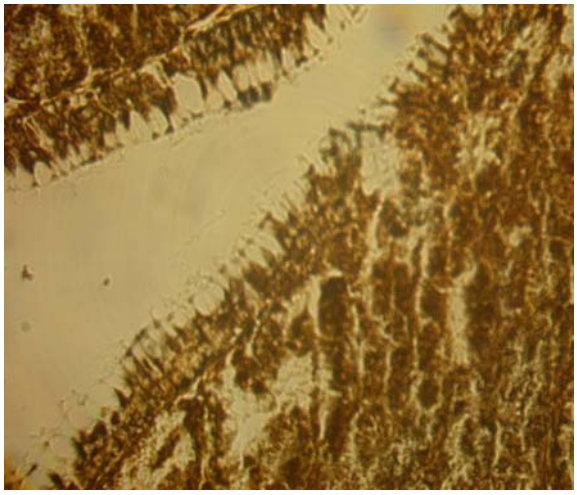

Fig. 17. The posterior third of the magnum. The mucosa with the epithelium which has many ciliated cells. Gomori stain; x 200

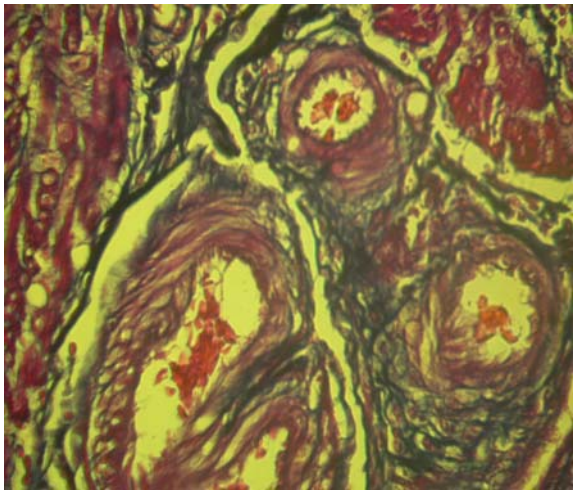

Fig. 18. The posterior third of the magnum. The intense vascularity of the musculosa and the presence of the tunica serosa. Novelli stain; x 400

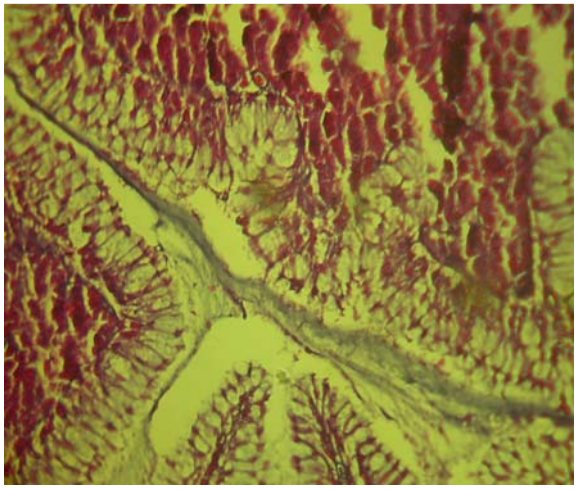

Fig. 19. The posterior third of the magnum. The albumen elaboration in the lumen. Novelli stain; x 200

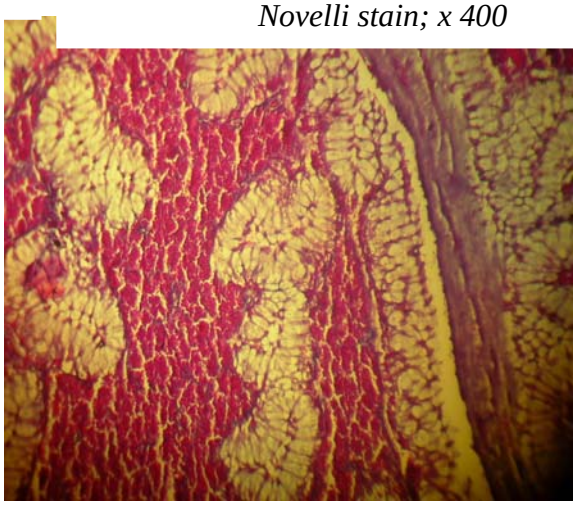

Fig. 20. The posterior third of the magnum. Thick bands of albumen in the lumen. Novelli stain; x 400

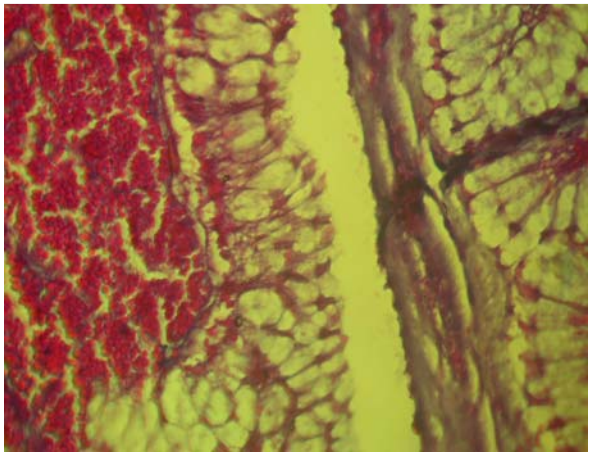

Fig. 21 . The posterior third of the magnum. Abundant secretion of albumen in the lumen. Novelli stain; x 400

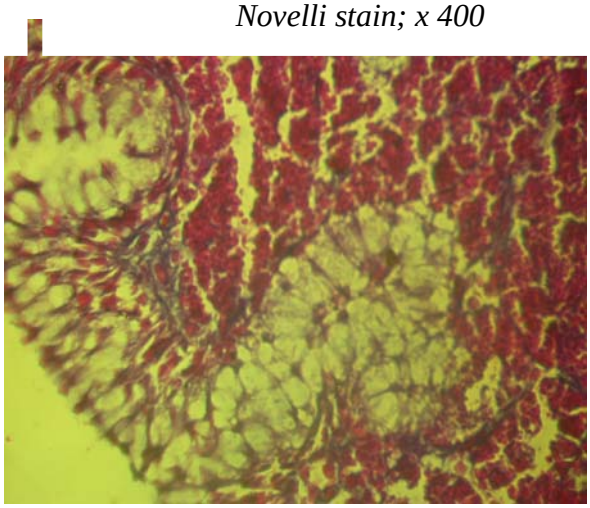

Fig. 22 . The posterior third of the magnum. Glands in the lamina propria with abundant secretion. Novelli stain; x 400

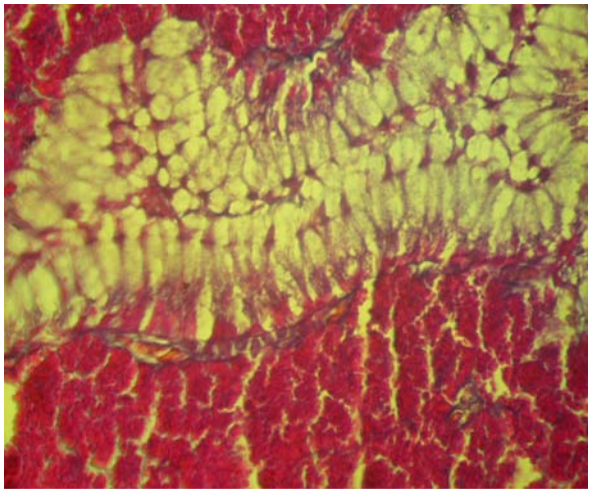

Fig. 23 . The posterior third of the magnum. The presence of capillaries in the vecinity of the basal lamina of the epithelium.
Novelli stain; x 400

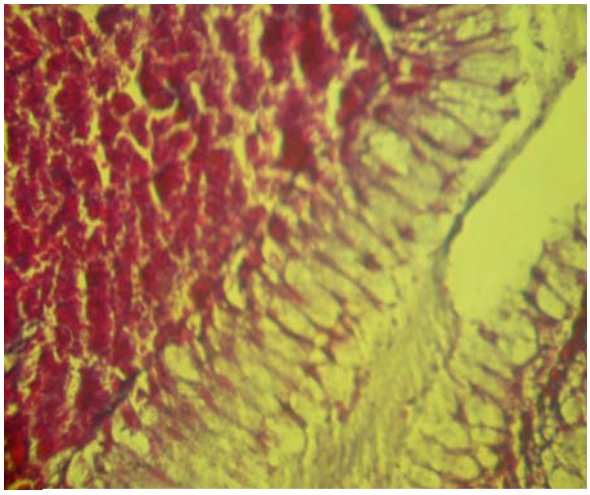

Fig. 24. The posterior third of the magnum.. The albumen elabration in the lumen. Novelli stain; x 400

CONCLUSIONS

- The magnum is the longest segment of the oviduct, measuring between 38 and 42 cm;
- The magnum has a histological structure that consists of the tunica mucosa, the submucosa, the tunica muscularis and the tunica serosa;
- The tunica mucosa is very well developed, folded, having 20–22 primary folds (measuring between 1000–1200 µm and 2000–2500 µm), numerous secondary and tertiary folds with the role of enlarging the secretory surface;
- In the surface epithelium (measuring 20-25 µm) there are ciliated and cup-shaped secretory cells, that alternate;
- The lamina propria consists of many tubular glands (50-65 µm) that open on the surface of the mucosa folds and that have secretory granules with the diameter of 1,5-2 µm;
- The tunica muscularis is structured from two layers of smooth muscle: the inner-circular layer, measuring 175-200 µm, and the outer-longitudinal layer, which is more developed, measuring 200-250 µm.

REFERENCES

1. **Chousalkar K.** (2008) – Ultrastructural changes in the oviduct of the laying hen during the laying cycle, Cell Tissue Res 332: 349-358;
2. **Cotea C.** (2003)– Histologie specială, Ed. Tehnopress, Iaşi;
3. **Hoober Karen** (1996) – A sulfhydryl oxidase from chicken Egg White, The journal of biological chemistry, vol 271, pp. 30510-30516;
4. **Marquardt R.** (1973) – Development, Cellular Growth, and function of the Avian Oviduct, Biology of reproduction 8, 283-298;
5. **Ozen A.** (2009) – Light and electron microscopic studies on the oviduct epithelium of the Pekin duck (*Anas platyrhynchos*);
6. **Rahman M.** (2007) – Mechanism of chalaza formation in quail eggs, Cell Tissue Res 330: 535-543;
7. **Vacaru-Opriş** (2002) – Tratat de avicultură II, ed. Ceres, Iaşi;
8. **Whittow C.** (2000) – Sturkie's Avian Physiology (Fifth edition) Elsevier.

HISTOLOGICAL RESEARCHES IN MALE PSEUDOHERMAPHRODITISM IN DOMESTIC SWINES (*SUS SCROFA DOMESTICA*)

CIORNEI Cristina, COTEA C.V., SOLCAN Carmen
Faculty of Veterinary Medicine Iasi

The study was conducted on a young gilt of Landrace breed, age 7 months and weighing 70 kg from an intensive livestock pig farm, from Iasi County

On the outside, this sow presented female characteristics, such as vulvae, the vulvae vestibule and a large clitoris. In addition we have noticed items of male phenotype, such as two externally testicle bags very visible.

To establish the exact type of intersexuality, the young sows was examined anatomically and ultrasound, confirming the diagnosis by histological examination. After these examinations, the case was classified as being male pseudo-hermaphrodite (PHM). The essential character of male pseudo-hermaphrodite is the regression of the peno-scrotal bodies from the uro-genital membrane and the development of uro-genital sinus towards female sex.

The PHM diagnosis was confirmed by histological examination. Fragments of gonads and genital tract were harvested, fixed in 10% formalin, Carnoy and Orth, included in paraffin, series sections were made at 5µm and stained HEA, PAS, Novelli, Alcian Blue, Papanicolau and Steedman Mowry .

Gonads, weighting of 108g the left gonad and 110g the right gonads, proved to be testesis. They have both compartments. The exocrine compartment is represented by seminiferous tubules very well distinguishable, in various forms such as "U", S "," V " forms. The endocrine compartment is present through Leydig cells in the connective space between the seminiferous tubules.

Epididymis was observed macroscopically, along the fixed edge of the testicle, and also microscopically. The duct of the epididymis was composed of an pseudo-stratifiedt epithelium with numerous stereocilia.

At one pole of the testis we have noticed a well-developed pampiniforme venous plexus, by the presence of many arteries, arterioles, veins and venules.

Regarding the genital tract it was observed only characteristics of female genital tract (two oviducts, two uterine horns, uterus, vagina, vaginal vestibule and vulva). At the abdominal end of the oviducts, the sow had two testesis.

From some histological stains, we have noticed few uterine glands and a secretion slightly PAS positive; the uterine horns have a length of 58 cm for the left, and 54 cm for the right.

Keywords: male pseudohermaphrotidism, swine, testesis.

The male pseudohermaphroditism (PHM) characterizes individuals whose gonads are testes, and internal and external genitalia shows an ambiguous differentiation, being more or less female-oriented gender.

The most important characteristic of PHM is the regression of the penoscrotal organs from the uro-genital membrane and urogenital sinus development predisposition for female gender.

MATERIAL AND METHODS

The study was conducted on a young gilt of Landrace breed, age 7 months and weighing 70 kg from an intensive livestock pig farm, from Iasi County

On the outside, this sow presented female characteristics, such as vulvae, the vulvae vestibule and a large clitoris. In addition we have noticed items of male phenotype, such as two externally testicle bags very visible.

To establish the exact type of intersexuality, the young sows was examined anatomically and ultrasound, confirming the diagnosis by histological examination.

Fragments of gonads and genital tract were harvested, fixed in 10% formalin, Carnoy and Orth, included in paraffin, series sections were made at 5µm and stained HEA, PAS, Novelli, Alcian Blue, Papanicolau and Steedman Mowry

RESULTS AND DISCUSSIONS

From anatomically point of view, on palpation of the two testicle bags it was noticed two testicles, located in normal position, in subrectal area. Above the two testicular bags, also in normal female position, it was present the vulvae orifice with it's labial components relatively thick, covered by a crinkled skin. The free end of the clitoris is very hypertrophied (fig.1).

The ultrasound exploration of the genital tract was performed percutaneous supine but also in patrupodal support The urinary bladder was used as a landmark and the exam started in a caudo-cranial way.

Ultrasound examination of the testicular bags showed that the gonads had a testicular aspect, and near by was present a structure like an epididym and also we have noticed the presence of the pampiniform plexus. The same exam revealed the existence of the female genital tract through highlighting of some structures resembling of uterine horns.

After these examinations, the case was classified as being male pseudohermafroditism type (PHM). The most important characteristic of PHM is the regression of the penoscrotal organs from the uro-genital membrane with urogenital sinus development predisposition for female gender.

At slaughtered, the gonads, weighing 108g the left gonad and 110g the right gonad, proved to be testicles. On the outside, it was notice a thick albuginee, pale pink, which maintains under pressure the testicular parenchyma, in the visible testicular bags (fig. 5).

In terms of histology, the testes showed both exocrine compartment, represented by seminiferous tubules, looking polymorphic, presenting of various forms "U", "S" ,"V", but also the endocrine compartment represented by Leydig cells in the connective tissue between the seminiferous tubules.

Seminiferous tubules are characterized by an intense vacuolization of the epithelium, both Sertoli cell cytoplasm and in spermatogonias. They are arranged in a single row (fig. 6, fig. 7, fig. 10, fig. 11, fig. 12). The Leydig cells were located in the connective tissue between seminiferous tubules, with vesicular nuclei (fig. 8, fig. 9). In some areas, the testicle was erratic, presenting some portions were the seminiferous tubules are present in thickness of the albuginea.

Epididymis was observed both macroscopically, along the edge of the testicle, covering one third of its circumference (fig. 2, fig. 3), and also histologically. In cross-section, the epididimar channel is structured of a epithelium ciliated with many stereocilia at the apical

pole of the cells, length of 5-7 µm and in its lumen were not observed spermatozoa due to the vacuolization of the Sertoli cell and the first seminal cell line (spermatogonias) (fig. 16, fig. 17).

The deferent duct shows small mucosal folds, printing it`s lumen in cross-section, a slightly festooned appearance. It was also noticed a slight PAS positive secretion and the absence of spermatozoa (fig. 14). In some sections the defent duct and the uterus are merger through the same mezou (fig. 18).

At one pole of the testis were observed the pampiniforme plexus highly developed, wich contains many arteries, arterioles, veins and venues (fig.13).

Regarding the genital tract, under histological aspect, were observed parts of female genital tract (two oviducts, two uterine horns, uterus, vagina, vaginal vestibule and vulva) (fig. 2). The abdominal part of the oviduct ended with the testicle instead of ovaries (fig. 3, fig. 4), histologically were structured in a mucosa with many folds.

Left uterine horn had a length of 58 cm and the right on length of 54 cm - both not showing the the sinuous form (intestiniform) characteristic of pigs (fig. 2, fig. 4). They were observed on ultrasound examination, differentiation from intestinal loops was made with no peristaltic waves. In terms of histology, the mucosa is thin, with an one layer epithelium, glands were placed in the string, seen in small numbers in lamina propria (fig. 19, fig. 21). These glands are structured in a simple prismatic epithelium with a low secretion in the lumen (fig. 20).

Macroscopically, near the vagina were observed two hard structures that in histological examination were clarified as male genital glands: the prostate gland and bulbo-urethral gland. Prostate gland is divided by a delicate connective tissue into lobules. The glandular prostatic acinii have a large an irregular lumen, due to the presence of small "spurs" (fig. 22). Acinii which forms the parenchyma of the bulbo-urethral gland were surprised in histological sections in various stages of secretion, with various shapes and sizes, with a weak PAS positive secretion (fig. 23)

Fig.1 – Male pseudohermaphroditism(PHM) - anatomical and clinical appearance – the presence of the vulvae orifice with a large clitors along with two testicular bags well developed

Fig.2 – Male pseudohermaphroditism(PHM) – Macroscopic aspect of the genital tract – the presence of testicles and female genital tract.

Fig.3 - Male pseudohermaphroditism (PHM) – Macroscopic aspect of the genital tract – testicles instead of the ovaries

Fig.4 - Male pseudohermaphroditism (PHM) – Macroscopic aspect of the genital tract – testicles instead of the ovaries

Fig.5 - Male pseudohermaphroditism (PHM) – Macroscopic aspect of the genital tract – the presence of the pampiniform plex on the edge of the testicle

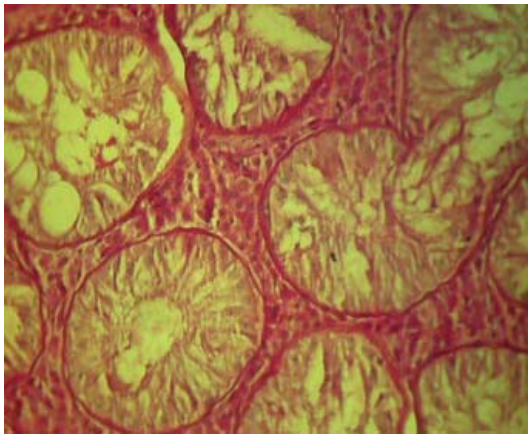

Fig.6 - Male pseudohermaphroditism (PHM) – intense vacuolisation of the seminiferous epithelium. Col. PAS; x200

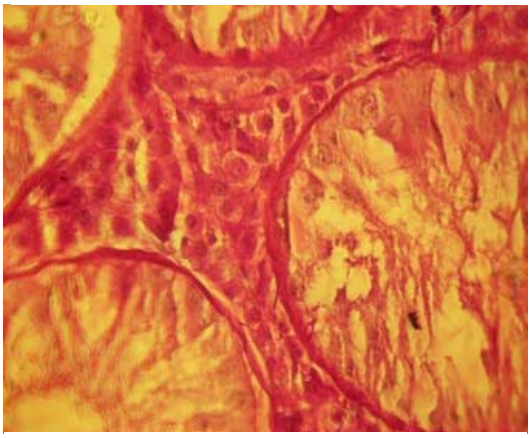

Fig.7 - Male pseudohermaphroditism (PHM) – intense vacuolisation of the seminiferous epithelium and the presence of the interstitial Leydig gland. Col. PAS; x400

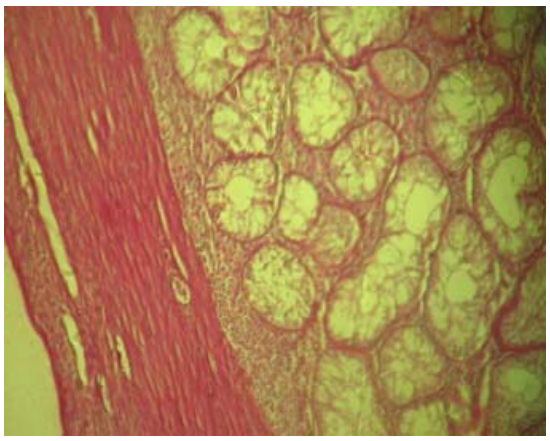

Fig.8 - Male pseudohermaphroditism (PHM) – thick tunica albuginee, interstitial Leydig gland and the intense vacuolisation of seminiferous epithelium. Col. HEA; x 200

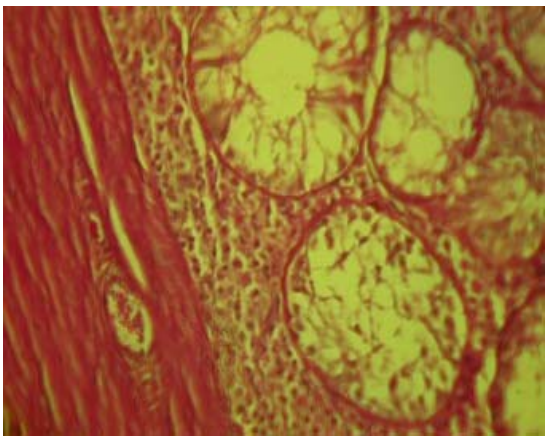

Fig.9 - Male pseudohermaphroditism (PHM) – the tunica albuginee, interstitial Leydig gland and the intense vacuolisation of seminiferous epithelium. Col. HEA;, x 200

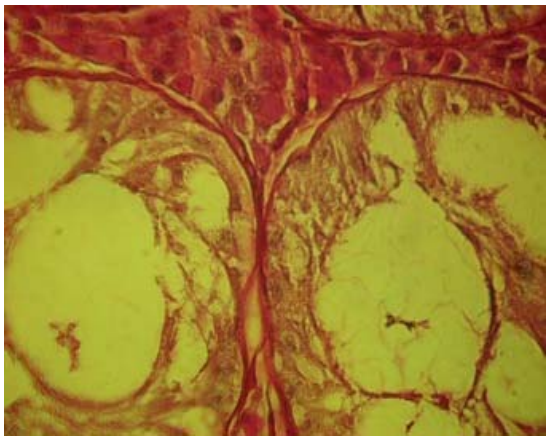

Fig.10- Male pseudohermaphroditism (PHM) – interstitial Leydig gland and seminiferous tubules with vacuolisation of the epithelium. Col. HEA; x 400

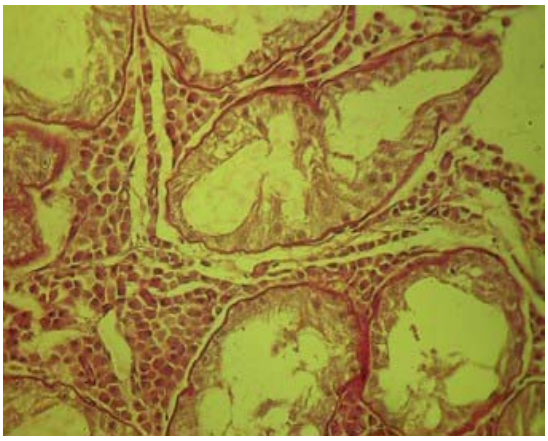

Fig.11- Male pseudohermaphroditism (PHM) – interstitial Leydig gland and seminiferous tubules with vacuolar epithelium. Col. HEA; x 200

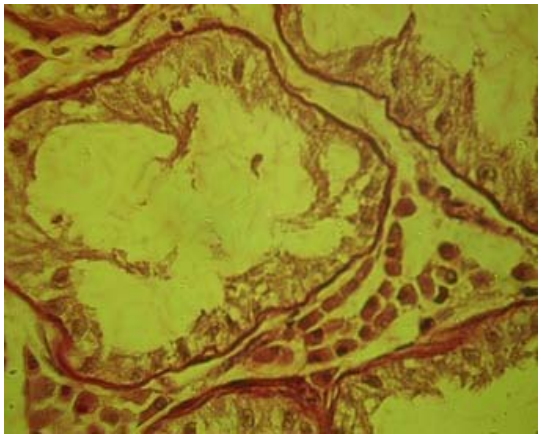

Fig.12-- Male pseudohermaphroditism (PHM)– interstitial Leydig gland and seminiferous tubules with vacuolar epithelium. Col. HEA; x 400

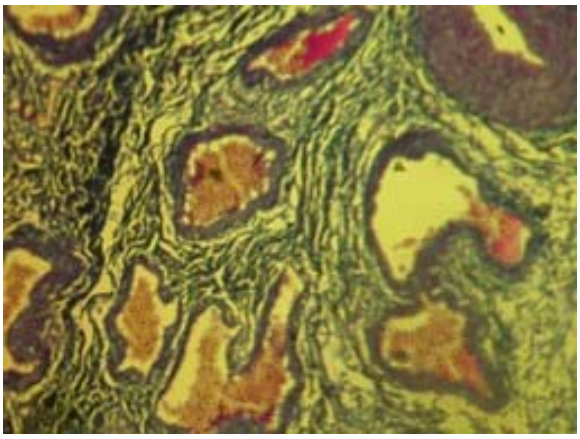

Fig.13 - Male pseudohermaphroditism (PHM)– Pampiniform plexus. Col. HEA; x400

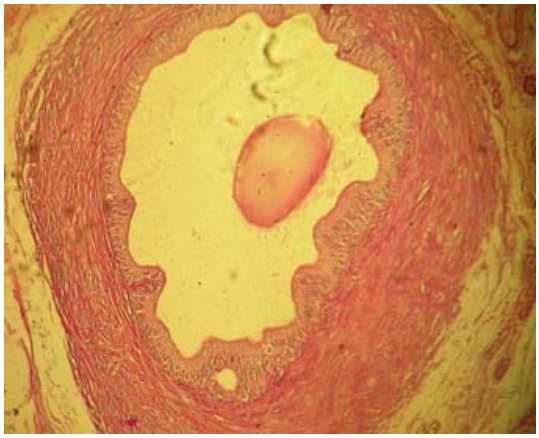

Fig.14 - Male pseudohermaphroditism (PHM) – the deferent duct with secretion in lumen , the absence of spermatozoa. Col PAS; x80

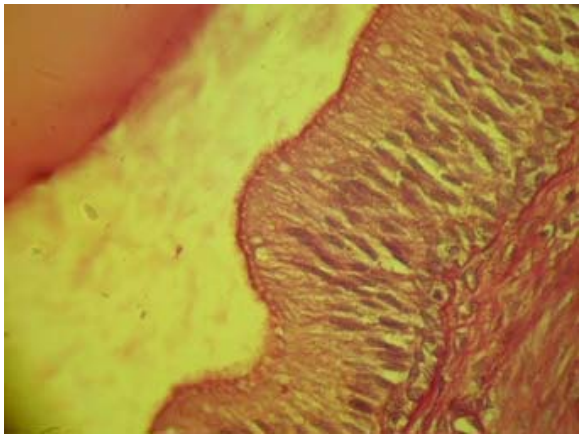

Fig.15- Male pseudohermaphroditism (PHM) – the deferent duct with secretion in lumen , the absence of spermatozoa. Col PAS; x400

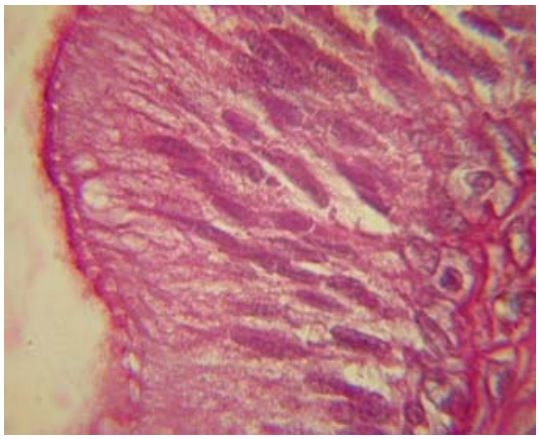

Fig.16 – Male pseudohermaphroditism (PHM) – the epydidymis, epithelium ciliated with stereocilia, length of 5-7 µm. Col PAS; x400

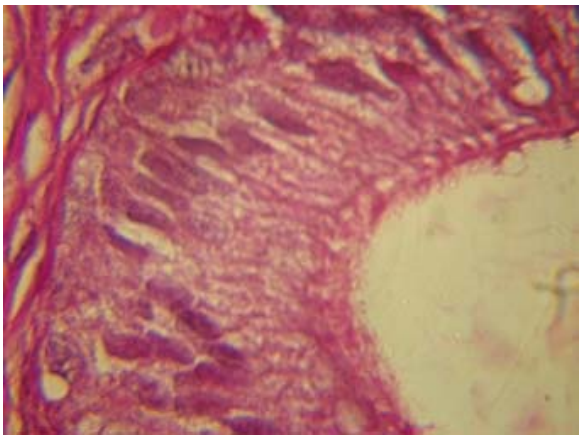

Fig.17 – Male pseudohermaphroditism (PHM) – the epydidymis, epithelium ciliated with stereocilia, length of 5-7 µm. Col PAS; x400

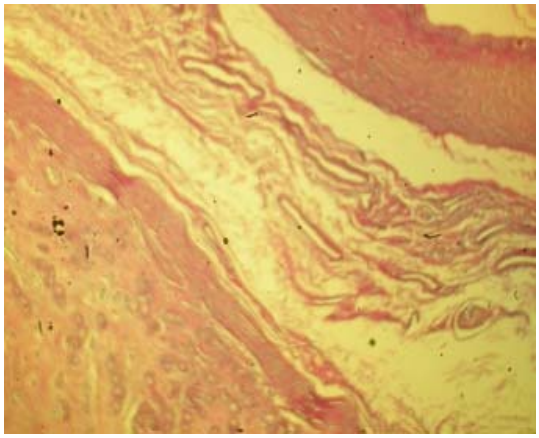

Fig. 18- Male pseudohermaphroditism (PHM) – the deferent duct and uterus, merged through the same mezou. Col. PAS; x100

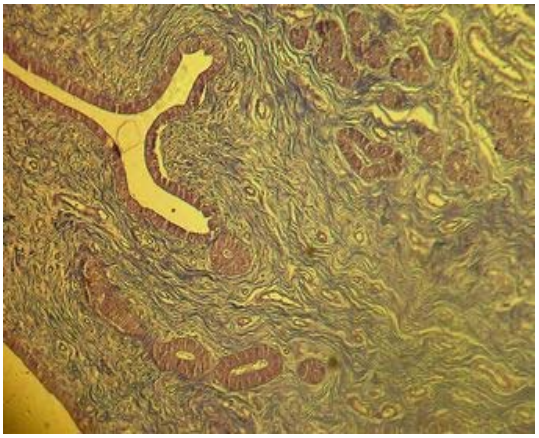

Fig. 19- Male pseudohermaphroditism (PHM) – uterin horn with glands. Col. PAS; x200

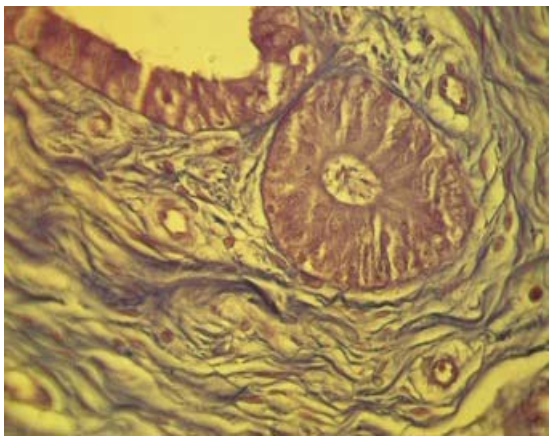

Fig. 20- Male pseudohermaphroditism (PHM) – uterin horn lumen and monomial alands. Col. PAS: x400

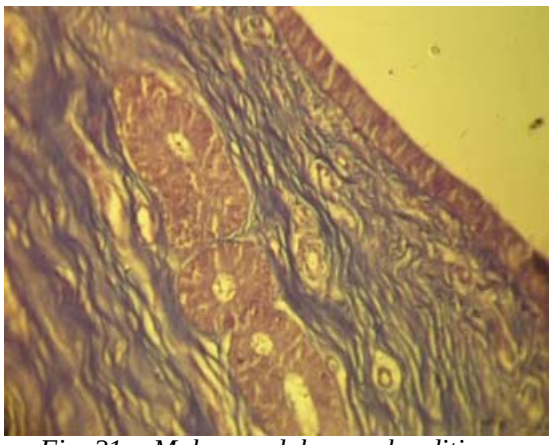

Fig. 21 - Male pseudohermaphroditism (PHM) – uterin horn lumen and monomial glands. Col. PAS; x400

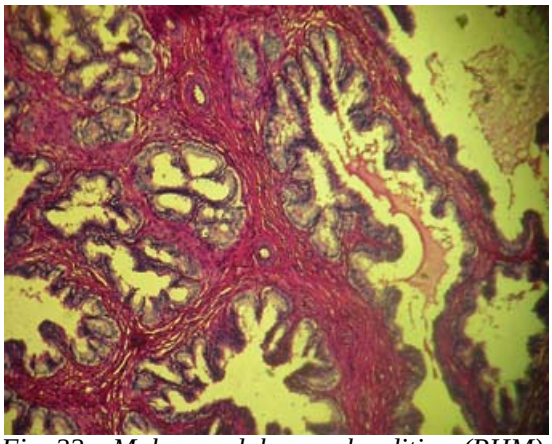

Fig. 22 – Male pseudohermaphroditism (PHM) – the epydidymis, epithelium ciliated with stereocilia, length of 5-7 µm. Col PAS; x400

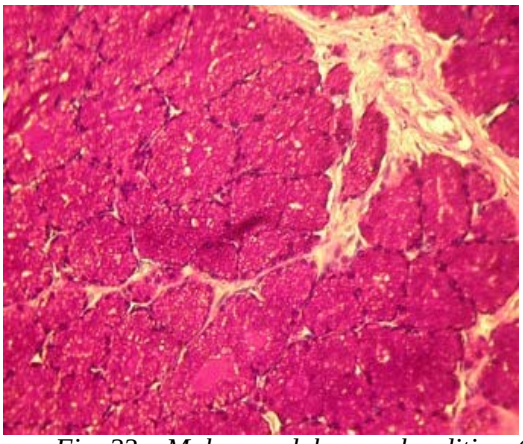

Fig. 23 – Male pseudohermaphroditism (PHM) – bulbo-urethral gland with secretori acini in different stages of secretion. Col. PAS; x200

Conclusions

1. This case, studied under anatomical, ultrasound and histological aspects, has been diagnosed as male pseudohermaphrodite type.
2. The gilt had testicles as gonads, and internal and external genitalia showed an ambiguous differentiation, being more or less female-oriented gender.
3. The testes showed both exocrine and endocrine compartments. The seminiferous tubules, looking polymorphic, showed an intense vacuolization of the epithelium (both Sertoli cell cytoplasm and in spermatogonias). The Leydig cells which represent the endocrine compartment also had a vacuolization of the cytoplasm.
4. Epididymis was along one edge of the testicle, covering one third of its circumference the epididimar channel is structured of a epithelium ciliated with many stereocilia at the apical pole of the cells, length of 5-7 µm and in its lumen were not observed spermatozoa due to the vacuolization of the Sertoli cell and the first seminal cell line (spermatogonias).

5. At one pole of the testis were observed the pampiniforme plexus highly developed, wich contains many arteries, arterioles, veins and venues and together with the deferent duct forms the spermatic cord.
6. In some sections the defent duct and the uterus are merger through the same mezou.
7. Near the vagina were observed two hard structures that in histological examination were clarified as male genital glands: the prostate gland and bulbourethral gland.

Bibliography

- Bansal N., Roy K.S., Sharma D.K., Sharma R. (2005) – Anatomical study on true hermaphroditism in an Indian pig. Journal of veterinary science, vol. 6, pag. 79-82.
- Basrur P. K., Kanagawa H. (1971) - Sex anomalies in pigs. Journal of reproduction and fertility, vol. 26, pag. 369-371.
- Bistriceanu I. M. (1971) – Studiul anomaliilor morfo-funcţionale şi genetice în intersexualitatea suină. Teză de doctorat. Timişoara.
- Brambell F. W. R. (1929) - The histology of an hermaprhrodite pig and its developmental significance. Journal of anatomy, vol 40, pag 397 – 407.
- Ciornei Cristina, Cotea C., Solcan Carmen (2009) – Cercetări histologice în hermafroditismul bilateral la suine (*Sus scrofa domestica*). Lucrări ştiinţifice, vol. 52 (11). Medicină Veterinară. Partea I. Ed. "Ion Ionescu de la Brad" Iaşi, pag. 44-50.
- Ciornei Cristina, Pavli C. (2009) – Utilizarea diagnosticului ecografic în stabilirea tipului de hermafroditism la suinele domestice (*Sus scrofa domestica*). Lucrări ştiinţifice, vol. 52 (11). Medicină Veterinară. Partea I. Ed. "Ion Ionescu de la Brad" Iaşi, pag. 51-55.
- Cotea C. (2003)– Histologie specială, Ed. Tehnopress, Iaşi.
- Gerneke W.H. (1967) – Cytogenetic investigations on normal and malformed animals with special reference to intersexes. Oderstepoort Journal of veterinary research., vol 34, pag.219-223.
- Gluhovschi N., Bistriceanu M. (1973) – Patologia reproducţiei animalelor de fermă. Ed. Facla, Timişoara.
- Halina W. D., Barrales D. W., Partlow G. D, Fisher K. R. S. (1984) – Intersexes in swine: a problem in descriptive anatomy. Canadian Journal of veterinary research vol. 48, pag. 313-321.
- Hunter R. H. F., Baker T. G., Cook B. (1982) – Morphology, histology and steroid hormones of the gonads in intersex pigs. Journal of reproduction and fertility, vol. 64 pag. 217-222.
- Laus J.E., Ferrari Iris, Lobo R. B (1984) – Inheritance of swine intersexuality (*Sus scrofa domestica*): an experimental study. Brazil Journal of Genetics, vol. II (4), pag.647-656.
- MacLachlan N. J. (1987) - Ovarian disorders in domestic animals. Environmental Health Perspectives, vol. 73, pag. 27-33.
- Okamoto A. Masuda H. (1977) – Cytogenetic studies of intersex swine. Physical and biological science, vol. 53, pag. 276-281.
- Pitoiu Claudiu (2009) – Cercetari referitoare la anomaliile congenitale ale aparatului genital la suine si implicatiile economice ale acestora. Teza de doctorat - Universitatea de Stiinte Agronomice si Medicina Veterinara Bucuresti.
- Tiranti I.N., Genghini R.N., Quintana G.H., Wittouck P. (2002) – Morphological and karyotypic characterization of intersex pigs with hernia inguinalis. Journal of Agricultural Science, 138, pag. 333-340.

HISTOLOGYCAL RESEARCHES OF TRUE BILATERAL HERMAPHRODITISM IN DOMESTIC SWINES (*SUS SCROFA DOMESTICA*)

CIORNEI Cristina, COTEA C.V., SOLCAN Carmen
Faculty of Veterinary Medicine Iasi

The case study was done on a gilt, Great White species, 9 months old, weighing 80 kg. The pig was found on a swine farm in Iasi County.On the exterior, the gilt presented a vulvae orifice along with two testicular bags well developed. Because of these two characteristics, the gilt was ruled to be an intersex animal. The animal has been examined from both an anatomical and ultrasound perspective, confirming the diagnosis through histological examination. Under histological aspects, the gonads were classified as being "ovotestis" with a testicular area located in the cranial side of the ovotestis, and a ovarian area located in the caudal area of the ovotestis. The ovotestisis being on both sides of the genital tract, the animal was classified as true bilateral hermaphrodit. From both sides of the mezou there was a rudimentary oviduct and a deferential canal that opened at the end of the urinary gland. Around the ovaries area of the ovotestis we acknowledge the presence of a thick albuginee and in the cortical zone, the development of the primary and secondary involutive follicles. Some of the follicles that end up in the third follicle phase present ovocits with the disorganized radiated crown and the nucleus in karyolysis and pyknosis phase. Inside the ovotestis, the semnifer tubules have a diameter of 130-140µm, with the spermatogonias being one after the other, all presenting the cytoplasm with intense vacuolization. Some nuclei are pyknotics, which demonstrates that the necrobiosis is present since the spermatogonium stage. Interstitial Leydig cells appear with a foamy cytoplasm, but we have to notice that they display the facultative gonosomic heterochromatin X.

Keyword: true bilateral hermaphroditism, swine, ovotestis

MATERIAL AND METHODS

The case report was done was done on a gilt, Great White species, 9 months old, weighing 80 kg. The pig was found on a swine farm in Iasi County.

Although the gilt presented a female phenotype thru the presence of the vulva and the vulvae orifice, it was also observed the presence of two testicular bags well developed (fig.1, fig 2). Because of this abnormalities the case ruled to be an intersex animal.

To establish the exact type of intersexuality, the gilt was examined anatomically and ultrasound (fig.2), confirming the diagnosis through histological examination. For the ultrasound examination we used the Aloca Prosound 2 device and a 6MHZ ultrasound probe. The ultrasound exploration of the genital tract was performed percutaneous supine but also in patrupodal support The urinary bladder was used as a landmark and the exam started in a caudo-cranial way.

For histological examination, fragments of gonads and genital tract were harvested, fixed in 10% formalin, Carnoy and Orth, included in paraffin, series sections were made at 5µm and stained HEA, PAS, Novelli, Alcian Blue, Papanicolau and Steedman Mowry.

RESULTS AND DISCUSSIONS

The testicular bags inspection has shown that these are placed subrectal, with a broad base, which continues with perineal skin, without a clear demarcation and that the

median line is very visible (fig. 1). On the palpation of the testicular bags we have not noticed the presence of the testicles , but a fluctuate mass, the ultrasound examination revealing an accumulation of fluid.

Under anatomically aspect the vulva had a normal aspect, it was just below the anal orifice and it's labial components were relatively thick, covered by a crinkled skin. The dorsal corner appears rounded, while the ventral one presents sharp with an cutaneous conoid appendix.

By deep palpation of the two orificies (rectal and vulvae), to highlight their functionality, has been observed that vulvae constrictor muscle is well developed.

At slaughter, it was noticed that the genital tract was consisted of two structures with a "blackberry" appearance that would correspond the gonads (fig. 5). These formations were bigger than the normal ovaries.

These formations were tied to the rest of the genital tract thru two long and thin tubules that would correspond to the uterus and the uterine horns. The vagina measured 4 cm long and inside was present the urinary bladder orifice (fig. 3, fig.4).

Under histological aspects, the gonads were classified as being "ovotestis" with a testicular area located in the cranial side of the ovotestis, and a ovarian area located in the caudal area of the ovotestis. The ovotestisis being on both sides of the genital tract, the animal was classified as true bilateral hermaphrodit.

In the ovarian area of the ovotestis, it was noticed a thick tunica albuginea and in the cortical area, we have noticed primary and secondary involutive follicles. Some of this follicles that reach the mature stage, presents the pellucida zone irregular and strangled (fig. 9, fig.10, fig 11), the radiated crown disorganized and the nucleus in karyolysis and pyknosis phase (fig.15). The granulosa membrane of the follicles shows a homogenous mass of cell, detached from Slawjanski membrane (fig. 12, fig. 13, fig.14). Some of these follicles were highlighted in the area where the ovarian area joins the testicle area thru a shared albugineea. Some follicles were observed near the seminiferous tubules from the testicular area of the ovotestis. Other mature follicles located at the merging of the two albugineas, have an abnormal structure through the absence of the oocyte (fig. 6, fig. 7, fig. 8). The association of the two structures (follicles and seminiferous tubules) is made through merging of the albugineas, resulting a thick albuginea.

Inside the ovotestis, the seminiferous tubules have a diameter of 130-140 µm, with the spermatogonias being on a single row, all presenting the cytoplasm with intense vacuolization. Some nuclei are pyknotics, which demonstrates that the necrobiosis is present since the spermatogonium stage (fig. 16, fig. 17, fig.18, fig. 19).

Interstitial Leydig cells, located in the connective tissue between seminiferous tubules (fig.18) appear with a foamy cytoplasm, but we have to notice that they display the facultative gonosomic heterochromatin X.

Regarding the genital tract segments, under histological appearance, it was noticed the presence of an rudimentary oviduct but also some parts of uterine horns (fig. 20, fig.21). The oviduct is about 1250 µm in diameter with an epithelium height of 17,5 µm. At the jonction of the oviduct and uterine horn, we have noted the presence of uterine glands (fig. 22, fig. 24).

Beside this, there were two deferent ducts suported through the same mezou (fig. 23).

The connection between the uterus and the vagina was poorly represented by a rudimentary cervix, this presenting numerous vegetative satellite ganglions that have a dual

role in providing vegetativ innervations (sympathic and parasympathic), with antagonistic action (fig. 25).

The mucosa of the vaginal wall is structured by a typical nonkeratinized stratified squamous epithelium, three layers (the basal layer, the intermediate layer and the superficial layer). The generating basal layer rests on a basal lamina, in intimate contact with a highly vascularized lamina propria, containing numerous sensitive corpuscles (fig. 26).

Fig.1 – Male pseudohermaphroditism(PHM) - anatomical and clinical appearance – the presence of the vulvae orifice with a large clitors along with two testicular bags well developed

Fig.2 - True hermaphroditism - anatomical and clinical appearance – the presence of the gonads in the abdominal cavity .

Fig.3 - True hermaphroditism – anatomical and clinical appearance of the uro-genital tract – the presence of the gonads, deferent duct, vagina and the vagina vestibule, the urinary bladder and the rectum.

Fig.4 – True hermaphroditism – macroscopic appearance of the gonads.

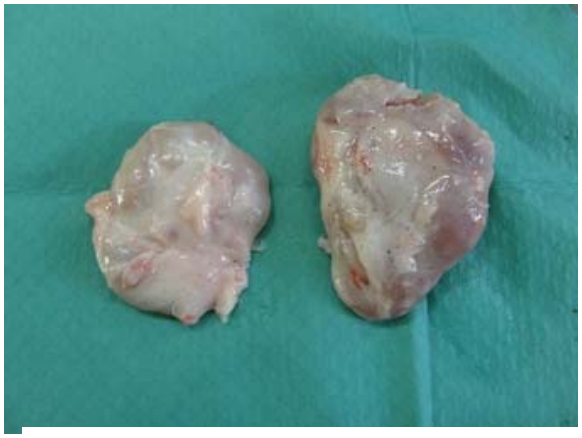

Fig.5 – True hermaphroditism – macroscopic appearance of the gonads.

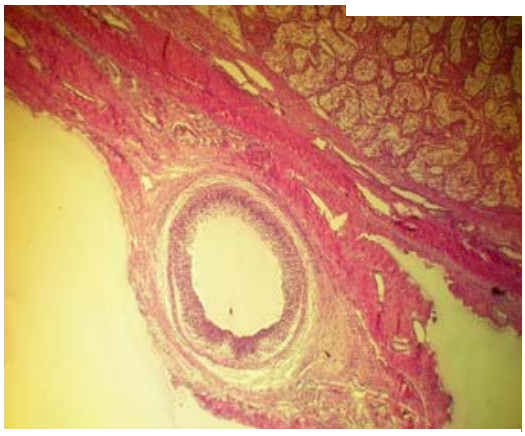

Fig.6 – Ovotestis – the presence of a ovarian mature follicle without the oocyte and the seminiferous tubules, separated through merging of the albugineeas. Col. HEA, x 80.

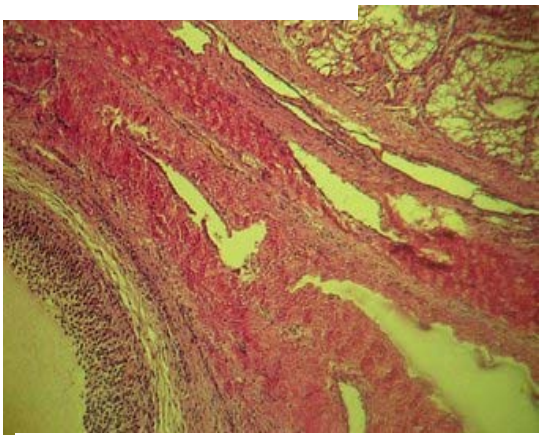

Fig.7 - Ovotestis – the presence of the ovarian mature foliclle and the seminiferous tubules, separated through a thick shared albugineea. Col. HEA, x 100

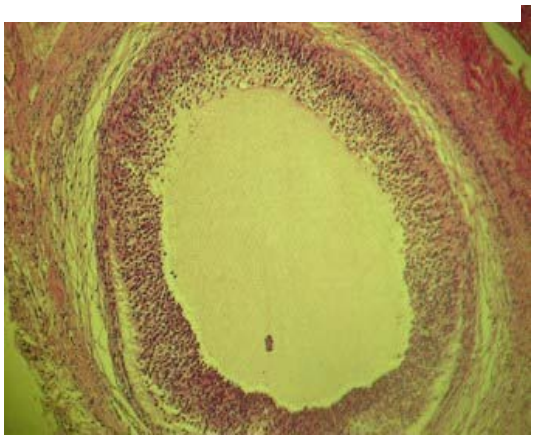

Fig.8 - Ovotestis –ovarian mature foliclle without the oocyte.Col. HEA, x 400.

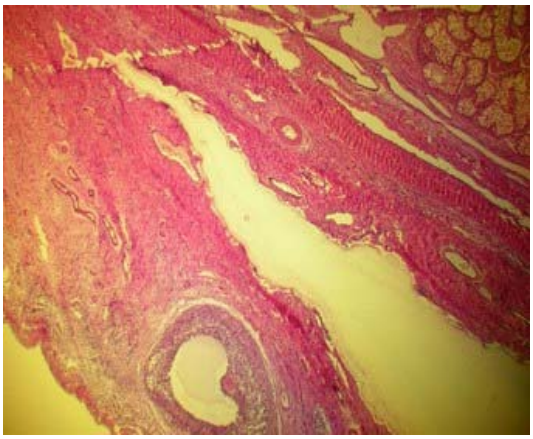

Fig. 9 - Ovotestis – Ovarian mature foliclle with one oocyte that presents the zona pellucida irregular and strangled, and separated by seminiferous tubules through a thick shared albugineea. Col. HEA, x100.

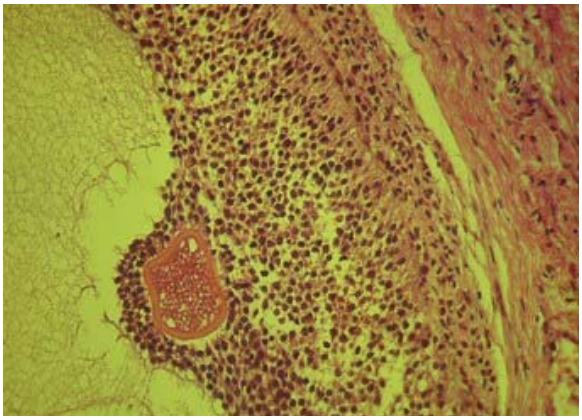

Fig.10 - Ovotestis – ovarian matur foliclle with one oocyte that presents the zona pellucida irregular and strangled. Col. PAS, x 200.

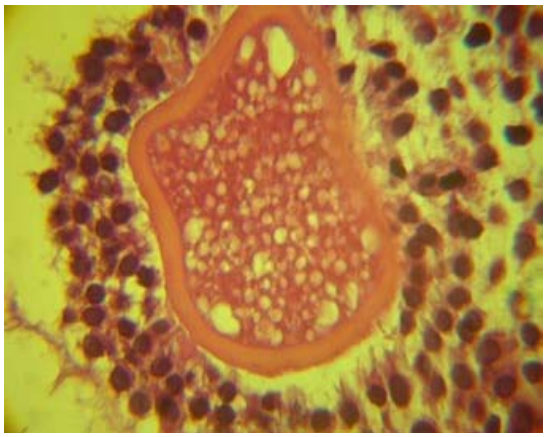

Fig.11 - Ovotestis – ovarian matur foliclle with one oocyte presenting an irregular and strangled zona pellucida. Col. PAS, x 400.

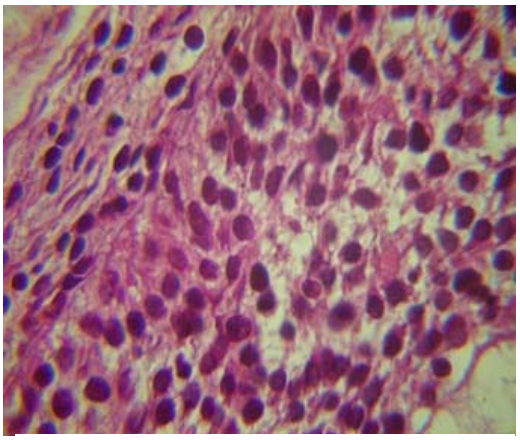

Fig.12 – Ovotestis – ovarian mature foliclle with granulosa membrane and internal sheath. Col HEA, x400.

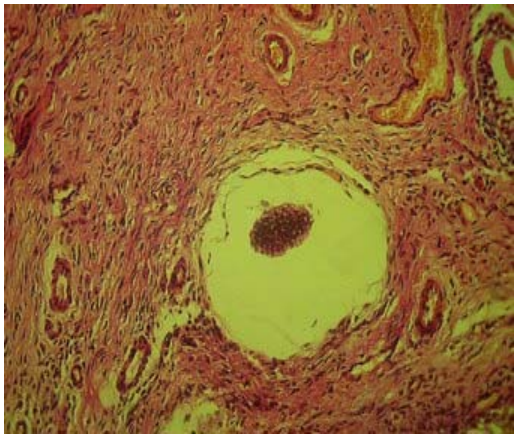

Fig.13 – Ovotestis – congestion of granulosa cell. Col PAS, x200

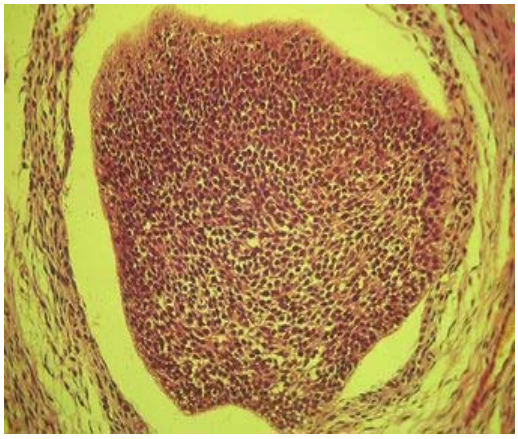

Fig.14 – Ovotestis – homogeneous mass of granulosa cells detached from Slawjanski membrane. Col PAS, x200.

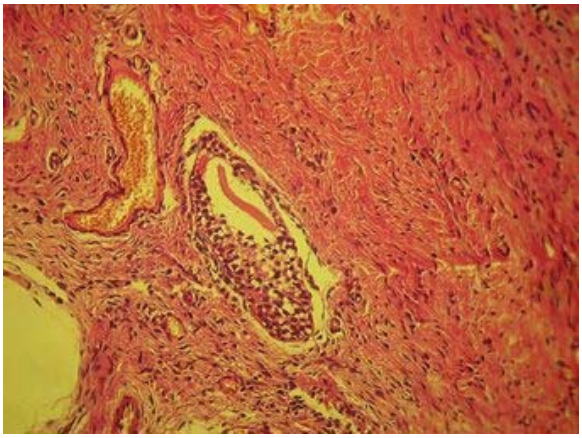

Fig.15 – Ovotestis – ovocytolysis. Col. PAS, x80.

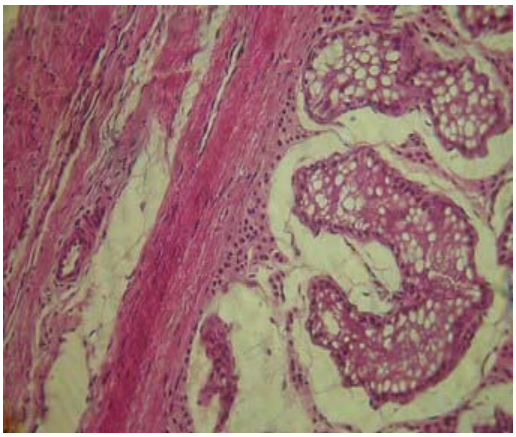

Fig.16 – Ovotestis – the tunica albuginea, the seminiferous tubules and interstitial Leydig gland. Col PAS, x80.

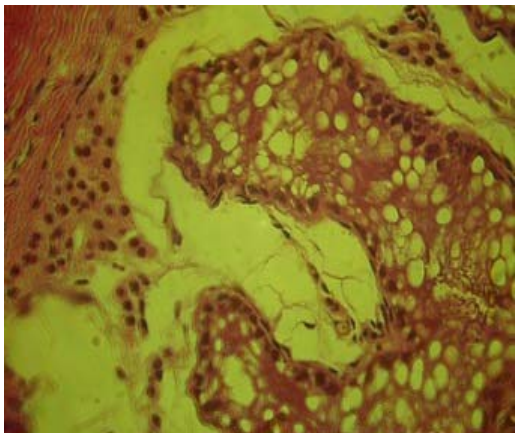

Fig.17 - Ovotestis – the tunica albuginea, the seminiferous tubules and interstitial Leydig

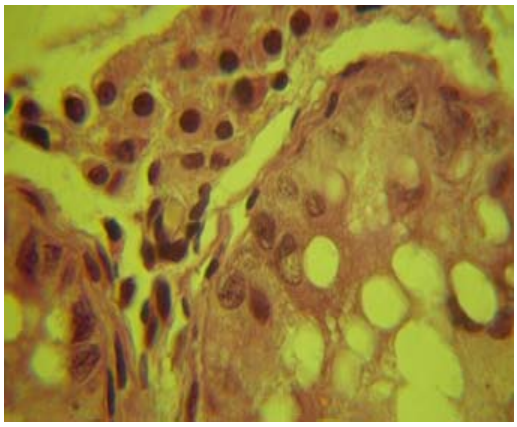

Fig.18 – Ovotestis – the tunica albuginea, the seminiferous tubules and interstitial Leydig gland. Col PAS, x80.

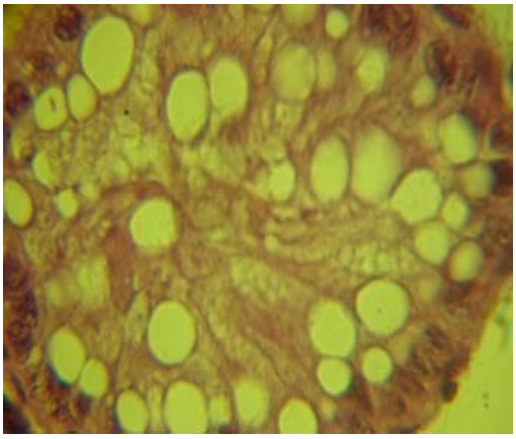

Fig.19 – Ovotestis – the tunica albuginea, the seminiferous tubules and interstitial Leydig gland. Col PAS, x80.

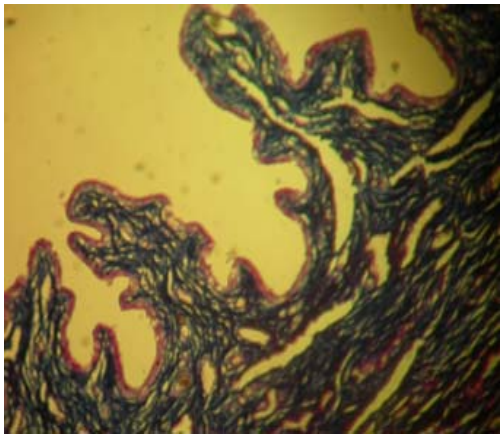

Fig. 20 – True hermaphroditism – rudimentary oviduct. Col. Novelli, x100.

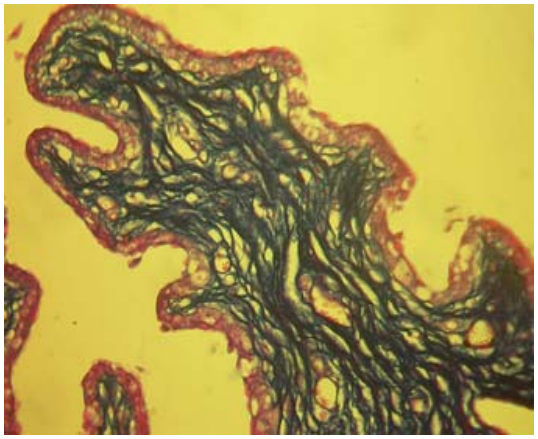

Fig. 21- True hermaphroditism – rudimentary oviduct. Col. PAS, x400.

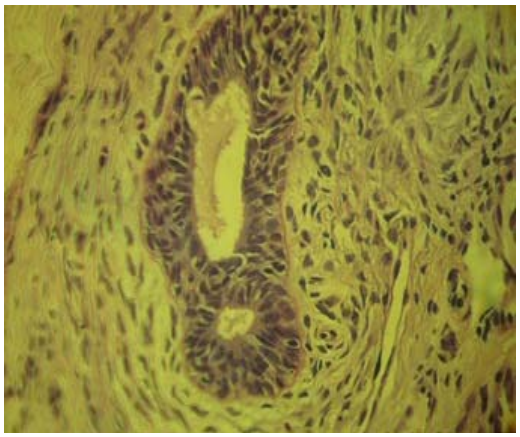

Fig. 22 – True hermaphroditism – the presence of glands at the jonction of the oviduct and uterin horn. Col. PAS, x400.

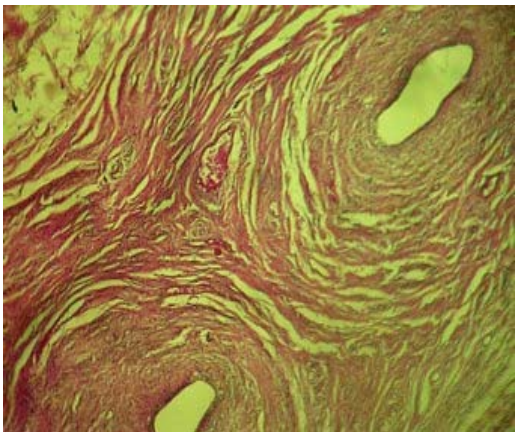

Fig. 23 – True hermaphroditism –two deferent ducts suported through the same mezou. Col. PAS. x100

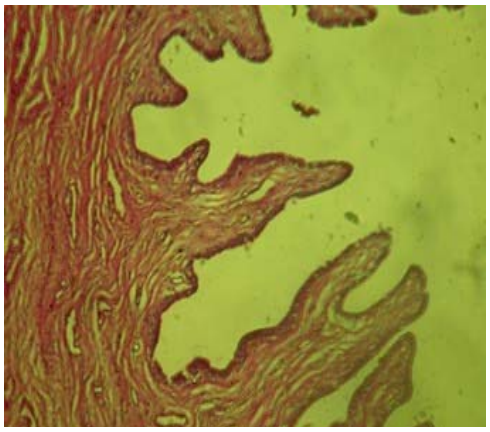

Fig. 24 – True hermaphroditism – the presence of glands at the jonction of the oviduct and uterin horn. Col. PAS, x400.

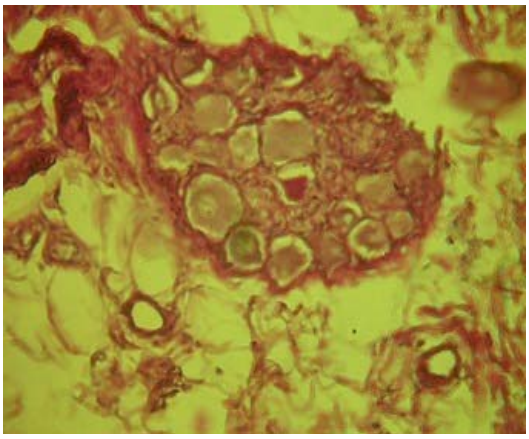

Fig. 25 - True hermaphroditism – vegetativ ganglion satellite of the cervix. Col. PAS, x400

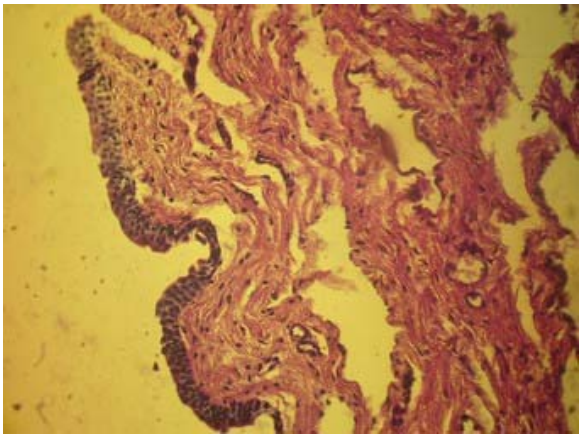

Fig. 26- True hermaphroditism – rudimentary vagina with three rows of stratified epithelium and lamina propria with a fringe appearance. Col. PAS, x200.

CONCLUSIONS

1. This case, studied under anatomical, ultrasound and histological aspects, was been diagnosed as

true bilateral hermaphrodite, because the existence of the ovotestis as gonads.

2. In the cortical area of the ovarian part, we have noticed primary and secondary involutive follicles

but also follicles that reached the mature phase. Some of this follicles presents the pellucida zone irregular and strangled, the radiated crown disorganized and the nucleus in karyolysis and pyknosis phase.

3. The granulosa membrane of the follicles, shows a homogenous mass of cell, detached from the

Slawjanski membrane. Some of this follicles were highlighted in the area where the ovarian area joins the testicle area thru a shared albugineea.

4. Other mature follicles located at the merging of the two albugineas, have an abnormal structure

through the absence of the oocyte and were observed near the seminiferous tubules from the testicular area of the ovotestis. The association of the two structures (follicles and seminiferous tubules) is made through merging of the albugineas, resulting a thick one.

5. Inside the ovotestis, the seminiferous tubules have a diameter of 130-140µm, with the

spermatogonias being on a single row, all presenting the cytoplasm with intense vacuolization. Interstitial Leydig cells, located in the connective tissue between seminiferous tubules appear with a foamy cytoplasm, but we have to notice that they display the facultative gonosomic heterochromatin X.

6. Under histological appearance, it was noticed the presence of an rudimentary oviduct but also

some parts of uterine horns. The oviduct is about 1250 µm in diameter with an epithelium height of 17,5 µm. At the jonction of the oviduct and uterine horn, we have noted the presence of uterine glands.

7. Beside this, there were two deferent ducts suported through the same mezou.

8. The rudimentary cervix had numerous vegetative satellite ganglions with a dual role in providing

vegetativ innervations (sympathic and parasympathic), with antagonistic action.

9. The mucosa of the vaginal wall is structured by a typical nonkeratinized stratified squamous epithelium, three layers (the basal layer, the intermediate layer and the superficial layer). The generating basal layer rests on a basal lamina, in intimate contact with a highly vascularized lamina propria, containing numerous sensitive corpuscles.

BIBLIOGRAPHY

1. Bansal N., Roy K.S., Sharma D.K., Sharma R.(2005) –Anatomical study on true hermaphroditism
2. in an Indian pig. Journal of veterinary science, vol. 6, pag. 79-82.
3. Basrur P. K., Kanagawa H.(1971) -Sex anomalies in pigs. Journal of reproduction and fertility, vol.
4. 26, pag. 369-371.
5. Bistriceanu I. M.(1971) –Studiul anomaliilor morfo-funcţionale şi genetice în intersexualitatea suină.
6. Teză de doctorat. Timişoara.
7. Brambell F. W. R.(1929) -The histology of an hermaprhrodite pig and its developmental
8. significance. Journal of anatomy, vol 40, pag 397 –407.
9. Ciornei Cristina, Cotea C., Solcan Carmen(2009) –Cercetări histologice în hermafroditismul
10. bilateral la suine (*Sus scrofa domestica*). Lucrări ştiinţifice, vol. 52 (11). Medicină Veterinară. Partea I. Ed. "Ion Ionescu de la Brad" Iaşi, pag. 44-50.
11. Ciornei Cristina, Pavli C.(2009) –Utilizarea diagnosticului ecografic în stabilirea tipului de
12. hermafroditism la suinele domestice (*Sus scrofa domestica*). Lucrări ştiinţifice, vol. 52 (11). Medicină Veterinară. Partea I. Ed. "Ion Ionescu de la Brad" Iaşi, pag. 51-55.
13. Cotea C.(2003)–Histologie specială, Ed. Tehnopress, Iaşi.
14. Gerneke W.H.(1967) –Cytogenetic investigations on normal and malformed animals with special
15. reference to intersexes. Oderstepoort Journal of veterinary research., vol 34, pag.219-223.
16. Gluhovschi N., Bistriceanu M.(1973) –Patologia reproducţiei animalelor de fermă. Ed. Facla,
17. Timişoara.
18. Halina W. D., Barrales D. W., Partlow G. D, Fisher K. R. S.(1984) –Intersexes in swine: a problem
19. in descriptive anatomy. Canadian Journal of veterinary research vol. 48, pag. 313-321.
20. Hunter R. H. F., Baker T. G., Cook B.(1982) –Morphology, histology and steroid hormones of the
21. gonads in intersex pigs. Journal of reproduction and fertility, vol. 64 pag. 217-222.
22. Laus J.E., Ferrari Iris, Lobo R. B(1984) –Inheritance of swine intersexuality (*Sus scrofa domestica*):
23. an experimental study. Brazil Journal of Genetics, vol. II (4), pag.647-656.
24. MacLachlan N. J.(1987) -Ovarian disorders in domestic animals. Environmental Health
25. Perspectives, vol. 73, pag. 27-33.
26. Okamoto A. Masuda H.(1977) –Cytogenetic studies of intersex swine. Physical and biological
27. science, vol. 53, pag. 276-281.
28. Pitoiu Claudiu (2009) – Cercetari referitoare la anomaliile congenitale ale aparatului genital la suine
29. si implicatiile economice ale acestora. Teza de doctorat - Universitatea de Stiinte Agronomice si Medicina Veterinara Bucuresti.
30. Tiranti I.N., Genghini R.N., Quintana G.H., Wittouck P. (2002) – Morphological and karyotypic
31. characterization of intersex pigs with hernia inguinalis. Journal of Agricultural Science, 138, pag. 333-340.

COMPUTERIZED MICROSCOPY RESEARCH ON STRUCTURAL BIOLOGY OF THE SEMINIFEROUS TUBULES AND INTERSTITIAL GLAND AT THE COCKS 60-90 DAYS OLD

Valerica DĂNACU, N .CORNILĂ, Nicoleta MOCANU, Ştefania PREDOI, M.CORNILĂ.

Facultatea de Medicina Veterinara, Bucuresti
valericadanacu@yahoo.com

SUMMARY

At the specimens from the age of 60 days, it was found that the seminiferous tubules epithelium is simple and consisting of Sertoli cells and the spermatogoniums. Myofibroblastes are obvious and located peritubulary. Peritubulary connective tissue in the testicular parenchyma is reduced quantitatively. From the age of 90 days is clear that an end point of pseudostratified seminal epithelium, but the cell types and Sertoli cells are still prevails spermatogoniums and take the other two age as described above. There is a very intense reaction P.A.S. Take the positive step of tubular basement of the seminiferous membrane. There are many cells in semen Sertoli epithelium, in peritubulary are located myofibroblastes. At cocks 60 days old, in the interstitial gland, is not observed oxifile grit cells. Seminiferous tubules are coverings by the monostratification epithelium, of a distinguished monostratificat, appear Sertoli cells and spermatogoniums. in peritubulary are located myofibroblastes. At the age of 90 days it observe a quantitative reduction of intertubular. Interstitial endocrinocytes have different size, some are fusiforme, others have cytoplasm vacuolar, being involved in hormonegenesis.

Key words: seminiferous tubules, gonocytes, Sertoli cells, Interstitial gland

MATERIAL AND METHOD

The researches were conducted on testes harvested from cock, race-variety white Leghorn 60 and 90 days, normally developed, clinically healthy, vaccinated, macroscopically and microscopically examined. It made an experiment which included two lots of cocks, each lot consisting of 4 copies each, from each individual were collected pieces of testicular parenchyma from skull pole, caudal, medial edge and lateral edge. The inspection of histological preparations were made on permanent histology, processed by usual histological techniques and colored by hematoxylin-eozine method, Giemsa slow sections, Tanzer-Unna and P.A.S histochemical techniques.

RESULTS AND DISCUSSIONS

In the sections performed in the testicular parenchyma is seen as the lumen of the seminiferous tubules of birds, like those of a mammal is defined by germinating epithelium

located on a basement membrane. In terms of histology, seminiferous tubules are three components: the basement membrane, Sertoli cells (sustentaculare) and seminal cells line Basal membrane surrounding the seminiferous tube. Internal layer is basal lamina. Is related to several collagen and elastic fibers to cells peritubulary (myofibroblastes), which form a blanket of 1-5 layers. External layer of the tubular basal lamina contains fibrocim and collagen fibers. Free mononuclear cells (lymphocytes and monocytes) invades the lamina propria, but never invades seminal epithelium. At the age of 60 days, it was found that the seminiferous tubules epithelium is simple and consists of Sertoli cells and spermatogoniums. Myofibroblastes are obvious and peritubular located. In the testicular parenchyma connective tissue peritubulary is significantly reduced. And at the age of 60 days, morphometric determinations were made of the outer diameter of seminiferous tubules, their lumen diameter and epithelium height semen to be compared with previous ones.

In table No. 1 are given values obtained:

SEMINIFERIOUS TUBULES	OUTSIDE DIAMETER (µm)	LUMEN DIAMETERS (µm)	EPITHELIUM HEIGHT (µm)
1	72,798	32,329	20,234
2	65,656	25,253	20,201
3	62,626	24,242	19,192
4	65,500	19,192	23,154
5	59,596	21,212	19,192
6	68,687	27,273	20,707
7	69,697	26,263	21,717
8	70,707	21,253	24,727
9	67,500	22,222	22,664
10	60,600	22,222	19,189
MEDIA	66,336	24,146	21,097

Since of the of 90 days old is found the seminal epithelium gets form of pseudostratification aspect, but the predominant cell types are Sertoli and spermatogoniums as the other two ages above. Appear a reaction P.A.S. intense positive in the basement membrane of the seminiferous tubules. In the seminal epthelium are many Sertoli cells, and in peritubulary are located myofibroblasts.

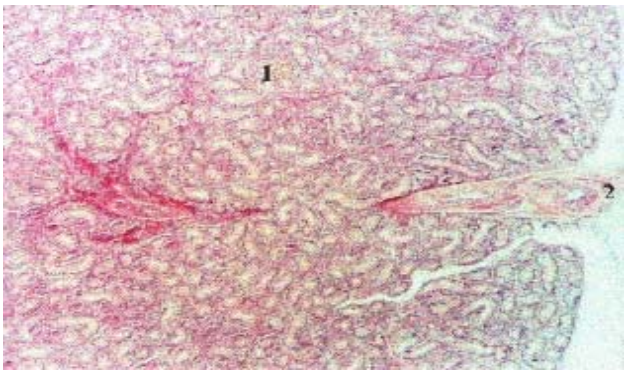

Fig. 1 General appearance of testicular parenchyma and lymphatic vessel intratesticulary at the cocks by 60 days. Ob. 4X, col. H.E.

1-testicular parenchyma; 2- blood vessel

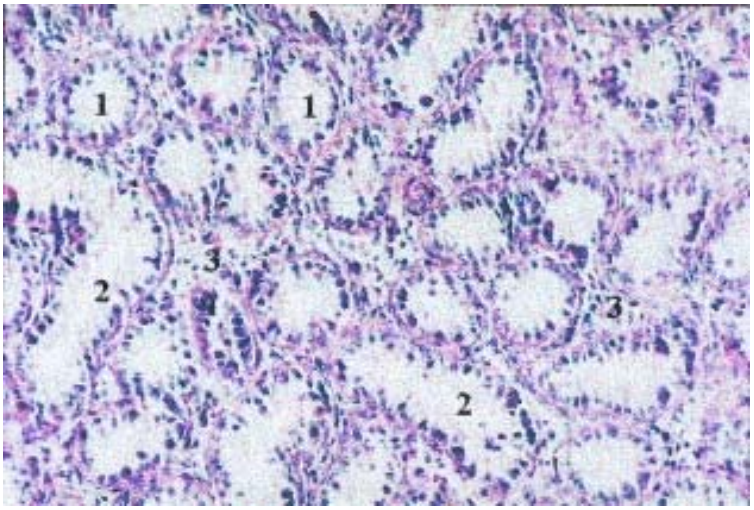

Fig. *2* Cocks testicle by 90 days. P.A.S., ob. 20X

1-seminiferous tube transversely sectioned; 2-seminiferous tube sectioned obliquely; 3- interstitial gland

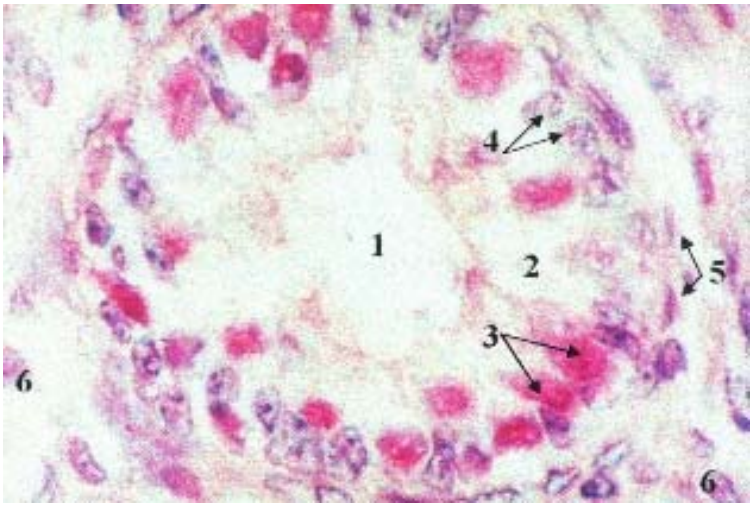

Fig. 3 Seminiferous tube sectioned transversally at Cocks by 90 days. H.E. Ob X100

1-lumen; 2-seminal epithelium; 3- sertoli cells; 4- Spermatogoniums; 5- nucleus myofibroblasts; 6- Leydig cells

In the histological sections made from the testicular parenchyma was observed that the spaces between the seminiferous tubules contain connective tissue laxity, blood vessels of different sizes, lymphatic vessels, adrenergic nervous fibers, fibroblast, free mononuclear cells and endocrinocite interstitial (Leydig cells). Connective tissue cells are represeted by the fibroblasts, undifferentiated connective cells, mastocytes and macrophages.

At the cocks with 60 days age, in interstitial gland is not observed cells with granulations oxifile. Seminiferous tubules are tapetap with a epithelium monostratification, were distinguished Sertoli cells and spermatogonium, and in peritubular arranged myofibroblasts .

At the age of 90 days it see a quantitative reduction of intertubular space. As the advance in

age, intertubular space where is interstitial gland is progressively reduced. In sections stained by Tanzer-Unna method gland interstitial appear in tubular tissue, delimited by elastic fibers from the basal lamina of seminiferous tubules.

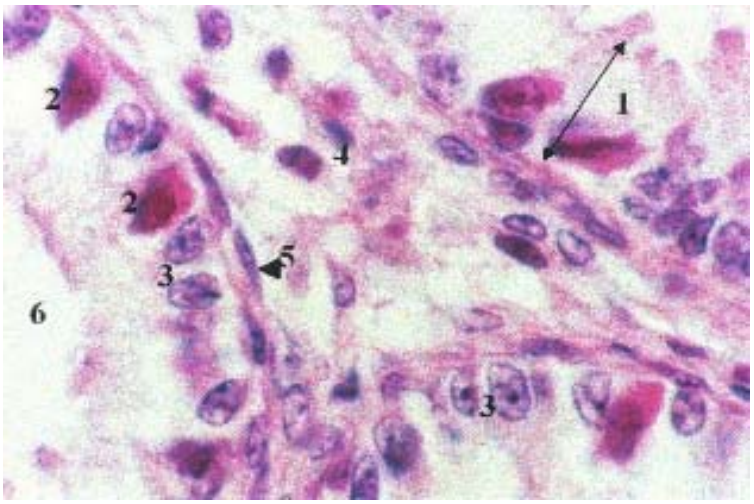

Fig. 4 Interstitial gland al cocks by 60 days, H.E., Ob.1ooX

1- seminal epithelium; 2- sertoli cells; 3- Spermatogoniums; 4- interstitial gland; 5- myofibroblasts; 6- lumen of the seminiferous tube

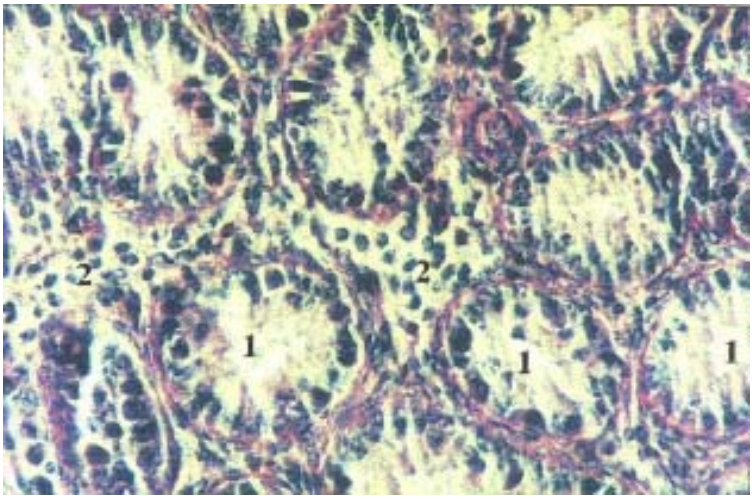

Fig. 5 Seminiferous tubules and interstitial gland at cocks by 90 days P.A.S., Ob 40X

1- seminiferous tubules sectioned transversely; 2- interstitial gland

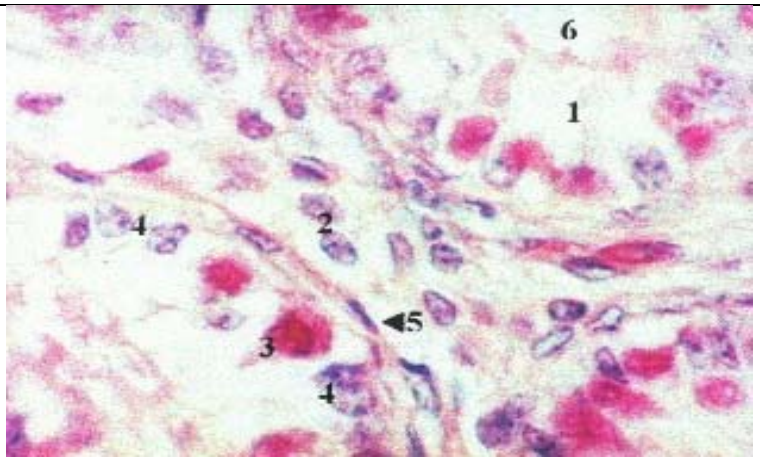

Fig. 6 Interstitial gland at cocks by 90 days . H.E., Ob 100X

1- seminal epithelium; 2- Leydig cells; 3- sertoli cell; 4- Spermatogoniums; 5- myofibroblasts; 6- the lumen of the seminiferous tube.

The research on electron microscopy of the testicular parenchyma, from the cocks, I highlighted some outstanding issues, unreported in the specialty literature. Seminal epithelium is placed on a thick basement membrane, composed of lamina lucid (rare), electronodense with thickness by 10 nanometers, homogeneous and crossed by fine filaments rare; a lamina thickness of 20-30 nanometers thick, composed by filaments fines abundants, contained in an amorphous matrix, dense and a lamina reticulata which pass to the connective tissue matrix. Basement membrane has many identary or invagination in the seminiferous epithelium, directed mainly by Sertoli cells and contains numerous electron-light granules. Is placed on a miofibrilar layer homogeneous devoid of collagen fiber. Is apparent basement membrane is apparent of the seminiferous tube, quite thick, being placed above the seminal epithelium, composed of cells Sertoli and seminal cells line. Herocromatic Sertoli cell has a nucleus composed of large coarse chromatin. In his cytoplasm are numerous mitochondria and rough endoplasmic reticulum.

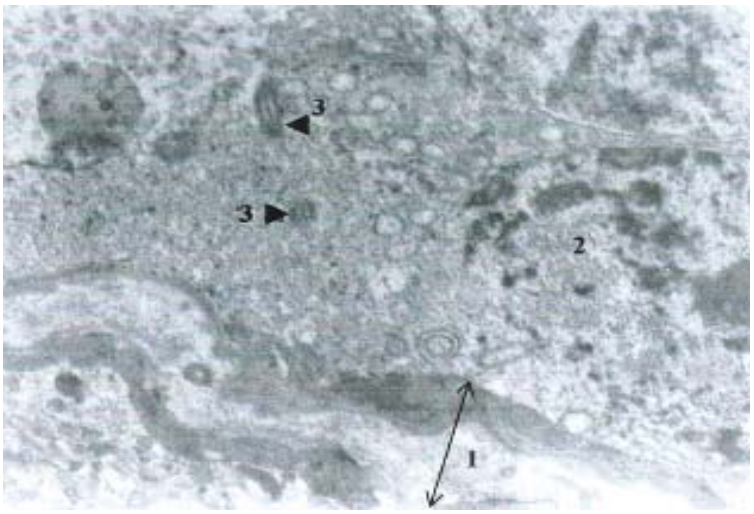

Fig. 7 Sertoli cell is located on the basement membrane of seminiferous tube (X22.000)

1- basement membrane; 2-nucleos Sertoli cell; 3- centrioles.

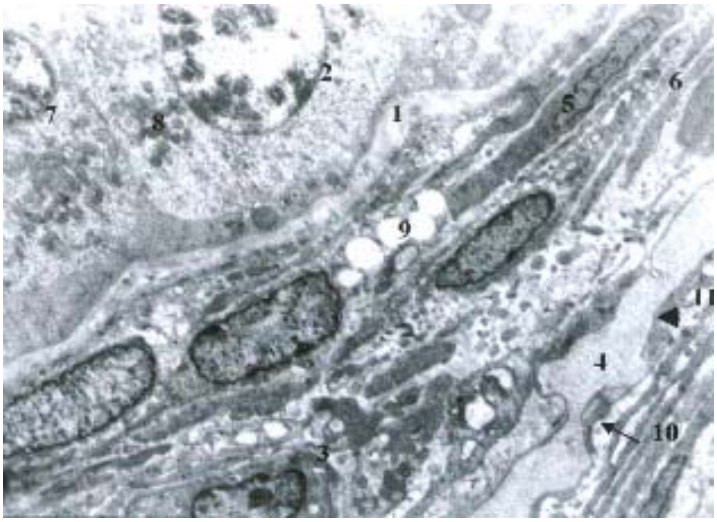

Fig. 8 Seminal epithelium – ultrastructure (X 22.000)

1- basement membrane; 2- Sertoli cell; 3-Leydig cell; 4- capillary blood; 5- fibroblast; 6- collagen fibres; 7-Spermatogonium; 8-mitochondria; 9-Elements of smooth endoplasmic reticulum; 10-the capillary basement membrane; 11- edoteliate cells

CONCLUSIONS

3.1. Histostructure of the testicular parenchyma at 60 days old is characterized by the presence of seminiferous tubules with reduced diameter in intertubular space occupied by a mass of tissue that is scattered the interstitial endocrinocites. In the seminal epithelium predominates the Sertoli cells and spermatogoniums.

3.2. At the age of 90 days the seminal epithelium tends to pseudostratification. At the age of 120 days in the seminal epithelium are present all types of cells of the seminal line - primary spermatocites, secondary spermatocites, spermatide and sperm, that indicating onset of spermatogenesis process. Sertoli cells were observed in cross sections of seminiferous tubules, they are willing unistratal, with the nuclei located basal, polymorphous nucleolus sometimes triangular course.

3.3. Sertoli cell is located on the basement membrane of seminiferous tube that makes complex jonctionale.

3.4. At the age of 90 days the interstitial Leyding gland appears in intertubular tissue, delimited by the elastic fibers from the basal lamina of seminiferous tubules.

3.5. It is noted that the basement membrane of seminiferous tube is thick and shows numerous invagination directed to the cytoplasm of the Sertoli cells.

3.6. The cytoplasm of the Sertoli cell is dense and has more organites- numerous cistern of smooth endoplasmatic reticulum, numerous mitochondria, rough endoplasmic reticulum profiles, lysosomal, Golgi complex, centrioli, etc.

ACKNOWLEDGEMENTS

The researches presented in this paper were financially supported by ID_1415 National University Research Council (C.N.C.S.I.S) research grant, contract no. 1066/2009.

REFERENCES

1. Aire, T. A. – Cyclicaal reproductive changes in the non-ciliated epithelia of the epididymis of birds. Atomonia, Histologia, embryologia, volume 31, bnnIssue 2, Page 113-8, 2002.
2. Bacha, J.Jr., Wood, L M.(2000) – Color atlas of veterinary histology. Lea and Febiger, Beckembaum, 2nd ed.
3. Cornila, N. (2000-2001) - Microscopic morphology of domestic animals. Ed. Bic. ALL, vol. I-II.
4. Hess, R.A., Franca, L.R. (2005)- Strcuture of Sertoli Cell. In: Sertoli Cell Biology. M. Griswold and M. Skinner. New York, Academic Press, 19-40.
5. Maretta, M., Marettova, E. (2004) – Immunohistochemical demonstration of myoid cells in the testis and its excurrent ducts in the domestic fowl. Vol 45, Number 5, Oct., 585-589.
6. Miranda, J.R., Rocha, D.C.M., Hess, R.A., Cassali, G.D., Franca, L.R. (2002) – Sertoli cell proliferation in the transition between seminiferous tubules and the rete testis. European Testis Workshop.
7. Oster, H. (2000) – Sexual differentiation. Semin Reprod Med; 18(1):41-9.
8. Sin, M.K., Cheng, C.Y. (2004) – Extracellular matrix: recent advances on its role in junction dymamics in the seminiferous epithelium during spermatogenesis. Biol Reprod; 71(2):375-91.
9. Wheater, P.R., Burkitt, H.G., Daniels, V.G. (2001) – Functional histology – A text atlas medical divisions of Langmann group limited. Churchill Livingstone.

COMPARATIVE STUDY OF THE THORACIC LIMB SKELETON IN THE LION (PANTHERA LEO) AND IN THE TIGER (PANTHERA TIGRIS)

C. DEZDROBITU, Melania CRIŞAN, Al. GUDEA, A. DAMIAN, Fl. STAN, Ioana CHIRILEAN, Fl. TUNS, Irina IRIMESCU

Faculty of Veterinary Medicine, Cluj-Napoca, 3-5 Calea Mănăştur.

E-mail: cristi_dezdrobitu@yahoo.com

ABSTRACT

Our anatomy study was conducted with the purpose of a comparative description of the bones of the thoracic limb in lions (Phantera Leo) and in tigers (Phantera Tigris). The lion and the tiger are the biggest felines in existence today (Nowak 1991; Sunquist 2002) and they are not a part of the Romanian natural habitat. The material used for this research has been provided by the Turda Zoo, Cluj County, being composed of two lion corpses and two tiger corpses.The anatomical pieces have been prepared at the Comparative Anatomy Laboratory of the Faculty of Veterinary Medicine of Cluj-Napoca. The goal of this study was to record morphologically distinct elements of the forelimb skeleton in the two aforementioned species.The forelimb zonoskeleton, the stylopodium and the zeugopodium are the main regions in which differences between the two species have been detected. We would like to mention that there are no differences between the two species in the autopodium region that would influence the functioning of the musculoskeletal system with regard to arthrology and myology.

INTRODUCTION

This comparative study of the thoracic limb skeleton in the lion and in the tiger aims to complete current available morphological data on felines, through means of a research which will ease the process of identifying the two species based on skeletal characteristics and will also provide correlation between the elements of the bone surface and the muscular mass that inserts itself on them. Specialized data on large felines is virtually nonexistent in our country, due to the fact that these species are not part of the natural Romanian habitat and are present only in national zoological parks.

MATERIAL AND METHODS

The research material, composed of 2 lion corpses and 2 tiger corpses, both males, with an age range from 8 to 10 years, was provided by the Zoo Park of Turda, Cluj County. The osseous pieces have been obtained through the removal of the soft tissues (muscles and ligaments), followed by the isolation of each anatomical region of the thoracic limb. These pieces have been thermically processed by boiling them in a detergent solution with degreasing substances. The thermal processing has been accomplished in several stages. During the first stage, the pieces were boiled for 5 hours, followed by a new mechanical cleaning of the bones. The second stage lasted 3 hours and consisted in boiling the pieces in a solution of surface active agents. According to the degree of clarity of the scoured bone surfaces, the thermal processing was repeated when needed. After these processing stages, the anatomical pieces have forgone a bleaching treatment using bleaching agents.

After this treatment, all the anatomical elements of the surface of the bones have been identified, thus detecting the criteria for the differentiation between the two aforementioned species considered for this study.

RESULTS AND DISCUSSION

The scapular region

The scapula is a flattened triangular bone, representing the anatomical base of the scapular region (the forelimb girdle). It has an oblique position, tilted ventro-laterally to adjust to the oval contour of the thorax. The tiger's scapula has a dorsal border which is convex-concave in the cranio-caudal direction. This constitutes the first difference from the lion's scapula, whose dorsal border is convex on its entire length. The cranial border of the scapula is concave-convex dorso-ventrally in the tiger and fully convex in the lion. Thus the shape of the cranial border of the scapula in tigers is identical to that of the dog, and the same shape found in the lion scapula resembles that of the cat. The thoracic (caudal) border is thick in both species considered for this study and has numerous muscular insertion lines (Fig.1).

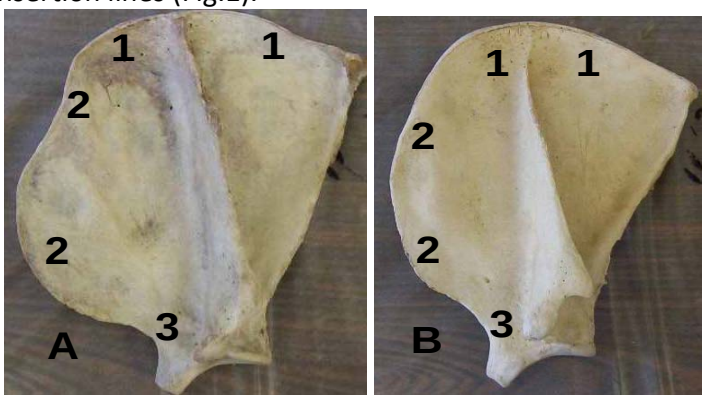

Fig.1.The scapula in tiger (A) and lion (B), lateral view
1- dorsal border; 2- cranial border; 3- scapular notch.

The scapular notch present in the terminal segment of the cranial border is shorter and deeper in the tiger's scapula than in that of the lion's. The scapular spine divides the lateral surface of the scapula in two equal halves, the ratio between the supraspinous fossa and the infraspinous fossa being 1/1 in both species. The tiger's scapular spine has a longer acromion than that of the lion's, but the latter has a better developed processus suprahamatus (paraacromion) than that of the tiger. The costal (medial) surface of the scapula has a subscapular fossa with 2 or 3 muscular insertion lines, which are more prominent in the tiger (Fig.2).

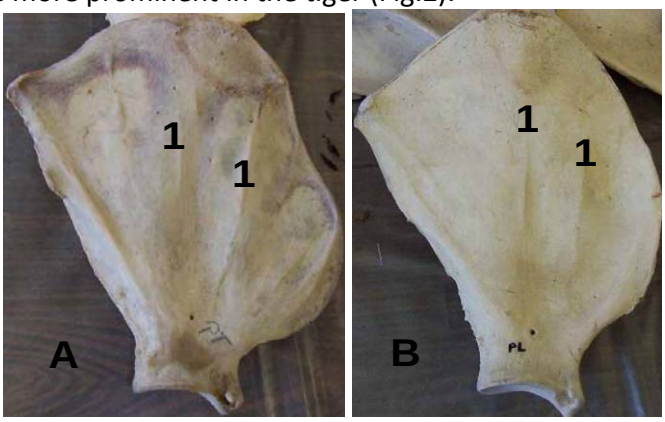

Fig.2.The scapula in tiger (A) and lion (B), medial view
1- muscular insertion lines.

The glenoid cavity is elongated in both species and reaches cranially to the supraglenoid tubercle. An element called coracoid process detaches itself from the supraglenoid tubercle and, in the tiger, tends to form a hole together with the border of the glenoid cavity (Fig.3).



Fig.3.The scapula in tiger (A) and lion (B), articular angle
1- coracoid process.

The arm region

The humerus is the anatomical base of the arm; it is a long bone, placed in a ventro-caudally oblique position at the level of the inferior half of the thoracic cage. The proximal extremity of the humerus is linked to the scapula and is composed of the articular head, the greater tubercle and the lesser tubercle. The humerus of the two feline species is recurved only in the proximal third of its length, the rest of it being straight and cylindrical. On the proximal extremity of the bone, the articular head is convex and the greater tubercle is situated laterally from it in both species, but the latter is bigger in lions. In both species, the lesser tubercle is reduced to a small eminence. The proximal epiphysis presents both in tigers and in lions a well delimited insertion surface for the infraspinatus muscle. In both species the bicipital groove is large and displaced medially (Fig.4).

On the humeral diaphysis there are the deltoid tuberosity and the teres tuberosity, both more prominent in the lion. The humeral crest, on the other hand, is sharper and more prominent in the tiger. The sulcus m. brachialis is almost leveled out, in both species (Fig.4 and Fig.5).

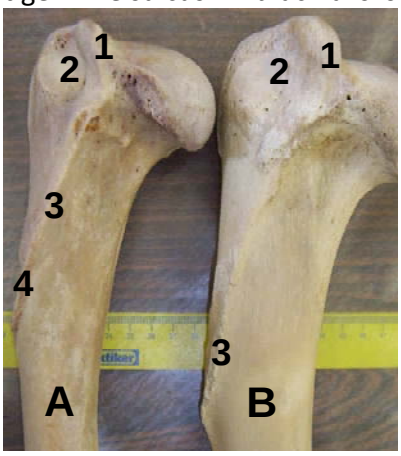

Fig.4.The humerus in tiger (A) and diaphysis lion (B), proximal epiphysis tuberosity.
1- greater tubercle;
2- insertion surface of the infraspinatus muscle;
3- deltoid tuberosity;
4- humeral crest.

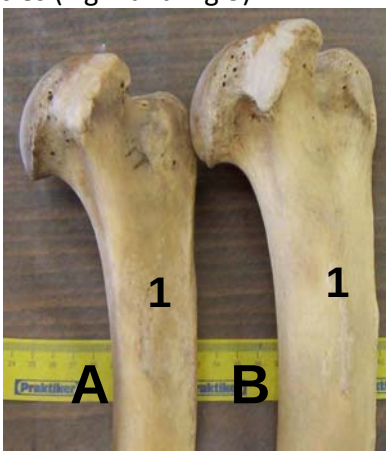

Fig.5.The humerus in tiger (A) and lion (B),
1- teres

The distal epiphysis is characterized by the epitrochlear fossa being situated above the medial epicondyle – an aspect generally seen in felines, in which it serves as a passage for the brachial artery. The epitrochlear fossa has a bigger circumference in lions. Above the trochlea, there is the olecranon fossa which also has a bigger circumference in lions. On the cranial face of the humerus,

the coronoid fossa is reduced in diameter in both lions and tigers. The lateral epicondyle emits a crest which orients itself proximally and caudally limits the groove of the brachial muscle. The crest of the lateral epicondyle is better developed in the tiger than in the lion, but it is sharper and longer in the latter (Fig.6).

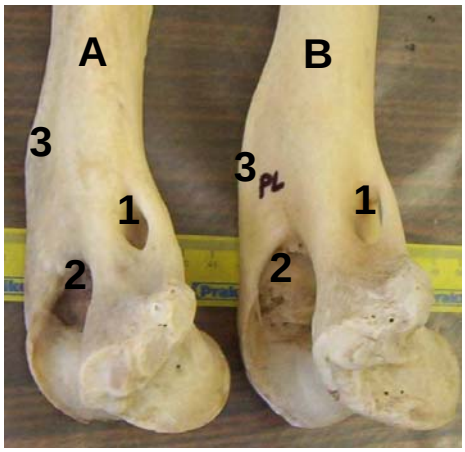

Fig.6.The humerus in tiger (A) and lion (B), distal epiphysis
1- epitrochlear fossa; 2- olecranon fossa; 3- crest of the lateral epicondyle.

The forearm region

The bones of the forearm, the radius and the ulna, show great morphological and functional variation, based on the type of specialization of the thoracic limb. It is a known fact that felines are able to perform supination movements with their thoracic autopodium, but it does not surpass a rotation of 80^0 (Gheție 1971). The capacity of performing supination in the species considered for this study is closely related to their climbing abilities. The proximal epiphysis of the radius is jointed only to the humeral condyle, for which purpose the articular surface is concave and has a circular contour fit for the humeral spherical condyle. The radius is thin in both species. There are no major differences of the proximal extremity between the two. The element which sustains the proximal epiphysis of the radius, the neck, is proportionally longer in the lion. On its medial surface there is the bicipital tuberosity, which is mammillary shaped in tigers and has a larger base in lions. The caudo-lateral crest for the insertion of the interosseous membrane is more prominent with a larger surface in lions. The distal extremity of the radius is voluminous because it is jointed to the carpal bones by means of a rectangular surface in lions, and of an oval surface in tigers, and which in both species reaches to the styloid process (Fig.8). In the lion, the styloid process is better developed and slightly distanced from the main articular surface. In the tiger, because of the presence of prominent crests, the tendinous grooves are very well marked (Fig.7).

Fig.7.The radius in lion (A) and tiger (B), distal epiphysis
1- styloid process;
2- tendinous grooves.

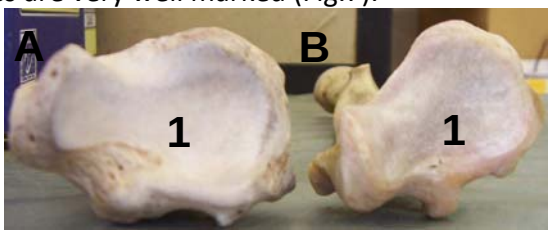

Fig.8.The radius in lion (A) and tiger (B), distal articular surface
1- glenoid cavity.

The ulna is a long bone which forms together with the radius the anatomical base of the forearm. Its proximal extremity presents a cranially drawn olecranon, which, in tigers has an anconeal

process delimited by a sharp crest. The coronoid process is very well developed in both, taking into account their ability to perform supination movements. In the lion, this process is very incurved and tends to form a hole together with the body of the ulna (Fig.9).

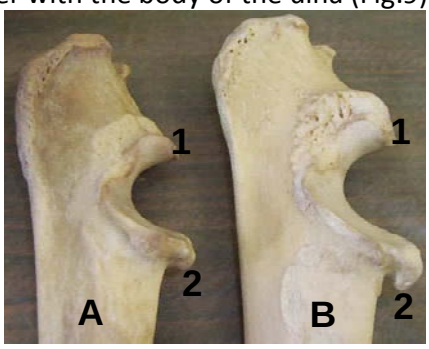

Fig.9.The ulna in tiger (A) and lion (B), proximal epiphysis
1- anconeal process; 2- coronoid process.

At diaphysis level, the caudo-lateral border for the insertion of the interosseous membrane is much more prominent with a wider base in lions.

The distal extremity is thinner in both species and it has a prominent and round styloid process which is bigger in the lion (Fig.10).

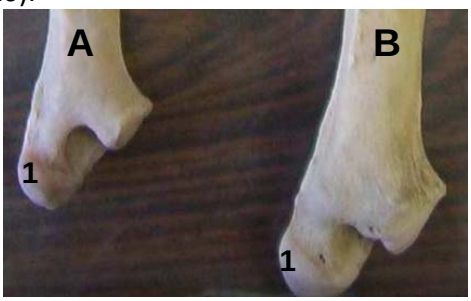

Fig.10.The ulna in tiger (A) and lion (B), distal epiphysis
1- styloid process.

The thoracic autopodium

The thoracic autopodium is composed of the *carpus*, the *metacarpus* and the *phalanges*.

In both species the **carpus** is made up of seven carpal bones, three of them disposed in a proximal row and the other four in a distal one. The order of the carpal bones, in a latero-medial direction, is the following:

Pisiform (*Os pisiforme*) - Triqutral (*os triquetrum*) – Scapholunar (*os scapholunatum*);

Hamate *(os hamatum)* - Capitate (*os capitatum*) - Trapezoid *(os trapezoideum)* - Trapezium (*os trapezium*).

The reduced number of bones in the proximal row is due to the coalescence of the lunate and the scaphoid bones into the scapholunar bone (Fig.11).



Fig.11.The carpus in tiger and lion, dorsal surface (A) and palmar surface (B)

The Metacarpus in both lions and tigers is represented by an anatomical piece made up of five parallel long bones. The first metacarpal bone is very small, and the best developed metacarpal bones are the third and the fourth ones. The body of the metacarpal bones is cylindrical in both

species. The proximal extremities of the second, third and fourth metacarpal bones have lateral eminences which overlap each on the next metacarpal bone. This occurs in both the tiger and the lion and it is also found in the domestic cat (Fig.12).

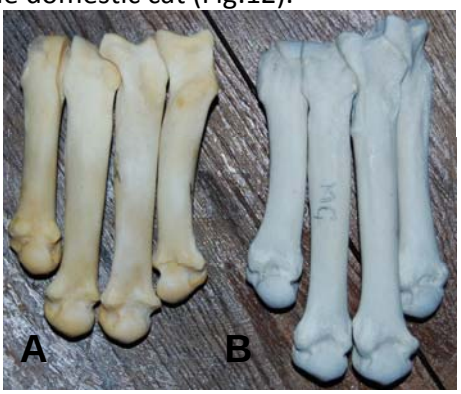

Fig.12.Metacarpal bones of the tiger (A) and of the lion (B)

The phalanges and the large sesamoids are the anatomical support of the fingers. In both of the two feline species, the second, third, fourth and fifth fingers are well developed, having three phalanges each, while the first finger only has tow phalanges, a proximal and a distant one (Fig.13).

Fig.13.Phalanges

CONCLUSIONS

1. The osseous elements of the skeleton of the thoracic limb of the tiger and lion are extremely important to joint function and muscular biodynamic, taking in consideration the natural habitats of these two species.
2. The cranial border of the scapula has a concave-convex shape in the dorso-ventral direction in the tiger, and it is fully convex in the lion. This aspect makes the cranial border of the tiger's scapula resemble that of the dog's and the lion's resemble that of the cat's.
3. The scapular spine has a longer acromion in the tiger than in the lion, but the latter has a better developed processus suprahamatus (paraacromion) than the tiger.
4. In tigers, the coracoid process of the scapula tends to form a hole together with the border of the glenoid cavity.
5. In the lion, the greater tubercle of the humerus is better developed than in the tiger, and in both these species the lesser tubercle is reduced to a mammillary shaped eminence.
6. The surface of insertion for the infraspinatus muscle is well delimited in both the tiger and the lion, a very important aspect for muscular mechanics.

7. The deltoid tuberosity and the teres tuberosity are much more prominent in the lion, but the humeral crest is sharper and more prominent in the tiger.
8. The bicipital tuberosity of the radius is mammillary shaped in the tiger, but has a wider base in the lion.
9. The distal articular surface of the radius is oval in the tiger and rectangular in the lion.
10. The lion has a better developed styloid process of the radius than the tiger, that is also slightly distanced from the main articular surface, and his styloid process of the ulna is also bigger than that of the tiger.
11. The coronoid process is very well developed in both species, which concurs with their ability to make supination movements. In the lion, this process is very incurved and tends to form a hole with the body of the ulna.
12. Both species have a carpus which is composed of seven bones placed on two rows, and five metacarpal bones, the first metacarpal bone being much reduced and the third and the fourth metacarpal bones being the best developed ones.
13. The small sesamoids are missing in both species.

REFERENCES

1. Andersson, K**,** 2004, Elbow-joint morphology as a guide to forearm function and foraging behaviour in mammalian carnivores, *Zool. J. Linn. Soc.* 142, 91 -104.
2. Bertram, J. E. and Biewener, A. A., 1990, Differential scaling of the long bones in the terrestrial Carnivora and other mammals, *J. Morphol.* 204, 157 -169.
3. Christiansen, P., 2007, Distinguishing skulls of lions (Panthera leo) and tigers (Panthera Tigris), Mammalian Biology, Published by Elsevier, doi: 10.1016/j.mambio.2007.08.001.
4. Coţofan, V., R. Palicica, Valentina Hriţcu, V. Enciu, 1999, The Anatomy of the Domestic animals, vol. I, The Musculo-skeletal System, Ed. Orizonturi Universitare, Timişoara.
5. Damian, A., N. Popovici, Ioana Chirilean, 2008, Comparative Anatomy - The Musculo-skeletal system Ed. AcademicPres, Cluj-Napoca.
6. Damian A., Crişan M., Dezdrobitu C., Mateaş C., Tuns F., Pop Al., Comparative study of the forelimb skeleton in camel , cow and mare, Lucrări Ştiinţifice vol. 52(11) Medicină Veterinară Partea I, Ed. „Ion Ionescu de la Brad”, Iaşi, 2009.
7. Gheţie, V., A. Hillebrand, 1971, The Anatomy of the Domestic Animals, vol.I - The Musculo-skeletal System, Ed. Academiei Republicii Socialiste România, Bucharest.
8. Goldfinger Eliot, 2004**,** Animal Anatomy for artists - *The Elements of Form*, Oxford Univ. Press.
9. Gonyea, W.J., 1976c., Functional implications of felid forelimb anatomy, Paleobiology 2, 332-342.
10. Kirberger, R. M., W. M. du Plessis, and P. H. Turner, 2005, Radiologic anatomy of the normal appendicular skeleton of the lion (*Panthera leo*), Part I: thoracic limb, J. Zoo Wildl. Med 36:21-28, BioOne, PubMed.
11. Kirberger, R.M., du Plessis WM, Turner P.H., 2005, Radiologic anatomy of the normal appendicular skeleton of the lion (Panthera leo), Part 2: pelvic limb, J. Zoo Wildl. Med;36:29-35.
12. Nowak, R.M., 1991, Walker’s Mammals of the World, I & II, Johns Hopkins University Press, Baltimore, MD.
13. Smuts, G.L., J.L. Anderson, and J.C. Austin, 1978, Age determination of the African lion (*Panthera leo*), J. Zool. Lond 185:115-146.
14. Sunquist, M., Sunquist, F., 2002, Wild Cats of the World, Univ. of Chicago Press, Chicago, 452pp.
15. Turner, A., 1997, The big cats and their fossil relatives, Columbia University Press, New York.
16. http://www3.interscience.wiley.com/journal/118759676/abstract?CRETRY=1&SRETRY=0.

ANTIOXIDANT ACTIVITY OF WILD PANSY (*VIOLA TRICOLOR*) AND BLESSED THISTLE *(CNICUS BENEDICTUS)* EXTRACTS ON LINOLEIC ACID SISTEM

Corina DURDUN, Maria CRIVINEANU, V. NICORESCU
Faculty of Veterinary Medicine Bucharest, 105 Splaiul Independentei,
050097, Bucharest, Romania, E-Mail: durduncorina@yahoo.com

ABSTRACT

Alcoholic extracts obtained from wild pansy (Viola tricolor) and blessed thistle (Cnicus benedictus) were examined for their total phenolics concentration, flavonoids and antioxidant activity against linoleic acid/water emulsion. Anti-oxidative efficiency to inhibit peroxidation of linoleic acid emulsions was investigated for 7 days at 37°C. The obtained results showed that the alcoholic extracts had a high content of total phenolics and flavonoids. The addition of plant alcoholic extracts to linoleic acid/water emulsion strongly affected hydroperoxides formation and exerted a moderate influence on conjugated dienes and thiobarbituric acid reactive substances development. The results were comparable to those obtained for butylated hydroxyanisole (BHA) synthetic antioxidant.

Key words: polyphenols, flavonoids, hydroperoxides, conjugated dienes, thiobarbituric acid reactive substances.

Free radicals are responsible for the oxidation of biomolecules like proteins, lipids and DNA, causing the death of cells (13). Free radicals are reactive species of oxygen, like superoxide radical (O_2^{-}•), hydroxyl radical (OH•) and peroxide radical (ROO•), which result from usual metabolic processes and have an important role in the initiation of some diseases: atherosclerosis, cancer, cardiovascular diseases (7, 8), neuronal pathologic diseases (4) and the cell aging (2, 8). Human body has different endogenous and exogenous systems to defend against free radicals. There are two main mechanisms for organism defense which involve the action of antioxidant compounds: the first mechanism refers to enzymatic protection (superoxide dismutase – SOD; catalase – CAT, etc.); the second mechanism refers to the action of compounds with antioxidant capacity, like polyphenols, flavonoids, etc (12). Polyphenols are the main compounds found in medicinal plants.
It has been recognized that flavonoids have antioxidant activity and their effects on human nutrition and healthcare are considerable. Action mechanisms of flavonoids are through scavenging or chelating process. Phenolic compounds are a class of antioxidant compounds which acts as free radical terminators.

MATERIALS AND METHODS

Preparation of extracts

In this study there were used dried aerial parts of wild pansy *(Viola tricolor)* and *blessed thistle (Cnicus benedictus)*. The interest parts of plants were powdered and extracted with ethanol 60 % (1:10 ratio, w:v) for 3 hours at 60ºC. The homogenates obtained were filtered using filter paper Watman no. 1. The filtrates were centrifuged for 20 min at 5000 rpm and 5ºC and the crude extracts were used for further investigation.

Determination of total phenolic compounds

Total polyphenols from *Viola tricolor* and *Cnicus benedictus* ethanolic extracts were determined with Folin-Ciocalteu reagent using caffeic acid as standard (3, 10). From the stock solution of the extract, suitable quantity was taken into a 10 mL volumetric flask and properly diluted. Then there were added 0.2 mL FolinCiocalteu reagent and 0.5 mL of 20 % (w/v) Na_2CO_3 solution, respectively. The solution was shaken and then water was added to 10 mL. The reaction mixture was left for color development for 1 hour and the absorbance was measured at 725 nm using an UV-VIS Jasco spectrophotometer V670. The total phenols content was expressed as mg caffeic acid equivalent/g of dry plant material.

Determination of total flavonoid content

Total alcoholic soluble flavonoid content of the extracts was determined by a colorimetric assay described by Jay et al. (5). The method is based on the interaction of flavonoids from ethanolic extracts with $AlCl_3$ reagent, resulting a colored compound. An aliquot of 5 mL of diluted plant extract, 2.5 mL of $AlCl_3$ reagent were added and absorbances were recorded at 430 nm against blank (5 mL of analyzed solution and 2.5 mL of extracting solvent) using an UV-VIS Jascospectrophotometer V670. The flavonoids contents were determined as µg quercetin equivalent/g of dry plant material.

Preparation of model system: linoleic acid emulsion

Linoleic acid emulsions were prepared by mixing 0.285 g of linoleic acid, 0.289 g of Tween 20 as emulsifier and 50 mL phosphate buffer (0.067 M; pH 7.2). The mixture was homogenized for 5 min., according to Yen et al. (11).The plants extracts properly diluted were added to linoleic acid emulsion. Butylated hydroxyanisole (BHA) 0.1 g L^{-1} was used as a control. The mixture was incubated in an oven at 37°C for 168 h. The course of oxidation was monitored by measuring conjugated dienes (CD) formation, peroxide value (PV) and thiobarbituric acid reactive substances (TBARS).

Determination of conjugated dienes formation (CD)

Aliquots of 0.02 g of linoleic acid emulsion treated with alcoholic extracts and BHA were taken at intervals of 4, 22, 48, 72, 96 and 168 h during incubation and 2 mL of isooctane were added (6). Then, the absorbance of mixtures was measured at 233 nm in an UV-VIS Jasco spectrophotometer V670. The inhibition percentage of conjugated dienes formation were calculated through Eq.(1):

$$\% \text{ Inhibition} = \frac{A_{blank} - A_{sample}}{A_{blank}} \times 100 \qquad (1)$$

Determination of peroxide values (PV)

The FTC (ferric thiocyanate) method was adapted after the method described by Romero et al. (9). 0.02 g of samples were dissolved in methanol:chloroform (30:70, v/v) solution and 300 g L^{-1} ammonium thiocyanate was added and mixed. After five minutes, ferrous chloride was added to the reaction mixture and the absorbance of the resulting red color was measured at 501 nm in a UV-VIS Jasco spectrophotometer V670 against a mixture of methanol:chloroform (30:70,v/v) solution as blank. The inhibition percentage of peroxides formation was calculated through Eq. (1).

Determination of thiobarbituric acid reactive substances (TBARS)

A modified thiobarbituric acid reactive substances (TBARS) method was used to measure antioxidant activity of alcoholic extracts in terms of inhibition on lipid peroxidation (1). 100 mg of sample from linoleic acid emulsion were taken, and the following were sequentially added: thiobarbituric acid (TBA) /trichloroacetic acid (TCA) solution (20 mM TBA in 150 g L^{-1} TCA). The mixture was heated in a 90°C water bath and cooled at room temperature. Afterwards, chloroform was added. The mixture was mixed and centrifuged. The chloroform layer was separated and the absorbance of the supernatant was measured at 532 nm in a UV-VIS Jasco spectrophotometer

V670 against a blank containing H_2O and TBA/TCA solution. The inhibition percentage of TBARS formation were calculated through Eq.(1).

RESULTS AND DISCUSSION

Flavonoid and total phenol contents of the extracts

Total phenols content was measured by Folin-Ciocalteu reagent in terms of caffeic acid equivalent. *Cnicus benedictus* ethanolic extract contained 7.83 ± 0.78 mg/g polyphenols, while the other investigated extract, *Viola tricolor,* presented 14.54 ± 2.57 mg/g polyphenols (table 1). The flavonoid content of extracts calculated as quercitin equivalent/g dried plant were 578.5 ± 37.12 µg for *Cnicus benedictus* and 1212.5 ± 101 µg for *Viola tricolor* (table 1).

Table 1

Phenolic and flavonoid contents of alcoholic extracts obtained from studied plants

Sample	***Phenolics content (mg equivalent caffeic acid/g dried plant)***	***Flavonoid Content (µg equivalent quercitin/g dried plant)***
Viola tricolor	14.54 ± 2.57	1212.5 ± 101
Cnicus benedictus	7.83 ± 0.78	578.5 ± 37.12

Antioxidant activity of alcoholic extracts

Initiation of lipid peroxidation is caused by attack of any species that has sufficient reactivity to abstract a hydrogen atom from a methylene group upon a polyunsaturated fatty acid (PUFA) (6). Since a hydrogen atom in principle is a free radical with a single unpaired electron, its removal leaves behind an unpaired electron on the carbon atom which it was originally attached. The carbon-centered radical is stabilized by a molecular rearrangement to form a conjugated diene, followed by reaction with oxygen to give a peroxyl radical. Peroxyl radicals are capable of abstracting a hydrogen atom from another adjacent fatty acid side-chain to form a lipid hydroperoxide, but can also combine with each other or attack membrane proteins.

The total antioxidant activity was used to estimate the peroxide level during the initial stages of lipid oxidation. This might be due to the reduction of peroxide, inactivation of free radicals or complexion with metal ions, or combinations thereof. Antioxidant activity of *Viola tricolor* and *Cnicus benedictus* may be attributed to the reduction of peroxides and to the inhibition of CD and TBARS formation.

Inhibition of conjugated dienes formation

Conjugated dienes are the first peroxidation products. The formation of conjugated dienes of linoleic acid occurs when free radicals attack the hydrogens of methylene groups separating double bonds and leading to rearrangement of the bonds. *Cnicus benedictus* alcoholic extracts presented a higher inhibition of the formation of conjugate dienes comparing with the standard BHA (Fig. 1). In the same time, *Viola tricolor* alcoholic extract presented less inhibition for CD comparative with BHA standard (Fig. 1). The obtained results demonstrate that *Viola tricolor* alcoholic extract inhibit the formation of conjugated dienes during incubation at 37°C for 168 hours in a manner similar to BHA synthetic antioxidant.

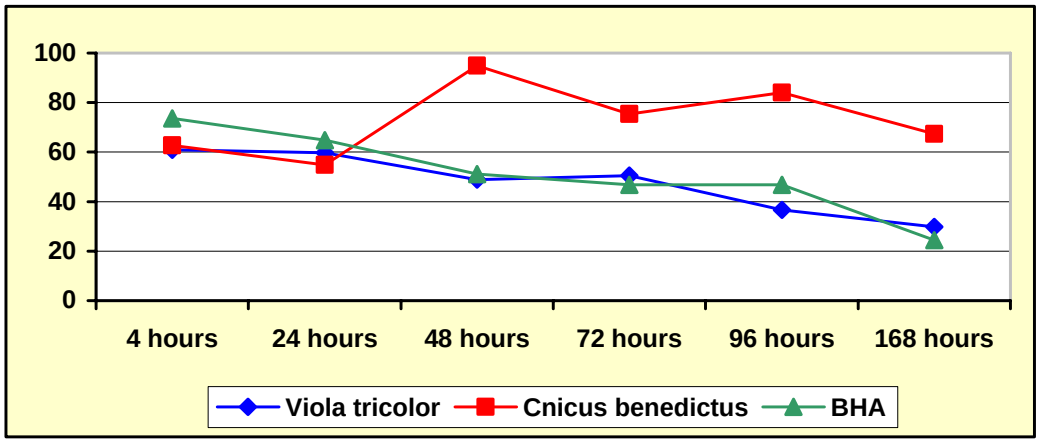

Fig. 1. Inhibitory effect of plant alcoholic extracts on conjugated dienes formation in linoleic acid model

Inhibition of hydroperoxides formation

Hydroperoxides are fairly stable molecules, but their decomposition can be stimulated by high temperatures or by exposure to transitional metal ions (iron and copper ions). In Fig. 2 it can be noticed that *Cnicus benedictus* and *Viola tricolor* alcoholic extracts presented an inhibitory effect upon hydroperoxides formation process. For *Viola tricolor* alcoholic extract and BHA, the maximum inhibitory effect was recorded after 4 hours of incubation at 37°C. Maximum inhibitory effect for *Cnicus benedictus* alcoholic extract was recorded after 96 hour of incubation at 37°C. After this interval, for the two tested plants it was recorded an intense decrease of the protective effect against lipid peroxidation process.

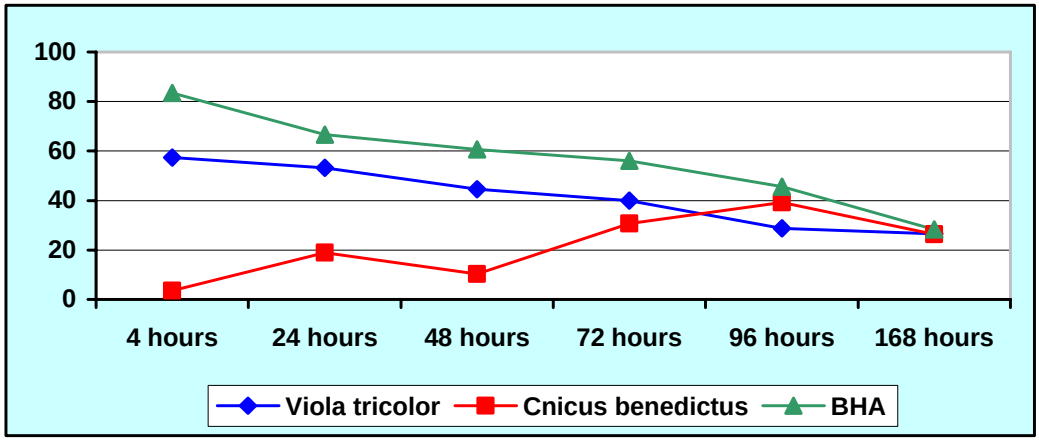

Fig. 2. Inhibitory effect of plant alcoholic extracts on hydroperoxides formation in linoleic acid model

Inhibition of thiobarbituric acid reactive substances (TBARS) formation

Decomposition of hydroperoxides generates a complex mixture of secondary lipid peroxidation products such as hydrocarbon gases (e.g. ethane and penthane) and aldehydes (e.g. malondialdehyde (MDA) and 4-hydroxynonenal). Linoleic acid peroxides generate a great number of carbonyl compounds upon decomposition. These compounds are secondary products of lipid peroxidation and in reaction with 2-thiobarbituric acid are widely used as a measure of rancidity

development. The inhibitory effect of *Cnicus benedictus* and *Viola tricolor* alcoholic extracts upon peroxidation of linoleic acid emulsion, comparative to BHA, is presented in Fig. 3. *Viola tricolor* alcoholic extract protected linoleic acid against peroxidation process in a manner superior to BHA synthetic antioxidant for 72 hour of incubation. The most pronounced inhibitory effect for *Cnicus benedictus* alcoholic extract was recorded after 48 hours of incubation at 37°C, after that interval being observed an accentuated decrease. After 96 hours of incubation, the inhibitory effect upon linoleic acid peroxidation process slightly increased for *Cnicus benedictus* alcoholic extract.

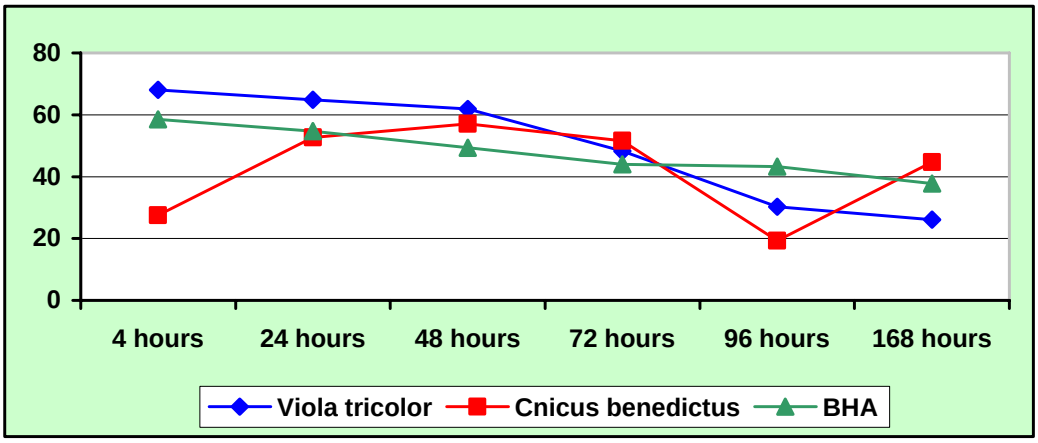

Fig. 3. Inhibitory effect of plant alcoholic extracts on thiobarbituric acid reactive substances (TBARS) formation in linoleic acid model

CONCLUSIONS

1. *Cnicus benedictus* alcoholic extract inhibited the formation of conjugated dienes better than BHA synthetic antioxidant.
2. *Cnicus benedictus* and *Viola tricolor* alcoholic extracts showed protective effect on hydroperoxides and thiobarbituric acid reactive substances (TBARS) formation in linoleic acid model.
3. *Cnicus benedictus* and *Viola tricolor* alcoholic extracts are able to protect linoleic acid against lipid peroxidation process.

ACKNOWLEDGEMENTS

This work was supported by CNCSIS –UEFISCSU, PNII – IDEI program, project number ID_1304/2009.

REFERENCES

1. Ahn D.U., Kim S.M. - Prooxidant effects of ferrous iron, hemoglobin, and ferritin in oil emulsion and cooked meat homogenates are different from those in raw meat homogenates. *Poult Sci*. 77, 348-355, 1998.
2. Albu M.G., Ghica M.V., Giurginca M., Trandafir V. - Spectral characteristics and antioxidant properties of tannic acid immobilized on collagen drug-delivery systems. *Rev. Chim. (Bucureşti)*, 60**,** nr. 7, p. 666, 2009.

3. Conrad A., Birch M., Dacombe C., Humphrey P.G., Martin P.T. - Factors affecting the caffeine and polyphenol contents of black and green tea infustions, *Journal of Agricultural and Food Chemistry*, 49, 5340 – 5347, 2001.
4. Garcia-Alonso M., De Pascual Sonia, Santos-Buelga C., Rivas-Gonzalo J.C. - Evaluation of the antioxidant properties of fruits. *Food Chemistry,* 84, p: 13-18, 2004.
5. Jay M., Gonnet J.F. - Premieres observations relatives a la variation dans l'expression du metabolisme flavonique chex le *Phragmites australis*. *Phytochemistry*, 14, 1605–1612, 1975.
6. Papuc C., Diaconescu C., Nicorescu V., Crivineanu C. - Antioxidant activity of polyphenols from Sea buckthorn fruits (*Hippophae rhamnoides*). *Rev.Chim. Bucureşti*, vol. 59, nr. 4, pp. 392-394, 2008.
7. Pop M., Lupea A. X., Turcus V. - Studies on the pholyphenolics compounds extraction from *Vaccinium* fruits. *Rev. Chim. (Bucureşti)*, 59, nr. 5, 2008, p. 491.
8. Rao Y. K., Madamanchi G., Shih-Hua F., Yeu-Min T. - *Antioxidant and cytotoxic activities of naturally occuring phenolic and related compounds: A comparative study*. *Food and Chemical Toxicology,* 45, p:1770-1776, 2007.
9. Romero A.M., Doval M.M., Romero M.C., Sturla M.A., Judisl M.A. - Antioxidant properties of soya sprout hydrophilic extract. Application to cooked chicken patties, *EJEAFChem., 7(8),* pp. 3196-3206*,* 2008.
10. Wollgast J. - The contents and effects of polyphenols in chocolate, qualitative and quantitative analys of polyphenols in chocolate and chocolate raw products as well as evaluation of potential implications of chocolate consumption in human health, Doctoral thesis, Jutus Liebig University of Giessen, Germany, 2004.
11. Yen G., Chang Y., Su S. - Antioxidant activity and active compounds of rice koji fermented with *Aspergillus candidus*. *Food Chemistry,* 83, pp. 49-54, 2003.
12. Yoo K. M., Choong H. L., Hyungjae L., BoKyung M., Chang Y. L. - Relative antioxidant and cytoprotective activities of common herbs. *Food Chemistry,* 106, p: 929-936, 2008.
13. Zhang H., Feng C., Xi W.., Hui-Yuan Y. - Evaluation of antioxidant activity of parsley (*Petroselinum crispum*) essential oil and identification of its antioxidant constituents. *Food Research International*, 39, p.833-839, 2006.

ORGANOGENESIS OF THE HARDERIAN GLAND IN RABBITS (*ORYCTOLAGUS CUNICULUS*)

Elena Cătălina FLOREA, C. V. COTEA, Carmen SOLCAN
FMV Iaşi

ABSTRACT

Within the Harderian gland in adult rabbits, two lobes are described, a white lobe and a pink lobe. The present research was undertaken in order to elucidate the organogenesis of this gland. The fetuses, aged 16, 20, 24 and 28 days, were harvested from two or three does for each of the four stages of pregnancy (11 does), by hysterectomy or cesarean section surgery. Their number ranged from 4 to 9 in each female. The samples obtained from every fetus were led up to paraffin, serially sectioned (frontally) at 5 µm and stained through the following methods: HEA, PAS, Novelli, Alcian blue and Papanicolau. The Harderian gland appears in the shape of cell cords originating from ectoderm. The cords are structured from 20 to 32 cells in fetuses aged 20 days and their number considerably increases at the age of 24 days. In fetuses aged 28 days, globular formations that will become the future glandular acini, appear at the distal end of the cords. In the late stages of pregnancy, at the age of 28 days, early glandular formations occur in fetuses both in the white lobe, and in the pink lobe. Thus, this research demonstrates for the first time the organogenesis of the Harderian gland in rabbits.

Key words: Harderian gland, organogenesis, rabbit.

In adult rabbit, the Harderian gland is a large organ placed in the rear-medial portion of the lower orbit, in direct contact with the eyeball, attached to the base of the third eyelid. It presents two well differentiated lobes (a pink one - ventral and a white one - dorsal), covering about half of the medial surface of the eyeball, to the deep cartilaginous skeleton of the third eyelid, eliminating its secretion through an intrinsic duct into the conjunctival sac of the third eyelid and accessory gland. The capsule is covered by a delicate connective tissue and almost completely surrounded by the venous sinus. (2, 7, 9) The histological structure of the Harderian gland in rabbits is a tubuloalveolar compound. The glandular formations of the white lobe are structured by a high prismatic epithelium with small lipid droplets, while in the pink lobe, the secretor units consist of an epithelium with low prismatic cells, the cytoplasm containing much bigger lipid droplets. (3, 4, 5, 6) The organogenesis of this gland has been studied in very few species and there is no data in the literature about its development in rabbits, which is why this study has been undertaken. (1, 8, 10)

MATERIAL AND METHOD

The samples were obtained from 67 rabbit fetuses, from 11 does on 16, 20, 24 and 28 days of pregnancy (fig. 1, 2, 3, 4). Fetuses aged 16 and 20 days were harvested by hysterectomy, and those aged 24 and 28 days by caesarean section. For the paraffin embedding, the heads of 24 and 28 days fetuses were cut mediosagital (hemisected) and from the fetuses of 16 and 20 days were embedded entirely. The 5 µm thick serial sections were taken starting with the frontal area and colored using the following methods: HEA, PAS, Novelli, Alcian blue and Papanicolau.

RESULTS AND DISCUSSIONS

In fetuses aged 16 days the formation of the eyeball (fig. 5) and the completion of retinal layers were revealed, remarking the pigment layer structured of melanoblasts (fig. 6, 7, 8). At this stage of pregnancy, in fetuses, the third eyelid has not yet been formed. In fetuses aged 20 days it was observed the initiation of the organization of the third eyelid and at the base of its cartilage the appearance of the cell cords, made of 20-32 cells that will structure the future Harderian gland (fig.9, 10, 11). Early organization of secretory formations occurs at the distal end of the cell cords at the base of the hyaline cartilage. At this stage of gestation, the retina is fully formed (fig.12).

In fetuses aged 24 days, cell cords are structured by a large number of cells. Primary acinar formations are more numerous and begin to associate in order to form glandular lobules (fig.13, 14). In some histological sections, it can be observed the attachment of the forming glandular tissue to the base of the hyaline cartilage of the third eyelid and the start of capsular organization (fig.15, 16). In fetuses aged 28 days, Harderian gland's formation is not yet completed. It can be noticed the grouping of the glandular acinar formations in lobules separated by conjunctive tissue, but the two lobes (the white and the pink one) cannot be yet differentiated (fig.19). The glandular tissue is attached by a delicate connective tissue to the base of the hyaline cartilage of the third eyelid (fig.17, 18). At its free portion it can be distinguished mucous glands in lamina propria (fig.20). In the prenatal stage, the gland does not show cytological and cytochemical characters in order to launch a specific discharge.

Fig.1 Rabbit fetuses – 16 days

Fig.2 Rabbit fetuses – 20 days

Fig.3 Rabbit fetuses – 24 days

Fig.4 Rabbit fetuses – 28 days

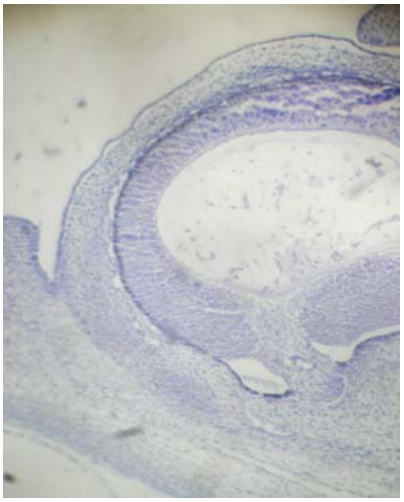

Fig.5 Rabbit fetus – 16 days.
Formation of the right eyeball.
Col. HEA, X60

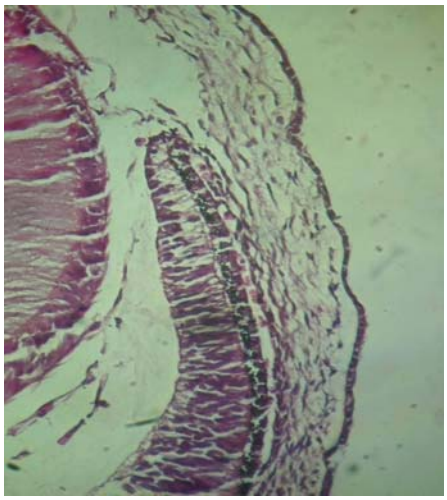

Fig.6 Rabbit fetus – 16 days.
Cytogenesis of the retinal layers, emphasizing the one with pigment cells containing melanoblasts.
Col. PAS, X100

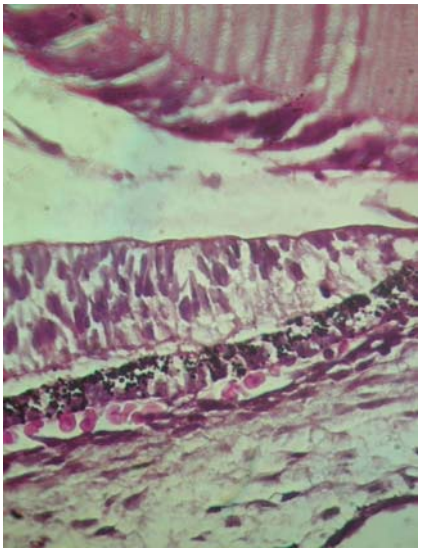

Fig.7 Rabbit fetus – 16 days.
Cytogenesis of the retinal layers, emphasizing the one with pigment cells containing melanoblasts.
Col. PAS, X400

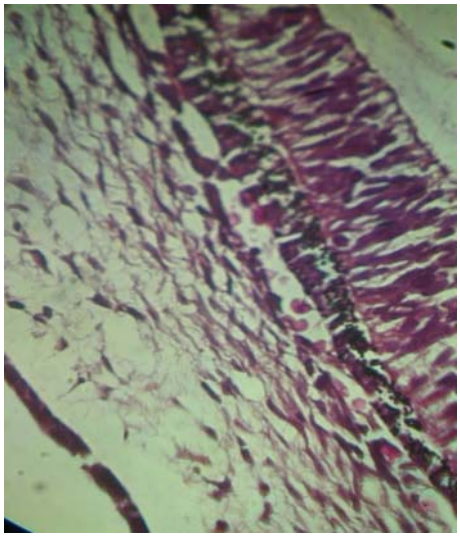

Fig.8 Rabbit fetus – 16 days.
Cytogenesis of the retinal layers, emphasizing the one with pigment cells containing melanoblasts.
Col. PAS, X400

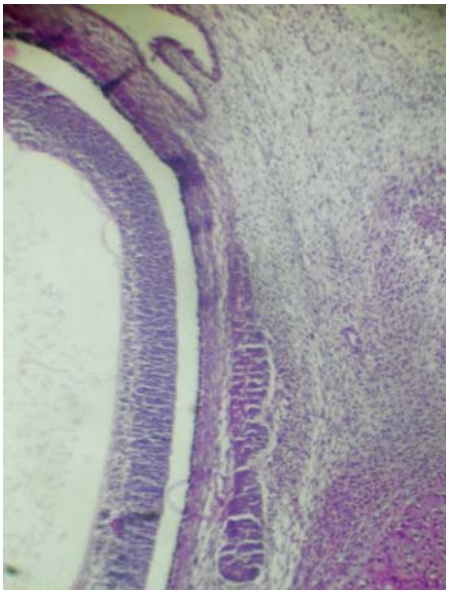

Fig.9 Rabbit fetus – 20 days. Organogenesis of the third eyelid and the appearance of the cell cords at its base, that will structure the future Harderian gland. Col. PAS, X60

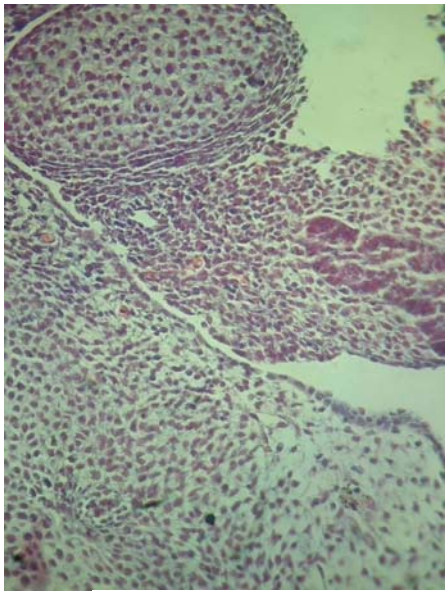

Fig.10 Rabbit fetus – 20 days. Cell cords at the base of the third eyelid. Col. PAS, X100

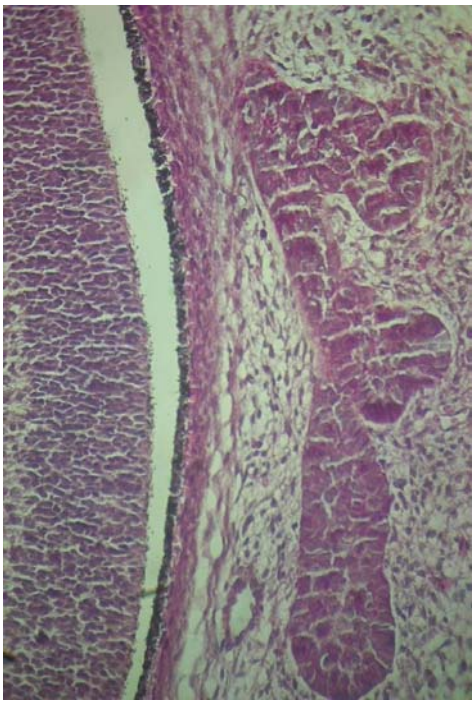

Fig.11 Rabbit fetus – 20 days. Early organization of secretory formations at the distal end of the cell cords at the base of the hyaline cartilage. Col. PAS, X200

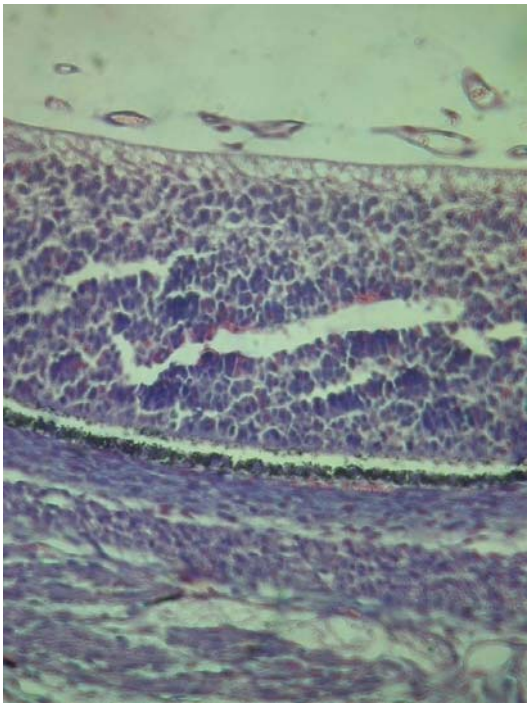

Fig.12 Rabbit fetus – 20 days. The structuring of the retina in the eyeball.

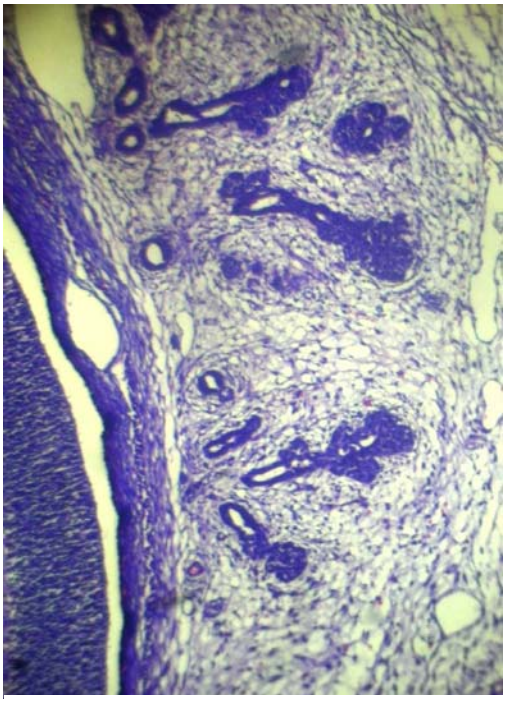

Fig.13 Rabbit fetus – 24 days. Primary acinar formations of the Harderian gland. Col. Novelli, X100

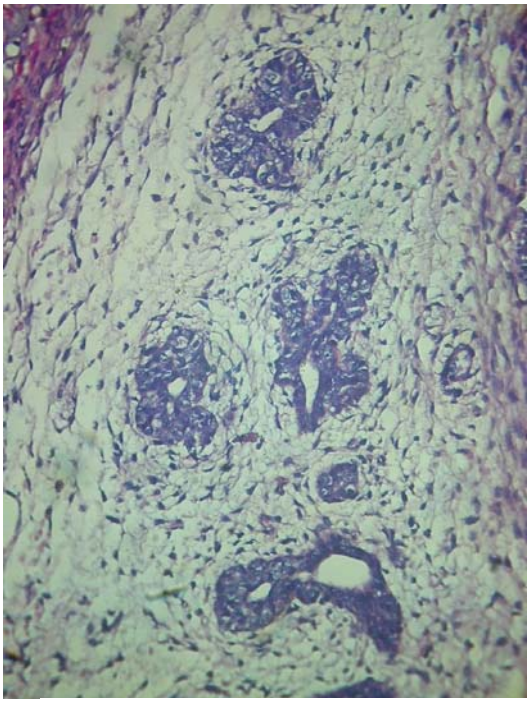

Fig.14 Rabbit fetus – 24 days. Primary acinar formations of the Harderian gland. Col. HEA, X200

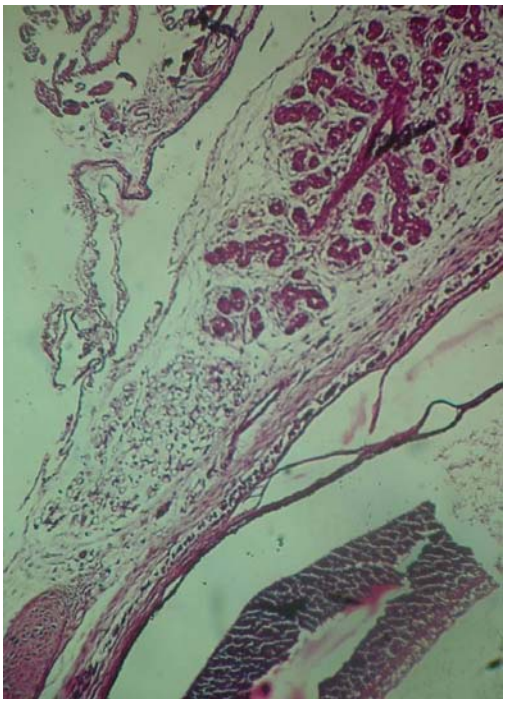

Fig.15 Rabbit fetus – 24 days. Primary acinar formations at the base of third eyelid hyaline cartilage.
Col. PAS, X60

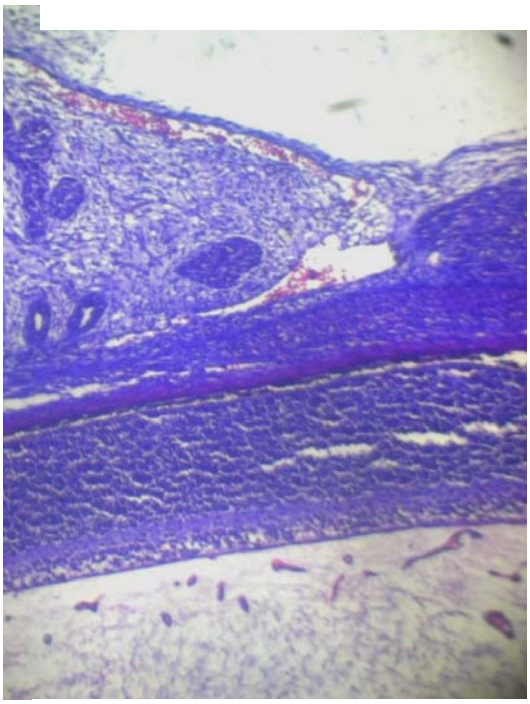

Fig.16 Rabbit fetus – 24 days. Primary acinar formations at the base of third eyelid hyaline cartilage.
Col. Novelli, X100

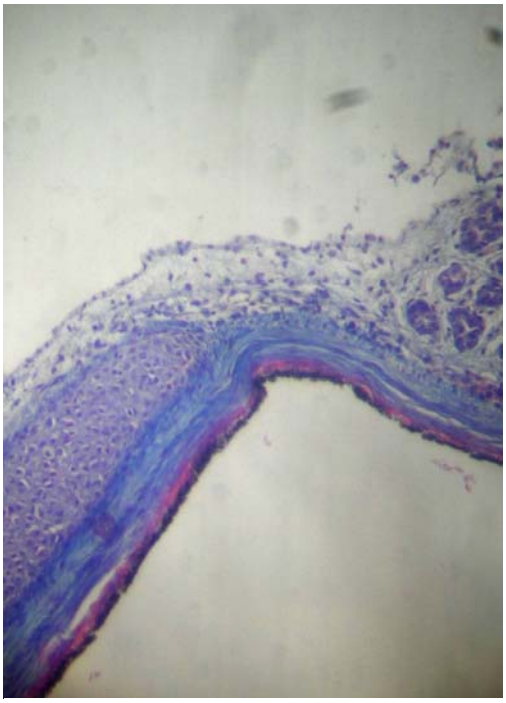

Fig.17 Rabbit fetus – 28 days. Glandular acinar formations at the base of third eyelid hyaline cartilage. Col. HEA, X60

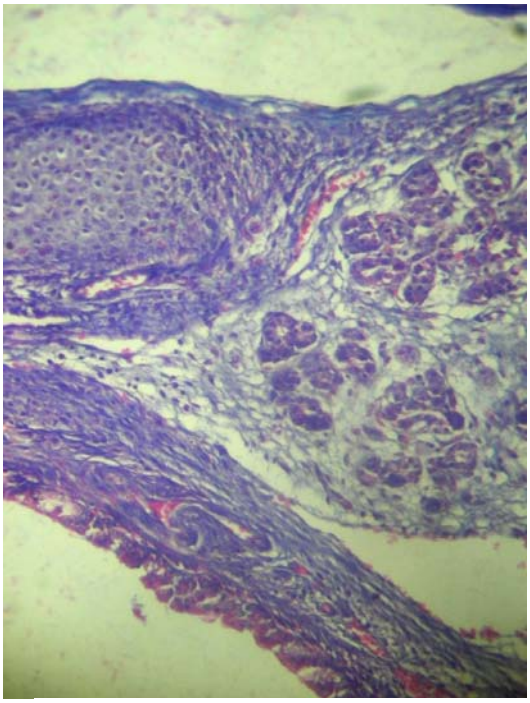

Fig.18 Rabbit fetus – 28 days. Glandular acinar formations at the base of third eyelid hyaline cartilage. Col. HEA, X100

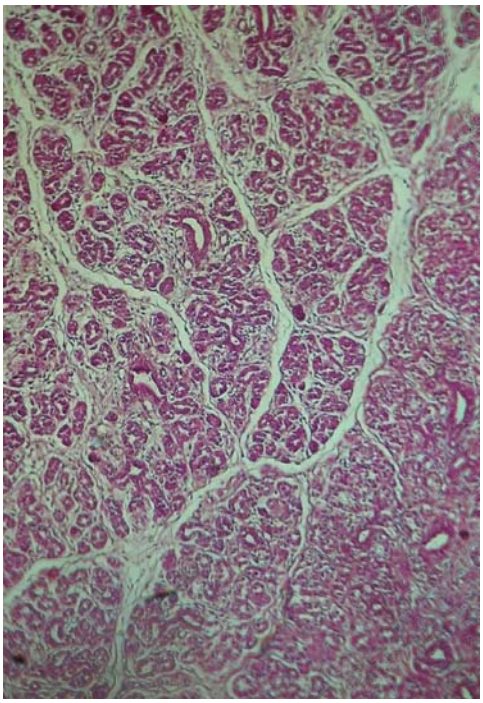

Fig.19 Rabbit fetus – 28 days. Grouping of the glandular acinar formations in glandular lobules. Col. PAS, X100

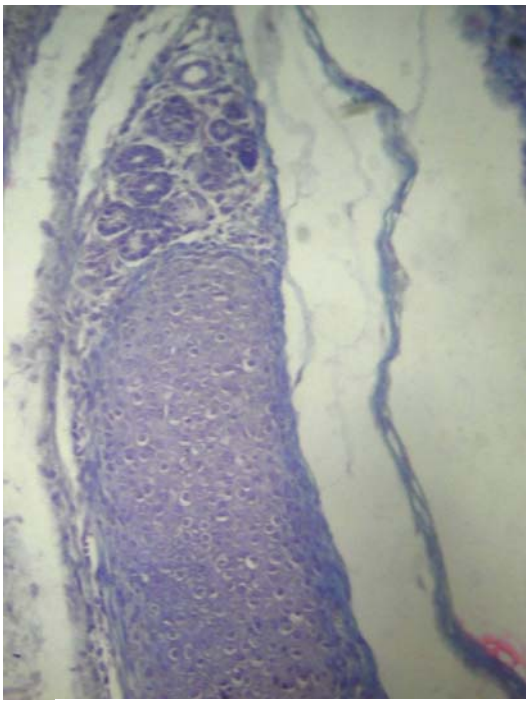

Fig.20 Rabbit fetus – 28 days. The cartilage of the third eyelid, the free portion, where we can see in lamina propria the presence of mucous glands. Col. HEA, X100

CONCLUSIONS

1. In fetuses aged 16 days is not yet initiated the organization of the third eyelid, with its deep gland.
2. In fetuses aged 20 days it was noticed the organization of the third eyelid and at the base of its cartilage the appearance of the cell cords, made of 20-32 cells that will structure the future Harderian gland.
3. Early organization of secretory formations occurs at the distal end of the cell cords at the base of the hyaline cartilage.
4. In fetuses aged 24 days, cell cords are structured by a large number of cells. Primary acinar formations are more numerous and begin to associate in order to form the glandular lobules and at this phase the capsule begins its organization.
5. In fetuses aged 28 days it was emphasized the grouping of the glandular acinar formations in glandular lobules separated by connective tissue, but the two lobes (the white and the pink one) cannot yet be differentiated.
6. The Harderian gland is attached by a delicate connective tissue at the base of the hyaline cartilage of the third eyelid.

BIBLIOGRAPHY

1. **Chieffi G**. – Organogenesis of the Harderian Gland: a comparative survey, Microscopy research and technique, 1996.
2. **Cotea C.** – Histologie specială, Ed. Tehnopress, Iaşi, 2008.
3. **Florea Elena Cătălina, Cotea C., Solcan Carmen** – Citochimia lobului roz al glandei Harder la iepurele de casă (Oryctolagus cuniculus), Lucrări ştiinţifice, Vol.51(10), Medicină Veterinară, Partea I, pg. 69-73, Ed. "Ion Ionescu de la Brad", Iaşi, 2008.
4. **Florea Elena Cătălina, Cotea C., Solcan Carmen** – Contribuţii la morfologia lobului alb al glandei Harder la iepurele de casă (Oryctolagus cuniculus), Lucrări ştiinţifice, Vol.51(10), Medicină Veterinară, Partea I, pg. 64-68, Ed. "Ion Ionescu de la Brad", Iaşi, 2008.
5. **Florea Elena Cătălina, Cotea C., Solcan Carmen** – Ultrastructura lobului alb al glandei Harder la iepurele de casă (Oryctolagus cuniculus), Lucrări ştiinţifice, Vol.52(11), Medicină Veterinară, Partea I, pg. 179-187, Ed. "Ion Ionescu de la Brad", Iaşi, 2009.
6. **Florea Elena Cătălina, Cotea C., Solcan Carmen** – Aspecte electron-optice în lobul roz al glandei Harder la iepurele de casă (Oryctolagus cuniculus), Lucrări ştiinţifice, Vol.52(11), Medicină Veterinară, Partea I, pg. 171-178, Ed. "Ion Ionescu de la Brad", Iaşi, 2009.
7. **Hillenius W.J., Phillips D.A., Rehorek J. Susan** – A new lacrimal gland with an excretory duct in red and fallow deer by Johann Jacob Harder (1694): English translation and historical perspective, Annals of Anatomy, Elsevier, 2006.
8. **Mukai H.** – Uber die feinere Struktur der Harderschen Drüse beim Kaninchen, Graefe's Archive for clinical and experimental ophthalmology 117, Springer Berlin, 1926.
9. **Payne A.P.** – The Harderian gland: a tercentennial review, Journal of Anatomy, 1994.
10. **Rehorek Susan J., Hillenius W.J., Sanjur J., Chapman N.G.** – One gland, two lobes: Organogenesis of the „Harderian" and „nictitans" glands of the Chinese muntjac (Muntiacus reevesi) and the fallow deer (Dama dama), Annals of Anatomy 189, 434-446, 2007.

RESEARCH ON THE MORPHOLOGY OF THE CAROTID ARTERY AT GOAT (CAPRA HIRCUS)

B. GEORGESCU, G. PREDOI, C. BELU, N. CORNILĂ,
I. DUMITRESCU, Petronela ROŞU, Carmen BIȚOIU, Anca ŞEICARU

Facultatea de Medicină Veterinară Bucureşti
georgescubogdi@gmail.com
Splaiul Independentei, nr. 105, sector 5

SUMMARY

The research was conducted on 10 samples of goats. We described the common carotid artery collaterals and we noted all the features observed. As in other species common carotid arteries come off from the common trunk. In the goat the origin is characterized by an obvious symmetry. Common carotid artery collaterals are numerous and some (muscular branches) are not constant. Common carotid artery has muscular, esophageal and tracheal branches. In 90% from cases the esophageal and tracheal branches are detached from a common trunk. Caudal thyroid artery is short and can arise from the cranial thyroid artery in 5% of cases. The laryngeal cranial artery is constantly a collateral from common carotid artery. In the top of paracondylar process, the common carotid artery is divide in external carotid and occipital arteries.

Key words: dissection, carotid artery, sheep.

Small ruminants are an excellent biological material for experiments and research in biology and medicine compared. In the literature are studies on little ruminants common carotid artery terminals (1,5,8, 9,10) but are less investigated the collaterals of this artery. Also there is relatively little information on the structure of the vessel (2,5). Our investigations have considered the collaterals of carotid artery, complementing existing data (3,4,6,7).

MATERIALS AND METHODS

The dissection was realized on ten adult goat. The skin was carefully, with a view to notice the relationships of all superficial anatomical formations with carotid artery. In order to identify the collateral branches of the carotid artery common, it was injected with contrast agent (AGO). Dissection was realized using stereomicroscope SMZ 2T-Nikon, taking photographs of the most important aspects. Histological preparations were made using traditional methods of fixing and staining. The following stains were used: Hematoxiline-Eosine and Orceine. The identification, description and homologation of the anatomical formations was made according to Nomina Anatomica Veterinaria -2005 and Nomina Histologica -1992.

RESULTS AND DISCUSSIONS

Designed primarily for irrigation of head regions, secondarily to some formations of the ventral neck, the common carotid artery takes shape from the bicarotic trunk of the cranial thoracic aperture and has an average diameter of 4-5 mm. Like on other species where the common

carotid arteries exits about the common core (equine, cattle), at goats the origin is characterized by an obvious symmetry. The two arteries are satellites of the trachea, initially placed on its ventral side, with an upward trajectory on both sides and then back up latero-dorsal through the throat region where it ends in the paracondilar process. The artery is located in a dorsal plan from the sternocefalic muscle and right under the wing of the atlas, where, in case of surgery, the access to the common carotid artery is possible through an incision in the jugular gutter parallel with the ventral margin of the brachiocefalic muscle. The whole trajectory of the cervical carotid artery is surrounded by a doubled pretracheal blade of the cervical fascia, that forms the carotid sheath. It is attended dorsal by the vagosimpatic nerve. The goat, like the other ungulates, the cervical connective is attached to the dorsal margin of the vagal nerve. In a ventral side of the common carotid the laringial nerve is found (recurrent) and the tracheal conduct. Sometimes on the trajectory of the common carotid artery common can be highlighted cervical lymph nodes. On the anterior third cervical region the common carotid artery is covered laterally by omohioidian muscle, pale, which cuts the jugular vein and on the caudal third part has connections with scalene muscle. The left common carotid artery has connections with the esophagus, and flanks it from a ventro-lateral plan. The common carotid artery collaterals are numerous and some (muscular branches) are not constantly topographic. Muscular branches, known in the special literature as the sterno-cleido-mastoidian branches are detached separately from 5 to 5 cm in the two caudal thirds of the neck. In turn they give back dorsal branches for the cleidocefalic muscle and ventral branches for the sternocefalic muscle. The common carotid artery, in the middle third, sends a branch with a retrograde trajectory that after about 6 cm reaches the posterior pole of the thyroid gland, being anastomosed with the caudal thyroid artery branches. From this artery, two dorsal esophageal branches and 2-3 ventral tracheal branches emerge. In 10% of cases this artery may be missing. The caudal thyroid artery, short (about 1 cm) penetrates directly into the gland's parenchyma, sending a tracheal branch distributed to the rings from 5 to 7. In 5% of cases, the caudal thyroid artery was represented by a branch of the cranial thyroid artery. The cranial thyroid artery emerges caudal to the laryngeal region, focusing on the ventral to the cranial pole of thyroid gland that surrounds it and trace its ventral caudal edge. At the cranial pole of the thyroid gland, it emits a branch of approx. 4 cm in length, distributed to the pharynx and esophagus-throat branch.
In accordance with May-1970, the caudal laryngeal artery emerges like a branch of the cranial thyroid artery, orienting towards the caudal end of the larynx. The terminal laryngeal artery branches approach the dorsal and lateral sides of the larynx serving the adjacent structures. Some finer branches accompany the laryngeal nerve reccurent towards the organ's mucosa.

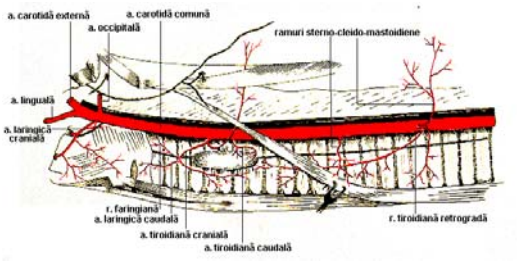

Fig. 1 A common carotid artery collaterals in goat

The cranial laryngeal artery, with a diameter of about 2 mm, emerges from the ventro-medial part of the common carotid artery in the area where the hipogloss nerve crosses its lateral side. It is oriented ventral, on a dorso-lateral side of the larynx to the cranio-dorsal angle of the thyroid cartilage, entering the fissure between cranial-dorsal angle (corniculate process) and thyroid

cartilage blade. It is depleted in the tiro-aritenoidian muscle and on the mucosa of the larynx. It is accompanied caudal by the cranial laryngeal nerve. The place where the cranial laryngeal artery enters inside the larynx, it emerges from it a thin branch that is oriented caudal on the side of the tyroid cartilage blade, being distributed to the tirohioidian and the tirofaringian muscles, and ends in the caudoventral angle of the blade. The thickest branch of cranial laryngeal artery is oriented ventro-cranial and penetrates under the tirohioidian muscle, perforating the tirohioidian membrane. From it emerges a different branch passing over the tirohioidian muscle, distributing to it and the cranial insertions of the sternohioidian and sternotiroidian muscles.

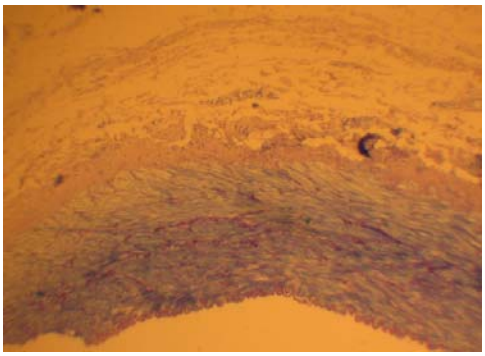

Fig. 2. A common carotid artery collaterals in goat (7,1x20, stain H.E.)

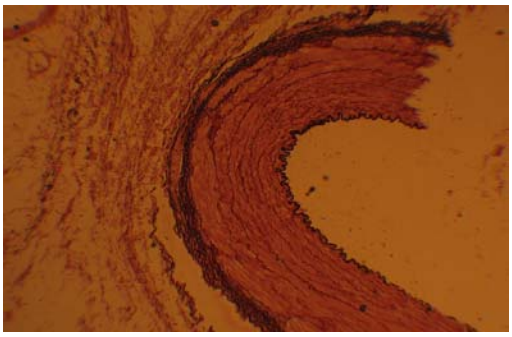

Fig. 3. A common carotid artery collaterals in goat (7,1x10, stain orceine).
Elastic fibers are evident in artery structure.

The pharynx's ascending artery was identified as a collateral of the cranial laryngeal artery, represented by one (in 80% of cases) or two branches which are distributed on the dorso-lateral wall of the pharynx. The common carotid artery ends at the paracondilar process through three branches, but the internal carotid, which forms a common trunk with the occipital artery, completely regresses after parturition, so that "post-partum" common carotid artery has a "small" ending artery represented by the occipital artery and a "large" ending as her real one-the external carotid artery.

CONCLUSIONS

1. The artery is located in a dorsal plan from the sternocefalic muscle and right under the wing of the atlas, where, in case of surgery,the access to the common carotid artery is possible through an incision in the jugular gutter parallel with the ventral margin of the brachiocefalic muscle.
2. The common carotid artery collaterals are numerous and some (muscular branches) are not constantly topographic.

3. The common carotid artery, in the middle third, sends a branch with a retrograde trajectory that after about 6 cm reaches the posterior pole of the thyroid gland, being anastomosed with the caudal thyroid artery branches. From this artery, two dorsal esophageal branches and 2-3 ventral tracheal branches emerge. In 10% of cases this artery may be missing.
4. The common carotid artery ends at the paracondilar process through three branches, but the internal carotid, which forms a common trunk with the occipital artery, completely regresses after parturition, so that "post-partum" common carotid artery has a "small" ending artery represented by the occipital artery and a "large" ending as her real one-the external carotid artery.

BIBLIOGRAPHY

1. Bamel, S.S.; Dhingra, L.D.; Sharma, D. – Arteries to the brain of buffalo (Bubalis bubalis). J. of Research 9, 361 – 365, 1979.
2. Banks, W.J. – Aplied Veterinary Histology. Williams and Wilkins Comp., Baltimore – London, 1981.
3. Barone, R. - Anatomie compare de mamiferes domestiques, Tome V Angiologie, Ed. Vigot, Paris, 1996.
4. Belu, C. - Cercetări comparative morfotopografice privind vascularizaţia şi inervaţia cervicocefalică la rumegătoarele mici, Teză de doctorat, Bucureşti, 2000.
5. Burchfield, D.J.; Pena, A.; Peters, A.J.; Abrams, R.M.; Phillips, D. – Cocaine does not compromise cerebral or myocardial oxygen delivery in fetal sheep. Reproduction, Fertility and Development 8(3), 383 – 389, 1996.
6. Cornilă, N.; Manolescu, N. – Structura şi ultrastructura organelor la animalele domestice. Ed. Ceres, Bucureşti, 1995.
7. Gabella, G. – Complex structure of the common carotid artery of sheep. University College London, Anatomical Record 243(3), 376 – 383, 1995.
8. Garcia, J.L.; Fernandez, N.; Garcia – Villalon, A.L.; Monge, L.; Gomez, B.; Dieguez, G. – Cerebral reactive hyperanemia and arterial pressure in anaesthetized goats. Acta Physiologica Scandinavica 153(4), 355 – 363, 1995.
9. Ghoshal, N.G. – Ruminant heart and arteries. Common carotid artery. In S. Sisson and J.D. Grossman: Anatomy of the domestic animals, vol. 1, 5 th ed. W.B. Saunders Comp., Philadelphia – London, 1005 – 1008, 1975.
10. Godznicki, S. Frackowiak, H., Jackowiak, H. - Internal carotid artery in rostral epidural rete mirabile in animals of the suborder of Ruminatia, Folia Morphologica 55 (4) 267-269, 1996.
11. May, N.D.S. – The anatomy of the sheep (a dissection manual), Third ed. University of Queensland Press, St. Lucia, 1970, 225 – 240.

THE INFLUENCE OF REMEDY BIOR ON PROTEIN METABOLISM IN YOUNG RABBITS

Natalia IACUB

Agrarian University of the Republic of Moldova

ABSTRACT

The elaboration and testing of a new range of medical products with adaptative, antistress, and biostimulating properties is an actual issue for veterinarian analysts and experts and other. In this respect, particular interest has been taken, internationally and locally, in ecologically pure products, especially the phytogenous ones, with the properties mentioned above. This work presents the results of scientific research undertaken through the implementation of young rabbits, aiming at the elucidation of the BioR product of algal origin on the protein metabolism. The study involved 4 lots of animals, 3 of which were treated with BioR three times in a row in does of 0,1;0,5 and 1,0 ml/head. The research has shown that the BioR remedy obtained through current technologies from Spirulina platensis given to rabbits from the day of weaning has a very good general and local tolerance, thus contributing to the improvement and regulation of protein metabolism in young rabbits.

Key words: remedy BioR, protein metabolism, young rabbit , total proteins, albumin, urea.

There are numerous studies in specialized literature which refer to the fact that in ensuring the population with foodstuff it is more perspective the growing of poultry, rabbits, fish, etc. (1;2;3;11). In this respect, particular interest has been taken, internationally and locally, in ecologically pure products, especially the phytogenous ones, with adaptative, antistress, and biostimulating properties.(4;5;8;12;13). BioR obtained from Spiraulina platensis and studied more widely in swine occupies a special place among biologically pure remedys (7). On the assumption of the above we decided to carry out a research of the BioR remedy in young rabbits and to elucidate the impact of this product on the protein metabolism of these animals.

MATERIALS AND METHODS

The research was carried out in with the implementation of weaned rabbits before their slaughter. At the beginning of the experimental period the rabbits were divided into 4 groups with 7 rabbits each. The young rabbit groups were formed on the day of weaning and were put in boxes with the same environmental conditions. The experimental rabbit lots 1,2, and 3 were treated with BioR obtained from Spirulina through current technologies introduced through intramuscular injections of 0,1; 0,5 and 1.0 ml/head, and to those from the control group – 1,0 ml 0,9% sol. NaCl. The remedy was injected 3 times: on the day of weaning, on the 14th and on the 26th day after weaning. Weaning, veterinary aid, feeding, watering, and keeping of young rabbits were identical in all groups according to the technology applied. Besides other activities, upon the beginning of the research and before injecting BioR, and at the end of the study, blood samples from the external articular vein of 5 rabbits from each group were taken into standard test tubes for biochemical research.

For the assessment of the physiological and metabolic status of the rabbits in the blood serum the level of total protein, albumin, and urea was determined with the help of the biochemical analyzer Biosystems A-15, under the instructions provided.

OUTCOME AND DISCUSSION

The study showed that the BioR remedy in young rabbits in animal farm conditions did not arouse any adverse reactions or other deviations from the health and development of the rabbits for a period of approximately 3 months. The multilateral study of new remedies presupposes the dosing of plasmatic proteins which react promptly to the action of external or internal factors (7;10). Thus, the importance of studying biochemical indexes which allow the assessment of protein metabolicm in animals plays a major role in the assessment of remedys including algal remedys. The results regarding some parameters of protein metabolism are represented in table 1.

Table 1. The level of some indexes of protein metabolism in blood serum in young rabbits under the influence of the BioR remedy

Rabbit lots	No. of rabbits	Total proteins g/l	Albumin g/l;	Urea, mmol/l
At the beginning of the study	5	46,98±0,49	31,32±0,58	4,36±0,11
Control	5	52,88±0,48***	34,52±0,21***	5,73±0,28***
Experimental 1	5	53,86±0,90	34,46± 0,64	5,74±0,39
Experimental 2	5	54,68±0,24**	34,14±0,52	5,99±0,18
Experimental 3	5	54,94±0,54*	36,56±0,47***	5,92±0,15

Note: *p<0,05;** p < 0,01 ;***p < 0,001

The analysis of the results presented in table 1 highlights an obvious tendency towards the increasing of the value of total proteins with age in all groups (p< 0,001). At the same time, the positive intervention of the BioR product tested on rabbits in the period of growth after weaning stood out at the end of the study before slaughter by an increase of the parameter studied by 1,8-3,9%, as compared to the control group. Similar tendencies of manifestation of total proteins with age and under the beneficial influence of natural remedies signaled other researchers as well (7;9;13) in poultry chicken and animal cubs. In order to complete and confirm the value of total proteins comes and the value of sulphur albumin which, with age, manifests growth tendencies in animal groups (p< 0,001), having therefore an anticipated physiological nuance in rabbits of the experimental group 3, treated with BioR each with 1,0ml/head, with 5,9% as compared to the reference group (p< 0,001). The research carried out as regards total proteins and albumin highlights a good physiological and metabolic condition in all animals involved in the experiment, being revealed a positive intervention of BioR in the organism in general and in the liver in particular. A major role in the appreciation of the metabolic comfort, especially of the protein metabolism in animals, is played by the sulfuric urea in our study in table 1. The results obtained show that the level of urea in blood serum in rabbits at the beginning of the study was 4,36 +/-0,11 mmol/l, a value that increases with age significantly in all groups (p< 0,001). Such increase of this index in young animals is reported by other authors as well (6;9). It should be mentioned that the BioR remedy in doses 0,5-1,0 ml/head lead to a slight increase of urea in blood by 3,3-4,5% as compared to the reference group in the same period of research. The manifestations of this parameter speak in the first place about the development of certain appropriate metabolic

processes in young rabbits in all groups involved in the experiment, as well as probably about the improvement of protein metabolism in the animal organism by BioR. Based on the research it can be noted that BoiR obtained from Spirulina through current technologies has a beneficial effect on the protein metabolism, which is based on the moderate increase of the level of total proteins, albumin, and urea in the blood serum in animals treated with this product.

CONCLUSION

1. BioR remedy obtained from Spirulina platensis through current technologies is very well tolerated generally and locally.
2. BioR remedy contributes to the improvement and establishment of a proper protein metabolism in young rabbits.
3. For the determination of the optimal dose of the BioR remedy in young rabbits, the continuation of research is imposed.

BIBLIOGRAPHY

1. Bâzgu I. Avicultura Moldovei : realizăzi şi perspective, Chişinău,1997.-120 p.
2. Bobîleva G.A., Sostoeanie i perspectivî razvitia otrasli ptițevodstva. - VI-i Mejdunarodnîî Veterinarnîî kongres po ptițevodstvu -Moskva, 26-29 aprelea 2010 . - s. 7-14.
3. Bucătaru N., Maciuc V., Afaceri în creşterea iepurilor de casă şi animalelor de blană Agenția Naț. de Dezvoltare Rurală.- Ch. Î.S. F. E.-P. „Tipografia Centrală”, 2005.- 96 p.
4. Grosu T., Macari V., Gudumac V., Rudic V. Procède de stimulation de la productive des porcins// 45 Salon Mondial de L'invention, de la recherche et l'innovation industrielle. Bruxelles EURECA '96.- 1996.- P.267.
5. Horoşevskaia L., Horoşevskii A. Laricev O., Maslovskii K., Kozlova M. Innovaționnîe podhodî k ispolizovaniu biologiceski aktivnîh preparatov v broilernom ptițevodstve. VI-i Mejdunarodnîi Veterinarnîi kongres po ptițevodstvu ., Moskva, 26-29 aprelea 2010 .- s.142-145.
6. Macari V., Influența preparatului BioR dinalge asupra unor parametri biochimici la scroafe şi descendenții lor, Luc. ştiinț., vol.44 (3), fascicula I, Medecina Veterinară ,Iaşi, 2001.- p. 311- 315.
7. Macari V. Aspecte fiziologico-metabolice ale acțiunii preparatului BioR de origine algală asupra organismului animal / Autoreferatul tezei de dr. hab. în biologie. – Chişinău, 2003.- 48 p.
8. Macari V., Manifistări ale ceruloplasminei în serul sanguin la scroafe, ratate cu remediul BioR // Luc. ştiinț.Vol.19, Medicină Veterinară, Chişinău 2008.- p.80 - 82.
9. Pârvu Gh. Supravegherea nutrițional metabolică a animalelor. Ed Ceres, Bucureşti,1992.- 391 p.
10. Pârvu Gh., Coste H., Costea M. Nutriția, răspunsul imun şi sănătatea animalelor. – Bucureşti: Ed. Ceres, 1996. -160 p.
11. Petcu I., Starciuc N., Scutaru I., Afaceri în avicultură. – Chişinău: ACSA, 2007 (F. E.-P. “ Tipografia Centrală”).- 112p.
12. Rudic V., Macari V., Burțeva S., Budanțev A., Rastimeşina I. ş.a. Tehnologii de obținere şi testare a biopreparatelor din microalge şi streptomicete în zootehnie // Catalog oficial. Expoziția Internațională specializată Infoinvent - 2002 (9 -12 octombrie) : Chişinău. Editura AGEPI.2002.- p. 53.
13. Sandul P.A.,Vlianie kormovoi dobavki iz rapsovogo masla na nekotorîe biohimiceskie pokazateli sîvorotki krovi țâpleat – broilerov. Simpozion ştiințific internațional :35 ani de învăț. super. medical veterinar din Rep. Moldova, Chişinău 15-16 oct. 2009/ col.red.:p. 40 - 43.

EFFECTS OF THE REMEDY BIOR ON CERTAIN HEPATIC INDEXES IN YOUNG RABBITS

Macari V., Iacub Natalia, Mațencu D., Macari Ana, Pavlicenco Natalia

Agrarian State University of Moldova

ABSTRACT

Today the promoters of growth based on antibiotics and growth hormones are not regarded as acceptable products for the maintenance of health, viability, and improvement of production performance of animals and thus the elaboration, testing, and usage of new and harmless ecologically pure products for both humans and animals become required. Thus the given study aims to determine the influence of the algal BioR remedy on young rabbits.
The experiment involved 4 groups with 7 rabbits each, from the moment of weaning. The young rabbits from 3 experimental groups received the BioR remedy in different doses (0,1 - 0,5-1,0 ml/head) and those from the control group -1,0 ml physiological serum. The product tested was given to 3 times: on the day of weaning, on the 14th day an don the 26th day after weaning. Blood samples were taken from 5 rabbits before injection and from 5 rabbits from each group at the end of the study. It was established that, in the course of the 3 months of the study, the BioR remedy did not cause any adverse reactions or other health or development deviations in young rabbits. Biochemical tests of blood samples of rabbits involved in the BioR treatment before slaughter show a decrease of general bilirubin and conjugated (direct) bilirubin, and signal a moderate increase of unconjugated (indirect) bilirubin by 12,6-19,1% as compared to the reference group. At the same time, the BioR remedy did not bring up a modification of transaminases ALT and AST in the groups examined while a slight increase of the ALT test by 7,9- 18,4% was observed in experimental groups, which may be regarded as positive in young rabbits. Thus the results obtained denote the harmlessness of the remedy as well as its beneficial effect on the organism, particularly on the liver.

Key words: remedy BioR, young rabbits, blood serum, hepatic indexes, bilirubin

There are more and more discussions in the national and international academic literature as regards the usage of various natural, ecologically pure drugs in the veterinary sector with a view to preventing the technological stress in animals and, last but not least, to increasing the adaptative possibilities of the bioproductive indexes (8;16;20;22). In this context, it is known that the more perspective natural products are the vegetable ones, especially those obtained from algae (1;16;22;23). At the same time, the investigations carried out in this field and related to the usage of biotechnologies have contributed to the obtaining of a wide range of algal biologically active remedies (16;17;18).The most studies algal remedy is BioR which is tested on both laboratory and farm animals (5;8;11;16;17).On the assumption of the above, the experiment aimed at revealing the influence of BioR injected in different doses to young rabbits on the health and certain biochemical indexes reflecting mostly the functional condition of the liver.

MATERIALS AND METHODS

The study was carried out at the SRL Fieditehnologii rabbit farm, Bacioi village, Chisinau and involved young rabbits directly after weaning, according to the schedule presented in table 1.

Table 1. Schedule of injection of BioR to young rabbits

Group	No. of animals	Injection	Dose, ml	Injection schedule
Control	7	IM	1,0 ml 0,9 % sol Na Cl	3 times: on the day of weaning, on the 14th and on the 26th day after weaning
Experimental 1	7	IM	0,1	
Experimental 2	7	IM	0,5	
Experimental 3	7	IM	1,0	

Animals included in the study were analogous according to genotype, age, physiological condition, and were kept in the same conditions. Weaning, nutrition, keeping, and veterinary assistance of the rabbits from all groups were identical under the technology practiced. At the beginning of the study blood samples were taken from 5 rabbits before the injection of the BioR remedy and at the end of the study blood samples from the external articular vein of 5 rabbits from each group, for the blood and biochemical testing. During the study the body temperature of 5 rabbits from each group was measured, the animals were examined clinically, and counted.
The activity of transaminases alanine-aminotransferase (ALT) and aspartate-aminotransferase (AST) as well as the level of general bilirubin and its fractions was determined with the help of the biochemical analyzer Biosystems A-15 under the instructions provided.

OUTCOME AND DISCUSSION

The injection of the BioR remedy to young rabbits did not cause any adverse reactions or other health or developmental deviations. This is confirmed by the indexes of the body temperature which, at the end of the study, at the age of approximately 4,5 months, in rabbits treated with BioR in doses of 0,5-1,0 ml/head was lower by 0,06-0,16 ^{o}C as compared to the reference group. Thus these results reflect a better ambient and metabolic adaptations in animals treated with BioR, which is a beneficial effect of the BioR remedy established in studies carried out on swine (8).

Metabolic indexes, especially those of the liver, are known to be very representative in the assessment of animals' health and in testing products with adaptative and stimulatory properties (9;21). The results of biochemical tests conducted before the injection of the BioR remedy and in the last research period are shown in table 2. An analysis of table 2 shows that the mean alkaline level of general bilirubin is 3,33±0,31 mmol/ l, an index which, in young rabbits from the control group increases with age by 36% as compared to the alkaline level ($p<0,01$). At the same time it has been determined that this index decreased by 17,4 – 21,4% in the experimental groups, as compared to the reference group. The low level of this parameter indicates, besides other actions the antitoxic action of the BioR remedy and the impact of this product on erythrocytes as it increases their life duration and the resistance to other harmful factors. This hypothesis may be tangentionally confirmed by the greater number of erythrocytes in blood in the animals treated with BioR, a fact we signaled earlier (10).

Table 2.Indexes of certain biochemical indexes of blood serum in young rabbits after the injection of the BioR remedy

	Alkaline level	Group			
		Control	Experi - mental-1	Experi - mental-2	Experi - mental-3
Number of animals	5	5	5	5	5
Remedy dose		1,0 ml-0,9% NaCl	0,1	0,5	1,0
General bilirubin, mkmol/l	3,33±0,31	4,53±0,16**	3,57±0,29*	3,56±0,41*	3,74±0,26*
Conjugated bilirubin, mkmol/l	0,40±0,40	1,75±0,27***	0,45±0,24**	0,38±0,24**	0,44±0,21**
Unconjugated bilirubin, mkmol/l	2,93±0,23	2,77±0,28	3,12±0,18	3,18±0,40	3,30±0,11
Alanine-aminotransferase,(ALT),u/l	39,24±2,13	43,52±2,70	36,9±1,30	51,52±4,67	46,98±7,19
Aspartate-aminotransferase (AST),u/l	24,82±0,94	21,46±0,49	19,56±0,32	22,92±0,97	21,28±0,99

Note: *p<0,05;** p < 0,01; ***p < 0,001

A special place in the assessment of the metabolic function of the liver is occupied by the conjugated or direct bilirubin. In the case of our research, the mean alkaline level of conjugated bilirubin 0,40± 40 mkmol/ l, an index which, in the rabbits of the control group manifests a tendency of growing by 4,4 times with age, as compared to the alkaline level. It should be noted that the BioR remedy has contributed to maintaining this parameter at a lower level in blood serum by 3,9 -4,6 times as compared to the control group, this fact may be considered as beneficial and explained through the impact of the product on the liver and especially on the excrectory function, due to which the massive elimination of conjugated bilirubin from the organism takes place. At the same time, in the rabbits treated with BioR, at the end of the study and before slaughter, an increase of the level of unconjugated (indirect) bilirubin in blood serum by 12,6 – 19,1% was noted, as compared to the reference group at the same period of research, which is also regarded as beneficial, as the high level of unconjugated bilirubin is a positive index, first of all due to the antioxidation effect of this fraction of bilirubin. Today it is unanimously agreed that the liver plays a major roled in the alkaline metabolism, especially that or proteins. Transaminases ALT and AST are considered to be the most important tests for the assessment of the functional condition of the liver, especially when testing new medical products (4;11;17). The analysis of results shown in table 2 denotes a slight increase with age of the ALT enzyme in the control group by 10,9% as compared to the alkaline level at the beginning of the study. At the same time the influence of the BioR remedy induces a moderate increase of the ALT test by 7,9-18,4% as compared to the control group, a fact which can be explained through the intensification of anabolic processes, especially of the proteosynthetic function of the liver. Concomitantly with the dosing of ALT, the functional level of AST was determined which decreases by 13,5% with age in the control group, which persists in rabbits from the experimental group. This index in experimental groups does not differ from that of the control group and a slight difference in the experimental group 2 by 6,8% is noted as compared to the control group.

Results obtained are in concordance with the results of researchers (12), who, after testing a biostimulating remedy – microvitar – on young cattle obtained greater indexes of the ALT and AST (by 8,0 -13,8%), and, asa result, the authors claims that the product tested by them stimulates the synthesizing function of proteins in the liver (12). Thus, after the experiment carried out on rabbits, it could be highlighted that the BioR remedy obtained from spirulina manifests beneficial properties reflected in the amelioration of metabolic processes in the liver.

CONCLUSION

1. The BioR remedy obtained from Spirulina platensis through modern technologies, injected into young rabbits 3 times in a row is very well tolerated generally and locally.
2. It was proved that in farm conditions the BioR products injected into rabbits manifests beneficial effects no the metabolic processes of the liver.
3. The research confirms the necessity to continue the studies related to the influence of the BioR products on young rabbits, with the purpose of optimizing the doses and injection schedule.

BIBLIOGRAPHY

1. Altunin D.A.,Şmeleva G.A, Kogan M.M.,Litenkova I.IU.,Titov I.N. ş.a. Primemenie spirulinî v jivotnovodstve I ptiţevodstve // Veterinaria,1999.-№10.-S. 11-13.
2. Bâzgu I. Avicultura Moldovei : realizăzi şi perspective, Chişinău, 1997.- 120 p.
3. Bobîleva G.A., Sostoeanie i perspectivî razvitia otrasli ptiţevodstva. - VI-i Mejdunarodnîî Veterinarnîî kongres po ptiţevodstvu -Moskva, 26-29 aprelea 2010 . -s. 7-14.
4. Krasociko P.A., Kapitonova E.A., Glaskovici A.A., Juravleva E.S., Sostoeanie obmennîh protesov u tîpleat –broilerov posle vkliucenia v ration immunostimuleatora „Aliviozan" i probiotika „Dialakt".Uc.zapiski ucerejdenie obrazovania „Vitebskaia ordena „ Znak poceta" Gos. Akademia veterinarnoi meditinî.Tom 45, vîpusk 2, ceasti Iiuli-dekabri 2009, R. Belarusi 2009, s.68-72.
5. Grosu T., Macari V., Gudumac V., Rudic V. Procède de stimulation de la productive des porcins// 45 Salon Mondial de L'invention, de la recherche et l'innovation industrielle. Bruxelles EURECA '96.-1996.-P.267.
6. Horoşevskaia L., Horoşevskii A. Laricev O., Maslovskii K., Kozlova M. Innovaţionnîe podhodî k ispolizovaniu biologiceski aktivnîh preparatov v broilernom ptiţevodstve. VI-i Mejdunarodnîi Veterinarnîi kongres po ptiţevodstvu ., Moskva, 26-29 aprelea 2010 .-s.142-145.
7. Macari V., Influenţa preparatului BioR dinalge asupra unor parametri biochimici la scroafe şi descendenţii lor, Luc. ştiinţ., vol.44 (3), fascicula I, Medecina Veterinară ,Iaşi, 2001.-p. 311-315.
8. Macari V. Aspecte fiziologico-metabolice ale acţiunii preparatului BioR de origine algală asupra organismului animal / Autoreferatul tezei de dr. hab. în biologie. –Chişinău, 2003.-48 p.
9. Macari V., Manifistări ale ceruloplasminei în serul sanguin la scroafe, ratate cu remediul BioR // Luc. ştiinţ.Vol.19,Medicină Veterinară, Chişinău 2008.- p.80-82.
10. Macari V., Iacub Natalia, Romanovschi Iu., Brenici V., Donica A., Lopacesco Maia, „Cercetări privind indicii hematologici la tineretul cunicol tratati cu remediul BioR" Simpozion ştiinţific internaţional „35 ani de învăţămînt superior madical veterinar din Republica Moldova" Chişinău: Centru editorial al UASM, 2009.- p23-26.
11. Macari V., Putin V., Gudumac V., activitatea pseudocolinesterazei şi nivelul seric al glucozei şi ureei la puii-broiler tratati cu BioR, Lucrări ştinţ. vol. 52 (11) Medicină Veterinară partea II; Editura „Ion Ionescu de la Brad" Iaşi 2009, p 1074-1077.
12. Mozjerin V.I., Kalimullina R.G.,Asadullina F:F.,Erkeev M.I., Uelidanov R.N, Vlianie biostimuleatorov na estestvenniu rezestentnosti organizma teleat // Veterinaria,2000.- №6.- S. 68-41.
13. Pârvu Gh. Supravegherea nutriţional metabolică a animalelor. Ed Ceres, Bucureşti, 1992.- 391 p.

14. Pârvu Gh., Coste H., Costea M. Nutriţia, răspunsul imun şi sănătatea animalelor. –Bucureşti: Ed. Ceres, 1996. -160 p. Petcu I., Starciuc N., Scutaru I., Afaceri în avicultură. –Chişinău: ACSA, 2007 (F. E.-P. " Tipografia Centrală").-112 p.
15. Rudic V., Macari V., Burţeva S., Budanţev V., Rastimeşina I. ş.a. Tehnologii de obţinere şi testare a biopreparatelor din microalge şi streptomicete în Zootehnie /Catalog oficial. Expoziţia Internaţională specializată Infoinvent-2002 (9-12 octombrie). –Chişinău: Editura Tehnică, 1993.- 304 p.
16. Rudic V., Şalaru V., Obuh A. Tulpina Spirulina platensis (Nordst) Geitil. CALU –producător de biomasă: Brevet MD Nr. 169// BOPI.-1995. – Nr. 3.-140 p.
17. Rudic V., Cojocari A. , Cepoi L., Chiriac T., Rudi I., Gudumac V. Macari V.,Codreanu S. ş.a. Ficobiotehnologie- cercetări fundamentale şi realizări practice/ Chişinău: s.n. 2007 (Tipografia „Elena V.I. SRL).- 365 p.
18. Rudic Valeriu BioR: Studii biomedicale şi clinice /Valeriu Rudic.- Ch.: S.n., 2007 (Tipogr. „Elena V.I. SRL).-376 p.
19. Sandul P.A. Ăffectivnosti primenenia broileram conţentrata vitaminov E i F uz rapsovogo masla// Ucennîe zapiski. Haucino-practiceskii jurnal.-Vitebsk.- T.43.-Vâpusk 1.- 2007.-p. 210 - 212.
20. Sandul P.A.,Vlianie kormovoi dobavki iz rapsovogo masla na nekotorîe biohimiceskie pokazateli sîvorotki krovi ţâpleat – broilerov. Simpozion ştiinţific internaţional :35 ani de învăţ. super. medical veterinar din Rep. Moldova, Chişinău 15-16 oct. 2009/ col.red.:p. 40-43.
21. Sasson A., 1993, Biotehnologii şi dezvoltare.Bucureşti, Ed. Tegnică,308 p.
22. Şalari V.M., Rudic V.F., Chiriac M.I. ş.a.Rekomendatii po tehnologhii polucenia i ispolizovania biomasi sine-zelenoi mikrovodorosli spirulinî v ratîonah seliskohozeaistvennoi ptitî/ Chişinev. -1989.-4 s.

MANIFESTATIONS OF ALKALINE PHOSPHATASE IN BLOOD SERUM OF BROILER CHICKS TREATED WITH THE BIOR REMEDY

V. MACARI, V. PUTIN, Cristina GAVRIL, Ana MACARI, A. POPESCO
Agrarian State University of the Republic of Moldova

ABSTRACT

This study is devoted to the testing of the BioR obtained from the Spirulina platensis algae through modern technologies on broiler chicks in poultry farm conditions. The research involved 5 groups of broiler chicks with 30 chicks each. The young broilers from the experimental groups I-IV received intramuscular BioR injections twice as follows: on the 9th day - 0,3-0,6ml/head and on the 21st day – 0,4-1,0ml/head. The broilers in the control group were injected physiological serum respectively 0,4 and 0,6 ml/head. The study showed that the BioR product injected into broiler chicks starting with the 9th day of life is very well tolerated both generally and locally and has a positive impact on the activity of the alkaline phosphatase and its hepatic and bone fractions, which indicates a stimulating and protective action of BioR.

Key words: BioR remedy, blood serum, alkaline phosphatase, broiler chicks

Due to the intensification of poultry farming and establishment of large poultry farms biologically active substances are highly significant as they are used in premixes and combined forage for different types of poultry (1;7;9). Multiple studies are carried nationally and internationally to elucidate the influence of different combinations of vitamins, microelements, and other chemical additives and biologically active substances in the nutrition of poultry (3;7;16). Presently even more aspects related to the elaboration, testing, and usage of biologically active drugs in various branches of zootechnics and veterinary medicine are studied. Priority is given to those drugs which are natural and harmless for both humans and animals. Drugs obtained from microalgae through modern technologies occupy a special place in this category (8;13).The testing of these drugs on laboratory animals and swine revealed positive properties, especially hepatoprotective ones (5;6;13). It is therefore important to study certain sides of the alkaline metabolism in order to elucidate the mechanisms of action of the new drugs. In this context the importance of elucidation of the influence of BioR on the level of alkaline phosphatase in blood serum is unquestionable. That is why we decided to verify and examine some mechanisms inherent in the effects of BioR on broiler chicks.

MATERIALS AND METHODS

The study involved 5 groups of broiler chicks with 30 chicks each, in poultry farm conditions at Avicola Şaver poultry farm, Bucovat, Republic of Moldova. The principle of organization of the study with the use of the BioR remedy is shown in table 1. The BioR remedy tested is natural and is obtained by biotechnological means from Spirulina platensis (8;13). This drug contains a wide range of bioactive substances such as: amino acids, especially immunoactives, phycobiliproteins (C-phycocyanin), sulfated polysaccharides, oligopeptides, microelements, etc. For the carrying out of biochemical tests blood samples of 5 chicks from every group were taken on the 9th day before injection of the BioR remedy and on the 41st day before slaughter.The activity of alkaline

phosphatase and its fractions was dosed in blood serum in the biochemical analyzer FP-900, Finland, with the help of reagent sets of Eliteh Company, France, under the instructions attached.

Table 1. Schedule of usage of BioR remedy in broiler chicks

Group	No. of chicks	Type of injection	Dose, ml		Schedule
			1st time	2nd time	
Control	30	IM	0.4ml, 0.9% sol NaCl	0.6 ml, 0.9% sol NaCl	Twice: on the 9th day and on the 21st day of life of the chicks
Experimental 1	30	IM	0.3	0.4	
Experimental 2	30	IM	0.4	0.6	
Experimental 3	30	IM	0.5	0.8	
Experimental 4	30	IM	0.6	1.0	

OUTCOME AND DISCUSSION

The results obtained after testing the BioR remedy for a period of approximately 30 days in production conditions did not cause any adverse reactions or other health or development deviations in young poultry. It should be mentioned that the BioR remedy was first tested on broiler chicks in different doses and under different schedules. It is therefore important how this remedy influences the metabolism on cell level and, last but not least, on the functions evolving in the liver and bones – key organs for the growing organism of animals and birds. Thus, in order to obtain significant indexes regarding the impact of the BioR remedy on the cell activity, we dosed the alkaline phosphatase in blood serum; the indexes are shown in table 2.

Table 2. The level of alkaline phosphatase in blood serum upon injection of the BioR remedy into broiler chicks

Group	No. of chicks	Total alkaline phosphatase, u/l	Thermostable alkaline phosphatase, u/l	Thermolabile alkaline phosphatase, u/l
At the beginning of the study	5	307.62 ± 3.85	279.84 ± 9.97	27.78 ± 7.43
Control	5	172.46 ± 5.23***	150.62 ± 7.61***	21.84 ± 6.96
Experimental 1	5	197.96 ± 15.09	168.12 ± 3.72	29.84 ± 11.40
Experimental 2	5	205.50 ± 10.54*	175.72 ± 5.73	29.78 ± 5.87
Experimental 3	5	168.96 ± 3.67	153.62 ± 5.97	15.34 ± 8.70
Experimental 4	5	197.86 ± 8.98*	172.32 ± 0.95	25.54 ± 4.94

Note: *$p<0,05$; ***$p < 0,001$

Table 2 shows that the mean value of the alkaline level of total alkaline phosphatase in blood serum of broiler at the age of 9 days, before the injection of BioR is 307.62 ± 3.85 u/l. Towards the end of the study, on the 41st day of life the alkaline phosphatase index decreased in the control group by 1.8 times as compared to the previous results (P<0.001).

This elicitation is a unanimously accepted physiological peculiarity of young animals. A remarkable decrease with age of total serum alkaline phosphatase was also observed in experimental groups, and regularity in comparison with the control group was revealed. Thus the BioR product tested contributed to a greater metabolic intensification in broilers of the experimental groups 1,2 and 4, where the level of total alkaline phosphatase in blood serum is higher by 15.4- 19.8% as compared to the control group. Results obtained by Bessarabov şi col. (1999) in relation to the effect of mumie-siladjit with high levels of Fe^{++} and Mg^{++} given to poultry, on the alkaline phosphatase coincide with the data presented in this study. It should therefore be mentioned that scientists Durlea F. şi col. (1997) concluded that the activity of alkaline phosphatase is lower in cachectic broilers than in healthy ones (4). Results given in table 2 regarding the evolution of thermostable alkaline phosphatase in blood serum in intact broiler chicks treated with BioR is in consistency with the manifestations of total alkaline phosphatase in animals involved in the study. In this context, thermolabile alkaline phosphatase plays a significant role in the alkaline metabolism, especially that of young poultry, and represents the bone fraction of alkaline phosphatase. (15). Date given in table 2 confirm that thermolabile alkaline phosphatase in broilers not treated with BioR decreases towards the end of the study by 21.4% as compared to the alkaline level at the beginning of the study. at the same time the calculations showed that the BioR remedy is beneficial for the bone fraction of alkaline phosphatase, especially in experimental groups 1, 2 and 4, where a moderate growth by 16.9-36.6% as compared to the control group at the end of the study is observed. This activity of the index may be considered beneficial, as the growth of young poultry in industrial conditions imposes the intensification of the bone metabolism – processes to which the product tested may make a positive contribution. Thus, based on the data obtained, it can be mentioned that the BioR remedy obtained from Spirulina platensis through modern technologies manifested positive properties in the activity of total alkaline phosphatase and its hepatic and bone fractions, which indicates the stimulatory and protective function of the product tested.

CONCLUSION

1. The BioR remedy obtained from Spirulina platensis through modern technologies and injected into broiler chicks did not cause any adverse reactions or health or development deviations.
2. The BioR remedy contributes to the improvement of the metabolic function of the liver and bone tissue, which is confirmed by the higher activity of the total alkaline phosphatase and its hepatic and bone fractions.
3. The results obtained allow the carrying out of further more profound and detailed research on poultry of different ages or physiological condition, with a view to optimizing the dose and schedule of usage.

BIBLIOGRAPHY

1. Alexeev F.F., Asriak M.A., Belcenco N.B., Fisinin V.I.,Tardatian G.A. i dr.Promâşlennoe ptițevodstvo, M.: Agropromizdat, 1991.- 544 s.
2. Bessarabov B. F., MEdinikova i. i., Gonțova L. P., Dorogavțev A. A. Priminenie mumiedlia stimuliații formirovania imuniteta u ptiț//Veterinaria, 1999.- №6.- s.15 -16.
3. Curcă D., Pantă L. Cercetări experimentale privind influența suplimentării hranei cu seleniu şi crom asupra conținutului de colagen muscular la puii de carne//. Simpozion Ştiințific Internațional „70 ani ai

Universităţii Agrare de Stat din Moldova",Medicină Veterinară,7-8 octombrie 2003,Chişinău 2003,p.65-67.

4. Durlea F., Popa V.V.,Orăşanu A.,Dojana N. Activitatea fosfatazei alcaline la găină în funcţie de vârstă, stare de sănătate // Al VII-lea Congres Naţional de Medicină Vet. Din România,21-24 octombrie 1997.- Voineasa, jud. Vâlcea România,1997.- 409 p.
5. Grosu T., Macari V., Gudumac V., Rudic V. Procède de stimulation de la productive des porcins// 45 Salon Mondial de L'invention, de la recherche et l'innovation industrielle. Bruxelles EURECA '96.-1996.- P.267.
6. Gudumac V.,Rudic V., Gulea A., Chiriac T.,Bulmaga V.,Macari V.,Technologies d'obtetion de immunostimulateurs et hepatoprotecteurs d'origine algale//29^{eme}Salon Internationaldes Inventions ,des Techniques et produitus nouveau.4-8 avril 2001.-Palexpo.-Geneve.-2001.-p.179.
7. Julean C.,Drinceanu D., Acatincăi S., Simiz Eliza, Ştef Lavinia, Luca I. Corelaţii privind efectul sursei şi nivelului de mangan din hrană asupra indicilor nutritivi şi productivi la puii de carne., // Luc. ştiinţ.,v.18 Zootehnie şi Biotehnologii., Chişinău 2008,p.19 - 22.
8. Macari V.,Buza V., Gangal N.,Balan I., Vrincean V .,Donea V.,Bazele zooveterinariei/Chisinau:Centru Ed. al UASM, 2002-188 p.
9. Petcu I., Starciuc N., Scutaru I., Afaceri în avicultură. –Chişinău: ACSA, 2007 (F. E.-P. " Tipografia Centrală").-112 p.
10. Rudic V., Macari V., Burţeva S., Budanţev V., Rastimeşina I. ş.a. Tehnologii de obţinere şi testare a biopreparatelor din microalge şi streptomicete în Zootehnie /Catalog oficial. Expoziţia Internaţională specializată Infoinvent-2002 (9-12 octombrie). –Chişinău: Editura Tehnică, 1993.- 304 p.
11. Rudic V., Şalaru V., Obuh A. Tulpina Spirulina platensis (Nordst) Geitil. CALU –producător de biomasă: Brevet MD Nr. 169// BOPI.-1995. – Nr. 3.-140 p.
12. Rudic Valeriu BioR: Studii biomedicale şi clinice / Valeriu Rudic.-Ch.: S.n.,2007 (Tipogr. „Elena V.I. SRL).-376 p.
13. Rudic V., Cojocari A.,Cepoi L., Chiriac T., Rudi I., Gudumac V., Macari V.,Codreanu S. ş.a. Ficobiotehnologie - cercetări fundamentale şi realizări practice/ Chişinău: s.n. 2007(Tipografia „Elena V.I. SRL).-365 p.
14. Sandul P.A. Ăffectivnosti primenenia broileram conţentrata vitaminov E i F uz rapsovogo masla// Ucennîe zapiski. Haucino-practiceskii jurnal.-Vitebsk.- T.43.-Vâpusk 1.-2007.- s. 210 - 212.
15. Ţiţa N. Ănţiclopedia cliniceskihlaboratornîh testov/Perevod s angl. Pod redacţiei V. V. Menişikova, M.: Izd. „Labinform" ,1997.- 960 s.
16. Vacaru – Opriş I., Apostol L., Movileanu G., Apostol T. F., Usturoi G., Sisteme şi tehnologii de creştere a puilor de carne. Editură Ceres, Bucureşti, 2005.- 224 p.

MACROSCOPIC ANATOMOPATHOLOGICAL CHANGES IN NATURAL INFESTATION WITH *ARGAS PERSICUS*

S. MORARIU[1], Gh. DĂRĂBUȘ[1], P. BRĂILĂ[2], M. ILIE[1], Florica MORARIU[3], M. CÎRSTEA[4],
[1]Faculty of Veterinary Medicine Timișoara, Calea Aradului 119, sorin.morariu@fmvt.ro;
[2]DSVSA Reșița, Calea Timișorii, 15;
[3]Faculty of Animal Sciences and Biotechnologies, Calea Aradului, 119.
[4]DSVSA Sibiu, Calea Șurii Mari, 12;

ABSTRACT

Poultry industry has been considerably developed in the past years by genetic potential improvement of broiler strains. But, the genetic selection for a rapid growth of birds also favored emergence of some specific diseases. This paper describes the macroscopic anatomopathological changes found in naturally infested broilers with Argas persicus ticks. The main changes were: erythema, white scales of different sizes, yellow-reddish crusts, hematomas, and angiectasia. After the ticks detachement, pea-like or smallest nodules, sometimes infected, with a small central crater, hematomas, and necrotic zones were observed.

Key words: broilers, Argas persicus, naturally infestation, anatomopathological changes.

Poultry mites and ticks will always raise problems in their control because they are the most important hematophagous ectoparasites. Moreover, they are ubiquitous and can exert direct effects on the egg production by blood consumption and/or by their toxic secretions, induced anemia and irritations, which can lead to the death of infested individuals (2, 3, 4).
Also, these ticks proved to be vectors for several poultry pathogens, including spirochetes, pox virus, and even eastern equine encephalomyelitis (1, 5, 8). Occasionally, argasids can induce dermatitis in poultry keeper personnel or in pigeon breeders (6, 7, 9).
In this study the macroscopic changes induced by argasid parasites at the site of attachment were recorded.

MATERIALS AND METHODS

11 broilers, Ross-308, from Food 2000 Bocșa poultry farm were used. The broilers were 2 weeks old and they were moved in a household from Carașova locality (Caraș-Severin County) where *Argas persicus* ticks were identified. Broilers were breed separately from other poultry of the household, in the infested shelter, with free access into paddock. Same fodder as in the originate farm was feed. The experiment was carried out in September 2006, and broilers were slaughtered in October, at the age of 56 days.

RESULTS AND DISCUSSIONS

Macroscopic changes induced by parasites could be observed in figures 1-4.
Thus, after broilers were introduced into the household, all of them were attacked by *A. persicus* juvenile stages. The maximal intensity of parasitism was recorded in the fourth day after broiler introduction. The number of attached ticks varied between 183 and 319 on one individual. After 6-7 days of feeding, the ticks leaved the broilers body to metamorphosis.

In Figure 1 a large number of ticks attached to the axillary skin could be observed. But they were encountered in almost all body regions: neck, ventral abdomen, cloacae, etc.

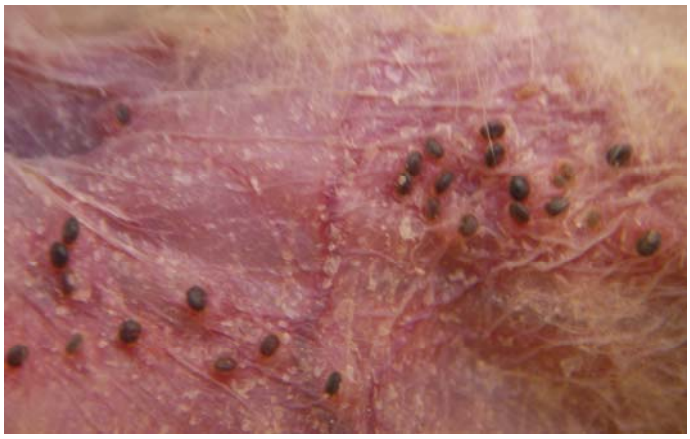

Figure 1. A large amount of *Argas persicus* ticks fixed on axillary's region (original).

The presence of ticks in different stages of starving is evident. The majority of engorged ticks had an intense reddish color, and the area where they were attached was heavily erythematous. Also, on the skin surface at place of attachment, white scales of different sizes and yellow-reddish crusts due to plasma and blood extravasations, and which solidified in contact with the air, could be observed. In the second figure, changes at the feeding place could be noticed. Following anticoagulant and vasodilator substances inoculation at the same time with saliva, a hematoma of different sizes is formed at the site of attachment, in which the blood is oozing, favoring the thelmophagic feeding of ticks. The area's erythema is expanded and blood vessels are dilated showing a dermatographism aspect.

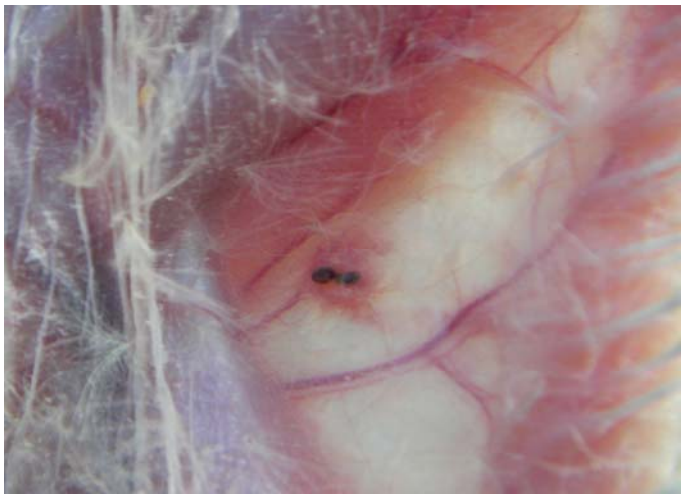

Figure 2. Some juvenile stages of *Argas persicus* fixed on axillary's region. It can be observed the hematoma, erythema and angioectasias (original).

After ticks finished the blood meal and left the broilers' body it can be observed papules, pustules and yellowish pea-like nodules, with a small reddish central crater at the site were the tick was attached. Some nodules had a sticky yellowish pussy content, which means that they underwent a

secondary infectious process (Figures 3 and 4). There could be seen also hematomas and small necrotic areas, some of them covered with yellow or yellow-brownish crusts.

Figure 3. Some yellowish nodules with a small crater in central part on an erythematous zone at the site where ticks have been attached (original).

Figure 4. Haematomas and necrotic lesions at the site where ticks have been attached (original).

Majority of the lesions healed after 4 weeks from the beginning of the ticks attack.

CONCLUSIONS

At the site where ticks were attached it can be observed: erythema, whitish scales of different sizes, yellow-reddish crusts, hematomas and angioectasias.
Pea-like nodules, sometimes infected, with a small central crater, hematomas and necrotic areas could be seen after ticks' detachment.

REFERENCES

1. Durden, L.A., Linthicum, K.J., Monath, T.P., 1993 – Laboratory transmission of Eastern equine encephalomyelitis virus to chicken by chicken mites (Acari: Dermanyssidae). *J. Med. Entomol*., 30, 281-285.
2. Kettle, D.S., 1993 - Acari-Prostigmata and Gamasida. In: Medical and veterinary entomology. CAB International, Wallingford, UK, 380-406.
3. Kim, I.S., Yi, J.H., Tak, J.H., Ahn, Y.J., 2004 – Acaricidal activity of plant esentials oils against *Dermanyssus gallinae* (Acari: Dermanyssidae). *Vet. Parasitol*., 120, 297-304.
4. Lancaster, Jr., J.L., Meisch, M.V., 1986 – Mites attacking fowls. In: Arthropods in Livestock and Poultry Production. Wiley, New York.
5. Mulla, M.S., Su, T., 1999 – Activity and biological effects of neem products against arthropods of medical and veterinary importance. *J. Am. Mosq. Control Assoc.*, 15, 133-152.
6. Rolla, G., Nebiolo, F., Marsico, P., Guida, G., Bigo, P., Riva, G., Zanota, S., 2004 - Allergy to pigeon tick (*Argas reflexus*): demonstration of specific IgE-binding components. *Int. Arch. Immunol*., 135, 293-295.
7. Sirianni, M.C., Mattiacci, G., Barbone, B., Mari, A., Aiuti, F., Kleine-Tebe, J., 2000 - Anaphylaxy after *Argas reflexus* bite. *Allergy,* 55, 303.
8. Turell, M.J., Mores, C.N., Lee, J.S., Paragas, J.J., Shermuhemedova, D., Endz, T.P., Kohodjaev, S., 2004 - Experimental transmission of Karshi and Langat (tick-borne encephalitis virus complex) viruses by *Ornithodoros ticks* (Acari: Argasidae). *J. Med. Entomol*., 41, (5), 973-977.
9. Veraldi, S., Scarabelli, G., Grimalt, R., 1996 - Acute urticaria caused by pigeon ticks (*Argas reflexus*). *Int. J. Dermatol*., 35, 34-35.

SPONTANEOUS CASES OF CHRONIC HEPATOPATHIES IN DOGS

NAGY A.L., C. CĂTOI, A. GAL, P. BOLFĂ, M. TAULESCU, F. TĂBĂRAN, COSMINA CUC, G. BORZA, R. MOUSSA

University of Agricultural Sciences and Veterinary Medicine, Department of Pathology, 3-5 Mănăştur Street, 400372, Cluj-Napoca, Romania
E-mail:nagyandras26@gmail.com

SUMMARY

The aim of this study was to identify and describe the most frequently macroscopical and histological aspects found in chronic hepatopathies in dogs. We have taken into study 15 hepatic samples from 15 dogs, which suffered complete necropsy exam at the Pathology Department of our Faculty. The pathological aspects varied widely according to cases. Commonly affected were the aged dogs, the median age was 10 years. No sex or breed predisposition were noticed. We also performed a staging and a grading of the hepatic samples according to Knodell HAI. Knodel HAI score represents the combined scores for necrosis, inflammation, and fibrosis.

Keywords: cirrhosis, dog, tumors, fibrosis

INTRODUCTION

Chronic hepatopathies represent an important part in pathology. Lobular dissecting hepatitis, chronic progressive hepatitis, viral hepatitis (adenovirus), leptospirosis (6), drug induced (primidone, phenytoin) hepatitis, copper toxicity (Bedlington terriers, West Hound White terriers), or suppurative and non-suppurative cholangiohepatitis are frequently diagnosed in dogs. Also, cirrhosis – the end stage fibrosis of many inflammatory hepatic diseases – as well as neoplasms, both primary or metastatic are often diagnosed (2,7). Chronic hepatitis is characterized by hepatocellular apoptosis or necrosis, a variable mononuclear or mixed inflammatory infiltrate, regeneration and fibrosis. The proportion and distribution of these components vary widely and it is necessary to include in the diagnosis the activity and stage of the disease as well the possible etiology. The activity of the disease is determined by the quantity of inflammation and extent of hepatocellular death. The stage of the disease is determined by the extent and pattern of the fibrosis and possible presence of architectural distortion and development of cirrhosis. The regeneration of the parenchyma may be seen as well as the proliferation of ductular-like structures at the periphery of the parenchyma and within fibrous septa (3,4). The Knodell histology activity index (HAI), published in 1981, was the first system of its type and is widely regarded as the benchmark for objective, semiquantitative, reproducible description of the various morphological lesions of chronic hepatitis. HAI score is the combined scores for necrosis, inflammation, and fibrosis (1).

MATERIALS AND METHODS

We have taken into study liver samples from 15 dogs (10 females and 5 males) with ages between 5 and 13 years, which were investigated for diagnosis at the Pathology Department of the Faculty of Veterinary Medicine Cluj-Napoca. The animals suffered complete necropsy exam, during necropsy the liver was examined macroscopically, and samples were taken for histopathology. For histological exam, samples were preserved in formalin for 24 hours, embedded in paraffin, the

sections made at 4 micrometers with a microtome Leica RM 2125 RT and stained by Haematoxiline–Eosine and Masson's trichrome methods. Then the slides were examined under a microscope Olympus BX 51. The images were taken with Olympus SP 350 digital camera and processed by a special image acquisition and processing program: Olympus Cell B. We performed a staging and grading of the liver disease using Knodell HAI. The Knodell score or HAI is commonly used to assess or "stage" liver disease (1,5). The examinations were carried out in a double-blinded manner.

Table1. Inflammation scores in Knodell HAI (8)

Sum of inflammation scores in HAI	Description of activity
0	None
1-4	Minimal
5-8	Mild
9-12	Moderate
13-18	Marked

Table2. Fibrosis scores according to Knodell HAI (8)

Score	Microscopic feature
0	No fibrosis
1	Fibrosis portal expansion
3	Bridging fibrosis (portal-portal or portal-central linkage)
4	Cirrhosis

RESULTS AND DISCUSSION

The gross lesions found at necropsy were represented by hepatic cirrhosis, liver tumors (both primary and metastatic), and hepatic fibrosis. Liver fibrosis was associated in the majority of the cases with chronic blood stasis, a consequence of heart failure.

Microscopically the lesions were graded and staged using Knodell HAI. The evaluated criteria were the periportal and intralobular necrosis, the intralobular degeneration, the portal inflammation and the fibrosis (5). Out of the 15 cases 2 (13,33%) were represented by cirrhosis, 5 (33,33%) by tumors (both primary or metastatic), and 8 (53,33%) cases of central or bridging (especially central-central bridges) fibrosis due to chronic blood stasis. Chronic blood stasis was associated in all cases with heart failure. In the 2 cases of cirrhosis the dominant feature was represented by extensive scarring of the tissue, loss of normal hepatic lobular architecture with fibrous septae separating and surrounding nodules; the score given for the assessment of fibrosis was 4. The necroinflammatory activity varied between the 2 cases. The first case was represented by a 10 year old female dog, common breed, with hepatocutaneous syndrome (necrolytic migratory erythema). The histologic diagnosis was biliary cirrhosis. A marked proliferation of cholangiocytes (increased number of bile ductules) was noticed. Vacuolar disthrophy and hepatocelullar necrosis was also evident. The score given for assessment of necroinflammatory activity was 6 (mild inflammation).

Fig.1. Macronodular cirrhosis.

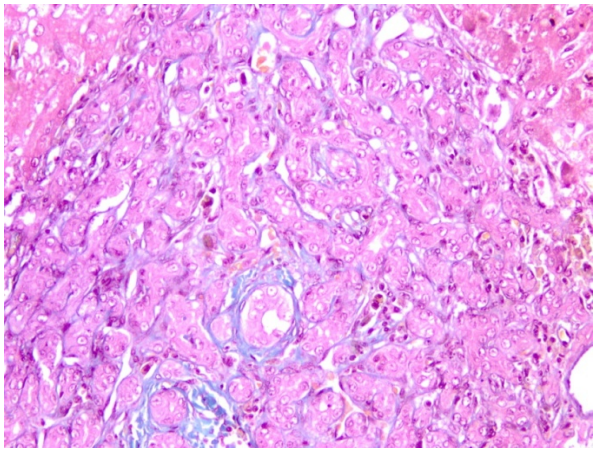

Fig.2. Marked proliferation of cholangiocytes, Masson's trichrome x200.

The second case was represented by a 12 year old female dog, Caniche breed, with cardiac cirrhosis. Grossly the liver presented micronodular cirrhosis. Microscopically we found a central-central bridging fibrosis, a marked dilatation of the sinusoids with the atrophy of the hepatocytes. The central-central bridges delimitate nodules, due to hypoxia the hepatocytes from the center of the nodules suffer macrovesicular steatosis. The hemosiderosis was evident. The histologic score given for assessment of fibrosis was 4. The score given for assessment of necroinflammatory activity was 5 (mild inflammation).

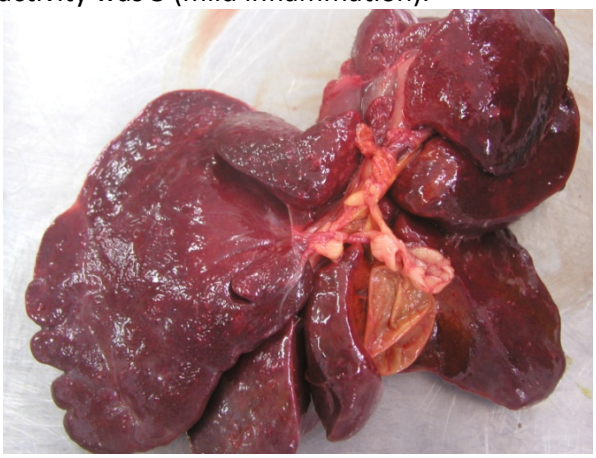

Fig.3. Micronodular cirrhosis.

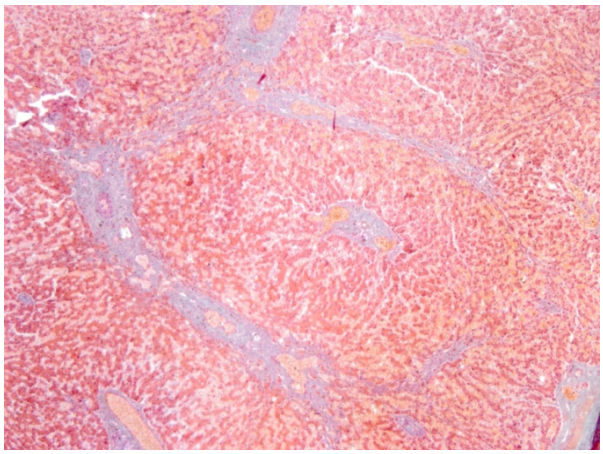

Fig.4. Central-central bridging fibrosis delimiting nodules, Masson's trichrome x100.

Eight cases were represented by central fibrosis due to chronic blood stasis. Grossly the liver was enlarged, firm and the cut surface shows alternating dark areas of congestion with pale areas of fatty change. The microscopic lesions were represented by central fibrosis, with segmentation of the central vein. The sinusoids were dilated and the hepatocytes from the central area suffered atrophy and necrosis or apoptosis. In the portal spaces and in the proximity of the central vein macrophages with ceroids were present. In one case we found a marked proliferation of blood vessels- a sign of adaptation and regeneration. The scores for necroinflammatory activity varied between 4 (minimal inflammation) and 7 (mild inflammation). The fibrosis was staged as follows: stage 1 fibrosis (minimal scarring) and stage 3 fibrosis (bridging fibrosis). Five cases were represented by hepatic tumors (both primary and metastatic). There were 2 cases of hemangiosarcoma, 1 of cholangiocarcinoma, 1 case of metastatic granulosa cell carcinoma, and 1 case of metastatic suprarenal cortical carcinoma associated with Cushing syndrome. Hemangiosarcomas as primary tumors are found to develop mainly in spleen, with frequent metastasis in liver, but the liver can also be the primary site of this tumor (2). The tumoral lesions were accompanied by different amounts of hepatocellular death and parenchimal fibrosis.

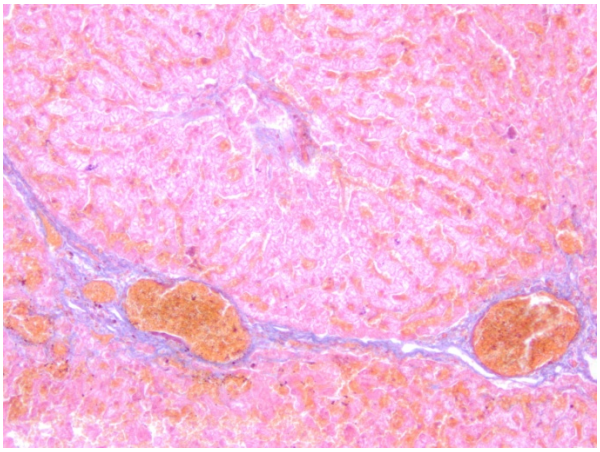

Fig.5. Central-central bridging fibrosis, Masson's trichrome x100

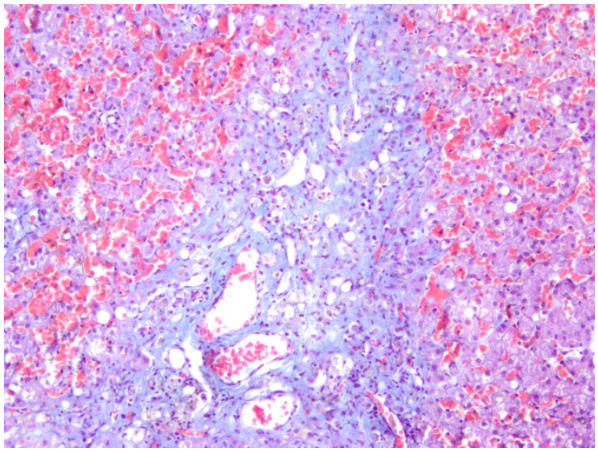

Fig.6. Blood stasis, marked proliferation of vessels, Masson's trichrome x100

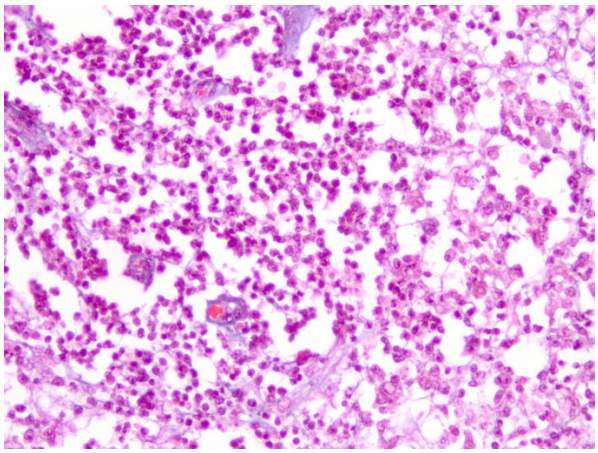

Fig.7. Hemangiosarcoma, Masson's trichrome x200.

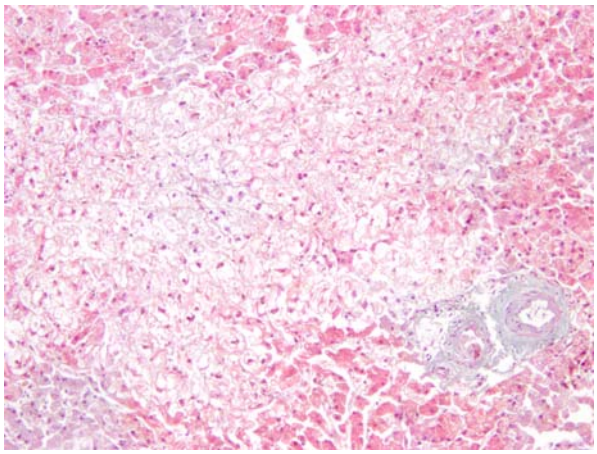

Fig.8. Metastatic suprarenal cortical carcinoma, Masson's trichrome x200.

CONCLUSIONS

1. Chronic hepatopathies are more frequently diagnosed in aged dogs, the median age being 10 years.
2. The use of scoring systems for objective, semiquantitative, reproducible description of the various morphological lesions of chronic hepatitis is useful tools for the characterization and interpretation of these disorders.
3. The etiology of a chronic inflammatory condition in the liver is generally never determined.
4. The most frequent cause of central fibrosis or central-central bridging fibrosis is chronic blood stasis due to right heart failure.

REFERENCES

1. **Elizabeth M. Brunt**,2000, Grading and staging the histopathological lesions of chronic hepatitis: the Knodell Histology Activity Index and beyond, HEPATOLOGY Vol. 31, No. 1,.241-246.
2. **Baba, A.I**., **C.Cătoi**,2007, Comparative Oncology, The Publishing House of the Romanian Academy, 228.
3. **Cătoi, C.,**2006, Anatomie patologică specială, , Editura AcademicPres, Cluj-Napoca, 354-372.
4. **Linda Ferrell**, 2000, Liver Pathology:Cirrhosis, Hepatitis, and Primary Liver Tumors. Update and Diagnostic Problems, Modern Pathology, VOL. 13, NO. 6, 679
5. **Knodell RG et al**.,1981, Formulation and application of a numerical scoring system for assessing histological activity in asymtomatic chronic active hepatitis. Hepatology, 1:431.
6. **Kearns Shawn**, 2009, Infectious Hepatopathies in Dogs and Cats, Volume 24, Number 4, 189-198.
7. **http://www.vin.com/vindbpub/searchpb/proceedings/pr05000/pr00128.htm.**
8. **www.janis7hepc.com/biopsy.htm.**

USE OF BLOOD PARAMETERS IN HEMATOLOGY AND CYTOLOGY HEALTH CRECK CARPS (CYPRINUS CARPIO) REARED IN SYSTEM SEMI-INTENSIVE

L. OGNEAN , Ani Alina Rodica, Cristina CERNEA, M. CERNEA, C. PESTEAN, Meda Maria MOLDOVAN

Universitatea de Ştiinţe Agricole şi Medicina Veterinara
Cluj– Napoca, str. Manaştur nr. 3 – 5, 400372;
Romania; Fax +40-264-593792
lognean@yahoo.com

SUMMARY

Haematologycal investigations have been performed on a batch of 12 carp (Cyprinus carpio), selected randomly from a heterogeneous group (n = 400) of fish reared in a semi-intensive system. The investigations consist of blood counts and cytomorphological examinations on colored blood smear (Panoptic). Blood samples were collected on EDTA by caudal vein puncture, the following determinations have been done: hematocrit (Ht), hemoglobin (Hb), total erythrocyte (E), total leukocyte (Le), leukocytes and reporting on erythrocytes / leukocytes that lymphocytes/granulocytes. Individual data have been recorded and interpreted, and at the end their statistical analysis, using GraphPad Instat 3 program, was done. The obtained results revealed low mean of erythrocytes total number (1.28 milioane/mm3) associated to the frequency of lower levels of hemoglobin concentrations (5.12 to 8.16 g / dl), corresponding to the evolution of a state of anemia for the investigated group of carp. The mean value of 27.67 mii/mm^3 of the total number of leucocytes was correlated with increased cellular defence mechanisms, expressed by a slight leukocyte reaction. Distribution of leucocytes subpopulations showed a tendency to granulocytic with neutrophilia (8%), associated with monocitozis (6%). A case with neutrophilia reached 12% and three cases of monocitozis reached 11%. Particular relevance was given to following individual ratios values of erythrocytes/leukocytes and lymphocytes/granulocytes, resulting in atypical average levels of 27/1 respectively 12/1. These values were judged as being below the minimum limits of 30/1 for erythrocytes/leukocytes and 20-50/1 for lymphocytes/granulocytes (Pirvu et al., 1984). The correlation between values of haematological indices and the reports of erythrocyte elements and leucocyte elements, showed persistent anemia syndrome and irritative effects due to the development of argulus on the carp group.

Keywords: Cyprinus carpio, haematological parametres, anemia, argulosis

INTRODUCTION

The evaluation of developments in health, wellbeing and weight dynamics in farmed fish is mainly based on biometric measurements and clinical examinations, and biochemical and haematological investigations are employed seldom. Determination of haematological indices in salmonids is limited by the existence of numerous controversies and uncertainties regarding the interpretation of data and even the technique adopted to obtain the hemogram (*Ognean şi col., 2009).*

Previous research has shown the biological value of major haematological indices needed to assess the health of fish, also suggesting the need to expand the tests with the investigation of factors related to cellular defence. Fish may be investigated from the point of view of both: (1) the fixed phagocytes activity, represented by fibroblasts and fibrocytes of connective tissue, lymphoid intestinal cell, angioblasts and endothelial cells of the liver, spleen or kidney; and (2) the mobile phagocytes activity, represented by granulocytes and macrophages. This is related to the main feature of the phagocytosis process, which is its dependence of temperature and the level of immunization. Trough the present research we establish the correlation of red and white cell indices needed to develop a model for haematological assessment of fish health based on the quantification of certain categories of items and ratios between them (erythrocytes/leukocytes, lymphocytes/granulocytes).

MATERIAL AND METHOD

Researches have been carried out on a batch of carp (*Cyprinus carpio*, and Galician variety Lausitz) at Mărtineşti farm, Cluj County. According to our objectives the study batch of carp (n = 400) was a heterogeneous biological material regarding the age, rearing system, weight and health. The investigated fish was at the state of consumption, and was reared in semi-intensive system, in pools of land, with the following mean water parameters in the period June-November 2009: O2 = 5.73 mg/l, pH = 7,66; KMnO4 organic substance = 55.6 Mg/l, nitrite = 3.11 mg/l, nitrates = 0.01 mg/l = 18.41 ° C average temperature. In practice this farm uses a technology of manual feeding. The feed ratio structure presents (1) physiological oscillations (mainly related to seasons and temperature) and (2) a series of random oscillations (management, feed consignment and storage). However, under these conditions what dominated was the adoption of combined technologies based on the administration of granulated feed in 1-3 portions, with varying quantities depending on water temperature and biomass. Regarding the biological indices one can observe the development towards poor health, mainly due to persistent argulus among the carp group. The main consequence of this body crustacean located on the carp is anaemia.
Blood tests consisting of blood counts and blood cytomorphological examinations on colored panoptic smear were carried out on 12 fish, randomly taken from the investigated group. For this analysis to be done we collected EDTA blood by tail vein puncture. Blood investigations have been carried out using known methods (De Luca et all., 1983; Ognean et al., 2007) to determine: hematocrit (Ht), hemoglobin (Hb), the total number of erythrocytes (E) and total number of leukocytes (Le). We also made panoptic on coloured blood smears (Dia–Quick Panoptic) to characterize subpopulations of leucocytes and the ratios: erythrocytes/leukocytes and lymphocytes/granulocytes. In parallel, control slaughter were carried out (10 carp), in order to analyse mainly the heart, kidneys, bowel, gastrointestinal contents and muscle tissue. Individual data have been recorded and interpreted, and at the end their statistical analysis, using GraphPad Instat 3 program, was done.

RESULTS AND DISCUSSIONS

When investigating haematological indices of carp from the selected group we reported some deviations of individual values and average values from physiological limits (Table 1). Correlation and analysis of these data was the basis for quantifying the health status and any subsequent biological effects. As outlined in Table 1 the development of an anaemia status was dominant, expressed particularly by the decrease of the total number of erythrocytes. Individual recorded

values of erythrocytes are between 0.99 and 1.56 milions/mm^3 with an average of only 1.28 million/mm^3. Values of hemoglobin also decreased, but significantly less than erythrocytes values, with an average of 6.69 g/dL and variations between 5.12 and 8.16 g/dl. In contrast, the hematocrit, erythrocyte constants and the total number of leukocytes have evolved between physiological limits, individual variations being insignificant. To justify the interpretations we made is enough to compare our data with data reported by some knowledgeable researchers in the field, who published the following oscillations of the main indices of haematological values at carp: 44-49% for Ht, 6-10 g/dl Hb; 2 millions/mm^3 the total number of erythrocytes, 93% for lymphocytes, 0% basophils (*Oțel V*. şi *Constantin Gh*., 1989). On the basis of the evolution of the total number of leukocytes, with individual values between 18 and 44 thousands/mm^3 and average indices of 27.67 thousands/mm^3 we found an increase in cellular defence mechanisms of investigated carp, expressed trough a slight leukocyte reaction (Table 1). After comparing these data with those from literature, a great variation in reported data was noted. Unlike most researchers in the field, who evaluate averages of 20 to 25 thousands/mm^3, there are authors who argue that the total number of leucocytes in healthy carp can vary even between 45 and 95 thousands/mm^3 (Pirvu et al., 1984).

Table 1. *Evolution of individual and average values of main haematological indices a group of carp (Cyprinus carpio)*

Carp (no.)	Ht (%)	Hb (g/dl)	Erythrocytes (T/L)	Leukocytes (G/L)	Average constant erythrocyte		
					VEM (fl)	HEM (pg)	CHEM (g/dl)
1	33,33	7,36	1,27	32,00	262,44	57,95	22,08
2	33,33	8,16	1,56	30,00	213,65	52,31	24,48
3	30,77	6,40	1,25	44,00	246,16	51,20	20,80
4	36,84	6,88	1,42	32,00	259,44	48,45	18,68
5	30,00	7,20	1,22	30,00	245,90	59,02	24,00
6	32,00	6,72	1,17	18,00	273,50	57,44	21,00
7	31,70	6,40	0,99	26,00	320,20	64,65	20,19
8	33,00	6,88	1,28	20,00	257,81	53,75	20,85
9	35,00	5,12	1,15	22,00	304,35	44,52	14,63
10	41,20	6,88	1,40	24,00	294,29	49,14	16,70
11	46,00	6,72	1,52	32,00	302,63	44,21	14,61
12	34,00	5,60	1,12	22,00	303,57	50,00	16,47
Average	***34,76***	***6,69***	***1,28***	***27,67***	***273,66***	***52,72***	***19,54***
St. Dev.	***4,627***	***0,786***	***0,169***	***7,177***	***31,586***	***6,128***	***3,348***

To support the above discussed issues it is worth to mention the evolution of leukocyte subpopulations, whose interpretation shows a tendency towards granulocytic with neutrophilia (8%) associated with monocytosis (6%) and limited proportion of lymphocytes (86%). As development of Leukocyte formula values show for a case the neutrophilia peaked 12% and the monocytosis reached 11% in three cases (Table 2).

Table 2. *Proportions and ratios of erythrocytes and leucocytes elements for a group of carp (Cyprinus carpio)*

Carp (no.)	Erythrocytes (%)	Leukocytes (%)	E/Le (no.)	Leukocyte subpopulations (%)			L/G (no.)	E+Le (no.)
				G (%)	L (%)	M (%)		
1	95,5	4,5	21/1	9	86	5	10/1	500
2	96,2	3,8	25/1	9	80	11	9/1	500
3	94,1	5,9	20/1	10	86	4	9/1	500
4	96,8	3,2	30/1	6	88	6	15/1	500
5	94,6	5,4	18/1	14	76	10	5/1	500
6	96,4	3,6	27/1	6	89	5	15/1	500
7	93,5	6,5	14/1	5	84	11	17/1	500
8	97,0	3,0	32/1	6	90	4	15/1	500
9	96,9	3,1	31/1	3	92	5	31/1	500
10	97,2	2,8	35/1	7	87	6	12/1	500
11	97,4	2,6	37/1	12	84	4	7/1	500
12	96,8	3,2	30/1	6	91	3	15/1	500
Average	**96.03**	**3.96**	**27**/1	**7.75**	**86,0**	**6.16**	**13.3**	**500**
St. Dev.	**1.305**	**1.305**	**7.139/1**	**3.137**	**4.621**	**2.855**	**6.719**	**-**

Even more relevant is the distribution of individual values and mean recorded levels of the ratios: erythrocytes/leukocytes and lymphocytes/granulocytes. In that respect what has to be mentioned are the atypical values of the 2 parameters: 27/1 for erythrocytes/leukocytes and 12/1 for lymphocytes/granulocytes. These values are below the minimum set point of physiological limits set by Pirvu et al. (1984), (30/1 for erythrocytes/leukocytes and 20-50/1 for lymphocytes/granulocytes). The correlation of values recorded for ratios established on smear between a considerable number of erythrocytes and leucocytes elements with those reported for the main hematological indices, indicates the persistence of irritative effects and feeble produced by the continuous action of a pathogen agent upon the group of carp. All these developments confirmed our diagnosis regarding argulus on the group of carp. The persistence of anemia, of leukocyte reactions and of irritative effects are consequences of the parasite breakthrough the skin, using the valve for blood feeding on its mouth (Fang, 1992, Verburg-van et all., 1995). In assessing the parasitism intensity, we found an average of 3 parasites/carp. In this context, we recall the finding of Gabriela Munteanu Bogatu D. (2008) according to which the presence of 20 parasites/carp may cause animal death. The morphological configuration of blood cells, highlighted on the panoptic coloured smears, there are also many controversies, some of them even excluding the monocytes-macrophages from the morphological configuration of blood cells (Pirvu et al., 1984). As outlined in the following two figures obtained from the investigated carp (Fig. 1 and 2.), we showed almost all features of peripheral blood cells except eosinophils, granulocytes and basophils.

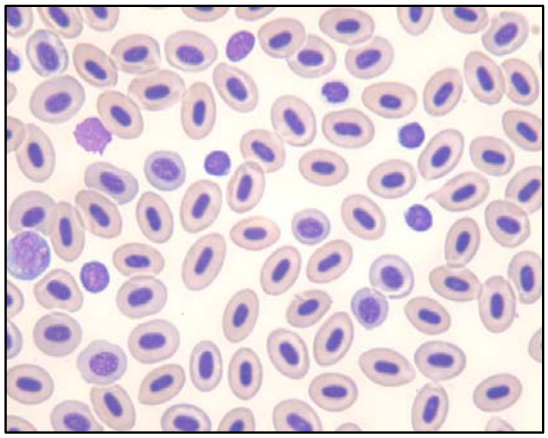

Fig. 1. *Citomorfologic characteristic aspect of carp peripheral blood; lymphocytes are predominant, and granulocytes and monocytes extremely rare (Dia - Quick Panoptic; X 100)*

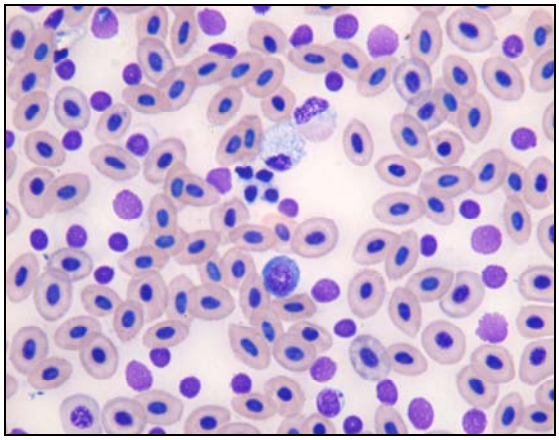

Fig. 2. *Citomorfologice dominant elements in the blood of carp with argulus; among the lymphocytes there are many monocytes macrophages in different states of activity (Dia - Quick Panoptic; X 100)*

In the context above presented issues we recall several features of the inflammatory response in fish. Thus, inflammation is often non-specific to fish, especially for large ones, such as carp (in specimens over 35 kg), which prefer muddy areas with holes, which feeds with plants, worms and insects. Caused by parasites, bacteria, viruses, radiation and various toxic substances, inflammation in fish is characterized by vasodilatation, leukocyte inflammation and exudative (Ellis, 1989). Neutrophil granulocytes as first leukocytes, located in the inflammatory spot, don't have a very relevant role, because they are engaged in extra cellular activity, releasing enzymes and free radicals that cause tissue destructions, while the phagocytic function is performed almost exclusively by macrophages (Tyzard, 1992). Lymphocytes are also present in the inflammatory spot. However the inflammatory response is not always sufficient to neutralize the pathogen agent which can be encapsulated with deposit of collagen, calcium and pigment (Fergusson, 1989).

CONCLUSIONS

1. Low average values reported for the total number of Erythrocytes of only 1.28 milllions/mm^3 (0.99 to 1.56 milllions/mm^3) and their association with the frequency of lower levels of hemoglobin concentrations (5.12 to 8.16g/dl) were the basis for detecting a state of anaemia of the investigated group of carp.
2. Individual variations are less significant and averages are falling within physiological limits for hematocrit (34.76%) and erythrocyte constants.
3. The evolution of the total number of leukocytes, with individual values between 18 thousands/mm^3 and 44 thousands/mm^3 and average of 27.67 thousands/mm^3, correspond to strengthening the cellular defense mechanisms of investigated carp, expressed trough a slight leukocyte reaction.
4. Distribution of leukocyte subpopulations showed a tendency towards granulocytic with neutrophilia (8%) associated with monocytosis (6%), a case with neutrophilia reaching 12% and 3 cases with monocytosis reaching 11%.
5. Particularly relevant are the individual values of ratios: erythrocytes/leukocytes and lymphocytes / granulocytes, resulting in atypical average levels of 27/1, respectively 12/1, both below the minimum limits of 30/1 and respectively 20-50/1.

6. The correlation of values of haematological indices with the ratios between erythrocytes and leucocytes elements, showed persistent anemia syndrome and irritative effects due to argulus development in the carp group.

BIBLIOGRAPHY

1. De Luca D., M. Wilson and G.W. Warr, 1983. Lymphocyte heterogeneity in the trout, *Salmo gairdnerii*, defined with monoclonal antibodies to IgM. Eur. J. Immunol, 13, 546-551.
2. Ellis, A.E., 1989. The immunology of teleosts. Roberts, R.J. (Ed.). Fish Pathology. 135-152.
3. Fange R., 1992. Fish Blood Cells. In: Hoar, W.S., D.J. Randall & A.P. Farrell (Eds.). Fish Physiology Acad. Press, Inc USA. XII Parte, B, 1-50.
4. Fergusson, H.W., 1989. Systemic pathology of fish. A text and atlas of comparative tissue responses in diseases of Teleosts. Iowa State Univ Press/Ames, 64-103.
5. Dumitru B. Gabriela Munteanu, 2008. Tratat de Ihtiopatologie. Excelsior Art., 2, 565-572.
6. Ognean L., Cristina Cernea, 2007. Aplicații practice de Fiziologie Medical – Veterinară. Ed. AcademicPres, Cluj-Napoca.
7. Ognean L. Barbu A., 2009. The estimation of the biostimulator potential of some fodder additives based on the main hematological and biometrical indices of brook trout (*Salvelinus Fontinalis M.*). Annals of the Romanian Society for cell biology, vol. XIV, 292-296.
8. Pârvu G., Barna I., Caprarin A., 1984. Hematologie veterinara practică, Ed. Ceres, Bucureşti, 95-97.
9. Oțel V., Constantin Gh., 1989. Ghid ihtiopatologic, Buletin de cercetari piscicole, supl. 2.
10. Sakai M., M. Kobayashi and H. Kawauchi, 1996. In vitro activation of fish phagocytic cells by GH, prolactin and somatolactin. J. Endocrinol, 151, 113-118.
11. Staykov Y., S. Denev, P. Spring, 2005. The effects of mannan oligosaccharide (Bio-Mos) on the growth rate and immune function of rainbow trout (*Salmo gairdneri irideus G.*) grown in net cages. Lessons from the past to optimise the future. European Aquaculture Society, Special Publication, 35, (June), 427-428.
12. Tizard I., 1992. The phylogeny of the immune system. In:Veterinary Immunology an introduction. W.B. Saunders Company (Ed.). Harcourt Brace Jovanovich, Inc. USA, 457-469.
13. Verburg-van Kemenade & J.H.W.M. Rombout, 1994. Characterization of immunoglobulin-binding leucocytes in carp (*Cyprinus carpio L.*). Dev. Comp. Immunol, 18, 45-56.
14. Verburg-Van-Kemenade, B.M.L., F.A.A.Weyts, R. Debets, G. Flik., 1995. Carp macrophages and neutrophilic granulocytes secrete an interleukin 1-like factor. Com. Immunol, 19, 59-70.

THE USE OF SOME QUICK TESTS FOR BLOOD TYPING IN DOGS AND CATS

L. OGNEAN, S. HABAGO, Meda MOLDOVAN, I. MORAR
Universitatea de Ştiinte Agricole şi Medicina Veterinară,
Facultatea de Medicina Veterinară, str.Manaştur 3-5,
400372; Cluj– Napoca, Romania; Fax +40-264-593792
lognean@yahoo.com

SUMMARY

The purpose of this study was to establish the efficacy of the commercially available blood typing kits for canine and feline potential blood donors screening. Regarding this we tested 10 animals, using 2 types of kits (Rapid Vet®H -DMS Laboratories and Rapid DMEVET -Alvedia) and the results revealed four DEA1.1 positive dogs , one DEA 1.1 negative dog and five cats type A positive. We appreciate these tests simple, practical, operatives, the Alvedia kits beeing easier to interpret than Card tests and allow interpretation even if autoagglutination is present or if the animal has a low hematocrit value. In cats, this tests allow the identification of all recognized blood types (A, B and AB) and avoid the immediate transfusion reactions. We strongly recommend DEA 1.1 blood type testing in dog donors and receivers, because this is the most immunogenic blood type. The usage of the two quick tests for blood typing is useful in blood donors screening of DEA1.1 negative dogs, the other blood types being requested only in case of Crossmatch test incompatibilities or hemolytic transfusion reaction.

Keywords: blood typing tests, transfusion compatibility, dog, cat.

INTRODUCTION

The progress made for establish blood compatibility by blood typing or crosmatch tests, already a current practice in dogs and cats, made possible the extension of blood transfusion therapy in different species of animals even in birds and ferrets (Hohenhaus, 2004). The selection of compatible blood is essential for the safety and efficacy of this therapeutically procedure. Although the preformed plasmatic antierythrocytes antibodies has no clinical importance in dogs, each blood unit can be distinct of antigenic viewpoint and so in at least 5 days the receiver immune system can produce posttransfusion antibodies to the foreign transfused antigens. By Crossmatch testing it is possible to prevent the immediate imune adverse reactions, but not the delayed ones, which are due to patient sesitization, in this case repeating the tests in future transfusion is required (Stephen P. DiBaktola, 2006). To limit the sensitization of the patient to the blood products is recommended to test blood compatibility by blood typing in the first or even in the second transfusion, even if DEA 1.1 negative blood is used. As is well known, dogs can develop alloantibodies to any blood type antigen that they don't possess, the only antigen with clinical significance is DEA 1.1 because it is highly immunogenic (Giger U and col., 1995, Giger U.,2000). Unlike dogs, cats may possess plasmatic antierythrocyte isoantobodies, which in case of incompatible transfusion can produce severe adverse reactions, even fatal and so in this species is mandatory the pretransfusion evaluation of compatibility by blood typing and crossmatching.

MATERIALS AND METHODS

This study is mainly focused on assessing the effectiveness of two commercially available tests in our country, for establishing the optimal transfusion compatibility level on two patterns of potential donors by determining the blood group DEA1.1 in dogs and A, B in cats, using Rapid Vet®H (DMS Laboratories) and Rapid DMEVET (Alvedia) kits. The research was carried out on dogs (n=5) and cats (n=5), which represented the potential donors usable in a private practice and in clinics of the Cluj-Napoca Veterinary Faculty. From these potential donors, available for the preparation of blood products, were collected blood samples in EDTA tubes for hematology (using automatic analyzer Abacus Junior Vet), blood typing, with two types of kits and establishing blood compatibility level. For blood typing in the selected dogs and cats we resorted to the use of 2 quick methods: a CARD based agglutination test (RapidVet®H - DMS Laboratories) and ALVEDIA (DMEVET) kits. The general principle in these blood typing methods consist in revealing the agglutination reactions that occurred within seconds or minutes, released by specific monoclonal antibodies bound to erythrocyte antigens on the membrane surface. The interpretation will be based on the fact that the lack of agglutination indicates a negative result, the investigated animal being considered negative for that tested blood type. However it must be noted that currently there is no universally accepted standard method for determining blood type in dogs. (Urs Giger, 2005).

The CARD method involves a simple technique, based on the detection of visible agglutination reaction between tested erythrocytes antigens and the lyophilized specific monoclonal antibodies (anti DEA1.1 for dogs, respectively anti A and anti B for cats). The procedure for testing blood type in dogs involves the following steps:

1. Preparation of the card, positive control red blood cells and dilution liquid;
2. Autoagglutination verification by reconstruction of the monoclonal antibodies with a dilution liquid (resulting antiserum) in the designated area for the control test;
3. Homogenization of the antiserum with 50 microliters of whole blood with a wooden rod pressing firmly onto the card;
4. Reading the autoagglutination result a positive result invalidates the test, a negative result allows further testing;
5. Repeating the procedures from paragraphs 2 and 3 on the areas designated for performing the positive control test, respectively patient test;
6. Reading the results on the mentioned areas - in positive control test agglutination is always present and it also appears in positive individuals in the area for patient testing;
7. Blood group testing in cat provides a similar procedure like that described in dogs and differs only that it lacks the positive control test.

The rapid ALVEDIA method is based on the migration of red blood cells on a membrane, that has previously been specially treated with specific monoclonal antibodies (anti DEA1.1 for dogs and antiA, antiB for cats), under the influence of a buffer flux moving along due to capillary action.

In these conditions, positive erythrocytes bounded by specific antibodies are highlighted as a red line on the membrane. To confirm the accuracy of the migration line there is also a specific control line for comparison (C), required to be identified in each valid test. For testing, with these kits, can be used fresh whole blood (including umbilical cord blood) and also anticoagulant treated blood (EDTA, CPD-A, ACD-B, ACD-A, heparin). According to the protocol, test sequence involves the following steps:

1. Preparation of the migration strip and fluid buffer
2. Homogenization of a drop of blood, taken with an absorbent strip, with three drops of dilution fluid, deposited in the test well

3. Placing the migration strip end in the prepared well and maintained it upright for two minutes to achieve the migration
4. Read the results by the identification of the migration red line and control line (C)

The interpretation implies two possibilities: the appearance of the migration red line and control line when the test is positive, respectively the lack of the migration red line and the presence of the control line when the result is negative.The obtained individual data were recorded and compared and for their interpretation we appeal to the results obtained by other researchers with basic concerns in blood compatibility and transfusion theraphy in dogs and cats.

RESULTS AND DISCUSSIONS

Reading and interpreting the obtained results in the 5 tested dogs showed dominance of DEA1.1 group, 4 of the dogs were positive and only one negative. Regarding the tested cats, we observed only the presence of blood type A, as we expected. Expression of the results at an appreciable level required maximum two minutes in all the tested cases. For reading the agglutinations by Card method we appeal to slightly tilting the support in order to clarify the reaction and indicated blood type (fig.1). As indicated in the indication sheet, we also noted that reading the results after more than 2 minutes may lead to false positive reactions. When the autoagglutination reaction on the card is positive the test will be invalidated. In feline tests, the agglutination of both areas may signify the AB blood type, but probably it is because of autoagglutination due to evolution of some diseases with autoimmune component (Wayne E. Wingfield and Marc R. Raffe, 2002), this blood type being very rare (Giger U.,2000). When the hematocrit value is very low (below 10%), blood centrifugation to concentrate red blood cells avoids obtaining a false result (Douglas H. Slatter, 2003).

Figure 1. The appearance of agglutination reactions to positive tests obtained in the investigated dogs

The found bibliographical data showed that this test (CARD) is used in clinical practice for over a decade (Giger U.,2000).

The interpretation of Alvedia test showed clear positive reactions, expressed by the appearance of a red line in the marked area for the specific type, indicating the appropriate blood group. We also obtained reliable results even when autoagglutination was present, because the membrane did not allowed the migration of agglutinated erythrocytes. According to our results, the intensity of agglutination reaction in case of the Card method and the migration line color in Alvedia method differs between individuals and to the positive control because in dog, unlike human, can occur several primary blood groups in the same individual, when red blood cells possesses each blood group antigen. Such individuals contain fewer DEA1.1 antigens. Following the tests carried out on the investigated dogs and cats, the intensity of Card agglutination method was reduced in each evaluation and did not persisted after drying, on the other hand the positive line in Alvedia test was evident and stable. Currently there is a wider range of blood group tests, but are not yet available on the market in Romania. Of these, the Michingan State University (MSU) is the most complex because of the polyclonal antisera used (anti DEA 1.1, DEA 1.2, DEA 3, DEA4 şi DEA5). For some blood groups (DEA 6, DEA7) there are no available antisera. The **GEL** test is adapted to modern tehniques of human blood typing and is based on erythrocytes agglutination in microcolumns, which contains anti DEA1.1 monoclonal antibodies, in a matrix of gel (Bromilow IM, 1991). The **TUBE** test (proposed by researchers in Japan) is based on a new classification of erythrocytes antigenic systems, with 9 blood groups in dogs, using 4 types of monoclonal antibodies (A, B, D şi E) (Kaoru A and Kyo K, 2001). As indicated by the kits manufacturer, this new antigenic system differentiates three levels of blood transfusion compatibility (Ognean L et al., 2009).

CONCLUSIONS

1. We evaluated that the tested blood typing kits available in our country are simple, operative, practical, Alvedia tests being easier to interpret then the Card test, in which may occur uncertainties in interpreting weak intensity reactions (low titer of plasmatic isoantibodies)
2. Alvedia method has advantages over the test card because allows testing even if autoagglutination is present or the patients are very anemic, the technique being more accessible and the used strips can be placed in their original packing and stored for a long time.
3. The use of two blood group tests in cats, allows the identification of the three existing groups in this species, avoiding the immediate transfusion reactions, which can be fatal because of natural titers of serum isoagglutinins.
4. We recommend testing DEA 1.1 blood group in donor and receiver dogs, as this group is the most clinically important in transfusion therapy, being the most immunogenic.
5. We believe that using the two rapid tests for blood group typing is useful in the screening of the ''universal'' DEA1.1 negative donors, the determination of other groups is indicated in case of Crossmatch tests incompatibilities or when is suspected a hemolytic transfusion reaction

REFERENCES

1. Douglas H. Slatter, Textbook of Small Animal Surgery, edition a3a, ed. Saunders, 2003
2. Giger U, Gelens CJ, Callan MB, et al: An acute hemolytic transfusion reaction caused by dog erythrocyte antigen 1.1 incompatibilities in a previously sensitized dog. J Am Vet Med Assoc 206:1358-1362, 1995

3. Giger U., Blood typing and crossmatching to ensure compatible transfusions. In:Bonagura JD, ed. Kirk's current veterinary therapy 13th ed.Philadelphia:WB Saunders Co;396-399, 2000
4. Giger U., Blais MC, Ensuring blood compatibility: update on canine typing and crossmatching.Proc Am Coll Vet Intern Med 2005
5. Hohenhaus Ann E., Importance of Blood Groups and Blood Group Antibodies in Companion Animals, Transfusion Medicine Reviews, Vol 18, No 2 (April), 2004: pp 117-126
6. Kaoru A, Kyo K. Determination of canine and feline blood types using monoclonal antibodies. Provet 2001; 10:12-16Ognean L şi col., 2009
7. Ognean Laurenţiu, Cristina Cernea, Viorel Miclaus, Adela Joanta, Meda Moldovan. Investigation of erythrocyte antigenic profile and blood compatibility by blood typing in dogs. Studia Universitatis "Vasile Goldiş", Seria Ştiinţele Vieţii Vol. 19, issue 1, 2009, pp. 63-68
8. Wayne E. Wingfield, Marc R. Raffe, The Veterinary ICU Book, Ed.Teton NewMedia, 2002

MORPHOPATHOLOGICAL CHANGES IN AVIAN INFECTIOUS BRONCHITIS, IN THE RESPIRATORY FORM , IN CHICKENS AND ASPECTS OF HISTOPATOLOGICAL DIAGNOSIS OF DISEASE

A. OLARIU JURCA[1], M. COMAN[1], I. OLARIU-JURCA[1], A. STANCU[1], A. LAZĂU[1], E. AVRAM[2]

1. Faculty of Veterinary Medicine Timişoara, 119 Calea Aradului
2. DSVSA Satu-Mare

ABSTRACT

Avian infectious bronchitis, respiratory form, was macroscopically and microscopically diagnosed in 67 corpses of chickens, aged 4-24 days, ROSS 308 hybrids.Macroscopically we observed the following lesions: 4 days old chickens presented coryza and serous airsacculitis, exudate in the thoracic cavity, serous and/or sero-catarrhal tracheitis, active and/or passive pulmonary congestion; at 17-21 days old chicks noted coryza and catarrhal sinusitis, catarrhal laryngotracheitis and airsacculitis, passive congestion, pulmonary edema, catarrhal bronchopneumonia and pulmonary dystrophies.Histopathologycal was observed in all ages tracheal epithelium hypertrophy by ciliated columnar cells hyperplasia accompanied by their deciliation and fall into the tracheal lumen, *hypertrophy of the tracheal mucosa* with lymphohistiocitar hyperplasia, pronounced ectasia of the alveolar capillaries and serous exudates; in the trachea, besides the recorded changes, at 17-21 days old chickens has revealed metaplasia of tracheal epithelium from cylinder to cubic, becoming flattened and pluristratified aspect, numerous lymphoid follicles and many pseudoglands in the lamina propria; in the lungs was identified congestion and serous exudates of alveolar septa, pneumocytes swelling and their fall into the alveolar lumen.

Keywords: chicken, avian infectious bronchitis, respiratory form, morphopathological changes.

Avian infectious bronchitis (BIA) is a coronavirosis specified to all ages of hens but with greater lethality in chickens (2, 3, 4). Clinically affected chickens shows dyspnea, tracheal rales, sneezing with nasal discharge, and different pathological lesions depends on age, pathogenity of the strain and the immune status of birds (6, 7).

MATERIALS AND METHODS

In the discipline of Legal Medicine, during October 2009-March 2010, were carried morphological research on 67 corpses of chickens, ROSS 308 hybrids, aged 4-24 days (22 for 4 days, 24 for 17 days, 21 for 24 days), coming from intensive systems growth,. Macroscopic examination reported structural changes translated by serous, catarrhal, fibrinous inflammation of airway and air sacs and congestion, edema and catarrhal bronchopneumonia in most 17-24 days old chickens. These changes guided us to the morphopathological diagnosis of avian infectious bronchitis, respiratory form. Clear diagnosis was determined by ELISA technique. For this test were taken randomly blood sampled from chickens which clinical showed respiratory signs (dyspnea, tracheal rales, sneezing with nasal discharge). For performing histopathological examination were sampled from the trachea, lungs and air sacs. Samples were fixed in formaldehyde sol.10%, then processed by the paraffin technique, sectioned at 6 µm and colored by HEA method. Histological preparations thus

obtained were microscopically examined with increasing targets, interpreted and then the most characteristic lesions were microphotographs.

RESULTS AND DISCUSSION

External examination of corpses noticed, in most cases, mediocre state of maintenance, lack of skin elasticity and enoftalmy, pale of oral, nasal, conjunctival and tracheal mucosa and their covered with a semifluid whitish gray deposit. At 7 corpses of 24 days old chickens, on the internal front of the opacificated air sacs were preset friable fibrin yellowish gray deposits, which were identified in the lower third of trachea. At 4 days old chickens, lung were increased in volume, pasty, with bright red tense pleura and presented negative docimasy- active pulmonary congestion (Fig.1). Chickens of 17 to 24 days old presented following lesions: in 12 cases the cherry red lungs were increased in volume and weight, pasty and with docimasy between two water - passive pulmonary congestion; in 20 cases the lungs were increased in volume and weight, whitish gray colored and pasty which on section expressed a sparkling red liquid and docimasy was between two water - inflammatory pulmonary edema; in 16 cases lungs were increased in volume and weight, with positive docimasy and red tense pleura – catarrhal bronchopneumonia (Fig.2).
Histopathological was revealed, at all ages: swelling of ciliated columnar pseudostratificat tracheal epithelium, ciliated cells hyperplasia accompanied by their deciliation and fall into the tracheal lumen- serocatharral tracheitis (Fig.3), hypertrophy of the tracheal mucosa with lymphohistiocitar hyperplasia in the lamina propria which causes a volume increase that is about 8-10 times higher than normal, ectasia of the alveolar capillaries accompanied by a serous exudates on different area (Fig.4); in the trachea, besides the recorded changes, at 17-24 days old chickens has revealed metaplasia of tracheal epithelium from cylinder to cubic, becoming flattened and pluristratified aspect, numerous lymphoid follicles and many pseudoglands in the lamina propria; in the lungs was identified congestion and serous exudates of alveolar septa, catarrhal bronchopneumonia (Fig.5), pneumocytes swelling and their fall into the alveolar lumen, swelling and partial separation of the bronchial and tracheal epithelium, inflammatory cell infiltration in alveolar septa in the lumen of alveoli, bronchus and trachea, swelling and partial peeling of bronchial epithelium; epithelial surface of the air sacs presented a network of fibrin partially exfoliated and in young tissue blade were noted vascular changes translated by ectasias, congestions, edema and diffuse lymphocytic infiltration, fibrinous aerosaculitis (Fig.6).
Morphological changes identified by us in the trachea, bronchi and lungs coincide with those reported in the literature (1, 5, 6, 7).

Fig.1Active congestion
(4 days old chickens)

Fig.2. Catharral bronchopneumonia
(17-24 days old chickens)

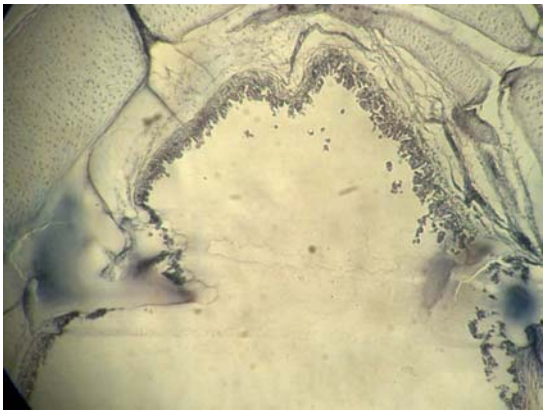

Fig.3. Serocatharral tracheitis (4 days old chickens) epithelial hyperplasia, ectasia of the tumefaction ,deciliation and fall into the tracheal lumen. Col.HEA x 200

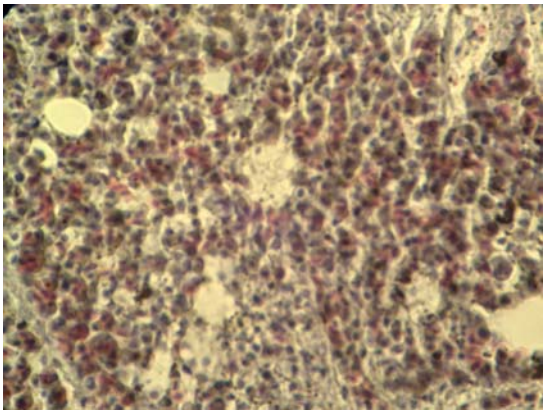

Fig.4.Active pulmonary congestion (4 days old chickens) alveolar capillaries. Col. HEA x 100 .

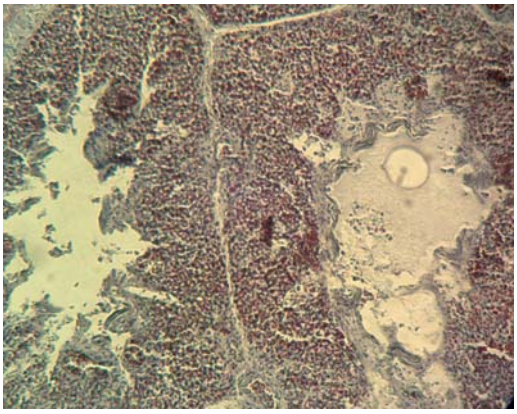

Fig.5. Catarrhal bronchopneumonia (17-24 days old (17-24 days old chickens) pneumocytes swelling and their fall network of fibrin on the surface of the air sacs, edema, swelling and peeling of mesangial cells. Col.HEA x 200.

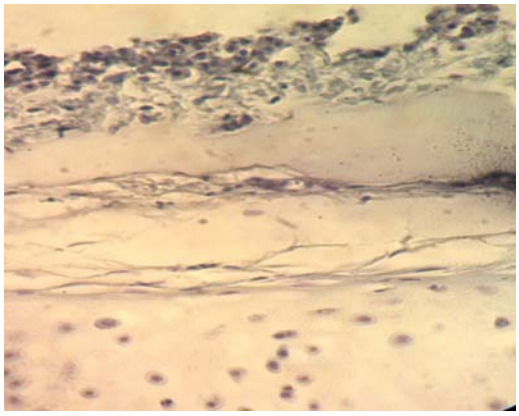

Fig.6. Fibrinous aerosaculitis chickens) into the alveolar lumen and sero-cellular exudates in the parabronchia. Col.HEA x 200.

CONCLUSIONS

Avian infectious bronchitis was anatomopathological diagnosed at 67 bodies of chickens, Ros308 hybrids, aged between 4 and 24 days.Macroscopical and microscopical was identified: at 4 days old chickens – coryza and serous airsacculitis, serous and/or serocatharal tracheitis, active and/or pulmonary congestion; at the chickens aged between 4 and 24 days – coryza and catharral sinusitis, fibrinous laringotracheitis and airsacculitis, passive congestion, inflammatory pulmonary edema and catharal and/or mucopurulent bronchopneumonia. Catharal and/or mucopurulent bronchopneumonia is the consequence of associated flora intervention to individuals with low immune status due infection with virus BIA.· At 4-17 days old chickens were predominant serous and/or catarrhal inflammatory lesions of the airways and active and/or passive pulmonary congestion. This age group has presented the highest percentage of morbidity and mortality (32%). Also were identified lesions of catarhal bronchopneumonia at 17-24 days old chickens. At 17-24 days old chickens, the predominant lung lesions were those of catarhal bronchopneumonia .

BIBLIOGRAPHY

1. **BABA, I. A., (1996)** – *Diagnostic necropsic veterinar,* Ed.Ceres, Bucureşti.
2. **CAVANAH, D., NAQI, S. A. (2003)** - *Infectious Bronchitis* În: Diseases of poultry, Editor-in-chief, Saif Y. M., 11'th Edition, Blackwell Publishing, Iowa State University Press, 101-121.
3. **COOK, J. K. A., CHESHER, J., ORTHEL, F., WOODS, M. A., ORBELL, S. J., BAXENDALE, W., HUGGINS, M. B. (2000)** - *Avian pneumovirus infection of laying hens: experimental studies,* Avian Pathology, 29, 545-556.
4. **HOFSTAD, M. S., H. W. YODER, Jr. (1996)** - *Avian infectious bronchitis-virus distribution in tissues of chicks*, Avian Dis, 10, 230-239.
5. **PAUL,I., (1996)** – *Etiomorfopatologie veterinară*,Ed. All.
6. **PERIANU,T. (2005)** – *Boli infecțioase ale animalelor-viroze*,vol. II, Ed.Universitas XXI.
7. **VASIU,C. (2006)** – *Virusuri,viroze şi boli prionice la animale*, Ed. Mega, Ed.Argonaut

POTASSIUM DICHROMATE IMPACT ON SOME BIOMARKERS OF FEMALE PHYSICAL DEVELOPMENT (VAGINAL OPENING) IN RATS (THREE GENERATION STUDY)

Snejana PETROVICI[1], Alexandra TRIF[1], Muselin, F.[1], Cristina, R. T.[1], Milca PETROVICI[2]
[1]Banat's University of Agricultural Sciences and Veterinary Medicine, Faculty of Veterinary Medicine, Calea Aradului, 119, 300645, Timişoara email: petrovicisnejana@yahoo.com
[2]West University of Timisoara, Faculty of Chemistry, Biology, Geography, 300115, Timişoara Pestalozzi n16A, Romania

ABSTRACT

The aim of this study was to emphasize potassium dichromate impact on some biomarkers of female physical development in rats (age and body weight at vaginal opening).The study, carried out on three generations (F_0, F_1 and F_2) White Wistar female rats exposed to potassium dichromate, pointed out that the age at the vaginal opening was the most delayed in F_2 generation, followed by F_1 and F_0, with significant differences between F_2 and F_0 generations.The weight at the vaginal opening was the lowest in F_2 generation, followed by F_1 and F_0 generation, with significant differences between F_1, F_2 and F_0 generations.

Key words: chromium, rat, vaginal opening

INTRODUCTION

Various chromium based industries like tannery, chemical processing unit, steel industry and dye manufacturers release chromium compounds into environment. Workers and residents of chromium based industries are highly exposed to chromium. Excess chromium exposure is associated with various pathological condition including reproductive dysfunction [1, 5, 6, 16].

MATERIALS AND METHODS

The study was carried out first on F_0 generation: 28 female White Wistar rats exposed three months to potassium dichromate, mated with males exposed also three months to potassium dichromate. The exposure of F_0 female rats continued during pregnancy and lactation period. The F_1 generation females (also 28) were exposed to potassium dichromate *in utero*, in suckling period, and after that via drinking water until sexual maturity. They were mated with other males exposed to the same doses of potassium dichromate to obtain F_2 generation. The exposure followed during pregnancy and lactation, the resulting female offspring, belonging to $\mathbf{F_2}$ generation being further exposed until sexual maturity. So, the $\mathbf{F_2}$ generation was exposed *in utero,* during suckling period and until sexual maturity. In $\mathbf{F_0}$, $\mathbf{F_1}$ and $\mathbf{F_2}$ generation, the age and weight (by technical balance) at vaginal opening (puberty onset) were evaluated. Potassium dichromate (Cr VI) was administered in drinking water as follows: E_1: 25 mg Cr (VI)-LOAEL [16], E_2: 50 mg Cr (VI) (2 x LOAEL), E_3: 75 mg Cr (VI) (3 x LOAEL), C: tap water not containing chromium. All results were statistically analyzed by Anova method and Student test. Food and water were *ad libitum.*
The experiment was in accordance with present laws regarding animal welfare and ethics in animal experiments [10, 11, 12, 13, 14, 15].

RESULTS

The age and body weight at the vaginal opening moment in F_0, F_1 and F_2 generations are presented in table 1, figure 1.

Table 1.

Age and weight at vaginal opening moment

F_0 generation						
	age			**weight**		
	X±Sx	**D.S.**	**N.C. 95%**	**X±Sx**	**D.S.**	**N.C. 95%**
C	40.13±0.02	0.05	0.05	95.19±0.04	0.11	0.08
E_1	50.03±0.02	0.05	0.05	118.73±0.01	0.02	0.08
E_2	60.09±0.03	0.09	0.05	142.03±0.06	0.15	0.08
E_3	70.04±0.03	0.08	0.05	165.30±0.03	0.08	0.08
X_E	**60.05±5.78**	**10.01**	**13.17**	**142.02±13.44**	**23.29**	**21.69**
F_1 generation						
	age			**weight**		
	X±Sx	**D.S.**	**N.C. 95%**	**X±Sx**	**D.S.**	**N.C. 95%**
C	41.00±0.33	0.93	0.70	90.84±0.54	1.53	1.12
E_1	70.25±0.45	1.28	0.70	79.35±0.58	1.64	1.12
E_2	80.12±0.30	0.83	0.70	70.03±0.39	1.11	1.12
E_3	88.00±0.27	0.76	0.70	61.11±0.64	1.81	1.12
X_E	**79.46±5.13**	**8.89**	**13.17**	**70.16±5.27**	**9.12**	**21.69**
F_2 generation						
	age			**weight**		
	X±Sx	**D.S.**	**N.C. 95%**	**X±Sx**	**D.S.**	**N.C. 95%**
C	42.29±0.03	0.09	0.06	92.24±0.06	0.16	0.11
E_1	75.16±0.03	0.08	0.06	76.04±0.04	0.11	0.11
E_2	85.10±0.02	0.04	0.06	66.91±0.05	0.12	0.11
E_3	93.19±0.04	0.11	0.06	57.97±0.05	0.14	0.11
X_E	**84.48±5.21**	**9.03**	**13.17**	**66.97±5.22**	**9.04**	**21.69**

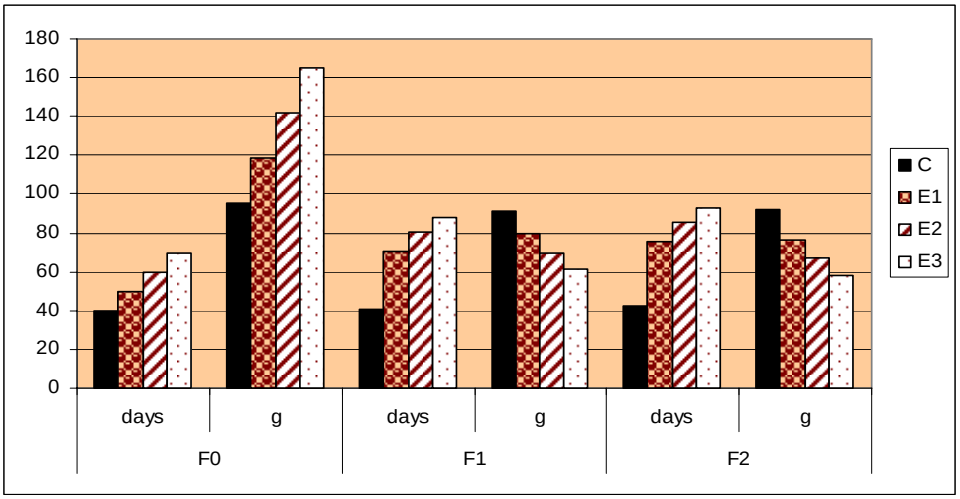

Figure 1. Age (days) and weight (g) at the vaginal opening moment in three potassium dichromate exposed generations

F_0 generation. In E individuals, the vaginal opening moment was significantlly ($p<0.01$) delayed comparative to C group and over the physiological limits (33-43days) [3] (E_1/C: +24.66%, E_2/C: +49.73%, E_3/C: +74.53%), at a body weight between 118.73 and 165.30g (considered physiological)

[3] (E_1/C: +24.72%, E_2/C: +49.20%, E_3/C: +73.65%). The delay of the vaginal opening moment was directly, significantly (p<0.01) correlated with the exposure level (p<0.01): (E_2/E_1: +20.10%, E_3/E_2: +16.55%, E_3/E_1: +39.99%). Between the body weight at the vaginal opening moment and the level of exposure a direct, significant (p<0.01) correlation was established: (E_2/E_1: +19.62%, E_3/E_2: +16.38%, E_3/E_1: +39.22%).

F_1 generation. In E individuals, the vaginal opening moment was significantly (p<0.01) delayed comparative to C group and over the physiological limits (33-43days) [3] (E_1/C: +71.34%, E_2/C: +95.41%, E_3/C: +114.63%) and at a body weight under 100 g (61.11 – 79.35 g) (considered physiological) [3] and under the C group weight (E_1/C: -12.64%, E_2/C: -22.90%, E_3/C: -32.72%).

The delay of the vaginal opening moment was directly, significantly (p<0.01) correlated with the exposure level (E_2/E_1: +14.04%, E_3/E_2: +9.83%, E_3/E_1: +25.26%). Between the body weight at the vaginal opening moment and the level of exposure an inverse, significant (p<0.01) correlation was established (E_2/E_1: -11.74%, E_3/E_2: -12.73%, E_3/E_1: -22.98%).

F_2 generation. In E individuals, the vaginal opening moment was significantly (p<0.01) delayed comparative to C group and over the physiological limits (33-43days) [3] (E_1/C: +77.72%, E_2/C: +101.22%, E_3/C: +120.35%) and at a body weight under 100 g (57.97 – 76.04 g) (considered physiological) [3] and under the C individuals weight (E_1/C: -17.56%, E_2/C: -27.46%, E_3/C: -37.15%).

The delay of the vaginal opening moment was directly correlated, significantly (p<0.01), with the exposure level (E_2/E_1: +13.22%, E_3/E_2: +9.50%, E_3/E_1: +23.98%). Between the body weight from the vaginal opening and the level of exposure, an inverse, significant (p<0.01) correlation, was established (E_2/E_1: -12.006%, E_3/E_2: -13.36%, E_3/E_1: -23.76%).

DISCUSSIONS

As influence of the period of exposure, the age at the vaginal opening was the most delayed in F_2 generation (X_E: 84.48), followed by F_1 (X_E: 79.46) and F_0 (X_E: 60.05), with significant (p<0.01) differences F_2 and F_0 generations: $X_EF_1//X_EF_0$: +32.32%, X_EF_2:/X_EF_1: +6.31%, X_EF_2:/X_EF_0: +40.68%.

The weight at the vaginal opening was the lowest in F_2 generation (X_E: 66.97), followed by F_1 generation (X_E: 70.16) and F_0 (X_E: 142.02), with significant (p<0.01) differences between F_1, F_2 and F_0 generations: X_EF_1/X_EF_0: -50.59%, X_EF_2:/X_EF_1:- 4.54%, X_EF_2:/X_EF_0: -52.84%. The delay of the vaginal opening (puberty onset) consecutive potassium dichromate exposure was also recorded by other authors: Staniek, H., et al., 2010 [9], Rodriguez R., 2007 [8]. De Lucca et al., 2009 [2], Staniek, H., et al., 2010 [9], Rao, M.V, et al., 2009 [7], Matos, R. C., et al., 2009 [4], are other authors that reported the decrease of the body weight consecutive potassium dichromate exposure. Kei-Ichiro et al., 2000 [3], pointed out a correlation between the body weight and the moment of the vaginal opening, the importance of these markers, and the fact that the vaginal opening depends more of the weight than of the age. In conclusion, in three generations comparative experiment regarding the impact of potassium dichromate on some biomarkers of female physical development in female rats, the age at the vaginal opening was the most delayed in F_2 generation, followed by F_1 and F_0, with significant differences between F_2 and F_0. The weight at the vaginal opening was the lowest in F_2 generation, followed by F_1 generation and F_0, with significant differences between F_1, F_2 and F_0.

REFERENCES

1. Chandra, A. K., Chatterjee, A., Ghosh, R., Sarkar, M., (2010): Vitamin E – supplementation protect chromium VI – induced spermatogenic and steroidogenic disorders in testicular tissues of rats, Food and Chemical Toxicology, in press;
2. De Lucca, R. C., Dutrey, P. L., Villarino, M. E., Ubios, A. M., (2009): Effect of different doses of hexavalent chromium on mandibular growth and tooth eruption in juvenile Wistar rats, Experimental and Toxicologic Pathology 61, pp. 347-352;

3. Kei-Ichiro Maeda. Satoshi Ohkura., Hiroko Tsukamura, (2000): Physiology of Reproduction, Academic Press, Japan, , pp. 145-456;
4. Matos, Rita, C., Vieira, Catarina, Morais, Simone, Pereira, Maria de Lourdes, Pedrosa, J., (2009): Nephrotoxicity effects of the wood preservative chromium copper arsenate on mice: Histopathological and quantitative approaches, Journal of Trace Elements on Medicine and Biology, 23, pp. 224-230;
5. Oliveira, Helena, Spano, M., Guevara, M. A., Santos. Teresa Margarida, Santos, C., Pereira, Maria de Lourdes, (2010): Evaluation of in vivo reproductive toxicity of potassium dichromate in male mice, Experimental and Toxicologic Pathology, in press;
6. Paffetti, A., Trabalzini, L., (2009): Metabolic Pathways of Carcinogenic Chromium, Environmental Health, Research/Genetic Toxicology and Environmental Mutagenesis Environmental toxicity, oxidative stress and apoptosis: Ménage à Trois, Mutation Research 6743–22;
7. Rao, M. V., Chawla, S. L., Sharma, S. R., (2009): Protective role of vitamin E on nickel and/or chromium induced oxidative stress in the mouse ovary, Food and Chemical Toxicology 47, pp. 1368–1371;
8. Rodriguez, R., Samuel, J., Arosh, J., Lee, J., Aruldas, M., Banu, S., (2007): Chromium toxicity induces ovarian follicular developmental arrest, apoptosis, and deregulated steroidogenesis: vitamin C restores follicular survival and function, Biology of Reproduction 77, pp. 215-215;
9. Staniek H., Kostrzewska-Poczekaj Magdalena, Arndt Magdalena , Szyfter K, (2010): Genotoxicity assessment of chromium (III) propionate complex in the rat model using the comet assay, Food and Chemical Toxicology 48, pp. 89–92;
10. Directiva 86/609 din 24.11.1986 privind pretecția animalelor utilizate în scopuri experimentale și în alte scopuri științifice, http://ec.europa.eu/food/fs/aw/aw_legislation/scientific/86-609-eec_en.pdf.;
11. Legea 205/26.05.2004 privind pretecția animalelor, M. O. nr. 531/14.06.2004;
12. Legea 206/27.05.2004 privind buna conduită în cercetarea științifică, dezvoltarea tehnologică și inovare, M. O. nr. 505/4.06.2004;
13. Legea 471/9.07.2002 privind aprobarea O.G. nr. 37/2002 pentru protecția animalelor folosite în scopuri științifice sau în alte scopuri experimentale, M. O. nr. 535/23.07.2002;
14. Legea 9/11.01.2008 pentru modificarea și completarea Legii nr. 205/2004 privind pretecția animalelor, M. O. nr. 29/15.01.2008;
15. Ordin 143/400 pentru aprobarea instrucțiunilor privind adăpostirea și îngrijirea animalelor folosite în scopuri științifice sau în alte scopuri experimentale, M. O. nr. 697/24.09.2002;
16. Toxicology Profile for Chromium, U.S. EPA, (2001): home page address: http://www.epa.gov;

CONSEQUENCES OF POTASSIUM DICHROMATE INTAKE ON ENERGETIC PROFILE IN FEMALE RATS (SIX MONTHS EXPOSURE)

Snejana PETROVICI[1], Alexandra TRIF[1], Eugenia DUMITRESCU[1], Milca PETROVICI[2] Camelia TULCAN[1]

[1]Banat's University of Agricultural Sciences and Veterinary Medicine, Faculty of Veterinary Medicine, Calea Aradului, 119, 300645, Timişoara email: petrovicisnejana@yahoo.com.
[2]West University of Timisoara, Faculty of Chemistry, Biology, Geography, 300115, Timişoara Pestalozzi n16A, Romania

Abstract
The study carried out on 28 white Wistar adult female rats, divided in three experimental (E) groups, exposed for six months to 25 ppm Cr – LOAEL (E_1), 50 ppm Cr – 2 X LOAEL (E_2), 75 ppm Cr – 3 X LOAEL (E_3) and one control (C) group which received tap water not containing chromium pointed out: significant increase of glucose seric level in E groups (exceeding the maximum physiological limit), directly correlated with the exposure level; significant decrease of cholesterol seric level, under the inferior physiologic limit, inversely correlated with the exposure level; significant decrease of triglycerides seric level in E groups (under the minimum physiologic limit), inversely correlated with the exposure level; significant decrease of total lipids seric level (under the physiologic limit), inversely correlated with the exposure level.

INTRODUCTION

Hexavalent chromium exposure is of concern in many chromium - related industries and their surrounding environments. Chromium VI compounds are widely used industrially in stainless steel production, welding, electroplating, leather tanning, production of dyes and pigments and wood preservatives. Industrial uses result in the annual release of more than 10^5 tons of chromium into the environment, and Cr contamination is of significant concern at many sites [4, 5, 6, 9].

MATERIALS AND METHODS

The study was carried out on 28 white Wistar adult female rats, divided in three experimental (E) groups, exposed for six months via drinking water to 25 ppm Cr – LOAEL (E_1) [15], 50 ppm Cr – 2 X LOAEL (E_2), 75 ppm Cr – 3 X LOAEL (E_3) and one control (C) group which received tap water not containing chromium. The female rats were fed with standard diets, corresponding to species and age. Forages and water were *ad libitum*. The seric level of glucose, cholesterol, triglycerides and total lipids, was determined at multiparametric analyzer EOS Bravo Forte, Hospitex Diagnostics, wet chemistry, Hospitex Diagnostics reagents, at PFCI (Interdisciplinary Research Platform), Timișoara. The results had been processed by ANOVA method and Student test. All assays with animals were conduced in accordance with present laws regarding animal welfare and ethics in animal experiments [10, 11, 12, 13, 14].

RESULTS

The results regarding the energetic profile seric values are presented in table 1, figure 1, 2, 3 and 4.

Table 1

Energetic profile seric values after six months exposure to potassium dichromate

Energetic profile values					
		Glucose (mg/dL)	Cholesterol (mg/dL)	Triglycerides (mg/dL)	Total lipids (mg/dL)
C	(X±Sx)	130.24±0.01	55.45±0.01	58.89±0.03	87.62±0.01
	S. D.	0.01	0.01	0.01	0.01
	C.L.	0,01	0.01	0.01	0.01
E_1	(X±Sx)	190.21±0.01	45.54±0.01	19.01±0.01	73.23±0.01
	S. D.	0.01	0.01	0.01	0.01
	C.L.	0.01	0.01	0.01	0.01
E_2	(X±Sx)	194.00±0.01	32.22±0.01	14.63±0.01	61.24±0.01
	S. D.	0.01	0.01	0.01	0.01
	C.L.	0.01	0.01	0.01	0.01
E_3	(X±Sx)	198.13±0.01	24.72±0.01	12.88±0.01	42.25±0.01
	S. D.	0.01	0.01	0.01	0.01
	C.L.	0.01	0.01	0.01	0.01

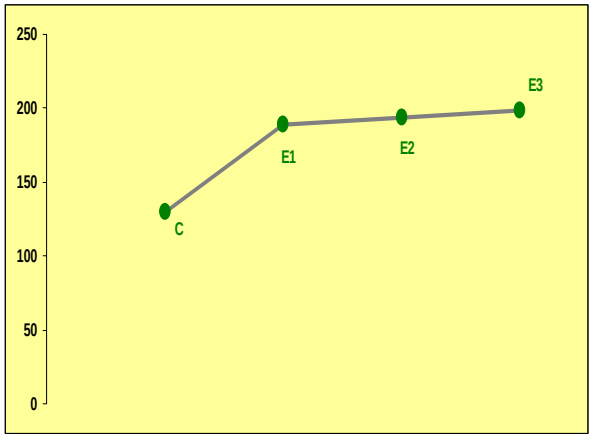

Figure 1. Glucose seric level

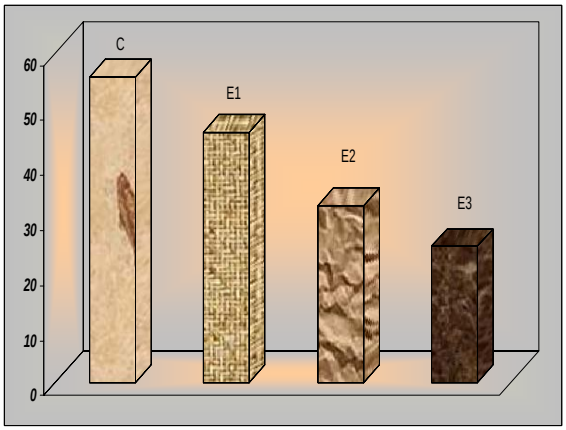

Figure 2. Cholesterol seric level

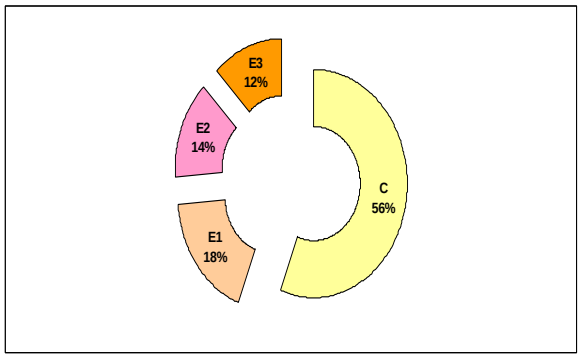

Figure 3. Triglycerides seric level

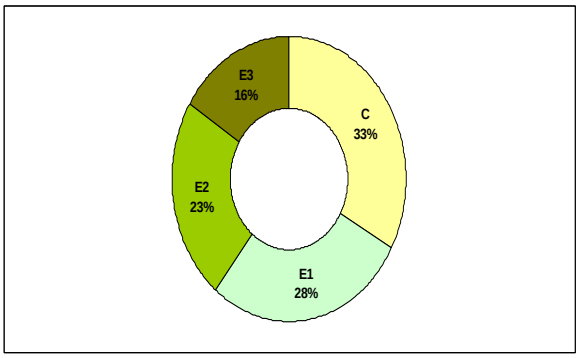

Figure 4. Total lipids seric level

Glucose seric level increased significantly ($p<0.01$) comparative to C group (E_1/C: +46.04%, E_2/C: +48.95%, E_3/C: +52.12%), exceeding the maximum physiological limit (mean value: 115 mg/dL, limits: 95.00-152.00 mg/dL) [3], directly, significantly ($p<0.01$) correlated with the exposure level (E_2/E_1: +1.99%, E_3/E_2: +2.12%, E_3/E_1: +4.16%).

Comparative to C group, **cholesterol** seric level was significantly ($p<0.01$) decreased in E groups (E_1/C: -17.87%, E_2/C: -41.89%, E_3/C: -55.41%), inverselly, significantly ($p<0.01$) correlated with the

exposure level: E_2/E_1: -29.24%, E_3/E_2: -23.27%, E_3/E_1: -45.71% and under the inferior physiologic limit in all three experimental cases (mean value: 96.50 mg/dL, limits: 47.00-182.00 mg/dL) [3].

Triglycerides seric level decreased significantly ($p<0.01$) in E groups comparative to C group (E_1/C: -67.71%, E_2/C: -75.15%, E_3/C: -78.12%), under the bottom physiologic limit (mean value: 67 mg/dL, limits: 30.00-205.00 mg/dL) [3], inverselly, significantly ($p<0.01$) correlated with the exposure level (E_2/E_1: -23.04%, E_3/E_2: -11.96%, E_3/E_1: -32.24%).

Total lipids seric level recorded a significant ($p<0.01$) decrease in E groups comparative to C group (E_1/C: -16.42%, E_2/C: -30.10%, E_3/C: -51.78%), inverselly, significantly ($p<0.01$) correlated with the exposure level: E_2/E_1: -16.37%, E_3/E_2: -31.00%, E_3/E_1: -42.30%, and under the physiologic limit of 240 mg% [3].

DISSCUTIONS

Exposure of female rats for six months to potassium dichromate pointed out: significant increase of glucose seric level directly correlated with the exposure level and significant decrease of cholesterol, triglycerides and total lipids seric level, all inversely correlated with the exposure level. The world wide findings regarding the accidental or experimental impact of hexavalent chromium on animal and human health (especially biochemical results) are few in the context of their high incidence (both in animals as in humans) and importance. The increased level of glucose was also pointed out by other authors [7]. The results regarding hexavalent chromium impact on the level of cholesterol are in accord with the ones found by other authors, that also pointed out the decrease of seric cholesteol following chromium exposure [1, 8]. Also, Sabiha and Mahmood, [8] found low triglyceride level after potassium dichromate exposure. Chundawat and Sood, [2] obsearved decreased lipid level following exposure to hexavalent chromium compounds, same results as those presented in this study.

REFERENCES

1. Bucher, Jr., (2007): NTP toxicity studies of sodium dichromate dihydrate (CAS No.7789-12-0) administered in drinking water to male and female F344/N rats and B6C3F1 mice and male BALB/c and am3-C57BL/6 mice, Toxic Rep Ser., (72):1-G417342194;
2. Chundawat, R. S., Sood, P. P ., (2004): Vitamins and glutathione are ideal therapeutic agents to cope up with chromium toxicity, Journal of Tissue Research, 4 (2), 231-237;
3. Giknis, M. L. A., Charles, B., Clifford, C. B. (2006): Clinical Laboratory Parameters fr. Crl:CD(SD) Rats, Charles River Laboratories;
4. Myers, Judith. M., Myers, C. R., (2009): The effects of hexavalent chromium on thioredoxin and peroxiredoxins in human bronchial epithelial cells, Free Radical Biology and Medicine, 1477-1485;
5. Newairy A. S. A., Abdou, H. M., (2009): Protective role of flax lignans against leadacetate induced oxidative damage and hyperlipidemia in rats, Food and Chemical Toxicology 47, 813-818;
6. Ott, M., V. Gogvadze, S. Orrenius, B. Zhivotovsky, (2007): Mitochondria, oxidative stress and cell death, Apoptosis 12, 913–922;
7. Rafael. A.I., Almeida, A., Santos, P., Parreira, I., Madeira, V.M.S., Alves, R., Cabrita, A.M.S., Alpoim, M.C., (2007): A role for transforming growth factor-b apoptotic signaling pathway in liver injury induced by ingestion of water contaminated with high levels of Cr (VI), Science Direct, 211(2), 154-158;
8. Sabiha, Fatima, Mahmood, R., (2008): Vitamin C attenuates potassium dichromate-induced nephrotoxicity and alterations in renal brush border membrane enzymes and phosphate transport in rats, Clin Chim Acta, 17822687;
9. Tabrez, S., Ahmad, M., (2009): Effect of wastewater intake on antioxidant and maker enzymes of tissue damage in rat tissues: implications for the use of biochemical markers, Food and Chemical Toxicology 47, 2465-2478;
10. *** Legea 205/26.05.2004 privind pretecţia animalelor, M. O. nr. 531/14.06.2004;

11. *** Legea 206/27.05.2004 privind buna conduită în cercetarea științifică, dezvoltarea tehnologică și inovare, M. O. nr. 505/4.06.2004;
12. *** Legea 471/9.07.2002 privind aprobarea O.G. nr. 37/2002 pentru protecția animalelor folosite în scopuri științifice sau în alte scopuri experimentale, M. O. nr. 535/23.07.2002;
13. *** Legea 9/11.01.2008 pentru modificarea și completarea Legii nr. 205/2004 privind pretecția animalelor, M. O. nr. 29/15.01.2008;
14. *** Ordin 143/400 pentru aprobarea instrucțiunilor privind adăpostirea și îngrijirea animalelor folosite în scopuri științifice sau în alte scopuri experimentale, M. O. nr. 697/24.09.2002;
15. *** Toxicology Profile for Chromium, U.S. EPA, http://www.epa.gov, (2001).

MORPHOLOGICAL OBSERVATIONS OF NEURONS IN THE SPINAL NUCLEUS BULB AT SHEEP

Alina POPA[1], C. V. COTEA,[2] Carmen SOLCAN[2], Stefania ANDERCO[3]
[1]DSVSA Bacau
[2]Faculty of Veterinary Science Iaşi
[3]DSVSA Iasi

ABSTRACT

The research was conducted after removal of spinal bulbs from 64 sheep.The animals were clinically healthy, normally slaughtered for public consume in approved slaughterhouses for cutting them. The fragments of the bulb were fixed in saline formalin, included in paraffin, sectioned at 5µm, coloured by HE method, HEA, Holmes argentic impregnation McManus technique and examined with the Olimpus optical microscope. The neurons were studied in the following nuclei: hipoglos, vague dorsal, cuneat, solitar tract, olivar, spinal tract, reticuar formation. The number and the size of the neurons in the spinal bulb varies depeding on the nucleus.

Key words: spinal bulb, nucleus, neurons

MATERIALS AND METHODS

The material used for the research is represented by the sheep brain and it had been studied for 5 years, starting from 2004 up to 2008, from Bacau, Neamt and Botosani districts. The researches have been made at the Estate Sanitar Veterinary Laboratory from Bacau, at the Histology Compartment. The samples of the rahidian bulb at sheep have been taken from 64 clinically healthy animals normally sacrificed for public consume in authorized abattoirs. Their harvest was made either by taking the brain entirely or only the rahidian bulb using the foramen magnum technique. The brain samples were fixed in saline formaline, sampled, refixed, processed, sectioned at 5qm, coloured after the HE, HEA, Holmes argentic impregnation-McManus technique and examined with the Olimpus BX51 microscope.

RESULTS AND DISCUSSIONS

There have been studied the nuclei from the rahidian bulb at sheep, section at obex: the hipoglos nucleus, the vague dorsal nucleus, the cuneati nuclei, the ambiguous nucleus, the olivar nuclei, the reticular formation, the lateral fascicular nucleus, the nucleus and the spinal and solitar tract (fig.1). In the rahidian bulb at sheep, section at obex were identified nine simetrical pericarional structures compared with the median bulbar rafeu. These structures, more or less compact, are formed of neuronal agglomerations, that are placed grey substance's mass, where there also can be found the nerve prolongations of the pericarions, the last ones forming the so called neuropil.

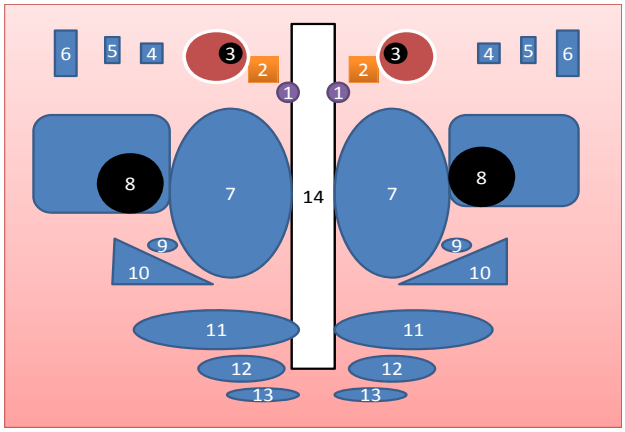

Fig.1 The scheme of the nuclei identified in the rahidian bulb at sheep, section at obex: 1. The hipoglos nucleus; 2. The vague dorsal nucleus; 3. The nucleus and the nucleus of the solitar tract; 4. The inferior cuneat nucleus; 5. The median cuneat nucleus; 6. The superior cuneat nucleus; 7. The reticular formation; 8. The nucleus and the tract of the spinal nucleus; 9. The ambiguous nucleus; 10. The lateral fascicular nucleus; 11.12.13. the olivari nuclei; 14. The median rafeu (original).

The nucleus of the hipoglos nerve, vague dorsal and the solitar tract along with the cuneati ones occupy the superior part of the rahidian bulb, being clearly delimitated from the reticular formation and the group of fascicular lateral and ambiguous nuclei situated in the median bulbar area. In the inferior side of the rahidian bulb there are the olivar nuclei. All these nuclei admit a mirror topohistologie, being simetrically situated compared with the median rafeu of the rahidian bulb.

Tabel no.1

The schematic presentation of the nuclei grouping and the tracts of some nuclei of the cranial nerves.

.The group of the superior bulbar nuclei	The group of the median bulbar nuclei	The group of the inferior bulbar nuclei
The hipoglos nucleus	The reticular formation	The superior olivar nucleus
The vague dorsal nucleus	The nucleus and the spinal tract	The median olivar nucleus
The nucleus and the solitar tract	The lateral fascicular nucleus	The superior olivar nucleus
The inferior cuneat nucleus	The ambiguous nucleus	
The median cuneat nucleus		
The superior cuneat nucleus		

The hipoglos nuceus is situated in the space between the median rafeu, the reticular formation, the nucleus of the vague dorsal nerve and the wall of the third (IIIrd) ventricle. It is formed if a small group of neurons, of small and median dimensions, generally oval-triangular shaped, the root's nerve prolongations being well-determined. The neuropilar structure, with a retiform aspect, delimitates from place to place bloody capilars. In some cases the nucleus of the hipoglos nerve appears with some rarefactions of the neuronal cell populations right in the heart of its structure. In other cases, these pericarional rarefactions are interested in the peripheral areas, especially in the limitary areas with the nucleus of the vague dorsal nerve.

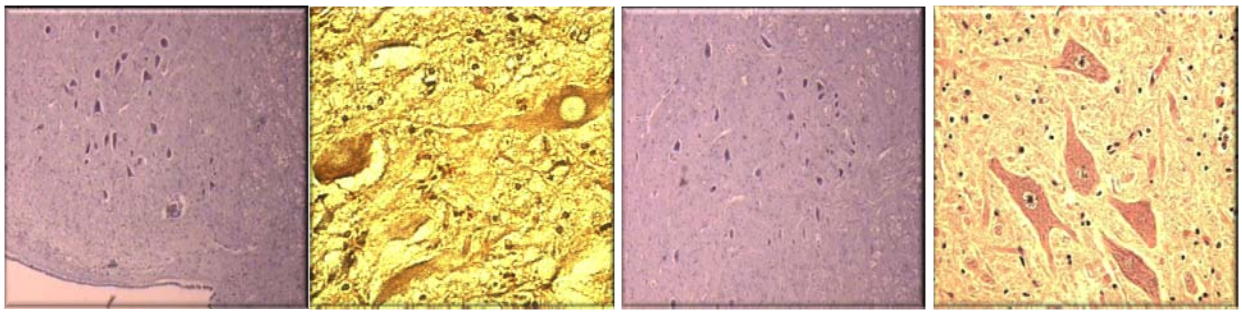

Fig.2 The hipoglos nucleus (a,b); The vague dorsal nucleus (c,d); Sheep rahidian bulb.Col HEAx 40(a,c); the argentic impregnation, Holmes technique x1000(b,d).

The vague dorsal nucleus practically represents the structure with the largest dimension of all the nuclei situated on the superior side of the rahidian bulb. The topohistological delimitation indicates the ventricular wall, the lateral formation and the nucleus' tract of the solitar nerve. The large dimension of the nucleus of the vague dorsal nerve is due to, on one side to the large number of neurons which form it, and on the other side is due to the predomination of large and median size of the pericarions, most of them triangular and multiangular shaped, with large, vesicular and nucleolati nuclei. Compared with the nucleus of the hipoglos nerve, this nucleus is compactised enough under a cellular raport, the intercellular spaces not being laxes at all. The pericarions'nerve prolongations forms a well-determined neuropil and let it to be observed the presence of the bloody capilars and a rich gliocitar population.

The nucleus and the solitar tract is a structure that at this bulbar level is characterized by a central position of the solitar nerve. The tract of this nerve delimitates the latero-superior nucleus of the vague dorsal nerve from the nucleus of the inferior cuneat nerve, and in the distal area it adjoins with the reticular formation and with the nucleus and the tract of the spinal nerve.

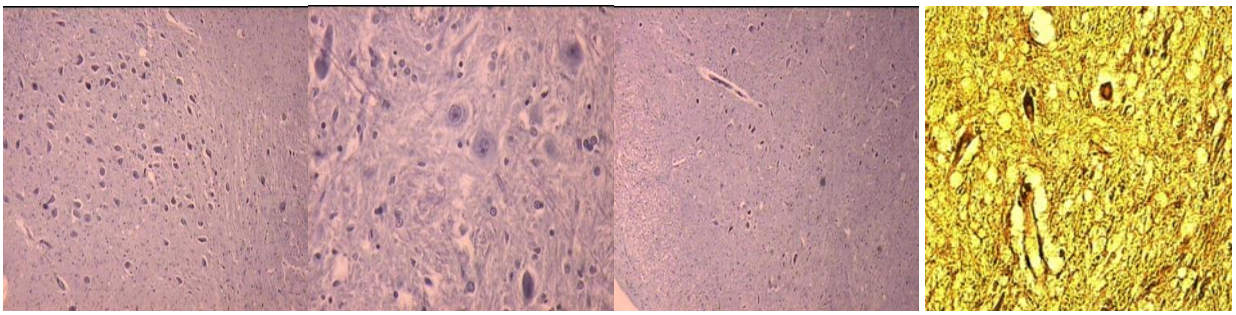

Fig.4 The nucleus *the nucleus and the solitar tract* (a,b) The cuneati nuclei (c,d) Sheep rahidian bulb. Col. HEAx40(a,c); x200(b), argentic impregnation, Holmes technique x 400(d).

The cuneat nucleus is made of difuse neuronal cells, uncertaintly delimitated, generally of median size with poliform aspect with the predomination of granular forms, having the large nucleus, centrally disposed, round with the chromatine under the form of blocks under nucleoleme, with a nucleol intensely basofil. The neurons have a soft pervulent cytoplasme in the pericarion. These neurons have weak developed prolongations. The nucleus contains oligodendrologies with nuclei with very condensed chromatine and also microglies, but in a smaller number, intensely coloured in HEA because it has the nucleus with o very condensed chromatine, and they are satellites for the neuronal cells.

The nucleus of the spinal tract is formed of the star-shaped neurons which have lots of long, ramificated prolongations that are well-determined through the argentic impregnation method.

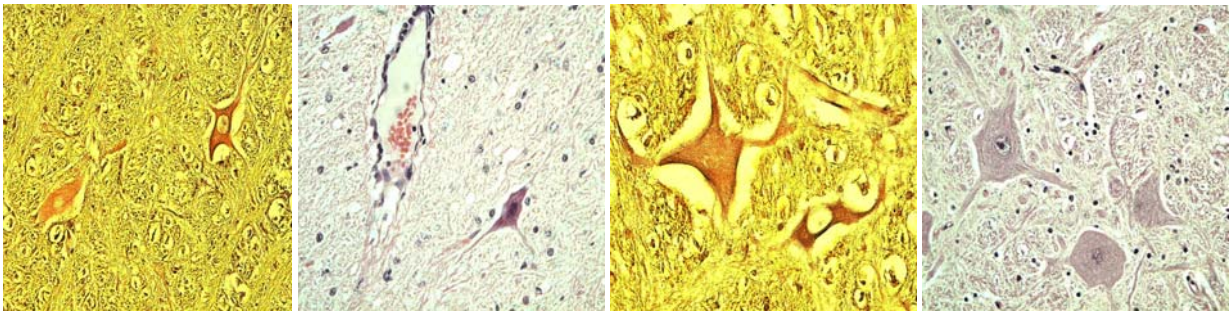

Fig.6 The pericarions from the nucleus of the spinal tract. Sheep rahidian bulb. Argentic impregnation x200(a); HEAx200(b). Argentic impregnation x400(c). HEAx400(d)

The reticular formation has the neuropil made of white mielenic nerve fibers under the form of some nests(argentic impregnation and HEA) among which there are multipolar neurons of large dimensions, with the large neuron easily excentric disposed and with long and thick extensions. The fibrilar neuronal device is softly assigned in the entire neuronal cytoplasme among the Nissel corps, as it can be observed in the argentic impregnation. The chromophil granulations are disseminated both at the implementation base of the prolongations(dendrites) and also on a certain distance of these.

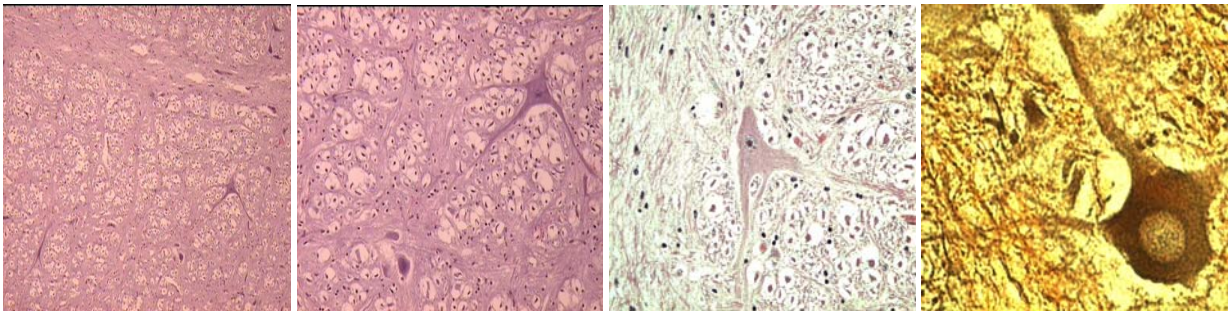

Fig.7 The pericarions from the reticular formation. Sheep rahidian bulb. HEAx40(a); x200(b); x400(c); the argentic impregnation x1000(d).

The oliv nucleus is formed of three nuclear parts disposed one on another (under the form of some pilled plates) well-conturated on both sides of the median rafeu in the bulb's ventral area, with small sized neurons of pyramidal and multipolar shapes with short expansions, that posses little chromatopil substance under the form of basofil dust. In the argentic impregnation can be observed a soft neurofibrilar device that has two areas of densification, the first one near the nucleus and the second one the one from the cytoplasme's limitary. The nucleus of the nerve cells is large dimenssionated compared with the cellular corp.

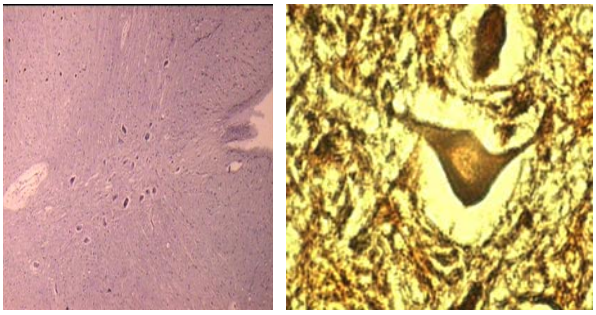

Fig.8. The pericarions from the oliv nucleus. Sheep rahidian bulb. HEAx40(a); the argentic impregnation x 1200(b).

It had been made an estimative counting of the neurons on the histological section in the following nuclei: hipoglos, vague dorsal, cuneati, the reticular formation, olivar, the nucleus and the tract of the solitary and spinal nerve(table no.2).

Tabel no.2

The estimative number of the neurons of the most important nuclei shown on the histological section at the level of the obex. Sheep rahidian bulb

The nucleus	I	II	III	IV	V
The hipoglos nucleus	24	24	30	28	25
The vague dorsal nucleus	30	30	28	32	29
The nucleus of the solitar tract	55	53	58	60	55
The cuneat nucleus	36	38	36	30	37
The nucleus of the spinal tract	20	20	30	25	25
The reticular formation	51	50	50	45	48
The olivar nuclei	61	51	56	58	56

The number and the neurons' dimension vary according to the nucleus. The average of the identified neurons on each histological section is the following: the hipoglos nerve 26 neurons, the vague dorsal nerve 29 neurons, the nerve and the tract of the solitar nerve 56 neurons, the cuneati nerves 35 neurons, the nerve and the tract of the spinal nerve 24 neurons, the reticular formation 49 neurons, the olivar nerves 56 neurons. The ambiguous nucleus and the lateral fascicular nucleus are structures that at the bulbar level are not so well represented. The rahidian bulb or the elongated marrow is situated in the posterior level of the skull and on the cranial side of the rahidian channel. The bulb's surface has a similar configuration as the rahidian marrow, especially on the caudal side where it continues with this surface. In the interior the bulb is formed of white and grey substance. Some of the nerve fibers that form the anterior pyramids cross at the level of the bulb, passing from one side to another. Because of these crossings, the bulb's white substance goes through the grey substance which fragments it. Thus, fragments of grey substance are formed surrounded by fascicles of white substance. These types of fragments form the **bulbar nuclei.**

CONCLUSIONS:

1. In the rahidian bulb at obex section, nine simetrical pericarional structures were identified, with a mirror topohistology compared with the rafeu of the median bulb.
2. The hipoglos, the vague dorsal,the cuneati nuclei, the nucleus of the solitar tract occupy the superior side of the rahidian bulb.
3. The group of the lateral fascicular and ambigous nuclei are situated on the median bulbar area being clearly delimitated from the reticular formation, but are not so well determinated.
4. On the inferior side of the rahidian bulb are put the olivar nuclei.

5. The number and the dimension of the neurons varry according to the nucleus. The vague dorsal nucleus has large neurons, most of them triangular-shaped, compact enough under a cellular raport.
6. The neurons of the hipoglos and vague nuclei are disposed at a huge distance from the others compared with the ones from the solitar nucleus where they are very closed.

BIBLIOGRAPHY:

1. Bacha J. Jr., Wood L. M., 1990, Color atlas of veterinary histology. Lea and Febiger, Beckembaum. Bankroft J. D., Stevens A., 1990,Theory and practice of histology, 2nd ed. Churchill Livingstone.
2. Banks W. J.,1992 Applied veterinary histology. 3rd Edition.Williams Wilkins Baltimore, London, Los Angeles, Sydney, 1992.
3. Barone R.,2004, Anatomie Comparée des mamifères domestiques, Tome 6, Neurologie I, Sistème nerveux central, Ed. Vigot, ISBN 2 711481948.
4. Coman T., Cornilă N.,2002 Structura şi ultrastructura ţesuturilor la animale, Ed. FRM, Bucuresti.
5. Cotea C., 2008 – Histologie specială. Ed. Tehnopress, Iaşi.
6. Coţofan V., Palicica R., Hriţcu Valentina, Ganţă Carmen, Enciu V.,2000, Anatomia animalelor domestice, Vol. III., Ed. Orizonturi universitare, Timişoara.
7. Junqueira L. C., Carneiro J., Iielley R.O.,1998, Basic Histology, 9 ed., Appleton and Lange, Stamford, Connecticut.
8. Weiss L., 1983 Histology Cell and Tissue Biology, Elsevier Biomedical New-York, Amsterdam, Oxford.

THE FORM AND THE LOCATION OF NUCLEI OF THE RAHIDIAN BULB AT SHEEP

Alina Coralia POPA[1], Corneliu V.COTEA[2], Mihaela SPATARU[2]
[1]DSVSA Bacau,
[2] Faculty of Veterinary Science Iaşi

ABSTRACT

The rahidian bulb at sheep is characterized by the trapezial aspect with a deep rhombusal fose. The pontin trigon, a component of the rhombusal fose, has the shape of an equilatera triangle, presents an excellent round which is visible and long. The transversal sections made at the level of the aperent origin of nerves on pieces taken from sacrificed animals and then fixed in phormol had shown the presence of bulbian nuclei gradually and in different levels according to the given sections.The macroscopic omologation of nuclei was made following the localization sketch of the bulbarian nuclei at animals.

Key words*:* rahidian bulb, nuclei, rhombusal fose, nervs.

INTRODUCTION

The CNS study of the rahidian bulb at sheep has in view the identification of nuclei, of the real origins of the cranial nerves situated at the level of the rahidian bulb. This represents a major scientific importance for the morphology and physiology of the CNS and a clinical importance for the pathology of the CNS. Many studies have been made in this area at equines, cattle etc. where schemes were realized concerning the topography and the identification of the structure of the bulbarian nuclei

MATERIALS AND METHODS

In drawing this worksheet, five harvested encephalons were used from adult sheep of different sexes and ages, sheep coming from private owners from Bacau district that were authorized as being clinical healthy. The encephalons have been entirely harvested and then the pieces were formolizated with saline formalin for fifteen days and, after that, there were taken photos of them and examinated through specific surgical methods. Serial sections have been made right near the apparent origin of each cranial nerve that detaches from the bulb. Thus, they have obtained the apparent origins with the appropriate nuclei for each bulbar nerve. The identification of the rahidian nuclear bulbs at sheep was made through the identification of the neuronal agglomerations coloured in grey from the depth of the rahidian bulb; each of their identification being made according to the described topography in the specialized literature at other species of domestic animals.

RESULTS AND DISCUTIONS

The rahidian bulb (medulla oblongata) is situated in the posterior level of the skull and in the cranial side of the rahidian channel. It is the spinal cord's continuation, that's why it is also called the prolonged marrow. It has the form of a truncated cone with the large base situated on the cranial side, a length at about 2,5-3 cm and a weight of about 5g.

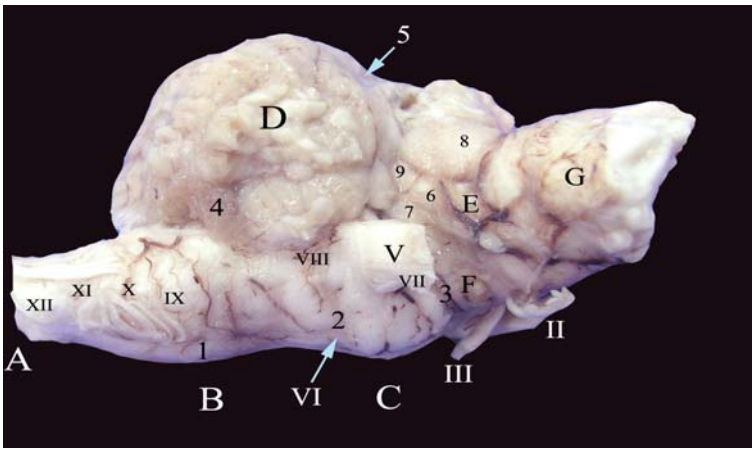

Fig.1. The mielencefal, the metencefal, the mezencefal and the diencefal at sheep-side issue

A. A- the spinal cord,B-the rahidian bulb, C- the deck,D- the cerebellum,E- the patrugemeni peduncles,F- the cerebral peduncles, G- the thalamus.

1-the bulbar pyramids; 2- the pontopenducular ditch; 3-the pontopenducular ditch; 4- the choroid plexus; 5- the cerebellar tent; 6- the geniculat body side; 7- the geniculat medial body; 7- the geniculat medial body; 8- the anterior patrugemeni tubers; 9- the posterior patrugemeni tubers; II-XII- the aparent origins of the cranial nerves II-XI.

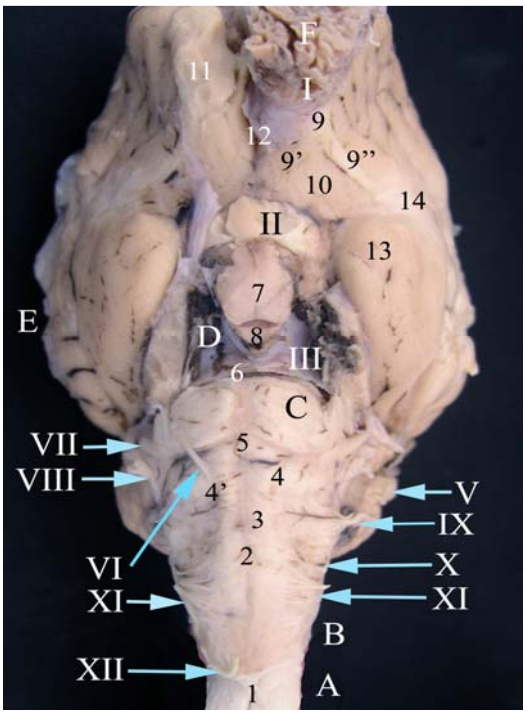

Fig.2. The encefal at sheep- the ventral aspect

A. the spinal cord, B- the rahidian bulb, C- the deck, D- the cerebral peduncles, E- the cerebral hemispheres, F- the ethmoid volute.

1-the ventral median ditch of the spinal cord; 2. the median ventral of the bulb; 3. the bulbar pyramids; 4-4 the acoustic and facial tubercle; 5. the pontobulbar ditch; 6. The pontopenducular ditch; 7. the pituitary; 8. the mamilar tubers; 9. the olfactory peduncles; 9-9" the olfactory strips(medial and lateral); 10. the olfactory trine; 11. the olfactory bulb; 12. the ethmoid's cribrosa blade; 13. the pear-shaped lobe; 14. Sylvius's valley.

I-the olfactory nerve; II- the optical nerve; III- the common oculomotor nerve; IV- the trochlear nerve; V- the trigemen nerve; VI- the abducens nerve; VII- the intermediofacial nerve; VIII- the statoacustic nerve; IX- the glosofarigian nerve; X- the vague nerve; XI- the spinal nerve; XII- the hipoglos

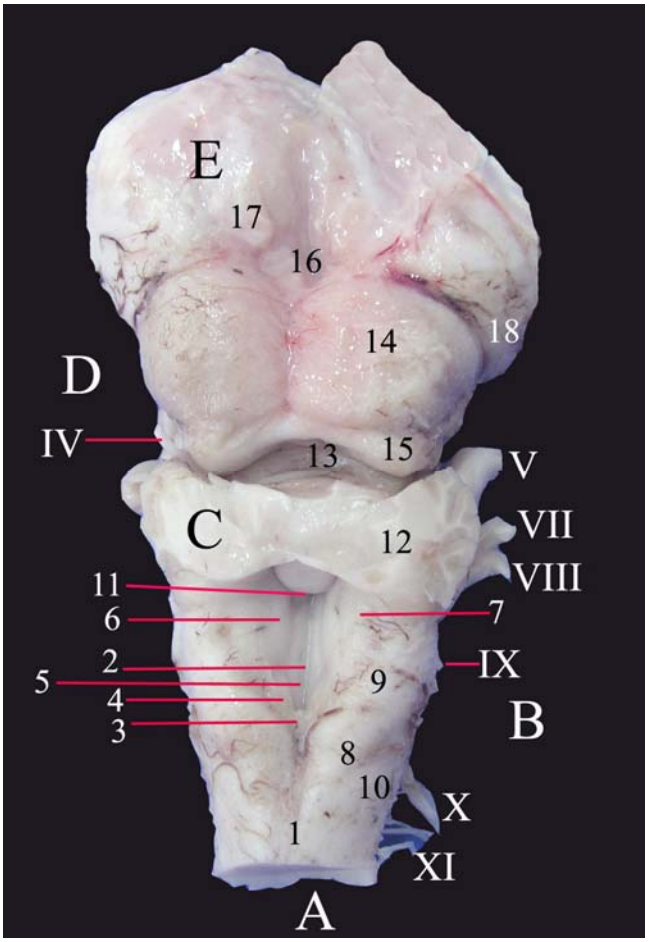

Fig. 3. The cerebral trunk at sheep- the dorsal aspect

A- the spinal cord, B- the rahidian bulb,C- the cerebellar peduncles, D- the mezencefal, E- the thalamus
1- the median dorsal ditch; 2. the median dorsal ditch of the rhomboidal fossa; 3. the obex; 4. the trine of the hipoglos nerve; 5. the trine of the vague nerve; 6. the eminent medial and borded ditch; 7. the locus ceruleus; 8. the Gracilis's nucleus; 9. the Cuneatus's nucleus; 10. the relief of the trigeminal tract; 11. the Sylvius aqueduct; 12. the cerebellar peduncles; 13. the cerebral peduncles; 14. the anterior patrugemeni tubers; 15. the posterior patrugemeni tubers; 16. the fossa of the epifization gland; 17. the habendules;
IV-XI- the cranial nerves- the aparent origin.

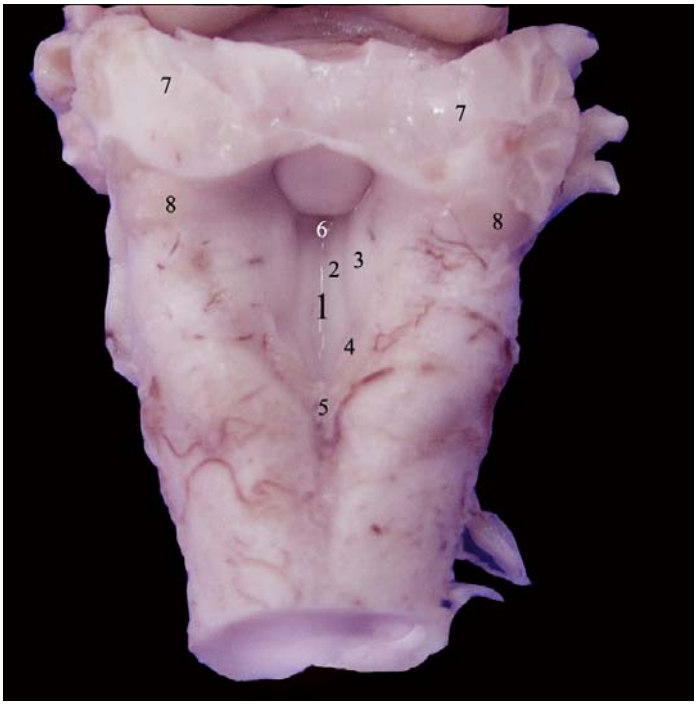

Fig.4. The rahidian bulb at sheep, the dorsal aspect (the original one)

1- the dorsal sagital ditch of the rhomboidal fossa , 2- the trine of the vague nerve, 3- the coeruleus place, 4- the trine of the hipoglos nerve, 5- the posterior medular vail, 6- the opening of Sylvius aqueduct,7- the cerebellar peduncles,8- the posterior cerebellar peduncles (Bulbo-cerebellar)

The skull ends where the Varolio's ditch begins and the candal border is indicated by the place where the nerve fibers cross and form the anterior bulbar pyramids. The bulb's area has a similar configuration to that of the marrow's extern one especially in the candal side.

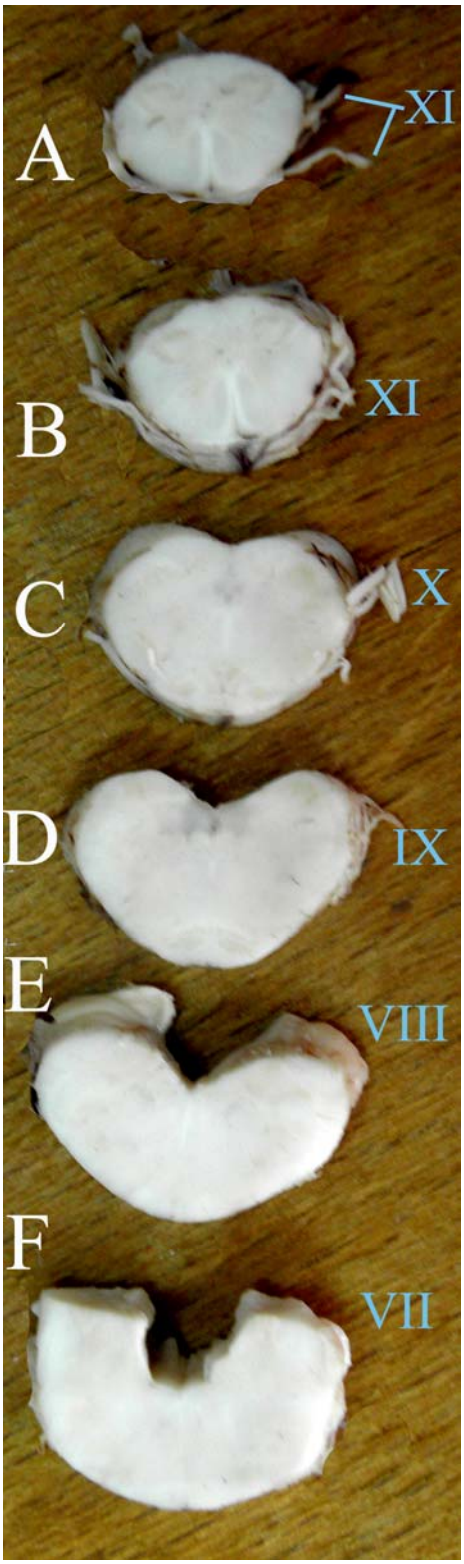

Fig. 5. Serial sections through the rahidian bulb at sheep:

A- section through the spinal cord at the level of the aparent origin of the spinal branch of the accessory nerve of the vague's (XI)

B- section through the rahidian bulb at the level of the aparent origin of the nerve XI

C- section through the rahidian bulb at the level of the aparent origin of the nerve X

D- section through the rahidian bulb at the level of the aparent origin of the nerve IX

E- section through the rahidian bulb at the level of the aparent origin of the nerve VIII

F- section through the bulb at the level of the trapezoid-shaped body near the VIIth pair.

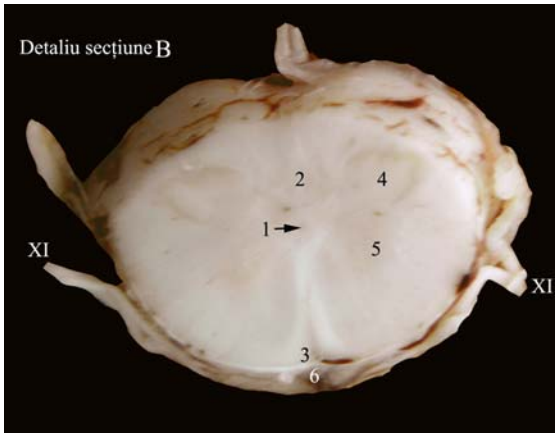

Fig.7. The omologation of the bulbarian nuclei in section B at the level of the aparent origin of the nerve XI

1- , the ependimar channel, 2- the parasympathic nucleus of the vague nerve, 3- the pyramidal desscusasion , 4- the nucleus of the solitary tract of the nerve V, 5- the ambiguous nucleus , 6- the ventral longitudinal ditch

On the anterior side you can find the median ventral ditch on which sides there are two cords called bulbar pyramids that are still seen in the continuation of the ventral cords of the marrow. On each pyramid's lateral side there is the collateral ventral ditch. On the lateral side of the bulb, laterally of the collateral ventral ditch, there are the

lateral cords of the bulb posteriorly borded by the collateral dorsal ditch. Each lateral cord ends cranially through an oval bulge with the large axe situated longitudinally that is called the bulbarian oliva.

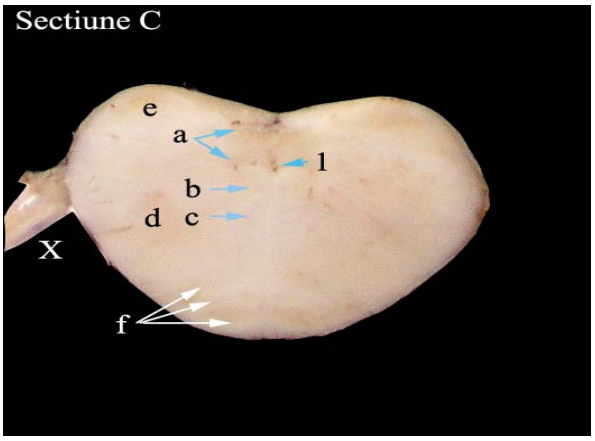

Fig. 8. The omologation of the bulbarian nuclei in section C at the level of the aparent origin of the nerve X.

1-the ependimar channel; a- the proprioceptive colons, the cuneiform nuclei and gracilis; b- the viscero-ceptive column, the nucleus of the solitar tract; c- the semimotric columns, the nucleus of the hipoglos nerve; d- the brahiomotric columns; e- the exterceptive columns, the nucleus of the spinal tract of the of the trigemen nerve.trigemen nerve.trigemen nerve.

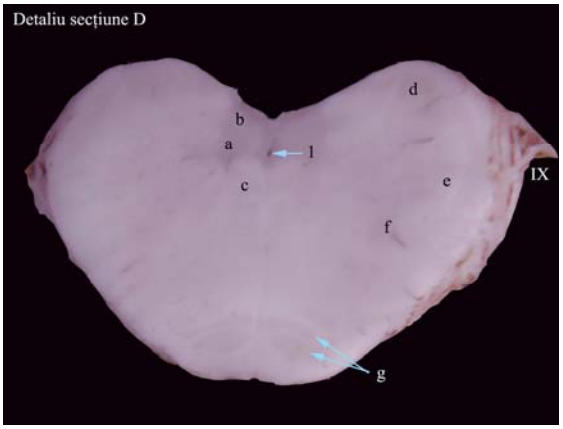

Fig. 9. The omologation of the bulbar nuclei in section D at the level of aparent origin of the nerve IX

1- the ependimar channel

a-the nucleus of the hipoglos nerve; b- the parasymphatic nucleus of the nerve X; c- the nucleus of the solitar tract; d- the vestibular nucleus; e- the nucleus of the spinal tract of the trigemen nerve; f- the ambiguous nucleus;

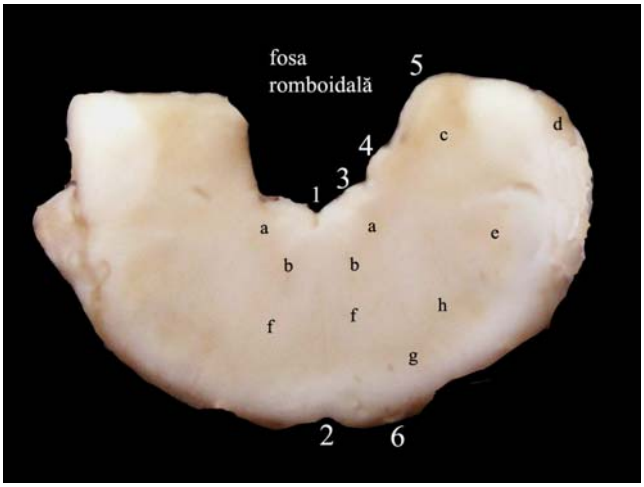

Fig. 10. The omologation of the bulbar nuclei in section F at the level of the aparent origin of the nerve VII

1- the longitudinal ditch the rhomboidal fossa, 2- the ventral longitudinal ditch, 3- the gracilis fascicle, 4-the cuneiform fascicle,5-the trigeminal fascicle, 6- the bulbar pyramid ,

a-the parasympathic nucleus of the facial nerve;b- the nucleus of the abducens nerve;c- the vestibular nucleus;d- the dorsal cohlear nucleus;e. the trigeminal nucleus; e- the trigeminal nucleus f.-the motor nucleus of the facial nerve;g- the nuclei of the trapezoidal body.

On the posterior side, the bulb presents the dorsal median ditch. On its side there are the cords made of Goll's fascicles (gracilis) and Burdach's (cuneatus), separated through the dorsal intermediary ditch. On the candal side of the bulb, they have the same position as they in the marrow.On the half cranial side of the bulb, the cords made of Goll's and Burdach's fascicles deviate themselves from the medial line, directing obliquely up and laterally and determinating in the extension of the ependimar channel the formation of a cavity that is called the IVth ventricle. From this level, Burdach's fascicle continues itself with a formation called the restiform body with the cerebellar peducle being considered inferior and the Goll's fascicle which also continues itself with a formation called the posterior pyramid. The structure of the rahidian bulb has two characteristics: the existence of the IVth ventricle and the disposal of the two kinds of substance. Inside the rahidian bulb, the ependimar channel enlarges a lot and forms the bulbar part of the IVth ventricle; a ventricle which is a cavity situated between the buld, the ditch and the small brain; it has a rhomboidal form- that's why it is also called the rhomboidal fossa. The bulbar part has the form of a triangle with the base headed up. The IVth ventricle is situated on the dorsal part of the bulb,and the mass of the nerve substance forms its floor, where it can be seen a longitudinal ditch called the posterior median crack from where some strips called medular streaks come in both parts of that ditch. The posterior median crack along with the medular streaks are also known as being called calamus scriptorius. The IVth ventricle is dorsally covered, on the bulbar portion, with a very fine epiteliel membrane. The white and grey substances that can be found in the bulb's composition are exposed in a characteristic way. Some of the nerve fibers that form the anterior pyramids cross out at the level of the bulb passing from one side to another; this type of crossing is called the pyramids' descusation and marks the bulb's caudal limit. At the level of the rahidian bulb, there are also some sensitive fibers that cross along. Because of these crossings, the bulb's white substance goes through the mass of the grey substance which fragments it. Thus, it is formed fragments of grey substance surrounded by fascicles of white substance. These fragments are called centers or bulbar nuclei. From the fragmentation of the ventral columns, motor nuclei are formed; from the fragmentation of the dorsal columns, sensitive nuclei are formed and from the laterally ones, vegetatives nuclei are formed. At the sheep, the rahidian bulb is shorter and wider than the one from the horse. The facial tubercle is less evidently, but the extreme archiforms are more developed that streche from the bulb's caudal line up to the facial ventral tubercle. The abducens nerve comes out with few millimeters than the pyramids' lateral border. The pyramids are less developed than at the horse, and their anterior extremities are attached. Before they decusa themselves, the pyramids get thinner by getting out at the surface of some olivary eminent, corresponding to the caudal ones. On the dorsal side,the gracilis and cuneat fascicles diverge in a right angle. Rolando's tubercle is less visible.

CONCLUSIONS

1. The rahidian bulb at sheep has the shape of a truncated cone with the large base situated cranial, with a length of 2,5-3cm and with a weight of 5g.
2. The facial tubercle is less evidently, but the extreme archiforms are more developed, stretching themselves from the bulb's caudal line up to the ventral facial tubercle.
3. The bulbar pyramids are more developed than the other species are, and their anterior extremities are attached.
4. Before they decusa themselves, the pyramids get thinner by the coming out of some olivary eminent, corresponding to the caudle olivaries ones.
5. The sections made at the level of the aparent origin of the bulbar nerves show macroscopically the presence of the dark-coloured nuclei (grey-browny) that are well-shaped.

BIBLIOGRAPHY:

1. Barone R., Anatomie Comparée des mamifères domestiques, Tome 6, Neurologie I, Sistème nerveux central, Ed. Vigot, 2004, ISBN 2 711481948;
2. Coţofan V., Palicica R., Hriţcu Valentina, Ganţă Carmen, Enciu V., Anatomia animalelor domestice, Vol. III., Ed. Orizonturi universitare, Timişoara, 2000
3. Fontaine J.J., UP.D Histologie et Anatomie pathologique DSBP-ENVA, Anatomie patologique speciae, lesions du systeme nerveux, september 2002;
4. Gilroy, Mac Pherson, Ross, Schuenke, Atlas of Anatomy, Editura Thieme Verlog, 2008;
5. Junqueira L. C., Carneiro J., Basic Histology text&atlas, Ed. McGraw Hill Professional, 2005;
6. Netter F. H., MD, Atlas de anatomie a omului, Editura Medicală Callisto, 2008;

HEPATIC LESIONS IN DOLPHINS STRANDED FROM THE ROMANIAN BLACK SEA COAST

Oana Melania POPA, M. COMAN, Alexandra TRIF, A. STANCU, Diana ARGHERIE
Banat's University of Agricultural Science and
Veterinary Medicine, Calea Aradului 119, 300645 Timisoara, Romania.
E-mail: orpopa@yahoo.com

ABSTRACT

The Romanian Black Sea costal waters faced pollution by fluvial discharges, municipal, agricultural and industrial waste water discharges, maritime traffic and offshore oil activities. In the present study were investigated histopathological findings in the liver of six dolphins, *Phocoena phocoena* and *Tursiops truncates*, found stranded along Romanian Black Sea coast. The main hepatic lesion was difuse hepatic lipidosis, which was diagnosed in all six dolphins, four *Phocoena phocoena* and two *Tursiops truncatus*, three females and three males. Other lesions were: minor dystrophic (processes, inflammations, dissociation of hepatocytes lamine, conjunctive neogenesis, fibrosis and necrosis. The cause of changes in the liver described in this paper can only be speculative. There is an enormous number of hepatotoxic agents (biological, chemical or physical) that could provoke such changes. Therefore pollutants could be considered the cause of these lesions but further studies are needed.

Key words: dolphins, hepatic lesion, Black Sea.

INTRODUCTION

The Black Sea dolphins are top-predator living in one of the most dramaticaly altered marine ecosystems in the world. The conservation status of the dolphins is poor although some measure to protect them were taken. Black Sea dolphins faced threats as ecosystem changed, killing, catching and pollution (1, 2, 16, 17, 18). At the Romanian Black Sea coast, the quality of the marine environment is influenced mainly by the Danube waters, the industrial and agricultural waste waters, the domestic waste waters, the maritime traffic and marine drilling, the activities from Midia, Constanta and Mangalia harbour, as well as by tourism (6, 13, 14, 18). Marine mammals bioaccumulate anthropogenic pollutants as heavy metals, organochloride pesticides and polycyclic aromatic hydrocarbons (5, 10, 19). The liver accumulates the highest concentrations of metals, except for cadmium and chromium and polyciclic aromatic hydrocarbons (3, 5, 11, 12, 19, 20).
While the synergic effects of the various pollutants are not well understood, the accumulation of toxic compounds could lead to a stress condition in an organism (4, 9, 11). Chromium as a metal could have an immunotoxic effect on marine mammal health (5, 9, 11, 12). Lead may increase the susceptibility of animals to diseases and determine hepatic lesions, mostly hepatocytic fatty vacuolation (11). It was speculated that polycyclic aromatic hydrocarbons induced tumors in belugas of St. Lawrence River estuary through the formation of DNA adducts. However, DNA adducts occur at similar levels in liver of beluga from remote location without significant PAH contamination. In other cetacean species tumors occur very rarely (12). While is not easy to relate dolphin death to contaminants, the accumulation of metals represent a risk factor to dolphin health (11, 15, 19, 20).

MATERIALS AND METHODS

Between April 2005 and October 2008, along Romanian Black Sea coast, have been found beached six dolphins proper for histopathological sampling. The stranded dolphins were four *Phocoena phooaena* dolphins and two *Tursiops truncatus* dolphins, three males and three female. All dolphins were found dead on the beach; however, might actually have been by-caught, their corpses being released at sea afterwards. All tissues processed in the laboratory have been properly labeled and fixed in 80^{c} alcohol. Tissues were infiltrate with paraffin, sectioned at 5 microns, placed on glass slides, stained with trichromic Mallory stain. Slides were examined using ordinary light microscopy 10 x and 400x.

RESULTS

Pathologic findings are summarized in Table 1.

Table 1. Hepatic lesions recorded in Black Sea dolphins

Lesions/Species	**No. carcases**	**Femele**	**Male**	***Phocoena phocoena***	***Tursiops truncatus***
Hepatic congestion	1	-	1	1	-
Intraarterial thrombosis	1	1	-	1	-
Minor distrophic processes	3	1	2	2	1
Difuse hepatic lipidosis	6	4	2	4	2
Inflammations (intravascular and interstitial inflammatory infiltrate)	2	1	1	1	1
Intravascular endothelial proliferations	1	1	-	1	-
Necrosis	1	1	-	1	-
Modified hepatic structure (dissociation of hepatocytes lamine)	2	1	1	2	-
Conjunctive neogenesis	2	1	1	1	1
Fibrosis (perivascular and interstitial)	2	1	1	1	1

The main hepatic lesion was difuse hepatic lipidosis, which was diagnosed in all six dolphins, four *Phocoena phocoena* and one *Tursiops truncatus*, three females and three males. In liver parenchyma were seen intra-cytoplasmic small and large vacuoles from round to oval shapes, without any content. The only macroscopic evidence of this disease was diffusely pale liver (Fig.1).
Minor distrophic processes were found in three dolphins, two *Phocoena phocoena* and one *Tursiops truncatus*, two females and one male. These degenerative processes were seen in hepatocytes cytoplasma as round or oval vacuoles with or without content.

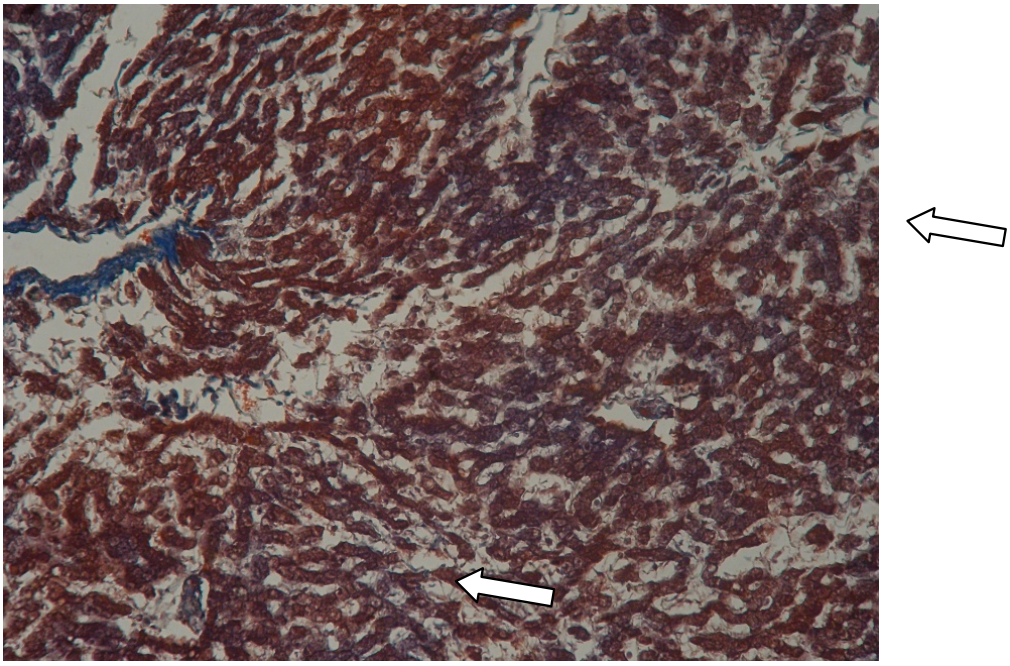

Fig. 1 Intra-cytoplasmic vacuoles, Mallory stain, 10x

Inflammations (intravascular and interstitial inflammatory infiltrate) were identified in two dolphins, one *Phocoena phocoena* and one *Tursiops truncatus*, one female and one male. The histopathologic appearance of this lesion was a diffuse inflammatory infiltrate in portal areas, around the hepatic veins, and within hepatic sinusoids. This inflammatory infiltrate varied from mild to severe in the different cases, and it was composed of lymphocytes and plasma cells (Fig. 2).

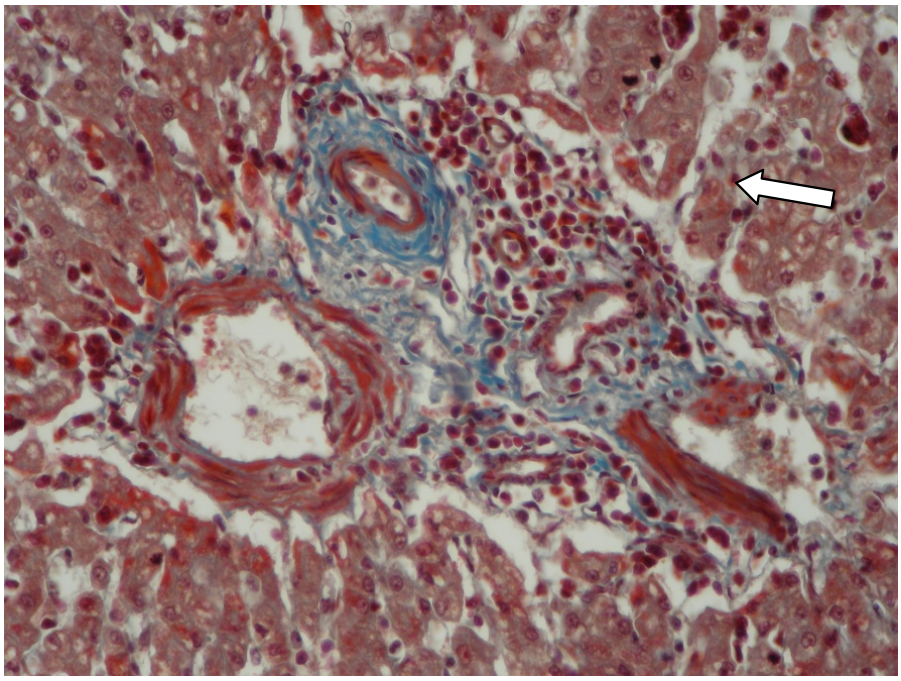

Fig. 2 Inflammatory infiltrate, Mallory stain, 400x

Modified hepatic structure, dissociation of hepatocytes lamine, was observed in two dolphins, two *Phocoena phocoena*, one female and one male. The hepatocytes lamine were divided in smaller parts, being isolated from the main parenchyma. The normal consequence is hypoxia and anoxia, followed by necrosis (Fig. 3).

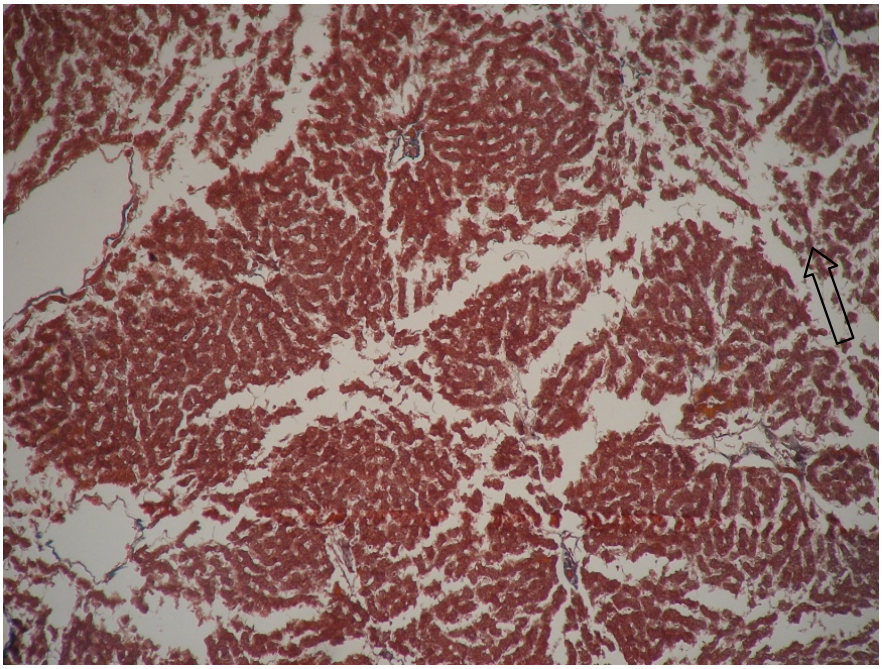

Fig. 3 Dissociation of hepatocytes lamine, Mallory stain, 10x

Conjunctive neogenesis was found in two dolphins one *Phocoena phocoena* and one *Tursiops truncatus*, one female and one male. The lesion was located around perilobulare veins and in parenchyma. Hepatic cells were replaced by conjunctive fibres.

Fibrosis was observed in two dolphins, one *Phocoena phocoena* and one *Tursiops truncatus*, one female and one male. Fibrosis was seen around hepatic veins and in parenchyma (Fig. 3).

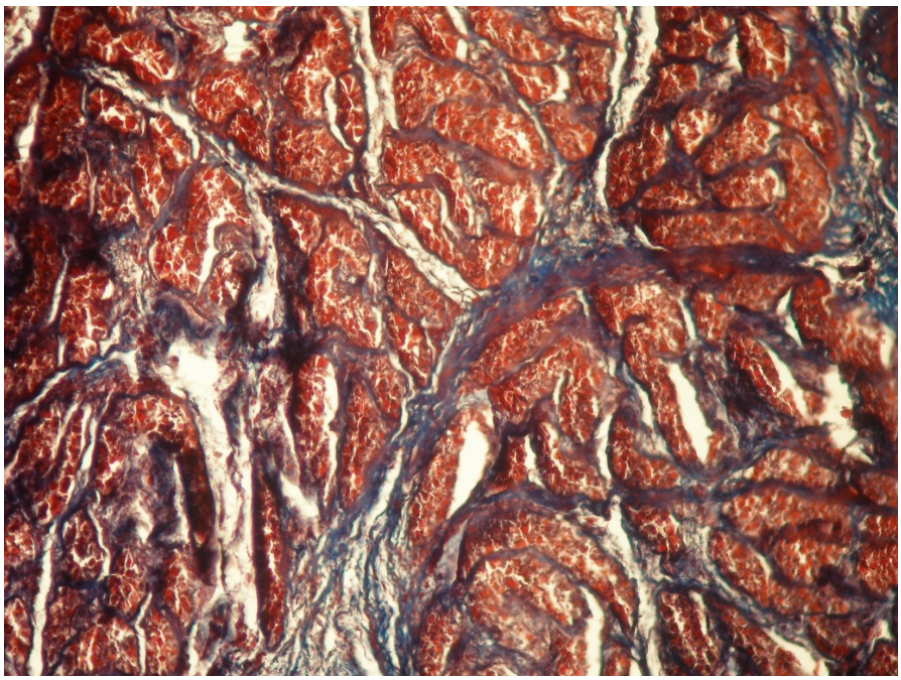

Fig. 3 Fibrosis in parenchyma, Mallory stain, 400x

Neoplastic lesions were not seen in any of the livers examined.

DISCUSSION

Hepatic lipidosis is a relatively common finding in stranded cetaceans with metabolic disorders produced by toxic injuries or nutritional deficiencies. Stranded animals with severe starvation, or breast-feeding animals that have a dietary intake high in carbohydrates, may accumulate excessive triglycerides within hepatocytes. The hepatic lipidosis observed in this study occurred in adult animals and, therefore, could be related for example, to poor nutrition or a toxic insult, thus making it very difficult to establish a common etiology for the lesions in these animals (8).
Other diagnostic present in the cetaceans in this study was a nonspecific chronic reactive hepatitis, which was characterized by infiltration of lymphocytes and plasma cells thorough the liver parenchyma and in the portal or perivenular stroma with or without minimal hepatocytic necrosis. Nonspecific reactive hepatitis, which may be acute or chronic, has been reported as a type of hepatitis different from chronic active hepatitis in human beings and dogs (8). In both species, histopathologic features of nonspecific chronic reactive hepatitis were quite similar to that observed in the cetaceans of the present study. Several types of hepatitis, particularly nonpurulent, interstitial hepatitis and subacute to chronic pericholangitis, have been commonly found in wild, free-living, and captive dolphins (7, 8). In human beings, nonspecific reactive hepatitis is a morphologic entity widespread within the liver, representing either the residuum of previous inflammatory intrahepatic disease or a response to a variety of extrahepatic disease processes, especially febrile illnesses and inflammation somewhere in the splanchnic bed. In domestic animals, it is almost always related to systemic disease or diseases in the splanchnic bed (8). In the cetaceans of the present study, this lesion may be related with previous inflammatory processes of viral or bacterial origin and could be the results of toxic immunosupresion.
Hepatic lipidosis, nonspecific reactive hepatitis, dissociation of hepatocytes lamine, conjunctive neogenesis, fibrosis and necrosis were the main histologic findings in the livers of cetaceans analyzed in this study. The studied dolphins presented some or all degree from congestion to necrosis and then neogenesis and fibrosis, demonstrating the fact that Black Sea dolphins faced stressful environment due to pollution.

CONCLUSIONS

The cause of changes in the liver described in this paper can only be speculative. There is an enormous number of hepatotoxic agents (biological, chemical or physical) that could provoke such changes. Therefore pollutants could be considered the cause of these lesions but further studies are needed.

ACKNOWLEDGEMENTS

We are grateful to C. Mihai, N. Ursu and F. Timofte for the precious help in the collection of the samples.

REFERENCES

1. Birkun, Jr., 2003, – The Current Status of Bottlenose Dolphins (Tursiops truncatus) in the Black Sea http://www.iwcoffice.org/documents/sci_com/2003progreports/SC/55/ForInformation16/ProgRep%20USA.pdf.
2. Bossart, G. D., 2006, - Marine mammals as sentinel species for oceans and human health, *Oceanography Vol. 19, No. 2*.
3. Cardellicchio, N., Giandomenico, S., Ragone, P., Di Leo, A., 2000 – Tissue distribution of metals in striped dolphins, *Marine Environmental Research* **49**: 55-66.

4. Cowan, D. F., Curry, B. E., 2002 – Histopathological assessment of dolphins necropsied onboard vessels in the Eastern Tropical Pacific tuna fishery, Administrative report LJ-02-24C
5. Das, K., Debacker, V., Pillet, S., Bouquegneau, J. M., 2003, - Heavy metals in marine mammals, in: *Toxicology of Marine Mammals*, Taylor & Francis, London and New York, pp. 135-167.
6. Dumitrescu, E., Nicolaev, E., Cocciasiu, A., Oros, A., Coatu, V., 2004, – Data on Marine Environment Pollution from the Romanian Black Sea Coast, *Workshop: A glance to the Black Sea*, Umut Kağitcilik San.veTic.ltd. Şti. Istanbul, pp.66-82.
7. Gomercic, H., Huber, D., Gomercic, Vera, Vukovic, S., Skrtic, D., Gomercic, T., Dobranic, V., Lucic, H., Duras, M., Curkovic, S., Gomercic, Ana, Kardos, L., 2000 – Fatty liver and subcutaneous edema in a free bottlenose dolphin (*Tursiops truncatus*) from the Adriatic Sea; light- and electron-microscopical study, Veterinary arhiv 70 (5), 259-277.
8. Jaber, J. R., Perez, J., Arbelo, M., Andrada, M., Hidalgo, M., Gomez-Villamandos, M., Van Den Ingh, T., Fernandez, A., 2004 – Hepatic lesions in cetaceans stranded in the Canary Islands, Veterinary Pathology 41:147-153.
9. Kakuschke, A., Valentine-Thon, E., Griesel, S., Fonfara, S., Prange, A., 2005, – Immunological impact of metals in harbor seals (*Phoca vitulina*) of the North Sea, *Environ. Sci. Technol*. **39**: 7568-7575.
10. Norman, **A**., 2004, - Multidisciplinary investigation ofstranded harbour porpoises
11. O'Hara, T. M., O'Shea, T., 2001 - CRC Handbook of Marine Mammal Medicine, edited by Dierauf, Leslie A., Gulland, Frances M. D., CRC Press.
12. O'Shea, T., Aguilar, A., 2001, - Cetacea and Sirenia, in: *Ecotoxicology of Wild Mammals*, John Wiley & Sons, LTD, pp.428-480.
13. Piescu, V., Coatu, V., Oros, A., Patrascu, V., Pecheanu, I., 2004, Assessment of dangerous substances level of the Danube mouths, *Recherches Marine,* **35:** 39-59.
14. Polikarvop, G. G., Egorov, V. N., Gulin, S. B., Mirzoyeva ,N. Yu., 2004, – Pollution of the Black Sea and Suggestions on Solutions, *Workshop A Glance to the Black Sea,* Umut Kağitcilik San.veTic.ltd. Şti. Istanbul, pp. 91-128.
15. Roditi-Elasar, M., 2000, - Marine Pollution as a Morbidity Factor in Dolphins: Evidence from Heavy Metal Concentrations in Tissues and Bones of modern Dolphins Found along the Mediterranean Coast*, RIM newsletter 27*, http://maritime.Haifa.ac.il/cms/newslett/rims27/27-13.htm.
16. Simmonds, M. P., 2003, – *The Black Sea Dolphin – What Next?* http://www.icoffice/documents/sci_com/2003progreports/IWC/SC/55/SM12/ProgRep%20USA.pdf.
17. Strezov, A., Nonova, T., 2005, - Environmental monitoring of heavy metals in Bulgarian Black Sea green algae, **105**: 99-110.
18. *** - Consideraţii privind prezenţa şi mortalitatea delfinilor la litoralul românesc, http://www.cier.ro/new/delfini/Fisier%20Secundare/Consideratii.html.
19. *** - Environmental Contaminants in the Moray Firth cSAC, A Summary of Information of the Impacts/potential impacts on bottlenose dolphins and proxy species, http:/partenership.org/ext/extdocs/Centre/Environmental%20Contaminants%20and%20dolphins%20%20A%20Summary%20of%20information.pdf.
20. *** - Heavy metals*,* http://www.1.unep.org/marine-mammals/HeavyMetals.doc.

MONITORING THE ANTITOXIC EFFECT OF SOME GLUTATHIONE RICH VEGETAL PRODUCTS

Cornelia PRISĂCARU
University of Agricultural Sciences and Veterinary Medicine "Ion Ionescu de la Brad" Iaşi

ABSTRACT

Acrylic amide is a double unsaturated chemical compound that possesses a strong toxic potential, represented by neurotoxicity, carcinogenity, embriotoxicity and reproductive toxicity. Acrylamide takes birth during the thermal processing of foods, mainly by the Maillard reaction. The experiment presented in this paper represents a part from a sequence of experiments that aim to find possibilities of limiting the synthesizing process of this toxic. The experiment focuses on the antiradicalic effect of glutathione, based on the fact that acrylamide exerts its toxicity mainly through its epoxidic metabolite, glycidamide. The biochemical test battery (oxidative stress parameters: superoxid dismutase, glutathione peroxidase, catalase, free sulfhydryl groups) carried out on rats treated with pure tripeptide, yeast and avocado fruit emphasize the existence of a significant antiradicalic effect of glutathione in acrylamide intoxication.

Key words: acrylamide, oxidative stress, soya aqueous extract, avocado aqueous extract.

INTRODUCTION

Acrylamide (AA), a chemical compound known since the end of XIXth century for its neurotoxic and carcinogenic effects, was found in fried, roasted, baked and grilled food by the Swedish researchers in April 2002. Consequently, carcinogenic action has been reconfirmed by experimental researches on laboratory animals and by epidemiologic studies. Furthermore, acrylamide was found to be a genotoxicant and a reproductive and developmental toxicant (1, 2, 3). Among the toxics that aggress the organism by the means of foods is classified acrylamide, a substance that is formed during the thermal processing of aliments. The numerous ways of formation are facilitated by many factors that crystalize around the presence of some precursors like: amino acids (alanine, asparagine and glutamine, methionine), triglycerides or monoglycerides, acetaldehyde and formaldehyde, or the Maillard precursors. The sustained efforts regarding acrylamide conducted finally to an experimentally proved mechanism of acrylamide formation starting from the amino acid called asparagine and reducing sugars that undergo the Maillard reaction (4, 5, 6, 7).

MATHERIAL AND METHOD

The present experiment is part of a more ample project that regards finding diminishing methods of some alimentary noxes by phytotherapeutical means (8, 9, 10, 11). The experimental model was made up of 5 groups of white rats, Wistar line, with a mean body weight of 216.8 g. The first group represented the reference group, the values of the tested parameters being compared to these values. The second group was considered the control lot of the oxidative stress provoked by acrylamide (control group 1), taking into consideration the fact that the toxicodynamics of acrylamide is consumed by the free radicals of glycidamide, the major metabolite of acrylamide resulted consequently to the epoxidic reaction. In this direction, the animals of this group were

treated with acrylamide in doses of 25 µg/Kg bw/day. The animals of the third group (control group 2) were chosen to monitorize the antioxidant-antitoxic effect of glutathione, the most popular non-vitaminic antioxidant. In order to achieve this objective, the 5 rats were administered a dose of 10 drops of a 3% aqueous solution of glutathione, along with the regular acrylamide dose. The fourth group, experimental group 1, was treated with 20 drops of a 3% aqueous solution of *Sojae semen*, trying to evaluate the antiradicalic capacity given by the glutathione content. The last group, experimental group 2, was made up in order to test the antioxidant potential of a phytoextract obtained from avocado fruit (*Percea americana*). According to this necessity, the animals of this group received, along the usual acrylamide dose, 20 drops of the aqueous extract of avocado fruit. At the end of the experiment, unfolded on a period of 6 weeks, blood samples were collected in order to determine the biochemical parameters of oxidative stress: catalase (CAT), superoxid dismutase (SOD), glutathione peroxidase (G-Px) and free sulfhydryl groups.

Table 1 Experimental model

Groups	**ACR [µg/Kgc]**	**G-SH aqueous extract 3%**	**3% aqueous soya extract**	**3% aqueous avocado extract**	**Biochemical parameters**
Reference group	-	-	-	-	CAT, SOD, G-Px, -SH
Control group 1	25	-	-	-	
Control group 2	25	10 drops	-	-	
Exper. group 1	25	-	20 drops	-	
Exper. group 2	25	-	-	20 drops	

Legend: ACR = acrylamide; G-SH = glutathione; CAT = catalase; SOD = superoxid dismutase; G-Px = glutathion peroxidase; -SH = free sulfhydryl groups

RESULTS AND DISCUSSIONS

The study of catalase evolution in the serum of the rats, as it is shown in table 2 and figure 1, emphasizes a strong diminution of the activity of this enzyme for the animals that were administered acrylamide (control group 1). This diminution reveals the implication of this enzyme in annihilating the free radicals resulted from acrylamide. The catalase activity is significantly higher for the groups protected with glutathione, both in pure form and from vegetal products. Comparing the glutathione protected groups the conclusion that the highest antioxidant potential belongs to soya extract can be drawn. In this case, the catalase values are significantly closet o the reference group.

Table 2 Evolution of catalase

CATALASE (U/L)			
Experimental groups	**Mean**	**Minimum**	**Maximum**
Reference group	560,19	499,50	581,3
Control group 1	441	398,9	493,7
Control group 2	542,13	489,9	588,3
Exper. group 1	552,3	489,5	585,5
Exper. group 2	525,4	500	583,3

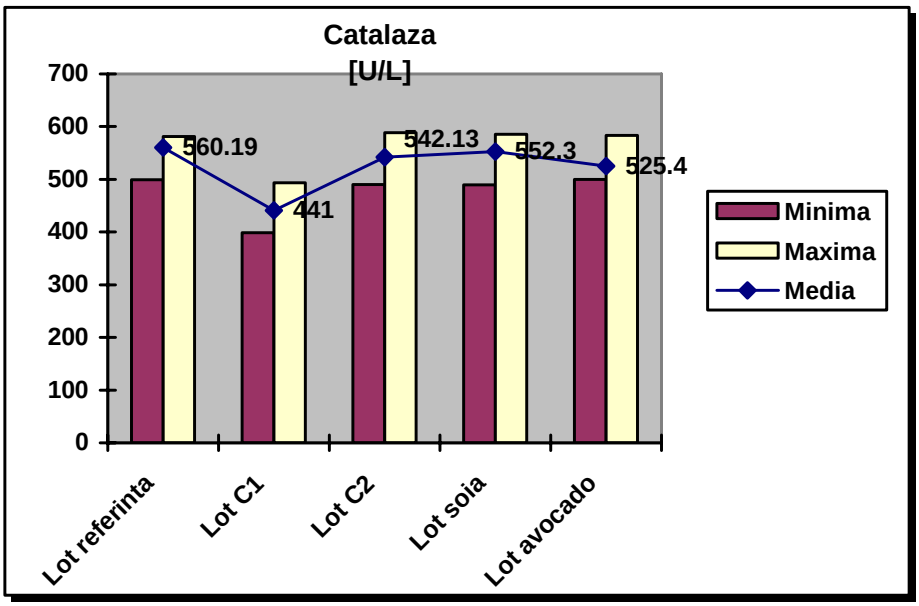

Fig.1 Catalase evolution

Table 3 Superoxid dismutase evolution

SUPEROXID DISMUTASE (U/L)			
Experimental groups	**MEAN**	**MINIMUM**	**MAXIMUM**
Reference group	438,383	415	469,5
Control group 1	378	342,9	453,5
Control group 2	431,33	420,2	459
Exper. group 1	437,77	423,9	465
Exper. group 2	424,4	416	459,9

The evolution of superoxid dismutase values (table 3, fig.2), enzyme that acts together with catalase, is almost identical with the evolution of this previous enzyme. The activity of superoxid dismutase decreases dramatically for the group that was administered only the solution of acrylamide, while for the groups protected with one of the glutathione sources an obvious improvement appears, the closest value being registered in the case of the soya extract.

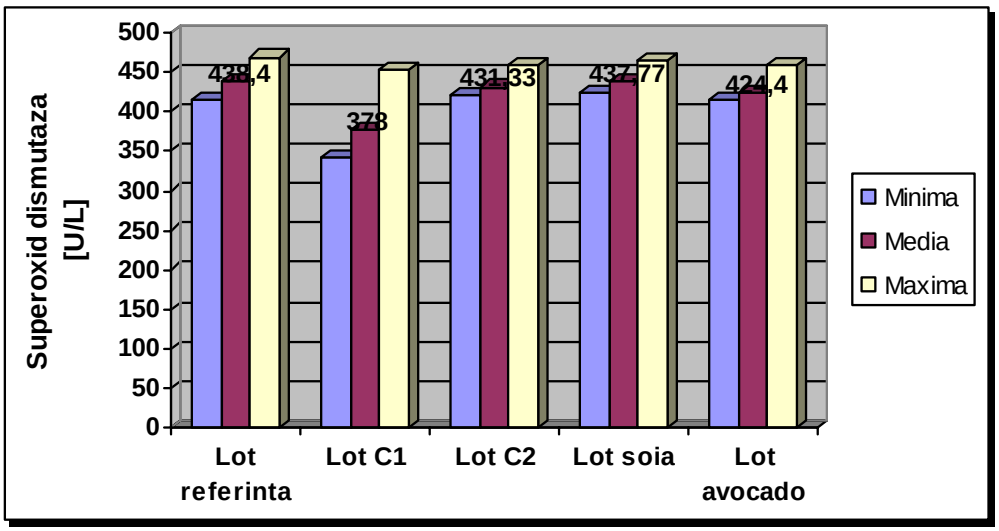

Fig. 2 Superoxid dismutase evolution

Table 4 Superoxid dismutase evolution

GLUTATHIONE PEROXIDASE (U/L)			
Experimental groups	**Mean**	**Minimum**	**Maximum**
Reference group	56,88	49,51	61,2
Control group 1	51,33	49,16	53,5
Control group 2	60,74	59,6	66,15
Exper. group 1	57,76	54,12	66,12
Exper. group 2	58,5	53,5	69,6

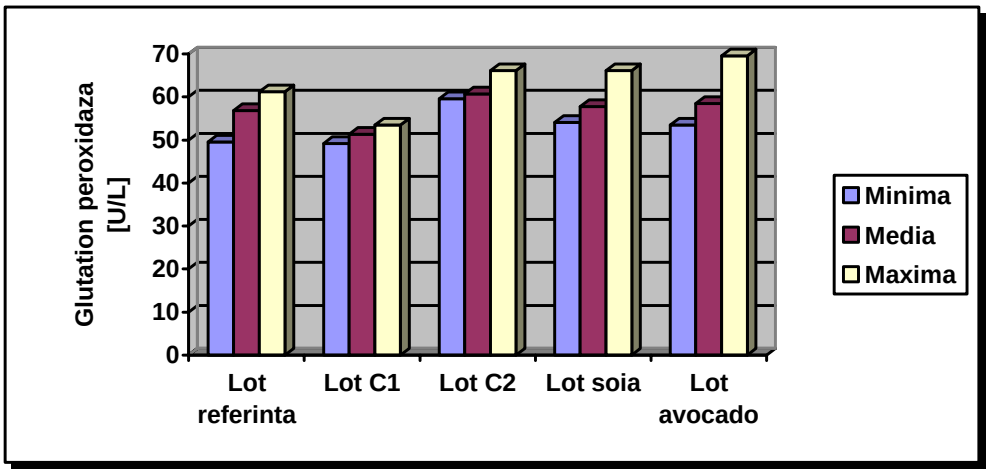

Fig.3 The activity of glutathion eperoxidase

The third parameter of oxidative stress, glutathione peroxidase, is an enzyme that forms in proportion of 70% an antioxidant system with SOD in cytosol and in proportion of 30% with catalase in mitocondria, endoplasmatic reticulum and peroxisomes, acting mainly on peroxidic radicals. The variation of this parameter, in the context of the present experiment, is very eloquent, as can be seen in figure 3 and table 4. From the study of these values, a discreet diminution of the enzyme with 5.55 units can be noticed for the group that was administered only the acrylic amide. The improvement of the values is significant for the groups protected with the tripeptidic antioxidant. In these cases, the activity of the enzyme outruns the values of the reference group. Thus, for the group protected with soya extract, the activity of glutathione peroxidase rises to 57.7 U/L, while for the group protected with avocado extract the value of the enzyme is 58,5U/L. The maximum of the activity is reached in the blood of the animals treated with pure glutathione (60.74 U/L). The quantification of free thiols (fig. 4 and table 5) leads to results that sustain the antiradicalic effect of the vegetal products that contain glutathione, the most convincing value belonging to the group treated with soya extract (371 µmol/mL compared to 375.5 µmol/mL, the value for the control group).

Table 5 Concentration of free sulfhydryc groups

FREE SULFHYDRYC GROUPS (µmol/mL)			
Experimental groups	MEAN	MINIMUM	MAXIMUM
Reference group	355,26	348	395,6
Control group 1	332,5	311	342
Control group 2	375,5	349	536
Exper. group 1	371	355,6	399
Exper. group 2	353,33	331	389

CONCLUSIONS

1. The evolution of seric catalase emphasize the fact that the most strong antioxidant potential belongs to the seeds soya extract;
2. The evolution of superoxid dismutase, similar to the evolution of catalase, reveals the same implication in anihilating the free radicals resulted from the presence of acrylamide and the antioxidant potential of the soya extract;
3. The oscilation of glutathione peroxidase sustains the antiradicalic potential of the vegetal products that contain glutathione (soya and avocado extracts), but demonstrate that the pure glutathione owns the most strong potential;
4. The quantification of the free sulfhydryc values sustains the fact that the most important antioxidant potential belongs to soya extract.

BIBLIOGRAPHY

1. ******* - CERHR, Monograph on the Potential Human Reproductive and Developmental Effects of Acrylamide (2005).
2. Dybing, E., Farmer, P. B., Andersen, M., Fennell, T. R., Lalljie, S. P. D., Muller, D. J. G., Olin, S., Petersen, B. J., Schlatter, J., Scholz, G., Scimeca, J. A., Slimani, N., Tornqvist, M., Tuijtelaars, S., Verger, P. (2005). Human exposure and internal dose assessments of acrylamide in food. *Food and Chemical Toxicology*, 43: 365–410.
3. Dybing, E., Sanner, T. (2003). FORUM: Risk Assessment of Acrylamide in Foods. *Toxicological Sciences*, 75: 7-15.
4. Ehling, S., Hengel, M., Shibamato, T. Formation of acrylamide from lipids, Anaheim, CA, 227th ACS National Meeting, 2004.
5. Eriksson, E., Acrylamide in food products: Identification, formation and analytical methodology. Doctoral Thesis, Stockholm University, 2005: 5-7; 9-10.
6. Lindsay, R., Generalized Potential Origins of Acrylamide in Foods, Workshop on FRI Acrylamide Project, Chicago, 2002.
7. Mottram, D. S, Wedzicha, B. L., Dodson, A. T. (2002). Acrylamide is formed in the Maillard reaction. *Nature*, 419: 448-9.
8. Burlacu Anca-Irina – Cercetări privind prezenţa acrilamidei în alimentele prelucrate termic. Teză de doctorat. Universitatea de Medicină şi farmacie *Gr. T. Popa* Iaşi (2009).
9. Prisăcaru, C., Rotaru, L. (2008). Monitorizarea efectului antitoxic al unor uleiuri volatile ce conţin ftalide (*Apii aetheroleum* şi *Levistici aetheroleum*). *Med. Chir. Soc. Med. Nat. Iaşi*, vol II, 112, nr 1, Supliment nr 1: 412-416;
10. Prisăcaru, C., Burlacu, A. I., Rotaru, L. (2008). Evaluation of biochemical changes from oxidative stress specific to ochratoxicosis induced by *Apii aetheroleum* administration. *Lucrări ştiinţifice USAMV, secţia Medicină Veterinară, Iaşi*, 51(10): 140-143 ;
11. Prisăcaru, C., Burlacu, A. I. (2009). Evaluation of the Antitoxic Effect of Phthalides from *Apium graveolens* in Acrylamide Intoxication I. Evolution of the Hepatic Cytolysis and Proteosynthetic Parameters in Acrylamide Intoxication on Background of Phthalide Protection. *Notulae Botanicae Hort. Agrobot.*, 37 (2): 129-133.

STUDY OF SOME OXIDATIVE STRESS PARAMETERS DYNAMICS UNDER THE INFLUENCE OF THE EXOGEN ASCORBIC ACID CONTRIBUTION IN SUBACUTE ACRYLAMIDE INTOXICATION

Anca Irina PRISĂCARU[1], Cornelia PRISĂCARU[2]

[1] University of Medicine and Pharmacy "Gr. T. Popa" Iaşi, irina.prisacaru@yahoo.com
[2] University of Agricultural Sciences and Veterinary Medicine "Ion Ionescu de la Brad" Iaşi

ABSTRACT
Acrylamide, a well known food toxicant formed during the thermal culinary process, possesses a toxicological profile characterized by carcinogenicity, mutagenicity, neurotoxicity, and reproductive toxicity. The present experiment is framed into the category of experiments that have as research direction the study of diminishing the acrylamide toxicity and aims to evaluate the biochemical changes in subacute acrylamide intoxication and the protective potential of ascorbic acid. The experiment was performed on 5 groups of male rats, Wistar line, and unfolded on a period of 2 weeks. At the end of the experiment, blood samples were collected from the retro-orbital sinus in order to determine the oxidative stress parameters (seric catalase and superoxid dismutase) and liver detoxifying parameters (free sulfhydryl groups and seric ascorbic acid). The results emphasize the implication of the toxic amide in increasing the concentration of the oxygen reactive species, mainly by its major epoxidic metabolite, glycidamide. The benefic action of ascorbic acid is demonstrated by the important improvement of the oxidative stress parameters.

Key-words: acrylamide, glycidamide, superoxid dismutase, catalase, free sulfhydryl groups

INTRODUCTION

The experimental research on laboratory animals have proven the neurotoxic potential of acrylamide, translated into tremor, lack of coordination, ataxy, muscle weakness, increased bladder, loss of weight, severe tonico-clonic convulsions and other clinical signs of diffuse central excitement (1). Moreover, the research in the field have shown the carcinogen potential of acrylamide for laboratory animals, the molecule of the toxic amide producing the increase of incidence of certain malignant or benign tumors, identified in different organs such as the thyroid, suprarenal glands, testicular mesothelioma and mammary glands (2). Recent experimental research proves the importance of the vitamin-related antioxidants for the protection of live organisms against the toxic action of the harmful chemical substances. The ascorbic acid is an important food antioxidant, which fights the effects of the reactive species of oxygen, that are responsible for the oxidative stress put on the lipidic, proteic macromolecules, DNA involved in the chronic neurodegenerative diseases (3, 4, 5, 6). The objectives of this paper are as follows: assessment of the biochemical modifications in the acrylamide subacute intoxication to laboratory animals, comparison of the acrylamide toxic effects intensity by means of the oxidative stress indices and detoxifying parameters but also the estimation of the potential protective effect of ascorbic acid.

MATERIAL AND METHOD

After the collection, the blood samples meant for the biochemical determinations were left at room temperature for coagulation, and then centrifuged for 15 minutes, at 3000 rotations per minute. The obtained serum was immediately subjected to the biochemical investigation which was performed as a test battery following two main directions:

I. **Assessment of the oxidative stress:**
   a) the determination of the seric catalase activity (CAT);
   b) the determination of the superoxid dismutase activity (SOD)

II. **The evaluation of the hepatic detoxification function**
   a) quantitative determination of free sulfhydryl groups;
   b) the determination of ascorbic acid.

RESULTS AND DISSCUSSIONS

I. Evaluation of the oxidative stress

The test set which aimed at the assessment of the oxidative stress caused by the acrylamide inflow and the monitoring of the antioxidant effect of the ascorbic acid comprised two biochemical parameters: the catalase and the superoxid dismutase (SOD).

a) ***Evaluation of catalase***

The results obtained following the quantification of the catalase activity in the serum of the animals contained in this experiment are shown in fig. I. The catalase, an enzyme located in the mitochondria and peroxisomes registers obvious changes for the groups which were intoxicated using acrylamide, which shows its involvement in the neutralizing reactions of the reactive species of oxygen, which are liable for the occurrence of the oxidative stress.This involvement is supported by the decrease of its activity in the serum of the group which was treated using 50 mg/kg body weight dosages of acrylamide, where the value decreases from 605.58 U/L (value that characterizes the reference group) to 543.15 U/L. A similar situation, even more relevant, occurs in the group which was treated using the 100 mg/kg body weight dosage of acrylamide, where the activity of the enzyme decreases to 411 U/L. While the presence of the oxidative stress is suggestive, the same degree of eloquence is present in the antioxidant intervention of the ascorbic acid. This statement is supported by the evolution of the catalase activity for the groups which benefited from the ascorbic acid protection. Thus, the activity of the enzyme in the serum of the animals protected using vitamin C increases to 579.65 UI in comparison with that of the animals treated with 50 mg/kg body weight of acrylamide and non-protected using vitamin C, where the value is of 543.15 UI. In the case of the animals which benefited from the ascorbic acid protection on the background of the inflow of a 100 mg/kg body weight dosage, an increase of the CAT activity to 504.34 U/L is registered, in comparison with the animals which did not receive the antioxidant vitamin dosage, the value of the enzyme in their blood being consumed by the free radicals of oxidative stress at 433.14 U/L.

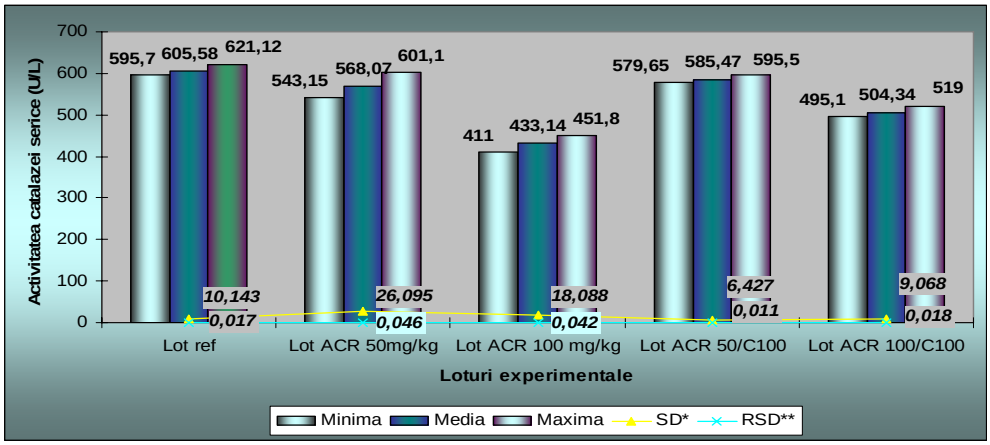

Legend: Lot ref = reference group; ACR = acrylamide; ACR 50 = acrylamide 50 mg/kg/48 h; ACR 100 = acrylamide 100 mg/kg/48 h; C 100 = ascorbic acid 100 mg/kg/48 h; SD* = standard deviation; RSD ** = relative standard deviation

Fig. I. Evolution of the catalase activity

b) ***Evaluation of superoxide dismutase***

The second oxidative stress parameter, the superoxid dismutase (SOD), is a metalloenzyme which acts along with catalase, its sublayer being the superoxide radical ($O_2^{\cdot -}$). The results obtained following the quantification of this antioxidant are comprised in fig. II.

The study of these values shows a similar evolution to that of the other oxidative stress index, the catalase. Just like in catalase case, the SOD activity is progressively diminished from the reference group (459.92 U/mL) to the group which was intoxicated using the 50 mg/kg body weight dosage (375.04 U/mL), the most diminished value (346.6 U/mL) being that of the group which experienced the doubling of the acrylamide dosage. The study of the SOD activity values in the serum of the animals protected by ascorbic acid highlights improvements of the enzyme's activity towards values which suggest a decrease of the oxidative stress, decrease which may be the consequence of its neutralization by the redox system L-ascorbic acid/L- dehydroascorbic acid. Thus, the SOD value is improved for the group which was treated simultaneously with acrylic amide and vitamin C (408.16 U/mL) in comparison with the group which was deprived of the ascorbic acid protection (375.04 U/mL). The same improving ascension is also registered by SOD in the serum of the animals which were intoxicated using 100 mg/kg body weight of acrylamide and simultaneously treated with vitamin C (392.37 U/mL) in comparison with the animals which did not receive the inflow of vitamin C (346.6 U/mL).

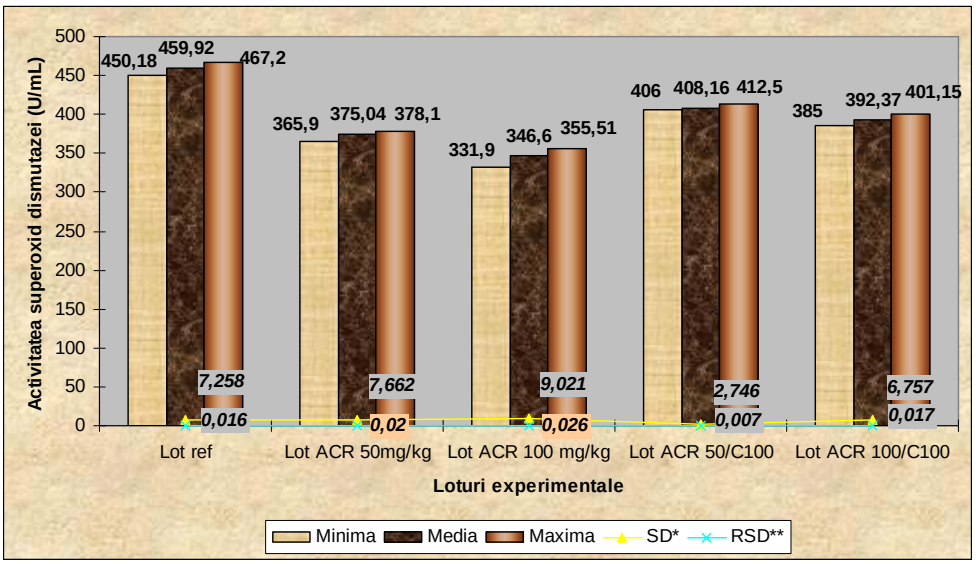

Legend: Lot ref = reference group; ACR = acrylamide; ACR 50 = acrylamide 50 mg/kg/48 h; ACR 100 = acrylamide 100 mg/kg/48 h; C 100 = ascorbic acid 100 mg/kg/48 h; SD* = standard deviation; RSD ** = relative standard deviation

Fig. II. Evolution of the superoxid dismutase (SOD) activity

II. Evaluation of the detoxification function of the liver

The liver, organ with the highest metabolic flexibility, benefits at the same time of the most obvious vacillation as regards the inducement of specific enzymes in response to the changeability of the nutritive supply provided to it (7). The detoxification function of liver depends on this inductive vacillation of enzymes, mainly of the metabolizant enzymes, function which has to be investigated when toxic implications of acrylamide and vitamin C antioxidizing effects are evaluated.

a) ***Evaluation of free sanguineous sulfhydryl groups***

To evaluate liver detoxification capacity, one of its most important functions, a major role is played by γ-glutamyl cysteinil-glycine, glutathione. This tripeptide serving as a constituent element of

amino acid transport systems, activating agent of some enzymes, protector against oxidation of some cell components, is in a dynamic equilibrium with the free plasmatic sulfhydryl groups (8).
Results of quantitative measures of –SH groups in the plasma of animals included in the experiment presented in this chapter are rendered in figure III. Study of the values obtained after quantification of free thiolic groups shows that the highest level is found in the plasma of the animals from the reference group (389.64µmol/mL).

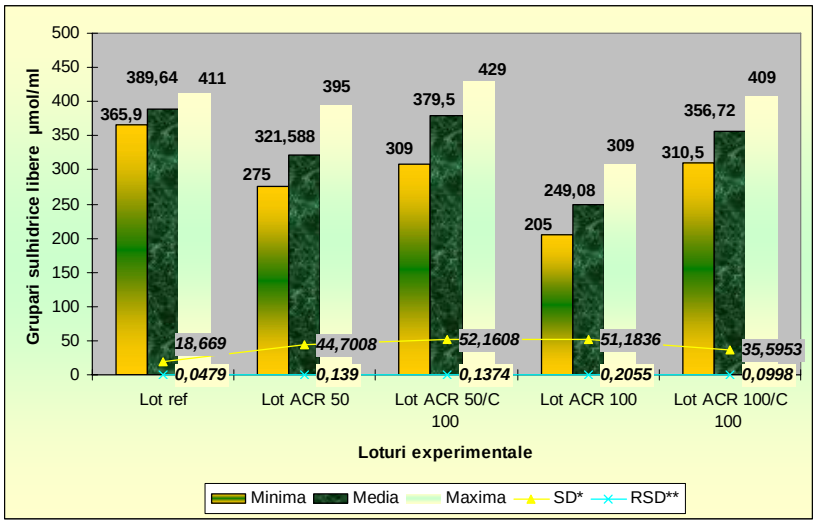

Legend: Lot ref = reference group; ACR = acrylamide; ACR 50 = acrylamide 50 mg/kg/48 h; ACR 100 = acrylamide 100 mg/kg/48 h; C 100 = ascorbic acid 100 mg/kg/48 h; SD* = standard deviation; RSD ** = relative standard deviation

Fig. III. Plasmatic level of free sulfhydryl groups

Comparative analysis of plasmatic concentrations of the free sulfhydryl functions for the groups intoxicated with acrylamide leads to uncommon significant reductions. Thus, level of –SH free groups in the plasma of the animals in the group treated with 50 mg/kg acrylamide drops from normal value of 389.64 µmol/mL to 321.588 which proves that they have wasted themselves against glycidamide free radicals. A more significant decrease is found in the plasma of animals treated with 100 mg/kg acrylamide, case in which the value is 249.08 µmol/mL. This severe diminution confirms the hypothesis over the exhaustion of free thiolic groups, as result of the attack of epoxidic radicals of acrylamide or their use for activating some metabolizable enzymes of the gluation-S-transferase type (ligandin), cellular enzyme rendered evident through its 5 iso-enzymes (9, 10). Monitoring variations of concentration of -SH free plasmatic groups for the groups protected with 100 mg/kg vitamin C, an improvement in their plasmatic level can be noticed, which means an improvement of the detoxification function. In this respect we observe that the level of the free thiolic groups in the plasma of the third lot of animals intoxicated with 50 mg/kg acrylamide and protected with a dose of 100 mg/kg ascorbic acid is increased to 379.5 µmol/mL. Plasmatic concentration of the free thiols of this lot rises to a value drawing nearer to that of the refernce group. A more significant increase in the concentration of free thiolic functions is obvious in the fifth lot which benefited from supply of antioxidant vitamin, where value goes to 356.72 µmol/mL when inside the plasma of the unprotected group the level of 249.08 µmol/mL has been quantified. This situation shows an improvement of the liver detoxification potential which benefited from the antitoxic/antioxidant effect of vitamin C.

b) Evaluation of the ascorbic acid in the serum

Numerous implications of this controversial molecule with a vitamin function are put down to the redox character of the ascorbic acid. The detoxification role, the starting point of this experiment, is ensured by the property of accelerating the xenobiotics'metabolism by means of the

intervention over the microsomial hydroxylant system. However, due to this effect and owing to the capacity of this redox molecule of inhibiting the peroxidase, the ascorbic acid is incriminated by the bioactivation of the procarcinogens as benzipyren, aflatoxins, etc. The antitoxic potential of vitamin C is also expressed by the antioxidizing action, action mainly exerted over the $^1O_2$, $OH^{\cdot}$, and the peroxides radicals. Thanks to this major evidence which supports the antitoxic role of the ascorbic acid the present experiment is trying to establish if the supply of this vitamin on the background of the poisoning with acrylamide has reverberations over ascorbemia, marker of the detoxification function. Results of the monitoring of this biochemical parameter, results shown in fig. IV, point out values which seem to evolve non-uniformly at first sight, but which significantly correlate with data in reference literature. The study of these results leads to the idea that ascorbemia of animals belonging to the reference group come to the average value of 74.66µ mol/L.

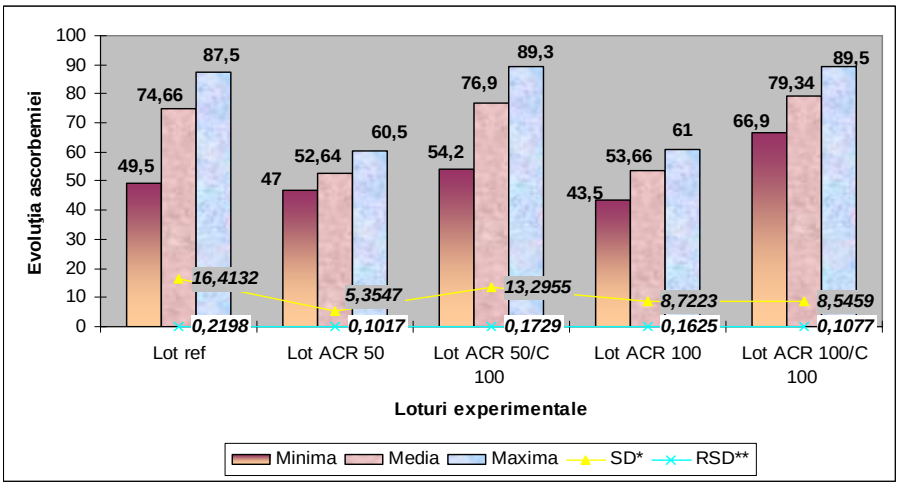

Legend: Lot ref = reference group; ACR = acrylamide; ACR 50 = acrylamide 50 mg/kg/48 h; ACR 100 = acrylamide 100 mg/kg/48 h; C 100 = ascorbic acid 100 mg/kg/48 h; SD* = standard deviation; RSD ** = relative standard deviation

Fig. IV. Evolution of ascorbemia

Comparing variations of the ascorbemia for the animals intoxicated with acrylamide we notice a very significant decrease which may be due to the consumption of the ascorbic acid after destruction of free radicals excess caused by the presence of the alimentary toxin. Thus, the concentration of ascorbic acid for the animals undergoing intoxication with acrylamide 50mg/kg/48hours is 52.64 µmol/L, whereas for the group intoxicated with 100mg/kg acrylamide/48 hours ascorbemia is 53.66µmol/L. Surprisingly, the ascorbemia of the animals in the group which received acrylamide in double dose (100mg/kg/48 h) has a slightly increase value compared to that of the lot which received half the dose alimentary toxin. The increase of ascorbic acid in the blood of the animals agressed by the big dose of acrylic amide may be interpreted as reaction of adaptation to the presence of high concentration of free radicals (11). Analysis of the ascorbemia in the groups protected with vitamin C points out to its significant increase compared with the unprotected lots. This way, the plasmatic concentration of ascorbic acid for the animals of the lot intoxicated with acrylamide 50mg/kg and protected with 100mg/kg vitamin C increases to 76.9 µmol/L compared to 52.64 µmol/L, the value of the lot intoxicated with the same amount of acrylamide and unprotected. One should even observe that value of ascorbemia of this lot exceeds by 2.24 units the value of ascorbemia of the reference lot. This increase cannot be interpreted but as a direct consequence of supply exogen C vitamin. A more prominent increase (79.34 µmol/L), an increase which exceeds even the number of the reference group by 4.68 µmol/L, appears in the group treated with 100 mg/kg acrylamide and 100mg/kg vitamin C, fact that confirms the previous results.

CONCLUSIONS

1. The variation of the catalase denotes its certain involvement in the neutralization reactions of the reactive species of oxygen, which are liable for the occurrence of the oxidative stress; this involvement is supported by the decrease of its activity in the serum of the groups which were intoxicated with acrylamide and the improvement of its activity for the groups which benefited from the ascorbic acid protection;
2. The sinuous game of the superoxid dismutase (SOD) activity for the groups in the experiment confirms the antitoxic/antioxidant action of ascorbic acid against the SRO_2 attack, chemical species which generate the oxidative stress.
3. The comparative analysis of free sulfhydryl groups for the groups intoxicated with acrylamide leads to significant decreases that sustain the hypothesis that the thiolic groups were consumed consequently to the attack of the epoxidic radicals of acrylamide.
4. The plasmatic levels of free thiols for the groups protected with ascorbic acid reach values that are closed to the reference group, illustrating an improvement of the detoxifying potential of the liver.
5. Comparing the variation of the ascorbemia for the groups intoxicated with acrylamide, a significant decrease can be observed. This decrease can be explained by the depletion of ascorbic acid consequently to the free radicals excess provoked by the presence of acrylamide.
6. Ascorbemia of the group that received 100 mg/kg acrylamide has a higher value than the group intoxicated with 50 mg/kg acrylamide. This increase can be interpreted as an adapting reaction to the presence of high concentrations of free radicals.
7. The analysis of ascorbemia for the groups protected with ascorbic acid emphasize an increase compared to the unprotected groups, increase that can be interpreted as a direct consequence of the exogen contribution of the vitamin.

BIBLIOGRAPHY

1. *** - CERHR, Monograph on the Potential Human Reproductive and Developmental Effects of Acrylamide (2005).
2. Dybing, E., Sanner, T. (2003). FORUM: Risk Assessment of Acrylamide in Foods. *Toxicological Sciences*, 75: 7-15.
3. Ghosha, M., Talukdara, D., Gosha, S., Bhattacharyyaa, N., Raya, M., Ray, S. (2006). In vivo assessment of toxicity and pharmacokinetics of methylglyoxal. Augmentation of the curative effect of methylglyoxal on cancer-bearing mice by ascorbic acid and creatine. *Toxicology and Applied Pharmacology*, 212: 45 – 58.
4. Hana, J.-M., Changa, B.-J., Lib, T.-Z., Choeb, N.-H., Quana, F.-S., Janga, B.-J., Choa, I-H., Hongc, H.-N., Leea, J.-H. (2007). Protective effects of ascorbic acid against lead-induced apoptotic neurodegeneration in the developing rat hippocampus *in vivo. Brainresearch*, 1 1 8 5: 68–74.
5. Jariyapongskul, A., Rungjaroen, T., Kasetsuwan, N., Patumraj, S., Seki, J., Niimi, H. (2007). Long-term effects of oral vitamin C supplementation on the endothelial dysfunction in the iris microvessels of diabetic rats. *Microvascular Research*, 74: 32–38.
6. Tokuda, K., Zorumski, C. F., Izumi, Y. (2007). Effects of ascorbic acid on UV light-mediated photoreceptor damage in isolated rat retina. *Experimental Eye Research*, 84: 537-543.
7. Lehninger, A.H. (1992) – Biochimie, ediţie în limba română, Editura Tehnică, Bucureşti, 102, 368-371.
8. Olinescu, R. (2001) – Metode biochimice de laborator clinic, Editura CERMA, Bucureşti, 136.
9. Mace, K., Offord, E. A., Harris, C.C. (1998) – Development of in vitro models cellular and molecular studies in toxicology and chemoprevention, *Arch. Toxicol. Suppl*. 227-236.
10. Mc Hugh, Atkins, W. M., Racha, K.J., Kunze, K. I. (1996) – Biding of the toxin-glutation conjugate to mouse glutation-S-transferase A3-3 is saturate at only one ligand per dimmer, *Journal of Biological and Biochimistry*, 27470-27474.
11. Olinescu, R. (1994). Radicalii liberi în fiziopatologia umană, Edit. Tehnică, 132-134, 134-136.

EFFECTS OF THE REMEDY BIOR DRUG ON THE TRYPSIN-ANTITRYPSIN SYSTEM IN BROILER CHICKS

V. PUTIN

Agrarian University of the Republic of Moldova

ABSTRACT

This work presents the results of a scientific research carried out in poultry factory conditions with the purpose of delineating the impact of BioR on the trypsin-antitrypsin system in broiler chicks. The study involved 150 broilers divided into 5 grouprs with 30 broilers each. The young broilers from the experimental groups 1-4 received intramuscular BioR injections twice as follows: on the 9th day - 0,3-0,6ml/head and on the 21st day – 0,4-1,0ml/head. The broilers in the control group were injected physiological serum respectively 0,4 and 0,6 ml/head.

The study showed that the BioR product obtained from Spirulina platensis through modern technologies and injected into broiler chicks starting with the 9th day of life is very well tolerated both generally and locally and improves the trypsin-antitrypsin system in broilers.

Key words: remedy BioR , system trypsin-antitrypsin, young broilers, α_{2-} macroglobulin

Today the promoters of growth based on antibiotics and growth hormones are not regarded as acceptable products for the maintenance of health, viability, and improvement of production performance (4;5;9). In this context, the issue of elab oration, testing, and usage on a broad scale of natural, ecologically pure, and harmless for both animals and humans (1;2;4;5;11;12). As the algal drugs, especially the BioR product was worked out at the Academy of Sciences of the Republic of Moldova (7) and was multilaterally tested on swine (4;5;6;10), we deemed it appropriate to extend the study and investigate the results of this remdy in poultry. That is why we decided to elucidate the effects of the algal BioR remedy on the trypsin-antitrypsin system in brroiler chicks.

MATERIALS AND METHODS

The study was conducted at the Avicola Saver poultry farm in Bucovat, Moldova on 150 broiler chicken divided into 5 groups with 30 chicks each. The young broilers from the experimental groups received intramuscular BioR injections twice as follows: on the 9th day - 0,3-0,6ml/head and on the 21st day – 0,4-1,0 ml/head. The broilers in the control group were injected physiological serum respectively 0,4 and 0,6 ml/head. The broiler chicks were permanently monitorized during the study, and blood samples of 5 chicks from every group were taken twice for laboratory investigation – on the 9th day before injection of the product tested and on the 41st day before slaughter. The activity of trypsin, the α_2 value of macroglobulin and α_1 value of antitrypsin were determined according to methods compiled by Kareaghina M.D. and executed according to techniques adjusted for the application of the FP-901 biochemical analyser (Labsystems, Finlanda) descrise de (3).

OUTCOME AND DISCUSSION

The research showed that the BioR remedy does not affect the birds' health and, on the contrary manifests adaptative and antistress properties tangentially confirmed by better indexes of the blood test(6). The biochemical results obtained bfore the injection of the remedy tested and at the end of the study are shown in table 1.

Table 1. Indexes of the trypsin-antitrypsin system in the blood serum of broiler chicks treated with the BioR remedy

Group	Number of chicks	Trypsin nmol/s.l.	Antitrypsin mkmol/l	α_2 macroglobulin g/l
At the beginning of the study	5	91,06±1,72	46,84± 1,69	4,91± 0,44
Control	5	72,04 ± 4,27**	35,20 ±1,47***	3,52±0,57
Experimental 1	5	80,26 ±1,27	43,90 ±4,50	4,94± 0,36
Experimental 2	5	72,14 ±5,16	44,94 ±1,06	3,53 ±0,07
Experimental 3	5	80,54 ±3,40	36,64 ±2,64	4,51 ±0,44
Experimental 4	5	74,64 ± 4,59	43,76 ±2,08	4,04± 0,61

Note: ** $p < 0,01$; *** $p < 0,001$

It can be deduced from the data presented in table 1 that the mean alkaline level of trypsin in the blood serum in chiks brfore the injection of the product tested was 91,06 ± 1,72 nmol/s.l. – an index that tends to decrease with age (P< 0,01). Macari V. (2003) also reported a decrease with age of trypsine in blood serum in swine. The trypsine index in experimental groups treated with BioR do not show any clear deviation tendencies; however, a statistically inconclusive superiority of this parameter is signalled in the experimental groups 1 and 3 with 11,4% and, respectively 11,8% as compared to the control group (p>0,5). It should be noted that a more clear elucidation of trypsinemia could be made through the analysis of the antiproteolytic aspect, especially of α_1-antitrypsin, which decreased by 24,8% with age in chick broilers from the reference group untreated with BioR, as compared to the previous research period (P<0,001). It shoulud be mentioned that the remedy tested at the end of the study favored an obvious growth tendency of serum α_1–antitrypsin by 4,1-27,7% in experimental groups, as compared to the control group. The results obtained are corroborated by the previous studies where similar results were obtained from the testing of BioR on swine (4;5). A significant role in the trypsin-antitrypsin system and, of course, in the antiproteolytic protection is played by α_2-macroglobulin which makes it possible to obtain extensive information about the physiological and metabolic condition of poultry both treated and untreated with various remedies. At the beginning of the study the alkaline level of α_2-macroglobulin in chicks was 4,91± 0,44 g/l, an index which decreases with age in broiler chicks from the control group by 39,5%. It should be noted that the BioR remedy hampered the decline of this index by the end of the study in the experimental groups 1, 3 and 4 by 14,8 - 40,3% as compared to the control group. Similar results were obtained by other scientists who studied this index in animals treated with bioactive drugs made of algae, peat, and microorganisms (4;5;13;14). Thus it was ascertained that the BioR remedy obtained from algae has the property to cause the synthesis of α_2–macrogblobulin in young poultry, which is beneficial, as this protein contributes to the capture and removal of trypsin from circulation and which acts as a modulator of biological response, etc. (7;14). Consequently, the BioR remedy obtained form Spirulina platensis has properties that contribute to the correction of the trypsin-antitrypsin system in broiler chicks during growth and usage in the stress conditions of a poultry farm.

CONCLUSIONS

1. The BioR product obtained from Spirulina platensis through modern technologoes, injected to broiler chicks on the 9th day of life is very well tolerated both generally and locally.
2. It was proved in poultry farm conditions that the BioR remedy injected in meat poultry has properties of correction deviations of the trypsin-antitrypsin system.
3. The study conforms the necessity to continue the research of the influence of BioR on broiler chicks, in order to optimize the injection dose and schedule.

BIBLIOGRAPHY

1. Decun M.,Stoiţa M.,Legislaţie pentru managementul calităţii produselor de origine animală/Timişoara:Ed:Mitron,1999.-272 p.
2. Grosu T., Macari V., Gudumac V., Rudic V. Procède de stimulation de la productive des porcins// 45 Salon Mondial de L'invention, de la recherche et l'innovation industrielle. Bruxelles EURECA '96.- 1996.- P.267.
3. Gudumac V., Baciu E., Martin V., Macari V., Melnic D. ş.a.Investigaţii enzimologice. Elaborare metodică.- Chişinău, 2000.- 56 p.
4. Macari V. Aspecte fiziologico-metabolice ale acţiunii preparatului BioR de origine algală asupra organismului animal / Autoreferatul tezei de dr. hab. în biologie. – Chişinău, 2003 - 48 p.
5. Macari V., Manifestări ale sistemei Tripsină-antitripsină la produşii scroafelor Tratate cu remediul BioR. Luc. şt. Medicină Veterinară, vol.XXXVI. Timişoara, 2003.- p.217-219.
6. Macari V.I., Putin V.N. Vlianie biostimuliatora na ghematologhiceschie pocazateli ţâpleat broilerov // Agrarnâi vestnik priciornomoria: Cbornic Haukovâh praţ.- T.42, ciasti1.-Odessa, 2008.- S.34-38.
7. Matei L. α_2 macroglobulina serică: structura, forme, mecanisme de reacţie interacţiuni fiziologice // St.cerc. biochim. 1998.-T.41, 1-2. – P. 119 -138.
8. Rudic V., Gudumac V., Popovici M.,1995, Fotobiotehnologie-realizări noi în biomedicină. Chişinău , Cuant, 207 p.
9. Rudic V., Cojocari A. , Cepoi L., Chiriac T., Rudi I., Gudumac V. Macari V.,Codreanu S. ş.a. Ficobiotehnologie- cercetări fundamentale şi realizări practice/ Chişinău: s.n. 2007 (Tipografia „Elena V.I. SRL).- 365 p.
10. Rudic Valeriu BioR: Studii biomedicale şi clinice / valeriu Rudic.- Ch.: S.n., 2007 (Tipogr. „Elena V.I. SRL).-376 p.
11. Sandul P.A.Ăffectivnosti primenenia broileram conţentrata vitaminov E i F uz rapsovogo masla// Ucennîe zapiski. Haucino-practiceskii jurnal.-Vitebsk.- T.43.-Vâpusk 1.- 2007.-C. 210 - 212.
12. Sasson A., 1993, Biotehnologii şi dezvoltare.Bucureşti, Ed. Tegnică,308 p.
13. Кобозев В.И. К запросу изучения острой и хронической токсичности оксидата торфа // Уч. Записки Витебской Гос. Академии Вет. Медицины, Витебск,1994.-Том.31.-С.164 -169.
14. Прощенко В.М. Коррекция иммунной недостаточности у поросят //Ветеринарные и зооинжинерные проблемы в животноводстве и научно-методическое обеспечение учебного процесса: Материалы II междун.нучно-практической конференции, г.Витебск, 25 - 26 сентября.- Минск, 1997.-С.133 -135.

CLINICAL, ANATOMOPATHOLOGICAL AND HISTOLOGICAL ASPECTS IN GUINEA PIGS SENSITIZED WITH *M. bovis* AN5, USED TO BOVINE PPD STANDARDIZATION

Maria-Mioara RĂDUȚĂ[1], P. ŞTIUBE[1], Viorica CHIURCIU[1], Şt. POPESCU[2]

[1]S.C.Romvac Company S.A.
[2]Veterinary Consultant
mariamraduta@yahoo.com

SUMMARY

Reducing the incidence of bovine tuberculosis and its eradication is largely conditioned by the use of internationally standardized tuberculins PPD. The delayed hypersensitivity test (DHT) is the standard method for detection of bovine tuberculosis and for standardization of bovin PPD. In the campaigns for tuberculosis eradication is necessary the utilization of bovine PPD tuberculins, with a potency that is identical or close to that of the International Standard PPD-BOV (IS) - NIBSC, Weybridge from England, regardless of their origin. The potency of tuberculins must be estimated by biological methods on comparison with IS, and potency is expressed in International Units (IU). In this study, clinical signs observed during the experiment, and the pathological lesions found after killing guinea pigs, come to confirm known previous data about pathogenesis and tuberculosis diagnosis. Two groups (n = 6) of guinea-pigs were sensitised with 0.001 mg wet weight of live bacilli of M. Bovis AN5, 46 days prior to potency test of bovin PPD. At the time the intradermal skin test, the guinea-pigs infected had in good health. Two series of working standard bovine PPD (WS1, WS2) have been bioassayed against the IS. Each guinea pig from the experimental group and still 2 guinea pigs unsensitized from the control group was intradermally injected with 0.1 ml from each dilution of WS1 or WS2 and from the IS. The reading and interpretation of the allergic reactions was done after 24 hours. All reactions with diameter over 5 mm was considered positive. The WS potency was expressed as percentage from the IS potency. After 7 days 10/12 guinea pigs M. bovis sensitized were sacrificed and examinated. The necropsy examination confirmed the hypertrophy of the internal organs and popliteal lymph nod, and the presence of tuberculous granulomas in the spleen, liver, kidney. Also, the guinea-pigs do not suffered from open tuberculosis and thus are not excreted tubercle bacilli. The tissues were sectioned (4 and 5 µm) and stained by the different techniques (Ziehl–Neelsen, HE). Macro- and microscopic examination detected that there is a large variability of nodular granulomas (as size, numbers , structural stages) in the tissues.

Key words: bovin PPD standarization, international standard PPD-BOV, DHT, guinea pig, tuberculous granulomas

Bovine tuberculosis is a chronic bacterial disease of animals and humans caused by *Mycobacterium bovis*. Transmission to humans constitutes a public health problem. *Mycobacterium bovis* is a zoonotic organism and, during diagnostic examination, it should be treated as a risk/hazard group III organism with appropriate precautions to prevent human infection occurring.

Bovine tuberculosis is characterised by formation of nodular granulomas known as tubercles. At necropsy, tubercles are most frequently seen in bronchial, mediastinal, retropharyngeal and portal lymph nodes and may be the only tissue affected. In addition, the lung, liver, spleen and the

surfaces of body cavities are commonly affected. Early nodular pulmonary lesions can often be detected by palpation. Macroscopically, a tuberculous granuloma usually has a yellowish appearance and is caseous, caseo-calcareous, or calcified in consistency. Occasionally, its appearance may be purulent. The appearance may be more purulent in cervids and camelids. Some nontuberculous granulomas may be indistinguishable macroscopically from tuberculous granulomas. The presumptive diagnosis of mycobacteriosis can be made if the tissue has characteristic histological lesions (caseous necrosis, mineralisation, epithelioid cells, multinucleated giant cells and macrophages). As lesions are often paucibacillary, the presence of acid-fast organisms in histological sections may not be detected, although *M. bovis* can be isolated in culture. The 196 countries and territories that reported data in 2008 account for 99.6% of the world's estimated number of TB cases and 99.7% of the world's population. Globally, there were an estimated 9.27 million incident cases of TB in 2007. This is an increase from 9.24 million cases in 2006, 8.3 million cases in 2000 and 6.6 million cases in 1990. There were an estimated 13.7 million prevalent cases of TB in 2007 (206 per 100 000 population), a decrease from 13.9 million cases (210 per 100 000 population) in 2006.(6) The standard method for detection of bovine tuberculosis is the tuberculin test, which involves the intradermal injection of bovine tuberculin purified protein derivative (PPD) and the subsequent detection of swelling (delayed hypersensitivity) at the site of injection 72 hours later. This may be performed using bovine tuberculin alone or as a comparative test using avian and bovine tuberculins. The tuberculin test is usually performed on the mid-neck, but the test can also be performed in the caudal fold of the tail. The skin of the neck is more sensitive to tuberculin than the skin of the caudal fold. To compensate for this difference, higher doses of tuberculin may be used in the caudal fold. Delayed hypersensitivity may not develop for a period of 3–6 weeks following infection. Thus, if a herd/animal is suspected to have been in contact very recently with infected animals, delaying testing should be considered in order to reduce the probability of false-negatives. As the sensitivity of the test is less than 100%, it is unlikely that eradication of tuberculosis from a herd will be achieved with only a single tuberculin test. It should be recognised that when used in chronically infected animals with severe pathology, the tuberculin test may be unresponsive. The intradermal tuberculin test enables presumptive diagnosis and elimination of infected animals before signs appear (..). Due to their higher specificity and easier standardisation, purified protein derivative (PPD) products have replaced heat-concentrated synthetic medium tuberculins. Bovine PPDs prepared with the *M. bovis* production strain AN5 are more specific for detecting bovine tuberculosis than human PPDs prepared with *M. tuberculosis.* The production culture substrate must be shown to be capable of producing a product that conforms to recognised international standards (WHO, European Pharmacopoeia or other recognised control authorities). It must be free from ingredients known that cause toxic or allergic reactions. *M. bovis* AN5 is cultured in a synthetic medium, the protein in the filtrate is precipitated chemically (ammonium sulphate or trichloroacetic acid [TCA] are used), then washed and resuspended. PPD tuberculin is recommended as it can be standardised more precisely. Further dilutions are made with a buffer according to the protein content and the required final concentration, usually 1.0 mg/ml The protein level of the PPD concentrate is determined by the Kjeldahl or other suitable method. (1, 3). In several countries, bovine tuberculin is considered to be of acceptable potency if its estimated potency guarantees per bovine dose at least 2000 IU (+/-25%) in cattle. In cattle with diminished allergic sensitivity, a higher dose of bovine tuberculin is needed, and in national eradication campaigns are recommended doses of up to 5000 IU. The volume of each injection dose must not exceed 0.2 ml. The reactions are interpreted on the basis of appropriate schemes (8). The final product must be bioassayed in guinea-pigs, potency and specificity assays are carried out in comparison with a reference tuberculin (PPD). The potency is expressed in International Units (IU) from international standard. The produced PPD tuberculins are bioassayed in homologously sensitised guinea-pigs against the standard for bovine PPD tuberculin by a six-point assay comprising three dilutions at five-fold

intervals of each tuberculin. The estimated potency for bovine tuberculins must be not less than 66% and not more than 150% of the potency stated on the label (8, 7).

MATERIALS AND METHODS

Sensitization of guinea pigs with *M. bovis* AN5:

Experimental group: Two groups of guinea pigs (n = 10) were sensitised with a low dose (0.001mg wet weight/animal) live bacilli of AN5 strain *M. bovis, 46 days* prior to the assay. The bacilli were suspended in physiological saline and 1 ml was deep intramuscular injected on the medial side of the thigh.
Control group (n = 4) remained unsensitized.

Intradermal allergic test (DHT)

Antigens

1. National Working Standard Bovine PPD (WS1) - 0.97 mg protein/ml
2. National Working Standard Bovine PPD (WS2) - 1.02 mg protein/ml
3. International Standard Bovine PPD (IS) - 32,500 IU/ml

The dilutions of the WS1, WS2 and IS were made in isotonic buffer solution that contained 0.0005% (w/v) polysorbate 80 (Tween 80). Volumes of 0.001 (1:100), 0.0002 (1:500) and 0.00004 (1:2500) mg tuberculoprotein corresponding to the international standard for PPD of 32, 6.4 and 1.28 IU, were chosen because these allergic skin reactions easy to read. Two test tuberculins (WS1, WS2) were compared with the IS in guinea-pigs, applying six intradermal injections (each of 0.1 ml volume) per animal. The reading of the assays was done 24 hours after the injection of the tuberculins. The different diameters of erythema were measured with callipers in millimetres and recorded on assay sheets. Alergic responses were positive considered if the diameters of erythema was more than 5 mm. The results were statistically evaluated using standard statistical methods for parallel-line assays according to Finney (2). The relative potencies of the two test tuberculins were calculated with their 95% confidence limits, the slopes of the log dose–response curves for each preparation (increase in mean reaction per unit increase in log dose) and the F ratios for deviations from parallelism.

Necropsy examination.

After 7 days from DHT, 10 sensitized guinea pigs were sacrificed. Each guinea pigs were examined anatomopathological. The tuberculosis granulomatous lesions observed in the internal organs (liver, spleen, kidney) were photographed. Then, it were collected the samples (lung, liver, spleen, kidney, popliteal lyph nod, skin, muscle) for histological examination.

Histopathological examination.

The tissues (lung, liver, spleen, kidney, popliteal lyph nod, skin, muscle) selected for microscopy are removed from each animal and fixed by immersion in formaldehyde to prevent deterioration from microbial attack and autolysis. Following this step, the fixed tissue was washed, dehydrated in a series of increasingly concentrated solutions of ethanol, and embedded in wax. The wax impregnated block of tissue was chucked into the holder of a microtome, cuts very thin (4 and 5 µ) off the block. The section was collected on a glass slide, and the wax removed by dissolving it in xylene. Then, water was replaced by rehydration and the tissue was stained by more techniques**,** like: Ziehl Neelsen, Hematoxylin and Eosin, Krutzay trichromic**.** After staining has been completed, the now colored section was again dehydrated (in the alcohol series) and finally covered with a

glass coverslip cemented in place with Canada Balsam. After dried specimens preparation were ready to examine with the light microscope (magnification .....).

RESULTS AND DISCUSSIONS

DHT in guinea pigs

Intramuscular injection of *M. bovis* live bacilli cause the hypertrophy and necrosis of the popliteal lymph nod (Fig 1 A). At the time of the assay, the guinea-pigs infected with the low dose of *M. bovis* had in good health. DHT in sensitized guinea pigs was caracterized by appearance of erythema, oedema, and necrosis in IS (1:100) inoculation point (Fig1 B, C– detail). Positive reactions, but not accompanied by necrosis (Fig. 2 A, B, C) were detected at WS1 and WS2. At unsensitized guinea pigs were reported the negative reactions, regardless of tuberculin injected (Fig 2 C) (4, 5).

A B C

Figure 1 Hypertrophy and necrosis of popliteal lymph nod after *M. bovis* AN5 sensitization (A). Positive reactions and necrosis at IS (1:100) inoculation point (B, C)

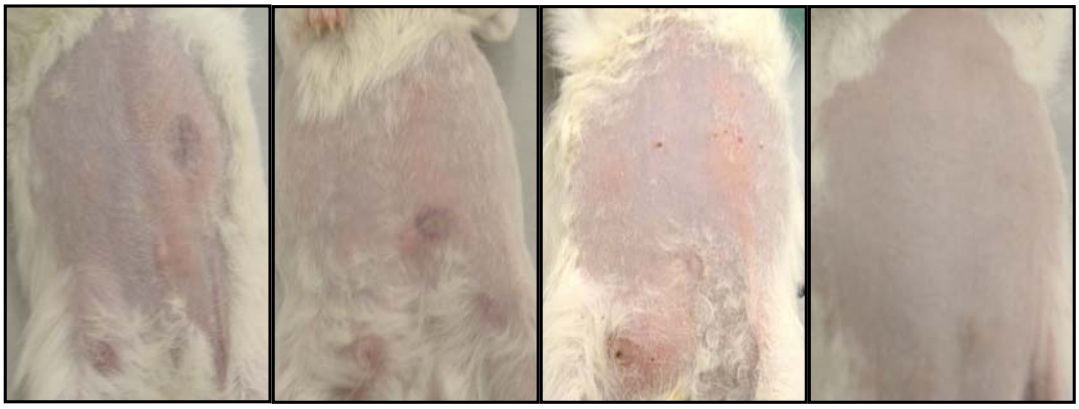

WS2 IS WS2 IS WS1 IS WS1 IS

A B C D

Figure 2. DHT in guinea pigs - positive reactions (A , B, C) and negative reactions (D)

Potency of WS1 and WS2, determined in homologous sensitized guinea pigs, was 93.54% (30,400 IU/ml), respectively 94.85% (30,800 IU/ml) from IS value (32,500 IU/ml)

The results of necropsy examination

At the examination of guinea pigs was found a large individual variability of tuberculous granulomas. All guinea pigs (100%) presented hipetrophy (spleen, liver, kidney and popliteal lymph nod). Miliary tuberculosis (necrosis and granulomas lesions) was observed in the liver (10/10,

100%,) and in the spleen (3/10, 30%) at examined animals. A large number (size of 3-5 mm) the confluent tuberculosis granulomas was reported in tissues and on surface of spleen (7/10, 70%). At 30% (3/10) of guinea pigs examinated were found 1-5 haemorrhagic areas in the spleen. At the injected site of *M. bovis* AN5 was found a could intramusculary abcess of 10% (1/10) investigated guinea pigs. Macroscopically, a tuberculous granuloma usually has a yellowish appearance and is caseous, caseo-calcareous,or calcified in consistency

a b c

Figure 3 Tuberculosis in guinea pigs sensitized with *M. bovis* AN5 - liver

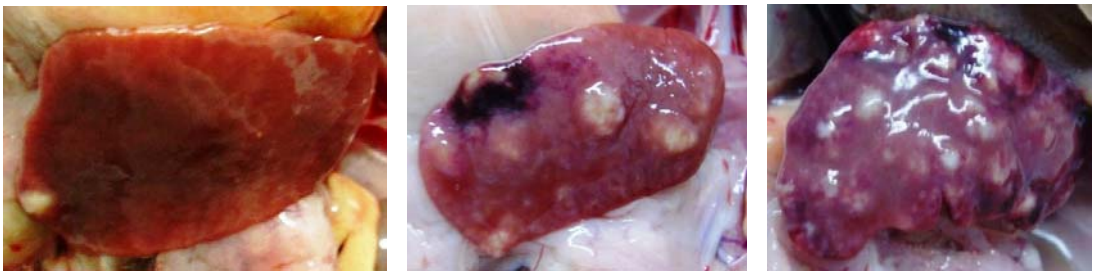

a b c

Figure 4 Tuberculosis in guinea pigs sensitized with *M. bovis* AN5 - spleen

a b c

Figure 5 Tuberculosis in guinea pigs sensitized with *M. bovis* AN5 - lymph nod (a, b, c) and intramuscular cold abscess (c)

<u>The results of histological examination</u>

Number and size of macro- and microscopic lesions have varied greatly in different individuals. The caseous centre was dry, firm, and covered with a fibrous connective capsule of varying thickness. Serial sectioning of organs and tissues was required to detect the small lesions contained within the tissue. Characteristic histological lesions (caseous necrosis, mineralisation, epithelioid cells, multinucleated giant cells and macrophages) were found in spleen, liver, lung and kidney. The results of post-mortem examinations carried out shortly after the standardisation assays showed that the guinea-pigs do not suffered from open tuberculosis, **as shown by other researchers**

CONCLUSIONS

A low dose (0.001 mg wet weight/animal) live bacilli of AN5 strain of *M. bovis* had a good health 53 days after sensitization**,** cited and by the OIE and NIBSC. The guinea pigs appears popliteal lymph nod hypertrophy and the cold abscess to the inoculation site of antigen. Intradermal skin test with bovine PPD tuberculins in homologous sensitized guinea pigs, give allergical reactions as erythema and necrosis (the Koch reaction) which varies with their concentration. The results of post-mortem examinations, carried out shortly after the standardisation assays, show that the guinea-pigs do not suffer from open tuberculosis and thus are not excreting tubercle bacilli. Were observed hypertrophy of spleen, liver, kidney and popliteal lymph nod. Also, the necrotic patognomonic plates and tuberculous granulomas, with variable sizes in liver and spleen were present. Histological examination confirmed appearance of tuberculous granulomas in the lungs, popliteal lymph nod, liver, variable as dimensions and stages and muscular abscess. According to the European Pharmacopoeia and OIE Manual the estimated potency for bovine tuberculins must be not less than 66% and not more than 150% of the potency stated on the label. The working standard (under a lyophilized form) will be use for determining the potency of bovine PPD tuberculins for obtaining a PPD tuberculins with a biological value as uniform as possible. Only these PPD enable a correct diagnosis in infection with M. bovis and, the complete eradication of bovine tuberculosis in our country in future. Low cost of DHT in comparison with the other tests for diagnosis, recommended it the most used method in diagnosis surveillance and in programs eradication of bovine tuberculosis. DHT can be used for in bovine tuberculosis diagnostic, complementary with various serological tests (gamma-interferon assay, lymphocyte proliferation assay, enzyme-linked immunosorbent assay). The NIBSC Laboratory from England recommend the WS preparation under a lyophilized form (with 5 years of validity) which must be tested for potency against IS (32,500 IU/ml), annually. According the WHO and OIE, guinea pigs sensitized with live bacilli of *M. bovis* AN5 are used in this test.

BIBLIOGRAPHY

1. Angus R.D.. Production of reference PPD tuberculins for veterinary use in the United States. *J. Biol.Stand*., **6**, 221, 1978.
2. Finney D.J. *Statistical Methods in Biological Assays*, Second Edition. Charles Griffin, London, UK, 1964.
3. Haagsma J. & Angus R.D.. Tuberculin production. *In: Mycobacterium bovis* Infections in Humans and Animals, Steele J.H. & Thoen C.O., eds. Iowa State University Press, Ames, Iowa, USA. 1994 (32)
4. Raduta Maria-Mioara, I. Togoe, St. Popescu, Maria Ionescu. Testing a Working National Standard Bovine PPD by sensitization guinea pig with live *Mycobacterium bovis* AN5 bacilli, *Scientific works Veterinary Medicine, C Series XL, Bucharest*, pp.161-168, 2006.
5. Raduta Maria-Mioara. Researches Concerning Antigenicity And Specificity Of Certain Tuberculinic Extracts. University Of Agronomical Sciences And Veterinary Medicine Bucharest, 2007.
6. World Health Organization. Global tuberculosis control- WHO report 2009 http://www.who.int/tb/publications/global_report/2009/key_points/en/index.html
7. ***European Pharmacopoeia 4-th Edition, Council of Europe, 67075 Strasburg, Cedex, France, Printed in Germany, Drukerei C.H. Beck, Nördligen, pp. 2087-2091, 2001
8. ***OIE Manual of Diagnostic Tests and Vaccines for Terrestrial Animals, 4th edition, Copyright Office International des Epizooties, Paris, France, pp. 451-464, 2004
9. ***The 1 st International Standard for tuberculin, PURIFIED PROTEIN DERIVATIVE (PPD), BOVINE, pp. 1-6, NIBSC, United Kingdom, 09 February 2004.

THE CONSEQUENCES OF HEXAVALENT CHROMIUM COMPOUND SIX MONTHS EXPOSURE ON SOME MORPHOLOGICAL BIOMARKERS IN MALE RATS

Jelena RANKOV, Alexandra TRIF

Faculty of Veterinary Medicine
Calea Aradului, 119 Timisoara, Romania
jelenarankov@yahoo.com

ABSTRACT

Chromium is known as human and animal carcinogens. Exposure to hexavalent chromate has been reported to occur during the production of chromate pigments, chrome plating, leather tanning, stainless steel welding. The aim of this study was the evaluation of morphological biomarkers of reproductive toxicity: body weight, weight of sexual organs (testes, epididymis) and sexual accessory glands (seminal vesicle, prostate and bulbo-urethral gland) after six months exposure to hexavalent chromium compound. The study carried out on 28 male white Wistar rats divided in three experimental E_1: 25 ppm Cr VI (LOAEL); E_2: 50 ppm Cr VI; E_3: 75 ppm Cr VI; and one control group which received tap water (without chromium content) pointed out: significant decrease of body weight at the end of exposure period comparative to control group and in inverse, significant, correlation to exposure level; significant decrease of testes, epididymis, seminal vesicle and bulbo-urethral glands weight comparative to control group and in inverse, significant correlation to exposure level; significant decrease of prostate weight comparative to control group and in inverse correlation to exposure level, significantly only when exposure level increased from 25 to 75 ppm Cr and from 50 to 75 ppm Cr.

Keywords: male, rats, chromium VI, level

INTRODUCTION

Chromium is a metallic element with several oxidation states. The most common and most stable are trivalent and hexavalent forms. Trivalent chromium compounds occur in the nature and essential for human and animal organism but in small amounts. Hexavalent chromium compounds rarely occur in the nature, and are produced by anthropogenic sources. Hexavalent chromium compounds are more toxic and carcinogenic than trivalent because the former readily enter the cells. (1). Chromium is known as human and animal carcinogens (12). Occupational exposure to hexavalent chromate has been reported to occur during the production of chromate pigments, chrome plating, leather tanning, stainless steel welding. The workers engaged in this processes are exposed to chromium though inhalation, ingestion and dermal contact (1). The sources are the same for animals.The aim of the study was the evaluation of hexavalent chromium compound exposure impact on integrity and performances biomarkers of male reproductive system. The objective was the estimation of hexavalent chromium compounds exposure consequences on some morphological biomarkers (body and sexual organs weight) in male rats.

MATERIALS AND METHODS

The study was carried out on 28 male white Wistar rats purchased from Faculty of Medicine and Pharmacy Biobase Cluj-Napoca. All the animals were equally divided in three experimental and

one control group, consisted of seven rats per group. Experimental groups received potassium dichromate in drinking water for six months as followed E_1: 25 ppm Cr VI (LOAEL) (8); E_2: 50 ppm Cr VI (2 x LOAEL); E_3: 75 ppm Cr VI (3 x LOAEL); and control group received tap water (without chromium content). After six months of exposure, rats were sacrificed following protocols and ethical procedures and morphological biomarkers were determined. The genital organs and sexual accessory glands were dissected out trimmed off the attached tissues and weighted using analytical balance Shimadzu AY 220.All the animals were provided free access to food and water. The study was performed in compliance with national and international law regarding animal welfare and ethics in animal experiments: 143/400/2002; 471/2002; 205/2004; 206/2004; 9/2008; 86/609/CEE (6,14,15,16,17,20).The results were statistically analyzed by Anova method and Student test.

RESULTS AND DISCUSSION

Results are presented in table 1-2 and figure 1-2.

Table 1

Mean body weight (g) after six months of hexavalent chromium compound intake

Groups	Initial body weight (g)		
	x±Sx	SD	CI 95%
C	417.86±1.01	2.67	2.00
E_1	402.14±1.01	2.67	2.00
E_2	378.57±0.92	2.44	2.00
E_3	338.57±0.92	2.44	2.00

Six months exposure to hexavalent chromium compounds determined significant (p⍰0.01) decrease of body weight in E groups comparative to C (E_1/C: -3.77%; E_2/C: -9.41%; E_3/C: -18.98%). Correlation with exposure level was significant (p⍰0.01) and indirect (E_2/E_1: -5.87%; E_3/E_2: -10.57%; E_3/E_1: -15.81%).

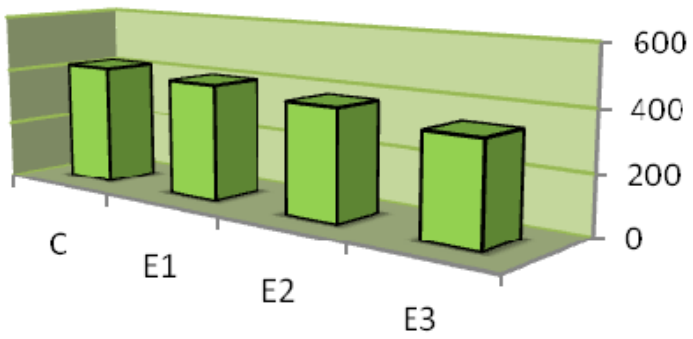

Fig. 1 Body weight dynamics in male rat after six months of exposure

Table 2

Male rat genital organs and sexual accessory glands absolute weight values

Specification		x ± Sx	SD	Confidence interval 95 %
Testes	C	3.47±0.01	0.02	0.01
	E_1	3.32±0.01*	0.01	0.01
	E_2	3.17±0.01*	0.01	0.01
	E_3	2.92±0.01*	0.01	0.01
Epididymis	C	1.75±0.07	0.18	0.10
	E_1	1.33±0.05*	0.13	0.10
	E_2	1.19±0.03*	0.09	0.10
	E_3	1.09±0.02*	0.06	0.10
Seminal vesicle (with coagulating gl.)	C	2.12±0.03	0.07	0.05
	E_1	1.91±0.03*	0.07	0.05
	E_2	1.81±0.02*	0.05	0.05
	E_3	1.70±0.02*	0.04	0.05
Prostate	C	0.88±0.03	0.08	0.05
	E_1	0.74±0.03*	0.09	0.05
	E_2	0.68±0.02*	0.04	0.05
	E_3	0.62±0.02*	0.06	0.05
Bulbo-urethral gland	C	0.67±0.01	0.01	0.01
	E_1	0.58±0.01*	0.01	0.01
	E_2	0.50±0.01*	0.01	0.01
	E_3	0.45±0.01*	0.01	0.01

C/M: ^{ns} – not significant

*: $p<0.01$

In all exposed individuals testicular weight decreased significantly (p0.01) after six months of potassium dichromate intake, comparative to unexposed ones (E_1/C: -4.33%; E_2/C: -8.65%; E_3/C: -15.86%) and in inverse, significant (p0.01) correlation to exposure level (E_2/E_1: -4.52%; E_3/E_2: -7.89%; E_3/E_1: -12.05%). At the end of exposure period epididymis weight significantly (p0.01) dropped off in comparison to C group (E_1/C: -24.00%; E_2/C: -32.00%; E_3/C: -37.71%). Epididymis weight dynamics was indirectly, significantly correlated to hexavalent chromium intake level (E_2/E_1: -10.52%, p0.05; E_3/E_2: -8.41%, p0.05; E_3/E_1: -18.04%, p0.01). Seminal vesicles weight also decreased significantly (p0.01) in E groups comparative to C group (E_1/C: -9.91%; E_2/C: -14.62%; E_3/C: -19.82%), being in indirect, significant (p0.01) correlation to exposure level (E_2/E_1: -5.24%; E_3/E_2: -6.08%; E_3/E_1: -11.00%). Prostate weight had the same dynamics, respectively in E groups weight values had fallen away, significantly (p0.01), in comparison to C group (E_1/C: -15.91%; E_2/C: -22.72%; E_3/C: -29.55%) and in inverse correlation to exposure level, significant only when chromium level increased from 25 to 75 ppm and from 50 to 75 ppm (E_2/E_1: -8.11%, p0.05; E_3/E_2: -8.83%, p0.05; E_3/E_1: -16.22%, p0.01). The bulbo-urethral glands weight's values decreased significantly (p0.01) in E groups comparative to C group (E_1/C: -13.44%; E_2/C: -25.38%; E_3/C: -32.84%), and was in indirect correlation to intake chromium level (E_2/E_1: -13.80%; E_3/E_2: -10.00%; E_3/E_1: -22.42%).

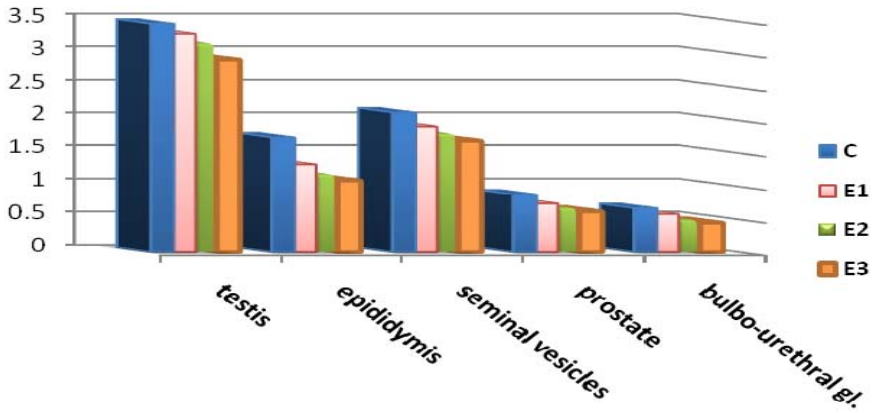

Fig. 2 Genital organs and sexual accessory glands weight dynamics in male rats

This study demonstrated that exposure to hexavalent chromium had reduced the body weight and weight of genital organs in adult male Wistar rats when compared with the control animals. Reduction of body weight after chromium VI exposure was reported by others (Ernst, 1990; Mizanul *et al.*, 2002; Kim *et al*., 2004; Yousef *et al*., 2006; Chandra *et al*., 2007). Also decrease of testes (Ernst, 1990; Chowdhury and Mitra, 1995; Aruldhas *et al*., 2005; Yousef *et al*., 2006; Chandra *et al*., 2007), epididymis (Yousef *et al*., 2006; Chandra *et al*., 2007) and seminal vesicles (Elbetieha and Al-Hamood, 1997; Al-Hamood *et al*., 1998; Chandra *et al*., 2007) have been demonstrated.
In contradiction Elbetieha and Al-Hamood, 1997 emphasized that mice exposure to Cr III and Cr VI determines testicular weight increase and Pereira *et al*., 2005 concluded that Cr VI has no influence on body, testicular and epididymis weight.The possible explication for decreased body and sexual organs weight could be due to gain in lean body mass and decrease in body fat which were observed in humans exposed to chromium (Gilbert *et al*., 1998). Testosterone is responsible for body growth, structural integrity, functional activities and growth of genital organs and sexual accessory glands (Nieschlag *et al*. 2004). Therefore, for reduced values of body and sexual organs weight can be responsible low seric testosterone levels, as chromium exposure affects dynamics of this hormone. Decrease of testosterone seric level after chromium treatment was pointed out by research team (Trif *et al*. 2009) and by others (Ernst and Bonde, 1992, Yousef *et al*. 2006 and Chandra *et al*. 2007).

CONCLUSIONS

The exposure of adult male rats for six months to potassium dichromate (Cr VI) in drinking water (25, 50 and 75 ppm Cr) determined:

- Significant decrease of body weight at the end of exposure period comparative to control group and in inverse, significant, correlation to exposure level;
- Significant decrease of testes, epididymis, seminal vesicle and bulbo-urethral glands weight comparative to control group and in inverse, significant correlation to exposure level;
- Significant decrease of prostate weight comparative to control group and in inverse correlation to exposure level, significantly only when exposure level increased from 25 to 75 ppm Cr and from 50 to 75 ppm Cr.

Acknowledgements
Acknowledgements to CNCSIS for financial support (project BD, code project 90/2008).

REFERENCES

1. Agency for Toxic Substances and Disease Registry, Toxicological profiel for chromium. Atlanta, september 2000, www.adsdr.cdc.gov
2. *Al-Hamood, M.H., Elbetieha, A., Bataineh, H. – Sexual maturation and fertility of male and female mice exposed prenatally and postnatally to trivalent and hexavalent chromium compounds,* Reproduction, Fertility and Development, **10**(2), 1998, p. 179-183
3. *Aruldhas, M.M., Subramanian, S., Sekar, P., Vengatesh, G., Chandrahasan, G., Govindarajulu, P., Akbarsha, M.A. – Chronic chromium exposure-induced changes in testicular histoarchitecture are associated with oxidative stress: study in a non-human primate (Macaca radiate Geoffroy),* Human Reproduction, **20**(10), 2005, 2801-2813
4. *Chandra, A.K., Chatterjee, A., Ghosh, R., Sarkar, M., Chaube, S.K. – Chromium induced testicular impairment in relation to adrenocortical activities in adult albino rats,* Reproductive Toxicology, ***24***, 2007, 388-396
5. *Chowdhury, A.R., Mitra, C. – Spermatogenic and steroidogenic impairment after chromium treatment in rats,* Indian Journal of Experimental Biology, **33**(7), 1995, 480-484
6. Directiva 86/609 din 24. 11. 1986 privind protecţia animalelor utilizate în scopuri experimentale şi în alte scopuri ştiinţifice, http://ec.europa.eu/food/fs/aw/aw_legislation /scientific/86-609-eec_en.pdf
7. *Elbetieha, A., Al-Hamood, M.H. – Long-term exposure of male and female mice to trivalent and hexavalent chromium compounds: effect on fertility,* Toxicology, 116(1-3), 1997, 39-47
8. Environmental Protection Agency, *Locating and Estimating Air Emissions from Sources of Chromium*, http://www.epa.gov
9. *Ernst, E. – Testicular toxicity following short-term exposure to tri- and hexavalent chromium: An experimental study in the rat,* Toxicology Letters, **51** (3), 1990, 269-275
10. Ernst, E., J.P. Bonde - *Sex hormones and epididymal sperm parameters in rats following sub-chronic treatment with hexavalent chromium*, Human Experimental Toxicology, **11** (4), 1992, 255-258
11. *Gilbert, R.K.*, Kenneth, B., Dennis, P., Samual, C.K., Robert, W. *– A Randomized, double-masked, placebo-controlled study of the effects of chromium picolinate supplementation on body consumption: a replication and extension of a previous study*, Curr. Ther. Res, **59** (6), 1998, 379-388
12. International Agency for Reasearch on Cancer, 1990 www.iarc.fr
13. *Kim, H.Y., Lee, S.B., Jang, B.S. – Subchronic inhalation toxicity of soluble hexavalent chromium trioxide in rats,* Archives of Toxicology, **78** (7), 2004, p. 363-368
14. Legea 205/26. 05.2004 privind protecţia animalelor, M.O. nr. 531/14.06.2004
15. Legea 206/27.05.2004 privind buna conduită în cercetarea ştiinţifică, dezvoltarea tehnologică şi inovare, M.O. nr. 505/4.06.2004
16. Legea 471/9.07.2002. privind aprobarea O.G. nr. 37/2002 pentru protecţia animalelor folosite în scopuri ştiinţifice sau în alte scopuri experimentale, M.O. nr. 535/23.07.2002
17. Legea 9/11.01.2008 pentru modificarea şi completarea Legii nr. 205/2004 privind protecţia animalelor, M.O. nr. 29/15.01.2008
18. *Mizanul, I., Bhowmik, M.K., Sarkar, S. – Effects of chromic chromium toxicity on growth, organ body weight ratio and tissue enzymatic activity in broiler chickens,* Indian Journal of Animal Sciences, **72** (8), 2002, 661-662
19. Nieschlag, E., Behre, H.M., Nieschlag, S. – *Testosterone action, deficiency, substitution*, Cambridge University Press, 2004, Cambridge, UK
20. Ordin 143/400 pentru aprobarea instrucţiunilor privind adăpostirea şi îngrijirea animalelor folosite în scopuri ştiinţifice sau în alte scopuri experimentale, M.O. nr. 697/24.09.2002
21. *Pereira, M.L., Neves, R.P., Oliveira, H., Santos, T.M., Jesus, J.P. – Effect of Cr(V) on reproductive organ morphology and sperm parameters: An experimental study in mice,* Environmental Health: A Global Access Science Source, **4**, 2005, 9-18
22. Trif, Al., Rankov, J., Argherie Brezovan, D., Petrovici, S., Florin M. - *The consequences of exposure to potassium dichromate (Cr VI) on testicular architecture and seric testosterone dynamics in male rats*, Proceedings of IVth Congress of the Romanian Scientist, Timisoara, Romania, 2009, 495-500
23. *Yousef, M. I., El-Demerdash, F.M., Kamil, K. I., Elaswad, F.A.M. – Ameliorating effect of folic acid on chromium (VI)-induced changes in reproductive performance and seminal plasma biochemistry in male rabbits,* Reproductive Toxicology, **21**, 2006, 322-328

SIX MONTHS EXPOSURE TO POTASSIUM DICHROMATE OUTCOMES ON HISTOARCHITECTURE OF GENITAL ORGANS AND SEXUAL ACCESSORY GLANDS IN MALE RATS

Jelena RANKOV, Alexandra TRIF, Diana BREZOVAN

Faculty of Veterinary Medicine
Calea Aradului, 119 Timisoara, Romania
jelenarankov@yahoo.com

ABSTRACT

The aim of the study was the evaluation of potassium dichromate intake consequences on some morphological biomarkers of male reproductive toxicity after six months intake period. The study was carried out 28 male white Wistar rats divided in three experimental and one control group. Experimental groups received potassium dichromate in drinking water for six months as followed E_1: 25 ppm Cr VI (LOAEL); E_2: 50 ppm Cr VI; E_3: 75 ppm Cr VI; and control group received tap water (without chromium content). All the animals were provided free access to food and water. The study was performed in compliance with national and international law regarding animal welfare and ethics in animal experiments: 143/400/2002; 471/2002; 205/2004; 206/2004; 9/2008; 86/609/CEE. The histological examination pointed out congestive and degenerative lesions: in testes - interstitial edema, seminiferous tubules membrane necrosis and exfoliation, seminiferous tubules epithelial atrophy, Leydig cell necrosis, vascular congestion; in epididymis - interstitial edema, epithelial necrosis, basal membrane exfoliation, epithelial smoothing; in prostate, seminal vesicles and bulbo-urethral glands - epithelial necrosis, membrane exfoliation.

Keywords: male, rat, chromium, histoarchitecture

INTRODUCTION

Chromium is a transition element found in many compounds in the Earth's crust. It occurs in the environment mainly in two states, trivalent and hexavalent. Chromium III is an essential trace element, in small amount, whereas chromium VI is considered highly toxic to living beings (12). Chromium is used in the production of chromates, chromium plating, chromate pigment manufacture and the production of cement and stainless steel. Hexavalent chromium is primary toxic form to which organisms are exposed. Carcinogenic potential of chromium is thought to be a result of macromolecular damage induced by reactive oxygen species (ROS) arising in the course of intracellular reduction of hexavalent to trivalent chromium. Trivalent chromium does not cross the cell membrane and therefore accumulates in the cells (6). The aim of the study was the evaluation of potassium dichromate intake consequences on some morphological biomarkers of male reproductive toxicity. The objective was the estimation of genital organs and sexual accessory glands architecture in male rats after six months exposure.

MATERIALS AND METHODS

The study was carried out on 28 male white Wistar rats purchased from Faculty of Medicine and Pharmacy Biobase Cluj Napoca. All the animals were equally divided in three experimental and one

control group, consisted of seven rats per group. Experimental groups received potassium dichromate in drinking water for six months as followed E_1: 25 ppm Cr VI (LOAEL) (5); E_2: 50 ppm Cr VI (2 x LOAEL); E_3: 75 ppm Cr VI (3 x LOAEL); and control group received tap water (without chromium content). After six months of exposure, rats were sacrificed following protocols and ethical procedures and morphological biomarkers were determined. The genital organs and sexual accessory glands were collected, trimmed off the attached tissues and histological examined after staining by Hematoxylin and Eosin (H.E.) method. All the animals were provided free access to food and water. The study was performed in compliance with national and international law regarding animal welfare and ethics in animal experiments: 143/400/2002; 471/2002; 205/2004; 206/2004; 9/2008; 86/609/CEE (4,7,8,9,10,16). The results were statistically analyzed by Anova method and Student test.

RESULTS AND DISCUSSION

Results are presented in figures 1-5.

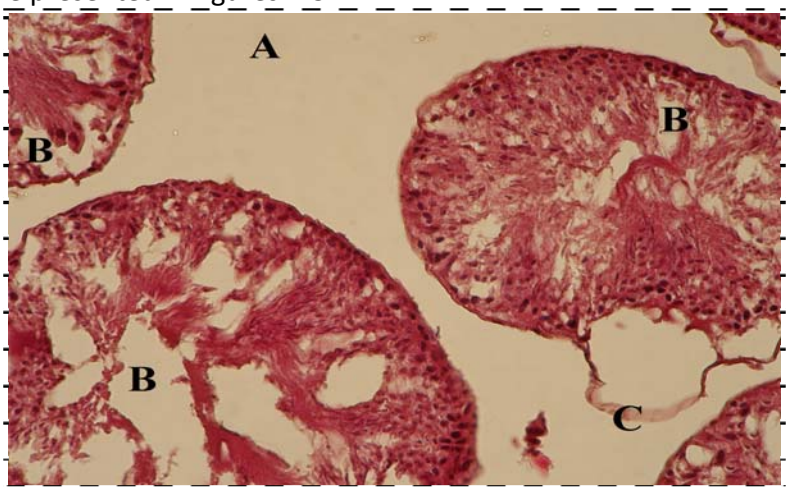

Fig. 1 Testis section (25 ppm Cr VI, H.E., 100 x magnification)
A – interstitial edema, B – seminiferous tubules cell destruction, C – seminiferous tubules membrane necrosis and exfoliation

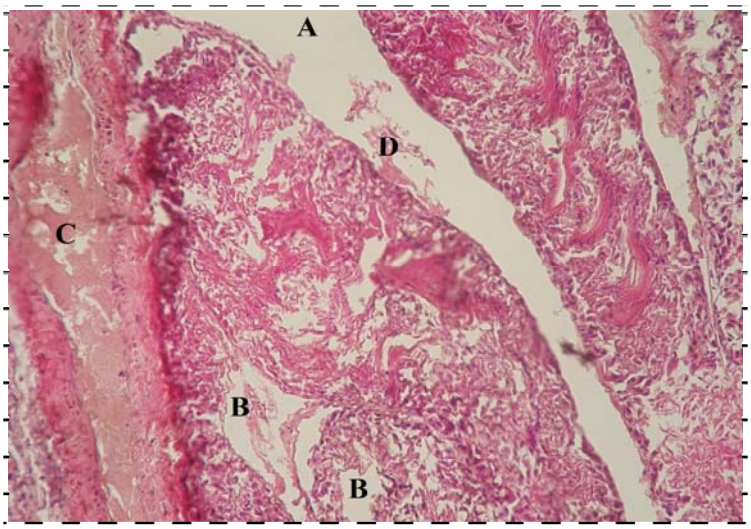

Fig. 2 Testis section (75 ppm Cr VI, H.E., 400 x magnification)
A – interstitial edema, B – destruction of seminiferous tubules cells, C – vascular congestion, D – exfoliation of basal membrane

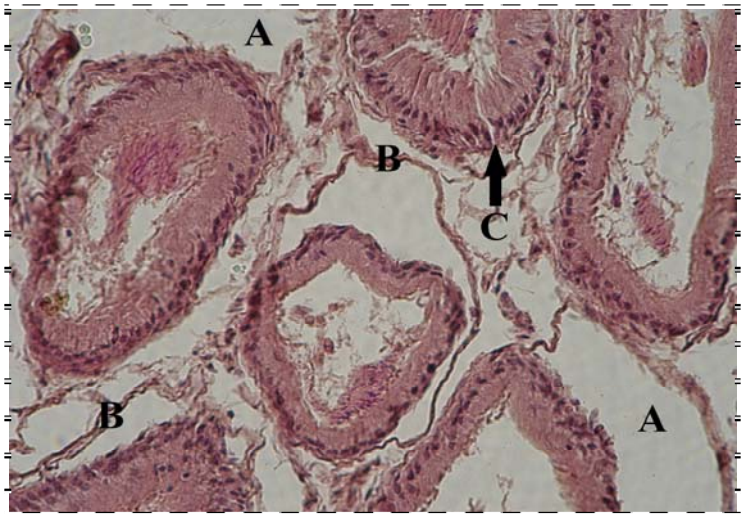

Fig. 3 Epididymis section (75 ppm Cr VI, H.E. 400 x magnification)
A – interstitial edema, B – basal membrane exfoliation,
C –basal membrane and epithelium necrosis

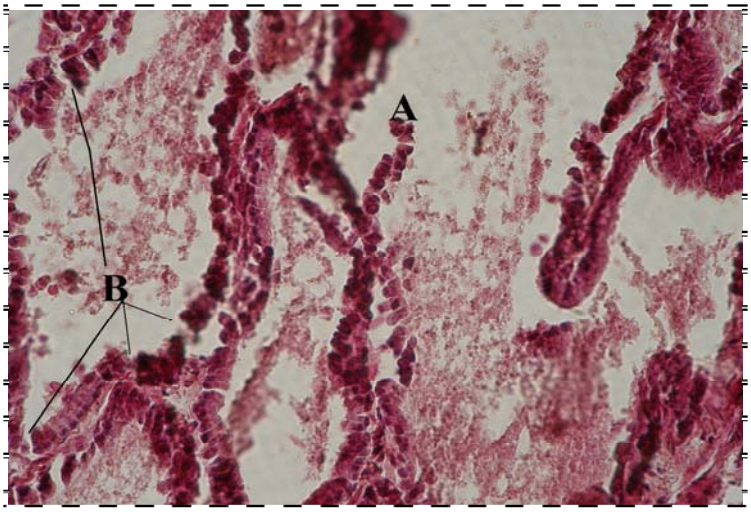

Fig. 4 Prostate section (75 ppm Cr VI, H.E. 400 x magnification)
A – basal membrane total necrosis, B – membrane and epithelial segmentation

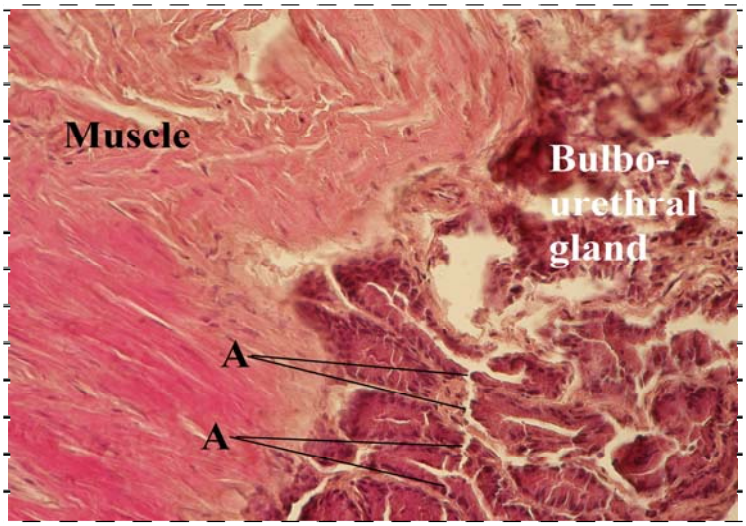

Fig. 5 Bulbo-urethral gland section (75 ppm Cr VI, H.E. 400 x magnification)
A – epithelial necrosis

The histological changes were:

- *in testes:* interstitial edema, seminiferous tubules membrane necrosis and exfoliation, seminiferous tubules epithelial atrophy, Leydig cell necrosis, vascular congestion;
- *in epididymis:* interstitial edema, epithelial necrosis, basal membrane exfoliation, epithelial smoothing;
- *in prostate, seminal vesicles and bulbo-urethral glands*: epithelial necrosis, membrane exfoliation.

Modification in sexual organs histoarchitecture were also presented by Chowdhury and Mitra 1995, Li *et al.* , Murthy *et al.* 1991, Muselin *et al.* 2006, Aruldhas *et al*. 2005, Chandra *et al.* 2007.
Hexavalent chromium compounds are responsible for morphological alterations of testis in adult male rats (Chowdhury and Mitra, 1995). The histopathological examination of genital organs (testes and epididymis) and sexual accessory glands (seminal vesicles, prostate and bulbo-urethral glands) revealed that there are visible congestive and degenerative lesions. Testosterone is a hormone responsible for growth, integrity and functionality of sexual organs (Nieschlag *et al*. 2004). Low seric testosterone level, observed in individuals exposed to hexavalent chromium compounds (Rankov *et al*., 2009, Trif *et al*. 2009), could be a consequence of Leydig cell necrosis and also the reason for the further alteration of morphological structure in sexual organs.
Another possible mechanism for the structural alteration in testis after hexavalent chromium intake may be due to the disruption of blood-testis barrier with consequent accumulation of chromium in testis. The accumulation of chromium in genital organs and sexual accessory glands strengthen this supposition (Rankov *et al*. 2009, Trif *et al*. 2009).

CONCLUSIONS

Exposure to different levels of potassium dichromate during six months induced: congestive and degenerative lesions in male rat's genital organs and sexual accessory glands.

Acknowledgements
Acknowledgements to CNCSIS for financial support (project BD, code project 90/2008).

REFERENCES

1. *Aruldhas, M.M., Subramanian, S., Sekar, P., Vengatesh, G., Chandrahasan, G., Govindarajulu, P., Akbarsha, M.A. – Chronic chromium exposure-induced changes in testicular histoarchitecture are associated with oxidative stress: study in a non-human primate (Macaca radiata Geoffroy),* Human Reproduction, **20** (10), 2005, 2801-2813
2. *Chandra, A.K., Chatterjee, A., Ghosh, R., Sarkar, M., Chaube, S.K. – Chromium induced testicular impairment in relation to adrenocortical activities in adult albino rats,* Reproductive Toxicology*, **24**,* 2007, 388-396
3. *Chowdhury, A.R., Mitra, C. – Spermatogenic and steroidogenic impairment after chromium treatment in rats,* Indian Journal of Experimental Biology, **33** (7), 1995, 480-484
4. Directiva 86/609 din 24. 11. 1986 privind protecția animalelor utilizate în scopuri experimentale și în alte scopuri științifice, http://ec.europa.eu/food/fs/aw/aw_legislation /scientific/86-609-eec_en.pdf
5. Environmental Protection Agency, *Locating and Estimating Air Emissions from Sources of Chromium*, http://www.epa.gov
6. International Agency for Reasearch on Cancer, Chromium, nickel and welding, in: Monographs on the Evaluation of the Carcinogenic Risk of Chemicals in Humans, 1990, www.iarc.fr
7. Legea 205/26. 05.2004 privind protecția animalelor, M.O. nr. 531/14.06.2004
8. Legea 206/27.05.2004 privind buna conduită în cercetarea științifică, dezvoltarea tehnologică și inovare, M.O. nr. 505/4.06.2004

9. Legea 471/9.07.2002. privind aprobarea O.G. nr. 37/2002 pentru protecţia animalelor folosite în scopuri ştiinţifice sau în alte scopuri experimentale, M.O. nr. 535/23.07.2002
10. Legea 9/11.01.2008 pentru modificarea şi completarea Legii nr. 205/2004 privind protecţia animalelor, M.O. nr. 29/15.01.2008
11. Li, H., Chen, Q., Li, S., Xu, Y., Yao, W., Chen, C. – *Studies on male reproductive toxicity caused by hexavalent chromium*, Chinese Journal of Preventive Medicine, 1999, 33 (6), 351-353
12. *Mertz, W. – Risk assessment of essential trace elements: new approaches to setting recommended dietary allowances and safety limits,* Nutr Rev, 1995, 53 (7), 179-185
13. Murthy, R.C., Saxena, D.K., Gupta, S.K., Chandra, S.V.**,** Ultrastructural observations in testicular tissue of chromium-treated rats, Reproductive Toxicology, 1991, 5, 443-447
14. Muselin F., Trif Al., Argherie D. – *The consequences of acute Cr VI exposure on the genital organs and sexual accessory glands histoarchitectonics*, 6th International Conference of PhD Students, University of Miskolc, Hungary, 2006, 12-18 Aug, 135-138
15. Nieschlag, E., Behre, H.M., Nieschlag, S. – *Testosterone action, deficiency, substitution*, Cambridge University Press, 2004, Cambridge, UK
16. Ordin 143/400 pentru aprobarea instrucţiunilor privind adăpostirea şi îngrijirea animalelor folosite în scopuri ştiinţifice sau în alte scopuri experimentale, M.O. nr. 697/24.09.2002
17. Rankov, J., Trif, Al., Brezovan, D., Negrea, P. – The impact of potassium dichromate (Cr VI) on exposure (chromium level) and integrity (genital organs and sexual accessory glands histoarchitecture) biomarkers of reproductive toxicity in male rats*, Proceedings of the Xith International Symposium Young People and Multidisciplinary research,* 147-152, Nov 2009, Timisoara, Romania
18. Rankov, J., Trif, Al., Negrea, P., Steliac (Marr. Munteanu), S. – *Potassium dichromate exposure consequences on chromium level in rats genital organs and sexual accessory glands. Two generation study,* Scientific papers Veterinry Medicine Timisoara, 2010 – article in press
19. Trif, Al., Rankov, J., Argherie Brezovan, D., Petrovici, S, Florin M. - *The consequences of exposure to potassium dichromate (Cr VI) on testicular architecture and seric testosterone dynamics in male rats*, Proceedings of IVth Congress of the Romanian Scientist, Timisoara, Romania, 2009, 495-500

THE PECULIARITIES OF THE PELVIC LIMB MUSCLES IN RED SQUIRREL (SCIURUS VULGARIS)

Mihaela SPATARU, C. SPATARU, V. COTOFAN, M. LAZAR, A. MUNTEANU

ABSTRACT

The studies on the posterior limb muscle development in squirrel-related features reveal how motion of this species. Moving by leaps and ground movement by climbing the arboreal environment led to the biceps femoris muscle represented propellants, and semimembranosus, semitendinosus recognized as providing the propulsion musculature in all species, the squirrel to customize through their insertion on the sacrum crest and base of the tail acting as effective in lifting and moving quadruped and biped position body support. This action is associated the medial muscles by mobile insertion on the caudo-medial face of femur and shank muscles by muscle spindle with long muscle belly and tendons strong and fine.

Key words: squirrel, tendon, bone, muscle, extension.

Muscles, part of the locomotory system are the essential factor in osteo-lgamentar action, with subsequent adjustments which involve changes or lifestyle changes for the species or sometimes even on individual adaptations consecutive accidental changes to the conditions on which it was adapted. The pelvic member, at the all species, through the muscles and conformation to osteo-ligament system, ensure adequate propulsion and stability of habitat conditions in which each species was formed. Studies on development of posterior limb muscle of the squirrel highlights the features related to lifestyle and travel (1, 2, 9, 10).

MATERIAL AND METHODS OF WORK

The studies were performed by dissecting the muscle from cadavers of dead squirrel. After regional and stratigraphic dissection, were identified: source, form, trajectory and joint angles in relation to integration. Depending on these features and osteo-ligament system was established the role of each muscle and the morpho-functional features correlated with all morphological structures. The particular issues were described, photographed and interpreted in terms of cause and effect and were compared with those from specify literature.

RESULTS AND DISCUSSIONS

The pelvic limb muscles in squirrel to customize the stretched muscle belly, that demonstrates propulsion efficiency by climbing, the propulsion of the trunk and the movement by bipedal hopping. Pelvic limbs use as a propulsion engine that are adapted to same changing circumstances led to the development of the propusor strong muscles, abductor or adductor in moving. For the movement to be effective until the distal end respectively in contact with the fulcrum, were evidencing some modify to the shank muscles, too, showed through the long and fusiform muscular belly that are continued with the short and strong tendons, for the proximal acting muscles, or long, well formed and independent tendons for the muscles with distal action (1, 2, 4, 5). The gluteus muscles at squirrel, like at the same in carnivorous, willing to customsize the appearance of widearea evenly without by biceps muscle, it has originate on the sacrat crest and insertion on the big throcanter of femour and biceps muscle (Fig. 1). The biceps femoris muscle

apears like a plate with a broad muscular area> on the median sacrat crest, ischium tuberosity and on the transverse processes of III-V tail vertebrae. The large body of femoural biceps is insered on the caudal face of the femur, on the patella, on the shank fascia and calcaneum (Fig. 1). Muscle acts as a propellant, strong extensor coxo-femoral joint to raise and support leading to the resort biped torso, flection and lateral rotation of the shank (6, 7, 8). The semitendinosus muscle, located caudal of the biceps muscle, has the proximal insertion like the biceps muscle and distal on tibial insert ridge. The contraction acting propulsion trunk in extension stifle the member is supported, in tilting the pelvis and trunk lift. Semimembranosus muscle is thick and prismatic, being inserted on the tuberosity of ischium proximally, and distally inserts on the caudal portion of the femur with a low and a widened tendon on the medial condyle of the tibia. In contraction, produces the lifting trunk, the extension of the coxo-femoral joint, the knee joint flexion and medial rotation of leg (Fig. 2).

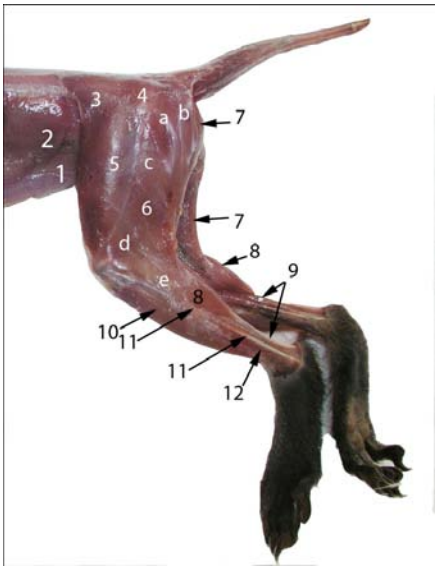

Fig. 1. The lateral aspect of the pelvic muscles at squirrel

1- M. rectus abdominis, 2- m. obliquus externus abdominis, 3- m. gluteus superficialis, 4- m. gluteobiceps, 5- m. quadriceps femoris, 6- m. biceps femoris (a- insertion on ischium, b- insertion on the base of the tail, c- the body of muscle, d- insertion on the patella, e- insertion on tibia), 7- m. semitendinosus, 8- m. gastrocnemius, 9- tendo calcaneus comunis, 10- m. extensor pedis longus, 11- m. extensor pedis lateralis, 12-m. tibialis cranialis



Fig. 2. The medial aspect of the pelvic muscles at squirrel

1- M. rectus abdominis, 2- m. obliquus externus abdominis, 3- lig. inguinalis, 4- m. transverses abdominis, 5- simphisa, 6- m. semimembranosus (6”- tibial insertion, 6”- femoral insertion), 7- m. quadriceps femoris, 8- m. tensor fasciae latae, 9- trigonum femorale, 10- patella, 11- m. gastrocnemius, 12- m. extensor pedis longus, 13- m. flexor digitorum superficialis, 14- mm. flexorum digitorum profundi, 15- m. sacrocaudalis ventralis medialis, 16- m. sacrocaudalis ventralis lateralis.

The cvadriceps muscle to customize the parts that the four muscles that form it are mixed are unequal, the more developing of them being the rectis femoris and the vastus lateralis. The vastus intermediaris is reduced, the vastus medialis has about half the volume of vastus lateralis. These four portions are well individualized, being united by a strong tendon, short and wide on the insert

patella. The rectus femoris has its twice originates: on the neck on ilium and on the evident preacetabular tubercle (1, 4, 5, 8). Also, the thickness of the muscle portions, there is still the original form of fan tendon gaps that give muscle strength. The sartorius muscle is wide and thin, insert, like other species on the inguinal ligament, has paths on the medial quadriceps muscle and then inserted through the fascia of the leg and on the medial face of the tibia (Fig. 1, 2). The gracilis muscle plate appears as a broad muscle, originates on the pubic symphysis and the tuberosity of ischium. Distal, the muscle is inserted on the shank fascia and the caudal portion comes to be inserted on the medial face of tibia, proximal by the semitendinosus muscle insertion.
The adductor major muscle is long and prismatic in shape, being placed caudally of the adductor minor muscle. Its origini s on the ventral face of ischium and distal it is insered on the caudal face of the third distal part of the femour, dorsal of the gastroncnemius muscles insertions (Fig. 3).
The adductor minor muscle is triangular in shape, it is originated on the ventral face of the ischium, cranial of the adductor major insertion level. Distal, it inserts on the caudal face of the middle third of the femur. Proximal of the adductor minor insertion, there are the deep muscles of the pelvis are the most developed is the external obturator muscle cone looks. The base of the cone represent the origin of the muscle, insered around the obturated hole, and the apex of the cone, on the caudal femur, dorsal of the adductor minor muscle insertion (Fig. 3).
The muscles of shank region, divided according to its role in acting muscle in flexion, extension, and proximal or distal muscles acting. They long to customize the muscle belly and tendons obvious fine and strong (1, 3, 4, 10).



Fig. 3. The medial deep muscles of the pelvic leg at squirrel

1-M. iliopsoas, 2- m. adductor minor, 3- m. quadriceps femoris, 4- m. adductor magnus, 5- m. semimembranosus, 6- m. semitendinosus, 7. N. ischiadicus, 8- m. gastrocnemius, caput laterale, 9- m. gastrocnemius, caput mediale, 10- tendo calcaneus communis, 11- m. extensor pedis longus, 12- extensor pedis lateralis, 13- m. fibularis longus, 14- mm. flexores digitorum profundi, 15- tendo distale mm. extensor digitorum profundi et lateralis

Fig.4. The caudal and deep muscles of the pelvic leg at squirrel

1- M. gastrocnemius, caput mediale, 2- tendo m. flexor digitorum superficiale, 3- mm. flexores digitorum profundi, 4- tendo comunis m. flexor digitorum superficiale, 5- tendo mm. flexores digitorum profundi, 6- mm interossei.

The gastrocnemius muscles, with highly developed muscle belly, the tubers originate on supracondilar tubercle of femur. In the thick tendons of origin are present in the sesamoid bones and on the half of distal part are continued with strong tendons that insert on the calcaneus (1, 2, 9). The flexor superficialis muscle presents a very developed belly originate on the lateral supracondilar tubercle of the femur. The belly muscle is placed between the gastrocnemius muscles. The muscle tendon is deployed distal third of the shank region, mid-caudal turns

becoming shallow. The tendon passes over the calcaneum, in the palmar region is divided into three tendons for the fingers II, III, IV (Fig. 3, 4). The tibialis caudalis muscle is represented by a small muscle belly, occurring predominantly tendinous and flattened. Their origin is on the caudal tibia, lateral condyle below. Its tendon passes caudal to the long flexor muscle of the leg and then joins the tendon of halucis flexor longus muscle outside the palmar sheath. The longus pedis flexor muscle originates on the caudal tibia under the condyles join, respectively under the popliteus muscle and on the caudo-medial edge of tibia. At the distal third of leg continues with a thin tendon that passes through its sheath (7, 9). Then attach the flexor tendon and caudal tibial muscle and halucis longus muscle, forming deep flexor muscle tendon (Fig. 4). On the metatarsal region, under the superficial flexor muscle tendon, it is divided into five tendons of the caudal part cylindrical watching fingers and gets to be inserted into plantar tubercle of each phalanx final (4, 5, 7). It acts as a flexor of the phalanges successively. The cranial muscles of the shank are caracterised through the muscle belly long, strong and fusiform appearance. Regional fascia, on the distal extremity of the tibia forms a fibrous ring that supports tibial tendons of the tibial cranial muscle, long fibular and digital common extensor muscles. The cranial tibial muscle originates on the cranial tibia and fibula. It is the most developed of the cranial muscles of the shank, covering the extensor pedis lateralis muscle. The tendon inserts on the proximal extremity of the metatarsus I (Fig. 3). Fibular muscle is spindle and long, originates on the proximal extremity of the fibula, then continue with a strong tendon which passes the dorso-lateral tubercle of the tarsus and insert on the caudo-lateral muscle tubercle of the metatarsus V. The extensor pedis longus muscle has muscle belly with fusiform appearance. Through a long tendon it inserts into foseta extensoria of lateral condyle. Then passes through the tibia extensor incizura where a portion is attached through the ring then fibular fascial. On the back of metatars bones is separated into four tendons strong fingers I-IV insert the extensory eminence of each distal phalanx. The lateralis extensor pedis muscle originates in the lateral condyle on the tibia and fibula cranio-laterally. Through its tendon sheath and the metatarsl region is divided into three tendons for the fingers III, IV and V (Fig. 3).

CONCLUSION

1. Propulsory muscles, through their sacrum and inserts the tail provides propulsion on land environment but inclusion of origin, through their action reversible, supporting the effectiveness of climbing and bipedal position of the trunk.
2. Medial thigh muscles, and in addition adductor action of the member, it works very effectively in propulsion, coxofemurale extension and knee joints when the member is in support.
3. Flexor muscles (superficial and deep) through their action gradual cause unguale phalanx flexion or flexion of the three arch-shaped phalanx.

BIBLIOGRAPHY:

1. Cotofan Vasile and colab- Anatomia animalelor domestice, vol I, Ed. Orizonturi universitare, Timişoara, ISBN 973-9400-30-2
2. Hriţcu Valentina, V. Coţofan, E.V.Sindilar, Mihaela Spataru - Criterii morfologice diferenţiale între oasele membrului pelvin de nutrie, câine, pisică şi iepurele de casă - 2003- Lucr. Şt. Revista Română de Med. Vet. Al IX-lea Congres de Med. Vet. Iaşi, p. 179
3. Grasse P.P. - Traite de Zoologie. Anatomie, Systematique, Biologie. Tome XVI, Fascic. VII, Paris, 1972.
4. Konig H. E., Liebich H.C. – Anatomie der Haussangeliere. Band I, Schattauer, Stuttgart, New York, 1999.

5. Nickel R., Schummer A., Seiferle E. – Lerbuch der Anatomie der Haustiere. Band I, Verlag Paul Parey, Berlin und Hamburg, 1992.
6. V. Rizac, C. Spataru, Mihaela Spataru- Particularitaţi funcţionale ale articulaţiei zono-stilopodiale ale membrului pelvin la bizam, Lucr. St., vol 48, Med. Vet., Iasi, 2005, p.234-238
7. Spataru C., Mihaela Spataru, Gh. Vlad – 2008- The morphological peculiarities of the shank and foot muscles at the brown bear, Buletin USAMV-CN, 65 (1-2) 2008 (-), ISSN1454 238253, Cluj
8. C. Spataru, Mihaela Claudia Spataru, Vlad Ghe – 2008- The muscles of the pelvic basin and the thigh at the brown bear, vol LIV, 2008, ISSN 1222-5304, p. 483-488, Bucureşti,
9. Spataru Mihaela, C. Spataru -2006- Particularităţi anatomo- fiziologice ale membrului pelvin la veverita (Sciurus vulgaris), Lucr. Stiint la Simp. Stiint de Med. Vet., vol 49.
10. Tudor Denisa, Constantinescu, Gheorghe - Nomina Anatomica Veterinaria. Ed. Vergiliu, Bucureşti, 2002.

Acknowledgements

Researches financed from grant
PN/II/DE/1112/2008 by CNCSIS-UEFISCSU

MORPHO-FUNCTIONAL PARTICULARITIES OF THE AXIAL SKELETON AT RED SQUIRREL (SCIURUS VULGARIS)

C. SPATARU, Mihaela SPATARU, V. COTOFAN, V. VULPE, M. LAZAR, A. MUNTEANU
Faculty of Veterinary Medicine, Iassy

ABSTRACT
The researches concerning the axial skeleton at squirrel show the morphological features of the axial skeleton and the adaptation to the habitat conditions by moving in leaps and terrestrial environment or climbing the arboreal environment. The studies have shown backbone oriented trapezoid appearance of cervical region dorso-ventral flattening given back and detaching springs in the lateral transverse processes. Elongation lumbar region compared to the other species of rodents and progressive reduction of transverse processes side shows extensive movements in the region. Ribs, proximal and distal ends by flattening the end cranio-caudal and latero-lateral flattening of the middle third, lead can flatten the thoracic cavity without disrupting the function of breathing.

Key words: scapula, humerus, squirrel.

Placed in the large group of rodents, the squirrel skeletal conformation is consistent with the needs of transportation and nutrition, living environment dependent. Thus, in terms of morphofunctional features of the skeleton, the squirrel is observed the skeletal adaptation to earth moving by leaps and movements of the climb in the arboreal environment.

MATERIAL AND METHOD OF WORK

Studying morpho-functional features of the skeleton in squirrel dissection and preparation was done by scraping tissue from adjacent bone parts on them, in length and appearance of muscle insertion process and extent of jointing surface of each bone. The specificites found were photographed, described and compared with the similar structures seen in other species, seeking to permanently interpretation, basic anatomical principles, in terms of cause and effect.

RESULTS AND DISCUTION

The magnitude and diversity of movements is closely correlated with bone developing processes, which are powerful levers for muscle action, form and extent of surface motion jointing shows the possibilities and their amplitude. Cervical vertebrae in squirrel falls into a trapezoid with the large base oriented caudally. The arches of vertebrae springs are equal in size, the wide vertebrae due to gradual deployment in the lateral transverse processes. Atlas ring looks, spinal hole having a circular appearance. Arch back has the same length as that of the ventral arc. Dorsal edge is polished, the dorsal tubercle of the atlas is absent. Dorsally, to the cranial edge of the each arch is present the alar hole. Ventrally, the lateral vertebral hole opens very wide, communicates caudally with the transverse hole and dorsally with alar hole. Transverse hole is very large. Atlas wings are reduced the glenoid cavities for articulation with the occipital condyles that are concave, triangular and in continuity with one another. Cranially, on the ventral arc is seen polishing its cranial edge and a growing presence across the cartilage which supports the axis dental process (Fig. 1). The caudal surfaces for axis condyles jointing are concave and triangular aspects and the jointing surfaces continuous under dental process (Fig. 2, 3).

Axis height reduced as well as to customize the layout rectangle length. The odontoid process is cylindrical-conical, part is bordered by low notches based on a slight cranio-dorsal direction. Cranial jointing surfaces are triangular layout plan to arrive half vertebra, ventrally limited by a crest bone. The dorsal arch has a spinous process ends reduced as height cranio-caudal height gradually increases, giving it the appearance of lamellar-looking crest. This detaching by the caudal middle of each vertebra surpasses its caudal jointing surfaces. The transverse processes are reduced. The caudal notches vertebrae are deep (Fig. 4).



Fig. 1- The Atlas bone at red squirrel, the cranially aspect
1-spinal hole, 2- ventral arch , 3- wings of the atlas, 4- glenoid cavity, 5- vertebral lateral hole, 6- dorsal tubercle, 7- transverse crest

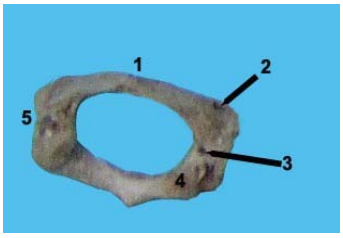

Fig.2. The Atlas at the red squirrel, caudal aspect
1- dorsal tubercle, 2- alar hole, 3- transvers hole, 4- caudal jointing surfaces, 5- the wing of the atlas.

Fig. 3 The atlas bone at red squirrel, dorsal aspect

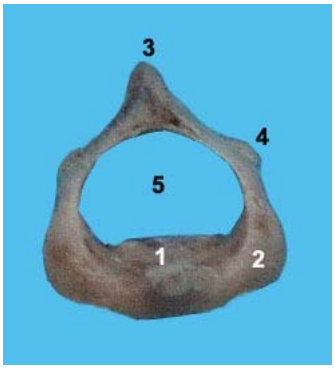

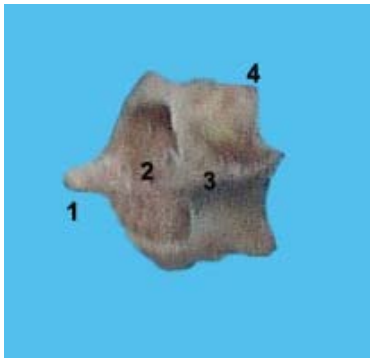

Fig. 4. The axis at red squirrel, A- lateral aspect, B- cranial aspect, C- dorsal aspect
1- dental process, 1'- cranial jointing surface, 2- vertebral body, 3- spinous process, 4- caudal jointing surfaces, 5- transverse hole, 6- caudal jointing surfaces.

Third cervical vertebra is extremely short body. Arch back underrepresented ends with a small dorsal tubercle, barely visible (Fig. 6). Side view representation of the neural arch is confined only to the dorsal tubercle and that supports and develops the cranial and caudal jointing processes. The transverse processes are like a bone blades, are unicuspide heads and ends. Come off at right angles and are moving more latero - reaching the mid-caudal vertebra next. The transverse process is transverse by the same dug.

Fourth cervical vertebra differs from III in that it is shorter, is equipped with a dorsal tubercle lower than previous dorsal tubercle. The transverse processes are latero-caudally detached, ending with a single buttoned tubercle, greatly exceeding the caudal limit of vertebra reaching plan ahead. The cranial and caudal jointing processes are detached along the upper edge of the neural arch, linked by one bone blade. Fifth cervical vertebra is very similar to vertebrae of IV, the only difference being the edge partition aspect of the transverse processes. The ventral tubercle is flattened, along with the same of the seventh vertebra defines the ventral vertebral groove that is superficial and extremely large. Sixth cervical vertebra is different from the others because has a disunited edge of the transverse process, the lateral cusp is similar to previous vertebrae but the ventral cusp forms a ventral spinal gutter (Fig. 5). Seventh cervical vertebra body is reduced, the back arch is limited to one half the length of the blade bone vertebrae and the dorsal tubercle is lacking. Transverse processes are long, flattened dorso-ventrally, seconded slight lateral cranial orientation. Cranial and caudal jointing processes are similar in shape, beyond the arch but dorsally.

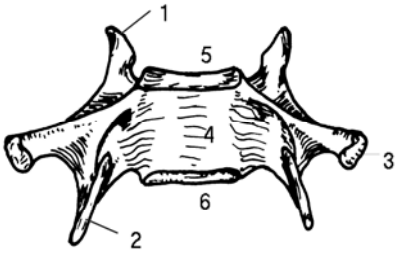

Fig. 5. The ventral face of the sixth cervical vertebra at squirrel

1- transverse process - cranial tubercle, 2- caudal tubercle, 3- ventral tubercle, 4- The ventral face of the vertebra, 5- cranial jointing surface, 6- caudal jointing surface

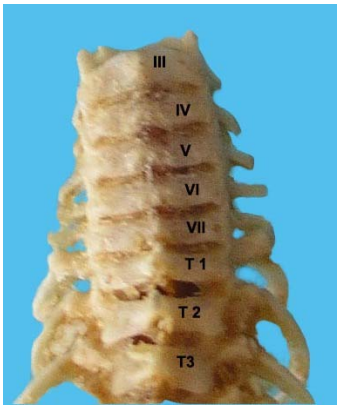

Fig. 6. The cervical vertebrae at the red squirrel, dorsal view

Thoracic vertebrae to the squirrel. Thoracic vertebrae are 13 in number. Spiny processes are reduced in height to the first two vertebrae and then rose sharply to 0.3 cm in height, is committed to caudal, to the last vertebrae are again straight, being the tenth vertebra the vertebrae anticline. The transverse process of the XI vertebrae guided cranially, the rest of processes are much reduced. Vertebral body of the first vertebra is lower but flattened, the last vertebra were developed and cylindrical body. Cranial and caudal jointing surfaces are planes. Ventral face of the vertebrae bodies are flat in the first 4-6 thoracic vertebrae and the rest of them are cylindrical. Arch back is broad, flattened dorso – ventrally, the neural canal is elongated to the lateral side. Move the bow back thorny process that occurs as the first two thoracic vertebrae tuber becomes high and conical up to the ninth vertebra as the last vertebra to take part lamellar and not exceed 0.5 cm, height is tricky process of the lumbar vertebrae. Transverse processes are long jointing surface being provided with the tubercle coast oval and well demarcated. The free edge of the transverse process has the mamilare processes attached by the base. The laterally detaching of the transverse processes is caudally progresive reduced because the last two ribs, the floating ribs, are jointed only with the body of the same degree vertebrae. Since tenth thoracic vertebra one's shows the progressive development of accessory processes. At the tenth vertebral level seen posting and increasing cranial and caudal jointing processes, the appearance is similar to that of the lumbar vertebrae (Fig. 7, 8).

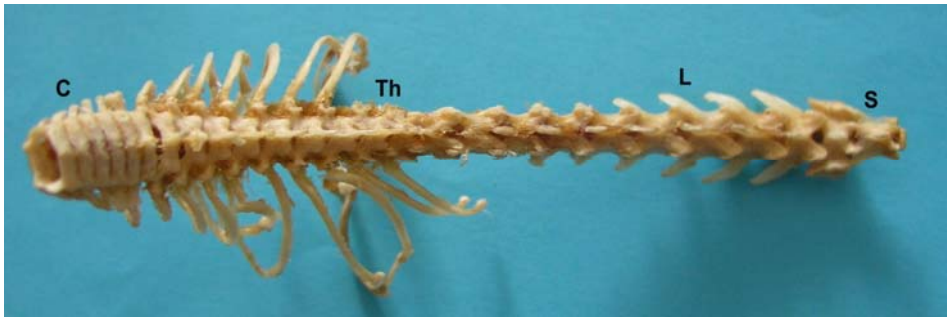

Fig. 7.The spine at red squirrel, dorsal view
C- cervical vertebrae, Th- thoracic vertebrae, L- lumbar vertebrae, S- sacral vertebrae.

RIBS

Fig. 8. The spine, the ribs and sternum at red squirrel

The ribs are 13 pairs of numbers where seven pairs articulate with the sternum directly, as sternal ribs, four pairs formed hypochondrium and two pairs are floating. Sternal ribs are arched especially in proximal third (Fig. 7, 8). Articular head consists of two halves at the middle joints that allow little space, notch of the head ribs being replaced by a low rib tuber for ligament insertion. The two joint surfaces are not equal than the first rib, and caudal articular surface is reduced in size, remained predominant first, the cranial that offering wider opportunities for dragging, expanding more in the lateral chest area. Distance between head and tubercle rib coast not significantly alter at the sternal ribs, being large, reaching almost a quarter inch proximally coast and dropping. First rib is short, massive, very curved and supports a powerful jointing head rests on a long neck. The rib tubercle is deployed, has a triangular aspect layout oriented caudally (Fig. 6). The ribs increase in length towards the caudal, while appearing and changes depending on the degree of their coasts: they lose convexity ribs became almost flat (floating ribs) and the tuber of the ribs approaching the head of the ribs size is reduced so that at the floating ribs merging it and disappears.

Both sides differ as a function of its degree and its length. Thus, the proximal third is flattened cranio-caudal coast is like a harvest, the middle third of the body there is a rotating cylinder and becoming the third coast, the coast becomes flatter distal latero-medially, sternal end of coastline is tuberous in order to enhance the surface of the condrojointing cartilage. These changes are very evident at the sternal ribs, especially being in contrast to the floating ribs that are cylindrical throughout its length.

Sternum is composed of seven and six sternebres young animals to adults because the bodies five and six are welded together. First sternebra is approximately quadrilateral edge is flattened and has joint surfaces of each clavicle. The joint surfaces are formed behind other areas for articulation with the first-rib cartilage. Ventral face of the first sternebra has a sharp ventral ridge. At the

second to fifth, the bodies of sternebrae are approximately cylindrical shaped, flattened on the back. The sixth continues with an appendix cartilage looking as a leaf. The sternebra bodies are ossified, the jointing among the sternebra is through intersternebral discs, the condrocostal cartilage, the same ossified, is articulated between two sternebrae. The condro-costal cartilages are more in the lateral moved. Because they are ossified, increase the resistance of the thoracic cavity. This is complemented by the architecture of each cartilage. Thus, rib cartilage has uniform appearance along the length, the proximal third is flattened medio-laterally (like the rib), the middle third at the angle of the cartilage is cylindrical and the distal third is flat transversecranio-caudally, to strengthen and achieve a wider area as the sternum joint, especially for increasing cartilage strength.

Lumbar vertebrae, numbering six, have body twice longer than the thoracic the spinous process is wide and the same height as the spiny thoracic processes. Transverse processes develop gradually towards the last lumbar vertebra where the maximum length and are cranio-ventrally oriented (Fig. 9).

Sacral vertebrae, number two vertebrae, are welded together. First sacral vertebra has the same wide as the lumbar vertebrae. Because posting the full length of the body it looks rectangular wings sacrum. Mamiloarticular processes are welded together delimiting suprasacrale holes. Transverse processes form the lateral sacral crest. The second sacral vertebra narrows to half the width of sacrum and is very similar to the morphological characters of the tail vertebrae (Fig. 10).

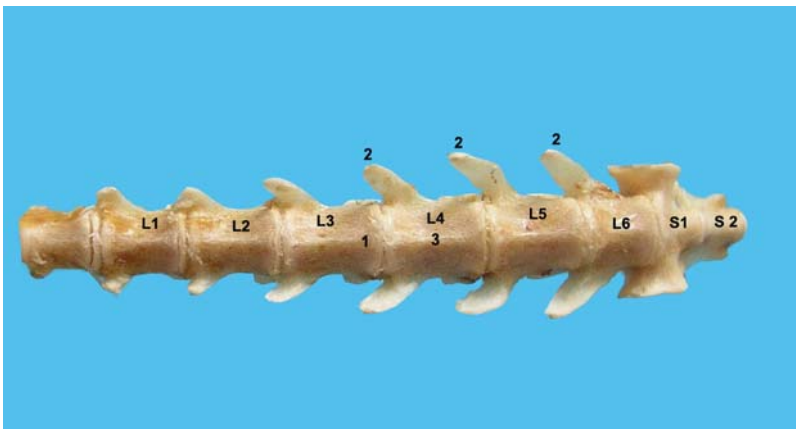

Fig. 9 The ventral aspect of the lumbar vertebrae at red squirrel

1- the vertebral body, 2- transverse processes, 3- the ventral vertebral crest

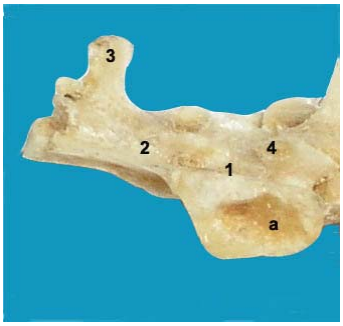

Fig. 10 The sacrum at red squirrel, latero- dorsal aspect

1-caudal jointing process, 2- transverse processes, 3- spinous proces, 4- mamiloarticulare processes, a- facies auricularis.

The tail vertebrae. In squirrel numbers are tail vertebrae 22-23. The first vertebra attached to the sacrum, the transverse processes of it are reduced, increasing in size to second vertebrae and then reduce to the sixth vertebra, and then disappear. Spiny processes gradually reduced. Ventrally, the bodies of the third and fourth regional vertebrae present a ventral crest and the seventh and eighth present the hemal arch (Fig. 11).

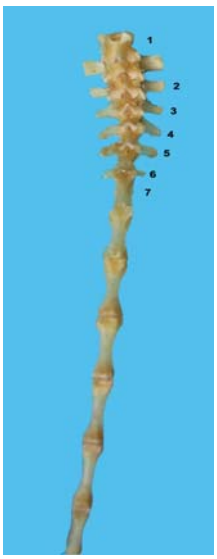

CONCLUSIONS

1. Cervical spine looks trapezoid region by reducing the length and increase in width following the development of transverse processes of the V-VII vertebrae. This side shows the motion reduced and limited to the neck region.
2. Coasts by flattening their cranio-caudal end of the proximal and distal extremities and latero-lateral flattening on the middle third ample opportunity to determine the dorso-ventrally flattening of the thoracic cavity without disturbing the function of breathing.
3. The lumbar region is noted that doubling the length of the region from the other species and reduced the transverse processes, which are evident only at the last lumbar vertebra. These morphological features indicating the possibility of large movements in the region including the movement side by reducing the transverse processes.

BIBLIOGRAFY

1. Barone R., şi colab. – Atlas d'anatomie du lapin, Ed. Masson, Paris, 1973
2. Coţofan V., Palicica R., Valentina Hriţcu, Enciu V. – Anatomia animalelor domestice, vol. I, Ed. Orizonturi Universitare, Timişoara, 1999.
3. Hriţcu Valentina, Coţofan V. – Anatomia animalelor de blană- Nutria şi Dihorul. Ed. Ion Ionescu de la Brad Iaşi, 2000.
4. Konig H. E., Liebich H.C. – Anatomie der Haussangeliere, Band I, Schattauer, Stuttgart, New York, 1999.
5. Tudor, Denisa, Constantinescu, Gheorghe - Nomina Anatomica Veterinaria, Ed. Vergiliu, Bucureşti, 2002.

Acknowledgements

Researches financed from grant
PN/II/DE/1112/2008 by CNCSIS-UEFISCSU

MORPHO-FUNCTIONAL PECULIARITIES OF THE THORACIC LIMB JOINTS AT RED SQUIRREL (SCIURUS VULGARIS)

C. SPATARU, Mihaela SPATARU, M. LAZAR, A. MUNTEANU
Faculty of Veterinary Medicine, Iassy

SUMMARY

Dissection performed on the frontlegs of the dead squirrels took into account evidence of the shape of the jointing surfaces and ligaments, following by a description and interpretation of morpho-functional features of this species. Following is remarkable articulation with the trunk and front legs through the clavicle constitute a powerful lever between the trunk and limbs. Scapulo-humeral joint with double axis shaft cranio-caudal to latero-medial shows extensive movements of flexion and extension arms. Elbow joint to customize with the shape twisted in 'S "of demimoon notch of the articular surface of the olecranon while making joint flexion and extension rotation with autopodium and make movement of pronation. The wrist joint to customsize the look elongated concave latero-medially end of the jointing surface of radius and ulna and proximal face of the convex aspect of the wrist.

Key words: sciurus, anatomy, joint, ligament

Joints are connected more or less mobile of the bones of the body. Mobility is provided by muscles acting on the principle levers of power. Mode of action of force can be determined morphologically the shape and development of flesh on the bone surfaces (1, 2, 3). Connecting means providing support and guidance but, braking or changing direction of action, are closely interrelated with development and the position they occupy ligament or ligaments against joint angle (2). Morphological studies on mammals and birds osteoligamentar system showed osteoligamentar private structures, correlated with differentiation and precision of movement (ring ligament of elbow joint in carnivores, lig. glenohumeral, etc) (2, 3, 4).

MATERIAL AND METHODS

The study was made on the Sciurus vulgaris frontlegs, after theirs hunting. The joints were prepared or cut out the adjacent tissues. In this matter the pieces was submitted to the description of the form bones, length and development of the osseous processes, jointing surfaces and jointing mobility. All of this were treated in comparison with the same structures had met at the reference species, the peculiarities discovered being photo illustrated.

RESULTS AND DISCUSSION

The frontlegs used in climbing, travel and support land and harvesting food for gripping resistive, will present some particular morphological structures adapted to these requirements. Thoracic limb attachment is via the trunk muscles and joints are formed between the clavicle and sternum and collarbone and shoulder. Clavicle by prismatic look slightly curved in 'S', presents a convex articular surface that articulates with the articular surface of sternal manubrium. Distal it is articulated trough an elongated surface of acromion (Fig. 1, 2). Scapular-humeral joint capsular ligament has a broad, being reinforced by a glenohumeral ligament inserted between the choracoid process and under the joint head of the humerus. Glenoid cavity of the case spread on

tuber supraglenoid cranial-caudal axis determines that the joint is twice higher than latero-medial axis. The articular head of humerus is convex, than the width being much elongated glenoid cavity surface cranio-caudal (Fig. 1, 2). The elbow joint has the most important changes that adapt to the type of motion. For exemple, cranially, the articular condyle of the humerus is joined to the lateral lip of humeral trochlea being rounded like a head joint. Caudally, it marrows the jointing surface is transformed into a ridge which, togeder with the medial lip, marks the humeral trochleea (Fig. 3). The humeral condyle articulates with the glenoid cavity of the radius (2, 3). Thus, humeral medial lip of trochlea has sharpened separate from the side by a broad moat, oblique latero-medially. Articular surfaces of radius and ulna to customize a circular radius glenoid cavity for articulation with the humeral condyle articular surface and twisted in the shape of 'S' which appears on the olecranon incizure crescent, the surface that articulates with humeral trochlea. Joint articular capsule is reinforced by enhanced lateral collateral ligament and medial funicular that provision (Fig.2, 4). Radius, proximal ulna is supported by an annular ligament (4) that has the insertions of ulna coronoid processes. Form the articular surface, in particular the semimoon notch produces the supination of hand during flexion and pronation hand during extension. These morphological features indicating effective adaptation of species to move by climb (Fig. 4).

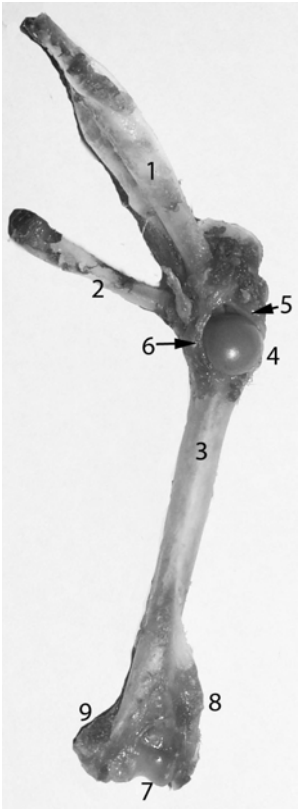

Fig. 1. The shoulder joint at red squirrel, caudal aspect
1-scapula, 2-clavicula, 3-humerus, 4-caput humeri, 5-cavitas glenoidalis, 6-lig. glenohumeralia, 7-trochlea humeri, 8-epicondylus lateralis, 9-epicondylus medialis.

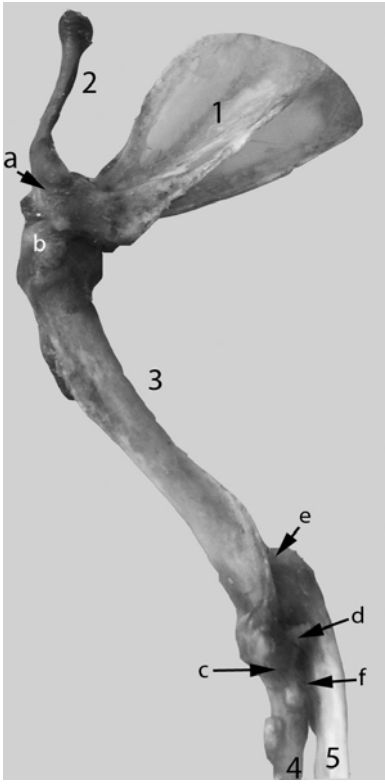

Fig. 2.The shoulder and elbow joints at red squirrel, lateral aspect
1-scapula, 2-clavicula, 3-humerus, 4-radius, 5-ulna. a-articulaţia acromio—claviculară, b-tuberculum majus, c-lig. colaterale laterale, d-lig.anulare radii, e-olecranon, f-proces coronoideus lateralis.

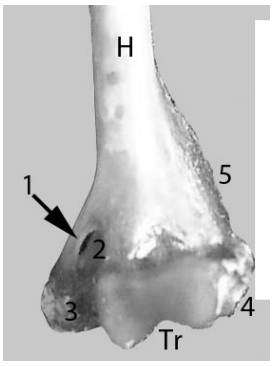

Fig. 3. The distal joint surfaces of humerus at red squirrel
H-humerus, Tr.-trochlea humeri, 1-epicondilus mediali, 2-foramen epicondilaris,3-condylus humeri mediali, 4- condylus

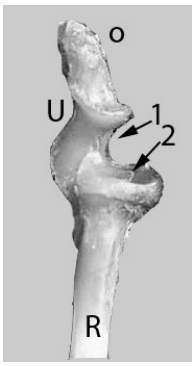

Fig.4. The proximal joint surfaces of radius and ulna at red squirrelU- ulna, R – radius, o-olecranon, 1-incisura trochlearis, 2-fovea capitis radii.

To customize the carpal joint: the articular surfaces of the distal extremities of radius and ulna form a common cavity elongated and concave latero-medial and cranio-caudal convex. The articular surface articulates with the articular surface is composed of scafolunar and pyramidal, elongated and convex latero-medial and cranio-caudal concave. Form articular surfaces lead to large latero-medial movements and movements of flexion and extension. Rotation movements are limited by shorter collateral ligaments, the jointing surface flattening and widening intercarpal and antebrahio-carpal joint cavities (Fig. 5). At the metacarpo-phalanx joints, like other species, the distal articular surface is like a head (dorsally) and, a longitudinal relief in two separates, as a condyls, the articular surface (palmary). This mode allows safe use of finger joints in support of foods, in making the nest, in climbing, etc. by total or partial flection of the phalanx (Fig. 6).

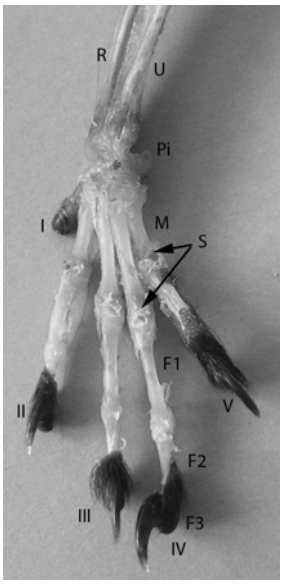

Fig. 5. The acropodial joins, dorsal aspect

R-radius, U-ulna, Pi-os pisiforme, M-ossa metacarpalia, s-ossa sesamoidea dorsalia, F1,F2,F3,-phalanx 1,2,3. I-V-ossa digitorum

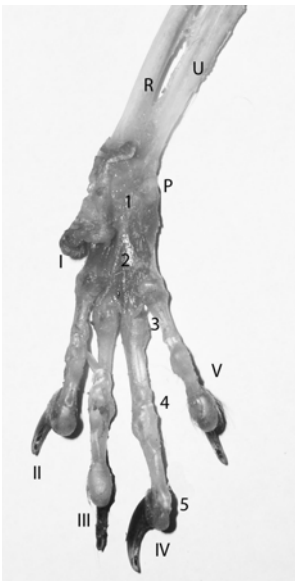

Fig.6.The acropodial joints, palmary aspect
R-radius, U-ulna, P-os pisiforme, M-ossa metacarpalia, s-ossa sesamoidea dorsalia, F1,F2,F3,-phalanx I,II,III, I-V-ossa digitorum
1-capsula articularis, 2-mm. interossei, 3- articulationes metacarpophalangiene, 4-5-articulationes interphalangiae

CONCLUSIONS

1. Attach the trunk and limb chest through cleido-steral joint is an important level between the trunk and the member who opposes direct action on the chest muscle during the current movements of the limbs.
2. Elongation in cranio-caudal end of the glenoid cavity and humeral surface that is congruent causes large movements of flexion and extension and slight adductor movements and abduction.
3. At the elbow joint, the aspect in "S" of the semimoon articular surface of olecranium causes pronation and supination movement beside the flexion and extension
4. Convex-concave shape of the articular surfaces of the distal extremity of the radius and ulna and their negative of the first row of carpal bone determines cranio-caudal and latero-medial motion.
5. Dorsal articular head of each metacarpals bone, are continued palmarry with two condyles separated by a ridge and articular cavity of the phalanx palmarry are continued with two separate cavities through a notch allowing precision and stability during flexion phalanx.

BIBLIOGRAPHY

1. Grasse P.P. - *Traite de Zoologie*. Anatomie, Systematique, Biologie. Tome XVI, Fascic. VII, Paris, 1972.
2 Konig H. E., Liebich H.C. – *Anatomie der Haussangeliere*. Band I, Schattauer, Stuttgart, New York, 1999.
3. Nickel R., Schummer A., Seiferle E. – *Lerbuch der Anatomie der Haustiere*. Band I, Verlag Paul Parey, Berlin und Hamburg, 1992.
4. Tudor Denisa, Constantinescu, Gheorghe - *Nomina Anatomica Veterinaria*. Ed. Vergiliu, Bucureşti, 2002

Acknowledgements
Researches financed from grant
PN/II/DE/1112/2008 by CNCSIS-UEFISCSU

CLINICS

A NEOPLASIC ENCEPHALOPATHY IN DOG-CASE REPORT

Mihaela ARMAȘU, M. MUSTEAȚĂ, Carmen SOLCAN, Gh. SOLCAN
Faculty of Veterinary Medicine Iasi

A 9 year old male Bichon dog was presented to Internal Clinic of the Faculty of Veterinary Medicine Iasi with confusion, no menace response and diminished direct pupillary light reflex in the right eye. A right facial paresis was present and hemiwalking reaction on the right side was diminished. He had poor reaction at nasal mucosa stimulation on both nostrils. On computed tomography exam we observed two isodense masses in both temporal lobes surrounded by hypodense oedema zones. The right lateral ventricle and mesencephalic aqueduct were dillated. At necropsy we observed two hemorrhagic zones in both temporal lobes. In abdominal cavity a serohemorrhagic peritoneal liquid and a 10 cm diameter well circumscribed mass in omentum were present. Two nodular formations with increased consistency were present in the spleen.

Keywords: computer tomography, tumor,brain, dog

INTRODUCTION

Hemangiosarcoma is a malignant tumor of the endothelial cells. The dog is the most frequently affected species, hemangiosarcoma being observed in 0,3-2% of all canine necropsies and constitutes about 7% of all malignancies in dogs (Smith Annette N., 2003). The average age of the dogs presented for medical examination is 11 years (Summers B. A., 1985), and at the moment of presentation 80% of the subjects already have metastases in liver or lungs (Smith Annette N. 2003, Withrow S. J. 2001). In 14% of the cases the tumor gives cerebral metastases, making hemangiosarcoma the main type of sarcoma with cerebral metastases (Waters D.J. 1989).

MATERIAL AND METHODS

The study was made on a Bichon 9 years old male dog who was presented to Internal Clinic of Faculty of Veterinary Medicine Iasi. The dog was submitted to neurologic and imagistic exam. Computer tomografical examination was performed under general anaesthesia using a combination of medetomidin (Domitor) in dose of 0,03 mg/kg iv and Ketamine in dose of 0,3 mg/kg i.v . Computer tomography was made with Siemens Emotion CT the dog being placed in sternoabdominal position. The images were captured before and after contrast enhancement (Scan Lux 750 mg/Kg i.v). For euthanasia T61 commercial substance was used.

RESULTS AND DISCUSSIONS

The dog was presented for consultation because in the last 4 days it showed contraction of the right facial muscles. The clinical examination revaled physiological values within normal limits (temperature 38,5˚C, heart rate 91 beats/minute, respiratory rate 26 breaths/ minute), normal appetite for water and food. At neurological exam was observed confusion, diminished hemilocomotion on the right side, normal spinal reflexes, absence of menace response and diminished pupillary light reflex on right eye, diminished response to the stimulation of the nasal mucosa on both nostrils and right facial nerve paresis. In the next

48 hours the neurological status of the dog depreciated leading to walking in wide circles towards the left side, right hemiinatention and the billateral loss of superficial pain.

CT scan revealed: a bilateral presence in the temporal lobes of 2 isodense regions surrounded by a hypodense halo with 11-19 UH radioatenuation without intensification at contrast enhancement, suggesting for cerebral oedema (fig.1), the dilatation of the right lateral ventricle and of the mesencephalic aqueduct, the latter being extended and observed in the postcontrast slides up to the pons, (fig.2).

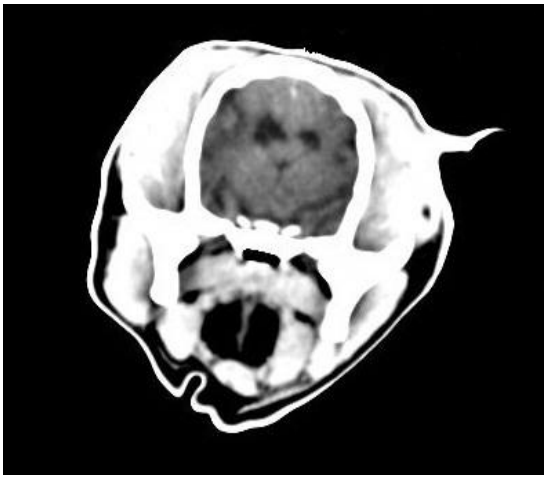

Fig. 1 Cerebral section at cortico-mesencephalic level. Bilateral isodense tumoral lesions in the temporal lobes.

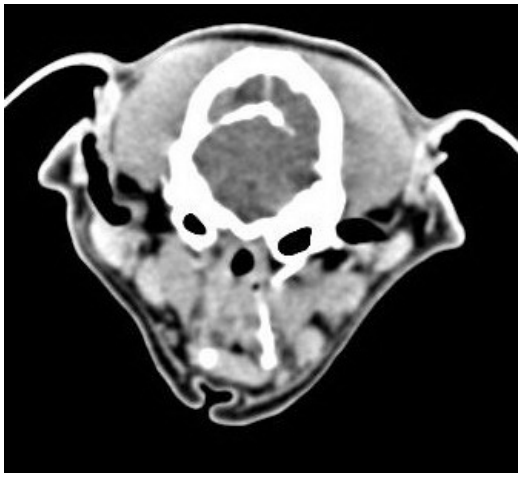

Fig. 2 Cerebral section at the supratentorial level. Dilatation of the mesencephalic aqueduct

The coroboration of the clinical and imaging data led to the diagnostic of neoplasy.

After the anesthesia, the neurologic status of the pacient got worse (status epilepticus) and the owners chosed euthanasia.

The gross lesions observed on the body were: the presence of a sero-hemorrhagic liquid in the abdominal cavity, a well delimited, purple-red, 10 cm in diameter mass on the epiploon and 2 nodules in the spleen. In the temporal lobes, there were 2 purple-red, hemorrhagic masses. The left mass was more extended than the right one(fig.3).

The results of the histopathological exam were consistent with hemangiosarcoma.

Fig.3. Encephalon. Hemorrhagic lesion in the left temporal lobe.

The clinical signs manifested by the dog at the moment of the presentation suggested the presence of a lesion in the right temporal cortex which caused the focal epileptic crisis, manifested by right facial contractions. After a few days, the clinical signs were altered by the

compression of the brainstem manifested by the central paresis of the right facial nerve with the loss of the ipsilateral menace response. In this case, it is obvious that the clinical signs related to the lesion of the brainstem can supress the ones regarding a lesion of the cerebral cortex.

The loss of the sensitivity of the nasal mucosa, of the superficial sensitivity of the trunk, together with the hemineglect are suggestive for a corticodiencephalic lesion that causes a defficit of the integration of the sensorial information provided by the contralateral side of the body (Platt, S.R., 2004).

In this case, the CT and the necropsic examination show that the symptoms of the cerebral neoplasms are not directly correlated with the size and site of the tumoral lesions, but the collateral effects of the growth of the tumoral process causes more serious symptoms and may mask the signs determined by tumor itself (Braund K.G., 2002).

Another interesting aspect observed on this pacient was the particular CT images of the affected cerebral parenchyma. The images presented 2 isodense zones surrounded by a hypodense halo suggestive for an oedema, without intensification at contrast enhancement, although Dennler M., (2007), Akutsu H., (2004) and Guode Z. (2006) described the hemangiosarcoma as a hyperattenuated zone surrounded by oedema. Particular aspects of the hemangiosarcoma neuroimaging were occasionally reported in the medical literature. Renukaswamy G.M. (2009) could not diagnose a hemangiosarcoma of 1 year old child using CT imaging technique because of its isodensity with the cerebral parenchyma, but discovered it later using RMN.

In the absence of a histopathological exam, the cerebral metastasis of the hemangiosarcoma in dog, because of the variable clinical signs of the neoplasia, requires a careful approach in establishing the diagnosis, prognosis and therapy.

CONCLUSIONS

1. The isoattenuation and the absence of contrast enhancement of the affected cerebral parenchyma represent particular aspects in the hemangiosarcoma neuroimaging, these being rarely reported in the medical literature.
2. The solely association of the clinical data and CT images may lead to misdiagnosis because of the variable CT aspect of the cerebral hemangiosarcoma, a certain diagnsosis being possible only after the histopathological exam.

REFERENCES

1.Akutsu H, Tsuboi K, Sakamoto N, Nose T, Honma S, Jikuya T., 2004 -Cerebral metastasis from angiosarcoma of the aortic wall: casereport., Surg Neurol;61:68 –71.
2.Braund K. G. (2002)- Clinical Neurology in Small Animals - Localization, Diagnosis and Treatment Ed International Veterinary Information Service Ithaca, New York, USA
3.Dennler M., Lange Eva Maria, Schmied O., Kaser-Hotz Barbara 2007- Imaging diagnosis-Metastatic Hemangiosarcoma causing cerebral hemorrhage in a dog, Veterinary Radiology &Ultrasound vol.48, issue 2, pg.138-140.
4. Gabor L.J., Vanderstichel R.V., 2006- Primary cerebral hemangiosarcoma in a 6 week old dog, Vererinary Pathology, vol.43 nr.5 pg.782-784.
5. Platt S.R. ,Olby Natasha J. 2004–Canine and feline neurology, Third edition, BSAVA, pg.172-188
6. Renukaswamy G. M., Boardman Simone J,. Sebire J.N., Hartley B.E.J., 2009 -Angiosarcoma of skull base in a 1-year-old child—A case report, International Journal of Pediatric Otorhinolaryngology 73, pg. 1598–1600

7. Smith Annette N., 2003- Hemangiosarcoma in dogs and cats, Vet. Clin. Nth Am. Small Animal Practice, 33:533-52.
8. Summers BA*,* deLahunta A., 1985, Cerebral angioendotheliomatosis in a dog*. Acta Neuropathol (Berl) 68: 10–14.*
9. Waters DJ*,* Hayden DW*,* Walter PA, 1989,-*:* Intracranial lesions in dogs with hemangiosarcoma*. J Vet Intern Med* 3*:* 222–230.
10. Withrow S.J., Mac Ewen E.G., 2001,-Small Animal Clinical Oncology, 3rd ed. WB Sauders Co, Philadelphia, PA, pg 639-645.
11. Zhai Guode, Pang Qi, Guo Hua, Xu Shangchen, Wang Hanbin -Primary cerebellopontine angle angiosarcoma , Journal of Clinical Neuroscience, vol.15, issue 8, 2008, pg.942-946

RESEARCH REGARDING THE INCIDENCE, DIAGNOSIS AND TREATMENT OF RETAINED PLACENTA IN AUSTRIAN BROWN COWS

L. BOGDAN, I.S. GROZA, Simona CIUPE, M. CENARIU, I. PAŞCA, Sanda ANDREI, Anamaria PETREAN, Sorana MATEI, Sidonia BOGDAN
Faculty of Veterinary Medicine Cluj-Napoca, 3-5 Mănăştur Street, 400372 Cluj-Napoca

Abstract

The purpose of this study was to diagnose retained placenta in cows and to find the best therapeutic procedure for this reproductive disorder, in order to minimize expenses and obtain quick cycle resumption and a new pregnancy. The research has been carried out on 4 batches of Austrian Brown cows using 4 different therapeutic protocols: first protocol consisted of keeping the retained placenta in place and using an intrauterine suspension called Puerperal; the second protocol consisted of removing the retained placenta and using the same intrauterine suspension; the 3rd protocol consisted of keeping the retained placenta in place and using Veyx YL PELET intrauterine pellets, while the 4th protocol consisted of removing the retained placenta and using the same intrauterine pellets. The best results were obtained for the first protocol where the retained placenta was kept in place and the Puerperal intrauterine suspension was administered. The classical therapeutic procedure where the retained placenta is manually removed is no longer adequate, as better results can be obtained when the retained placenta is left in place and specific intrauterine suspensions are used.

Key words: retained placenta, cows, alternative treatment, cycle resumption

INTRODUCTION

Retained placenta represents one of the main causes of infertility in intensive cattle breeding farms. In many of these farms, retained placenta affects 75-80% of the dairy cows, with special economic consequences, given the puerperal and chronic endometritis that follow this disorder. [1, 5, 12, 13].

All these finally lead to the prolongation of service period that sometimes reaches over 180 days, the profit obtained in the respective farm being questionable. [3, 4, 8, 11].

In cattle, the frequency of retained placenta is much higher than in other species. Although this disorder is studied for over 100 years, taking into consideration its medical and economic importance, its etiology is still not completely clarified. [2, 10, 14]. Among other things, this is explainable as retained placenta in cattle is not a disease itself but represents rather a disorder that has a syndrome-like character, having multiple causes and being influenced by multiple factors. [6, 7, 9].

The purpose of our research was to find the most efficient method of solving retained placenta in cows, taking into consideration its increased incidence in farms from Dorna region.

MATERIAL AND METHODS

The research has been carried out during September 2008 – December 2009 in 4 farms from the Dorna region, on 82 cows divided into four batches according to the therapeutic protocol that was applied.

The therapeutic protocols that were applied

The first protocol referred to solving the retained placenta without extracting it, by performing a intrauterine instillation using 100 ml of Puerperal suspension 3 times every 48

hours. Thus, the placental cone was externalized and sectioned at the level of the vaginal vestibule in order to avoid contact with the exterior and therefore uterine infection (fig. 1). The protocol was applied to 20 cows belonging to batch I.

The second method consisted of manual extraction of the placenta followed by therapy using 200 ml of Puerperal intrauterine suspension, the number of treatments being established from case to case. Manual extraction of placenta referred to its removal using the standard method, as complete as possible. The part of the placenta that could not be removed after the first operation was taken out

during the second treatment. This protocol was applied in batch II made up of 20 cows with retained placenta.

Puerperal intrauterine suspension contains lincomycin, argil, boric acid, betadine and vitamins. Before use, the suspension must be homogenized in order to obtain a uniform substance, while its temperature must be of 38°C.

The intrauterine insertion was made using a special catheter and a large syringe. The catheter was inserted up to the uterine body so the suspension could enter both uterine horns.

The third protocol consisted of treating the retained placenta without extracting it using intrauterine foaming pellets (Veyx YL PELET, Veyx-Pharma GmbH). The treatment was performed respecting the manufacturer's protocol, i.e. 4 pellets for one administration, the number of treatments depending on the possibility of intrauterine insertion (fig.2). The protocol was applied to 21 cows belonging to batch III.

The last protocol used for the treatment of retained placenta consisted of the manual extraction of placenta followed by the therapy using foaming pellets (Veyx YL PELET, Veyx-Pharma GmbH), 4 pellets for one administration, the number of treatments depending on the possibility of intrauterine insertion. The protocol was applied in 21 cows belonging to batch IV.

Throughout the whole duration of puerperium and after, the cows were monitored in order to observe the evolution of puerperium, the first cycle after calving, the length of puerperium and the number of inseminations needed for a pregnancy.

Fig. 1 Insertion of the Puerperal intrauterine suspension

Fig. 2 Intrauterine insertion of the foaming pellets

RESULTS AND DISCUSSIONS

Following the research performed in the four farms we obtained close percentages regarding the incidence of retained placenta, due to similar nutrition and management: Farm A – 60.52%; Farm B – 57.14%; Farm C – 55.88%; Farm D – 55.55% (Chart 1).

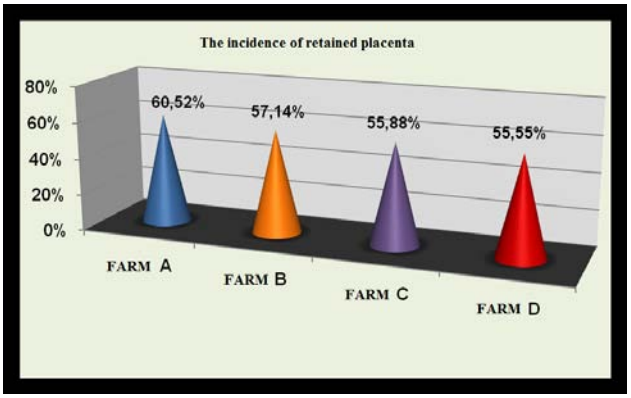

Chart 1 – Incidence of retained placenta in the four farms

In what the incidence related to season was concerned, the highest incidence was observed during winter (54.87%), a more reduced incidence during spring (26.82%) and autumn (14.63%) while during summer time the retained placenta was observed in a very small percentage of 2.43% (Chart no.2).

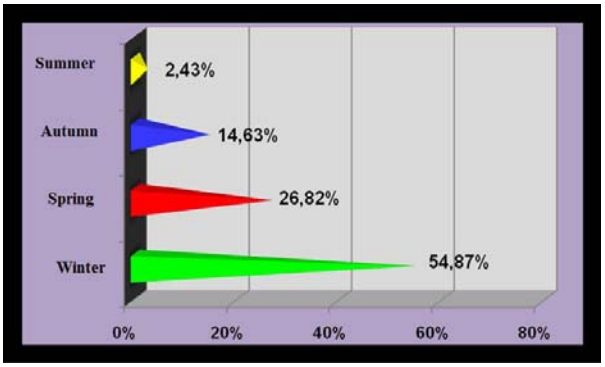

Chart no.2 – The incidence of retained placenta according to season in the four farms

Regarding the age and previous pregnancies, following the research conducted throughout a year in the four farms, a high incidence of retained placenta was observed in heifers (65.85%), followed by cows at the second delivery (17.97%), while the lowest incidence was observed in cows with more than 2 calvings (4.87%) (Chart no.3).

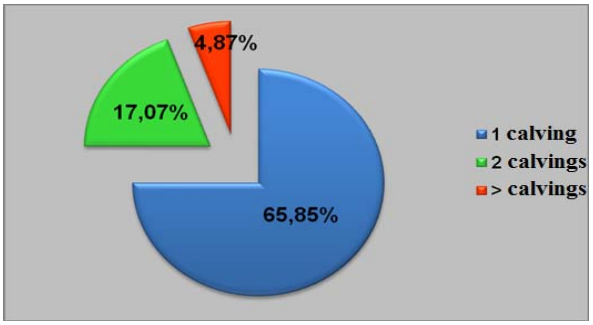

Chart 3 – Graphic representation of retained placenta according to the number of deliveries in the four farms

Following the treatment performed in order to solve retained placentas using the Puerperal intrauterine suspension without extraction, they had a normal evolution with maceration and elimination of the placenta in 19 cows (95%). For a complete treatment 3 administrations of Puerperal intrauterine suspension were needed, the placenta being expelled after 7-9 days from delivery. Following this protocol, one cow presented complications with infected placenta and lochia, and followed another therapeutic protocol.

Following the second protocol that consisted of intrauterine Puerperal suspension after placenta removal 18 cows (90%) showed a physiological post-partum evolution, while two cows presented lochiometritis and were treated accordingly.

The third protocol using foaming pellets without placenta extraction was performed in 21 cows. Among these, 10 (47.61%) eliminated the placenta after 6-9 days without complications (macerated placenta), while 11 cows showed infected placenta and lochia with severe modifications of the general status and followed another therapeutic protocol.

In case of the 4th protocol, from 21 cows that were treated using foaming pellets after placental extraction, 12 cows (57.14%) had a physiological evolution of puerperium, while 9 cows presented lochiometritis and followed another therapeutic protocol.

The healing percentage of retained placenta according to the therapeutic protocol that was applied is shown in chart 4.

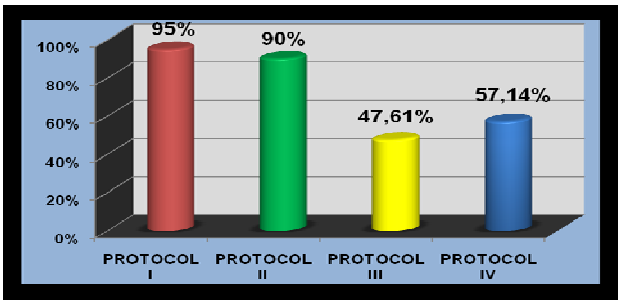

Chart no. 4 Healing percentage of retained placenta according to the therapeutic protocol that was applied

Regarding the monitoring of the first cycle after delivery, it was shown that after the first therapeutic protocol using Puerperal intrauterine suspension without placenta extraction, the first cycle appeared 32-37 days after delivery in 19 cows, while the heats were well expressed with transparent, stringy mucus. The rectal palpation showed a typical estrus concerning the uterus, with the presence of a Graafian follicle. One of the cows (the one showing complications) presented the first cycle 65 days after delivery while the rectal examination showed a slightly thickened uterus, the follicle had around 1.2 cm and the mucus showed traces of mucosa, being diagnosed with occult chronic endometritis and treated accordingly.

After the treatment of cows using the second protocol, the first cycle appeared 30-36 days after delivery in 15 cows, 40-52 days after delivery in 3 cows while 2 cows had not shown any signs of estrus up to 90 days after delivery, being diagnosed with first degree uterine and ovarian hypoplasia. Among the 15 cows that showed estrus 30-36 days after delivery, 14 had normal heat signs while one cow showed abundant gray mucus but no modification for rectal palpation.

In cows treated using protocol III, with Veyx YL PELET foaming pellets without placenta extraction, the first cycle appeared 34-39 days after delivery in 6 cows among which 2 showed transparent, stringy mucus and clinical signs of estrus, while 4 showed gray mucus with white spots. The other 4 cows showed signs of estrus 42-52 days after delivery, 3 of which had a weakly expressed estrus with small amount of mucus, decreased erectility of the uterus in

rectal palpation and 1-1.5 cm follicles; one of the cows showed purulent secretion while the uterus was thick and non-reactive after rectal palpation.

Regarding the cows diagnosed with retained placenta and treated using the fourth protocol, 7 cows showed the first estrus signs 30-34 days after delivery while 5 cows showed heats 40-49 days after delivery. The first 7 cows showed transparent, stringy mucus and physiological signs of estrus, while among the other 5 cows, 3 showed a small amount of viscous mucus, colored in gray. Nine cows had not shown signs of estrus 90 days after delivery and were diagnosed with 2nd and 3rd degree of uterine and ovarian hypoplasia.

Regarding the interval between delivery and the first fertile insemination, we had the following situation:

In cows submitted to protocol I, the service period was of an average130 days, needing 1.2 doses of semen for a pregnancy, with a rate of 100%.

The average duration of service period for cows treated by the second protocol was of 152 days, with 1.5 doses of semen/pregnancy. Only 19 cows were pregnant (95%) while one of the cows was not diagnosed pregnant throughout our research.

The cows treated by protocol III using Veyx YL PELET foaming pellets and without extraction of the placenta had an average duration of service period of 210 days, needing 1.2 doses of semen for a pregnancy, while 4 cows were not diagnosed pregnant throughout our research, the pregnancy rate being of 80.95%.

The cows treated using the fourth protocol had an average duration of service period of 230 days needing 2.2 doses of semen for one pregnancy. The number of pregnant cows after the treatments was of 18 (85.71%), while 3 cows were not diagnosed pregnant throughout our research.

Following the research concerning the therapy of retained placenta we also calculated the costs for each protocol that was used, including the treatment of cows that showed complications, until the next pregnancy. The price for protocol I using Puerperal intrauterine suspension without extraction of the placenta was of 50 lei/cow, for protocol II using Puerperal intrauterine suspension with extraction of the placenta of 70 lei/cow, while the treatments using protocol III and IV using Veyx YL PELET foaming pellets with or without extraction of the placenta the price was of 100 lei.

CONCLUSIONS AND RECOMMENDATIONS

1. Regarding the incidence of retained placenta in the four farms no significant differences were observed: Farm A – 60.52%; Farm B – 57.14%; Farm C – 55.88%; Farm D – 55.55%.
2. From the point of view of the time of occurrence, most retained placenta were diagnosed in winter time (54.87%), spring (26.82%) and autumn (14.63%), while the lowest percentage of retained placenta was diagnosed during summer time (2.43%).
3. Given the fact that heifers were imported, the accommodation stress, transportation, nutrition and management change, the highest incidence of retained placenta was shown in primiparous cows (65.85%), followed by second calving cows (17.07%), while the lowest percentage was met in cows with more than 2 deliveries (4.87%).
4. Following the application of the 4 therapeutic protocols in order to treat the retained placenta we can conclude the following: the healing percentage of retained placenta was of 95% for protocol I , 90% for protocol II, 47.61% for protocol III and 57.14% for protocol IV.
5. The service period in cows belonging to batch I was of 130 days, batch II 152 days, batch III 210 days and batch IV 230 days.

6. The number of semen doses used for a pregnancy was of 1.2 for batch I, 1.5 for batch II, 1.2 for batch III and 2.2 for batch IV.
7. The pregnancy rate in the four farms according to the therapeutic protocol that was applied was of: Farm A – 100%; Farm B – 95%; Farm C – 80.95%; Farm D – 85.71%.
8. The price of the therapy of retained placenta was of 50 lei for protocol I, 70 lei for protocol II, and 100 lei for protocol III and IV, including the treatment of complications.
9. The results obtained by us make us conclude that today the classical method of placenta extraction is no longer successful the application of therapy without extraction being more adequate in what the price, healing process and recovery of cows for a new pregnancy is concerned.

BIBLIOGRAPHY

1. **ARTHUR G.H., NOAKES D.E., PEARSON H.,** 1989 – Veterinary Reproduction and Obstetrics, Ed. VI Bailliere Tindall;
2. **BELL M.J., ROBERTS D.J.,** 2007- The impact of uterine infection on a dairy cow's performance.Theriogenology. Oct 15; 68(7):1074-9;
3. **BOGDAN M.L.** – Reproducție, obstetrică, terapie şi însămânțări artificiale la animale, Ed. AcademicPress, Cluj-Napoca, 2001;
4. **CAIROLI F., L. FERRARIO, S. CARLI, F. SOLDANO,** 1999 - Efficacy of oxytetracycline and tetracycline-benzydamine in the prevention of infection after placental retention in cattle, The Veterinary Record, Vol 133, Issue 16, 394-395;
5. **DROST M.,** 2007 - Complications during gestation in the cow. Theriogenology, Volume 68, Issue 3, Pages 487-491;
6. **GRANT S. FRAZER,** 2005 **–** A rational basic for therapy in the sick postpartum cow. Veterinary Clinics of North America: Food Animal Practice, Volume 21, Issue 2,, Pages 523-568;
7. **GROZA I. şi col.** - Ginecologie, Andrologie si Obstetrica Veterinara Compendiu, Editura Academiei Romane, Bucuresti, Romania, 2006;
8. **HAFEZ E.S.E** – Gestation, prenatal physiology and parturition. In: Hafez, B., Hafez, E.S.E. (Eds.), Reproduction in Farm Animals, 7th edition. Lippincott Williams and Wilkins, Philadelphia, 2000, p: 140-155;
9. **KANKOFER M.**, 2001 - Placental Release/Retention in Cows and its Relation to Peroxidative Damage of Macromolecules Reproduction in Domestic Animals Volume 37 Issue 1, p. 27–30;
10. **KANKOFER M., J. LIPKO, S., ZDUNCZYK,** 2005 – Total antioxidant capacity of bovine spontaneously released and retained placenta. Pathophysiology, Volume 11, Issue 4, Pages.215-219;
11. **RISCO C. A. -** 2004 - "Managing the postpartum cow to maximize pregnancy rates", Proceedings 2004 Florida Dairy Reproduction Road Show, www.medwellonline.net;
12. **STEPHEN J. LEBLANC,** 2008 - Postpartum uterine disease and dairy herd reproductive performance; A review The Veterinary Journal, Volume 176, Issue 1, Pages 102-114;
13. **TAMIR GOSHEN, NAHUM Y. SPIGEL,** 2006 **-** Evaluation of intrauterine antibiotic treatment of clinical metritis and retained fetal membranes in dairy cows**.** Theriogenology, Volume 66, Issue 9, December 2006, Pages 2210-2218.

DIETARY, MAINTENANCE AND PHYSIOPATHOLOGY FACTORS INVOLVED IN THE ETIOLOGY OF KETOSIS IN DAIRY COWS

Boghian V.
Faculty of Veterinary Medicine Iasi
Alley M. Sadoveanu no. 8
vboghian@yahoo.com

ABSTRACT

In 40 dairy cows of Holstein Frisian breed were determined some biochemical parameters of the energy profile, ketonuria and ketolactia. These cows were divided into four lots of 10 cows: group M (control), group A (high milk producing cows), group B (cows fed with hypoenergetic rations consisting mainly of maize silage), group C (cows maintained outdoors in winter season, with low temperatures at night).

Cows in group M had average values of glucose, lipids, serum β-hydroxybutyrate and alkaline reserve within the average reference and testing for ketonuria and ketolactia were negative.

Cows in group A had mean values of glucose, lipids, serum β-hydroxybutyrate and alkaline reserve included within the reference average values. Instead, individual determinations led to the diagnosis of subclinical ketosis, characterized by β-hydroxybutyrate values above 14.4 mg / dl in three cows in this batch. ketonuria determination was positive in three cases and ketolactia was only weakly positive in two cases.

Cows in group B had mean blood glucose, lipids, serum β-hydroxybutyrate and alkaline reserve values were within the reference average. Instead, after individual determinations 2 cases had β-hydroxybutyrate values specific to subclinical ketosis. ketonuria was positive and ketolactia weak positive in two cows belonging to this group.

Cows in group C the mean and individual glucose, lipids, β-hydroxybutyrate and alkaline reserve values were within reference. ketonuria and ketolactia in these cows were negative.

Thus, inadequate food rations with hypoenergetic products and silage excess or physiological state of increased metabolic demand in cows with high milk production are common factors involved in the etiology of ketosis. Low temperatures may not induce without the association of food or other physiological factors such as lactation, an energy shortage which leads to the development of ketonemia. In the laboratory diagnosis of ketosis ketolactia determination has greater diagnostic value than ketonuria determination.

Keywords: cows, ketosis, etiology

MATERIALS AND METHODS

To track the impact of various maintenance, operation and physiological factors to the onset of ketonemia were taken to study some change factors most often acting on dairy cows, namely: milk production, low temperature environment and poor nutrition .

Researches were conducted on a herd of 40 dairy cows of Holstein Frisian breed. All animals had a physiological state relatively similar, being in the first month of lactation and age between three and seven years. These were grouped into four lots of 10 cows, depending on: the production of milk, food and maintenance conditions, as follows:

-Group M (control) consisting of 10 cows with average milk production of 20 liters per day, maintained in a chained system, permanent calves and fed with forage-based diets consisting of alfalfa and natural grass, corn silage and corn grains, wheat bran, chalk and salt.

-Group A consisting of 10 cows with average milk production of over 30 liters per day (high milk producing cows), maintained and fed like cows in group M.

-Group B consisting of 10 cows fed with hypoenergetic rations and silage excess, with a milk production and maintenance system like cows in group M.

-Group C consisting of 10 cows, maintained in a free system where in the fall temperatures are low especially at night, with a similar milk production and fed like cows in group M.

After a week of clinical observation, during which factors of change have not modified, namely food, milk production and maintenance conditions, were taken samples of blood, urine and milk for laboratory determinations.

Blood samples were collected without anticoagulant for expression of blood serum to determine some parameters of the energy profile: the concentration of glucose, total lipids, β-hydroxybutyrate and alkaline reserve. They are most relevant biochemical parameters in the case of ketosis.

In urine and milk samples was monitored the presence of ketone bodies using semiquantitative methods, strips "Uric 10 FF" for urine and strips "Ketolac BHB" for milk.

RESULTS AND DISCUSSION

Values obtained from laboratory paraclinical determinations are presented in Table 1.

had averages values of 332.0 ± 21.0 mg / dL, β-hydroxybutyrate was on average 5.7 ± 1.8 mg / dl, and alkaline reserve has averaged 25.0 ± 0 5 mEq / L. All these results of the energy profile of the average values were within reference. Ketonuria had averaged less than 15 mg / dl, and Ketolactia had averaged less than 0.5 mg / dL. These results show the body's energy balance is characteristic for the metabolic health.

Cows in group A, with production of over 30 liters of milk per day had mean blood glucose values similar to those at the lower limit of the average reference values, namely 50.1 ± 3.1 mg / dl, and lipemia was similar to the average values located at the upper limit of the reference, respectively 477.9 ± 28.1 mg / dL. This assumes a negative energy balance of the body attributed to a carbohydrate deficiency.

In dairy cows a big part of blood glucose is used for mammary gland metabolism in the biosynthesis of milk. For lactose synthesis in a liter of milk is needed about 50g of glucose. This energy deficit leads to mobilization of fat deposits, explaining the existence of high lipemia.

Thus, high milk production is a factor involved in the etiology of ketosis. In this case serum β-hydroxybutyrate was on average 8.4 ± 1.4 mg / dL, mean value falling within the reference. But three cases in this group had individual values of β-hydroxybutyrate greater than 14.4 mg / dL, a value that characterizes the development of subclinical ketosis in the cow.

Alkaline reserve was on average 23.5 ± 0.5 mEq / L, value located within the reference average. But just as with β-hydroxybutyrate, 3 cases had alkaline reserve values at the lower

limit of the average reference. These values indicate the presence of excessive amounts of ketones that are not fixing bicarbonate.

In urine examination was found ketonuria 40 mg / dl in 3 cases, and in milk was revealed a ketolactia of 1 mg / dl, only in 2 cases. These values confirm the existence of subclinical ketosis. Ketone bodies have elimination threshold impairment which makes even physiological concentrations of ketones in the blood to be detected in urine. Unlike urine, in milk ketone bodies get harder, some of them being used in their mammar gland metabolism for lipid biosynthesis in milk. Only when the serum concentration of ketonemia exceeds a certain threshold they appear in the milk making ketolactia to be a more precisely test in the diagnosis of subclinical ketosis.From Table 1 it appears that cows in group M had mean glucose values of 58.5 ± 4.2 mg / dL. Lipemia

Cows in **group B** were fed with hypoenergetic feed rations consisting of the same feed sorts used in the feeding of cows in group M, but that was mostly corn silage.

The forage food ration used in the cows in group B is presented in Table 2.

Table 1.

The results of the laboratory determinations in the four groups of cows

Determined parameter		Glucose	Lipemia	B-hydroxy-butyrate	Alkaline reserve	Ketonuria	Ketolactia
Measurement unit		mg/dl	mg/dl	mg/dl	mEq/L	mg/dl	mg/dl
Reference values		62,0±12,0	300,0±150,0	sub 14,4	24,5±2,5	0-15	0-0,5
Group M (average values)		58,5±4,2	332,0±21,0	5,7±1,8	25,0±0,5	sub 15	sub 0,5
Group A	1	52,4	443,0	5,3	26,0	0	0
	2	39,8	586,0	14,8	22,0	40	0,5
	3	58,9	390,0	6,2	23,5	0	0
	4	64,3	375,0	5,6	23,5	0	0
	5	50,0	450,0	7,3	23,0	15	0
	6	56,2	422,0	6,0	24,0	0	0
	7	42,6	524,0	11,6	22,5	15	0,5
	8	36,7	614,0	16,7	21,5	40	1,0
	9	38,8	573,0	15,0	22,0	40	1,0
	10	61,5	402,0	5,5	25,5	0	0
	S±Sx	**50,1±3,1**	**477,9±28,1**	**8,4±1,4**	**23,0±0,5**	**3+**	**2±**
Group B	1	48,7	466,0	8,4	24,0	15	0
	2	44,6	454,0	11,9	22,5	15	0,5
	3	52,4	411,0	6,8	23,0	0	0
	4	56,2	388,0	7,1	24,5	0	0
	5	38,6	617,0	17,2	21,5	40	1,0
	6	54,8	485,0	7,4	22,5	15	0
	7	36,5	598,0	16,1	21,5	40	1,0
	8	44,7	426,0	9,2	22,0	15	0,5

	9	53,2	390,0	8,6	23,5	0	0
	10	45,9	464,0	10,4	22,0	15	0
	S±Sx	**47,5±2,1**	**469,9±25,1**	**10,3±1,1**	**22,4±0,5**	**2+**	**2±**
GroupC	1	55,6	465,0	6,7	23,5	15	0
	2	62,3	356,0	5,9	24,5	0	0
	3	66,1	439,0	4,4	25,0	0	0
	4	52,4	461,0	6,2	24,5	0	0
	5	48,5	482,0	7,8	23,5	15	0
	6	56,7	383,0	6,8	23,0	0	0
	7	42,6	504,0	10,8	22,0	15	0,5
	8	59,0	440,0	5,3	24,5	0	0
	9	44,1	494,0	11,0	22,5	15	0
	10	60,0	378,0	4,7	25,0	0	0
	S±Sx	**54,7±2,3**	**440,2±16,3**	**6,9±0,7**	**23,8±0,3**	**-**	**-**

Table 2.

The fodder ration of the dairy cows from group B

Chemical composition and NV/kg fodder (date din literatura de specialitate)					Fodder	Quantity (kg)	Food need/600 kg cow					
							18-21	**14,3**	**1560,0**	**116,0/67,0**	**76,0**	**650,0**
DS (%)	UN	PBD (g)	Ca/P (g)	Carotene			SU (kg)	UN	PBD (g)	Ca/P (g)	Salt (g)	Carotene (mg)
30	0,3	12,0	1,3/0,6	4,0	Corn silage	18	5,4	5,4	216,0	23,4/10,8	-	72,0
85	0,6	130,0	12,3/1,9	35,0	Alfalfa hay	4	3,4	2,4	520,0	49,2/7,6	-	140,0
85	0,6	60,0	12,3/1,9	35,0	Hay grass	4	3,4	2,4	240,0	49,2/7,6	-	140,0
85	0,4	22,0	6,2/2,3	-	Corn cobs	3	2,5	1,2	66,0	18,6/6,9	-	-
85	1,2	60,0	0,2/2,3	2,0	Maize	0,5	0,4	0,6	30,0	0,1/1,1	-	1,0
85	0,8	120,0	1,3/9,9	-	Grain bran	0,5	0,4	0,4	60,0	0,6/4,9	-	-
					Salt						Lumps	-
					Total	**30,0**	**15,5**	**12,4**	**1132**	**141,1/38,9**	**-**	**353,0**

From Table 2 appears that forage ration provided only 12.4 UN from 14.3 dry substance requirements and ration energy concentration was 0.80 (12.4 UN 15.5 kg dry substance). These data shows that forage ration was hypoenergetic.
In addition it appears that most of the ration consists of corn silage. These silos can grow by fermentation a large amount of butyric acid, and more than 50-100 g / day may lead to the development of subclinical ketosis.
From Table 1, it appears that in the cows in group B, blood sugar had averaged 47.5 ± 2.1 mg / dl and lipemia had averages of 469.9 ± 25.1 mg / dL. These values are at the lower average reference values for blood glucose and the higher average reference values for serum lipids are similar to those obtained from cows belonging to group A. This implies the existence at the metabolic level of an energy deficit such as alimentary origin achieved by feeding with rations that have small amount of soluble carbohydrates. Lack of glucose precursors makes that gluconeogenesis is inefficient. This will be used to store fat, as confirmed by small amount of glucose and high lipemia.
The lack of nutrient intake by dietary failure to ensure balanced, sufficient and qualitative rations, in particular by using a small amount of soluble carbohydrate is a causal factor of ketosis. The mean serum β-hydroxybutyrate was 10.3 ± 1.1 mg / dL. This value was within the limit of the average reference values, but in the individual determinations were two cows with β-hydroxybutyrate values above 14.4 mg / dL. This confirms the existence of subclinical ketosis. Urine examination was positive in 2 cases with a ketonuria of 40 mg / dL. In the determination of milk ketone bodies these cases reacted weakly positive, with a ketolactia of 1 mg / dl. Alkaline reserve has averaged 22.4 ± 0.5 mEq / L value at the lower end of the reference average thus not being metabolic acidosis.
Cows in **group C**, maintained in inadequate microclimate conditions with low ambient temperatures especially at night, had average blood glucose values of 54.7 ± 2.3 mg / dL. Lipids average values were 440.2 ± 16.3 mg / dL. These values express a balance of energy metabolism.
In determining of ketolactia and ketonuria all cows belonging to group C reacted negatively.
These values indicate that low temperatures may not cause an energy deficit without the combination of other factors that lead at a metabolic level to hypoglycemia, hyperlipidemia and hiperketonemia. This is confirmed by β-hydroxybutyrate mean serum values , respectively 6.9 ± 0.7 mg / dL, without registering individual values of over 14.4 mg / dL. And alkaline reserve has averaged mean values falling within the reference, respectively 23.8 ± 0.3 mEq / L.

CONCLUSIONS

1. Cows in group M, with average milk production of 20 liters / day, maintained in a chained system, permanent calves and fed with balanced energy rations had average values of glucose, lipids, serum β-hydroxybutyrate and alkaline reserve within the reference. This implies a balance in energy metabolism characteristic to body health. Tests for ketolactiea and ketonuria were negative.
2. Mean blood glucose, lipids, serum β-hydroxybutyrate and alkaline reserve in cows with high milk production of over 30 liters / day (group A) were within the reference average values. Individual determinations led to the diagnosis of subclinical ketosis, characterized by β-hydroxybutyrate values above 14.4 mg / dl in three cows in this batch. Ketonuria determination was positive in three cases and ketolactia was only weakly positive in two cases.
3. Mean blood glucose, lipids, serum β-hydroxybutyrate and alkaline reserve in cows fed with hypoenergetic rations and silage excess (group B) were within reference. Individual

determinations revealed in 2 cases that β-hydroxybutyrate values were specific to subclinical ketosis. Ketonuria was positive and ketolactia weak positive in two cows belonging to this group.

4. Average and individual glucose, lipids, β-hydroxybutyrate and alkaline reserve values in cows in low outdoor temperatures at night (group C) were within the reference average values. Ketonuria and ketolactia in these cows were negative.

5. Poor diet and hypoenergetic rations or silage excess and physiological state of increased metabolic demand in cows with high milk production are common factors involved in the etiology of ketosis.

6. Low temperatures may not induce without the association of food or other physiological factors such as lactation, an energy shortage which leads to the development of ketonemia.

7. In the laboratory diagnosis of ketosis ketolactia has greater diagnostic value than ketonuria.

BIBLIOGRAPHY

1. AL–RAWASHDEH O. F., 1999, Prevalence of ketonemia and associations with herd size, lactation stage, parity, and postparturient diseases in Jordanian dairy cattle. Rev. Vet. Med., vol. 31, pag. 117–125.
2. AMARAL D. M., J. J. VEENHUIZEN, J. K. DRACKLEY, M. H. COOLEY, A. D. MCGILLIARD, J. W. YOUNG, 1990, Metabolism of propionate, glucose, and carbon dioxide as affected by exogenous glucose in dairy cows at energy equilibrium, J. Dairy Sci., vol. 73, pag. 1244.
3. ANANTWAR L. G., BHOOP SINGH, 1994, Epidemiology, clinical patology and treatment of clinical ketosis in buffaloes, Indian vet. J.,vol 70 (2), pag. 152-156.
4. BOGHIAN V., 2006, Post-partum ketonemia determined by beta-hydroxybutyrate on Holstein Frize dairy cows, Lucr. Şt. USAMV Iaşi, vol. 49 (8), p. 241-245, ISSN 1454-7406.
5. BOGHIAN V., Solcan Gh., Solcan Carmen, 2007, The use of ultrasonography and histology exam to confirm the diagnosis of clinical ketosis in dairy cows, Congresul central european de buiatrie Gura Humorului, Suceava, Romania, 5-8 iunie, Rev. Rom. Med. Vet., vol. 17, nr. 2, pag. 414-418, cod. 239 B, ISSN 1220-3173.
6. DUFFIELD T. F., D. F. KELTON, K. E. LESLIE, 1995, An epidemiological survey of subclinical ketosis in Ontario dairy cattle, J. Dairy Sci., vol. 78(Suppl. 1), pag. 168.(Abstr.).
7. ENEMARK J. M., JORGENSEN R. J., 2001, Subclinical rumen acidosis as a cause of reduced appetite in newly calved dairy cows in Denmark: results of a poll among Danish dairy practitioners, Vet. Q., vol. 23 (4), pag. 206-210.
8. GEISHAUSER T., K. LESLIE, T. DUFFIELD, et al., 1997, Evaluation of aspartate aminotransferase activity and β-hydroxybutyrate concentration in blood as tests for left displaced abomasum in dairy cows, Am. J. Vet. Res., vol. 58, pag. 1216.
9. GUSTAFSSON A. H., L. ANDERSSON, U. EMANUELSON, 1995, Influence of feeding management, concentrate intake and energy intake on the risk of hyperketonaemia in Swedish dairy herds, Prev. Vet. Med., vol. 22, pag. 237–248.
10. HIBBITT K. G., NEILL D., RADFORD P., 1969, The effect of diet on the incidence of induced ketosis in the lactating dairy cow, Res. Vet. Sci., vol. 10, pag. 245-253.
11. KAUPPINEN K., 1983, Prevalence of bovine ketosis in relation to number and stage of lactation. Acta Vet. Scand., vol. 24, pag. 359–361.
12. OETZEL G. R., 1998, Dairy: Nutrition Management. Nutritional management of dry dairy cows, Comp Cont Ed. March, Food Animal 391.
13. REIST M., ERDIN D. K., VON EUW D., TSCHUMPERLIN K. M., LEUENBERGER H., HAMMON H. M., KUNZI N., BLUM J. W., 2003, Use of threshold serum and milk ketone concentrations to identify risk for ketosis and endometritis in high-yielding dairy cows, Am. J. Vet. Res., vol. 64 (2), pag. 188-194.
14. WHITAKER D. A., E. J. SMITH, G. O. DA ROSA, J. M. KELLY, 1993, Some effects of nutrition and management on the fertility of dairy cattle, Vet. Rec., vol. 133, pag. 61–64.

CORRELATION BETWEEN MORPHOPATHOLOGICAL EXAM AND EVOLUTIVE STAGE IN NATURAL INFECTION WITH EQUINE INFECTIOUS ANEMIA VIRUS

P. BOLFĂ , C. CĂTOI, M. TAULESCU, A. GAL, Cosmina CUC, R. MOUSSA, F. TĂBĂRAN, A. NAGY , G. BORZA , C. MUREŞAN , Marina SPÎNU

USAMV Cluj-Napoca, Faculty of Veterinary Medicine.

ABSTRACT

The aim of the present study was to correlate the evolutive stages of equine infectious anemia virus (EIAV) infection with the pathological and haematological changes in horses. EIAV is a lentivirus, with tropism for monocyte-macrophage cells, infecting equids worldwide. The biological material was represented by 19 EIAV positive horses (diagnosed at different time points with the reference AGID test) both males and females, with ages between 4 and 17 years, from Bistrița-Năsăud county. The animals were euthanized in May 2009. Blood samples on EDTA were collected and the necropsy examination took place at Protan Dej, where the animals were incinerated. Hematologic exams included: total leukocytes count, complete blood count and hemoglobin quantification. The biological samples (spleen, kidney and liver tissue) inserted into fixative agent (10% formalin, pH=7) were transported to the Pathology Department, Faculty of Veterinary Medicine, Cluj-Napoca. Histopathologycal examination of the samples was performed using an Olympus BX 41 optical microscope and the obtained images were processed using the CellB software. Most of the horses presented the following gross lesions: spleen hypertrophy with enlarged splenic follicles, liver hypertrophy, yellowish discoloration of the organ, chronic congestion and hepatic fibrosis. The microscopical findings from the EIAV infected equides, were represented by: focal mononuclear cell infiltrate in the liver (Kiernan space, porto-biliary space) composed mainly of lymphocytes and plama cells, Kupfer cell proliferation macrophages; fibrous tissue proliferation around the centrolobular vein and the porto-biliar spaces, forming fibrous bridges; accumulation of siderotic macrophages both in liver (Disse space) and spleen (perifolicular sinuses); membranoproliferative glomerulonephritis and interstitial nephritis. The hematological exam revealed values within the normal range regarding total leukocytes, blood count and hemoglobin. The results obtained by both pathological and hematological exam leads us to the conclusion that at the time point of the examination all investigated horses were in the chronic or asymptomatic evolutive stage of equine infectious anemia.

Keywords: horse, EIAV,evolutive stage, histopathological exam

Equine infectious anemia virus (EIAV) is a member of the Lentivirinae subfamily of retroviruses infecting equids worldwide. The likely vectors are the stable fly (*Stomoxys calcitrans*), horse flies (*Tabanus spp*.), and *Anopheles* mosquitoes (Jubb et al., 2007). Infection is lifelong and viremia is cyclic, resulting in a clinical course varying from asymptomatic to

acutely fatal and which resembles the idiopathic hemolytic anemias of dogs. The virus infects cells of the monocyte-macrophage system but, in acute viremic states, unintegrated viral DNA is present at levels two orders of magnitude higher in liver than in leukocytes and at lower levels in nodes, marrow, spleen and kidney (Bolfă, 2006; Jubb et al., 2007).
The relationship between the cyclic viremia, viral antigenic variation and the immune response is complex. Neutralizing antibody towards the principal antigen proteins is not detected before 2 months of infection. Subsequently, there is rapid variation in the glycoprotein envelope antigens that indicates that the preparation of an effective vaccine will be difficult as for the other Retroviridae (Jubb et al., 2007). The virus shares structural and sequence similarities with human immunodeficiency virus and simian inununodeficiency virus, and functional similarities with visna virus (Bolfă 2010). It has been suggested that the EIAV has little direct effect on tissues and that the pathogenesis of disease involves the indirect effects of the immune response. All signs of disease correspond to the appearance of circulating antibody, which is complement-fixing but not initially virus-neutralizing. C3 appears on erythrocyte membranes, and this probably accounts for macrophage recognition and erythrophagocytosis (Jubb et al., 2007). The clinical disease is arbitrarily divided into acute, chronic and asymptomatic forms, but death in the protracted cases results from acute exacerbation, so the signs are relatively constant (Leroux et al., 2007). In the acute stage of EIAV infection, anemia is severe and sufficient to cause death, and is accompanied by consistent thombocytopenia during febrile periods, with resulting petechiae. In the early stages of disease, there is anisocytosis, marked for the horse, with moderate poikilocytosis and, characteristically for the horse, no polychromatic red cells. In the early stage of an acute attack, there is macrocytosis whereas at a later timepoint, the anemia is normochromic, normocytic and nonresponsive. There is accompanying leukopenia with neutropenia, minimal left shift, lymphopenia and at least a relative monocytosis (Jubb et al., 2007).

OBJECTIVES

In the present study we aimed to investigate the histopathological changes in EIAV natural infection, from various organs, such as liver, spleen, lung and kidney. Our research also focused on the paraclinical changes that occur in the blood of EIAV infected horses. Finaly, the present study aimed to correlate the evolutive stages of EIAV infection with the pathological and haematological changes in horses.

MATERIALS AND METHODS

The biological material was represented by 19 EIAV positive horses (diagnosed at different time points with the reference AGID test) both males and females, with ages between 4 and 17 years, from Bistriţa-Năsăud county. The animals were euthanized in May 2009. Blood samples on EDTA were collected and the necropsy examination took place at Protan Dej, where the animals were incinerated. Hematologic exams included: total leukocytes count, complete blood count and hemoglobin quantification. The biological samples (spleen, kidney and liver tissue) inserted into fixative agent (10% formalin, pH=7) were transported to the Pathology Department, Faculty of Veterinary Medicine, Cluj-Napoca. For the histological examination, we used standard Hematoxilin-Eosin (HE) and Tricrom Masson (TM) stain. Histopathologycal examination and processing of the samples was achieved using an Olympus BX51 microscope and the image processing software Olympus Cell B from the Pathology Department of the Faculty of Veterinary Medicine Cluj-Napoca.

RESULTS AND DISCUSSIONS

Necropsy exam.

Following gross examination of the EIAV positive horses, the following changes were noted. Most of the animals were subicteric. In a few horses the spleen was enlarged, turgid and fleshy with capsular hemorrhages, with inapparent lymphoid follicles. In the majority of the equines, the liver was enlarged, dark and turgid with a fine lobular pattern and focal capsular hemorrhages. Petechial hemorrhages were noticed on some renal capsules and in the perirenal tissues. On cut surface, there were multiple fine hemorrhages throughout the cortex and medulla. Haemorhages were noticed on the surface of the lungs in some cases.

Histopathological examination.

Microscopic lesions occurred in all investigated tissues, but were most prominent in the liver, spleen and kidney. The liver presented a spectrum of changes which varied from mild periportal lymphocytic infiltrates to atrophic cords with sinusoidal dilation, Kupffer cell hyperplasia, broad loosely arranged periportal lymphoid infiltrates (picture 1B), and increased interstitial connective tissue. This fibrous tissue was organized in some cases in portal bridges (picture 1A).Hemosiderosis in Kupffer cells was also noted in some cases, which is a representative lesion for EIA (Baba et al., 1987; Cătoi et al., 2003). Generalized endothelial prominence, along with sinusoidal Kupffer cells and infiltrates composed of monocytes and plasma cells, gaved an overall picture of hypercellularity. Periacinar (centrolobular) fatty vacuolation of hepatocytes (picture 1B) was noticed in one case In some animals, probably in the asymptomatic stage of evolution, hepatocytes appeared normal and lymphoplasmacytic infiltrates subsided; sinusoidal hemosiderin-bearing macrophages (picture 1C) remained as evidence of previous hemolysis. Splenic follicles presented variable degrees of enlargement (picture 1F) but hypocellular, often with a sharp transition to congestion in the surrounding sinusoids. Hemosiderosis with macrophages and plasma cell proliferation was significant. The number of siderophages was increased. Renal lesions were represented by membranoproliferative glomerulonephritis (picture 1D), with reduction of urinary space and sometimes with atrophy of the vascular structure. In the interstitium, we noticed infiltrates composed of small lymphocytes, plasma cells and histiocytes, of different intensities, which separate tubules in an irregular manner. There was some degree of epithelial atrophy as well as severe interstitial fibrosis (picture 1E) in some cases. Connective tissue proliferation in the interstitium was significant in two cases. The large majority of histopathological changes, plead for the chronic and asymptomatic form of EIAV infection

Paraclinical exam in EIAV infected equids.

Analyzing the leukocyte chart, we observed that there is no large variation of the mononuclear or polymorphonuclear cells in the blood of the investigated horses. Similar to the other values obtained in the paraclinical examination, in the case of haemoglobin, the variations that occurred were not significant in the investigated animals, compared to the reference values. The average of the obtained results and standard deviations, are illustrated in table 1, together with the normal values.

In the case of the total leukocytes, in one horse the value was above normal and in another one a lower value appeared, compared to reference values. Nevertheless, we cannot speak about a leukocytosis (values greater than $15x10^3$/ $mm^{3)}$, or a leukopenia (values below $4x10^3/mm^{3)}$. The values of the white line's cells are within the normal range, except for

basophils, which are slightly elevated which may suggest some white cell proliferation, characteristic for EIAV infection.

Table 1

Mean value of blood leucocyte cells (normal range after Ghergariu et al., 2000)

Haematological exam	EIAV infected horses	Normal range
Total leucocytes $10^3/mm^3$	8.25	**5.5 – 12**
Monocytes (%)	2.4	**0.5 – 7**
Eosinophils (%)	3.9	**0.5 – 11**
Limphocytes (%)	43.3	**25 – 70**
Basophils (%)	4.6	**0 – 3**
Neutrophils (%)	45.8	**30 – 67**
Hemoglobin (g/dl)	11.9	**8 - 14**

Haemoglobin levels are directly proportional to those of red cells, and fall within the normal range. The explanation for this may be asymptomatic stage of EIA evolution, at the time of sampling; none of the investigated horses presented any clinical signs of disease at that timepoint. A single haematological examination, however, is insufficient for a paraclinical diagnosis; repeated exams are needed, consistently with hyperthermia, as between the febrile episodes, haematological parameters may return to normal (Moga-Manzat, 2005).

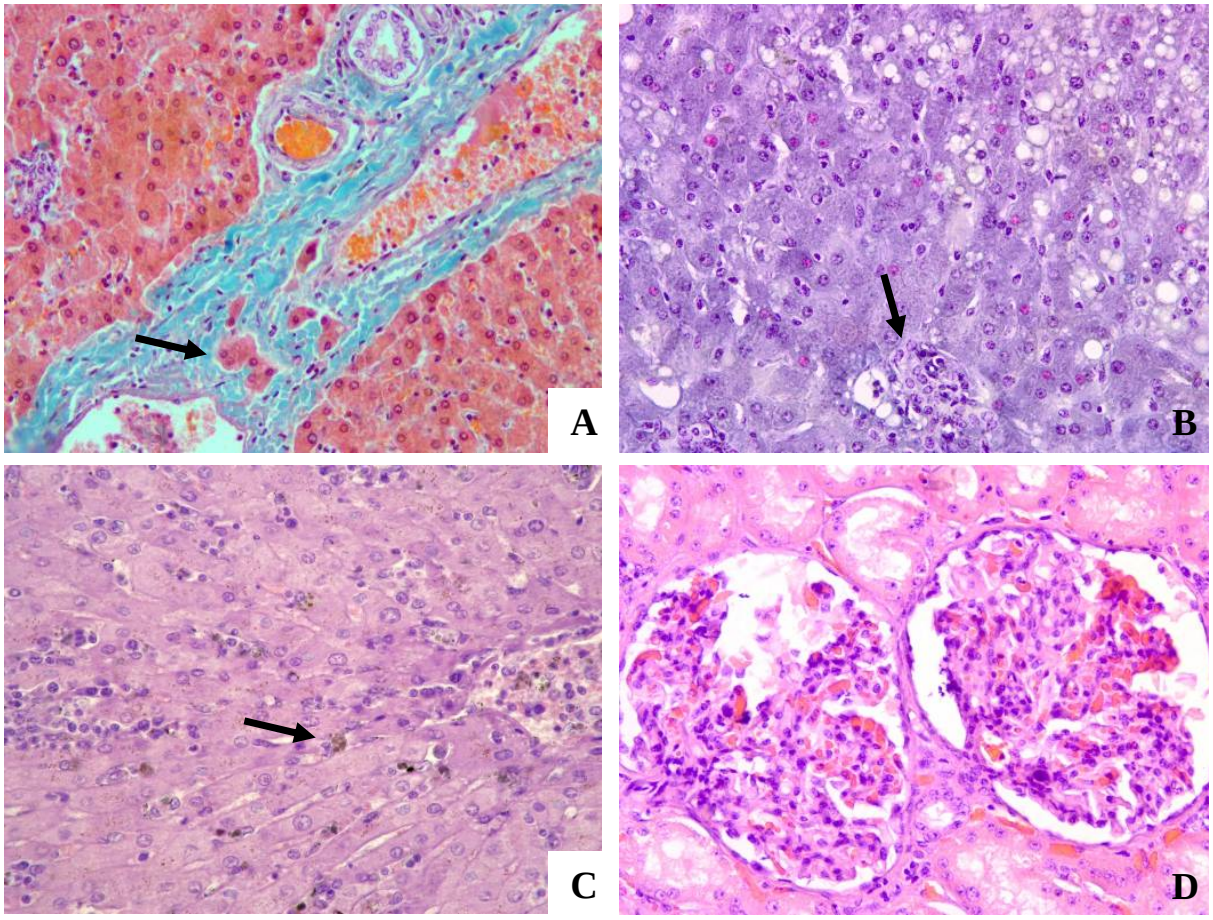

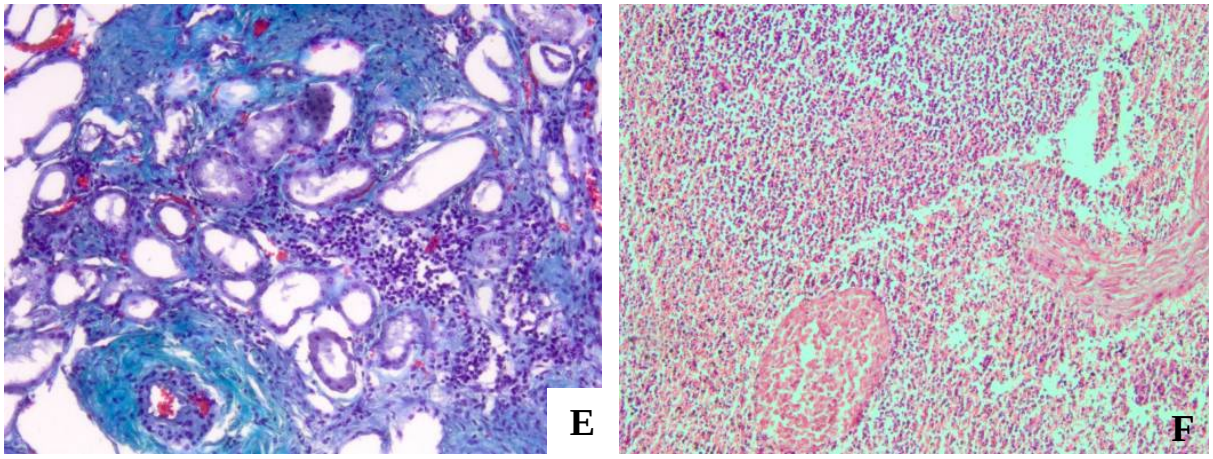

Picture 1: A – Liver: Periportal fibrosis due to chronic congestion; sequestered hepatocytes (arrow), dilation of sinusoids capillaries *(TMx200)*; **B –** Liver: Periacinar (or centrolobular) steatosis, hepatocytes undergoing necrosis, proliferation in nests (arrow) of monocytes and plasma cells *(TMx200)*; **C –** Liver: Increased quantity of hemosiderin in Kupfer cells (arrow) and hepatocytes; nest of mononuclear cells on the path of sinusoid capillaries *(HEx400)*; **D** – Kidney: Membranoprolipherative glomerulonephritis (thickened basement membrane accompanied by cellular proliferation) *(HEx200)*; **E** – Kidney: Interstitial fibrosis associated with interstitial proliferation of mononuclear cells (mainly plasma cells, small lymphocytes and histiocytes), tubular necrosis consecutive to compression atrophy*(TMx100)*; **F –** Spleen: Enlargement of splenic follicles, splenic congestion *(HEx100).*

The EIAV infected animal may die from the acute or chronic disease, but in many cases these signs are relatively mild and may be overlooked. The acute episode usually subsides within a few days, and then the animal enters the chronic stage of disease characterized by the recurrence of clinical cycles. If clinical episodes are frequent, the animal may develop classic clinical disease associating anemia, weight loss and oedema (Issel and Coggins, 1979). In practice, the course of disease may be clearly distinct in animals infected with the same strain of EIAV (Cook et al., 2003; Hammod et al., 2000; Leroux et al., 2001). Our study confirms that most of the animals infected at a certain time point by an *in vivo* viral strain are either in the asymptomatic or chronic stage of infection. None of the horses investigated showed clinical nor haematological or histopathological changes characteristic for EIAV acute stage of disease. Although seemingly these horses appear not to be a threat, they represent a lifelong “virus reservoir” for healthy animals in the area. So, it is very important to eliminate or to isolate these innaparent carriers from the areas with important equid population.

CONCLUSIONS

1. Changes in haematological parameters in EIA are associated with febrile episodes, and lack of circulating virus or fever at the time of sampling, confirms the antigenic "quiescence" period.
2. Histopathological exam proved that at the time point of the examination all investigated horses were in the chronic or asymptomatic evolutive stage of EIA.
3. Innaparent carriers of EIAV pose a potential threat for transmission of the disease to healthy horses, although clinical signs may lack.

REFERENCES

1. Baba A.I., Rotaru O., Răpuntean Gh., Cârstean C., Botez Gh., Gaboreanu M., Diagnosticul morfopatologic corelat cu examenul serologic în anemia infecțioasă ecvină, Buletin IACN ZMV, (1987), 41.
2. Bolfă P., Andrei Sanda, Şandru Carmen Dana, Spînu Marina, Tănase G., Immunological changes correlated with oxidative stress in equine infectious anemia. Buletinul USAMV-CN, Seria Medicină Veterinară, (2006) 63:452.
3. Bolfă P., Corelarea modificărilor imunologice cu stresul oxidativ în anemia infecțioasă ecvină, Teză de doctorat, Cluj-Napoca, (2010), 1-7.
4. Cătoi C., Diagnostic necropsic veterinar, Editura AcademicPres, Cluj Napoca (2003), 181.
5. Cook R.F., Cook S.J., Berger S.L., Leroux C., Ghabrial N.N., Gantz M., Bolin P.S., Mousel M.R., Montelaro R.C., Issel C.J., Enhancement of equine infectious anemia virus virulence by identification and removal of suboptimal nucleotides, Virology 313 (2003) 588–603.
6. Ghergariu, S., Pop Al., Kadar L., Spînu M., Manual de laborator clinic veterinar, Ed. All Educational, Bucureşti (2000), 110, 116.
7. Hammond S.A., Li F., McKeon B.M.S., Cook S.J., Issel C.J., Montelaro R.C., Immune responses and viral replication in long-term inapparent carrier ponies inoculated with equine infectious anemia virus, J. Virol. 74 (2000) 5968–5981.
8. Issel C.J., Coggins L., Equine infectious anemia: current knowledge, J. Am. Vet. Med. Assoc. 174 (1979) 727–733.
9. Jubb K., Kennedy P., Palmer N., Pathology of Domestic Animals, Publisher: Saunders Ltd., 5th edition, (2007) III:235-239.
10. Leroux C., Craigo J.K., Issel C.J., Montelaro R.C., Equine infectious anemia virus genomic evolution in progressor and nonprogressor ponies, J. Virol. 75 (2001) 4570–4583.
11. Leroux Caroline., Cadore J.L., Montelaro R.C., Equine infectious anemia virus (EIAV): what has HIV's country cousin got to tell us?, Vet. Res. (2004) 35:485-512.
12. Moga Mânzat R., Boli virotice şi prionice la animale, Ed. Brumar, Timişoara (2005), 605-610.

USING NUTRITIONAL-METABOLIC PROFILE AS A TOOL FOR PROGNOSIS GROUP OF DAIRY COWS IN FARM

S.I. BORŞ, L. RUNCEANU, Gh. SOLCAN, D. DRUGOCIU, P. ROŞCA, R.Mălăncuş*
Faculty of Veterinary Medicine, Iasi
bors.ionut@yahoo.com

Variations in the components of blood chemistry could be indicative of metabolic or nutritional imbalances in dairy cattle. Production disorders, as lactation ketosis or imbalances in nitrogen metabolism could be detected through the profile analysis. Metabolic imbalances are frequent in dairy cows of high production, usually as a consequence of feeding problems. Metabolic profiles could identify potential problems before they can be expressed as production losses or health and fertility disorders.
This study was conducted on a farm from North-East of Romania with NBR (Romanian Black Spotted) dairy cows.
Nutritional-biochemical assessment profile was made using a INRA program to check the food, concomitant with that we made the biochemical profile from a 25 cows randomly selected from the farm.
Existence of an optimal age to use of a cattle for breeding, but also large amounts calving interval on multiparous cows criminalize a milk production as the main cause for the changing of breeding parameters and the nutritional imbalances as a secondary cause.
Nutritional profile also revealed the existence of a decreased energy-protein intake and a low energy density of the ration.
Higher values of liver enzymes, hyperglobulinemia, hypercalcemia, hypoglycemia and hypophosphoremia, accompanied by an input energy - low protein in the diet coincided with higher media values of calving interval in cows at first, but especially the second and third lactation which reinforce the existence of a negative influence of the large milk production and improper food on breeding activity.
The idea that glucose concentration can be diminished in the blood of high milk yield cows, is reasserted by this study. In lactating cows it is common to observe liver injuries as a consequence of massive lipid mobilization, especially in high producing cows. In the present work, a higher level of AST was found in more productive cows, suggesting liver injuries.
Collectively, the findings of the present study suggest that cows with poorer reproductive performance showed a metabolic profile compatible with a restricted energy and protein diet, which is leading to a moderate hepatic lesion, and to an impaired fertility.

Key words: cows, nutritional profile, biochemical profile, calving interval

Late recovery of ovarian activity represents one of the main reproduction activity deficiency in dairy cows. Thus, we noticed an augmentation in the interval between calving and the next artificial insemination, service period and calving interval when the ovarian activity is impaired.

*Researches finnanced from grant PN II 51-004/2007 by Natoinal Center for Programs Management

The efficiency of reproduction activity is certified by some authors from the point of view of factors that inflluence it, like high protein (Jordan and Swandson, 1979), genetic selection of reproductive potential (MacMillan and col., 1996), milk production (Laben and col., 1982, Lean and col., 1989), energy balance (Haresign and col., 1981), number of heat cycles, progesteron quantity during heat cycle that proceeds insemination (Fonseca and col., 1983).

Deviation from normal of reproductive parametres determines a decrease in economic efficiency in dairy cows, low birth rate and slowing of the genetic amelioration in order to increase population number.

MATERIAL AND METHOD

Research has been performed on a dairy cow farm in the North East of Romania. The working matherial has been represented by local Black and White Spotted cows, with a total of 300 animals.
The exploiting system is that of permanent calving, with the cows being binded by the Grabner model, head to head. The stands are classical, concrete, of medium size, with sawdust on the floor.
The feed is the result of exploiting the vegetation from the farm. Almost all the feeding necessary is covered with these activities. Research has been conducted on a 24 clinically healthy , randomly chosen cows from the queen-nucleus, weighting 500-550 kg.
The daily feeding ratio has been chosen depending on the cows physiological needs (lactation, pregnancy, mammary rest), milk production.
The females have been maintained in the same conditions as the queen-nucleus, being separated of the herd only in the days of blood drawing.
Blood has been taken on special vacuum tubes, with a clotting activator factor. Cows have beeb splitted into 2 groups of 12 animals, and biochemical profiles have been made 14 days apart.
Blood samples, taken on special clotting activator factor, have been centrifuged 15 minutes at 3.000 rotations/minute, for a clear serum appearance. Serum has been stored in lid-Eppendorf tubes at 4ºC until biochemical determinations have been performed on Automat ACCENT 200 apparatus.
Reproductive indexes have been calculated in concordance with the gynecological charts existent in the farm.
Nutritional profile has beeb made by determining the nutritional values of each component from the daily ration, data later quantified using a INRA authorised verification programme.

RESULTS AND DISSCUSIONS

In order to evaluate the nutritional and metabolic farm profile, we procedeed to food analysis, data later quantified using a INRA authorised verification programme.
A nutritional control is hard to make, because the cows are freeely fed, causing high ecomonical loss by intake incapacity of nutrtional principles.
By data analysis we later observed the following. Dry substance for a lactating cow and for one day fits in a total of 21.88 kg.
From this total, 17.24 LFU (lactating feeding units) are ensured, which classes the ratio over the energetic available optimal level, but 0.79 LFU/volume unit are ensured, value situated

under the INRA accepted limit. All these values provide a 106% coverance and a 27 litres of milk/day.

Starch barely passes the lowest limit, while cellulose is at the opposite pole, overcoming the maximum level.

PDIN and PDIE are between the lowest and the highest values, slightly towards the minimum, having values of 1555 g and, respectively, 1584 g, ensuring, for a 23-24 milk litres/day, a 95-96% coverance. But IDP (intestinal digestible proteine) had a 71g/kg concentration, putting NIDP/kg and EIDP/kg, with values of 71 g/kg dry substance and 72 g/kg dry substance total nitrate material, under the accepted minimum limit of 95 kg/kg dry substance (**tabel no. 1**).

In case of mineral intake, calcium largely overcomes the maximum level, whereas phosphorus is under the minimum level.

Table no. 1

Feeding ration for 600 kg cows, of 25 litres milk /day, with 4% fat

Ratio	Kg/zi	DS Kg	LFU	IDPN (g)	IDPE (g)	P (g)	Pabs	Ca (g)	Cell	Starch
Lucerne	25,2	4,4	0,77	123	86	2,6	1,9	16,1	299	0
Meadow	54,4	11,9	0,69	56	64	1,8	1,2	9	313	0
Silage	10	3,5	0,96	50	71	2	1,6	2	165	350
Maize	1,5	1,3	1,05	64	84	2,6	1,8	0,4	22	641
Wheat bran	0,8	0,7	0,82	94	79	9,9	7,1	1,4	91	198
Ca carbonate	0,02	0,02						400		
Total	91,7	21	17,2	1555	1584	51	37,1	194	5745	2345

Where: DS– dry substance; LFU – Lactating feeding units; IDPN – intestinal digestible protein + intestinal digestible protein of microbian origin, which can be produced from available nitrogen; IDPE – intestinal digestible protein + intestinal digestible protein of microbian origin which can be produced, based on the available energy; Ca – calcium; P –phosphorus.

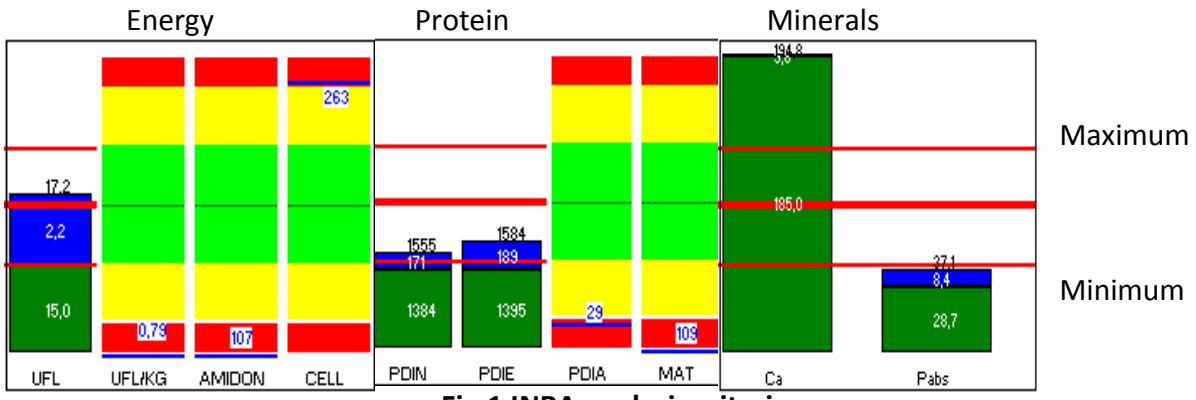

Fig.1 INRA analysis criteria

We can conclude that the feeding ratio given to the cows has a satisfying energy-protein contribution, a hypercalcemic and hypophophoremic intake, and a low energy density (**fig. 1**).

In order to follow the involvement of the feeding ratio in the reproductive activity of dairy cows, we made a metabolic profile by determining the metabolic indices that are considered to be most important for reproduction, but also representative for nutritional deficiences in this farm. We randomly chose, from each stable, 24 female cows, splitted in two groups, from which we draw blood and made biochemical analysis.

Table no. 2

BIOCHEMICAL PROFILE

Nr. crt.	Biochemical Investigated Parametres	UM	Average	Minimum	Maximum	Standard deviation	Refference values
1.	ALT	UI/L	60,51	9,1	312,2	92,6	6,9 – 35
2.	AST	UI/L	196,33	70,6	562,7	137,3	45 – 110
3.	Glucose	Mg/dl	48,67	23	74,48	20,09	42 – 75
4.	Triglycerides	g/l	13,05	5,9	35,7	9,4	15 - 45
5.	Total proteins	g/dl	9,7	6,5	13,3	2.34	6,2 – 8,2
6.	Albumines	g/dl	3,8	2,3	5.1	0,8	2,8 – 3,9
7.	Ca	Mg/dl	21,68	8,86	42,24	10,7	8,4 – 11
8.	P	Mg/dl	8,02	4,69	13,17	2,94	4,3 – 7,8
9.	Ca/P		2,7	1,88	3,2	-	1,5 – 2

Biochemical investigations showed high values of liver enzymes: 60.51 UI/l AST (with a maximum of 35 UI/l), 196 IU/l ALT (maximum 110 UI/l). We estimate that high levels of lipids have been used for milk production, thus increasing the values of liver enzymes. Low values of serum glucose and triglycerides show that there is a negative energy balance in the farm. Thus, when the negative energy balance has a significant increase, lipids from the liver are waisted and the export capacity decreases, with serious repercussions on serum values of triglycerides.

Low concentrations of plasma triglycerides have been noticed by Reid et all. (1983) and Gerloff et all. (1986) in cows near parturition or in those with a fat-liver syndrome.

Total proteins have also had tendencies of excessing maximum limits (9/7 g/dl, with a maximum of 8.2), and calcium (21.68, unlike 11 mg/dl) and phosphorus (8.02 unlike 7.8 mg/dl) also. Calcium/phosphorus ratio had a value of 2.7/1, limit admitted by some authors in cows with high milk productions.

High averages of total serum proteins, with a high blood cells, could be associated with inflammatory processes, like mastitis or endometritis, which usually evolve subclinically and have a negative impact on the cows reproduction status.

Table no. 3

BIOCHEMICAL PROFILE

Nr. crt.	Biochemical Investigated Parametres	UM	Average	Minimum	Maximum	Standard deviation	Refference values
1.	ALT	UI/L	23,56	16,3	30,5	4,6	6,9 – 35
2.	AST	UI/L	75,98	59,3	97,2	12,47	45 – 110
3.	Glucose	Mg/dl	50,7	30,5	82,62	10,2	42 – 75
4.	Triglycerides	g/l	20,98	9,3	37,2	8,52	15 – 45
5.	Total proteins	g/dl	8,18	6,4	9	0,7	6,2 – 8,2
6.	Albumines	g/dl	3,89	3,5	4,2	0,24	2,8 – 3,9
7.	Globulines	g/dl	4,29	2,2	5,3	0,97	3,4 – 4,3
8.	Ca	Mg/dl	21,98	10,15	34,86	10,58	8,4 – 11
9.	P	Mg/dl	6,58	4,62	8,55	0,9	4,3 – 7,8
10.	Ca/P		3,34	2,27	4,07	-	1,5 – 2

Repeating the biochemical profile on another group of females (n= 12) pointed out high levels of blood calcium, values higher than those cited by the literature. Although some biochemical parametres (total proteins, globules, albumines, glucose) had higher values in some females, they didn't have a negative influence on standard values of the refference group.
Ca/P had a value of 3,34/1, higher than the average of 2/1, although some authors accept, in high production milking cows, values of 3/1 or even 4/1. A perturbation of calcium and phosphor metabolism is seen in the refference group, for high values of calcium have been noted in the first and second group of cows. High requirements of calcium for milk production in the mammary gland can contribute to maintaining a low level of minerals in high producing milk cows. (Kerr, 1989). There are no health implications of high calcium dose ratio in milking cows. Low phophor values can cause a low appetite, low milking production and low fertility in cows, as cited by Goff, 1998. These values coincided with protein and energy deficiences in our research.
Nutritional profile has pointed out a low energy density in the ratio, this being noticed during biochemical investigations as well. So, we can conclude that there is a organic mobilization, with maintaing the glucose in physiologic limits. But this mobilization is made in detriment of cow reproduction and productive capacity.
The reproductive activity in the farm has been supervised along with determination of distribution of calving interval regarding the number of lactations and distribution of age at first parturition, according with the month of calves births (replacement group).
Distribution of calving interval (CI) according with the number of lactations revealed the following: its values were higher in cows at first, second and third lactation, compared to those at fourth and fifth, the latters showing values close to those cited by literature, standard average values accepted for their physiological and production category (**table no. 4**).

Table no. 4

Calving Interval Distribution according with the number of lactations

	1st lactation	2nd lactation	3rd lactation	4th lactation	5th lactation	Total
No.of cows	119	32	13	10	6	180
C.I. Average	448	449	448	411	379	443
Minimum	312	312	315	321	347	309
Maximum	716	778	734	615	635	696
Standard deviation	102,97	91	108.91	78	90,5	87

The existence of superior values of CI that depass those from the literature can be a solid argument in favor of low quality nutrients in the ratio, especially the energy ones, which cannot sustain the milk production in some cows.
In order to have an opinion on the farm's reproduction status, we noted the optimal moment for reproduction in cows, in accordance with the month of birth for the replacement calves, and the values are those cited by the literature. From a total of 116 cows, the average of birth of first parturition is 27 months, meaning that the optimal moment of artificial insemination is around the age of 17,5-18 months, varying with the month of birth of those calves (**fig.2**).

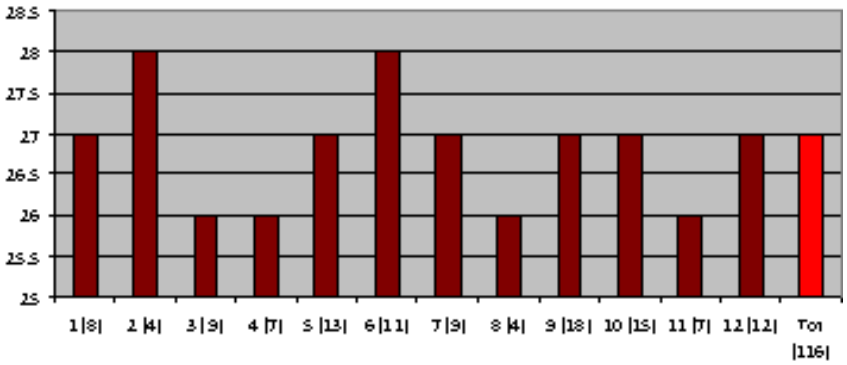

Fig.2 AGE DISTRIBUTION AT FIRST CALVING ACCORDING TO THE MONTH OF BIRTH

Thus, high milk production interferes with the reproductive status, because we noticed differences in CI values.

Liver enzymes, like AST, are used in cows for showing defficiences in liver and muscle functions. (Kaneko şi col. 1997). In cows with high milk productions we noticed liver injuries as a consequence of massive lipid mobilization, especially at 3rd and 4th lactation (Sommer, 1975). In our study, we noticed a high level of AST, probably due to the same cause. In milking cows, lipid mobilization is the answer of high energy requirements for milk production, responsable for a variable degree of liver injury (Butler şi Smith, 1989).

Our study revealed the existence of high values (maximum, average) of CI, as seen in table 4, in cows at 2nd and 3rd lactation, values seen also in some females with high numbers of AST and low numbers of glucose and serum triglycerides.

In conclusion, we can say that cows with poor reproductive status have a satisfying protein intake, but a low density energy ratio, which also determines liver injuries.

CONCLUSIONS

1. The nutritional and metabolic profile can be used as a prognostic instrument in milking cow groups.
2. Inbalance in ratios appeared along with high values of CI in cows at 1st, 2nd and 3rd lactation, periods in which productive solicitations are higher.
3. The existence of an optimal age for reproduction and high values of CI in cows with many births, incriminate milk production as the first cause of influence on reproduction parametres, nutritional imbalances being on the second place.
4. The existence of a high Ca/P fraction (>3/1), the hypercalciemiea and hypophophoremia indicate a endocrine or elimination problem, and it can have a negative influence on the reproduction activity in the farm.
5. High values of AST indicate liver injury, probably due to massive mobilization in order to sustain milk production and have a negative influence on the reproduction.
6. Low energy density in the ratio represents another cause of poor ovarian activity, with repercussions on CI values, especially in cows with a negative energy balance.

BIBLIOGRAPHY

1. **BUTLER, W.R., SMITH, R.D. 1989** – *Interrelationships between energy and post-partum reproductive function in dairy cattle.* J Dairy Sci., V. 72, P. 767 – 783.
2. **FONSECA, F. A., J. H. BRITT, B. T. MCDANIEL, J. C. WILK, AND A. H. RAKES. 1983**. *Reproductive traits of Holsteins and Jerseys. Effects of age, milk yield, and clinical abnormalities on involution of cervix and uterus, ovulation, estrous cycles, detection of estrus, conception rate, and days open*. J. Dairy Sci. 66:1128–1147.
3. **GERLOFF, B. J., T. H. HERDT, AND R. S. EMERY, 1986**: *Relationship of hepatic lipidosis to health and performance in dairy cattle.* J. Am. Vet. Med. Assoc. 8, 845–850.
4. **GOFF, J.P. 1998A** – Phosphorus deficiency . P 218 -220 in Current Veterinary Therapy 4: Food Animal Practice. J.L. Howard and R.A. Smith, Ed. Philadelphia.
5. **HARESIGN, W. 1981** - *Body condition, milk yield and reproduction*. Developments in Ruminant Nutrition, W. Haresign and D.J.A Cole, ed. Butterworths, London, United Kingdom. 1 -16.
6. **JORDAN, E. R., AND L. V. SWANSON. 1979**. - *Effect of crude protein on reproductive efficiency, serum total protein, and albumin in the high-producing dairy cow.* J. Dairy Sci. 62:58–63.
7. **KANEKO, I.J., HARVEY, J.W., BRUSS, M.L. 1997** – Clinical Biochemistry of Domestic Animals. Ed.5., San Diego: Academic Press, Inc
8. **KERR, M.G., 1989** – Veterinary Laboratory Medicine: Clinical Biochemistry and Haematology. Oxford, Blackwell Scientific Publication
9. **LABEN, R. L., R. SHANKS, P. J. BERGER, AND A. E. FREEMAN. 1982** - *Factors affecting milk yield and reproductive performance.* J. Dairy Sci. 65:1004–1015.
10. **LEAN, I. J., T. B. FARVER, H. F. TROUTT, M. L. BRUSS, J. C. GALLAND, R. L. BALDWIN, C. A. HOLMBERG, AND L. D. WEAVER. 1992**. - *Time series cross correlation analysis of postparturient relationships among serum metabolites and yield variables in Holstein cows.* J. Dairy Sci. 75:1891–1900.
11. **MAC MILLAN, K. L., I. J. LEAN, AND C. T. WESTWOOD. 1996 -** *The effects of lactation on the fertility of dairy cows*. Aust. Vet. J. 73:141–147
12. **REID, I. M., G. R. ROWLANDS, A. M. DEW, R. A. COLLINS, C. J. ROBERTS, AND R. MANSTON, 1983***: The relationship between postparturient fatty liver and blood composition in dairy cows*. J. Agric. Sci. (Camb.) 101, 473–502.
13. **SEICIU, FL., DRUGOCIU, G., BOITOR, I., 1987** – *Reproducţie normală şi patologică la animalele domestice*, vol. 1-2. Ed. Ceres, Bucureşti
14. **SOMMER, H., 1975** – Preventive Medicine in Dairy Cows. Vet. Med. Rev., V.1, P.42 – 63

RESEARCH ABOUT MORPHOLOGICAL ASPECTS WITH A BACTERIAL INFECTION ON BROILERS RAISED ON GROUND

Oana BUSUIOC
S.C. VIS AGRI S.R.L.

ABSTRACT

Mortality encountered in the S.C. VIS AGRI.S.R.L. farm was very different from one series to another, from one hall to another. Among bacterial infections, colibacillosis is the primary cause of mortality and morbidity in birds, being responsible for significant economic losses. Pathogenic avian strains of E Coli, is little time a distinct pathotype from the already known and recently is considered as potential risk agents for human health.

Key word: Bacteria infections, broilers, ground.

MATERIALS AND METODS

Research was based on 13 series of chicken with 5.631.109, watching the mortality and the bacterial flora depending on morphopathological changes. After morphopathological investigations made on organs from 728 corpses data were analyzed for diagnosis pointing.

RESULTS AND DISCUTIONS

From epidemiological investigations results that from 13 series of chicken who populated the VIS AGRI S.R.L. farm died 197000 chicken which is 3,46%. After morphopatthological investigations from that 728 corpses, were found many morphological aspects which have shown by laboratory tests, many microbial entities. It's find that the most common morphopathological changes in broilers whatever season or age are aerosaculite, pericarditis and E.coli septicemia. In vitro study of the potential virulence factors, confirm that E. coli. flu origin are not simple opportunistic bacteria but possess qualities which theoretically allows to cover all successive stages of the host invasion: adhesion through fimbriata type 1 would interfere in respiratory colonization, then the aerobactina system would allow multiplying in the organism, evasion from the host defense mechanisms owing to the surface antigens.

Table 1

Mainlesions in E. coli infections

No. corpses examined	Pathologic change	Escherichia coli															
		Conjunctivitis		Omfalititis		Vitelus neresorbit		Fibrinous pericarditis		Perihepatitis fibrinous		Aerosaculitis fibrinous		Septicemia		Enteritis	
Total		No.	%	No	%	No.	%	No.	%	No.	%	No.	%	No.	%	No..	%
728		619	85	58	8	58	8	95	13	109	15	131	18	153	21	124	17

There were pathogens strains of E. coli (APEC) identified and isolated after laboratory investigations which can be found also in living environment of birds like food plates and hall walls.

BIBLIOGRAPHY

1. **Maurer JJ, CL Hofacre, Wool RE, P. Gibbs, R. Froyman**, 2002, Avian Diseases, 46 (3), pp704-706.
2. **Nettle A., Stanica Andreea**, 2004 - Sensitivity to antibiotics of strains of E. coli, Salmonella ssp, Pseudomonas aeruginosa and Staphylococcus aureus isolated in the diagnostic center of SN "Pasteur Institute" in the year 2003, Newsletter 15 (1), pp14-18.
3. **Vasiu Constantin**, 2007 - Infectious diseases in animals, Mega, Cluj-Napoca.

THE EFFICACY OF MACROCYCLIC LACTONES AND BENZIMIDAZOLES COMBINATION IN EQUINE STRONGYLIDOSIS

Laura Cristina CERNEA[1], M. CERNEA[1], L. OGNEAN[1], V. NĂSTASA[2], Ş. RĂILEANU[3], M. MAREŞ[2], Anca CHEREJI[1] L. M. Madeira de CARVALHO[4]

1. USAMV Cluj-Napoca, Calea Mănăştur, no.3-5, 400372, Romania; 2. USAMV Iaşi, Aleea Mihail Sadoveanu no. 8, 700489, Romania; 3. INCDDD Tulcea, 165, Babadag Street, 820112 Tulcea, Romania; 4.Universidade Tecnica de Lisboa, Facultade de Medicina Veterinaria Lisbon, Portugal,

e-mail: mscernea@yahoo.com

ABSTRACT

In vitro research conducted on a number of 30 horses from CSV Abrud has the purpose of testing the combination of Ivermectin, Fenbendazole, Albendazole, Mebendazole combination, on strongyls from horses. Using in larvae development assay Ivermectin and Mebendazole reveal that these combination is more effective than the results obtained in separate testing of the two substances, thanks to the different mechanism of action of the two substances. Calculation of Y parameter (prediction equation) leads to a maximum value of -1609.64. The combination of Ivermectin and Fenbendazole, show that the risk of induction of adaptive phenomena on strongyls is much higher. The combination of Ivermectin and Albendazole highlighted a lethal concentration 50 (LC50) with the value of -0.0696 mg/ml which is higher than the values obtained by separate testing of each molecules.

Key words: equine, macrocyclic lactones, benzimidazoles, strongyls.

INTRODUCTION

Equine strongylidosis study is a world - wide highly important topic due to the serious consequences this disease can induce both by symptomatology and by decreasing physical capacity of animals [Moore, 2000; Monahan, 2000]. Strongyls presence may modify behavior, fertility, physical condition, organism development through maturity, decreases resistance to other phatogenous agents and may even become the cause of death. Due to extension and prejudices these diseases can inflict, diagnosis of parasite invasions has to be made even for those with sub-clinical evolution [Cosoroabă, 2002]. This diagnosis must be followed by exact identification of the etiological agent involved as well as its genetical, biological and ecological characteristic, and the possible resistance to specific medication, taking in to account the selection of certain antiparasitary medicine with enhanced efficacy [Adams 2001, Monahan, 2000, Madeira de Carvalho, 2001]. Current therapy is mainly based on the use of derivatives benzimidazoles and probenzimidazoles, tetrahydropyrimidines (pyrantel pamoate) and macrocyclic lactone - ivemectin, moxidectin and abamectin. Regardless of the medicine or anthelmintic programs used, systematic investigation of resistant helminthes populations must constitute a *sine qua non* condition in modern parasitology [Cernea 2007].

MATERIALS AND METHODS

In order to test the anthelmintic action of various substances on the horse strongyls, during November 2009-April 2010, were tested a total of three combinations of Ivermectin (IVM) and

Research funded by PNII, project - IDEI, 412/2007

enzimidazoles (Fenbendazole - FBZ, Albendazole - ABZ, Mebendazole - MBZ). Testing these substances in terms of their effectiveness on strongyls eggs and larvae was performed in vitro using larval development assay (LDA). Strongyls eggs were collected from 30 horses from CSV Abrud where are a total number of 136 equine population. In order to determining the number of eggs per gram faeces was carried McMaster method. Than eggs are collected by the flotation method and concentrated by centrifugation.

RESULTS AND DISCUSSION

Drug combination between Ivermectin (3 mg/ml) and Mebendazole (0.625 mg/ml) was tested by larval development Assay (LDA) using 10 serial dilutions from the maximum concentration of 3.625 mg/ml to 0.0071 mg/ml. Counting the larvae 3 larvae (L3) after a period of 14 days of incubation at 26°C showed total inhibition of larval development. In control samples the developing rate obtained was 87.57%. Calculating lethal concentration 50 (LC50) with ARP software was obtained the concentration of -0.0759 mg/ml (table 1). These figures reveal that the use of Ivermectin and Mebendazole combination is more effective, thanks to the different mechanism of action of the two substances. The prediction equation leads to a maximum value of the parameter Y equal with - 1609.64. For this particular situation even if the value of LC50 is less in combination of these two substances, in practical activity we not recommend to use the combination in the treatment of hors strongylidosis.

Table 1.

Results on LDA performed with solution of Ivermectin and Mebendazole on strongyls eggs collected from horses from CSV 1 Abrud

No. of samples	No. of eggs, L1, L2	No. of L3	Conc. mg/ml active ingredient	% of Development	Y parameter
1	40	0	3.6250	0	-1.609.64
2	60	0	1.8125	0	-796.86
3	80	0	0.9063	0	-390.47
4	40	0	0.4531	0	-187.27
5	160	0	0.2266	0	-85.68
6	160	0	0.1133	0	-34.88
7	160	0	0.0566	0	-9.48
8	80	0	0.0283	0	3.22
9	140	0	0.0142	0	9.57
10	220	0	0.0071	0	12.75
Control	20	280	0.0000	87.57	15.92
Parameter		CL 50	CL 90	CL 100	
a	-448.43	-0.0759	-0.1651	-0.1874	
b	15.92				

In vitro testing by larval development assay, the combination of Ivermectin and Fenbendazole reveal a 12.5% of L3 development at concentration of 0.2266 mg/ml and 10% at 0.0283 mg/ml concentration. To control samples, the percentage of development was 45.8% which leads to a LC50 of -0.1870 mg/ml (table 2). Because development rates obtained, the prediction equation was at the maximum concentration only -753.79. Comparative analysis of test results from a of Ivermectin and Fenbendazole combination, and each substance separately,

indicating that after association, the risk of induction the resistance phenomena of strongyls population, is much higher.

Table 2.

Results on LDA performed with solution of Ivermectin and Fenbendazole on strongyls eggs collected from horses from CSV Abrud

No. of samples	No. of eggs, L1, L2	No. of L3	Conc. mg/ml active ingredient	% of Development	Y parameter
1	20	0	3.6250	0	-753.79
2	60	0	1.8125	0	-371.63
3	80	0	0.9063	0	-180.54
4	20	0	0.4531	0	-85.00
5	140	20	0.2266	12.5	-37.23
6	140	0	0.1133	0	-13.35
7	160	0	0.0566	0	-1.40
8	180	20	0.0283	10	4.57
9	240	0	0.0142	0	7.55
10	120	0	0.0071	0	9.05
Control	240	200	0.0000	45.8	10.54
Parameter		CL 50	CL 90	CL 100	
a	-210.85	-0.1870	-0.3767	-0.4242	
b	10.54				

Similar results were also obtained, by in vitro testing using larval development assay for the combination of Ivermectin and Albendazole. The LC50 for this combination was -0.0696 mg/ml (table 3). At all concentrations tested, the percentage of larval development was nil, indicating good efficacy of the combination of Ivermectin and Albendazole. Maximum Y parameter was -1706.70 at the concentration of 3.6250 mg/ml.

Table 3.

Results on LDA performed with solution of Ivermectin and Albendazole on strongyls eggs collected from horses from CSV Abrud

No. of samples	No. of eggs, L1, L2	No. of L3	Conc. mg/ml active ingredient	% of Development	Y parameter
1	40	0	3.6250	0	-1.706.70
2	20	0	1.8125	0	-844.91
3	120	0	0.9063	0	-414.01
4	20	0	0.4531	0	-198.57
5	40	0	0.2266	0	-90.84
6	60	0	0.1133	0	-36.98
7	60	0	0.0566	0	-10.05
8	80	0	0.0283	0	3.41
9	60	0	0.0142	0	10.15
10	80	0	0.0071	0	13.51
Control	0	40	0.0000	92.85	16.88
Parameter		CL 50	CL 90	CL 100	
a	-475.47	-0.0696	-0.1537	-0.1748	
b	16.88				

Analyzing the efficacy of the combination between Ivermectin and benzimidazoles is noted that no phenomena of synergy exist between these anthelmintic substances. In all cases, the risk of induction of strongyls resistance was significantly reduced when Ivermectin when used alone. According with the values of Y prediction parameter, using the combination between Ivermectin and benzimidazoles, in this particular horse population, has the capacity to inducing more rapid the resistance phenomenon on strongyls population.

CONCLUSIONS

1. The use of Ivermectin and Mebendazole combination is more effective, thanks to the different mechanism of action of the two substances. The prediction equation leads to a maximum value of the parameter Y equal with -1609.64.
2. Comparative analysis of test results from a of Ivermectin and Fenbendazole combination, and each substance separately, indicating that after association, the risk of induction the resistance phenomena of strongyls population, is much higher
3. At all concentrations tested, the percentage of larval development was nil, indicating good efficacy of the combination of Ivermectin and Albendazole. Maximum Y parameter was -1706.70 at the concentration of 3.6250 mg/ml.
4. Analyzing the efficacy of the combination between Ivermectin and benzimidazoles is noted that no phenomena of synergy exist between these anthelmintic substances.

REFERENCES

1. ADAMS R., [2001]. Veterinary pharmacology and therapeutics. 8th edition, Iowa state University Press.
2. CERNEA MIHAI, [2007]. Chimiorezistenţa în strongilidoze la ecvine. Ed. Risoprint, Cluj-Napoca, (227 p), ISBN: 978-973-751-497-4.
3. COSOROABA I., [2002] Managementul rezistenţei la antiparazitare. Rev. Sc. Parasitol., Vol. 3, (1); 28-35.
4. MADEIRA DE CARVALHO L.M., [2001]. Epidemiologia e controlo da estrongilidose em diferentes sistemas de poducato equina em Portugal. Lisboa, 33-34.
5. MONAHAN C., [2000]. Anthelmintic Control Strategies for Horses. Ed. Bowman D.D., Department of Veterinary Preventive Medicine, College of Veterinary Medicine, Ohio State University, Columbus, Ohio, USA.
6. MOORE, J.N., [2000]. Controlling Equine Cyathostomes. Equine Forum, 391-393.

THE EFFICACY OF TETRAHYDROPYRIMIDINES AND BENZIMIDAZOLES COMBINATION IN EQUINE STRONGYLIDOSIS

Laura Cristina CERNEA[1], M. CERNEA[1], L. OGNEAN[1], V. NĂSTASA[2], Ş. RĂILEANU[3], M. MAREŞ[2], Anca CHEREJI[1] L. M. Madeira de CARVALHO[4]

1. USAMV Cluj-Napoca, Calea Mănăştur, no.3-5, 400372, Romania; 2. USAMV Iaşi, Aleea Mihail Sadoveanu no. 8, 700489, Romania; 3. INCDDD Tulcea, 165, Babadag Street, 820112 Tulcea, Romania; 4.Universidade Tecnica de Lisboa, Facultade de Medicina Veterinaria Lisbon, Portugal,
e-mail: mscernea@yahoo.com

ABSTRACT

In vitro research conducted on a number of 30 horses from CSV Abrud the purpose of testing the combination of Pyrantel, Fenbendazole, Albendazole, Mebendazole, on the horse strongyls, revealed the following phenomena of synergism between benzimidazoles and Pyrantel. Thus, comparing the lethal concentration 50 at Mebendazole and Pyrantel is noted that if the combined action of lethal concentration has values -0.0274mg/ml, highlighting the synergistic action. The combination between Fenbendazole and Pyrantel caused the LC50 of -0.0349 mg/ml, which lies between that obtained from Fenbendazole - 9.920 mg/ml, respectively -0.017mg/ml Pyrantel. The combination of Albendazole and Pyrantel was calculated LC50 of -0.0236 mg/ml which reflects synergism phenomena.

Key words: equine, Pyrantel, benzimidazoles, strongyls

INTRODUCTION

Internationally, the study of equine strongylidoses is a topical issue because these disease may have caused serious repercussions such symptoms, especially the decline in physical capacity of the animals [Moore, 2000; Monahan, 2000]. Problems on the occurrence of anthelmintic resistance and high costs for discovering new antiparasitic molecules (including costs necessary to control adjacent residues in medicinal products for human consumption falling - in countries where horse meat is consumed), determines to find new ways approach to this disease in terms of diagnosis, treatment and prevention [Cernea, 2007]. Strongylidoses therapy may be used in various preparations whose efficacy refers to the larval stages and / or adults. Current therapy is mainly based on the use of derivatives benzimidazoles and probenzimidazoles, tetrahydropyrimidines (pyrantel pamoate) and macrocyclic lactone - ivemectin, moxidectin and abamectin [Adams 2001, Monahan, 2000, Madeira de Carvalho, 2001].

MATERIALS AND METHODS

In order to test the anthelmintic action of various substances on the horse strongyls, during November 2009-April 2010, were tested a total of three combinations of Pyrantel (PYR) and benzimidazoles (Fenbendazole - FBZ, Albendazole - ABZ and Mebendazole - MBZ).

Research funded by PNII, project - IDEI, 412/2007

Testing these substances with respect to their effectiveness on eggs and larvae to exogenous strongyls, was performed by using in vitro test larval development test (LDA). Strongyls eggs was collected from a number of 30 horses from CSV Abrud where exist a total of 136 equine. In order to determining the number of eggs per gram of faeces was carried Mc Master method.

RESULT AND DISCUSSIONS

The first combination was made between Pyrantel and Mebendazole. We prepared 10 serial concentrations from 0.9mg/ml Pyrantel and 0.625 mg/ml Mebendazole (1.525 mg/ml active substance combined). Counting in the plate the number of eggs, the larvae stage 1 (L1) and two-stage
larvae (L2) compared with those of stage 3 (L3), showed zero percent larval development by LDA test. This data reflects a good therapeutic efficacy of the combination drug. Comparing the Mebendazole lethal concentration 50 (LC50 = - 0.00010 mg/ml) and Pyrantel lethal concentration (LC50 = -0.0178 mg/ml), we observed that the combined action of lethal concentration has values -0.0274 mg/ml (table 1). These data highlight the synergistic action of Pyrantel and Mebendazole on tested strongyls population, which can counteract these helmints reduced sensitivity to benzimidazole molecules. The phenomenon of synergism could be also easily observed by calculating Y parameter values by comparing the maximum concentrations used for substances tested separately and the combination of these. The value of this parameter for Mebendazole was -1578.35, -1632.47 for Pyrantel, and the combination of these substances reaching -1782.81.

Table 1.

Results on LDA performed with solution of Pyrantel and Mebendazole on strongyls eggs collected from horses from CSV Abrud

No. of samples	No. of eggs, L1, L2	No. of L3	Conc. mg/ml active ingredient	% of Development	Y parameter
1	80	0	1.5250	0	-1.782.81
2	120	0	0.7625	0	-882.61
3	120	0	0.3813	0	-432.51
4	140	0	0.1906	0	-207.46
5	102	0	0.0953	0	-94.94
6	180	0	0.0477	0	-38.67
7	160	0	0.0238	0	-10.54
8	220	0	0.0119	0	3.52
9	360	0	0.0060	0	10.56
10	120	0	0.0030	0	14.07
Control	0	320	0.0000	96.77	17.59
Parameters		CL 50	CL 90	CL 100	
a	-1180.59	-0.0274	-0.0613	-0.0697	
b	17.59				

In order to find new drug combinations among different groups of anthelmintic with efficacy in hors strongylidosis was studied the combination of Pyrantel with Fenbendazole. Similarly with previous study, we perform LDA using 10 serial dilutions, from 1.525 mg/ml (0.9 mg/ml Pyrantel + 0.625 mg/ml Fenbendazole) to 0.003 mg/ml. Development rates were zero except

the maximum concentration (12.5%) and minimum (25%). To the control samples the rate of L3 development was 69.7%. Calculation of lethal concentrations 50 through ARP's software, has led to obtain the value of
-0.0349 mg/ml, which lies between that obtained from Fenbendazole -9.920 mg/ml, respectively -0.017 mg/ml Pyrantel (table 2). These data reveal a trend of Y parameter towards - ∞, the maximum recorded being of -1418.42. This value is higher than that obtained from Pyrantel (Y = -1632.47) and Fenbendazole (Y = -1497.20). We consider that Fenbendazole, respectively Pyrantel, using separate has lower risk to inducing adaptive phenomena to strongyls from tested horses.

Table 2.

Results on LDA performed with solution of Pyrantel and Febendazole on strongyls eggs collected from horses from CSV Abrud

No. of samples	No. of eggs, L1, L2	No. of L3	Conc. mg/ml active ingredient	% of Development	Y parameter
1	140	20	1.5250	12.5	-1.418.42
2	20	0	0.7625	0	-700.65
3	80	0	0.3813	0	-341.77
4	120	0	0.1906	0	-162.32
5	60	0	0.0953	0	-72.60
6	80	0	0.0477	0	-27.74
7	140	0	0.0238	0	-5.31
8	140	0	0.0119	0	5.90
9	80	0	0.0060	0	11.51
10	60	20	0.0030	25	14.32
Control	160	320	0.0000	69.7	17.12
Parameters		CL 50	CL 90	CL 100	
a	-941.34	-0.0349	-0.0774	-0.088	
b	17.12				

The combination of Pyrantel (0.9 mg/ml) and Albendazole (0.626 mg/ml) using in other LDA test performed on the same strongyls population reveal zero percent of L3 development until the sample with 0.006 mg/ml concentration. At the lowest dilution (sample 10) with a concentration of 0.003 mg / ml, this percentage of development was 20% (table 3). Calculation of lethal concentrations 50 highlighted a concentration of -0.0236 mg/ml value that is between that obtained from Pyrantel (LC50 = -0.0178 mg/ml) and Albendazole (LC50 = -9.20689 mg/ml). Because the LC50 of drug combination is lower, we consider that between these two substances exist phenomena of synergism.
In Romania, the most common choice of the owners (and veterinarians) in prevention and treatment of horse strongylidosis is benzimidazoles, especial Albendazole. [Cernea 2007]. The widespread use of Albendazole in recent years has resulted in some actual occurrence of strongyls resistance to this molecule, and because resistance group, virtually all benzimidazole derivatives. The results obtained in our tests revealed that Albendazole combination with Pyrantel causes a significant reduction of lethal concentration, given the fact that Albendazole concentration used in the experiment was three times lower than with Albendazole alone.

This is a great practical application because it is also known that Albendazole in horses has most hepatotoxic effect.

Table 3.

Results on LDA performed with solution of Pyrantel and Albendazole on strongyls eggs collected from horses from CSV Abrud

No. of samples	No. of eggs, L1, L2	No. of L3	Conc. mg/ml active ingredient	% of Development	Y parameter
1	40	0	1.5250	0	-1.849.16
2	60	0	0.7625	0	-914.07
3	60	0	0.3813	0	-446.53
4	60	0	0.1906	0	-212.75
5	60	0	0.0953	0	-95.87
6	140	0	0.0477	0	-37.42
7	40	0	0.0238	0	-8.20
8	40	0	0.0119	0	6.41
9	60	0	0.0060	0	13.71
10	80	20	0.0030	20	17.37
Control	0	80	0.0000	94.44	21.02
Parameter		CL 50	CL 90	CL 100	
a	-1226.35	-0.0236	-0.0562	-0.0643	
b	21.02				

Practical tests carried out by associating tetrahydropyrimidin with benzimidazoles has been found that the combined use of Pyrantel with Mebendazole and Albendazole determined with a lower risk to induction of adaptive phenomena on strongyls. In addition, we reveal that drug doses used in both cases, were three times lower than usual.

CONCLUSIONS

1. Comparing the lethal concentration of Mebendazole (LC50 = -0.00010 mg/ml) and Pyrantel (LC50 = -0.0178 mg/ml) we reveal that the lethal concentration for combined action has values of -0.0274 mg/ml, highlighting the synergistic action. These synergism is also confirmed by the lower value of Y parameter -1782.81.
2. The combination of Fenbendazole and Pyrantel reveal the LC50 with the value of -0.0349 mg/ml, which lies between that obtained from separate testing of Fenbendazole, respectively Pyrantel. These data reveal a trend towards to -∞ of Y parameter, reflecting the synergistic action of this two anthelmintic.
3. The combination of Albendazole and Pyrantel revealed an LC50 of -0.0236 mg/ml, which lies between the value obtained using Pyrantel (-0.0178 mg/ml) or Albendazole (-9.20689 mg/ml) alone. These date confirm the synergic action of these tow molecule of anthelmintic.

REFERENCES

1. Adams R., [2001]. Veterinary pharmacology and therapeutics. 8th edition, Iowa state University Press.
2. Cernea Mihai, [2007]. Chimiorezistența în strongilidoze la ecvine. Ed. Risoprint, Cluj-Napoca, (227 p), ISBN: 978-973-751-497-4.
3. Cosoroabă I., [2002] Managementul rezistenței la antiparazitare. Rev. Sc. Parasitol., Vol. 3, (1); 28-35.
4. Madeira de Carvalho L.M., [2001]. Epidemiologia e controlo da estrongilidose em diferentes sistemas de poducato equina em Portugal. Lisboa, 33-34.
5. Monahan C., [2000]. Anthelmintic Control Strategies for Horses. Ed. Bowman D.D., Department of Veterinary Preventive Medicine, College of Veterinary Medicine, Ohio State University, Columbus, Ohio, USA.
6. Moore, J.N., [2000]. Controlling Equine Cyathostomes. Equine Forum, 391-393.
7. Nadler S.A., [1990]. Molecular approaches to studyng helminth population genetics and phylogeny. Int. Journal Parasitol, no. 20, 11-29.

BIOLOGICAL CONTROL OF PASTURES INFESTED WITH EQUINE STRONGYLS LARVAE

M. CERNEA[1], Laura Cristina CERNEA[1], Ş. RĂILEANU[3], V. NĂSTASA[2], M. MAREŞ[2], L. OGNEAN[1], L. M. Madeira de CARVALHO[4]

1. USAMV Cluj-Napoca, Calea Mănăştur, no.3-5, 400372, Romania; 2. USAMV Iaşi, Aleea Mihail Sadoveanu no. 8, 700489, Romania; 3. INCDDD Tulcea, 165, Babadag Street, 820112 Tulcea, Romania; 4.Universidade Tecnica de Lisboa, Facultade de Medicina Veterinaria Lisbon, Portugal, e-mail: mscernea@yahoo.com

ABSTRACT

Studies conducted in August 2009 for testing anthelmintic effect of four herbal decoctions on strongyls infestation forms located on land plots artificially infested, revealed that at the decoction of Hippophae rhamnoides the efficacy was highest (86.66%), followed by anthelmintic composition (60%), which includes Thymus serpyllum, Arthemisia absinthium, Frangula Alnus, Gentiana lutea, Inula helenium, Matricaria chamomilla, Rosa canina. Action over strongyls exogenous forms has been reduced or even zero using Pimpinella anisium or Juglans nigra decoction. Strongyls most resistant species belonged to genus Cyathostomum, whose strength is great both for the environment and to the anthelmintic medication.

Key words: equine, phytotherapy, strongyls

INTRODUCTION

On pasture, for any horse, there are two sources of infested cyathostoma larvae: the L3 from the previous season surviving on grass and those that develop de novo in the egg, reached the pasture with faeces. Also, horses can infest with Strongyls larvae that survived during winter in the pasture. These larvae will not be too many, until the temperature is not optimal for their metabolism. Prevention and limiting equine exposure to infected larvae on pasture is possible and achievable through a pest control program that does not pollute the environment with anthelmintic substances.

MATERIALS AND METHODS

Studies were conducted in August 2009, in city Belis, Cluj county, and consisted of checking the degree of strongyls infestation (larvae per kg grass - LpKI) with the five parcels of land with area of one square meter each, and identify any strongyls larvae (day 0) (table 1). Later (day 1) was infested all plots with Strongyls eggs, applying a quantity of 500 g equine faeces, with an average level of 1200 EPG. After 24 hours (day 2), on four plots were sprayed grasses with 500ml of one phytotherapeutic aqueous extract, 25% concentration. Plot number 5 was sprayed with water only, being a control. After 14 days have been verified the degree of infestation, respectively the effectiveness of phyto-therapy by collecting grass and soil samples (100g/plot) and quantifying the number of strongyl infected larvae per kg of grass (LpKI)

Research funded by PNII, project - IDEI, 412/2007

.

RESULT AND DISCUSSIONS

Checking pre-therapeutic level of infestation parcels not revealed the presence of strongyls larvae, because of geographic isolation of marked plots and absence of horses in the last nine years on this field.

Plot no. 1 - **anthelmintic decoction** (*Thymus serpyllum, Arthemisia absinthium, Frangula Alnus, Gentiana lutea, Inula helenium, Matricaria chamomilla, Rosa canina*).

After 16 days from plot infestation was found that the number of infected larvae per kilogram of grass was 60. Larvae identified belonged to species *Cyathostomum* (83.34%) and *Poteriostomum* (16.66%). Compared with the control plot (no. 5), where we identified a number of 150 LpKI strongyls larva, for this anthelmintic decoction the efficacy was 60%, which shows reduced anthelmintic action of the extract (table 1).

Plot no. 2 - *Hippophae rhamnoides* decoction

On this plot, were identified only *Cyathostomum* species (100%), their number was the lowest compared with other groups. Thus, only 20 LpKI were quantify, which reveal the 86.66% efficacy against strongyls larvae compared with the control plot (table 1).

Plot no. 3 - *Juglans nigra* decoction

The plot of land treated with decoction of *Juglans nigra*, was found with the highest number of Strongyls larvae (170 LpKI), all belonging to the genus *Cyathostomum*, which shows total lack of efficacy of these extracts on exogenous forms of strongyls. This is highlighted by comparing the number of larvae obtained from control plots, which were identified and quantified only 150 LpKI (table 1).

Plot no. 4 - *Pimpinella anisium* decoction

On this plot, after 16 days of artificial infestation were identified larvae belong to the species *Cyathostomum* (87.50%) and *Strongylus vulgaris* (12.50%). It is noted that for the first time have identified evidence of *Strongylus vulgaris* larvae on grass, knowing that they have a lower resistance in the external environment [Cernea, 2007]. Was quantifying 80 LpKI on this plot was, which reveal an efficiency of only 46.67% of the *Pimpinella anisium* decoction against L3 of strongyls (table 1).

The total number of larvae per kilogram of grass on control plots was 150. Was identified species belonging to the genus *Cyathostomum* (86.68%), *Poteriostomum* (6.66%) and *Strongylus vulgaris* (6.66%).

The results of this experiment reveal that the decoction of *Hippophae rhamnoides* has the highest efficiency (86.66%), followed by anthelmintic (60%), the composition of which includes *Thymus serpyllum, Arthemisia absinthium, Frangula Alnus, Gentiana lutea, Inula helenium, Matricaria chamomilla* and *Rosa canina*. Action on exogenous strongyls forms has been reduced or even zero at *Juglans nigra* and *Pimpinella anisium* decoction. However, it appears that most resistant strongyls species belonging to the genus Cyathostomum, whose strength is well known worldwide [Dorny et al., 2000; Monahan, 2000; Lloyd et al., 2000; Kaplan 2002; Tandon and Kaplan, 2004, Cernea, 2007].

Tablel 1.

Working methodology and results obtaining by testing 4 herbal extracts on parcels of land artificial infested with eggs strongyls from horses .

Plot no.	Pharmaceutical formulation and composition	Degree of infestation (day 0) LpKI			Degree of infestation (14 days) LpKI	Identified species (%)
1	Decoction from: *Thymus serpyllum*, *Arthemisia absinthium*, *Frangula alnus*, *Gentiana lutea*, *Inula helenium*, *Matricaria chamomilla*, *Rosa canina*.	0	Plots artificial infestation (day 1) 1200 E PG (500g feaces) per m^2	Phyto-therapy aplication on plots (day 2) using 500ml 25% per m^2	60	*Cyathostomum* spp. (83.34%) *Poteriostomum* spp. (16.66%)
2	Decoction from *Hippophae rhamnoides*	0			20	*Cyathostomum* spp. (100%)
3	Decoction from *Juglans nigra*	0			170	*Cyathostomum* spp. (100%)
4	Decoction from *Pimpinella anisium*	0			80	*Cyathostomum* spp. (87.5%) *Strongylus vulgaris* (12.5%)
5	Control plot	0		100 ml water	150	*Cyathostomum* spp. (86,68%) *Strongylus vulgaris* (6,66%) *Poteriostomum* spp. (6,66%)

Plot no. 5 – control

CONCLUSIONS

Studies conducted in August 2009 for testing anthelmintic effect of four herbal decoctions on strongyls infestation forms located on land plots artificially infested, revealed that:

1. With the decoction of Hippophae rhamnoides the efficacy was highest (86.66%), followed by anthelmintic composition (60%), which includes Thymus serpyllum, Arthemisia absinthium, Frangula Alnus, Gentiana lutea, Inula helenium, Matricaria chamomilla, Rosa canina.

2. Action over strongyls exogenous forms has been reduced or even zero using Pimpinella anisium or Juglans nigra decoction.
3. Strongyls most resistant species belonged to genus Cyathostomum, whose strength is great both for the environment and to the anthelmintic medication.

REFERENCES

1. CERNEA LAURA CRISTINA [2009]. *Modele de analiză în fitoterapia experimentală*. Editura AcademicPres, Cluj-Napoca, 2009
2. CERNEA MIHAI, [2007]. *Chimiorezistența în strongilidoze la ecvine*. Ed. Risoprint, Cluj-Napoca, (227 p), ISBN: 978-973-751-497-4.
3. DORNY P., MEIJER I., SMETS K., VERCRUYSSE J., [2000]. *A survey of anthelmintic resistance on belgian horse farms*. Vlaams Dierg. Tijds., 69; 334-337.
4. KAPLAN R.M., (2002). *Anthelmintic resistence in nematodes of horses*. Vet.Res., 33; 491-507.
5. LLOYD S., SMITH J., CONNAN R.M., HATCHER M.A., HEDGES T.R., HUMPHREY D.J., JONES A.C., [2000]. *Parasite control methods used by horse owners: factors predisposing to the development of anthelmintic resistance in nematodes*. Vet. Rec., 146; 487-492.
6. MONAHAN C., [2000]. Anthelmintic Control Strategies for Horses. Ed. Bowman D.D., Department of Veterinary Preventive Medicine, College of Veterinary Medicine, Ohio State University, Columbus, Ohio, USA.
7. TANDON R., KAPLAN R.M., (2004). *Evaluation of a larval development assay (DrenchRite) for the detection of antihelmintic resistance in cyathostomin nematodes of horses*. Vet. Parasitol. 121; 125-142.

THE EFFICACY OF HERBAL EXTRACT ON EQUINE STRONGYLIDOSIS

M. CERNEA[1], Laura Cristina CERNEA[1], Ş. RĂILEANU[3], V. NĂSTASA[2], M. MAREŞ[2], L.ț OGNEAN[1], L. M. Madeira de CARVALHO[4]

1. USAMV Cluj-Napoca, Calea Mănăştur, no.3-5, 400372, Romania; 2. USAMV Iaşi, Aleea Mihail Sadoveanu no. 8, 700489, Romania; 3. INCDDD Tulcea, 165, Babadag Street, 820112 Tulcea, Romania; 4.Universidade Tecnica de Lisboa, Facultade de Medicina Veterinaria Lisbon, Portugal, e-mail: mscernea@yahoo.com

ABSTRACT

Between December 2009 - April 2010, was tested in vitro 5 hidroalcoolic herbal extract in order to determining the effectiveness of these on strongyls eggs and larva. The Strongyls was isolated from 28 horses' faecal samples and were performed eggs hatching assay - EHA and larval development assay - LDA. With hidroalcoolic extract of Satureja hortensis and Ocimum basilicum, using EHA and LDA assay the value of LC50 was high, which shows reduced its effectiveness on strongyls eggs and larvae. Using the Arthemisia absinthium hidroalcoolic solution in EHA resulted a LC50 of 35.9413% and 22.7616% by LDA test which reveals average effective against strongyls eggs and larvae. In hidroalcoolic solution of Inula helenium and Allium sativum were obtained lowest values of LC50, which show good efficacy against strongyls.

Key words: equine, phytotherapy, strongyls

INTRODUCTION

Equine strongylidosis study is a world - wide highly important topic due to the serious consequences this disease can induce both by symptomatology and by decreasing physical capacity of animals [Moore, 2000; Monahan, 2000]. Regardless of the medicine or anthelmintic programs used, systematic investigation of resistant helminthes populations must constitute a sine qua non condition in modern parasitology. Because Strongyls resistance to anthelmintics, phenomenon which is becoming more frequently reported across the globe, it is necessary to find new ways of combating and alternative therapies to counteract this phenomenon [Cernea 2007].

MATERIALS AND METHODS

The study was conducted during December 2009 - April 2010 on 28 horses from Sălaj county (table 1). Were collected faecal samples in order to determine the infestation with strongyls. Was performed McMaster method and Stoll (adapted for quantitative larvae counting) and by Willis flotation method were collected strongyls eggs (table 1).

Tests were conducted by using 5 hidroalcoolic solutions of *Inula helenium, Allium sativum, Satureja hortensis*, *Ocimum basilicum and Arthemisia absinthium*. These solutions were using in egg hathing assay - EHA and larval development assay – LDA. To perform those two tests, were obtained six serial dilutions, with concentrations of 50%, 25%, 12.5%, 6.25%, 3 12%, and 1.56%. Control samples were performed with hidroalcoolic solution (25%). Subsequently, in

Research funded by PNII, project - IDEI, 412/2007

the plates with wells of 2.5 ml capacity was added 1 ml of stock solution and 1 ml of suspension strongyls eggs, so that the final dilutions in the plate were 25%, 12.5%, 6.25 %, 3.12%, 1.56% and 0.78%. For EHA test samples were kept in an incubator at a temperature of 27 Celsius degrees for 24 hours, after which the results were read, quantifying the number of eggs compared with hatched larvae stage 1 (L1) . It was calculated the percentage of hatching and was calculate the statistic prediction eguation for each sample separately. For LDA test results were read after 12 days of incubation of plates at the thermostat, quantifying the eggs, larvae stage 1 and 2 (L1, L2) compared with those of stage 3 (L3). It was determined the percentage of larval development and the statistic prediction equation. Data from both tests were analyzed using the program Anthelmintic Resistance Program (www.pharma-logic.ro), determining the parameters "a" and "b" required for statistic prediction equation and lethal concentration (LC) 50.

Table 1

The average infestation with strongyls eggs (EPG) and larvae (LPG) of the horses in the Salaj county

No. of sample	Sex	Age	EPG	LPG
1	F	7	100	200
2	F	1	1.000	2.200
3	F	5	1.900	2.000
4	F	8	500	900
5	F	7	300	1.100
6	F	5	500	700
7	F	3	2.800	4.100
8	F	6	400	1.000
9	F	10	100	600
10	F	5	0	100
11	F	9	0	100
12	F	7	0	200
13	F	6	100	600
14	F	27	300	600
15	F	3	600	1.100
16	M	14	300	1.100
17	F	9	1.000	2.300
18	F	11	800	800
19	F	3	100	800
20	F	6	0	500
21	F	2	100	400
22	F	7	400	500
23	F	12	1.500	2.200
24	F	17	1.000	1.600
25	F	7	5.800	8.300
26	M	3	1.400	1.900
27	F	4	2.800	3.300
28	F	6	0	700
Mean			**850**	**1425**
Extensivity (%)			**82,14**	**100**
Intensivity			**1034,78**	**1425**

RESULT AND DISCUSSIONS

Average number of strongyls EPG was 850, 1425 LPG respectively. Strongylidosis extensivity was 82.14% by EPG determination and 100% by LPG. The degree of intensivity was determined by EPG 1034.78 respectively LPG 1425. These results reflect the average levels of strongyls infestation in the equine population (table 1).

Satureja hortensis solution

In vitro testing of hidroalcoolic solution of *Satureja hortensis* by EHA showed maximum hatching percentage (100%) at 3.12% and 1.56% dilutions. The results obtained in other dilutions revealed high percentages of larval hatching. The parameter Y had values between 92.75 and 100, which resulted in a straight character pronounced positive prediction (table 2). The efficacy of this plant extract reveals low efficacy on strongyls eggs, also because the lethal concentration (LC50), calculate by mathematical determination was 167.3751%. In contrast, with LDA testing with *Satureja hortensis* has been shown that prolongation of contact between the active principles of plant and exogenous forms of the Strongyls yielded better results compared with EHA. The percentage of maximum development (80%) occurred in 1.56% concentration, and minimum (38.46%) at concentration of 25% (table 3). Determination of LC50 showed a concentration percent of 11.5234, which reflects the fact that is possible that repeated administration of plant extract to the horses could be an alternative if the strongyls have resistance to the classic anthelmintics.

Table 2.

Results on EHA performed with *Satureja hortensis* solution on strongyls eggs

No. of samples	No. of eggs	No. of hatchin eggs and L1	% of dilution	% of Hatching	Y parameter
1	280	420	25,00	60,00	92,75
2	60	320	12,50	84,21	96,38
3	20	340	6,25	94,44	98,19
4	0	180	3,12	100,00	99,10
5	0	220	1,56	100,00	99,55
6	4	320	0,78	98,77	99,77
Control	60	910	0	93,81	100,00
Parameter				CL 50	
a	-0,29	b	100,00	167,3751	

Table 3.

Results on LDA performed with *Satureja hortensis* solution on strongyls eggs

No. of samples	No. of eggs, L1, L2	No. of L3	% of dilution	% of Development	Y parameter
1	160	100	25,00	38,46	16,99
2	40	100	12,50	71,43	47,62
3	20	40	6,25	66,67	62,93
4	20	40	3,12	66,67	70,60
5	20	80	1,56	80,00	74,42
6	20	40	0,78	66,67	76,33
Control	60	515	0	89,57	78,24
Parameter				CL 50	
a	-2,45	b	78,24	11,5234	

***Ocimum basilicum* solution**

The results obtained by testing the *Ocimum basilicum* solution were similar to those obtained when the solution of *Satureja hortensis*. By EHA, maximum hatching percentage (100%) was obtained at concentration of 3.12%. The minimum percentage of hatching was recorded at the maximum concentration of 25%, this being 63.16%. Calculation of LC50 (102.4420%), indicating a poor efficacy *Ocimum basilicum* solution strongyls on eggs and first stage larvae. Determining the Y parameters yielded a minimum value of 87.57 (Table 4). LDA with *Ocimum basilicum* solution indicating the percentage of development of its better efficacy compared with extract of *Satureja hortensis*. Thus at 3.12% concentration the larvae development 3rd stage was completely inhibited. Even in these conditions, were achieved maximum rates of development at concentrations of 12.50% and 6.25%. Because these percentages of larval development, Y parameter have value of -17.74 and had negative trend (table 5). As a consequence of this action, *Ocimum basilicum* solution on larval development process had LC50 value of 8.0601%.

Table 4.

Results on EHA performed with *Ocimum basilicum* solution on strongyls eggs

No. of samples	No. of eggs	No. of hatchin eggs and L1	% of dilution	% of Hatching	Y parameter
1	140	240	25,00	63,16	87,57
2	20	120	12,50	85,71	93,57
3	20	140	6,25	87,50	96,57
4	0	60	3,12	100,00	98,07
5	0	240	1,56	100,00	98,82
6	0	280	0,78	100,00	99,20
Control	60	910	0	93,81	99,57
Parameter				CL 50	
a	-0,48	b	99,57	102,4420	

Table 5.

Results on LDA performed with *Ocimum basilicum* solution on strongyls eggs

No. of samples	No. of eggs, L1, L2	No. of L3	% of dilution	% of Development	Y parameter
1	160	60	25,00	27,27	-17,74
2	0	180	12,50	100,00	32,26
3	0	60	6,25	100,00	57,26
4	20	0	3,12	0,00	69,78
5	20	300	1,56	93,75	76,02
6	20	140	0,78	87,50	79,14
Control	60	515	0	89,57	82,26
Parameter				CL 50	
a	-4,00	b	82,26	8,0601	

***Arthemisia absinthium* solution**

Testing by the EHA and LDA the *Arthemisia absinthium* solution on eggs and larvae strongyls revealed no major differences in terms of its effectiveness compared with the previous plant extract. Thus, the minimum percentage of hatching on EHA was recorded at 25%

concentration and the maximum 1.56% and 0.78%. Based on these data, determined LC50 has values of 35.9413%. Minimum value of the parameter Y was 64.39 (table 6). In LDA, developing 3rd larvae stage was completely inhibited by concentration of 25%, maximum percentages of development were obtained at concentrations of 1.56% and 0.78%. Biomathematic calculating of LC50 was 22.7616%. Minimum Y parameter was 45.35, which showed a slight positive aspect of the prediction equation (table 7).

Table 6.

Results on EHA performed with *Arthemisia absinthium* solution on strongyls eggs

No. of samples	No. of eggs	No. of hatchin eggs and L1	% of dilution	% of Hatching	Y parameter
1	100	180	25,00	64,29	64,39
2	40	180	12,50	81,82	80,64
3	20	100	6,25	83,33	88,77
4	20	120	3,12	85,71	92,83
5	0	60	1,56	100,00	94,86
6	0	40	0,78	100,00	95,88
Control	60	910	0	93,81	96,89
Parameter				CL 50	
a	-1.30	b	96,89	35,9413	

Table 7.

Results on LDA performed with *Arthemisia absinthium* solution on strongyls eggs

No. of samples	No. of eggs, L1, L2	No. of L3	% of dilution	% of Development	Y parameter
1	100	0	25,00	0,00	45,35
2	20	40	12,50	66,67	72,48
3	20	160	6,25	88,89	86,04
4	60	220	3,12	78,57	92,83
5	0	60	1,56	100,00	96,21
6	0	60	0,78	100,00	97,91
Control	60	515	0	89,57	99,60
Parameter				CL 50	
a	-2,17	b	99,60	22,7616	

***Inula henelium* solution**

At *Inula henelium* solution was noted that it has a strong inhibitory effect on strongyls eggs hatching. At maximum concentration of 25%, only 8.33% have been hatched, while maintaining low rates till 3.12% concentration. Maximum hatching percentage (85.71%) was recorded at the minimum concentration of 0.78%. Statistical interpretation of these results determined to obtain a LC50 of 2.2664%. Minimum parameter Y was -167.54, which shows a strong negative trend of the prediction equation (table 8). In addition, *Inula henelium* solution had a strong effect on larval development, so that most high concentrations (from 3.12 to 25%), larval development rates have ranged between 9.52% and 31.58%. Overall analysis of the percentage of development has led to obtain LC50 value of 1.6152% and a minimum value of the parameter Y -164.67 (table 9). The results obtained in tests with *Inula henelium* solution by EHA and LDA shows its good performance on both eggs and larval stages of exogenous strongyls.

Table 8.

Results on EHA performed with *Inula henelium* solution on strongyls eggs

No. of samples	No. of eggs	No. of hatchin eggs and L1	% of dilution	% of Hatching	Y parameter
1	220	20	25,00	8,33	-167,54
2	300	60	12,50	16,67	-47,92
3	200	40	6,25	16,67	11,90
4	180	40	3,12	18,18	41,85
5	180	340	1,56	65,38	56,78
6	20	120	0,78	85,71	64,25
Control	60	910	0	93,81	71,71
Parameter				CL 50	
a	-9,57	b	71,71	2,2664	

Table 9.

Results on LDA performed with *Inula henelium* solution on strongyls eggs

No. of samples	No. of eggs, L1, L2	No. of L3	% of dilution	% of Development	Y parameter
1	260	120	25,00	31,58	-164,67
2	380	40	12,50	9,52	-49,92
3	240	60	6,25	20,00	7,46
4	220	60	3,12	21,43	36,19
5	160	160	1,56	50,00	50,51
6	40	180	0,78	81,82	57,67
Control	60	515	0	89,57	64,83
Parameter				CL 50	
A	-9,18	b	64,83	1,6152	

***Allium sativum* solution**

EHA test conducted with *Allium sativum* solution resulted in complete inhibition of egg hatching at 6.25% concentration. The concentration peaks were obtained at 12.50% and 0.78% concentration. However, because the blank hatching percentage was 93.81%, LC50 was lowest (0.6428%) compared with previous EHA trials, reflecting the high efficiency of the active principles of *Allium sativum* solution. Y parameter was strongly negative, with a minimum of -177.01 (table 10)

Good results were obtained in the case of LDA where LC50 test was 0.5932% because the maximum concentration (25%) up 6.25% at the larval development of stage 3 was completely inhibited. Maximum percentage of larval development was recorded at 3.12% concentration, but it was only 50% (table 11).

Table 10.

Results on EHA performed with *Allium sativum* solution on strongyls eggs

No. of samples	No. of eggs	No. of hatchin eggs and L1	% of dilution	% of Hatching	Y parameter
1	20	40	25,00	66,67	-177,01
2	100	300	12,50	75,00	-60,51
3	60	0	6,25	0,00	-2,26
4	140	20	3,12	12,50	26,91
5	40	20	1,56	33,33	41,45
6	40	120	0,78	75,00	48,72
Contol	60	910	0	93,81	55,99

Parameter				CL 50
a	-9,32	b	55,99	0,6428

Table 11.

Results on LDA performed with *Allium sativum* solution on strongyls eggs

No. of samples	No. of eggs, L1, L2	No. of L3	% of dilution	% of Development	Y parameter
1	80	0	25,00	0,00	-144,04
2	120	0	12,50	0,00	-44,67
3	60	0	6,25	0,00	5,02
4	20	20	3,12	50,00	29,91
5	100	80	1,56	44,44	42,31
6	160	100	0,78	38,46	48,51
Control	60	515	0	89,57	54,71

Parameter				CL 50
a	-7,95	b	54,71	0,5932

CONCLUSIONS

Overall analysis of the results of tests carried out by EHA and LDA using hidroalcoolic plant extracts revealed a good inhibitory capacity of eggs hatching and larval development by extracts of *Allium sativum* and *Inula henelium*, which had lowest LC50 values. According to the LC50, *Arthemisia absinthium* extract had an average efficiency of eggs hatching, worst results were obtained when extracts from *Ocimum basilicum* and *Satureja hortensis*. Instead, *Ocimum basilicum* extract had good efficacy, inhibiting the larval development and the LC50 of 8.0601%. The weak capacity to inhibit larval development was obtained with *Arthemisia absinthium* solution, which had LC50 value of 22.7616%.

REFERENCES

1. CERNEA LAURA CRISTINA [2009]. *Modele de analiză în fitoterapia experimentală*. Editura AcademicPres, Cluj-Napoca, 2009
2. CERNEA MIHAI, [2007]. *Chimiorezistenţa în strongilidoze la ecvine*. Ed. Risoprint, Cluj-Napoca, (227 p), ISBN: 978-973-751-497-4.
3. MONAHAN C., [2000]. Anthelmintic Control Strategies for Horses. Ed. Bowman D.D., Department of Veterinary Preventive Medicine, College of Veterinary Medicine, Ohio State University, Columbus, Ohio, USA.
4. MOORE, J.N., [2000]. Controlling Equine Cyathostomes. Equine Forum, 391-393.

CONTRIBUTIONS TO THE STUDY OF ECTOPARASITES *DEMODEX CANIS* LOCALIZATION ON DOGS` BODY SURFACE

Al. D. CHESLER,[1] M.D. CODREANU,[2] Iuliana CODREANU,[1] D. CRÂNGANU,[2] A. BÎLBĂ[1]
[1]S.C. Univet Constanta (chesler.alexandru@yahoo.com),
[2]Faculty of Veterinary Medicine, Spl. Independenței, No.105,
Bucharest (codveterinary@yahoo.com),

ABSTRACT

The paper brings original data regarding the population size of mite Demodex canis in dogs according to breed, but also to area of the body that is parasite: periocular area, the thoraco-lumbar and croup area.
Studies made on the 121 patients examined, belonging to breeds that German Shepherds, Labradors, Rottweiler, Doberman, common breed, Pekingese and show that the total number of parasites (adults, larvae and eggs) varies between 23 374 and 66 260 at the Pekingese German Shepherd.
Comparing the degree of parasite in the three areas studied, indicates that periocular area is the most affected area because is well vascularised and innervated.
Average density of parasites on the entire body (400 ex.cm-2, in Doberman breed, is higher than in other races.

Key words: *Demodex canis, density, periocular area, thoraco-lumbar area, croup.*

In dog`s demodicosis, the *Demodex canis* mite locate in the hair follicles, at first, on restricted areas, then, as a result of decreased ability of the dog's natural defenses, surfaces, extending and the parasitosis could complicate bacterial or fungal infections (1,4,6,12).
Mite infestation is through contacts and therefore the first areas affected are those that the ill subjects can easily reach. In case of localized demodicosis, dry form, the first infested areas are periocular area, thoraco-lumbar and croup area (2,7,9,11).
Our research have an original character, because the consulted literature no mention such of studies aimed at finding information regarding the structure of *Demodex canis* populations in each area where the parasite installed (3,5,8,10).

MATERIALS AND METHODS

Were followed 121 individuals belonging to six breeds of dogs and were examined over 24.7904 specimens of the species *Demodex canis* parasites.
To assess the demodicosis affected area, were cut textil pieces, were marked to indicate the dog breed, and the body area (periocular "demodectic glasses", the thoraco-lumbar and croup areas). Then by weighing this textile pieces on analytical balance, we determined by comparison with the weight of the determined fragment area (by proportion), have determined the affected area (1,2,4).
Following clinical examination, the animals were subject to contention and skin scrapes in affected areas. These samples were obtained using scalpel blades, deep to bleed (3). The examination was performed to the Veterinary Clinic "Univet" from Constanta, with Zeiss microscope.

RESULTS AND DISCUSSION

Following analysis of 121 individuals belonging to six dog breeds, were found 23.690 of parasites from *Demodex canis* species, determining the number of adults in each area, the larval stages and eggs (Table 1).

Table 1

Body areas infested with Demodex canis in different breeds

Dog breed	*No. of. subiects*	***Area (cm²)***						*No. of parasite*
		periocular		*thoraco-lumbar*		*croup*		
		mean	*SD*	*mean*	*SD*	*mean*	*SD*	
Common breed	***19***	*12,171*	*3118*	*13,226*	*0,6065*	*7,077*	*0,2427*	*3118*
Doberman	***12***	*12,175*	*4796*	*13,366*	*0,1552*	*7,095*	*0,2163*	*4796*
German Shepherds	***25***	*12,137*	*2322*	*13,382*	*0,3345*	*6,936*	*0,2761*	*2322*
Rottweiler	***15***	*12,185*	*5728*	*13,298*	*0,2292*	*7,067*	*0,2130*	*5728*
Labradors	***23***	*12,156*	*3488*	*13,357*	*0,0739*	*7,189*	*0,2586*	*3488*
Pekingese	***27***	*7,560*	*4238*	*5,339*	*0,4288*	*1,799*	*0,2249*	*4238*
TOTAL	***121***		*23690*					*23690*

Areas occupied by the parasite are broadly similar and relatively small to dogs of the same size (common breed, Doberman, German Sheppard, Rottweiler and Labrador).

On case of small breeds, like Pekingese, the surface that was installed the parasite were about two times smaller that the large breeds, ranging from about 7.5 cm^2 for periocular area (with individual values ranging from 7.47 cm^2 and 7.65 cm^2), 5 cm^2 for thoraco-lumbar area (with individual values ranging between 4.87 cm^2 and 5.79 cm^2) and an area of 1.7 cm^2 for croup area (with individual values ranging from 1.47 cm^2 and 2.11 cm^2).

A first conclusion which can outline is that the installs parasite occupies certain areas, bear in terms of trophic parasite population. The increases affected skin area due to over infections. Therefore, adequate food treatment and possible immunostimulatory preparations may help the organism host to overcome the parasitosis, without drug treatment

The average numbers of parasites in same dogs breed, ranges from 4.238 to Pekingese, 4796 to Doberman and 5728 to Rottweiler. Short hair of host was the important factors of installing the parasite (Table 1).

Periocular area average total number of parasites, varied between 563 individuals on average per unit area of Pekingese breed and 2218 in Doberman. Adults are 60.54% in Pekingese (mean 341 $ex.cm^{-2}$) and 49.57% in Doberman (mean 1100 $ex.cm^{-2}$).

Number of *Demodex canis* larvae in the periocular region, ranges from 197 to Pekingese $ex.cm^{-2}$, representing 34.89% of the population and the Doberman 932 $ex.cm^{-2}$, almost half the population (40.01%), indicating a high prolificacy of the parasite in the periocular area at this race (Chart No.1).

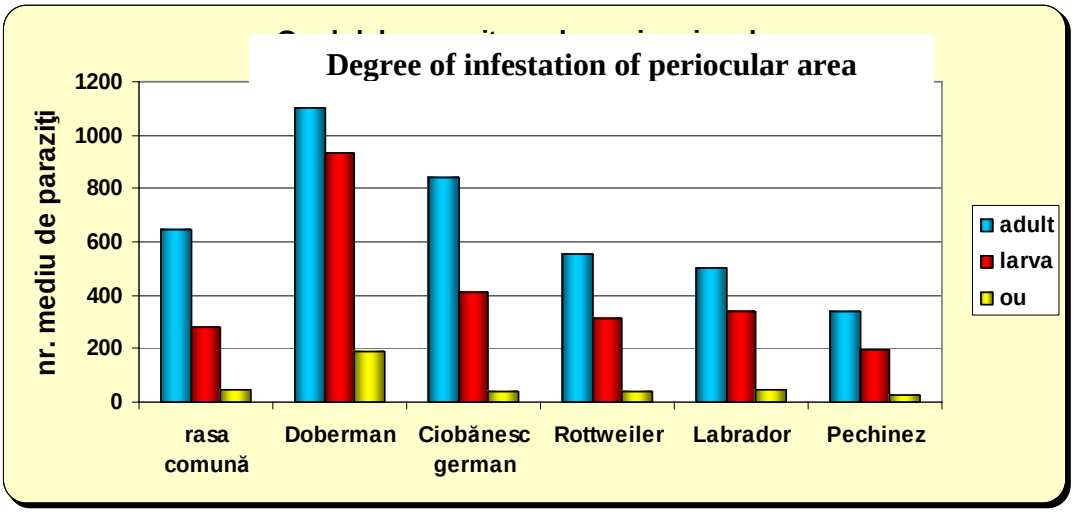

Chart No. 1. **Parasite *Demodex can*is in periocular area: population characteristics according to race**

In thoraco-lumbar area*, Demodex canis* found relatively good conditions for development, maximum population density were identified in Doberman (1701 ex.cm^{-2}), but 1.3 times lower as pericoculară region.

Population sizes are similar to German shepherd (1057 ex.cm^{-2}), the lowest value being to Pekingese (231 ex.cm^{-2}). Parasite populations are dominated by adults, larvae, representing around one third of their population, except that German Sheppard which larvae have a high density, representing 50.70% of the population.

Egg density between 10 ex.cm^{-2} (in Pekingese) and 156 ex.cm^{-2} (in Doberman), having a small share in the population (Chart No. 2).

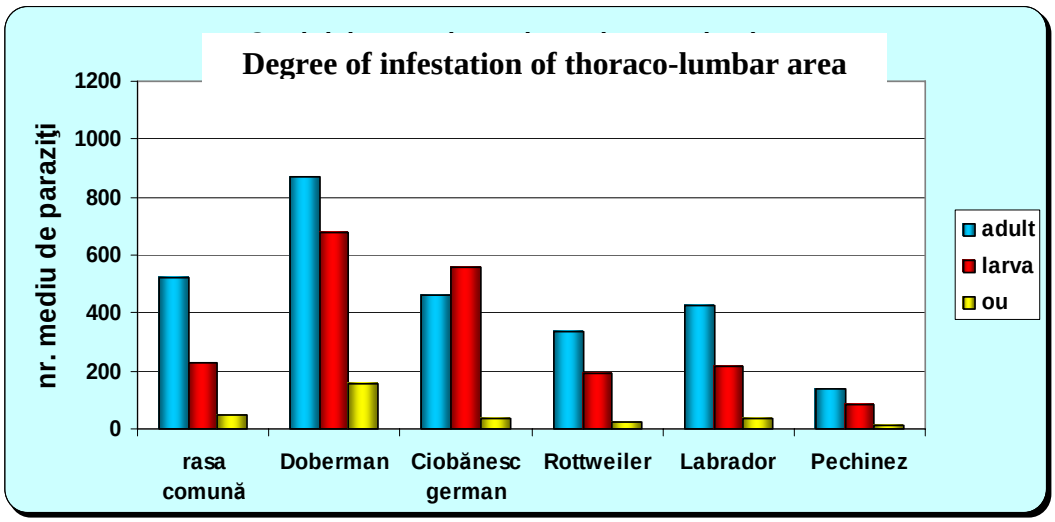

Chart No. 2. **Parasite *Demodex can*is in thoraco-lumbar area: population characteristics according to race**

Croup is the least attacked by the parasite, is an area where less in contact with other exemplares that could be infected. With a large effective population were identified in Doberman (1006 ex.cm^{-2}), but two times lower than in the periocular region.

Almost three times smaller populations of Demodex canis are in Rottweiler and German Shepherd breeds and the Labrador had the croup the average density of 207 ex.cm^{-2}. (Chart No. 3).

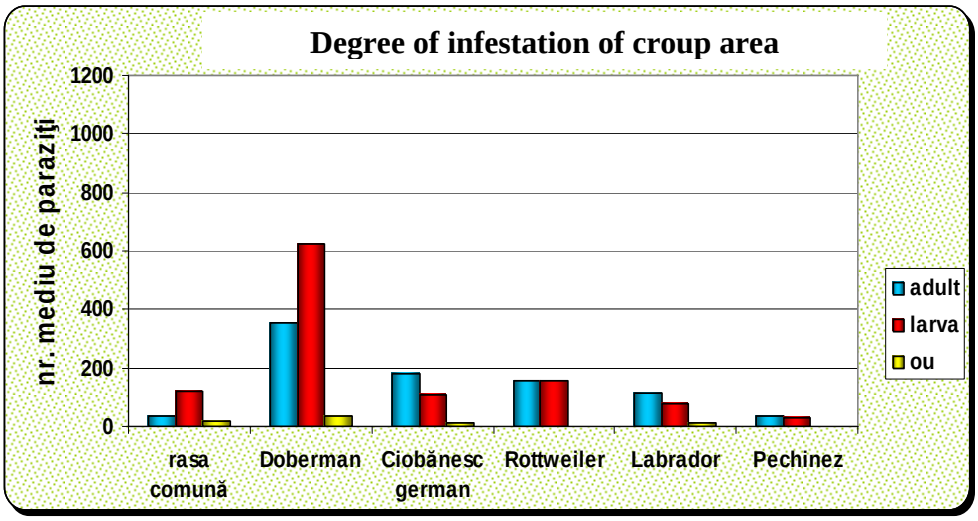

Chart No. 3. **Parasite *Demodex canis* in croup area: population characteristics according to rac**e

Average density of parasites throughout the affected area at various dog breeds, were 209 ex.cm^{-2}. Lowest average density was recorded in breed Labrador (152 ex.cm^{-2}) and highest in Doberman (400 ex.cm^{-2}). In contrast, the lowest standard deviation was obtained from Pekingese and highest densities as in the case, the Doberman (Table 2).

Table 2.

Overall environmental characterization of the *Demodex canis* parasite in various breeds of dogs

	COMUN BREED	DOBERMAN	ROTWEILLER	GERMAN SHEPARD	LABRADOR	PEKINGESE
Total density ex.cm^{-2}	3118	4796	2322	5728	3488	4238
Mean density ex.cm^{-2}	164	400	155	229	152	157
Median	162	400	150	230	152	158
Minim	136	326	120	168	110	128
Maxim	194	504	184	268	190	188
Standard deviation	18	48	20	25	23	16
AveDev	15	34	16	19	18	12

Structural similarities of populations of parasites from different breeds of dogs were identified by calculation of the degree of similarity between them. Such were calculated mean densities of these populations for each analyzed race, achieving initial matrix data.

CONCLUSIONS

Studies performed on 121 dogs from German Shepherds, Labrador, Rottweiler, Doberman, Pekingese and common breed, which were considered by *Demodex canis* areas affected (periocular, thoraco-lumbar and croup area), also according to the literature data, permits following conclusions:

1. Areas occupied by the parasite, determined with an original method, vary for dogs of the same size (common breed, Doberman, German Shepherd, Rottweiler and Labrador).
2. The installs parasite *Demodex canis* occupies certain areas, bear in terms of trophic parasite population.
3. Comparing the degree of parasite infection in these three studied areas, confirm the periocular area as the most affected, being an easily accessible area in the infestation because is well vascularized and can support large parasites populations (563 individuals on average per unit area in Pekingese breed and 2218 in Doberman breed).
4. Croup is the least attacked by the parasite, Demodex canis livestock populations were minimum of two times lower than in the periocular area;
5. In all areas examined, the larvae are an important segment of the population (about one third of the population in the thoraco-lumbar region, up to 40% in the periocular and two thirds of the population on the rump), indicating a high prolificacy of the parasite;
6. The values of ecological indices, designate Doberman breed as most affected by *Demodex canis* (mean parasite density of whole body was 400 ex.cm^{-2}).

REFERENCES

1. **Bowman, D.,D., Lynn, R.,C.** - Georgy's Parasitology for Veterinarians, Ed. VI, W.B. Saunders Company, Philadelphia, 1995
2. **Chesler, A.,D., Codreanu, M.,D., Mitrea, L., Codreanu, I., Bîlbă, A. –** Studiu privind biologia acarienilor din genul Demodex, Revista Română de Parazitologie, 2008
3. **Cosoroabă I., Gh. Darabuş, I. Oprescu** - Compendiu de parazitologie veterinară. Vol. 1-2, Edit. Mirton, Timişoara, 1995
4. **Cosoroabă, I.** - Parazitologie veterinară, Ed. Mirton, Timişoara, 2000
5. **Cosoroabă, I.** - Parazitologie veterinară. Acarioze. Entomoze. Edit. Mirton, Timişoara, 2000
6. **Cosoroabă, L., Dărăbuş, Gh., Oprescu, L., Morariu, S.** - Diagnostic paraclinic şi tehnici experimentale în parazitologie. Edit. Mirton, Timişoara, 2002
7. **Euzéby, J.** - Les parasits agents de dermatoses humaines d'origine zoonosique et leur role pathogene. Etiologie, Epidémiologie, Caractères cliniques, Contrôle, Ed. Merck-Sharp Dohme Chibret, Paris, 1999
8. **Kettle, D.,S.** - Medical and veterinary entomologie, Ed.II, Australia, CAB International, 1995
9. **Lungu T., Vartic N., Dulceanu N., Cosoroabă I., Şuteu I.** - Parazitologia şi clinica bolilor parazitare la animale. Ed. Did. şi Ped., Bucureşti, 1983
10. **Mitrea, I.L.** - Boli parazitare la animale. Ed. Ceres, Bucureşti, 2002
11. **Skolka, M**. – Zoologia neveretebretelor, vol. I-II, Ovidius University Press, Constanța, 2003
12. **Solcan Gh., Mitrea I.L., Miron L., Solcan Carmen** - Dermatopatologia animalelor de companie, Ed. Ion Ionescu de la Brad, Iasi, 2003.

INVESTIGATION CONCERNING THE INFLUENCE OF BIOTIC AND ABIOTIC FACTORS ON THE INCIDENCE AND PREVALENCE OF CANINE DEMODICOSIS

Al. D. CHESLER,[1] M.D. CODREANU,[2] I. DUCA,[2] Iuliana CODREANU,[2] A. BÎLBĂ,[1]
[1]S.C. Univet Constanta (chesler.alexandru@yahoo.com),
[2]Faculty of Veterinary Medicine, Spl. Independenței,
No.105, , Bucharest (codveterinary@yahoo.com),

ABSTRACT
Results on the frequency of canine demodicosis shows no differences between males and females, both sexes are equally affected: 336 cases diagnosed in females (50, 30%) and 332 in males (49,70%).
Regarding the race, the highest incidence we registered in mixed breeds - 169 cases (25.30%) We diagnosed 85 cases in German Shepherds breed (12.72%) and 48 cases on Spanish Cocker (7.19%).
The demodicosis highest incidence was noticed in puppets (434 cases - 65%). The incidence decreases with age, and it is estimated at 0.44% (three cases) in dogs over the age of 10 years.Analyzing the dynamics of incidence of Demodex canis infestation in relation to climatic factors, it appears that temperature does not influence the number of recorded cases of demodicosis.

Key words: dogs, biotic and abiotic factors, demodicosis

Throughout the study period, demodicosis maintains second position in the standings dermatological diseases, without being able to make a correlation between the three values: number of dogs examined the rate and incidence of skin diseases acariosis. Findings the demodicosis incidence in dog population from Constanta city, during the five years of study, we considering the place they occupy the acariosis in the structure of skin diseases and the influence of biotic (race, gender and age) and abiotic factors (climatic factors) on the extension of these disease.

MATERIAL AND METHODS

Our studies were made on a population consisting of 7705 dogs examined at veterinary clinic "Univet" - Constanta and the kennel "Interpet" of Palazu Mic, from 2003 to 2008.
Of all examined dogs, we diagnosed skin disorder in 2038 animals, which represent 26.45%.
In our research, the main diagnostic methods used were: clinical diagnosis method, scrape method, pathological diagnosis method and immunological investigations.

RESULTS AND DISCUSSIONS

One of the most important predisposing factors in epidemiology demodicosis is the age (2, 8, 12).Unanimous opinion of the authors is that demodicosis is a disease of young dogs, making his clinically debut, usually, between three months and one year (3, 4, 5, 9, 11).

The disease occurs in adult dogs and even in older ones, but with a much lower incidence and predisposing factors (2, 7, 10). Demodicosis highest incidence is noted in puppets (434 cases - 65%), it decreases with age, and is estimated at 0.44% (three cases) in dogs over the age of 10 years (Chart No.1). In 1-2 years age group, the incidence recorded value of approximately three times smaller (154 cases, 23.05%) compared to the puppets and three times higher values of the class 2-3 years (47 cases, 7.03%). Demodicosis incidence between 3-6 years is low (3.89%) dogs aged 6-10 years are even less affected (10 cases - 1.49%).

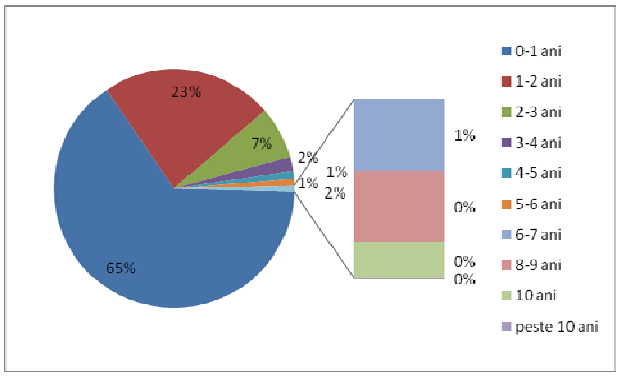

Chart No.1 - Demodicosis incidence by age

Correlation between age and sex shows that males demodectic dogs are most affected at the age group 0-1 year (218 cases) and over the age of five years (7 cases) but to point out semniticative differences in females, in the same category of age (218 cases, 5 cases).

We studied age issues and clinical form of the disease in dog and we obtained the following results: of 434 cases diagnosed with demodicosis (in puppets) in the majority clinical form was localized (79.03%) (Chart No. 2), 43 puppets showed generalized demodicosis (9.91%) (Chart No. 3) and the remaining percent showed pyodemodicosis (11.06%) (Chart No. 4).

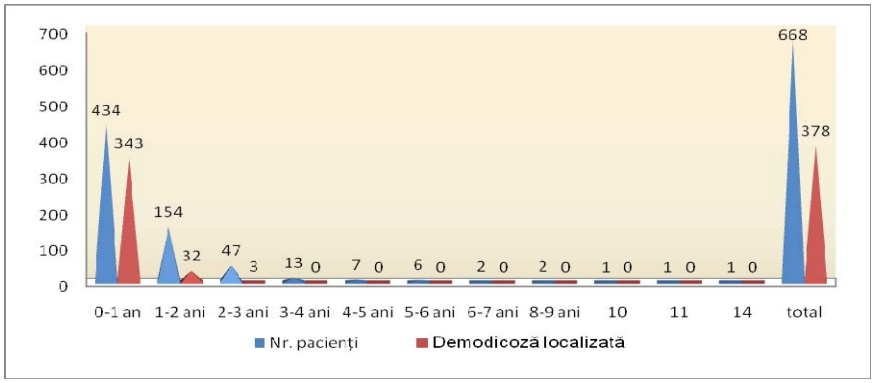

Chart No.2 - The local demodicosis incidency

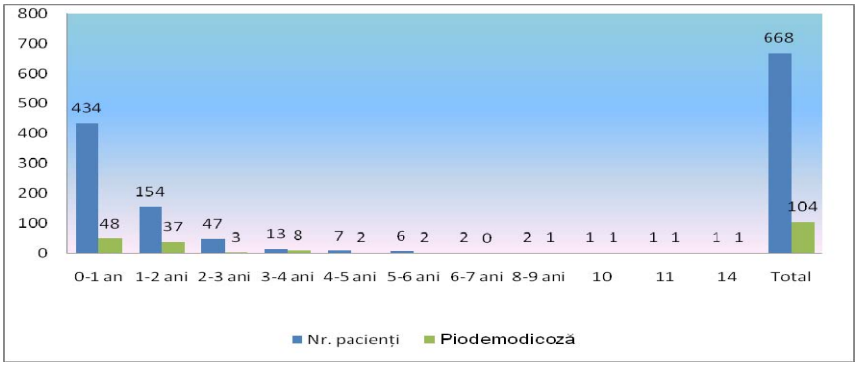

Chart No.3 - The pyodemodicosis incidency

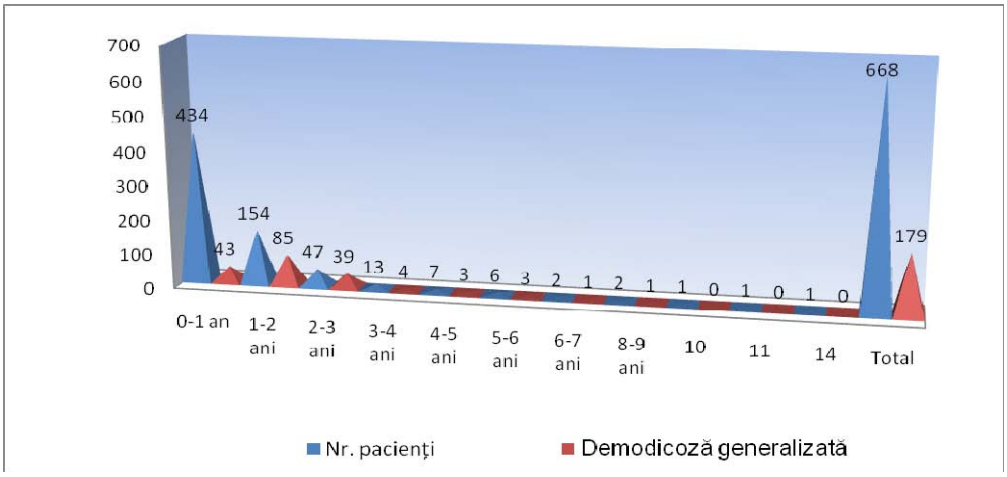

Chart No. 4 - The generalised demodicosis incidency

Regarding the influence of biotic and abiotic factors on the incidence and prevalence of canine demodicosis, annual growth rate of parasitosis is linked, obviously, with temperature and relative humidity (2, 7, 12); on the other hand, dynamic monthly acariosis present inconsistencies with abiotic factors, with some small exceptions. These survey results conducted in a population of 668 demodectic dogs, over a period of 60 months, led us to some interpretations and discussions.

Results obtained by associating the number of cases with mean monthly and annual abiotic factors/climatic (temperature, relative humidity and precipitation) revealed particular aspects (Table 1).

Table 1

The annual incidence of demodicosis depending on climatic factors/abiotic

Nr. crt.	Year	No. of cases	The average of the annual temperature (ºC);	Annual average relative humidity (%)	Average annual precipitation (l • m-2)
1	**2003**	153	10,97	73,92	554,60
2	**2004**	84	11,30	70,08	671,83
3	**2005**	184	12,43	76,75	296,30
4	**2006**	97	11,32	70,91	774,20
5	**2007**	150	12,25	72,90	572,80

TOTAL 668

In 2005 when the highest incidence of disease (184 out of 668 affected dogs, representing 27.54% of cases analyzed in this view), average annual temperature was the highest (12.43°C), associated with a relative humidity recording also highest in the period under study (76.75%). Demodicosis high incidence is not correlated with rainfall in 2005 (Chart No.5 a).

Analyzing the dynamics of incidence of *Demodex canis* infestation in relation to climatic factors, it appears that temperature does not influence the number of recorded cases of demodicosis.

Relative humidity - closely related to rainfall, influence the incidence of *Demodex canis* mite infestation (Chart No.5, b and Chart No.5.c). It appears, for the period of study (2003-2008), that with increasing relative humidity, increase the number of dogs affected by the mite (correlation coefficient R2 = 0.98). Also, frequent and large rainfall led to decreased number of cases of demodicosis (correlation coefficient R2 = 0.97).

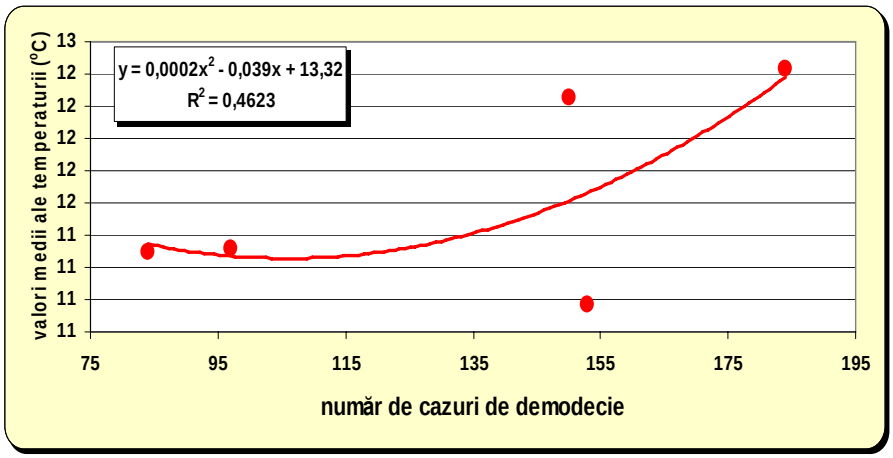

Chart No. 5. a - Number of cases of demodicosis

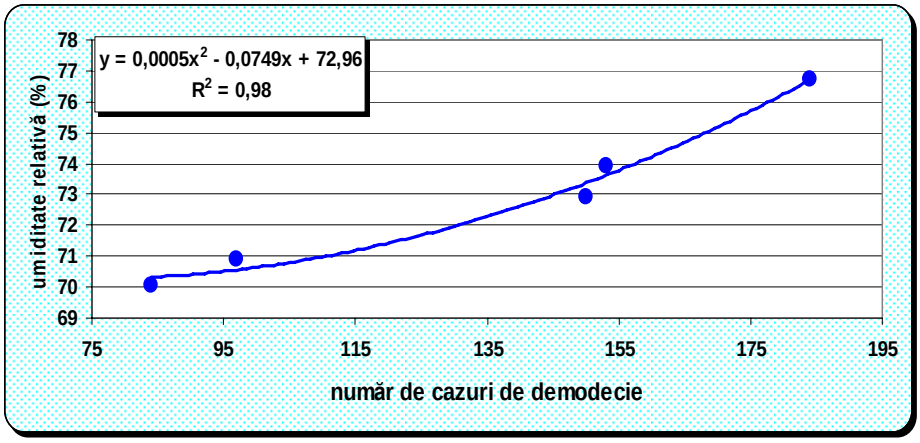

Chart No.5.b - Number of cases of demodicosis

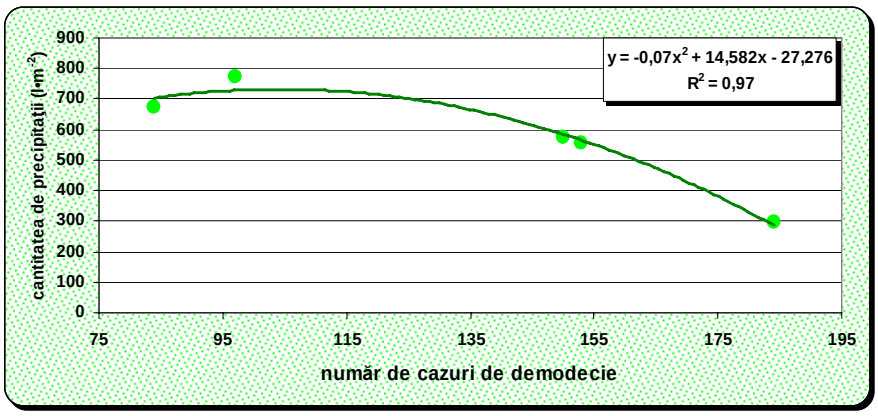

Chart 5.c – Number of cases of demodicosis

Chart No.5 - Correlation between incidence and climatic factors in demodicosis in dog:
a. temperature, b - relative humidity, c - rainfall

Maximum or minimum temperature and humidity can influence the overall condition of the host and thus indirectly influence deepening the parasitic attack.
Uneven distribution of casuistry in the five years of study, uneven births over that year, unable to establish the exact date of occurrence of first lesions, involvement of factors other than those included in the study (climatic factors, race, gender and age) were factors, which separately or together, have contributed to influencing the incidence and prevalence of canine demodicosis.

CONCLUSIONS

1. The results of the canine demodicosis frequency shows no gender differences between males and females, both sexes are affected equally.
2. The age of the dogs is an important epidemiological factor, the increased incidence demodicosis found it in dogs up to one year (64.97%) and it decreases with age.
3. Analyzing the dynamics of incidence of *Demodex canis* infestation in relation to climatic factors, it appears that temperature does not affect the number of recorded cases of demodicosis, with increasing relative humidity, increase the number of dogs affected by the mite (correlation coefficient R2 = 0.98), and frequent large rainfall led to decreased number of cases of demodicosis (correlation coefficient R2 = 0.97);

REFERENCES

1. **Bowman, D.,D., Lynn, R.,C.** - Georgy's Parasitology for Veterinarians, Ed. VI, W.B. Saunders Company, Philadelphia, 1995
2. **Chesler, A.,D., Codreanu, M.,D., Mitrea, L., Codreanu, I., Bîlbă, A.** – Studiu privind biologia acarienilor din genul Demodex, Revista Română de Parazitologie, 2008
3. **Cosoroabă I., Gh. Darabuş, I. Oprescu** - Compendiu de parazitologie veterinară. Vol. 1-2, Edit. Mirton, Timişoara, 1995
4. **Cosoroabă, I.** - Parazitologie veterinară, Ed. Mirton, Timişoara, 2000
5. **Cosoroabă, I.** - Parazitologie veterinară. Acarioze. Entomoze. Edit. Mirton, Timişoara, 2000
6. **Cosoroabă, L., Dărăbuş, Gh., Oprescu, L., Morariu, S.** - Diagnostic paraclinic şi tehnici experimentale în parazitologie. Edit. Mirton, Timişoara, 2002
7. **Euzéby, J.** - Les parasits agents de dermatoses humaines d'origine zoonosique et leur role pathogene. Etiologie, Epidémiologie, Caractères cliniques, Contrôle, Ed. Merck-Sharp Dohme Chibret, Paris, 1999
8. **Kettle, D.,S.** - Medical and veterinary entomologie, Ed.II, Australia, CAB International, 1995
9. **Lungu T., Vartic N., Dulceanu N., Cosoroabă I., Şuteu I.** - Parazitologia şi clinica bolilor parazitare la animale. Ed. Did. şi Ped., Bucureşti, 1983
10. **Mitrea, I.L.** - Boli parazitare la animale. Ed. Ceres, Bucureşti, 2002
11. **Skolka, M**. – Zoologia neveretebretelor, vol. I-II, Ovidius University Press, Constanța, 2003
12. **Solcan Gh., Mitrea I.L., Miron L., Solcan Carmen** - Dermatopatologia animalelor de companie, Ed. Ion Ionescu de la Brad, Iasi, 2003.

RESEARCH ON EFFICIENCY OF ” PRESYNCH-OVSYNCH” PROTOCOL ON COWS FROM HOLSTEIN BREED

C.A. CHIRUȚĂ,
S.C. CARMOLIMP S.R.L. chiruta_adrian@yahoo.com

SUMMARY

Artificial insemination of beaf cattle is a technology that allows producers to bring genetic improvement to their herds. Estrous synchronization is the technology that allows artificial insemination to occur more effectively and efficiently. Recent research has brought many new estrous synchronization systems and products. The OVSYNCH protocol was conceiwed and first used by Pursley et al in 1995. This protocol is most used to synchronize ovulation to heifers and cows, with a higher efficiency rate for the first. Research results showed that conception rate in cows synchronized with OVSYNCH protocol is higher to cyclic cows and lower to anestric cows. Fot this reason in this protocol was added a PRESYNCH protocol composed by a single or two prostaglandin administration. The purpose of this study is to test OVSYNCH protocol efficiency used for estrus synchronization on cows from Holstein breed, diagnosed with endometritisw and anestrus 35 days after calving. The researchs had the folowing results: the percentage of cows that showed heat synptoms, increased in the following order: PG1 (40%), PG2 (52%), OVSYNCH (68%); conception rate (CR) to the first insemination had a good level (57%); the healing rate was highest after the first treatment (54%), lower after the second treatment (26%) and 20% of cows were diagnosed with endometritis after two treatments; them anagement of calving-first insemination period is difficult for cows with anestrus and endometritis; this protocol proved its viability for cows with anestrus and endometritis 35 days after calving (Holstein breed).

Key words: presynch, ovsynch, anestrus, endometritis,

Artificial insemination in cattle is technology that can obtain genetic progress over generations. Once obtained, the synthetic hormones with effect on heats induction (prostaglandin, GnRH analogue, HCG, PMSG), were used to estrus synchronization (*Blowey R.W, 2000).*In the farms specialized in milk production and in the reproduction farms (specialized to obtaining and selling pregnant heifers) the estrus synchronization is commonly used. In the ”meat” farms synchronization are made during May-September period, from economic reasons (calvings synchronization and the best time for market bulls) and sanitar-veterinary reasons (more favorable condition for birth and growth in January-May period). Synchronization protocols and products used have evolved in the recent years and have been used more frequently in large farms. Although the hormonal products used to induce heat are the same (GnRH analogues, prostaglandin F2α, extrapituitary gonadotropins), the protocols efficiency is given by the combination and intervals between administration time (*Pursley, J. R et al 2005).* The ”OVSYNCH” protocol was conceiwed and first used by Pursley et al in 1995 composed of two doses of GnRH analogue administrations separated by a single administration of prostaglandin with next variations: days 0-7-9-10(AI) or 0-7-10(AI) and artificial insemination at 72-90 hours after prostaglandin administration (cows), 60-72 hours (heifers) or 16-18 hours after the second GnRH administration (*Portaluppi MA,* et al.. 2005).This protocol is most used to synchronize ovulation to heifers and cows, with a higher efficiency rate for the first. The conception rate to OVSYNCH protocol is varriably (with TAI or

insemination at second GnRH administration) between 40 et 55% CR at first insemination (*Brusveen DJ et al., 2006)* . Research results showed that conception rate in cows synchronized with OVSYNCH protocol is higher to cyclic cows and lower to anestric cows. Fot this reason in this protocol was added a single administration of prostaglandin, 12 or 14 days before (PG single shot) or two administration at 14 days interval (PG double shot) 12 days before OVSYNCH and was called PRESYNCH. The principal reason of this protocol is to induce heat in cows subjected to synchronization. The PRESYNCH protocol induce heat to 65-90% of cows synchronized (Stevenson J.S et al. 2007). The purpose of this study is to test OVSYNCH protocol efficiency used for estrous synchronization on cows from Holstein breed, diagnosed with endometritisw and anestrus 35 days after calving. Was calculated percentage of heat rate after first, second administration of prostaglandin and after OVSINCH protocol, healling rate after first and second treatment, conception rate at first artificial insemination.

1. MATERIAL AND METHOD

The study was conducted from December 1, 2009 to Aprilie 15, 2010 on a total of 50 cows from Holstein breed maintained in loose housing and monitored through a computerized management system of the type AfiFarm. The cows are multiparous (40 in second lactation and 10 in the fourth lactation), the AfiFarm program recording date and makes statistics (daily activity, milk production, electric conductivity, milkyng time, gynecological diagnosis)

The study considered only animals that not showed heat up to 35 days after calving (based on the activity record and confirmed by observation and transrectal examination). All cows were diagnosed by transrectal examination (performed 20 days postpartum) with different types of endometritis classified by leakege score (2,3,4 and cloudy mucus). Clinical signs for type 2 of endometritis: purulent discharge with mucus and no umpleasant odor; endometritis type 3: semileaking discharge, with mucus, jelly and fetid odor; endometritis type 4: cows with liquid discharge, brown with remnants of uterine placenta and fetid odor; cloudy mucus: with variable intensity and uniform dispersion. Cows diagnosed with endometritis at 10-20 days postpartum were treated with a combination of oxytetracicline 95%, hidrosoluble (3g), AD3E liposoluble vitamins (10 ml) and psyhological solution to 100 ml, a single administration (uterine infusion). In case of placentar retention were administered cloprostenol (2 ml) and oxytocine (6 ml) until the placenta was removed, but not more than three days. The folowing protocol was applied in the experimental group:

- 35 days PP – first cloprostenol administration, 500 micrograme (2 ml, i.m.Estrumate).
- 46 days PP - second cloprostenol administration, 500 micrograme (2 ml, i.m.Estrumate).
- 60 days PP - day 0 – buserelin acetate administration (2,5 ml i.m.Receptal)
- 67 days PP – day 7 – cloprostenol administration, 500 micrograme (2 ml, i.m.Estrumate)
- 69 days PP – day 9 – buserelin acetate administration (2,5 ml i.m, Receptal)
- 70 days PP – day 10 – I.A. (16 hours of the GnRH administration)

After each administration of cloprostenol are detected cows with heats symptoms and each animal is individually examined and classified by the leakage scor:

- OK PP – clear mucus, bright
- NOK – no mucus

- E2, E3,E4, cloudy mucus

Diagnosed endometritis are treated with procaine benzyl penicillin G (1g), dihydrostreptomicyn (1 g=50 ml PenStrep) and cefapirin (500 micrograms=1Metricure), a single administration. Cows diagnosed with endometritis to the first cycle after treatment will be treated with the same combination. Was calculated the healing rate after the first treatment,and the second, the percentage of cows inseminated after OVSYNCH, conception rate to the first insemination.

2. RESULTS AND DISCUSSION

The study was conducted on a total of 50 cows from Holstein breed, in the second and fourth lactation, diagnosed with endometritis at 20 days postpartum, wich were subjected to ”PRESYNCH-OVSYNCH” protocol (tabel 1). Average yield of cows in this study was 33,2 liters/day (10500/lactation).

Tabel 1

Composition of the experimental group

	LACTATION		
n	II	IV	Average yield l/day
50	40	10	33,2

Number of cows detected with endometritis at the heats simptoms was 35 (70%), after treatment (intrauterin infusion) healing rate was highest after the first treatement (54%) and lower (26%) after application of the second. A total of seven cases were not cured after two treatmets, representing 20% of cases (tabel 2).

Tabel 2

Healing rate after the first two treatments

	n	%
Total (cows with endometritis)	35	100
OK PP after the first treatment	19	54
OK PP after the second treatment	9	26
Endometritis after two treatments	7	20

Persistence of endometritis in 20% of cases is explained by the selection and presence of pathogens resistant to penicillin and the first generation of cefalosporins.

Folowing PRESYNCH protocol 40% of cows (n=20) showed estrous after first prostaglandin administration, 52% (n=26) after the second prostaglandin administration. After application of OVSYNCH protocol 68% (n=34) of cows were in heat after the second injection of GnRH analogue, and 2% (n=1) after the first administration.

Tabel 3

PRESYNCH-OVSYNCH *protocol results*

		PRESYNCH		OVSYNCH		
		Pg1	Pg2	GnRH 1	Pg	GnRH 2
HEAT	n	20	26	1	-	34
	%	40	52	2	-	68
ENDOMETRITIS	n	11	17	-	-	7
	%	22	34	-	-	14
IA	n	-	-	1	-	27
	%	-	-	2	-	54
CR	n	-	-	1	-	15
	%	-	-	100	-	55

The incidence of endometritis diagnosed to the estrus cycle was 22% (n=11) after the first prostaglandin administration, 34% (n=17) after the second administration and 14% (n=7) after OVSYNCH protocol (second GnRH administration). Number of cows inseminated at the end of the protocol was 27, representing 54% of experimental group (n=50) plus another 2% (n=1) inseminated after the first GnRH administration (tabel 3). Conception rate (CR) to the first artificial insemination wass 55% at the end of OVSYNCH protocol (57% in total), representing a total of 16 cows diagnosed pregnant at 50 days after artificial insemination (fig.1).

PRESYNCH OVSYNCH protocol efficiency

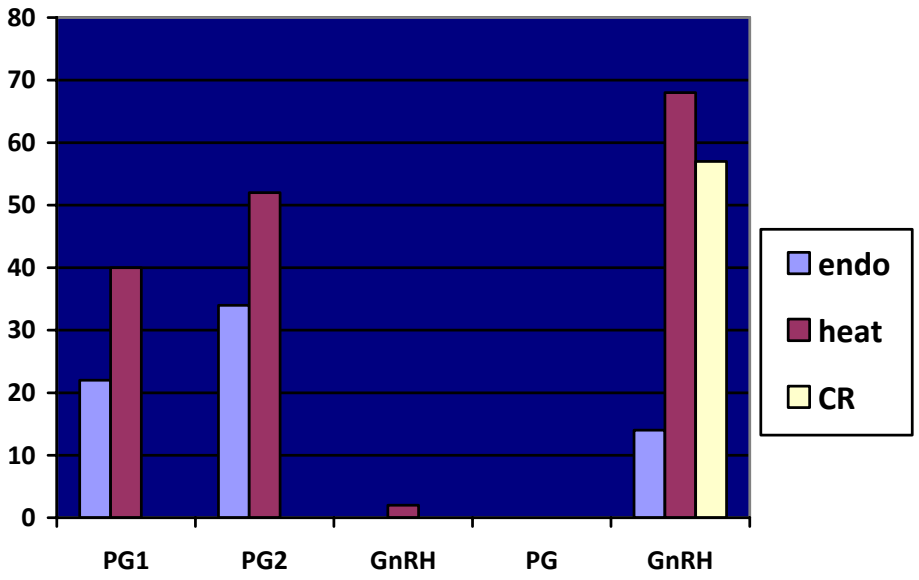

Fig.1

Results of the synchronization protocol PRESYNCH OVSYNCH for group in study led to the idea that it can be used successfully to cows from Holstein breed, diagnosed with clinical endometritis and anestrus at 35 days pospartum examination. The purpose of the protocol was double: managing the period 35 days postpartum-first artificial insemination by

synchronizing heats and therapy of endometritis. A disadvantage of this protocol application is the relatively high cost of hormonal products (10 euro) plus the costs of lost milk from cows treated with antibiotics. Protocol application is still usseful in large farms were calving-first artificial insemination period management is difficult.

3. CONCLUSIONS

3.1 Management of calving-first insemination period is difficult for cows with anestrus and endometritis.

3.2 Percentage of cows that showed heat synptoms, increased in the following order: PG1 (40%), PG2 (52%), OVSYNCH (6 8%).

3.3 Conception rate (CR) to the first insemination had a good level (57%).

3.4 Healing rate was highest after the first treatment (54%), lower after the second treatment (26%) and 20% of cows were diagnosed with endometritis after two treatments (probably germs resistant to the action of benzil penicillin G, dihydrostreptomycin, cefapirin).

3.5 This protocol proved its viability for cows with anestrus and endometritis 35 days after calving (Holstein breed)

BIBLIOGRAPHY

1. *Blowey R.W.*- A Veterinary book for dairy farmers, third edition, Farming Press, Ipswich, 2000
2. *Portaluppi MA,* Stevenson JS. 2005-Pregnancy rates in lactating dairy cowsafter presynchronization of estrous cycles and variations of the Ovsynch protocol.J Dairy Sci. 88:914-21.
3. *Brusveen DJ, Cunha AP, Silva CD, Cunha PM, Sterry RA, Silva EPB, GuentherJN, and Wiltbank MC.* 2006 - Effects on conception rates of lactating dairy cowsby altering the time of the second GnRH and AI during Ovsynch. J. Dairy Sci. 89,Suppl. 1. Page 150, Abstract 204
4. Stevenson J.S., Kobayashi Y. and. Thompson K.*E* - Reproductive Performance of Dairy Cows in Various Programmed Breeding Systems Including OvSynch and Combinations of Gonadotropin-Releasing Hormone and Prostaglandin F2a, Journal of Dairy Science Vol. 82, No. 3, 2007.
5. *Pursley, J. R., M. C. Wiltbank, J. S. Stevenson, J. S. Ot*tobre,H. A. Garverick, and L. L. Anderson- Pregnancy rates per artificial insemination for cows and heifers inseminated at asynchronized ovulation or synchronized estrus. J. Dairy Sci. 80: 295–300, 2005.

DIROFILARIA REPENS INFECTION PREVALENCE IN HUNEDOARA COUNTY

Roberta CIOCAN, Gh. DĂRĂBUŞ, M.S. Ilie, Mirela IMRE, Ionela HOTEA
Faculty of Veterinary Medicine Timisoara
Calea Aradului, No. 119, 300645, Timisoara, Romania
E-mail: roberta.ciocan@yahoo.com

SUMMARY

In this epidemiological study the prevalence of Dirofilaria spp. infection in dogs from Hunedoara County, Romania, was determined. A total of 92 blood samples were collected from shelter dogs in Deva. Blood samples were examined by modified Knott method and ELISA (D. immitis) (EVL Netherlands). Using Knott modified method two samples were positive for D. repens infection with a prevalence of 2.17%. At ELISA plate reading no blood sample was positive for D. immitis infection.

Keywords: *D. immitis*, *D. repens*, Knott, ELISA, dogs

The nematodes of *Dirofilaria* genus appertain to *Onchocercidae* family, *Dirofilariinae* subfamily, *Spirurida* order (1). *Dirofilaria* genus is divided in two subgenus: *Dirofilaria* subgenus which includes *Dirofilaria immitis* and *Nochtiella* subgenus which includes *Dirofilaria repens* (8).
Dirofilariosis is a parasitosis caused, in dogs, by the nematodes: *Dirofilaria* spp., *Dipetalonema* spp. and *Brugia* spp. Of these species, *D. immitis* has a specific importance due to the cardiac location of the adults (18).
Subcutaneous dirofilariosis caused by *Dirofilaria (Nochtiella) repens* is a helmintic zoonosis with wide distribution in Europe, Asia and Africa, reported with high frequency in humans (13) and in dogs (15).

MATERIALS AND METHODS

Blood samples were collected in June 2009 from a total amount of 92 dogs from Hunedoara County. Dogs tested lived in shelter. Blood samples were examined using two methods: ELISA and modified Knott method.
The research was carried out at the Department of Parasitology and Parasitic diseases of the Faculty of Veterinary Medicine Timisoara in July 2009.
From Hunedoara County shelter 50 dogs were male and 42 were females, aged between 7 months and 12 years. Blood was collected in EDTA and biochemistry vaccutainers.
Blood samples collected were evaluated for the detection of microfilaria using a concentration method: modified Knott method, on July 1, 2009.

Knott modificated method (Knott, 1939)

A quantity of 1 ml blood on EDTA is added to 9 ml of 2% formalin and centrifuged for 5-8 minutes at 1500 rpm. The supernatant is decanted from the centrifuge tube and the sediment is mixed with equal parts of methylene blue dye1:1000. The colorized sediment is smeared on

a slide, covered with another slide and examined at the microscope (10X and 40X objective) (Fig. 1).

The presence of adult nematodes was observed using specific antigen test ELISA (EV L Netherlands), which is based on identification of circulating antigens of adult female *D. immitis*. Processing of blood samples by ELISA was performed on July 2, 2009. Heartworm antigen test kit used was kit (*Dirofilaria immitis*) (EVL Netherlands) containing monoclonal antibodies for the determination of *D. immitis* antigen, from serum or plasma of dogs.

Kit's principle is based on the reaction of two monoclonal antibodies anti-*Dirofilaria* with *D. immitis* antigen. One monoclonal antibody, with which is lined the ELISA plate capture *Dirofilaria* antigens from serum/plasma, while the second antibody, enzyme labeled antigen determines the value limits.

RESULTS AND DISCUSSIONS

At the examination of the blood samples, microfilarias were identified in 2 of the 92 dogs examined, which means that the prevalence of dirofilariosis in dogs from our study was 2.17%.
Morphological examination of microfilaria isolated from the two dogs by modified Knott method, showed no cephalic hook, anterior end slightly conic and filiform caudal end, shaped like umbrella handle.
Modified Knott method is considered the reference method for microfilaria research, the most accurate method of differentiating the larvae of *Dirofilaria* spp, suitable for measuring length and thickness of microfilaria. This method is preferred as the formaldehyde fixed microfilaria extension allowing their measurement. The disadvantage of this method is that it takes time and experience (5, 7, 16).
Significant diagnostic importance for the presence of adults in *Dirofilaria* infections has the detection of microfilariae in the blood of dogs (17). The most important symptoms of subcutaneous dirofilariasis, which is an illness conditioned by underlying predisposing factors (babesiosis, leishmaniosis, ehrlichiosis, stress), are itching and skin sores (15). Subcutaneous dirofilariasis can be diagnosed in the presence of pruritic dermatitis, of the finding of *D. repens* microfilaria in the bloodstream and a negative result of the test for circulating *D. immitis* antigens (15).

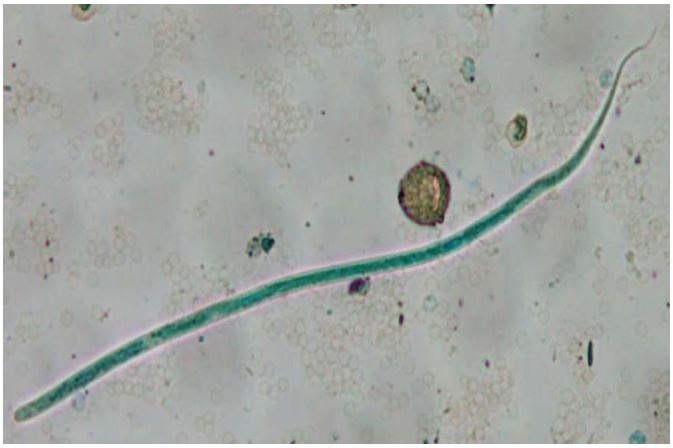

Fig. 1 *D. repens* larvae from a dog examined with modified Knott method, 10X, objective Olympus microscope (original).

Using ELISA test, a sample is considered positive when optical density (OD), obtained by reading is greater than the negative control and has at least the value of 0.300. All values obtained below the threshold of 0.300 are considered negative. Optical density of positive control must be at least 0.800.

At ELISA plate reading no results were positive for *Dirofilaria immitis*, all blood samples were negative.

ELISA tests can not detect directly the presence of parasitic elements, but the host response to them. These tests can be used to distinguish between *D. immitis* and *D. repens*. Also, they are used to detect occult dirofilariosis forms, characterized by the absence microfilaria in peripheral blood (5). These methods are useful in diagnosis of Dirofilariosis but will not be used as the unique method of diagnosis. For best results the presence of 2-3 adult females is necessary, because males cannot be detected. In dogs, antigens can be detected in blood to 5 - 6.5 months post infection. It is recommended retesting after 6 months (10).

The infections caused by filarial nematodes in dogs and cats are apparently spreading in different geographic areas, in the past decads (3, 9). Indeed, the distribution of *Dirofilaria* spp. in different European countries has been attributed to several factors including the introduction of new species of mosquitoes *Aedes albopictus*. Eventhough it has yet to be proven that the "tiger mosquito" is responsible for new and/or spreading foci of infection (2, 4, 6, 11, 12, 14).

CONCLUSIONS

- ✓ The prevalence of *D. repens* infection obtained by modified Knott method in dogs tested was 2.17%.
- ✓ All blood samples examined by ELISA (*D. immitis*), were negative.

REFERENCES

1. **Anderson R.C**. - Nematode parasites of vertebrates, their development and transmission. 2nd Edition, CABI Publishing, Wallingford, UK, 2000:650.
2. **Cancrini, G., Frangipane di Regalbono, A., Ricci, I., Tessarin, C., Gabrielli, S., Pietrobelli, M**. - *Aedes albopictus* is a natural vector of *Dirofilaria immitis* in Italy. Vet. Parasitol. 118, 2003: 195–202.
3. **Genchi, C., Rinaldi, L., Cascone, C., Mortarino, M., Cringoli, G**. - Is heartworm disease really spreading in Europe? Vet. Parasitol. 133,2005: 137–148.
4. **Gratz, N.G**. - Critical review of the vector status of *Aedes albopictus*. Med. Vet. Entomol. 18, 2004: 215–227.
5. **Hendrix, C.M., Robinson, E. –** Diagnostic parasitology for veterinary technicians, ed.3, St Louis, Mosby, 2006:229.
6. **Knols, B.G.J., Takken, W**. - Alarm bells ringing: more of the same, and new and novel diseases and pests. In: Takken, W., Knols, B.G.J. (Eds.), Emerging Pests and Vector-Borne Diseases in Europe. Wageningen Academic Publishers, 2007: 13–19.
7. **Knott, J**. - A method for making microfilarial survey on day blood. Trans. R. Soc. Med. Hyg. 33, 1939:191–196.
8. **Maria Teresa Manfredi, Annarita Di Cerbo, Genchi M**. - Biology of filarial worms parasitizing dogs and cats. Mappe Parasitologiche 8, 2007: 41.
9. **McCall, J.W., Genchi, C., Kramer, L.H., Guerrero, J., Venco, L**. - Heartworm disease in animals and humans. Adv. Parasitol. 66, 2008: 193–285.
10. **Mccall, J.W., Supakorndej, N., Donoghue, A.R., Tumbull, R.K., Radecki, S.V.** – Evaluation of the performance of canine heartworm antigen test kits licensed by diagnostic laboratories. In

Recent advances in Heartworm disease: Symposium '01" (R.L. Seward, ed), American Heartworm Society Batavia Illinois, 2001:97-104.

11. **Otranto, D., Dantas-Torres, F., Breitschwerdt, E.B.** - Managing canine vector-borne diseases of zoonotic concern: part one. Trends Parasitol. 25, 2009a :157–163.
12. **Otranto, D., Capelli, G., Genchi, C**. - Changing distribution patterns of canine vector borne diseases in Italy: leishmaniosis vs. dirofilariosis. Parasit. Vectors (Suppl. 1), 2009b.
13. **Pampiglione, S., Rivasi F., Angeli G., Boldorini R., Feyles E., Garavelli P.L., Incensati R.M., Maccioni A., Pastormerlo M., Pavesi M., Ramponi A., Valdès E., Vetrugno M. -** Quadri istopatologici della dirofilariasi umana da *Dirofilaria repens*. Atti Congr SIAP-IAP Bolzano May 24-27, 2000: 2-3.
14. **Scholte, E.J., Schaffner, F**. - Waiting for the tiger: establishment and spread of the *Aedes albopictus* mosquito in Europe. In: Takken, W., Knols, B.G.J. (Eds.), Emerging Pests and Vector-Borne Diseases in Europe. Wageningen Academic Publishers, 2007: 241–260.
15. **Tarello, W**. - La dirofilariose sous-cutanée à *Dirofilaria (Nochtiella) repens* chez le chien. Revue bibliographique et blinique. Rev Méd Vét 150, 1999: 691-702.
16. **Tarello, W**. - Dermatitis Associated With *Dirofilaria repens* Microfilariae in a Dog from Rome. The Veterinary Journal 165, 2003:175-177.
17. **Tarello, W**. - Cutaneous lesions in dogs with Dirofilaria(Nochtiella) *repens* infestation and concurrent tick-borne transmitted diseases. Vet. Dermatol. 13, 2002b: 267–274.
18. **Toparlak, M., Gargili M., Ulutas E.M., Cetinkaya H**. - Canine Filariosis Around Istambul, Turkey Employing Naphtol AS-TR Phosphatase. Acta Vet. Brno 74, 2005: 233-236.

SALPINX DISORDERS AS A FACTOR OF INFERTILITY IN COWS FOR MILK PRODUCTION

Şt. Gr. CIORNEI [1], L. RUNCEANU [1], D. DRUGOCIU [1], P. ROŞCA [1], V.D. PĂDURARU [1], C . BĂLU [2], GALAN C. [3], I. DOROBANȚU [3]

[1]F.M.V. Iaşi

[2]S.C. TIVAS IMPEX S.R.L. Vaslui

[3]DSVSA -Vaslui

Salpinx disorders are a cause for culling dairy cows due to generated infertility. This study aims to identify oviduct disorders at cows after sacrification. From 248 slaughtered cows 60.9% showed various genital tract disease and 9,27 % showed oviduct disorders. After the frequency of appearence: salpingitis (42,9%), perisalpingian adhesions (35,7%), hidrosalpinx (35,7%), parasalpingian cysts (14,3%) and abnormalities (7,1%). These problems were mono or bilateral, independent or asociated with other uterine or ovarian lesions.

Keywords: salpinx, patology, infertility, cow

Bovine genital tract inflammations cause significant economical losses due to increasing calving intervals, the cost of additional interventions, treatment and high rate of sacrifications [2,6,7,9,11].

In foreign literature there is a large amount of references regarding the etiology of cows infertility, but the ones regarding tubar sterility are relatively few [4,8,9,12].

One of the most important attributes of the oviduct is the transport of gametes, to ensure fecundation. Dynamic of salpinx activity is under hormonal control [4,12].

According to some authors, 52% of cattle slaughtered in the slaughterhouse had genital disorders. Oviduct disorders recorded 10%, and the ones with the higher frequency were the salpingitis and aderences with nearby organs.

Hatipoglu and colab. (2002), say that they meet only a 5.21% frequency of ovarien disorders and a 0.81% salpinx disorders, at Holstein and Swiss-Brown breeds, in some slaughterhouses from Turkey.

Other authors appreciate that the frequency in cows salpinx disorders is 8-10%, and the total amount of slaughtered cows due to genital disorders is between 55 and 60 percent [1,5,12].

MATERIALS AND METHODS

The research was conducted on a group of 248 cows slaughtered in a slaughterhouse from Vaslui county. The cows came from different breeds (Brown, BNR, Red-Holstein, H-F) and aged between 2,5 and 6 years. The cows came from two farms specialized in milk production, where nutrition and zooigiena conditions were in corresponding paramaters.

Macroscopic examinations sought to identify salpinx disorders, morpho-function and lesion appearance.

RESULTS AND DISCUSSION

After examining the genital apparatus of all slaughtered cows, we found that 151 had various lesions to the genital segment. So, a fairly large percentage of cull cows in milk production (60%), is related to genital disorders. These results are similar to those published in literature.

Remaining cows slaughtered in the slaughterhouse (39%) had no genital disorders, slaughter was an independent reason for their gynecological condition. Of these a proportion of 6.2% were pregnant at different stages of gestation.

After macroscopic examination, we found that salpinx disorders occur in 14 from 151 cases, representing 14 from 248 (5,64%).

In the following table are presented salpinx disorders in relation to breed and age of examinated cows. Salpingitis had the highest frequency (42,9%), followed by perisalpingian adhesions (35,7%), hidrosalpinx (35,7%), parasalpingian cysts (14,3%) and abnormalities (7,1%).

Table nr.1

Distribution of tubal disease

Nr. Crt	breed	Age (years)	Tubal disorders						Observations
			Salpingitis	Adhesions	Cysts	Hidrosalpinx	Abnormalities	Permeability	
1	B	2,5	right	-	-	-	-	-	Endometritis, hipotrophy
2	B.N.R.	3	-	-	-	-	double salpinx (right)	right	Infecundity
3	B	4	-	left/right	-	left/right	-	left/right	PCL left ov.(4,2 cm)
4	BNR	4,1	-	left	-	left	-	-	Luteal cyst left ov. (2,2cm)
5	B	6	right	-	-	right	-	-	LC left ov.(2cm)
6	RH	5,2	-	right	-	-	-	right	Perisalpingian adhesions
7	B	4	right	-	-	-	-	-	Purulent parametritis
8	B	2,3	-	-	Left	-	-	-	Left ov. cyst
9	BNR	3,2	right	-	-	-	-	left	Infecundity
10	H-F	3	-	-	right	-	-	-	Latent chronic endometritis
11	H-F	4,3	left/right	-	-	-	-	-	Ovarian cysts
12	H-F	2,6	-	right	-	-	-	right	infecundity
13	BNR	3	left/right	-	-	left/right	-	-	Ovarian cysts, pyometra
14	RH	4,1	-	right	-	right	-	-	Right periovaritis hipotrophy

The analysis of these data reveal that only in three cases salpinx lesions are not accompanied by other uterine disorders, that was the first reason of culling. Clinical, is very hard to diagnose a salpinx disease, that provides infecundity and sterility. To establish a diagnosis, datas must be combined with information from the history, the ultrasound and clinical examination of each case.

Gynaecological history is the most accurate method used to guide diagnosis of infertility, at milk producting cows. In this study, 21,4% from cases, came as the only clinical manifestation, the sindrom of infecundity, without other local or general associated simptoms. Note, that all these cases came positive at the test for tubal obstruction (fig. No. 6)..

Note, that test for identification of tubal obstruction came pozitive for 5 cases (35,7%). So, the migration of female and male gametes and zygote too, is imposible. Tubal permeability test was performed by air insufflation directly in the uterus horn.

Salpinx inflamation were found in 42,85 % from the cases, these represents the most frequent manifestation of injury at this level. Salpingitis were associated with other uterine disorders like: endometritis, piometra, parametritis (4 cases/66,6%) and ovarian diseases: persistent corpus luteum, ovarian cysts (3cases/50%). Salpingitis inflamations may be various from morpho-pathological point of view, and principal cause are upward or downward diffusion of inflammatory processes (fig. No.1). It appears that the inflamation is located with predilection in the right horn, this indicate an increased physiological activity at this level. A bilateral salpingitis was identified in two other cases.

Salpinx adhesions represents the existence of solutions of continuity between salpinx and surrounding tissue. We note fibrosis between salpinx and ovarus in many cases (ovarian-infundibulum adhesions), and less with meso or uterine horn. Adhesions were associated in high proportion with tubal obstruction. Adhesions were encountered on both the left and right side, but also bilateral (fig. No. 2).

These conditions lead to blocking the opening of the infundibulum, by fibrous tissue storage. Therefore eggs will be seized at this level and would be impossible to migrate downward. Finally it can lead to sterility and infecundity of those cows.

In a few cases (2/14;3%), have identified some cystic formations located on the salpingian wall (fig. No.3). Parasalpingian cysts have no known etiology, nor is it known whether they affect its functionality. We can say that in the examined cases, the test for tubal obstruction came negativ, so those cysts do not affect oviduct functionality.

Hidrosalpinx has often been observed unilaterally, right or left, but also bilaterally. This disease is an accumulation of fluid in lumen, after a inflamatory process or a stasis edema, that deforms the salpinx (fig. No. 4).

We identified one case of morphological abnormalities, double salpinx, on the right side of the genital tracts that we examined (fig. No. 5).

In some cases, clinical diagnosis was confirmed by examination after slaughter.

Repeated gynaecological investigations revealed a number of problems at different levels of reproductive tract: ovarian dysfunction, endometritis, salpingitis.

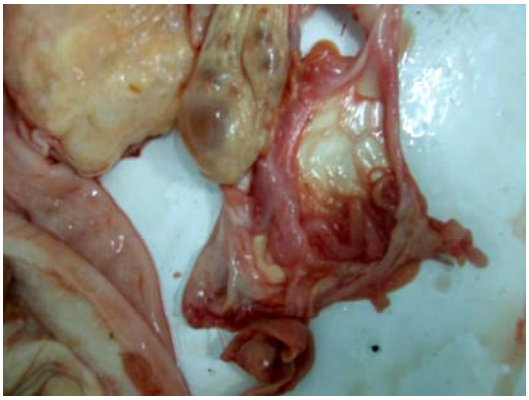

Fig. nr. 1. Salpingits
Congestia şi edemaţierea salpinxului unilateral

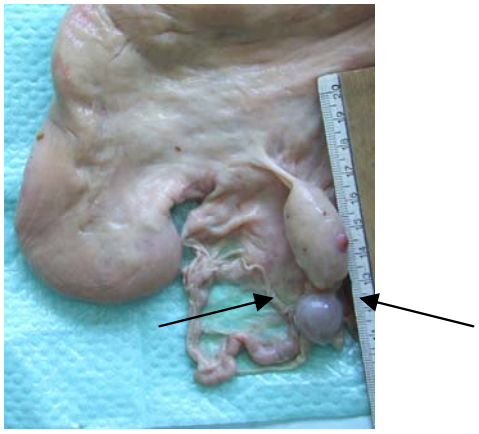

Fig. nr. 3. Perisalpingeal cysts

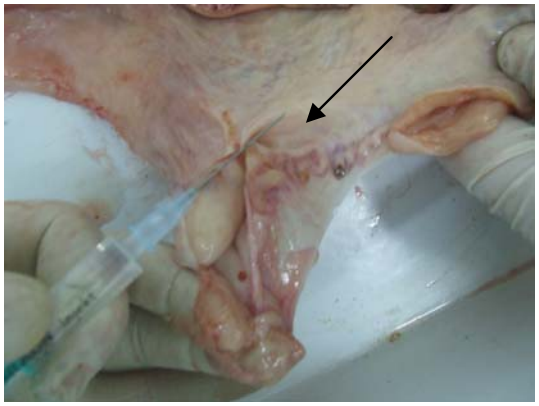

Fig. nr.2 A. Mezosalpingian aderence

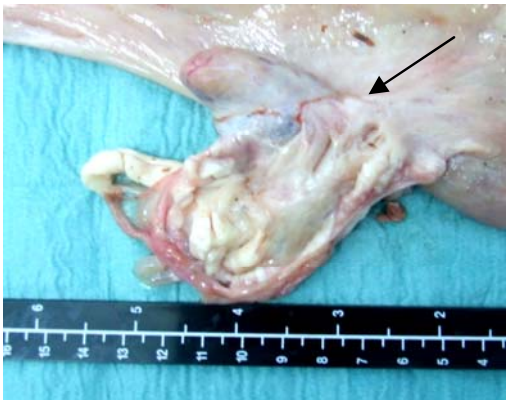

Fig. nr.2 B. Ovarobursal aderence

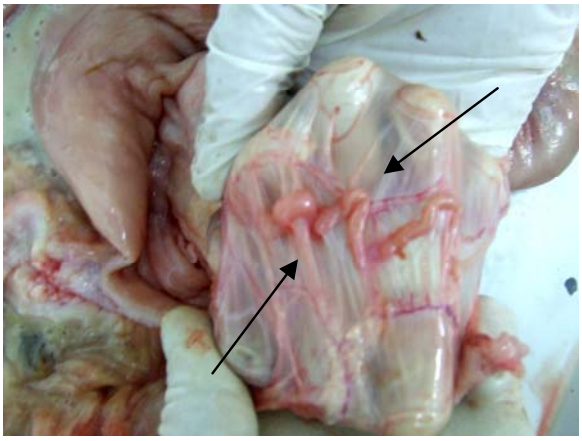

Fig. nr. 4. A. Hydrosalpinx unilateral

Fig. nr. 4. B. Hydrosalpinx bilateral

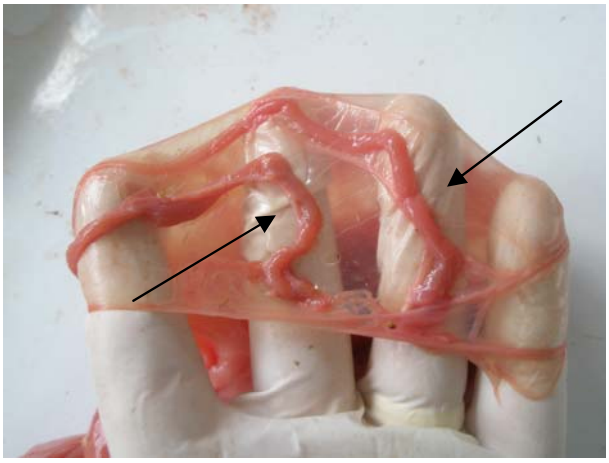

Fig. Nr. 5 Salpinx double

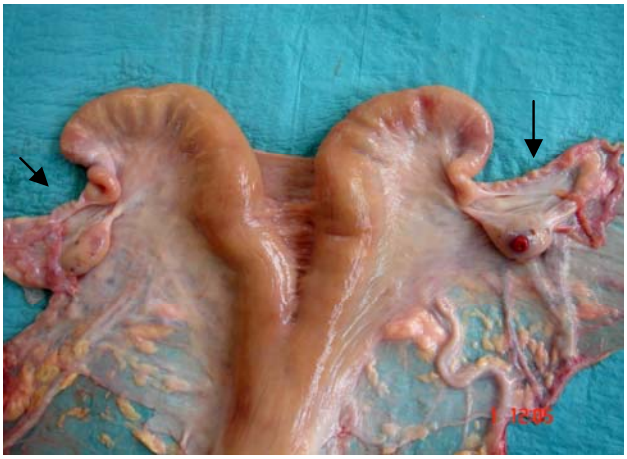

Fig. Nr. 6 Tubal obstruction

.

CONCLUSIONS

1. From 248 slaughtered cows, 60,9% had various diseases of the genital tract, of these, 9.27% of cows had salpinx lesions.
2. Gynecological history is the most accurate method used to guide diagnosis of infertility. In our study, 21.4% of cases examined, had as the sole clinical manifestation the infecundity syndrome, without other local or general associated symptoms. All these cases came positive at the test for tubal obstruction
3. We found salpinx inflammations in 42.85% from the cases. These represents the most frequent manifestation of injury at this level. Salpingitis were associated with other uterine disorders like: endometritis, piometra, parametritis (4 cases/66,6%) and ovarian diseases: persistent corpus luteum, ovarian cysts (3cases/50%).

BIBLIOGRAPHY

1. Al-Fahad TA, Alwan AF, Ibraheem NS., 2004 - Histological and morphological study of abnormal cases of female reproductive system in Iraqi buffaloes. Iraqi J Vet Sci; 18:109-115.6.
2. Alwan AF, Abdul-Hammed AN, Khammas DJ., 2001 - A macroscopical study of abnormal genitalia of Iraqi female buffaloes. Iraqi J Vet Sci.; 14: 129-132.
3. Azawi O. I., Ali A. J., Lazim E. H. 2008 – Pathological and anatomical abnormalities affecting buffalo cows reproductive tracts in Mosul, Iraqi Journal of Veterinary ciences, Vol. 22, No. 2, (59-67)
4. Drugociu D., (2005) – Bolile obstetrical-Ginecologice la animale. Ed. Ion Ionescu de la Brad, Iaşi
5. DURGUT, R., ERGÜN, Y., YAMAN, M. – 2003, Investigations on the Gross Hepatic, Pulmonary and Reproductive Lesions in Cows during an Abattoir Survey, Veteriner Cerrahi Dergisi (2003), 9 (1-2), 27-30
6. Gautam, G., Nakao, T., Yusuf, M., Koike, K., 2009. Prevalence of endometritis during the post-partum period and its impact on subsequent reproductive performance in two Japanese dairy herds. Animal Reproduction Science 10.
7. Gilbert, R.O., Shin, S.T., Guard, C.L., Erb, H.N., Frajblat, M., 2005. Prevalence of endometritis and its effects on reproductive performance of dairy cows. Theriogenology 64, 1879–1888.
8. Groza I. Şt. (2006) – Ginecologie, andrologie şi obstetrică veterinară Compediu, Ed. Academinei Române, Bucureşti
9. Hanzen Ch., Gautam G., Nakao T. - 2009, Prevalence of urovagina and its effect on reproductive performance in Holstein cows. Theriogenology, 71, 1451-1461.

10. Hatipoglu F., Ortatatli M., M.M. Kiran, Erer H., Çiftçi M.K., 2002 - An Abattoir Study of Genital Pathology in Cows :II. Uterus, Cervix and Vagina Revue Méd. Vét., 2002, 153, 2, 93-100

11. Knutti, B., Kupfer, U., Busato, A., 2000. Reproductive efficiency of cows with endometritis after treatment with intrauterine infusions or prostaglandin injections, or no treatment. Journal of Veterinary Medicine. A, Physiology, Pathology, Clinical Medicine 47, 609–615.

12. Runceanu L., and all., (2007) - Reproducție, obstretică şi ginecologie veterinară. ediția II –a, Ed. Ion Ionescu de la Brad, Iaşi.

BIOTECHNOLOGY RESEARCH ON RECOVERY, MORPHOLOGICAL ASSESSMENT AND VIABILITY TESTING OF CAT OOCYTES BEFORE AND AFTER "IN VITRO" MATURATION

Maria Simona CIUPE, I. Şt. GROZA, L. BOGDAN, Emoke PALL, Al. POP, Anamaria PETREAN, Sanda ANDREI, Sorana MATEI, Andrea CRIŞAN

Universitatea de Ştiinţe Agricole şi Medicină Veterinară Cluj-Napoca, Calea Mănăştur 3-5,
simona_ciupe@yahoo.com

ABSTRACT

Mammalian oocytes have the unique ability to continue maturation stages immediately after being released from the ovarian follicle that has hosted and provided them with development. This study aims to assess methods of collection of cat oocytes, the media used for maturation "in vitro" by cultivation on medium term and improve their original contributions. Also, we plan to improve the system for assessing the maturity and viability of oocytes before and after maturation through the correlation of the morphologic study and the correlation of the morphocytometry measurements using inverted microscope with intravital staining methods.
A total of 414 oocytes was collected from 46 ovaries, (23 ovariohysterectomy cats) in the clinic of the Reproduction, Obstetrics and Gynecology Department from Cluj Napoca. The assessment and classification of cat oocytes before and after "in vitro" maturation was based on the morphological examination and on the morphocytometry measurements made. Doing an overview of the results of a total of 312 oocytes cultured in two media, the morphologic examination revealed maturation to a number of 239 (76,60%), the remaining 73 (23,40%)) oocytes showing signs of degeneration. Revaluation of maturation process through morphocytometry, allowed accurate determinations process so that the total of 312 oocytes cultured in two culture media, 253 (81,10%) were considered mature the remaining 59 (18,90%), showing signs of degeneration or stagnation of development.

Keywords: cat, ovary, oocyte, in vitro maturation, morphocytometry.

MATERIALS AND METHOD

Research was conducted in January 2009 - March 2010, on a total of 414 oocytes collected from 46 cat ovaries from 23 cats, in the clinic of the Reproduction, Obstetrics and Gynecology Department from Cluj Napoca. Obtaining necessary to conduct research ovarian surgery was performed by ovaries ovariohysterectomy, one of the most common surgeries that are practiced on the genitalia of domestic carnivores being both an obstetric emergency and ass operation of convenience, the owner required to avoid subsequent gestation.
The ovaries were placed after surgery in a thermos collection bottle in 0.9% sodium chloride solution supplemented with 100 mm / ml streptomycin and 100 IU / ml penicillin at a temperature of 30-33 °C. Ovaries placed in "Petri" plates with washing medium (PBS) were passed three times in containers with fresh medium and then chopped with a scissors.

After identification and isolation, oocytes were subjected to morphological examination at stereomicroscope and inverted microscope.
The assessment and classification of cat oocytes before and after "in vitro" maturation was based on the morphological examination and on the morphocytometry measurements made.
The oocytes with the following morphological features were subjected to maturation: large diameter, integral ooplasma, dark pigmented, pellucida membrane integrity, cumulus cells had at least one layer around the oocyte. Maturation of oocytes was achieved by cultivation for 24 hours in two mediums : SOF (mSOF), supplemented with 10 µg/ml FSH, 10 mg/ml LH, antibiotics and TCM 199 medium supplemented with 10% FCS, 500 µl Na pyruvate and 500 µl antibiotics. In each culture plate there were placed 20-40 oocytes in 500 µl medium, under Sigma mineral oil. Cultivation parameters were: temperature 38 °C, in an atmosphere of 5% CO2, 5% O2 and 90% N2.
Quality classification of oocytes was performed after recovery and maturation through the stereomicroscope and inverted microscope. The morphocytometry of oocytes realised using the inverted microscope allowed us to determine the oocytes maturation depending on: diameter, crown radius thickness and pellucid membrane thickness.
For the assessment of the viability of cat oocytes after "in vitro" maturation, Trypan blue staining was used which allows the differentiation of cells by the capacity of viable cells to exclusion this dye. Before staining, the solution having a concentration of 0,4% was incubated for 2 hours at 37 °C. The oocytes were place in "Petri" plates in 300 µl Trypan blue solution 0,4% and were incubated at 37 °C for 15 minutes. After staining, oocytes were washed in PBS and there examined at inverted microscope.

RESULTS AND DISCUSSIONS

From the 23 cat ovariohysterectomies, 46 ovaries were collected and a total of 414 oocytes, the average is 9 oocytes per ovary. Of the 414 oocytes collected, after the stereomicroscopic morphological examination, 291 (70,30%) oocytes were included in cultivable category, the remaining 123 (29,70%) were considered no cultivable.
The inverted microscope examination of the 414 oocytes harvested were reclassified into four grades groups, 312 (75,36%) were in categories I and II, as the remaining 102 (24,63%) as III and IV were find considerate inappropriate for cultivation. (Fig.1).

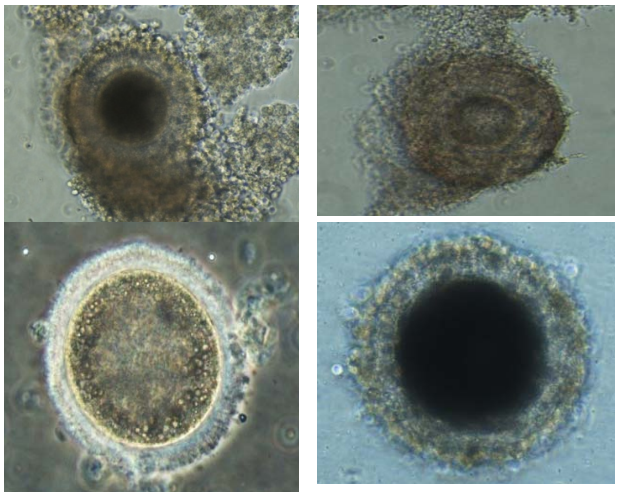

Fig.no. 1 Oocytes belonging to quality class I and II

There were used for "in vitro" maturation only classes I and II oocytes, and those in categories III and IV were excluded from experiment.
Comparing the results obtained by the two methods of assessment we noted that the inverted microscope method provides more accurate assessment opportunities. There is a difference of 5,07% cultivable oocytes between the two methods.
The morphocytometry of oocytes before "in vitro" maturation allowed establishing the oocyte diameter, crown radius thickness and pellucid membrane thickness. The average values of these measurements are presented in Table 1.

Table no. 1 Morphocytometry of growing oocyte before in vitro cultivation

Category of quality	Diameter of oocyte (average)	Pellucida membrane thickness (average)	Removed crown thickness (average)
Class I and II	75,7 µm	8,25 µm	17,6 µm
Class III şi IV	50,6 µm	5,8 µm	4,8 µm

"In vitro" cultivation of cat oocytes was performed in two culture mediums originally supplement for 24 hours. Stereomicroscope evaluation allowed morphological classification of oocyte quality into two categories: mature oocytes (expanded cumulus cells, smooth or slightly granular cytoplasm, uniform perivitelin space, pellucid membrane integrity) and degenerated oocytes (total or partial lost of cumulus cells, highly granular cytoplasm, uneven perivitelin space, broken pellucid membrane).
So, from a total of 156 oocytes cultured in mSOF medium supplemented with 10 µg/ml FSH, 10 mg/ml LH, and antibiotics, 127 (82%) showed signs of maturation, the remaining 29 (18,50%) suffering the degeneration processes or stagnation of development.
From the 156 oocytes cutured in TCM 199 medium supplemented with 10% FCS, 500 µl Na pyruvate and 500 µl antibiotics, 112 (71,70%) showed signs of maturation, the remaining 44 (28,3%) suffering the degeneration processes or stagnation of development.
Results demonstrate the superiority of mSOF medium in supporting maturation process, there are differences between the two averages of 10,3% in term of mature oocytes. (Graphic no. 1)

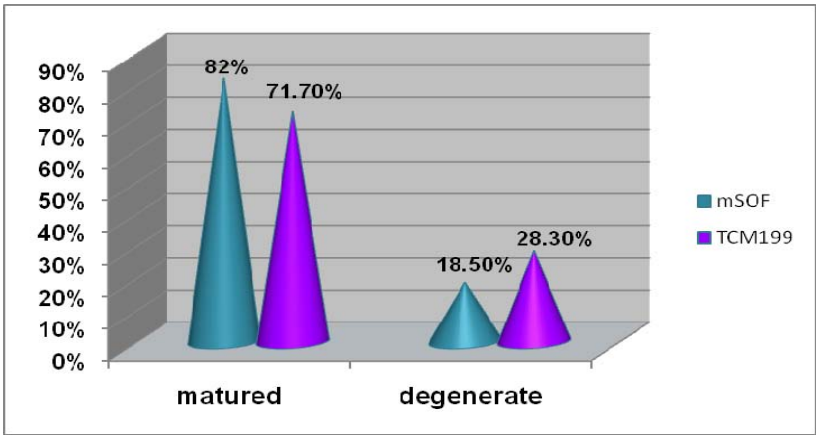

Graph no. 1 Results of in vitro maturation according to morphological examination

Morphocytometry measurements made on inverted microscope after "in vitro" cultivation of oocytes allowed determining the oocyte maturation depending on diameter, crown radius

thickness and pellucid membrane thickness. The average values of measurements made on mature oocytes are presented in Table 2.

Table no. 2 Morfocytometry of oocytes after in vitro cultivation

Growing medium	Oocyte diameter (average)	Pellucida membrane thickness (average)	Removed crown thickness (average)
mSOF and TCM 199	141,6µm	10.4 µm	252,3µm

Doing an overview of the results of a total of 312 oocytes cultured in two media, the morphological examination revealed maturation to a number of 239 (76,60%), (127 in mSOF medium, 112 in medium TCM 199) the remaining 73 (23,40%)) oocytes (29 respectively 44) showing signs of degeneration or stagnation of the development.
Revaluation of maturation process through morphocytometry, allowed accurate determinations process so that the total of 312 oocytes cultured in two culture media, 253 (81,10%) (135, respectively 118) were considered mature the remaining 59 (18,90%) (21 respectively 38), showing signs of degeneration or stagnation of development (Graphic no. 2).

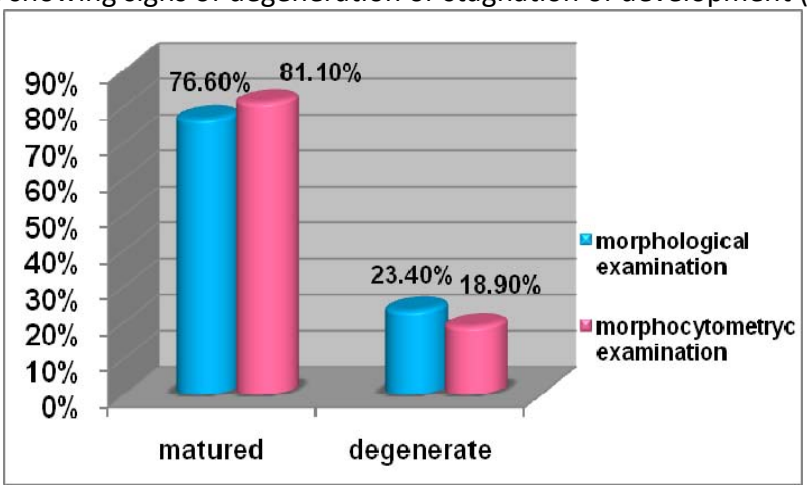

Graph. no. 2 Comparative results maturation degree between morphological and morphocytometryc examination

Measurements made, increases were noted in particular oocytes diameter and in the cumulus cells. Diameter of mature oocytes increased to 75,7 mm as the average before cultivation was 141,6 mm. Regarding the cumulus cells, these increased from 17,6 mm to 252,3 mm. Pellucida membrane increases but also presented more interest in morphological integrity and lack of resistance to influence oocyte damage.
Comparing the results in terms of assessing the degree of maturation by two methods, differences are found as follows: mSOF medium between the two methods of assessment, difference was of eight oocytes. For TCM 199 medium, between the two methods of assessment, difference was of six oocytes.
Overall, a total of 14 oocytes were transferred from the category of immature in mature oocyte, the accuracy of assessment method was tested by Trypan blue exclusion.
In parallel, checks were made of the degree of viability and category considered degenerated oocytes or stagnation of development of the 14 mature oocyte stained; 12 oocytes were not stained and two had an indelible stain, which demonstrated the accuracy of assessment done by morphocytometry.

CONCLUSIONS AND RECOMMENDATIONS

1. Using ovaries after ovariohysterectomy from animals represents a source of oocytes needed for the biotechnology applications.
2. Recovery of oocytes from cat ovaries shred method is an inexpensive and expeditive technique.
3. The Oocytes with the following morphological and morphometryc characteristics will be selected for cultivation: homogeneous cytoplasm, slightly granular, even perivitelin space, compact cumulus, intact pellucida membrane, the average diameter of 75,70 mm, average size of 8,25 mm pellucida membrane, average thickness of cumulus 17,60 mm.
4. Selecting the category of mature oocytes involves maintaining morphological and morphometryc parameters for recruitment: average oocyte diameter of 141,30 mm, average thickness of membrane pellucida 10,40 mm, average thickness of cumulus cell 252,3 mm.

   Finally, we recommend to assessing the viability of cat oocytes in parallel using the morphological and morphometryc measurements with intravital colour testing.

BIBLIOGRAPHY

1. Brown JL, Wildt D, Wielebnowski N, Goodrowe KL, Graham LH, Wells S, 1996. Reproductive activity in captive female cheetahs (Acinonyx jubatus) assessed by faecal steroids. J. Reprod. Fertil. 46, 106:337.
2. Ciupe Simona, 2004 – Cercetări privind morfologia embrionilor în vederea conservării şi transferului embrionar. Teză de doctorat, 2004.
3. Farstad,W., 2000. Current state in biotechnology in canine and feline reproduction. Anim. Reprod. Sci. 60–61, 375–387.
4. G. A. Losa**,** V. Peretti, F. Ciotola, N. Cocchia, G. De Vico, 1997. The Use of Fractal Analysis for the Quantification of Oocyte Cytoplasm Morphology of cat oocytes. J. Rep. Fert. Suppl. 1997; 51: 69-82.
5. Groza I., Bogdan L.M., Catana R., Cenariu M., Ciupe S., Ciupercescu D., Morar I., Muntean M., Pop R., Stegerean B. – Ginecologie, andrologie si obstetrica veterinara : compendiu. E. Academiei Romane, Bucuresti, 2006.
6. Groza Ioan, Hârceagă L., Moise D., Bogdan L., Morar I., Sotoc O., Ciupe Simona, 1996. Cercetări privind fecundarea in vitro a ovulelor de vacă. Simpozionul ” Lucrări ştiinţifice de Med. Vet.”, Timişoara, vol. XXIX, 271.
7. Katharine M. Pelican , David E. Wildt, Budhan Pukazhenthi, JoGayle Howard, 2006. Ovarian control for assisted reproduction in the domestic cat and wild felids. Theriogenology 66, 37–48.
8. Naoi H., Otoi T., Shimamura T., Karja N.W.K., Agung B., Shimiziu R., Taniguchi M., Nagai T., 2007. Developmental competence of cat oocytes from ovaries stored at various temperature for 24 h. J. Reprod. Dev. 53, 271–277.
9. Otoi T., Shin T., Kraemer D.C.,Westhusin M.E., 2004. Influence of maturation culture period on the canine oocytes after in vitro maturation and fertilization. Reprod. Nutr. Dev. 44, 631–637.
10. Wood T., Montali R.J., Wildt D.E., 1997. Follicle oocyte atresia and temporal taphonomy in cold stored domestic cat ovaries. Mol. Reprod. Dev. 46, 190–200.
11. Wood T.C., Wildt D.E., 2004. Effect of the quality of the cumulus oocyte complex in the domestic cat on the ability of oocytes to mature, fertilize and develop into blastocysts in vitro. Journal Reprod. Fertil. 110, 335-360.

CORRELATION BETWEEN THE CLINICAL AND EVOLUTIVE EXPRESSION AND TYPE OF ULTRASOUND CHANGES IN THE DIAGNOSIS OF CAVITARY ORGANS` DISEASES IN DOG

M. CODREANU,[1] Cristina FERNOAGĂ,[1] M.CORNILĂ,[1]
Iuliana CODREANU,[1] D. CRÂNGANU,[1] M. TURCITU[2]
[1]Faculty of Veterinary Medicine, Spl. Independenței, No.105, 5th District, Bucharest,
[2] Institute for Diagnosis and Animal Health, Bucharest, Romania
codveterinary@yahoo.com,

ABSTRACT

Clinical features and the ultrasound examination of the cavitary organs` diseases have in most cases a direct corespondance, in order to correlate them and to confirm the diagnosis. According to their precisely and easily identification of each component of the cavitary organ`s wall, any changes in their apearance and uniform/nonuniform thickening is very useful for the diagnosis of their diseases, in correlation with the size, position and echogenicity.
In the panel of the clinical expression of te cavitay organ`s diseases, the ultrasound changes can confirm te diagnosis with a high degree of specificty and a high degree of accuracy.

Key words: clinical expression, ultrasound changes, cavitary organs, diagnosis, dog

Regarding the cavitary organs` (stomach, small and large intestine, gallbladder and urinary bladder) diseases is wellknown that their clinical expression is in general obviously and very sugestive.
In adition the ultrasound examination alow the identification and the evaluation of the cavitary organs and of their parietal structure, the topography in accordance with the neighbour organs, the type and the amount of content and also the parietal tonus of the wall.
The parietal changes regarding the arhitecture and thickness, can consist and evaluated, as the: the maintaned structure of the wall, parietal abnormalities, uniform wall thickening (inflamatory changes), or nonuniform (neoplastic diseases), infiltrative changes (esspecially neoplastic diseases), edematous changes (vascular stasis).

MATHERIAL AND METHODS

In the diagnosis of the cavitary organs` (stomach, small and large intestine, gallbladder and urinary bladder) diseases, correlated with obvious clinical signs, the ultrasound examination can easily confirm the clinical hypothesis of the suspected affection (2,6).
The ultrasound examination of the cavitary organs can be performed using linear or convex probes, of normal or high frequency (6; 6,5; 7,5; 8 or 10 MHz), obtaining valuable information about their wall structure and thickness (normal 2-3 mm).
The clinical and ultrasound investigations were performed on 89 dogs of different age, sex or breed, diagnosed with different diseases of the cavitary organs, working with Aquila Vet ultrasound machines, using different probes (according to their size) of 5–10 MHz, in the

Internal Department Diseases of the Faculty of Veterinary Medicine Bucharest and the Veterinary Clinics „Canivet" and respectively „Crivet" from Bucharest. The clinical changes were registered and correlated with the results of the paraclinical investigations, especially with the ultrasound investigation results.
In such cases, for ensuring a maximum accuracy of the ultrasound investigations we`ve followed and respected strictly the steps for obtaining the most relevant images, without or with minimum artifacts images, in order to diminish the relevance of the obtained ultrasound images of the cavitary organs (1, 3).
The main causes of the artifacts inducing images are in most cases attributed to the gas accumulation, the lack of content (in case of urinary bladder evaluation). On behalf of the tendency of maximum reducing of the improper artifactual situations, was very important to recommend prior the ultrasound examination the food diet and the propper oral fluid intake (1,8).

RESULTS AND DISCUSSIONS

The most important objective of our study it was to achieve and to correlate the clinical expression of the cavitary organs` diseases with the ultrasound changes, in order to find strictly corespondances between these, in confirming the diagnosis.
After the clinical and ultrasound investigation of the cavitary organs (stomach, small and large intestine, gallbladder and urinary bladder), the most easily identified and confirmed were the diseases with high degree of specificity, as the inflammatory changes, dominated by the uniform thickening of the wall, esspecially of the superficial components and the maintaining of the parietal tonus (in acute inflammations)/or diminishing the parietal tonus (for the chronic inflammations).
The parietal oedema (infiltrative aspect), in correlation with other fluid retention changes are suggestive for the stasis and disturbances of the return blood circulation.
In additional, the infiltrative affection, on focal areas, correlated with loosing the specific wall structure (arhitecture) and thickness degree are more characterstique for neoplastic diseases.
From ultrasonographyc point of the view, the most importand and facile too is to identify the destruction of the parietal arhitecture, specific for each cavitary organ.
In this frame, for the investigated cavitary organs, the stasis of the content can be specific clinical correlated with the ultrasound changes, as in gastric or intestinal stasis (Figure 1 and Figure 2), with obvious digestive speciffic simptomatology, in accordance with the degree of obstruction, and parietal contractility injuries.
In case of gallblader or/and urinary bladder stasis, the distension is more easily observed by ultrasound scanning, less correlated with the clinical signs, with minimum influence to the layers arhitecture or thickness, but any changes in normall anechoic content of the normal bladders can be observed and evaluate (Figure 3 and Figure 4).
The sludge and the destroyed or blood cells of its, appears into the bladders as echoic corpuscular elements, without sedimentation tendency. The gallblader stasis is not always acomplished by an obviously clinical signs, in rare cases, biliary vomiting or/and inapetency (3,9).

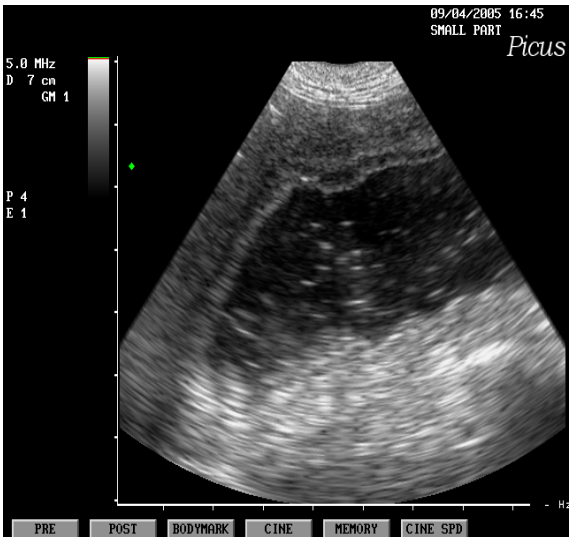

Figure 1. Gastric stasis.
The distended stomach by anechoic content with corpuscular elements in suspension and sediment, with unaffected wall.

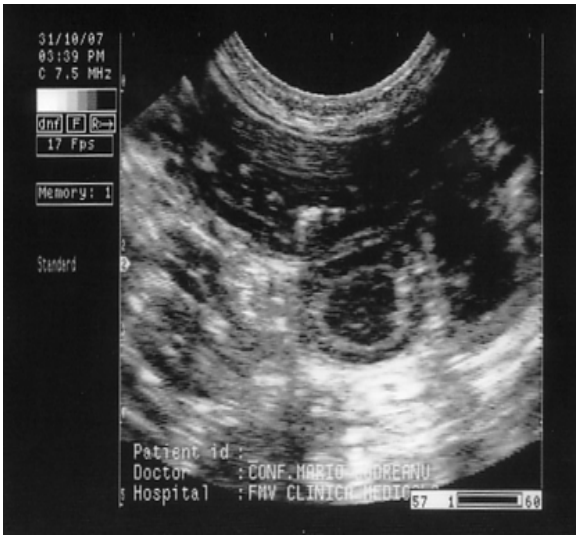

Figure 2. Intestinal ileus (stasis)
Dilated small intestinal segment by hypoechoic content (and parietal reaction) and normal parietal arhitecture (visualisation of each layer)

The accumulated content can be hommogenous or nonhommogenous, echoic or hypoechoic, in accordance with the ammount and the type of content.
The cavitary organ is in many cases unaffected or may be discreet ant uniform affected (with parietal reaction), as in intestinal ileus, urinary retention or cholestasis.

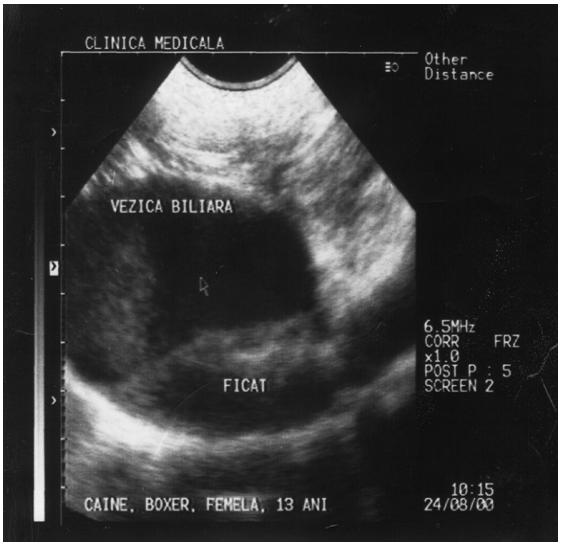

Figure 3. Cholestasis
Gallbladder distended by anechoic content with sludge, without parietal reaction.

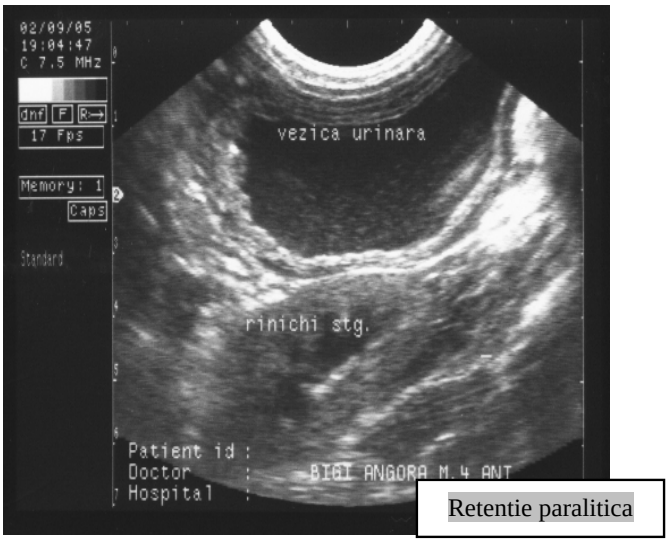

Figure 4. Urinary retention
Obvious distension of the urinary bladder by anechoic content, with high cellularity and secondary wall inflammation.

In many cases, the urinary retention (secondary to paralytic conditions) is accomplished by overposed infection of the urinary bladder (secondary cystites), with uniform thickening of the wall and reducing the specific parietal tonus.

The foreign bodies into the gastric and intestinal lumen are also visible, appearing as hyperechoic masses, with different degrees of distal shadowing, obviously in correlation with clinical signs of gastric or intestinal obstruction (Figure 5 and Figure 6). In such cases the wall structure (in first stages) is not or less affected (2).

Figure 5. Foreign body into the stomach. Gastric stasis by hypoechoic content and the presence of an hyperechoic mass with distal shadowing.

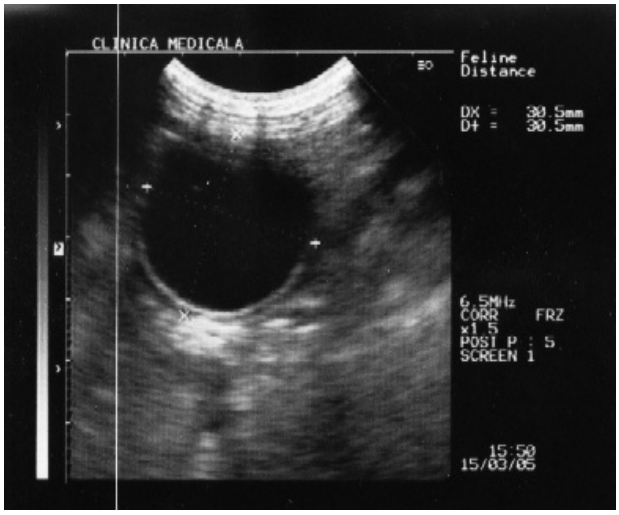

Figure 6. Intestinal foreign body. Rounded anechoic mass (without distal enhancement) into the intestinal lumenal.

The bladder stones and the gallbladder stones appears as hyperechoic masses, with regular shape and distal clear shadowing (specific artifacts). In most cases the parietal reaction is present, as uniform wall thickening, specific for the acute inflammatory changes (Figure 7 and Figure 8).

Figure 7. Urinary bladder stone with secondary cystites. Hyperechoic mass into the bladder with distal shadowing and inflammatory reaction of the wall. The urine is almost clear (as anechoic hommogenous content).

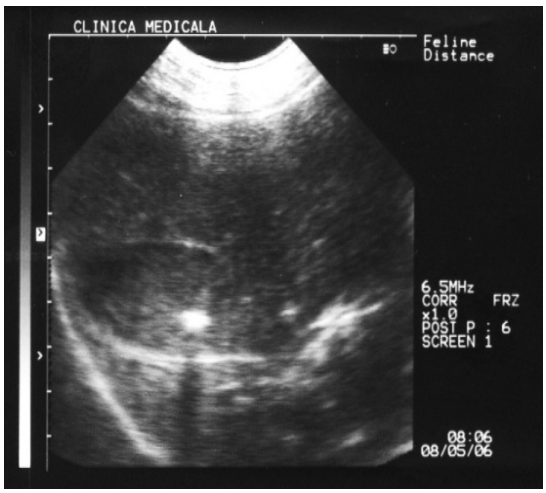

Figure 8. Gallblader stone. Into the bladder is observed an rounded hyperechoic mass, with distal shadowing artifact, and biliary sludge, with moderate reaction of the wall.

In gastritis the clinical signs are specific and contantly recorded, easily confirmed by the ultrasonographyc method, characterized by the uniform and obvious thickening of the gastric wall, with a normal or more intensive tonus and contractility (Figure 9).
For the chronic inflamatory processes at the gastric level, are more specific the discreet afecting of the wall thickness associated with a reduced tonus of the organ (Figure 10).

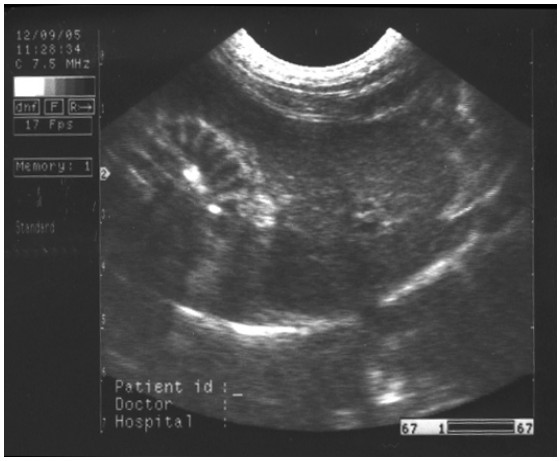

Figure 9. Acute gastritis.
Intense thickening of the gastric wall, with the normal layers arhitecture.

Figure 10. Chronic gastrites.
Moderate thickened wall of the stomac with a hypotonic aspect.

In case of acute or chronic infllammation of the bladders (gallbladder and urinary one) the reactive process is similar with those registered to the gastrointestinal level, consisting in thickening of the bladder wall, usual with an nonhommogenous content, with different degrees of tonus and motility injuries, corelated with keeping the normal viewing of the wall structures (parietal arhitecture), and different, but specific clinical expressions (Figure 9 and Figure 10).

Figure 11. Gallbladder inflammation.
Thickening of the gallbladder wall (edematous aspect), with normal anechoic content.

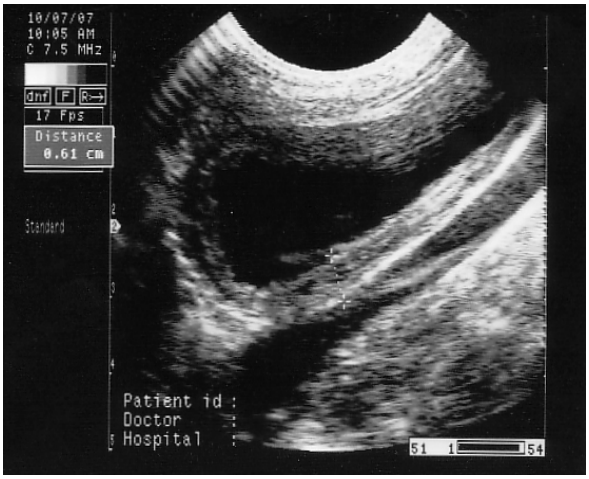

Figure 12. Acute cystites.
The urinary bladder with an uniform and obvious thickening of the wall (6,1mm).

From clinical point of view, in most cases the quantity changes of the cavitary organs indicates alterations of the morphology and functions of these, especially parietal injuries. Also, changes in the quality of the content of these cavitary organs (stomach, intestin, urinary bladder) are

usually sugestive regarding the type of the registered morphologyc alterations (haemorhagic vomiting, melena, hematuria etc.).
Additional the shape changes of the cavitary organs are less visible, but when are identified are suggesting the existance of severe wall structure alterations or injuries (3,7).
The focal changes are more facile to be identified, associated in most cases by alterations of the wall specific arhitecture (developed withe preponderency on different layers of the wall), with a high degree of specificity for the tumoral processes.

Figure 13. Gastric tumour.
Non-uniform thickening of the gastric wall (18,3 mm) loosing the wall specific structure/arhitecture.

Figure 14. Urinary bladder tumour.
The urinary bladder with intralumenal masses, associated with irregular thickening of the wall.

CONCLUSIONS

1. The clinical expression of the cavitary organs is very tight connected with the results obtained after the ultrasound investigation, in connection with his accuracy, specificity and non-invasive features.
2. The ultrasonography results are in most cases in order to confirm or to infirm the clinical diagnosis, sugested by the clinical signs.
3. The ultrasound examination alow the identification and the evaluation of the each component of the cavitary organs, the type and the amount of content in connection with the parietal tonus and the peristaltic activity.
4. The wall injuries, regarding the arhitecture and thickness, can be evaluated, more specific for the parietal abnormalities, uniform wall thickening (inflamatory changes), or nonuniform (neoplastic diseases), infiltrative changes (esspecially neoplastic diseases), edematous changes (vascular stasis).

REFERENCES

1. **Bratievici,R., Budau, M., Pop.T –** Vezica urinara. In: Ecografie clinica, diagnostica si interventionala, Editura Medicala, Bucuresti, 1998
1. **Codreanu M.D., Diaconescu A.** - Diagnosticul ecografic la animalele de companie. Ed. Coral Sanivet, Bucuresti, 2003
2. **Codreanu M.** – Patologia medicală a animalelor domestice, Ed. Printech, Bucureşti, 2009

3. **Dunlop Robert H., Malbert Charles-Henri** - Pathophysiology. Ed. Iowa State Press, Ames Iowa, p. 371-397, 2004
4. **Cornilă, N., Manolescu, N.** - Structura şi ultrastructura organelor la animalele domestice. Ed. Ceres, Bucureşti, 1995
5. **Dojană,N. –** Compendiu de Fiziologia animalelor domestice, Ed. Printech, Bucureşti, 2004
6. **Ettinger, S.J., Feldman, E.C. -** Textbook of Veterinary Internal Medicine. Diseases of the Dog and Cat, 5-th .Ed. W.B. Saunders Co., 1999
7. **Ford R.B., Mazzaferro E.** – Kirk and Bistner`s Handbook of Veterinary Procedures and Emergency Treatment, 8th Ed. Saunders, 2003
8. **Penninck D.G. –** Ultrasonography, Veterinary Clinics of North America, Small Animal Practice, 28(4), 1998
9. **Richard, W., Nelson, C., Guillermo, C. -** Small Animal Internal Medicine.Mosby, Inc. Company, 1998

STUDY REGARDING THE CORRELATION BETWEEN THE CLINICAL FEATURES AND/OR THE TYPE OF ULTRASOUND CHANGES IN THE DIAGNOSIS OF THE PARENCHYMATOUS DISEASES IN DOG

M. CODREANU,[1] Cristina FERNOAGĂ, [1]M.CORNILĂ,[1]
Iuliana CODREANU,[1] C. ŞERDEAN,[2] M. TURCITU,[3]
codveterinary@yahoo.com,
[1]Faculty of Veterinary Medicine, Spl. Independenței, No.105, 5th District, Bucharest,
[2]Pet & Vet E.R. Timişoara
[3]Institute for Diagnosis and Animal Health, Bucharest, Romania

ABSTRACT

The ultrasound examination in parenchymatous organs` diseases have a wide area of aplication, in order to correlate and to confirm the clinical diagnosis.
According to their characteristic size, topography and structure the ultrasound examination of the parenchymatous organs is very useful for the diagnosis of the diseases related to volume, topography, echostructure and echogenicity changes.
In this frame of clinical expression correlated with the ultrasound changes the diagnosis became obviously and easily confirmed.

Key words: clinical signs, ultrasound, parenchymatous organs, diagnosis, dog

The clinical evaluation of the most parenchymatous organs changes, regarding to their size are most frequent over-evaluated and non-objective. In ultrasound evaluation these changes, and the size and shape disturbances are very easy to be underlined. In clinical and ultrasound evaluation the most of the echo-structure and echogenicity changes are attributed to the tumoral processes (especially the focal hypo/hyper-echoic changes). In the same panel the most of the echogenicity changes (focal or diffuse), correlated with the raising of the echogenicity (hyperechogenicity), decreasing of its (hypoechogenicity) or the combined changes (heteroechogenicity) are also attributed to the neoplastic diseases.
Regarding to their incidence and specificity the neoplastic changes is the most important parenchymatous category, sensitive and characteristic ultrasound diagnosed.

MATHERIAL AND METHODS

In the diagnosis of the parenchymatous organs` (liver, spleen and kidneys) diseases, correlated with obvious morphologically and echostructure changes, the ultrasound examination is situated on an important place, as relevance and specificity.
Using the ultrasound technique the parenchymatous organs can be directly identified and evaluated, using different probes (5 -7,5 or 10 MHz), obtaining through this imagisthique method certainly information about their structure (echostructure) and density (echogenicity).
The investigations were performed on 157 dogs of different age, sex or breed, diagnosed with different organ affections, using PIE MEDICAL ultrasound machines (Ixos Vet and Aquila Vet), using different probes (according to their size) of 5 – 7,5 and 10 MHz, during the 2009-2010 period of time, at the Internal Department Diseases of the Faculty of Veterinary Medicine Bucharest and at the Veterinary Hospital „*Dr. Serdean*" - Timişoara. The clinical changes were

achieved, registered and after correlated with the results of the paraclinical investigations, especially with the ultrasound investigation results.

For ensuring a maximum accuracy of our investigations we`ve followed and respected strictly the steps for obtaining the most relevant images, without or with minimum artifacts images (in order to diminish the relevance of the obtained echographyc images). The main causes of the artifacts inducing images are in most cases attributed to the improper position of the patient for examination, or the position or incidence of the probe on the patients` abdominal skin surface. In additional, and the other responsive of artifacts inducing were limited or avoided (evacuating the asciting liquid, evacuating the gastrointestinal content and reducing the fermentative processes from the gut). On behalf of the tendency of maximum reducing of the improper artefactual situations, is very important to be able to identify and differentiate the normal ultrasound aspects of the parenchymatous organs of the pathological aspects, regarding their echostructure and echogenicity (especially the diffuse ones).

RESULTS AND DISCUSSIONS

After the clinical and ultrasound evaluation of the parenchymatous organs (liver, spleen and kidneys), the most easily identified and confirmed were the congestive and inflammatory changes, dominated by elevating the morphological parameters and the sonographyc patterns (echogenicity).

In this area the echogenicity is obvious decreased (Figure 1 and Figure 2) in accordance with an distal enhancement, with minimum influence to their echostructure. Subsequently the other diffuse changes are correlated with the fibrotic (Figure 3 and Figure 4) or the lipidic dystrophy diseases (Figure 5 and Figure 6).

Figure 1. Hepatic congestion. Hepatomegaly with hypoechoic aspect and important distension of the portal system.

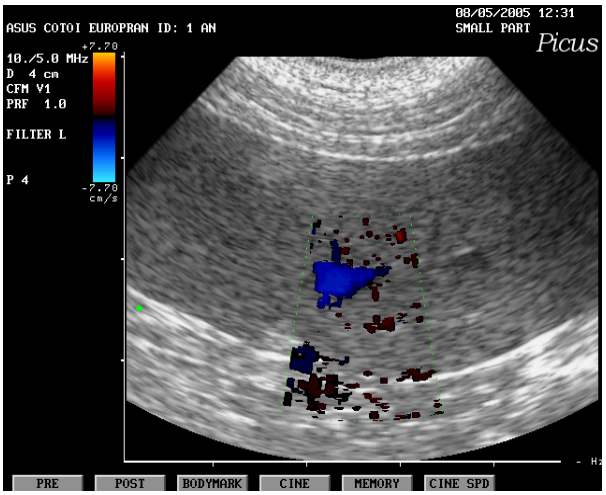

Figure 2. Splenomegaly (obvious raising of the volum and splenic vein distension) and hypoechoic aspect.

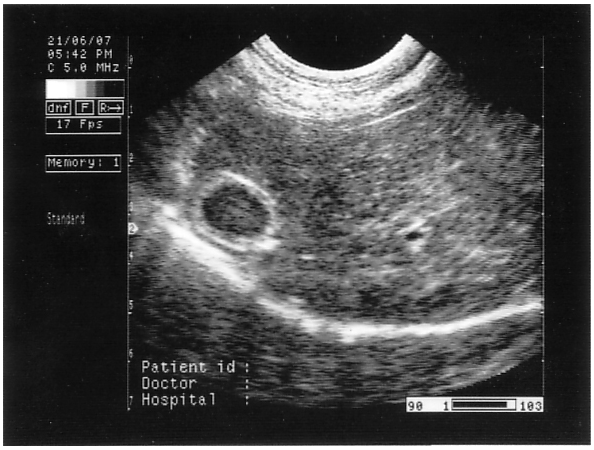

Figure 3. Liver cyrosis. Intense hyperecogenicity and low visualisation of the ductal structures and intraparenchymatous blood vessels

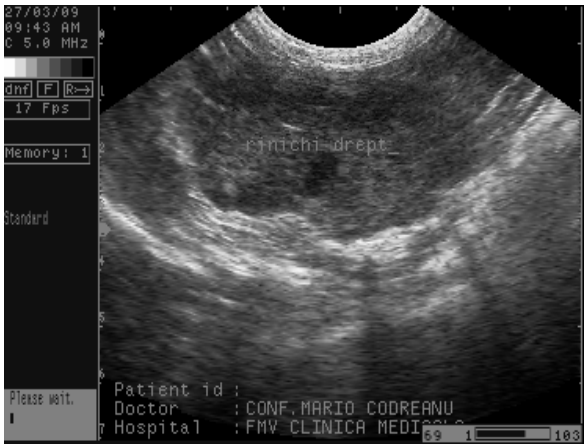

Figure 4. Kidney fibrosis. Irregular shape and hyperechoic aspect, correlated with and decreasing of the renal volume

In case of fibrotic and lipidic changes the echostructure of the parenchymatous organs became more dense and the echogenicity more intense, with distal attenuation and low visualization of the blood vessels and biliary ducts.

The clinical signs are in most cases, directly correlated with the degree and the type of parenchymatous affections, focusing and requesting additional investigations for certifieyng the organ disease.

In such cases the clinical expression is in general reduced and additional the biochemical and hematological profile changes are very representative with high specificity and accuracy staging of the functional distress.

Figure 5. Lipidic dystrophy of the liver. Hyperechoic pattern correlated with the low visualisation of the blood vessels and ”distal attenuation phenomena”

Figure 6. Bilteral renal lipidic dystrophy. Bilateral nephromegaly with hyperechoic aspect and thickening of the renal cortex.

The diseases associated with the focal ultrasound changes, in many of them, the clinical corespondance is very low and non-characteristique, as in cystic lesions, and abscesses.

The cystic lesions appears as circular or ovalar lesions, with homogenous anechoic content, with lateral shadowing and distal enhancement.

These are frequent identified in spleen (Figure 7) and kidneys, as isolated lesions or as multiple lesions in case of Polycystic Kidenys Disease in cats (Figure 8).

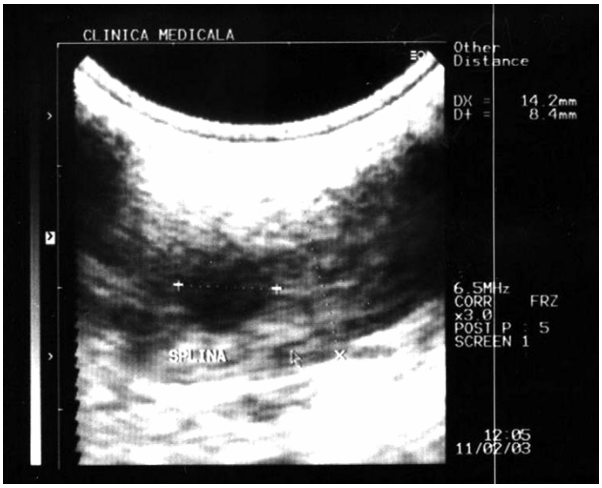

Figure 7. Splenic cyst.
Intraparenchymatous lesion with anechoic aspect.

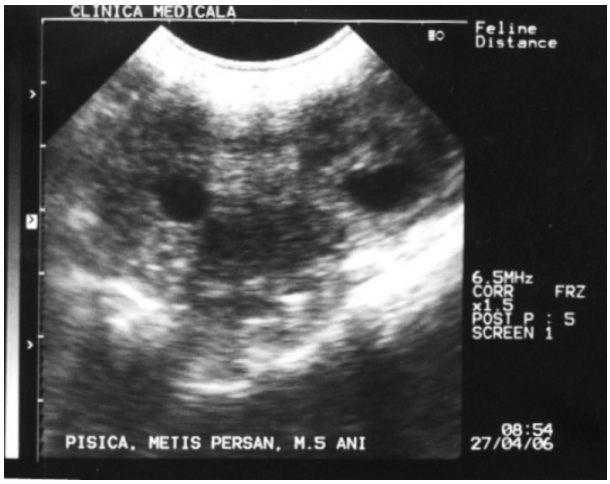

Figure 8. Kidney polycystic lesions. Multiple anechoic cavities into the kidneys` structure

The abscesses, in spleen or liver appears as hypoechoic lesions, with particles in suspension and rounded by an irregular hyperechoic membrane (figure 9 and Figure 10). Additional the clinical changes are very well and intense defined, and the hematological pattern is dominated by the leucocytosis and neutrophilia.

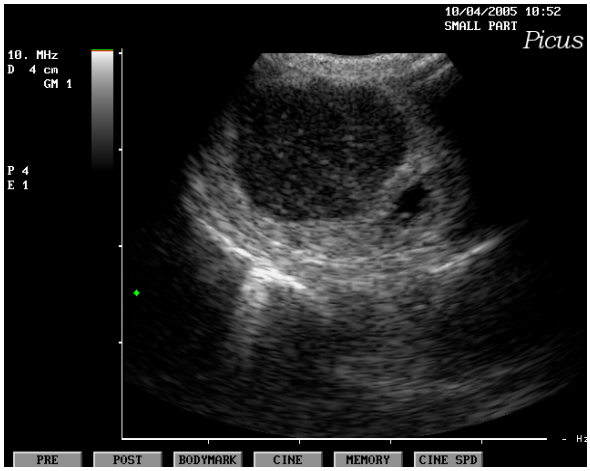

Figure 9. Splenic abscess.
Non-hommogenous echostructure of the spleen, with hypoechoic accumulation delimitated by an irregular hyperechoic capsular structure.

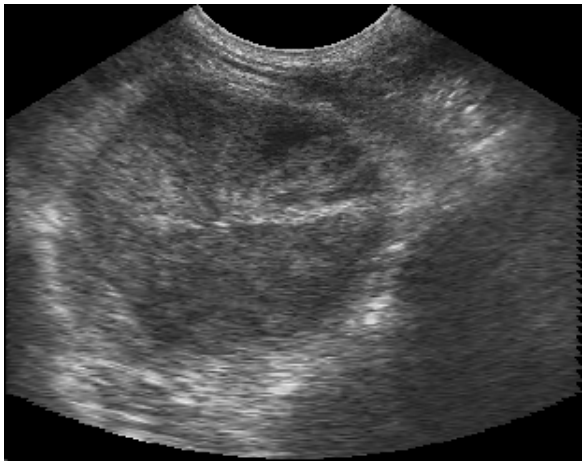

Figure 10. Hepatic abscess.
Intraparenchymatous accumulation with hypoechoic aspect, well defined by an hyperechoic and irregular membrane.

CONCLUSIONS

1. The ultrasound evaluation of the parenchymatous organs, through their accuracy, specificity and non-invasive features, could define this imagisthique method of diagnosis as a proper and accessible tool of diagnosis in such disturbances.

2. The evaluations of the parenchymatous organs, from clinical point of view (especially regarding to their size) are often over-evaluated and many times non-objective, these inconvenience can be avoided using the ultrasound technique.

3. In clinical and ultrasound evaluation the most frequent changes are related to alteration of the echostructure and echogenicity, attributed mainly to the tumoral processes (especially the focal hypo/hyperechoic changes).

4. From ultrasonographic point of view the most obvious are the echogenicity changes (focal or diffuse), correlated with the raising of the echogenicity (hyperechogenicity), decreasing of its (hypoechogenicity) or the combined changes (heteroechogenicity).

5. . From the total number of investigated dogs, as incidence and specificity, the neoplastic changes are the most frequent (sensitive and characteristic ultrasound diagnosed), in a 40,67 % (n= 64).

REFERENCES

1. **Badea, R.I., S. M. Dudea, P. A. Mircea, D. Zdrenghea** - Tratat de ultrasonografie clinica. Editura Medicala, Bucuresti, 2006.
2. **Bhadwal M.S., Mirkur K.K., Sharma S.N.** (2000) – Ultrasonographic imaging of the normal canine liver and gall-blader, Veterinary Bulettin, vol. 70, nr1, art.853, p.142.
3. **Codreanu,M.D., Diaconescu, Al. –** Diagnosticul ecografic la animalele de companie, Editura Coral Sanivet, Bucureşti, 2003
4. **Dojană, N.** – Compendiu de Fiziologia animalelor domestice, Ed. Printech, Bucureşti, (2009)
5. **Ettinger, S.J., Feldman, E.C.** - Textbook of Veterinary Internal Medicine. Diseases of the Dog and Cat, 5-th .Ed. W.B. Saunders Co., 1999
6. **Ford R.B., Mazzaferro E.** – Kirk and Bistner`s Handbook of Veterinary Procedures and Emergency Treatment, 8th Ed., Saunders, 2003
7. **Mwanza T –** Evaluation of experimentally indeced canine liver disease and portal hemodynamics using ultrasonographyc as a noninvasiv diagnostic method, Japanese Jurnal of veterinary research, vol 45, **(**1998)
8. **Narojec T –** Ultrasonic diagnosis of focal changes in the hepatic parenchyma in dogs and cats, Medycyna Weterynaryjna, vol 51 nr 8, **(**1995)
9. **Varshney JP, Hoque M –** Ultrasonographic examination of hepatobiliary system in dogs; and analisis of 35 cases, Veterinary Bulletin, vol 72, no 11, art 8744, p.1545, (2002).

PROFILACTICO-THERAPEUTIC STRATEGIES IN THE DOG DISORDERS MALIGNANT PROSTATE

D.CRINGANU[1], Manuela MILITARU[1], M. CODREANU[1], Al. DIACONESCU[1], Cristina PREDA,[1] Bogdan GHEONGHEOS[2]

[1] Faculty of Veterinary Medicine Bucharest,cringanudan@yahoo.com,
[2] Private Veterinary Office

ABSTRACT

The aim of the work was to provide comparative information on human-animal evolutionary stages, identifying markers that allow early diagnosis of prostate cancer. By using several diagnostic methods are trying to determine the first moment of malignisation, with beneficial repercussions vis-à-vis the establishment in early, curable therapy, with the consequence extend survival and increase the degree of comfort.

Increased incidence of prostate cancer is caused by exposure to domestic risk factors (hormonal disorders, weakened immune system, genetic mutations) and external (viruses, radiation exposure, contamination, inhalation or ingestion of toxic substances) and the change lifestyle of pets. Screening for early diagnosis and treatment of various diseases, from chronic inflammatory lesions (prostatitis, prostatic cyst, etc.) may prevent malignant or even block or allow the detection of tumor early stages by reducing the chances of metastasis and reduced patient suffering.

The studies in 33 dogs have shown that prostate tumors occur mainly in medium and large breeds, aged 8-10 years. Neutering at an early age had an effect on tumor development, which is not dependent on hormonal stimulation. This type of cancer in dogs is fundamentally different from humans, where this disease is completely androgen dependent and hormonal stimulus removal (castration and treatment) or estrogen use increases survival expectancy 60-70%. The survey also highlighted a problem: the risk of developing prostate cancer in neutered dogs is higher than those uncastrated.

The spread of prostate cancer in dogs is adenocarcinoma. Other cancers that can meet are scvamo-cell carcinoma, transitional cell carcinoma; leiomiosarcoma, undifferentiated carcinoma. Diagnosis is based on the laboratory tests: ultrasound, urine cytology summary, contrast radiography, puncture aspiration or trans-perineal, hemathologic exam and blood chemistry and specific detection of tumor markers.

*Therapy is multimodal, associating it with the inhibition or cytostatic polychemotherapy hormone replacement, as well as nonspecific immunotherapy. Important similarities were observed between clinical evolution **s**tage and evolutionary aspects of diagnosis and treatment of dogs with those of men, the pet can be a valuable experimental model for new means of prevention and therapy of the malignant cancer in humans.*

1.The order of the work is to provide comparative information on human-animal evolutionary stages, identifying direct and indirect markers that allow early diagnosis of prostate cancer. By using several diagnostic methods are trying to determine the initial moment of malignant, with beneficial repercussions vis-à-vis the establishment of early (curable) therapy, with the consequence extend survival and increase the degree of comfort.
Etiology: increased incidence of prostate cancer is caused by exposure to domestic risk factors

(hormonal disorders, weakened immune system, genetic mutations) and external (viruses, radiation exposure, contamination, inhalation or ingestion of toxic substances) and the change lifestyle of pets. Screening for early diagnosis and treatment of various diseases, from chronic inflammatory lesions (prostatitis, prostatic cyst, etc.) may prevent malignant or even block or allow the detection of tumor cancerised early stages by reducing the chances of metastasis and reduced patient suffering.

Epidemiology - studies in dogs have shown that prostate tumors occur mainly in medium and large breeds, aged 8-10 years. Neutering at an early age had an effect on tumor development, which is not dependent on hormonal stimulation. This type of cancer in dogs is fundamentally different from humans, where this disease is completely androgen dependent and hormonal stimulus removal (castration and treatment) or estrogen use increases survival expectancy 60-70%. The survey also highlighted a problem: the risk of developing prostate cancer in neutered dogs is higher than those uncastrated. The spread of prostate cancer in dogs is adenocarcinoma. Other cancers that can meet are scvamo-cell carcinoma, transitional cell carcinoma; leimiosarcom, undifferentiated carcinoma.

2. The materials and the methods using

Investigations and therapy were performed in the Oncology Clinic of the Faculty of Veterinary Medicine Bucharest, being examined 33 dogs of different breeds and aged between eight and 15 years. Were grouped in three lots of 11 animals, grouped according to the nature of prostate disease, including: prostatitis and prostatic cyst as inflammatory lesions, benign tumors (adenomas prostate) and prostate cancer, adenocarcinoma or other malignancies that.

Differential Diagnosis of prostate gland disorders was performed by clinical examintion and lab tests: ultrasound, cytology urinalysis, X-ray contrast ecogidata puncture aspiration or trans-perineal, haematological exam and blood chemistry and specific detection of tumor markers.

Clinical diagnosis was made by:

- **History,** which interested: race / age on clinical signs, clinical signs observed by the owner - slow moving, difficult urination, hematuria.
- **Inspection and prostate palpation.** Rectal examination is done by touch, you can appreciate the size of the male genital glands annexes. Prostate slip beyond the threshold of remarkable growth in the pubic signify its volume. It is estimated contour (regular, irregular), this area of compassion that can mean developing a tumor process. Location prostate is an indication and commitment and how to do a biopsy (transabdominal or transperineal) depending on the location of the prostate in the pelvic or abdominal cavity. In general, however, digital rectal examination correlated with ultrasound data may establish the diagnosis of prostate tumor, cyst or abscess, prostatic hypertrophy, so evida surgery is performed solely for exploratory or harvesting of a fragment of parenchyma in order to perform a histopathological examination.
- **Ultrasound examination**

  Although ultrasound can not provide data on prostate function, it complements uretrocistografia contrast, providing valuable information on prostate morphology, which were useful in determining the size, shape and internal architecture of the prostate gland. In addition, ultrasound has the advantage of not using ionizing radiation, contrast substances, and if the animal is not cooperating and is not necessary if biopsy is not necessary any animal sedation. Ultrasound allows the early identification of change in the parenchyma, differentiating between neoformations solid and fluid-filled cavities.

  Prostatic abscess is hiperecogena structure, with cavities in the parenchyma hiperecogene, irregular edges and asymmetrical shape. Degree of asymmetry depends on the size of the

abscess. Inner edge of the cavity is often irregular and may be septal lumen. Hematomas and hematic chistii appear as abscesses. Chistii paraprostatici large, are more like the bladder, but can contain more solid tissue and may have an irregular subdivision. Prostate tumor is irregular, asymmetric. Cavitary lesions are represented by infection, necrosis, hemorrhage, edema. This image is found and, in chronic prostatitis and prostatic hyperplasia and therefore require differential diagnostic biopsy.

- **X-ray examination**

Although not decisive, and directly contributes to prostate cancer diagnosis, direct radiography bring useful information for differential diagnosis and detection of metastases. It facilitates the differential diagnosis of prostatic nodules tough, palpated by rectal touch, as evident from bone metastases in some stage of their development. Thus corroborating and a chest radiograph reno-bladder and knowing that bone metastases are interested pelvic bones, vertebrae, femoral bones and ribs, bone radiography so close throughout the invasion left potentially exposed prostate neoplasm.

- **Intravenous urography**

Prostatic hypertrophy is counting on the effects on bladder function and anatomy of the excretory tract earlier. They are translated by bladder distension and bilateral uretero-hydronephrosis consequence of terminal ureteral displacement and compression by the enlarged gland volume. This method has its limits, which may occur due to an abnormal image, the early stages of cancer without being distinguished. May reveal only very advanced stages of evolution theory in terms of delayed treatment.

- **Cytological examination** was done by puncture aspiration with fine needle eco-guided

Cytology investigation is the method that is suitable inflammatory lesions and tumors of epithelial origin, and less abundant stromal tumors. Puncture aspiration was performed on animal contention, anesthesia is required only for uncooperative animals. Necessary instrumentation was the fine needles (hypodermic, 0.4-0.7mm) and 10 ml syringes. Smears were obtained by different methods May Grunwald Giemsa stained.

- **Prostatic secretions** were obtained by prostate massage. then be examined microscopically and bacteriologically, by comparison with reference sample. This technique is difficult in practice: if massage prostate hypertrophy when it toggles the abdomen, washing liquid that contains prostatic secretion with a tendency to leak into the bladder and not suction probe so that the secretions are obtained in small quantities, unlike sperm collection, also requiring the presence of two persons. Samples obtained were analyzed macroscopically and microscopically. Was considered as normal prostatic secretions appear sharp and clear, with a pH of 6.5-8. This blood or pus is easy to detect. Prostatic fluid is usually purulent, hemorrhagic and septic abscess in the prostate. Smears were displayed in the supernatant resulting from centrifugation of liquid collected, which were stained MGG.

- **Histological examination of raclatelor** (scraping the surface of section)

Histological examination was performed by surface ralarea prostate tissue samples obtained by biopsy, displayed as colored smears May-Grunwald-Giemsa. Remaining fragments were then fixed in 10% formaldehyde solution and included in paraffin. Sections obtained were stained by Masson tricromica method (hematoxylin-eosin methylene blue). Histological preparations were examined with optical microscopy, photographed, a part of imagery obtained illustrating this paper.

- **Histopathology of the sample biopsic**

Biopsy is an invasive surgical technique indispensable if other diagnostic means were insufficient to assess the evolutionary stage of an animal affected by cancer. Biopsy result should be interpreted with caution and in combination with results of other diagnostic procedures, such as blood tests, radiographs and other medical imaging techniques. The interpretation of the microscopic aspects into account the following general criteria: deviation from the normal histological structure, alteration of intercellular relationships with epithelial basement membrane structures, loss of polarity, this cell maturation disorders; stroma ratio change - parenchyma by invasion by tumor cells, appearance new vascular territories (angiogenesis), because elaboration of angiogenesis factors by tumor cells, assessing peritumoral immune reaction by determining the cells (lymphocytes, macrophages, plasma), changes in fibril elements of the stroma; the appreciation of the division rate this mitosis abnormal tumor grading .

Prostate tumor markers

P.S.A. (Prostate specific antigen) / arginine esterase is a glycoprotein, is a biochemical serinproteaza formed exclusively in the prostate gland, increasing its level of prostate cancer suggesting this. Most P.S.A. circulating serum proteins is linked. A small percentage is free, is called P.S.A. unbound (free). In prostate cancer, report P.S.A. Pool / P.S.A. Total decrease, the more it is lower, the more risk of prostate carcinoma is higher

Arginine esterase is an enzyme whose structure is similar to 60% with PSA In laboratory tests was fair in prostate cancer diagnosis at the front human dog.

C.E. (Carcinoembrionar antigen) is a glycoprotein produced by cells of malignant tumors grow ectoderm. Values its epithelial origin, which can be detected as early (the malignant process and the metastatic process marker screening before clinical phenomena).

Acid phosphatase is an enzyme, the prostate is usually rich in acid phosphatase, but her little part in determining serum levels of these enzymes. Acid phosphatase is controlled by androgen administration diminishing estrogen production by the prostate parenchyma.

K7 (Keratin 7) is a cytoplasmic filamentous protein formed in epiteliale.La human cells is used as a marker for differentiation of transitional cell carcinoma from adenocarcinoma, which does not produce PSA In dogs, was proposed as a method of identifying prostate cell invasion carcinomatoase uroteliale.

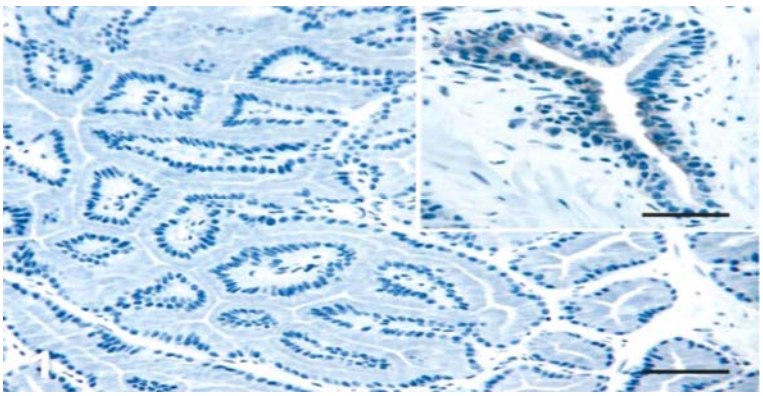

Normal prostate gland of dogs - K7 attached to massive basal epithelial cells and lumen (LeRoy, Nadella, Toribio, Leave, and Rosol, Vet Pathol 41:2, 2004)

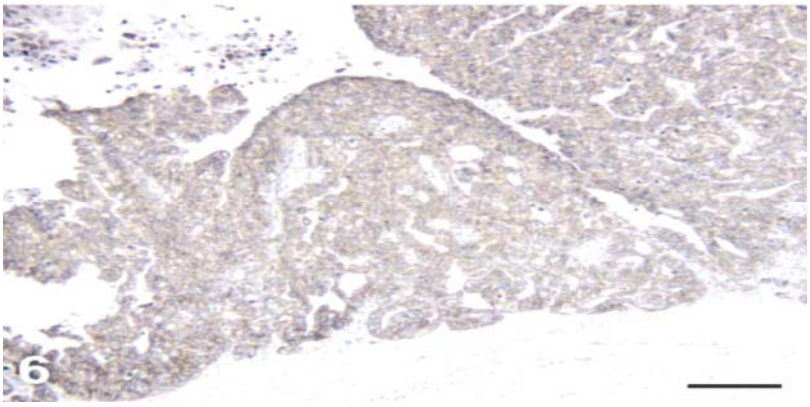

Prostate carcinoma in dogs, marking the K7 immunohistochemistry, cell cytoplasm golden brown (LeRoy, Nadella, Toribio, Leave, and Rosol, Vet Pathol, 2004)

RESULTS AND DISCUSSION

Lot I

Consisting of 11 dogs with benign prostatic disease diagnosis was treated consecutively addressed gland surgery therapy but castration and hormone inhibition or replacement.

Prophylactic therapy of chronic inflammatory prostate disease, cysts, abscesses, BPH (Benign prostatic hypertrophy) and benign tumors

Surgical therapy

a.Orhidectomia. In most cases, surgery is only necessary, very useful in BPH (benign prostatic hyperplasia) due to hormonal interdependence testicle - prostate. Results in a slow improvement (4 weeks), but surely the symptom. The prognosis is favorable in this situation. It is recommended that testicular cancer Sertolli cells intervention necessary, thus one can get to avoid the development of hypertrophy of the prostate, testicular malignancy and indirectly the whole structure, the appearance of perineal hernia.

b. adenomectomy and prostatectomy. Practiced in the case of adenomas excessive volume, the aura aggresses neighboring organs causing symptoms widening expression. Adenomectomy, and prostatectomy, not entirely reluctant body metastasis, prostate or the local or remote. This technique is sometimes used in human medicine dicutabile results, with no correspondence in veterinary medicine practice.

c. Orhidectomia and omentalizarea (epiploonara drainage of prostatic cyst) and removal of lymph zonal. Is a complex operation that requires only the situation of Investigations revealed a / some large cyst, invasive to adjacent organs. Is only possible if the animal's general state intervention also allows open scale. If the animal is found and lymph zonal attachment, their ablation is recommended. In all these cases, surgical therapy should be supported by polichimioterapy systemic treatment, which take into account any post-operative complications, supporting the general state of the animal and minimize postoperative discomfort.

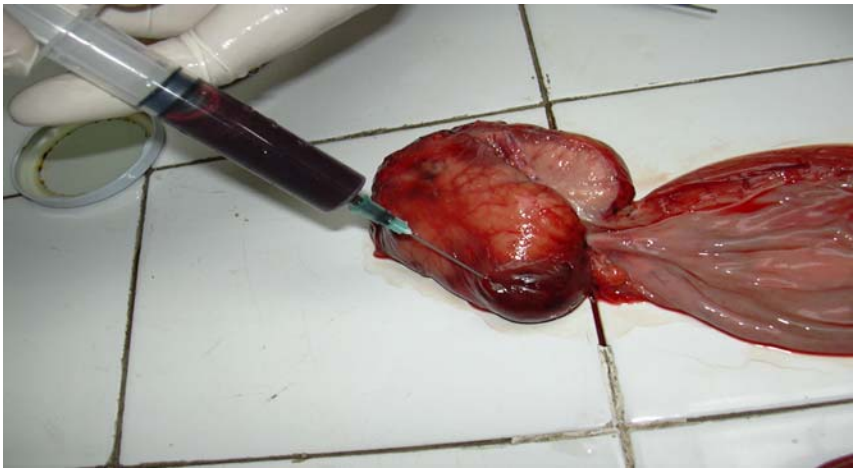

Prostate cyst, content sanguinolent (Original)

Paraprostatic cyst (*), prostate enlargement (after Nicola MA Parry, Tufts University School of Veterinary Medicine, Massachusetts)

Lot 2

It was composed of 11 dogs with benign tumor disease diagnosed by ultrasound and puncture aspiration eco-guided were treated with hormone orhidectomie associated with hormone substitute or inhibitor.

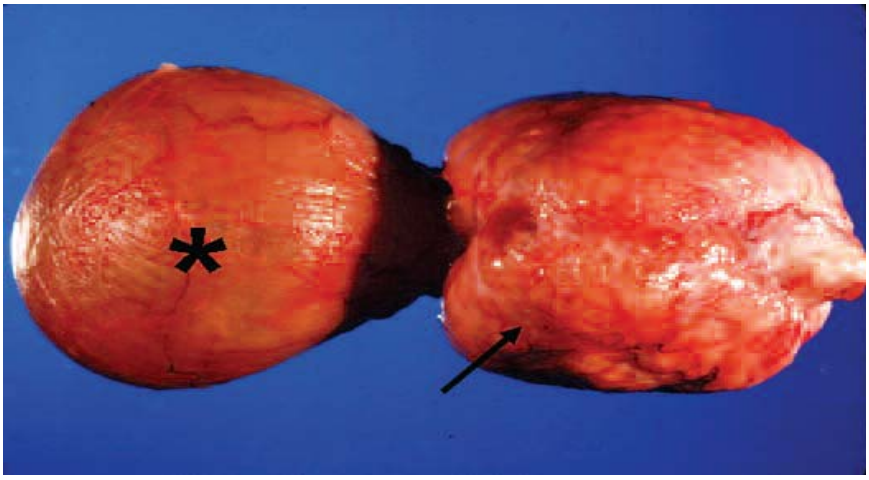

Benign prostatic hyperplasia: bladder (*), enlarged prostate bilaterally symmetrical (arrow) Necropsy evidence

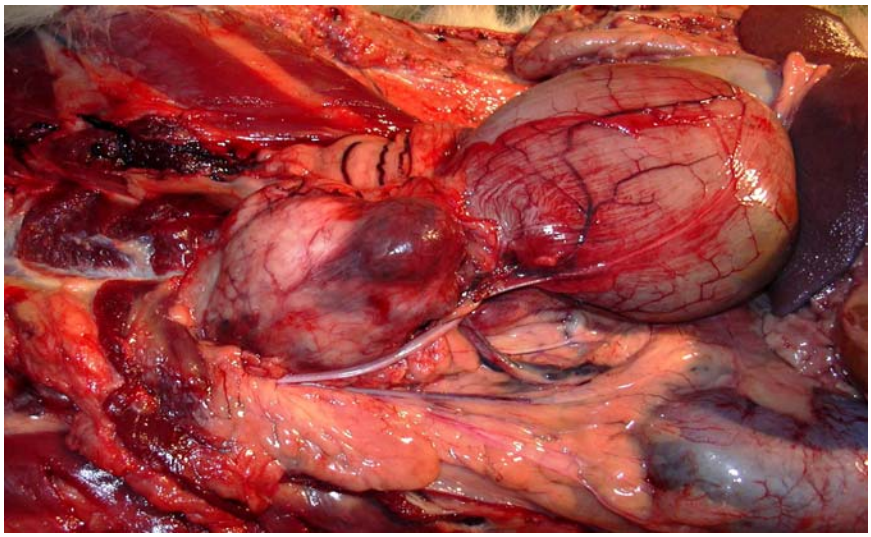

Hiperperplazie benign prostate and prostatic cyst (original)

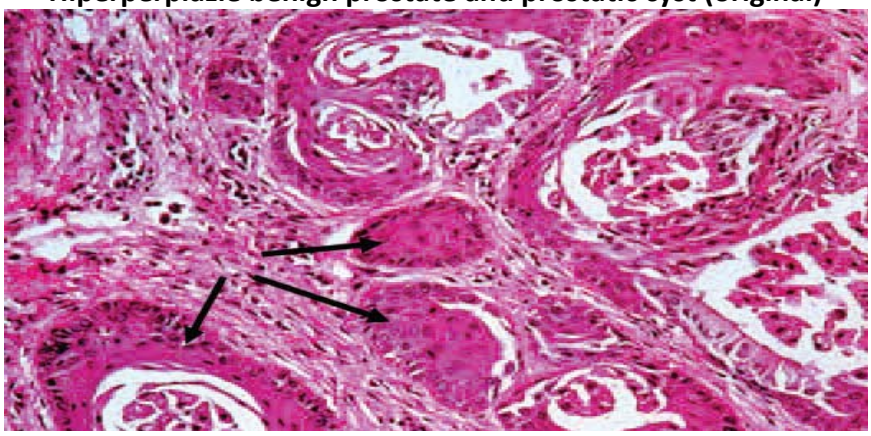

Scvamoasa metaplasia of glandular epithelium
(epithelium cuboidal epithelium replaced scvamos

Lot 3 - consisting of 11 animals with prostate cancer who were treated with cytostatic polichimioterapie associated with surgical excision and hormonal therapy inhibition or substitution together with nonspecific immunotherapy

Prostate adenocarcinoma. Irregular surface (Nicola Parry MA, Tufts University School of Veterinary Medicine, Massachusetts)

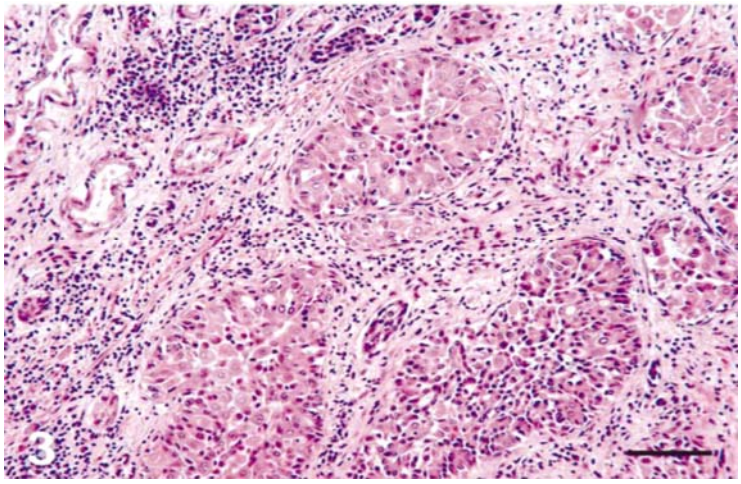

Prostate adenocarcinoma. Intraalveolar prostate carcinoma in dogs

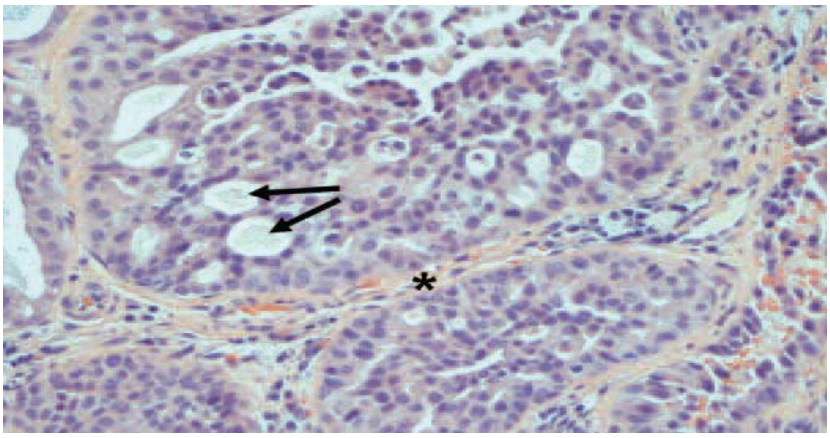

Prostate adenocarcinoma. Intraalveolar prostate carcinoma in dogs. (Nicola Parry MA, Tufts University School of Veterinary Medicine, Massachusetts)

Curative therapy of neoplastic diseases of the prostate gland (chemo-hormone-immunotherapy)

Treatment varies depending on prostate disease and consists of applying different schemes and different schemes prophylactic therapy of curative therapy

1. Cytostatic therapy Neoadjuvant

Was performed with anthracycline chemotherapy (doxorubicin 30 mg./m2) and alkilant agents (cyclophosphamide 50 mg./m2) associated with carboplatin and vinblastine 5 mg./m2.Are to reduce the tumor before surgery. Inhibit cancer cell growth in tumor periphery, which are the most aggressive, lowering the risk of their separation. As a result, the initial therapeutic response can be prognostic markers. It is a form prescribed in less severe stages, allowing redevelop surgical instrument (total ablation), or only partial remission, in which is made cito-reduction (comfort or palliative surgery). Application of neo-adjuvant chemotherapy correlates closely with increased free interval without symptoms of disease, survival, and the percentage decrease local recurrences.

2. Surgical therapy - used methods described in the prophylactic therapy.

3.Adjuvant cytostatic therapy

In veterinary oncology practice, is used after complete removal by surgical excision of primary tumor, having the role of minimal residual disease destroys persistent in tissues distant (metastases and micrometastazis). As a systemic treatment, can destroy disseminated tumor cells, being able to favorably modify the disease. Efficacy is increased as the polichimiotherapy in several cycles, using sequential low-dose and repeated long time. Be applied early, immediately after treatment locally, the scheme comprising three treatment cycles over a period of 120 days. Adjuvant chemotherapy toxicity is much lower than that used in advanced disease therapy.

4. Hormone therapy

a. additives - uses Antiandrogens: Flutamid, which blocks peripheral receptors for androgens result from the testes and the adrenal

b. Inhibition - is based on hormonal and enzymatic synthesis inhibitors: Ypakitine veterinary product, a TB. Daily 10 days, equivalent to human drug Proscar, which inhibit 5α reductase enzyme, which catalyzes the conversion of testosterone into 5 dihydrotestosterone; Aminoglutemida - inhibit the synthesis of adrenocortical steroid hormones.

c. competitive (substitute) - is based on hormone analogues: Zoladex - a synthetic analogue of LH, LH receptor blockade determines antero-pituitary, causing loss of concentration.

5.Malignizarii reversible therapy - the use of antioxidants

Vitamin A - stimulating antibody formation, has antitumor role, maintaining the integrity of the epithelium. **Vitamin E** - along with vitamin C prevents the formation of nitrosamines (carcinogens), derived from amino acid metabolism. **Vitamin C** - is involved in forming antibodies, interferon, preventing nitrosamines from protein catabolism. **Selenium** - works on glutathione that protects cells from oxidative free radical action.

6. Immunostimulation therapy

a. bacterial extracts: Calmete-Guerin bacillus (BCG) Cantastim; microbial elements processed (based on Corynebacterium genus)

b. Chemicals - levamisole - restore active immune potential of macrophages and T lymphocytes; Teobendazolul - stimulating effect of lithic and cytotoxic activity of immune cells, stimulating and antitumor anticorpogeneza.

c. biological response modifiers: interferon - a glycoprotein which interferes with cell division causing reduced cell proliferation rate, causing an increase in antibody-formatoare cells (lymphocytes B), stimulating and cytotoxic cells, and non-killer killer, Interleukin 2 - molecular mediators of the immune system - works on T lymphocytes, increasing the cytotoxic activity, colony stimulating granulo-monocitare, increasing the number of peripheral neutrophils and interferon-α. Monocitare granulocyte colony-stimulating factors: Filgrastim - regulates neutrophil production and function; Salgramostim restores the number and function of neutrophils, eosinophils, monocytes

d. Autovaccinuri antitumor = Teracine - induce the production of memory T cells, prolonging the antitumor effect

CONCLUSIONS

1. The important similarities were observed between clinical evolution poli-stage and evolutionary aspects of diagnosis and treatment of dogs with those of men, the pet can be a valuable experimental model for new means of cancer prevention and therapy of this malignancy in humans .

2. Prostate cancer is a malignancy with high incidence in dogs over 10 years, favored by sexual hiper function hiperproteic associated with eating.

3. Chronic inflammatory lesions (prostatitis, cysts, etc.) are precancerous states that undiagnosed and treated early, can degenerate into malignant lesions.
4. Investigation by specific markers allowed identification of neoplastic cells, early diagnosis of prostate cancer, prior to emphasize the clinical symptoms.
5. Malignant steps in dog prostate are similar to those of man, that acute prostatitis, chronic micro-cystic, adenomatous and then carcinoma "in situ", microcarcinoma, macrocarcinoma, metastases.
6. Further therapy was performed on each set differentiated clinical stage, that of early lesions, benign or malignant tumors.
7. Dogs with malignant prostate tumors were managed according to severity stage differentiated clinically.
8. In early tumor stages (To, T1, T2) without overt clinical metastases received:

- Take line cytostatic therapy without anthracyclines;
- inhibitory hormone therapy;
- orhidectomia;
- Postoperative adjuvant cytostatic therapy;
- substitute hormone therapy;
- nonspecific immunotherapy

9. Advanced TNM stages, diagnosed with clinical metastases were treated with chemotherapy group anthracyclines and platinum derivatives, both preoperative and postoperative.
10. Because the pace of evolution, prostate carcinoma is a serious malignancy, which requires an early diagnosis and the establishment of complex therapies.

BIBLIOGRAPHY:

1. Baba AI (2002) "Comparative Oncology", Romanian Academy Publishing House, Bucharest;
2. Rebecca Baker, Lumsden J.H. (2000) - "Color Atlas of Cytology of The Dog and cat, Mosby Inc.;
3. A Priest's Bica. Live From Seattle S, André Cornil N. Cranganu S., Hillebrand A., Nicolescu V. Oprisescu P., Radu Aurora., (1974) "Course morphology of domestic animals, Didactic and Pedagogic Publishing House, Bucharest;
4. Birtoiu IA,Diaconescu A. (2002) - Prostate Syndrome (I). "Canine guide, 3. 10-11;
5. Birtoiu IA Seiciu F (2002) - "Veterinary gynecology and andrology, Publisher of Tomorrow Foundation Romania Bucharest;
6. Bonagura JD(1995) "kirk's current veterinary therapy XII, ed.W.B.Company Saunders;
7. Chandler EA, Thompson DJ, Sutton JB, Price CJ (1994) - "Canine medicine and therapeutics" Third Edition, Blackwell Scientific Publications;
8. Nicolae Constantin - coordinator Birtoiu IA, Codreanu M, Constantin N., N. André Cornil, G. spine, Diaconescu A. Seiciu F., Sone A, (2003) - "Textbook of Veterinary Medicine, vol.III , Technical Publishing House Bucharest
9. N. André Cornil, Manolescu N. (1995) - "Structure and ultrastructure of organs in domestic animals", Publisher CERES, Bucharest;
10. Diaconescu A. Birtoiu A. (2002) - prostate syndrome (II). "Canine guide, April 9;
11. N. reproof, Doina Danes (1998) - "Biology and pathology of laboratory animals" vol II RATECH Publisher PRO
12. Ettinger SJ, Feldman EC (1996) - "Textbook of Veterinary Internal Medicine - Diseases.of the dog and cat 'Fourth Edition, vol VI;
13. E.C. Feldman, Nelson R.W., Saunder W.B. Company (1996) Canine and feline endocrinology and reproduction;
14. Boots V, Bica O Priest, Live From Seattle S. Nicolescu V. Oprisescu P, Balanescu F. (1967)"Anatomy of domestic animals"Didactic and Pedagogic Publishing House, Bucharest;
15. Hosken RF (1996) - "Canine theriogenology notes" SML. 531;

16. Kossi L.G. (1979) - Diagnostic Cytology, Third Edition. J.B. Company Lippincott, Philadelphia;
17. BE LeRoy, MVP NAdella, Toribio re leave i. rosol TJ (2004) - Canine Prostate Carcinomas Express Markers of Urothelial and Prostatic Differentiation, vet pathol
18. MacLachlan NJ, Kennedy PC (2002) - "tumors of the genital systems, Iowa State PRESS 2002
19. Manolescu N., (2002) - "Cytodiagnosis in veterinary medical practice" Publisher CERES;
20. N. Manolescu - coordinator, Alexander N., Balint E, Comisel V. Cranganu D. Mateescu C. Miclaus I, Tanase A, (2003) - "Introduction to Comparative Oncology, University Publishing House" Carol Davila , Bucharest;
21. Manolescu N. Alexander N. Ciobotaru Emilia, Dinescu Georgeta, Militaru Manuella (2000) Compendium of veterinary clinical pathology, Romania for Tomorrow Foundation Publishing House, Bucharest;
22. Meuten J. Donald, "tumors in domestic Animals, Fourth Edition" (2002) PRESS Iowa State, 2002;
23. Mialot JP, Dominique began, Guerin Christine (1984) - edition du point veterinaire output Edition;
24. Manuella Militaru., (1999) - "Fundamentals of pathological anatomy and necropsy diagnosis in medicine veterinard" Publisher elisavaros, Bucharest;
25. W.B Morrison (1998) - Cancer in dogs and cats. and Lippincott Williams Wilkins, Baltimore, USA;
26. Moulton J.E. (1990) - tumors in domestic Animals, Third Edition. University of California Press, USA
27. Ogilvie GK, Moore AS (1997) - "Handbook of cancerologie pratique veterinaire Ed. du point veterinaire, maisONS Alfort;
28. Overman NP (1995) - Compendium on Continuing education for the practicing veterinarian "published by Learning System, 17 (6), 791-806;
29. Nicola Parry MA (2004)The canine prostate gland: Part 1Non-inflammatory diseases
30. Pasta E, Muresianu E., Constantinescu G., Cotofan V. (1978) - "Comparative and topographical anatomy of domestic animals, Didactic and Pedagogic Publishing House, Bucharest;
31. Paul I., (1990) - Pathology equipment and organic systems. Newsletter NO. 23-24, Society of Veterinary Medicine, Romania;
32. Proc E., (1977) - Prostate Cancer Diagnosis, Medical Publishing House, Bucharest;
33. Sandu Cristina (2003) - Dissertation - "the dog prostate syndrome - clinical and pathological diagnosis, UASVM Bucharest, Faculty of Veterinary Medicine, Pathology Discipline;
34. Swinney G. (1998) "Five Prostatic neoplasia in dogs", ANSTI. VET., 76, 669-674;
35. Turrel, JM, (1987)"radiotherapy of the prostate gland in ten dogs, JAVMA 190, 1948-1952;
36. Vladutiu O. (1971) - "Pathology and surgical clinicd, Didactic and Pedagogic Publishing House, Bucharest;
37. Voicescu., Moldovan H. Birtoiu A. Seiciu F., Diaconescu A. Capatana F. (1999) - Breeding and insemination normaa "Romania for Tomorrow Foundation Publishing House, Bucharest;
38. Wallace B. Morison, (1998) - "Cancer in dogs and cats, Medical and Surgical Management, Lippincott Williams and Wilkins, Baltimore, USA;
39. White AS (1991) - "Handbook of Small Animal Oncology" british small animal Veterinary Association;
40. * * * - Merck Veterinary Manual (1998), Ninth Edition - Published by Merck & Co.., INC., Whitehouse Station, NJ, USA MERI Limited in Cooperation with merck and rhone - poulenc company 90, 1948-1952;
41. http://www.vetpathology.org

THE DIAGNOSTIC AND THERAPY APPROACH IN THE URINARY TUMORAL PROCESSES IN DOG

D. CRÎNGANU, Cristina PREDA, M. CODREANU, Raluca CRÎNGANU, V. NICORESCU
Faculty of Veterinary Medicine Bucharest, Bucharest, Romania
cringanudan@yahoo.com

ABSTRACT

Increased incidence in the urinary proliferation processes in dogs in the last two years suggested the idea of a study in the Faculty of Veterinary Medicine Clinic – Bucharest, Romania.It was found (at 37 dogs) that the appearance of age decreased from 7-8 years, averaging 3 to 4 years nowadays. In terms of incidence according to gender, males predominantly develop this neoplastic type, the ratio being 3/1, compared to females. Etiological be legally incriminated:

• the action of physical factors (bladder stones, urolithiasis), they share with a local mechanic-irritating;

• chemical factors such as chlorine in drinking water, some drugs (phenacetin and its derivatives) and sugar substitutes (synthetic sweeteners - cyclamat, saccharin);

• bladder polyp is incriminated as precancerous lesions.

Regarding clinical evolution, it depends on the type of tumor. Thus, primary malignant epithelial tumors develop directly to the transitional epithelium of urinary bladder without precancerous lesions. Secondary epithelial tumors evolve passing through a series of stages: proliferative chronic cystitis, papilloma or fibropapilloma, carcinoma „in situ" and later carcinomas with different histopathological aspects. Clinical and cytopathological exams revealed: hematuria, crystalluria and the transition of malignant cells in the urine, which leads to the diagnosis. Vera mesenchymal tumors show a low incidence; it was diagnosed a case of fibrosarcoma in trigonal bladder. Also, some of the processes at this level started as epithelial formations, evolving in mixed tumors. It was diagnosed a case of malignant lymphoma with secondary extend in bladder wall, characterized by infiltration of lymph-mast, giving the appearance of chronic cystitis in ultrasounds exam.

Establishing the correct diagnosis when the tumor processes developed at the bladder requires a complex approach, with clinical examination is required: ultrasound, urinary cytologic, biochemical examination and urinalysis, urography, optical fiber cistoscopy.

Ultrasound bladder is easy to satisfactory volume of urine to identify tumors; their presence is accompanied by changes localized to the bladder wall and loss of uniformity and continuity of the parietal layers. Tumor extension (except those with infiltrative appearance) intraluminal or perivesical occurs.

1.The order of the work:

Increased incidence of bladder tumors in dog in the last two years This study suggested the idea Clinic Faculty of Veterinary Medicine. age of appearance: decreased from 7-8 years, averaging now in 3-4 years. This dominant male developed location report of being 3 / 1, against female. se criminalize: # action physical factors (calculation bladder, urolithiasis) mechanic-acting local irritation chemical factors # # natural radioactivity chlorine from drinking water, various drugs (phenacetin and its derivatives) and sugar substitutes (sweeteners synthetic (ciclamatul , saccharin) # ca bladder polyp precancerous lesions; # Biological factors: chronic urinary tract infections (Pseudomonas, E. Colli); # genetic factors: bladder carcinoma is characterized by protooncogenei c-ras activation by point mutation in the GGC codon encoding glycine is replaced with GTC coding for valine codon, 12th amino acid peptide with a molecular mass of 21 000 D in this way protooncogena becomes active.

Most commonly affected breeds seem terriers, followed by Cocker, the opposite seems to be German Shepherd. In terms of transitional carcinoma predominant histopathological followed as a share of papillomas, benign epithelial tumors that taxonomic framed but very aggressive clinical and surgical recurrence after ablation.

Clinical primary malignant epithelial tumors developed directly from the Transitional epithelium of urinary bladder without precancerous lesions previously, passing through the secondary epithelial tumors proliferative chronic cystitis, or fibropapilom papilloma, carcinoma in situ and carcinomas of different histopathological aspects later. Clinical and cytopathology was revealed: hematuria, crystalluria and this transition malignizate cells in urine were diagnosed. Vera mesenchymal tumors in the bladder of the dog had a low incidence, a case of fibrosarcoma in trigonal bladder, part of the original bladder epithelial turning into joint. It was recorded and a case of malignant lymphoma with secondary visceralizare bladder wall, characterized by infiltration of lymph â mast, giving ultrasonographic appearance of chronic cystitis.

2. Materials and methods were included in the study and follow-up clinic a total of 37 dogs. Diagnostic steps have to follow the following steps: clinical examination Ultrasound examination of animal urine cytology biochemical examination, urinalysis cistoscopia optic Urography.

Ultrasound of the bladder: easy is satisfied a volume of urine and identify tumors, their presence is accompanied by changes localized to the bladder wall and loss of uniformity and continuity of parietal layers. extension tumor (except looking infiltrate) or perivezical occurs intraluminal.

Ultrasound appearance of the party before and after treatment

Cytodiagnosis exfoliative cytology remains a method of choice exam can be used as surveillance in areas with heavy chemical pollution and the examination for the diagnosis of primary tumors as well as monitoring posttherapeutic exam. A carcinoma in situ evidenced by the presence of posters discarioze cell hyperplasia with increased, cells are spindle or elongated nuclei are tahicromatici to appear, presenting polinucleosis macronucleosis and report kernel / nucleolus is clearly in favor of the latter. Citoarhitectonica is structured on a skeleton conjunctivo-vascular epithelium covered by a cylindrical-cubic.

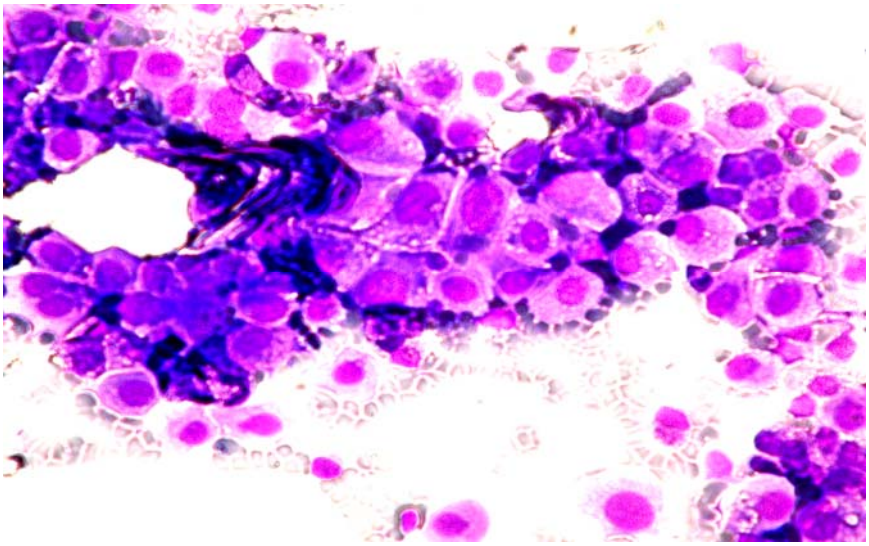

Placarde confluente de celule epiteliale tranzitionale maligne,
cu discarioza marcata si intensa acidofilie citoplasmatica

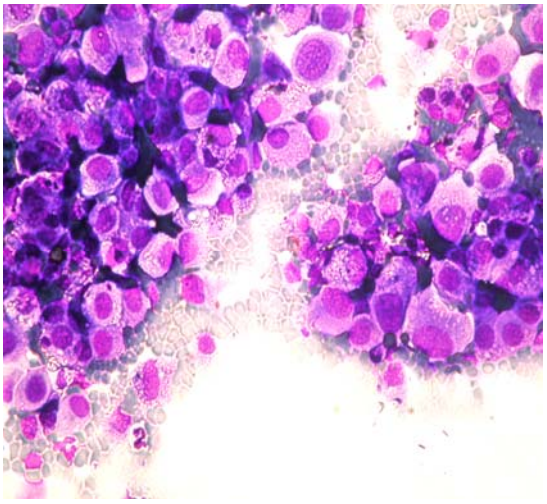

Macrocarioza, report in favor of core nucleo

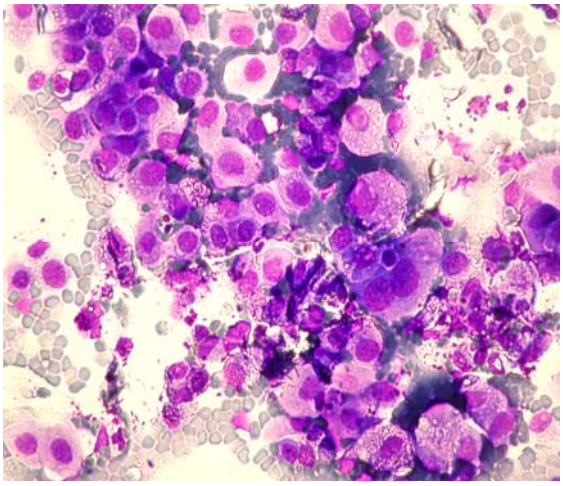

Mixture of malignant tumor epithelial cells, erythrocytes, inflammatory cells and cellular detrisuri

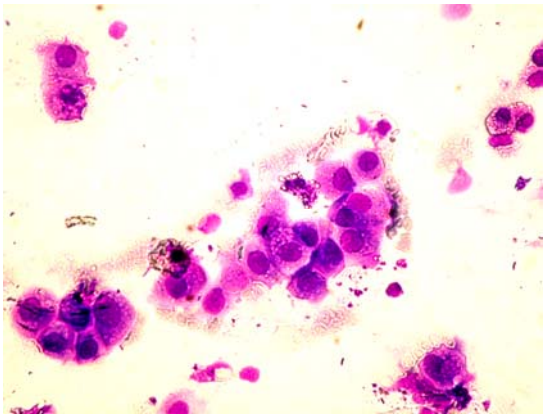

Groups of tumor cells with syncytial appearance

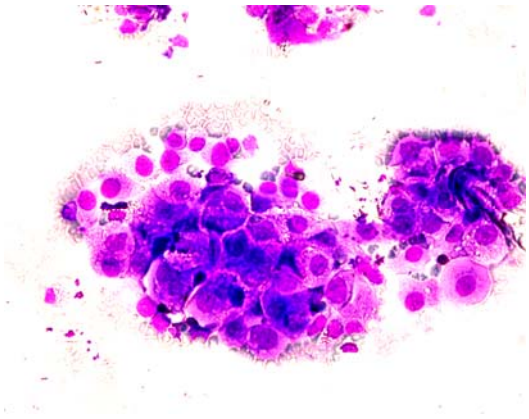

Conglomerate epithelial tumor, possibly with uniclonala origin, is an argument adezivitatea intercellular

THERAPY

According to the clinical stage of tumor was diagnosed, therapeutic means to appeal to the following:

Local (in situ) have occurred:

- Surgical removal of cases that have allowed (sessile polyp)
- Immunotherapy by instilații intravezicale with BCG,
- Adjuvant chemotherapy with doxorubicin chemotherapy or farmarubicină five fluoro-uracil at 14 days after surgery, administration is weekly.

By general, focused on multimodal therapy Medication on the whole body, using:

- Poli-chemiotherapy neoadjuvant chemotherapy:
- Cytostatic alkilante: Ifosfamida 200 mg / m² intravenously to 14 days;
- Platinum derivatives: Carboplatin 50 mg / m² intravenously to 28 days;
- Immunoprophylaxis with: Cantastim, seven days a vial subcutaneously; Polidin, one or two ampoules subcutaneously to 14 days, BCG

General Therapy for amending the disease syndromes paraneoplazice and chemotherapy, using: hemostatic drugs: etamsilat, fitomenadiona, calcium (intravenous); diuretics: furosemide, furantril 2 hours after chemotherapy, chemotherapy for elimination of excess body

CONCLUSIONS

- The main characteristics of malignant tumor cells highlighted in Transitional carcinoma of the bladder is pleomorfismul and clustering in posters
- Citodiversitatea malignant may have marked a high degree of significance aneuploidie
- Multimodal therapy aimed at inhibiting proliferation of malignant tumor cells with cytostatics bladder administered by instillation, but generally avoid metastazarii.
- Therapy was performed in situ with alternating chemotherapy and immunostimulatory (BCG)
- Full remission periods were different from 3 months to 2 year

BIBLIOGRAPHY:

1. Baba AI (2002) "Comparative Oncology", Romanian Academy Publishing House, Bucharest;
2. Rebecca Baker, Lumsden J.H. (2000) - "Color Atlas of Cytology of The Dog and cat, Mosby Inc.;
3. Nicolae Constantin - coordinator Birtoiu IA, Codreanu M, Constantin N., N. André Cornil, G. spine, Diaconescu A. Seiciu F., Sone A, (2003) - "Textbook of Veterinary Medicine, vol.III , Technical Publishing House Bucharest
4. N. André Cornil, Manolescu N. (1995) - "Structure and ultrastructure of organs in domestic animals", Publisher CERES, Bucharest;
5. Manolescu N., (2002) - "Cytodiagnosis in veterinary medical practice" Publisher CERES;
6. N. Manolescu - coordinator, Alexander N., Balint E, Comisel V. Cranganu D. Mateescu C. Miclaus I, Tanase A, (2003) - "Introduction to Comparative Oncology, University Publishing House" Carol Davila , Bucharest;
7. Manolescu N. Alexander N. Ciobotaru Emilia, Dinescu Georgeta, Militaru Manuella (2000) - Compendium of veterinary clinical pathology, Romania for Tomorrow Foundation Publishing House, Bucharest;
8. Dan Cringanu - Pathology pet, general oncology, Printech, 2009, Bucharest
9. Dan Cringanu Maria Crivineanu - Veterinary Cancer Therapy, Printech, 2009, Bucharest

FREE RADICALS SCAVENGING ACTIVITY OF SOME HYDRO-ALCOHOLIC PHYTOCOMPOUNDS

Maria CRIVINEANU, Camelia PAPUC, Corina DURDUN, V. NICORESCU

Faculty of Veterinary Medicine Bucharest, 105 Splaiul Independentei, 050097, Bucharest, Romania, E-Mail: durduncorina@yahoo.com

ABSTRACT

Reactive oxygen and nitrogen species are implicated in several physiological and pathological processes. To protect biological targets from oxidative damage, antioxidants must react with reactive species faster than biological substrates. The aim of the present study was to determine in vitro antioxidant activity of hydro-alcoholic extracts from St. John's wort (Hypericum perforatum), common hawthorn (Crataegus monogyna) and nettle (Urtica dioica), using several different assays: 2,2-diphenyl-1-picrylhydrazyl (DPPH•), superoxide anion (O_2•-), hydroxyl radical (HO•), nitric oxide (NO•) scavenging activity and lipid peroxidation inhibition activity. The amounts of total phenolic compounds were higher for Hypericum perforatum ethanolic extract (40.43 ± 3.39 mg/g), while the lowest content was recorded for Urtica dioica ethanolic extract (9.5 ± 0.95 mg/g). The highest amount of flavonoids was in found in Crataegus monogyna ethanolic extract (39.84 ± 3.11 µg/g). The maximum effect for DPPH• annihilation was observed for Crataegus monogyna and Hypericum perforatum alcoholic extracts (77.97 ± 5.10 % and 72.25 ± 5.07 % inhibition, respectively).

Keywords: polyphenols, flavonoids, reactive oxygen species, reactive nitrogen species.

There is increasing evidence that oxidative stress, defined as an imbalance between oxidants and antioxidant in favor of oxidants, leads to many biochemical changes and that is an important causative factor in several human chronic diseases, such as atherosclerosis and cardiovascular diseases, mutagenesis and cancer, several neurodegenerative disorders, and the aging process (3, 4).

Free radicals produced as a result of normal biochemical reactions in the body are implicated in various human diseases; therefore interest in reactive oxygen species (ROS) has substantially increased in direct relation to cellular abnormalities. However, quantities of ROS which overwhelm the capacity of the body's defense system may result in irreversible oxidative damage to DNA, proteins and lipids, causing cellular and metabolic injuries.

In the past few years, natural antioxidants have generated considerable interest in preventive medicine (7, 10). Epidemiological studies have shown that fruits and vegetables rich in antioxidants can have complementary mechanisms of action, including scavenging of free radicals, antibacterial and antiviral effects, stimulation of the immune system, regulation of cell proliferation and apoptosis (14). As a result, attention has been directed towards the characterization of antioxidant properties of plant extracts/their fractions and identification of the constituents responsible for those activities (11, 12).

MATERIALS AND METHODS

Preparation of ethanolic extracts

In this study there were used dried aerial parts of St. John's wort *(Hypericum perforatum),* common hawthorn *(Crataegus monogyna)* and nettle *(Urtica dioica)*. The interest parts of plants were powdered and extracted with ethanol 60 % (1:10 ratio, w:v) for 3 hours at 60ºC. The homogenates obtained were filtered using filter paper Watman no. 1 and the filtrates were then centrifuged for 20 min at 5000 rpm and 5ºC. These crude extracts were used for further investigation.

Determination of total phenolic content

Total polyphenols from *Hypericum perforatum, Crataegus monogyna* and *Urtica dioica* ethanolic extracts were determined with Folin-Ciocalteu reagent using caffeic acid as standard (2, 13). From the stock solution of the extract, suitable quantity was taken into a 10 mL volumetric flask and properly diluted. Then were added 0.2 mL Folin Ciocalteu reagent and 0.5 mL of 20 % (w/v) Na_2CO_3 solution, respectively. The solution was shaken and then water was added to 10 mL. The reaction mixture was left for color development for 1 hour and the absorbance was measured at 725 nm using an UV-VIS Jasco spectrophotometer V670. The total phenols content was expressed as mg caffeic acid equivalent/g of dry plant material.

Determination of total flavonoid content

Total hydroalcoholic soluble flavonoid content of the extracts was determined with a colorimetric assay described by Jay and Gonnet (6). The method is based on the interaction of flavonoids from ethanolic extracts with $AlCl_3$ reagent, resulting a colored compound. An aliquot of 5 mL of diluted plant extract, 2.5 mL of $AlCl_3$ reagent were added and absorbances were recorded at 430 nm against blank (5 mL of analyzed solution and 2.5 mL of extracting solvent) using an UV-VIS Jasco spectrophotometer V670. Flavonoids contents were determined as µg quercetin equivalent/g of dry plant material.

DPPH radical scavenging activity

DPPH radical scavenging activity was investigated according to the method described by Burits and Bucar (1). Briefly, to an ethanolic solution of DPPH (4mg/100mL), 0.05 ml of test compounds dissolved in ethanol were added. Equal amount of ethanol was added to the control. Absorbance was recorded at 517 nm after 30 minutes using an UV-VIS Jasco spectrophotometer V670.

Superoxide anion scavenging activity

Superoxide anions, produced by NADH (nicotinamide adenine dinucleotide) and PMS (phenazine methasulphate), reduce NBT (nitro blue tetrazolium salt) and produce a formazan compound. The intensity of color is inversely proportional to the antioxidant concentration (7). Reactions were started by adding NADH. After incubation at 25°C for 10 minutes, the color intensity of mixture was measured at 560 nm using an UV-VIS Jasco spectrophotometer V670 and inhibition percentage was calculated using the following equation:

$$\% \text{ Inhibition} = \frac{A_{blank} - A_{sample}}{A_{blank}} \times 100$$

Hydroxyl radical scavenging activity

The deoxyribose method for determining the scavenging effect of the hydroxyl radical was performed according to a described procedure (5). Reaction mixtures in a final volume of 2.5 ml, contained 500 µM $FeSO_4$, 20 mM H_2O_2, 20 mM deoxyribose, 100 µL diluted sample, 800 µL

distillated water, 2.8 % trichloroacetic acid (TCA) and 0.67 % thiobarbituric acid (TBA). All components were dissolved in 0.1 M, pH 7.4 phosphate buffer. After incubation at 100°C for 20 minutes, the absorbance of the resulting solution was measured at 532 nm using an UV-VIS Jasco spectrophotometer V670 and inhibition percentage was calculated through the same equation.

Nitric oxide scavenging activity

Nitric oxide scavenging activity was measured spectrophotometrically (8). Sodium nitroprusside (5mM) in phosphate buffer saline was mixed with diluted extract in ethanol and incubated at 29°C for 120 min. 2 ml of the incubated solution were removed and diluted with 1.2 ml of Griess reagent (1% sulphanilamide, 2% phosphoric acid, and 0.1% naphthyl ethylene diamine dihydrochloride). The absorbance of the chromophore formed during diazotization of the nitrite with sulphanilamide and subsequent coupling with naphthylethelene diamine was measured at 546 nm along with a control using an UV-VIS Jasco spectrophotometer V670 and inhibition percentage was calculated.

RESULTS AND DISCUSSION

Total phenolic content

The analysis of the phytocompounds showed the presence of high contents of phenolics, contents which may be responsible for the activity of the plants, beside other phytochemicals (table 1). The amounts of total phenolic compounds were higher in *Hypericum perforatum* ethanolic extract (40.43 ± 3.39 mg/g) comparatively to *Urtica dioica* ethanolic extract (18.57 ± 1.55 mg/g) and *Crataegus monogyna* ethanolic extract (33.89 ± 2.98 mg/g).

Total flavonoid content

The highest amount of flavonoids was found in *Crataegus monogyna* ethanolic extract (39.84 ± 3.11 µg/g), while the lowest amount was found in *Hypericum perforatum* ethanolic extract (11.31±1.21 µg/g) (table 1). In this study, very low correlation (R^2 = 0.0349) between phenolic compounds and flavonoids has been found; this correlation was also found by other researchers (9). This fact could be explained by the presence of some chemical groups such as amino acids and proteins that can also react with Folin-Ciocalteu reagent (9).

Table 1

Phenolic and flavonoid contents of the studied plant alcoholic extracts

Sample	Phenolics content (mg equivalent cafeic acid/ g dried plant)	Flavonoid Content (µg equivalent quercitin/ g dried plant)
Hypericum perforatum	40.43 ± 3.39	11.31±1.21
Crataegus monogyna	33.89 ± 2.98	39.84 ± 3.11
Urtica dioica	18.57 ± 1.55	22.90 ± 2.24

DPPH radical scavenging activity

DPPH• is a stable free radical at room temperature and it accepts an electron or hydrogen radical to become a stable diamagnetic molecule. DPPH radical scavenging activity was determined by the decrease of absorbance at 517 nm, which is induced by antioxidants. Fig. 1 illustrates a significant scavenging activity for all three studied plant extracts. A maximum

effect was observed for *Crataegus monogyna* and *Hypericum perforatum* alcoholic extracts: 77.97 ± 5.10 % and 72.25 ± 5.07 % inhibition, respectively. Good correlation (R^2 = 0.9144) has been recorded between the DPPH radical scavenging activity and total phenolics content. It has been suggested that polyphenol compounds are likely to be contributing to the radical scavenging activity (9).

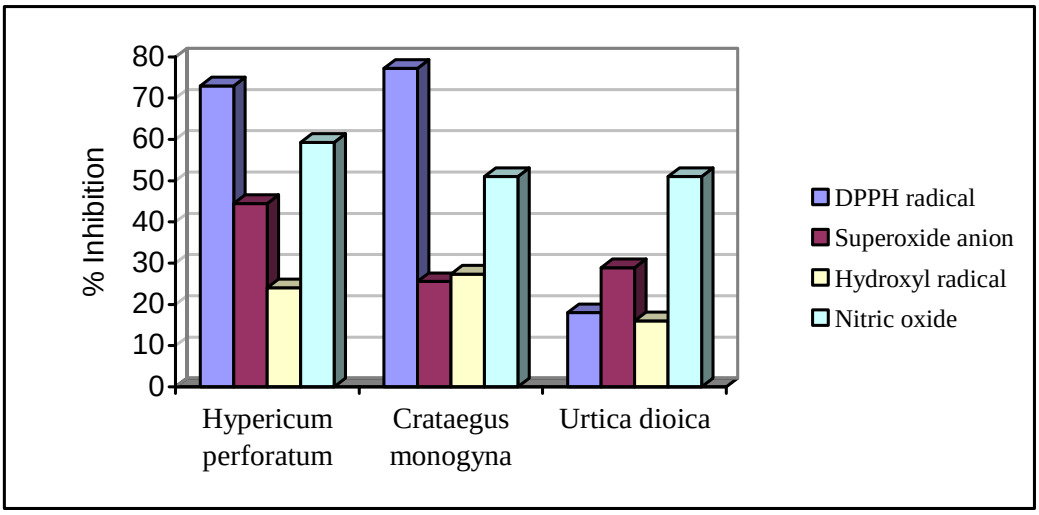

Fig. 1. DPPH radical, superoxide anion, hydroxyl radical and nitric oxide scavenging activity of the studied alcoholic extracts

Superoxide anion scavenging activity

In this study, superoxide anions are derived from PMS/NADH-NBT system. The decrease of absorbance at 560 nm with antioxidants indicates the consumption of superoxide anion in the reaction mixture. Fig. 1 shows the superoxide anion scavenging activity: 44.44 ± 4.02 % for *Hypericum perforatum,* 25.55 ± 2.20 % for *Crataegus monogyna* and 28.88 ± 2.12 % for *Urtica dioica*. *Hypericum perforatum* had strong superoxide anion scavenging activity.

Hydroxyl radical scavenging activity

Highly reactive hydroxyl radicals can cause oxidative damage to DNA, lipids and proteins. Deoxyribose is degraded by exposure to hydroxyl radicals generated by Fenton systems. If the resulting complex mixture is heated under acid conditions, fragments of deoxyribose may be detected by its ability to react with TBA to form a pink chromogen. Fig. 1 shows the effect of the extracts on the Iron (II)-dependent deoxyribose damage. *Hypericum perforatum* alcoholic extracts showed 24.06 ± 2.33 % inhibition, *Crataegus monogyna* alcoholic extracts inhibited 27.37 ± 2.31 % HO• and *Urtica dioica* alcoholic extracts showed 16.04 ± 1.09 % inhibition.

Nitric oxide scavenging activity

Nitric oxide generated from sodium nitroprusside at physiological pH was found to be inhibited by alcoholic extracts obtained from medicinal plants. Fig. 1 shows the percentage inhibition of nitric oxide generation by *Hypericum perforatum* (59.31 ± 5.29 %), *Crataegus monogyna* (50.98 ± 5.12 %) and *Urtica dioica* (50.98 ± 5.11 %).

CONCLUSIONS

1. *Hypericum perforatum, Crataegus monogyna* and *Urtica dioica* alcoholic extracts have important phenolic and flavonoid contents.
2. St. John's wort *(Hypericum perforatum),* common hawthorn *(Crataegus monogyna)* and nettle *(Urtica dioica)* ethanolic extracts manifested scavenging activities against DPPH•, superoxide anion, hydroxyl radical and nitric oxide.

ACKNOWLEDGEMENTS

This work was supported by CNCSIS –UEFISCSU, PNII – IDEI program, project number ID_1304/2009.

REFERENCES

1. Burits M., Bucar F. - Antioxidant activity of Nigella sativa essential oil. *Phytother Res* 14: 323–328, 2000.
2. Conrad A., Birch M., Dacombe C., Humphrey P.G., Martin P.T. - Factors affecting the caffeine and polyphenol contents of black and green tea infustions, *Journal of Agricultural and Food Chemistry*, 49, 5340 – 5347, 2001.
3. Dumitrescu C., Olteanu R.L., Bumbac M., Gorghiu L.M. - Antioxidant effect of some flavonoids on organic substrate. *Rev. Chim*. , 60(4), pp. 329-331, 2009.
4. Frei B, Stocker R., Ames B.N. - Small molecule antioxidant defenses in human extracellular fluids. In: Molecular Biology of Free Radical Scavenging Systems, Vol 5 (Scandalios JG, ed). Plainview, NY:Cold Spring Harbor Laboratory Press, 23-46, 1992.
5. Halliwell B., Gutteridge J.M.C., Aruoma O.I. - The deoxyribose method: a simple 'test tube' assay for determination of rate constants for reactions of hydroxyl radicals. *Annals Biochem*. *165*: 215-19, 1987.
6. Jay M., Gonnet J.F. - Premieres observations relatives a la variation dans l'expression du metabolisme flavonique chex le Phragmites australis, *Phytochemistry*, 14, 1605–1612, 1975.
7. Liu F., Ng T.B. - Antioxidative activity of natural products from plants. *Life Sci* 66: 725-735, 2000.
8. Marcocci I., Marguire J., Droy–Lefaiz M.T., Packer L. - The nitric oxide scavenging properties *Ginkgo biloba* extract. *Biochemical and biophysical Research communication.* 201: 748-755, 1994.
9. Meda, A., Lamien, C.E., Romito, M., Millogo, J., Nacoulma, O.G. - Determination of the total phenolic, flavonoid and proline contents in Burkina Fasan honey, as well as their radical scavenging activity. *Food Chem.*, *91*, 571-577, 2005.
10. Papuc Camelia, Diaconescu Cristiana, Nicorescu V., Crivineanu Carmen - Antioxidant activity of polyphenols from sea buckthorn fruits *(Hippophae rhamnoides). Rev. Chim. (Bucuresti)*, 59, pp. 392-394, 2008.
11. Soares J.R., Dinis T.C., Cunha A.P., Almeida L.M. - Antioxidant activities of some extracts of *Thymus zygis*. *Free Radic. Res*., 26: 469-78, 1997.
12. Valentao P., Fernandes E., Carvalho F., Andrad P. B., Seabra R. M., Bostos M. L., - *J. Agric. Food. Chem.*, 49, 3476—3479 2001.
13. Wollgast Jan, - The contents and effects of polyphenols in chocolate, qualitative and quantitative analys of polyphenols in chocolate and chocolate raw products as well as evaluation of potential implications of chocolate consumption in human health, Doctoral thesis, Jutus Liebig University of Giessen, Germany, 2004.
14. Yanping, Z., Yannua, A., Dongzhi, Wei. - Antioxidant Activity of a flavonoid rich extract of *Hypericum perforatum* L. in vitro. *J. Agric. Food Chem*., 52, 5032-5039, 2004.

THE EFFECTS OF THIAMPHENICOL ADMINISTRATION UPON KIDNEYS IN RATS

Maria CRIVINEANU, V. NICORESCU, Camelia PAPUC,
Maria VOICU (MIU), Elena ROTARU
Faculty of Veterinary Medicine Bucharest,
105 Splaiul Independentei, 050097, Bucharest, Romania,
maria_crivineanu@yahoo.com

ABSTRACT

The occurrence of adverse reactions is a common consequence of drugs use. The aim of this study was to identify renal modifications following the injectable administration of thiamphenicol in rats. The experimental model consisted in four lots of rats, which received the drug for different periods of time; it was studied the way in which thiamphenicol acts upon kidneys' functional capacity and in what manner it affects kidneys' morphology, taking into consideration the fact that this drug is eliminated from the organism mainly by urinary pathway. To accomplish these purposes, there were performed paraclinical exams, consisting in the determination of serum urea and creatinine and histopathological exams. The results showed that long treatments with thiamphenicol determined the appearance of renal functional changes (increased urea and creatinine), as well as histopathological modifications of the kidneys (progressive degenerations of tubular epithelium and tubular necrosis in the final stage).

Key words: thiamphenicol, kidney, rats, tubular necrosis.

Various degrees of nephrotoxicity caused by certain antibiotics, including those of phenicols group, were consecutively reported in animal therapy (3, 4, 5). Knowing that phenicols group antibiotics have different side effects, this experiment intended to reveal kidney disorders induced by thiamphenicol administration in rats.

Thiamphenicol is usually used for Gram-positive and Gram-negative severe infections control in animals (1, 2). The study of this antibiotic's pharmacokinetics showed that its elimination takes place mostly through the kidneys, making urine concentrations 50-100 times higher compared to blood levels (1, 2).

MATERIALS AND METHODS

The experiment was conducted using a total of eight rats, females and males, ageing approximately 4 month and weighting 150 grams. The animals were kept in darkness throughout treatment, in separate cages; watered *ad libitum*; feed was represented by grains of wheat, corn, grass, cabbage, carrots and industrial feed. The experimental model consisted in daily thiamphenicol administration for 20 days in a dose of 100 mg/kg once a day, by intraperitoneal injections.

The main goal of this study was to observe biochemical and histopathological modifications during thiamphenicol administration. Nephrotoxicity was appreciated by histological changes and impaired renal function.

The animals were split in four study groups of two rats each. The animals in first group were sacrificed after 5 days; those in the second group were sacrificed after 11 days, those in the third group were sacrificed after 15 days and the animals in the fourth group were sacrificed after 20 days. Animals were anesthetized with xylazine and ketamine, the abdominal cavity was opened on white line, the viscera were removed and blood was collected from aorta and heart to evaluate blood biochemical parameters, especially blood nitrogen urea and creatinine. Kidneys were sampled, placed in 10% formaldehyde solution and quickly sent to the laboratory (before cadaveric changes occur) for histopathological examination.

RESULTS AND DISCUSSIONS

Blood nitrogen urea and creatinine values after thiamphenicol administration in rats for 5, 11, 15 and 20 days are presented in table 1 and fig. 1.

Table 1

Blood nitrogen urea and creatinine values after thiamphenicol administration in rats

Experimental groups (days of thiamphenicol administration)		**Blood nitrogen urea (*mg/dl*)**	**Blood creatinine (*mg/dl*)**
Lot 1 (5 days)	Rat 1	19.0	0.70
	Rat 2	19.5	0.78
Lot 2 (11 days)	Rat 3	18.5	0.70
	Rat 4	19.1	0.80
Lot 3 (15 days)	Rat 5	30.0	0.88
	Rat 6	32.0	0.90
Lot 4 (20 days)	Rat 7	34.0	1.34
	Rat 8	33.0	1.50
Normal values		*20-24*	*<0.8*

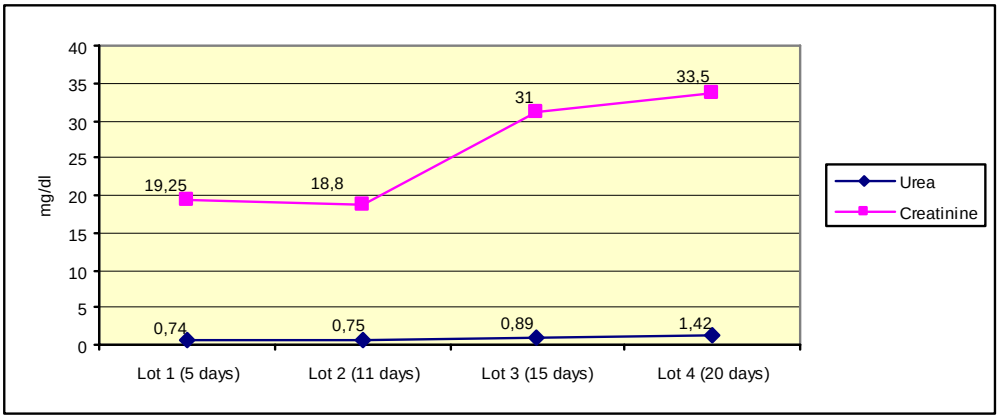

Fig. 1. Graphical representation of serum urea and creatinine mean values obtained in rats after the administration of thiamphenicol

Lot 1. The animals in first study group didn't show altered clinical state and blood biochemical parameters were within physiological limits (table 1).

Histological changes observed were represented by stasis in glomerular capillaries, Bowman's capsule discrete thickening, granular degeneration in renal tubes (Fig. 2), presence of hyaline cylinders and decreased glomerular filtration space (Fig. 3).

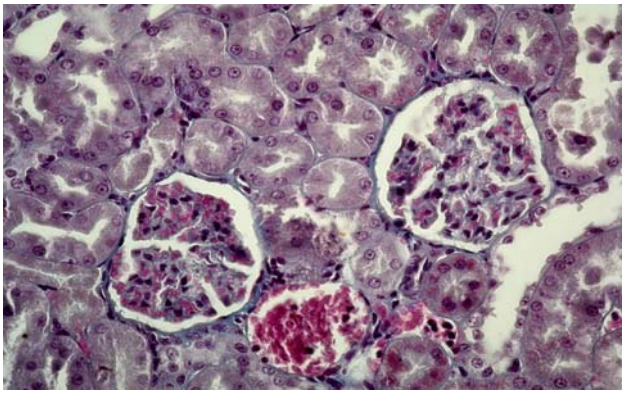

Fig. 2. Kidney – tubes granular degeneration, stasis in capillaries, thickened Bowman's capsule (Masson col., Ob. 40).

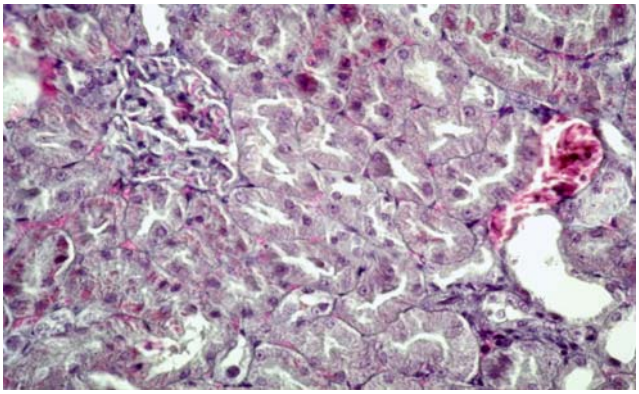

Fig. 3. Kidney – tubes with granulovacuolar dystrophy, presence of hyaline granules in tubes and glomerules with reduced filtration space (Masson col., Ob. 40).

Lot 2. After 11 days of intraperitoneal administration of thiamphenicol, there were not observed clinical changes in animals in this study group.

Histological examination showed kidneys with granular dystrophy in most tubes, in some areas vacuolar dystrophy and hyaline cylinders (Fig. 4, 5). Despite all these changes in kidneys, blood biochemical parameters were within normal limits (table 1).

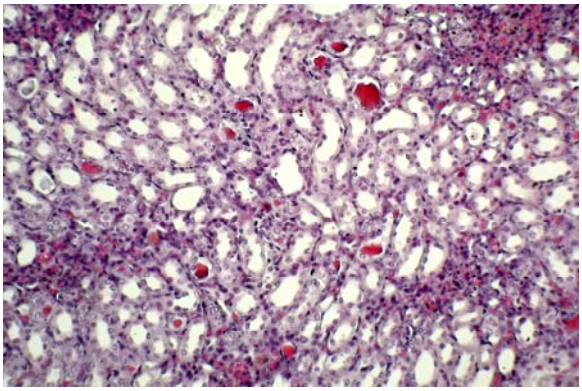

Fig. 4. Granular dystrophy in most kidney tubes and isolated vacuolar degeneration, and reduced mononuclear infiltrates (Masson col., Ob. 20).

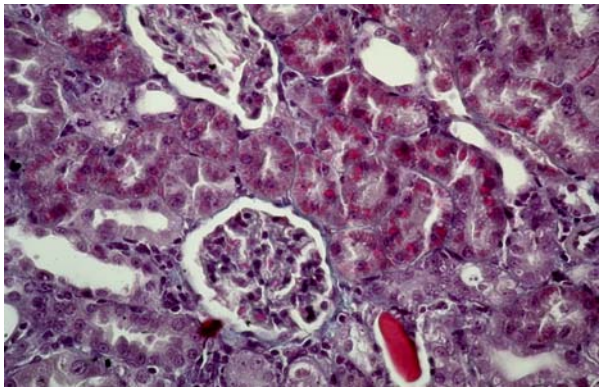

Fig. 5. Kidney with hyaline cylinders and Bowman's capsule thickening (Masson col., Ob. 40).

Lot 3. The animals in study group 3 (treated with thiamphenicol for 15 days) showed mild apathy and appetite loss; serum creatinine and blood nitrogen urea levels increased significantly (table 1). Histological examination showed ischemia in glomerular capillaries, tubular necrosis and hyalinosis (Fig. 6, 7).

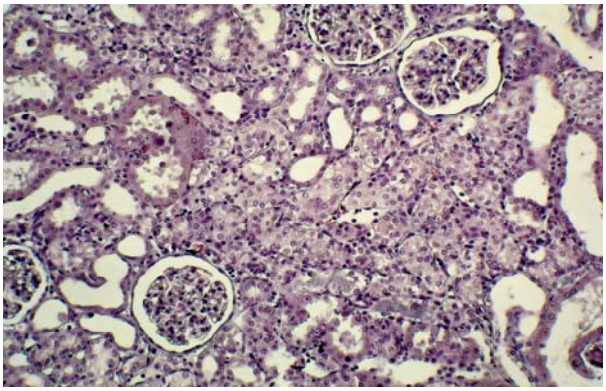

Fig. 6. Ischemia in kidneys glomerular capillaries, dystrophy and tubular necrosis (Col. Masson, Ob. 10).

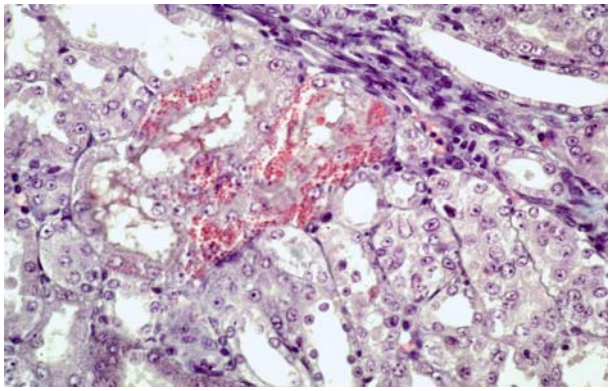

Fig. 7. Hyalinosis and kidney tubular necrosis (Col. Masson, Ob. 40).

Lot 4. Symptoms observed in animals in study group 4 were dominated by apathy. Blood nitrogen urea levels were over the normal limit, but the increase was not significant compared to those registered in animals in study group 3; instead, blood creatinine values almost doubled compared to those registered for animals in study group 3 (table 1). Histological examination revealed diffuse tubular necrosis and hyalinosis (Fig. 8). Toxic action of thiamphenicol resulted in tubular necrosis and some epithelial regeneration (Fig. 9).

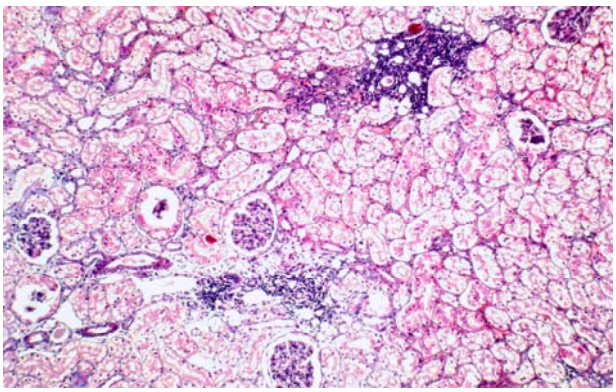

Fig. 8. Kidneys with interstitial mononuclear infiltrates, tubular necrosis and diffuse hyalinosis (Col. Masson, Ob. 10).

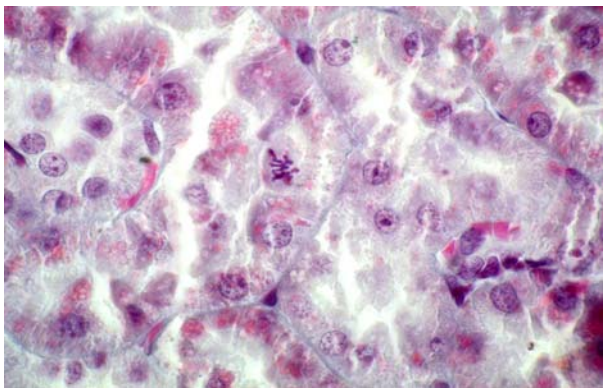

Fig. 9. Kidney tubular necrosis, hyalinosis and cells epithelium in division (Col. Masson, Ob. 100).

CONCLUSIONS

1. After 5 and 11 days of thiamphenicol administration in rats, blood urea and creatinine were within physiological limits; after 15 and 20 days of administration, these parameters presented elevated levels.
2. Histopathological modifications installed gradually and they consisted in stasis in glomerular capillaries, Bowman's capsule thickening, granular degeneration in renal tubes, hyalinosis and in the final stage it was recorded tubular necrosis.

3. Although animals in lots 1 and 2 presented kidney alterations, blood urea and creatinine were within normal limits.
4. Diffuse lesions were registered in samples from animals in lots 3 and 4 that led to the appearance of renal failure.

REFERENCES

1. Abdennebi E.H., N. Khales, R.J. Sawchuk, C.M. Stowe - Thiamphenicol pharmacokinetics in sheep. *J. Vet. Pharm. Ther.*, 17(1):12/16, 2008.
2. Abdennebi E.H., R.J. Sawchuk, C.M. Stowe - Thiamphenicol pharmacokinetics in beef and dairy cattle. *J. Vet. Pharm. Ther.*, 17(5): 365-368, 2008.
3. Ando J., Roza Ishihara, S. Imai, S. Takano, T. Kitamura, M. Takahashi, M. Yoshida, A. Maekawa - Thirteen-week subchronic toxicity study of thiamphenicol in F344 rats. *Tox. Lett.*, 91(2): 137-146, 1997.
4. Morin J.P., J.P. Fillastre, B. Olier - Antibiotic nephrotoxicity. *Chemioter.*, 3(1): 33-40, 1984.
5. Roberts M.C. - Antibiotic toxicity, interactions and resistance development. *Periodontol*., 28:280-297, 2002.

MORPHOLOGICAL ASPETCS OF THE MAJOR SALIVARY GLANDS IN THE RAT

A. DAMIAN, V. MICLĂUŞ, I. PAPUC
Faculty of Veterinary Medicine, Cluj-Napoca, 3-5 Calea Mănăştur
Email: catedra1mv@yahoo.com

ABSTRACT

Our study aimed to present the normal morphology of the major salivary glands in rats through the dissection of 12 subjects. The project was carried on in the Comparative Anatomy Laboratory and Histology Laboratories of the Faculty of Veterinary Medicine, Cluj-Napoca. Our paper has revealed the fact that the rat has three pairs of major salivary glands (parotid, mandibular and sublingual), closely located together, but with clearly distinctive histological structures and separated from each other by conjunctive tissue. We have also located the extraorbital lacrimal gland, paired organ specific to this species, which must not be accidentally included into the salivary glands group.

Key words: salivary glands, rat, morphology

INTRODUCTION

The rat (Rattus norvegicus) is one of the main species used in medical research. This animal offers an excellent model for the study of a large range of human diseases, which lends itself to type selection and genetic manipulation and is easily bred. [2]. Our study aimed to identify the rat's greater salivary glands, their topography, from the macroscopic perspective, as well as from the perspective of their histological structure. The purpose of this study was to verify and expand the few data existent in our country with regards to the rat's morphology.

MATERIAL AND METHODS

The research was conducted on 12 Winstar adult rats, 7 females and 5 males, weighting between 150 and 300 grams, provided by the Breeding Base of the University of Medicine and Pharmacology, Cluj-Napoca. The dissection was carried out in the Comparative Anatomy Laboratory of the Faculty of Veterinary Medicine, Cluj-Napoca, and the histological processing and interpretation of the samples was made in the Histology Laboratory of the same faculty.
After general anaesthesia, the rats were euthanatized, and the dissection was performed according to the following steps:

- removal of the skin from the inferior and lateral regions of the head and of the neck and from the pectoral region and forelimbs for an optimal visibility;
- removal of the subcutaneous tissue;
- removal of the adipose subcutaneous deposits;
- identification and highlighting of the major salivary glands:
    - parotid;
    - mandibular;
    - sublingual.

To analyse the structure of these glands, we have taken tissue samples of each, which were processed and stained following the Tricrom Goldner technique, followed by optical microscope examination.

RESULTS AND DISCUSSION

The major salivary glands of the rat are placed in the lateral and ventral sides of the neck (Fig.1). They are easily identified by carefully removing the skin and subjacent tissues, and are surrounded by a mass of adipose tissue and the local lymph nodes.

Fig. 1. General view of the major salivary glands of the rat, after the removal of the skin, ventral view.

Parotid gland

The parotid gland (Fig.2) is situated at the base of the ear, from where it extends to the ventro-lateral side of the neck, up to the scapulo-humeral joint. As mentioned by both Sharp (1998) and Krinke (2000), this gland is very well developed and consists of 3-4 lobes. Particular to the rat, there is an extraorbital lacrimal gland situated above the parotid and the subparotidian lymph node. Although Parhon et al. (1957) states that this is part of the parotid gland, our observations concur with the data provided by Krinke (2000), according to which this is a distinct element, which must not be mistook for a salivary gland.

Histologically, the parotid gland of the rat is composed of serous acini (Fig.3).

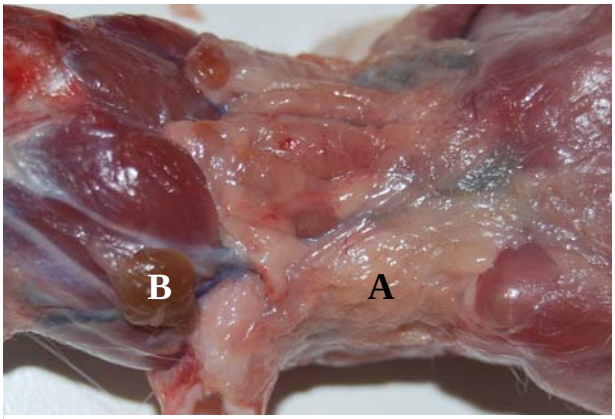

Fig. 4. Parotid gland (A) and extraorbital lacrimal gland (B).

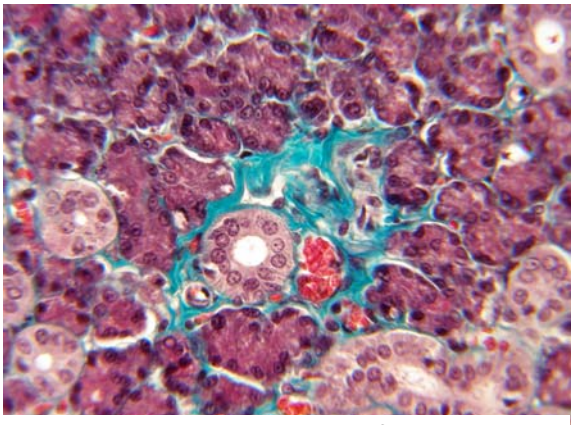

Fig. 3. Histological structure of the parotid – serous acini (Goldner ob. 40X).

Mandibular gland

This gland, also found in both foreign and local specialized literature under the older names of submandibular or submaxillary gland [2,3] is located ventrally from the parotid gland and is contiguous with the sublingual gland (Fig.4).

Approaching the mandibular gland, both Sharp (1998) and Krinke (2000) present it as a mixed sero-mucous gland., Yet we have ascertained, following our examination, that this gland has an unusual structure, unseen in any of the major of minor salivary glands of other species, namely the fact that it only presents small sized acini.

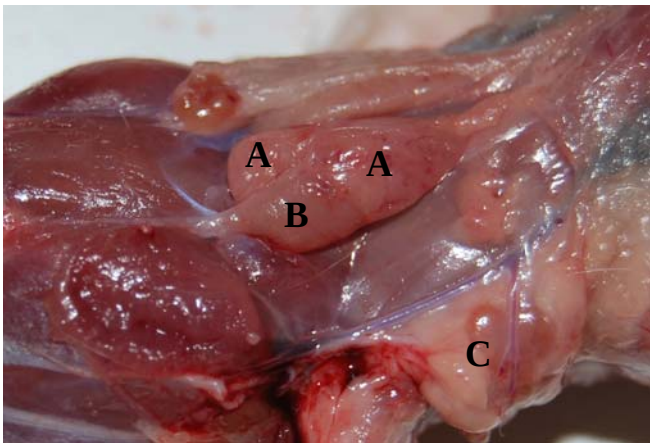

Fig. 6. Mandibular gland (A) and sublingual gland (B), after the detachment and lateral reflection of

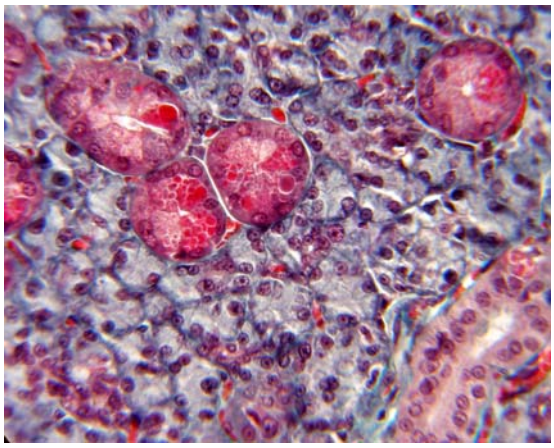

Fig. 5 Histological structure of the mandibular gland – small acini (Tricrom

Sublingual gland

The sublingual gland is small and round, placed slightly laterally to the apical pole of the mandibular gland, covering a third of it (Fig.4). It is intimately united to the mandibular gland's body, creating the illusion of being a part of it.

The histological examination of the sublingual gland has proven that this gland is made up of mucous acini (Fig.6), a fact also supported by the specialized literature [2,3].

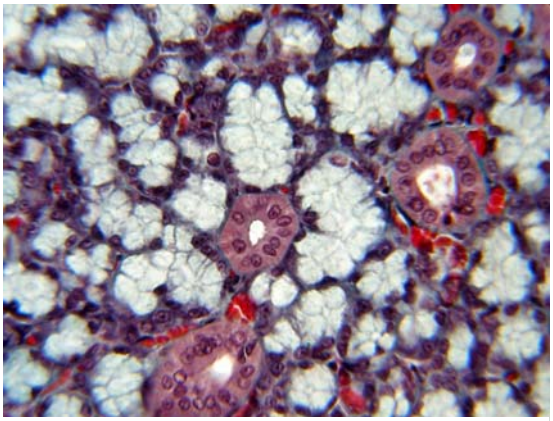

Fig. 7. Mucous acini and striated canals in the sublin-gual gland (Tricrom Goldner, ob

Parhon (1957) describes the mandibular gland as being composed of three portions, a serous one, a mucous one and a heterocrine one and does not mention the presence of a sublingual gland. Following our observations, we have found that this presentation is not accurate.The histological sections made by us have shown that the first portion described by the aforementioned author is distinctively separated by a thin but dense capsular. As to its structure, it is composed exclusively of serous acini and excretory canals. These serous acini have all the characteristics of the serous acini form the parotid gland of the majority of species and of those from the exocrine pancreas (Fig.7c).

Taking into account the definite isolation (by means of its own capsule) and all its structural characteristics similar to the parotid's, we consider this portion to be an actual part of the parotid gland, a prolongation of it which comes in contact with the mandibular gland.

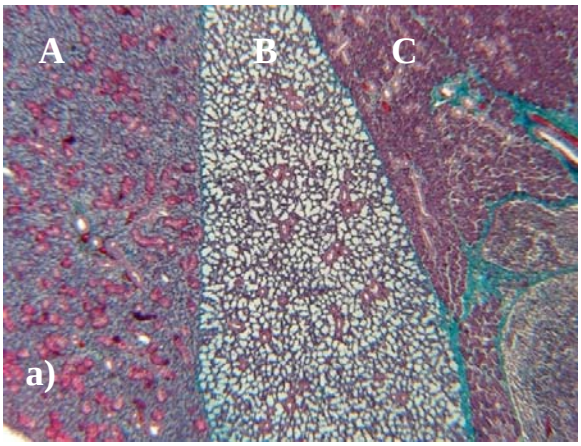

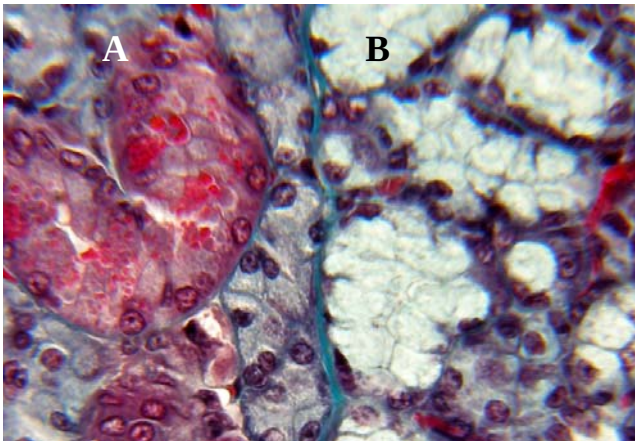

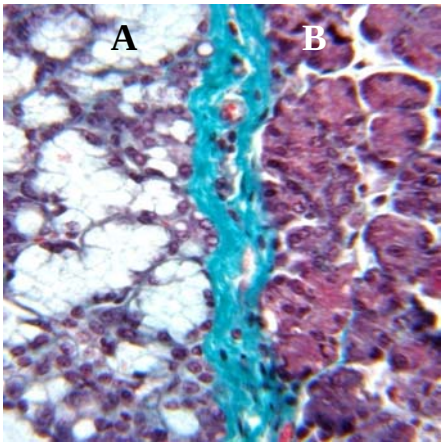

Examining the second segment described by Parhon (1957), we have notice that it is made of mucous acini and it is also separated from the other two portions through its own capsule, similar in density and width to that of the previous segment (Fig.7b). Due to all their characteristics, the acini of this segment resemble those of the sublingual gland in the majority of species. Taking into account all these aspects, we consider this second segment to be a part of the sublingual gland and not one of the mandibular gland, to which it is only intimately adjacent to. The third portion, as we have mentioned earlier, is not a classic mixed gland with three types of acini as in the other mammals, but it contains a single type of particular acini. We consider that this segment is actually the mandibular gland. Out study underlines, thus, the fact that the mandibular gland of the rat is not made up of three segments, but rather the three major salivary glands are closely adjacent to each other, composing a glandular complex (Fig.7a). It is a very interesting

Fig. 7 The intimate adjacent placement of the three major salivary glands:

a) Cross section, left to right: mandibular gland (A), sublingual gland (B) and parotid gland (C) (Tricrom Goldner, ob 4X);
b) Conjunctive capsule between the mandibular gland (A) and the sublingual gland (B) (Tricrom Goldner ob. 16X);
c) Conjunctive capsule between the sublingual gland (A) and the parotid gland (B) (Tricrom Goldner ob. 16X).

particularity which we have not encountered in any other species that we have studied. We consider this to be a morphological particularity of this species, but without any functional implications.

CONCLUSIONS

1. The major salivary glands ale located on the latero-ventral sides of the neck, with the sublingual gland forming a common body with the mandibular gland.
2. In the rat, on each latero-ventro-caudal side of the head, there is a extraorbital lacrimal gland, situated cranio-dorsally to the parotid, at the cranial pole of the parotidian lymph node.
3. The parotid gland covers with its ventral border a third of the mandibular gland, laterally to which the sublingual gland is located.
4. The major salivary glands - parotid, mandibular and sublingual, make up in the rat a glandular complex in which they are so closely placed together that is creates the impression of them sharing one common capsule.
5. From a histological point of view, the separation of the three glands is very clearly made through distinctive conjunctive capsules belonging to each.
6. Structurally, the parotid gland is a serous type, the sublingual is mucous and the mandibular gland presents a particular heterocrine type.
7. The major salivary glands - parotid, mandibular, and sublingual, form in the rat, a glandular complex in which they are so closely placed together that they generate the impression of a common capsule.
8. This aspect represents a morphological particularity which we have not encountered in any of the species studied by us, but it does not seem to have important functional implications.
9. The morphology and topography of the major salivary glands was not influenced by the gender of the subjects.

REFERENCES

1. COŢOFAN, V., PALICICA, R., GANŢĂ, C., HRIŢCU, V., ENCIU, V., 2007 - *The Anatomy of the domestic animals,* vol. II. Editura ”Orizonturi universitare”, Timişoara.
2. MICL□UŞ, V., 2001 – *Special histology*, Ed. Risoprint, Cluj-Napoca.
3. KRINKE, G. J., 2000 - *The Laboratry Rat (Handbook of Experimental Animals)*, Ed.AcademicPress
4. PARHON, C. I., BABEŞ, A., PETREA, I.**,** 1957 - *Endocrinologia Gandelor Salivare*, Ed. A.R.P.R..
5. POPOVICI, I., DAMIAN, A., POPOVICI, N., CHIRILEAN, IOANA, 2003, *Tratat de anatomie comparată: Splanhnologie*, Ed. AcademicPres, Cluj-Napoca.
6. SHARP, P.E., LA REGINA, MARIE C., 1998, *The laboratory rat*, Ed. CRC Press LLC.

EYE FUNDUS VASCULAR PATTERN IN SOME DOMESTIC ANIMALS

Alina DONISA, A.MUSTE, I.PAPUC , F.BETEG, M.MUSTE
University of Angricultural Sciences and Veterinary Medicine
Calea Mănăştur 3-5 Cluj-Napoca,
donisaalina@yahoo.com

ABSTRACT

The aim was to examine, identify and photograph the vasculature (vascular pattern) fundus in some domestic animals. For this purpose we used subjects from canine species (n=87), feline (n=62), horse (n=23) and bovine (n=68) by different breed, age and both genders. The animals were from the surgery clinic of the Faculty of Veterinary Medicine in Cluj Napoca from veterinary clinics and private farms. All subjects underwent indirect ophthalmoscopic examination, performed with indirect ophthalmoscope Heine Omega 2C and study duration was 2.5 years (2007-2010). Results showed that the vascular pattern of fundus species differs in terms of number of vessels, placement (location) and their appearance (design) overall.

Key words: animal retina vessels, dog retina, horse ophthalmology.

INTRODUCTION

Fundus vasculature in animals is little known in the literature Gelatt (2001) mentions the types of the retina in animal series: dog, cat and cattle have a holangiotic retina -type were the retinal vasculature is represented by the central arteries and cilioretiniene and the horse have a paurangiotic retina – represented by the coriocapilare. In dogs and cat fundus vasculature is very similar, almost identical (Sheila Crispin 2005), while the horse is described only limited vascular area around your hard optical (Samuelson DA. 1999) and bovine retinal vessels are highly developed (Sheila.Crispin 2008).

MATERIAL AND METHOD

In this study the material was composed of a total of 240 animals from different species: canine, n=87, representing 36.25%, feline,n=62, representing 25.83% equine, n=23, representing 9.58% and bovine, n=68 representing 28.33% , all subjects were by different breed, age and both genders and came for consultations at the surgical clinic of Faculty of Veterinary Medicine in Cluj Napoca, veterinary clinics and private farms.) .In this study we have chosen only clinically healthy animals.The animals were from the surgery clinic of the Faculty of Veterinary Medicine in Cluj Napoca from veterinary clinics and private farms.
Indirect ophthalmoscopy technique. The principle of the method is similar to all species, the only difference is the animal position for examination , the dogs and cats were set on the table or in the assistant arms .The large animals, cows and horses , were restayning on the surgery table or have been examined standing up. About tranquilization, we use very rarely drugs and in small doses. The examination position must be comfortable for the animal and examiner too. To every patient we administrated tropicamide 1% for pupil dilatation with 10.-20 minutes before the examination. To do ophthalmoscopy examination, all the patients have

been taken in a especially dark room, used in that purpose. The next step is the ophthalmoscopy technique, where the examiner take the lent with one hand and put her between light source and animal, at the same distances as we are talking before. Then with easy movements nearly and beyond, he, will show the tapetal reflex of the posterior pole, than very carefully , with ought losing tapetal reflex , he will move the lent until will obtain a generally view of eye fundus (retina, optic disc, choroids). The imagine obtained can be generally or can fallow in particularly different aspects as vascular aspect, optic disk aspect or retinal endothelium aspect.

RESULTS AND DISCUSSIONS

After ophthalmoscopic examination we noticed species differences in the retinal vascular pattern. In each obtained image we sought to identify blood vessels, their path and branches or collaterals.

Dog's retinal vessels

The largest vessels are the primary veins, 2-5 in number, many dogs have 3-4 primary veins.The arteries form an arch in the center of the optic disc (fig. 1).

Often, the arch spring seems to pulse, but the pulse is not correlated with heart rate ,it is caused by the side of increased vascular pressure on eyeball movement in orbit.

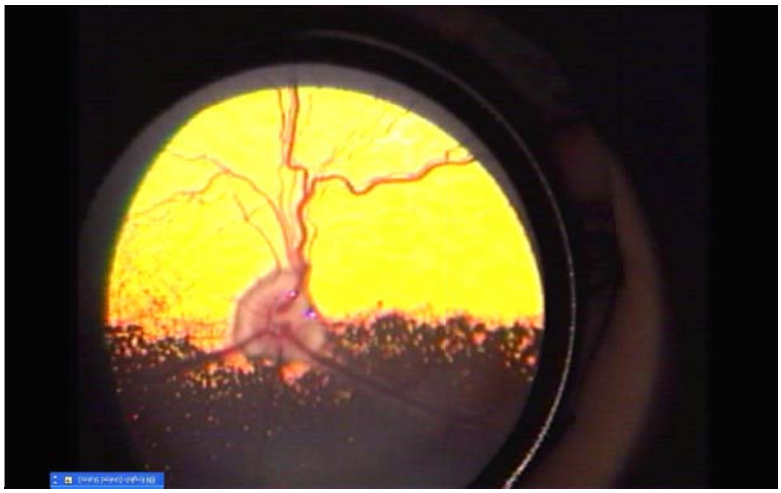

Fig.1.Normal dog eye fundus .

The secondary veins are the same size as the arteries but can be distinguished by their origin are arcului.The arteries are in number to 20 but normally are 10 to 12, are small and originate from the tip of optic nerve, we didn't find any pairs of veins as in other species.

Rowing towards the periphery of fundus the blood vessels are becoming thinner, so in some areas is observed only short branches without identifying a specific origin.

Vascular path is different so in the non tapetal portion the retinal vessels have a linear course while in the retinal vessels are tortuous wallpaper.

Cat's retinal vessels

The vascular pattern is usually composed of three retinal veins, which meet at the tip of the optic disc and from there through the entire fundus (fig. 2). In addition there are a number of small arteries chorioretinal which follows the same pattern except that size is more reduced. The veins and arteries emerge from the edge of the optic disc, this trajectory course is characteristic of this species .Following the course, the arteries are accompanied by the veins and are doubled, the difference between them making it easier on vessel size and color.

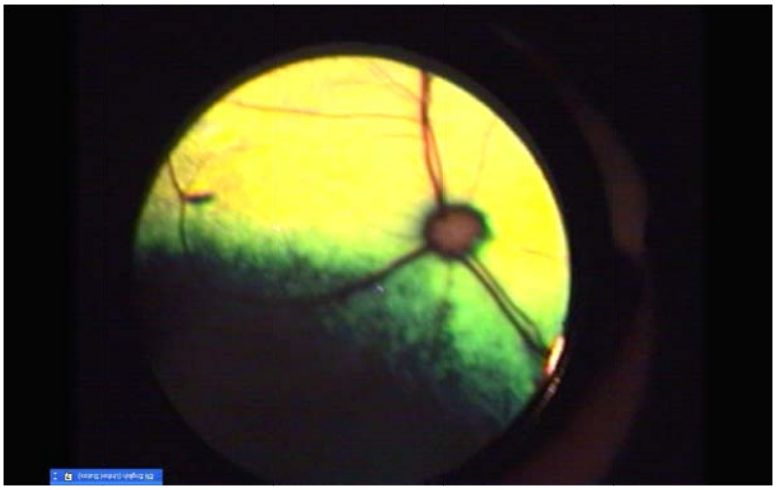

Fig.2.Cat normal eye fundus

Equine retinal vessels

The horse has a paurangiotic fundus (Gelatt 2001), in which blood vessels are located near to the optic disk .In our study we failed to put in evidence the retinal vessel with independently branches and with a well know trajectory .In this case we turned to study some angiography from veterinary ophthalmology literature with which we pursued to compare the obtained pictures from indirect ophthalmoscopy.

. Around the optic nerve head we managed to put out some retinal vessels, although they are very thin. Although in horses, the angiography had revealed nearly 50 blood vessels radiating from a 15 mm horizontally and 10 mm vertically of the optic disk at the ophthalmoscope examination, we failed to identify them (fig. 3).

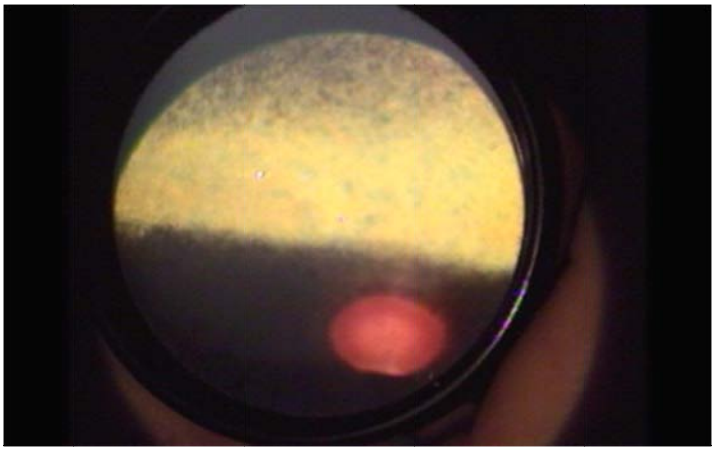

Fig.3.Normal eye fundus in horses

Bovine retinal vessels

In bovines, the retinal vessels identifications was easily and record three major veins and three or more arterioles, the veins and arterioles often turned to each other. (Fig.4.) Again, the vascularization starts at the optic disk; major veins are large size, becoming thin to periphery. We observe that from each major vessel after a sinuous trajectory start small and thin vessels like tree branches witch gradually narrows.

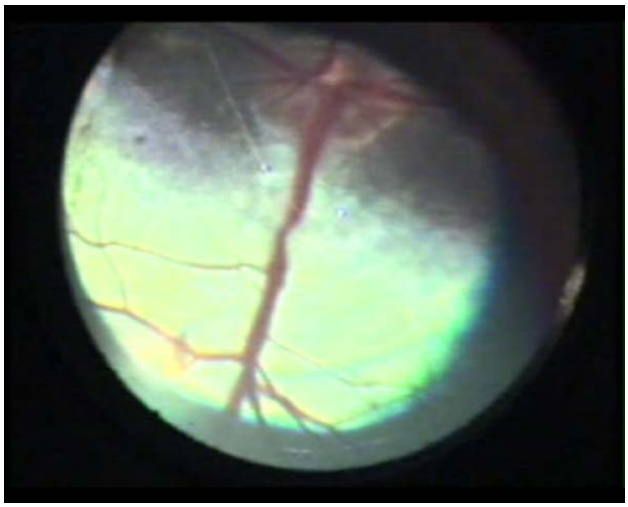

Fig.4.Normal eye fundus in bovine

The fundus periphery is supplied by small retinal vessels from major vessels. In bovine we can see very easy the differences between vein and artery, sometimes are close to each other looking like netting tissue.

CONCLUSIONS:

1 .The vascular pattern of the fundus is different from species to species, in some cases we can see the major vessels, theirs branches and we can fallow the trajectory, in other cases we can see only small or thin vessels with ought a trajectory.
2. In dogs, cats and bovines, we can see the entire vascular pattern, we can count all blood vessels and make differences between major and minor vessels and between vain and artery.
3.The dog have 2-5 major vessels who starts from the central zone of the optic disk, the cat have 3 major vessels who starts from the edge of the optic disk and the bovine have 3-4 major vessels starting from the central zone of the optic disc.
4.The blood vessels trajectory in all 3 species(dogs, cats, and bovines) is sinuous and distinguish from other tissues.
5.The horse retinal vessels pattern is not visible at the ophthalmoscopy, we sow only 2-3 small and thin vessels, near the optic disk edge.

BIBLIOGRAPHY:

1.Daniel M. Albert, Kerry L. Ketring, Richard R. Dubielzig, Gillian J. Mclellan Veterinary Ocular Pathology: A Comparative Review,Saunders 2010.
2.K. C. Barnett, Sheila M. Crispin Equine ophthalmology: an atlas and text , Elsevier 2004 ,
3.Kirk N. Gelatt (Editor) ,Essentials of Veterinary Ophthalmology, 2nd Edition,Black Well Publishing,2008.
4.Samuelson D.A.et all.Ophthalmic anatomy ,Lippincon,Williams and Wilks,Philadelphia 1999.
5. Sheila M. Crispin Notes on Veterinary Ophthalmology,john Willi and Sons,2008.
5.Roger William Blowey, Anthony David Weaver Color atlas of diseases and disorders of cattle, Mosby,2003.

MORPHOLOGYCAL ASPECTS OF THE EYE FUNDUS IN DOMESTIC RABBIT(*ORYCTOLAGUS CUNICULUS DOMESTICUS)*

Alina DONISA, A.MUSTE, F.BETEG, A.KRUPACi, M.MUSTE
University of Angricultural Sciences and Veterinary Medicine
Calea Mănăştur 3-5 Cluj-Napoca,
donisaalina@yahoo.com

SUMMARY

The study purpose is to identify the morphological aspects of the domestic rabbit eye fundus. A total of 28 rabbits of both genders, with age between 6 months and 1year were examined through indirect ophthalmoscopy technique with indirect ophthalmoscope Heine Omega 2C. The examinations were made at the Surgery Clinic of Veterinary Medicine Faculty from Cluj Napoca and in private farms. All rabbits were clinically healthy. The study was made on a period of one year 2009-2010.We also make dissections on 10 rabbit ocular globe and observe the components at the stereo magnifier Olympus SZX16.
The images obtained with the video ophthalmoscope was representative for this species, we found a lack of tapetum lucidum, red eye fundus, a characteristic shape of the optic disk and wings fibers.

Key words: rabbit fundus, animal retina.

INTRODUCTION:

The rabbit became an interest for humans because for many years the rabbit was the experimental model for human medicine in all kinds of experiments and in veterinary medicine one of the earliest documents about rabbit retina dating from 1969 when A.N.Bekchanov writing about the rabbit histological retina.
The rabbit retina is merangiotic meaning is partially vascularised (Sheila.M.Crispin 2005) the blood vessels were found only in a one side of the optic disk (K.N.Gelatt, 2001) the rabbit has a long horizontal visual streak, giving it good vision all along the horizon so its blood vessels are away from the line of high photoreceptor density (David.L.Williams.2005) and the fundus color is depending by the coat color (David.L.Williams.2005).The fundus color can be red or grey and is influenced by the lack of the tapetum lucidum and the quantity of the retinal pigment(Pfeiffer 2006).

MATERIALS AND METHOD

Our observation were made between 2009 - 2010 at the Surgery Pathology Clinic from FMV Cluj, and in private farms on a total of 28 rabbits by both genders and with age between 6 months and 1 year. We examined animals without ought macroscopic modification of the eye being clinically healthy. The breeds taken were Belgian Hare(10 subjects), Chinchilla(8 subjects), Big White(10 subjects).
The examination on the ocular globe with Sterio magnifier Olympus SZX16 was made in 20 minutes after harvest. For the examination we used indirect ophthalmoscopy method with indirect ophthalmoscope Heine Omega 2C The principle of this method is the examination of

animal ocular globe, an examination made with indirect ophthalmoscope (with light source and video camera incorporated) and with a lent between examiner (ophthalmoscope) and patient.The lent is not incorporated in ophthalmoscope so, in the time of examination she must be hold with a hand by the examiner. The lent dioptrically power is 20 D and we can obtain 4-5x magnification field of view. This lent must be settle at 4-5 cm from the patient eye and at 0,5 -.0,75 m from the examiner (this in an advantage for the examiner because he keep distances from the animal). The obtained imagine by indirect ophthalmoscopy is real and upside down. In the present study, all patients have been exanimate with ought tranquilization, the contention was mad in a good and comfortable position for the animal and examiner too. To every patient we administrated tropicamide 1% for pupil dilatation with 15-20 minutes before the examination. To do ophthalmoscopy examination, all the patients have been taken in a especially dark room, used in that purpose. The next step is the ophthalmoscopy technique, where the examiner take the lent with one hand and put her between light source and animal, at the same distances as we are talking before. Then with easy movements nearly and beyond, he, will show the tapetal reflex of the posterior pole, than very carefully , with ought losing tapetal reflex , he will move the lent until will obtain a generally view of eye fundus (retina, optic disc, choroids). The obtained imagine can be generally or can fallow in particularly different aspects as vascular aspect, optic disk aspect or retinal endothelium aspect.

RESULTS AND DISCUSSIONS

After the ophthalmoscope examination of all 28 rabbits we didn't see any age differences, the young rabbit has the same fundus characteristics as the adult rabbit.
In the domestic rabbit the tapetum lucidum is missing and the fundus color is the the blood vessels color, meaning red (fig.1,2,3,4).If the tapetum is missing the most important eye fundus elements remain the optic disk and blood vessels.
At the stereo magnification exam we saw a ventral nasal orientation of the optic disk with lack of tapetum lucidum. The domestic rabbits don't have tapetum lucidum.The examination was done in 1-2 hours after harvest and we observe a detach retina and a shiny choroidal tissue. The optic disk is oval and grey white in color with small vessels under his surface. If we look closer we can see thinly vessels branches(fig.1).

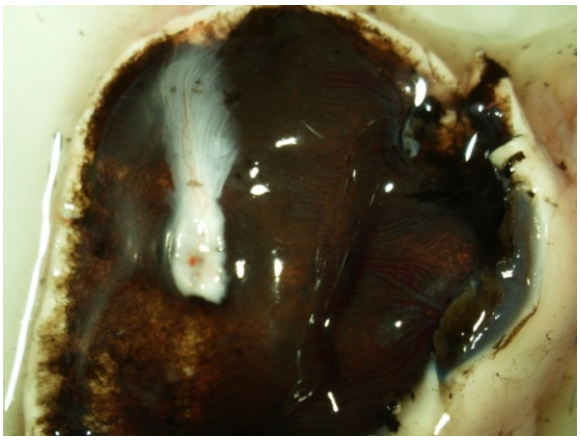

Fig.1.Posterior eye pole in domestic rabbit. See
the choroidal tissue, white optic disk and the retina detatch .

At the ophthalmoscopic exam we saw a strong red color of the fundus, this is non pigmented eye and the color is given by the choroidal tissue and blood vessels (fig.2, 3, 4).The fundus color in not uniform, in some cases we can distinguish longitudinal areas dark brown in color in the optic disk area and at the periphery.

The Optic disk is round or oval situated in the dorsal quadrant is pink red an in center we can see very well the physiological cup. From the edge of the optic disk we can see blood vessels, very thinly, going to the periphery in a straight horizontal line (fig.3)

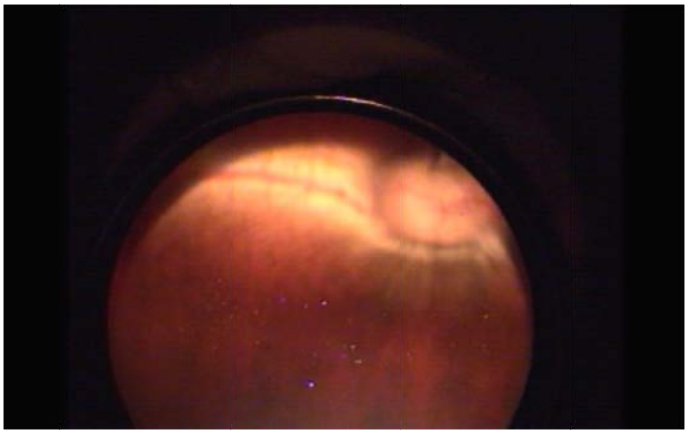

Fig 2.Normal rabbit eye fundus.Round optic disk.

An important and characteristic element in this species is the presence of the medullary wings, an obviously elongation of the nervous fibers along the optic disk diameter, horizontally oriented. The wings are straight without wrinkles (fig.3).

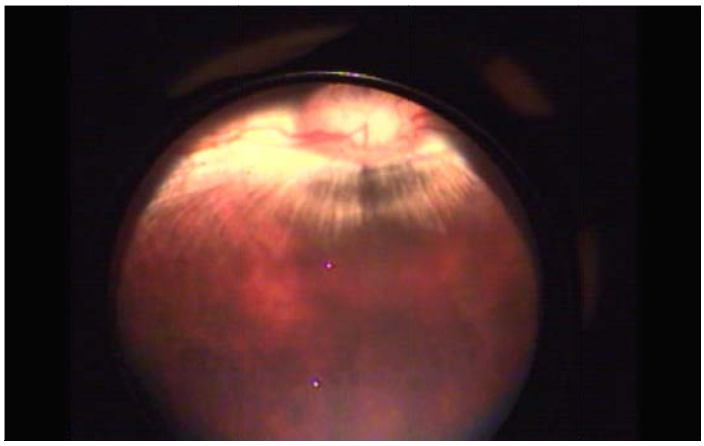

Fig.3.Normal rabbit eye fundus, oval optic disk, and retinal vessels dark brown fundus areas and medullary wings.

All 28 subjects had a similar eye fundus although the age breed and sex were different, we didn't sow tapetum lucidum in any cases .All rabbits had red color of the fundus although no one was albinotic type.

CONCLUSIONS:

1. The domestic rabbit don't have tapetum lucidum , this feature is seen at the stereo magnifier lamp and at the ophthalmoscopic exam .
2. Although all subjects were from different breed age and sex, we didn't find any differences depending by those elements; the eye fundus was the same in all cases.
3. The rabbit retina is merangiotic , optic disk is red pink, round or oval, with a pronounced physiological cup and is situated in the superior quadrant.
4. A very important species characteristic is the presence of the medullary wing that no species bothers .

BIBLIOGRAPHY:

1. Williams L.David.2005.Rabbit eye disorders.Journal of Veterinary Ophthalmology.
2. Sheila M.Crispin, Notes on Veterinary Ophthalmology ,2005,Willy Blackwell.
3. Kirk N. Gelatt. Color atlas of veterinary ophthalmology 2001.Lippincott Williams & Wilkins
4. Kirk N. Gelatt Veterinary Ophthalmology.2007.Lippincott Williams & Wilkins,

MEDICINES FOR BEES- CURRENT SITUATION AND FUTURE ASPECTS, AN IMPORTANT SUBJECT DEBATED AT EUROPEAN LEVEL

Alina Karina DRAGHICI , Anca BITOIU, Lollita TABAN

Institute for Control of Biological Products And Veterinary Medicines.
ROMANIA, Bucharest, 39 Dudului Street, Sector 6, 060603,

ABSTRACT

In order to analise the current situation and future aspects concerning the bee health and treatment options, the European beekeepers, medicines Agencyes from countrys from Europa and veterinary medicines manifacturers organised many meetings. One of these meeting (Workshop on medicines for bees- What the Agency can do to increase availability) took place in December 2009, to EMA (European Medicines Agency) from London, UK. The group's task was to provide an analysis of current situation, identify the critical diseases in the beekeeping sector, the available options for treatment and conclude whether the options for treatment available are sufficient.

MATHERIAL AND METHOD

The Romanian beekeepers are very interested about the availability of medicines for bees in Europe, in particular what medicines are needed and what can be done to increase the availability of the medicines. Unfortunaly the current perception of many beekeepers would be that any treatment that helps to fight diseases is allowed. However, the safety profile of the medicines, ensuring safety of the user, consumer safety, effectiveness and low side affects to the bees should be the choice. In order to analise the current situation and future aspects concerning the bee health and treatment options, the European beekeepers organised many meetings. In order to analise the current situation and future aspects concerning the bee health and treatment options, the European beekeepers , medicines Agencyes from countrys from Europa and veterinary medicines manifacturers organised many meetings. One of these meeting (Workshop on medicines for bees- What the Agency can do to increase availability) took place in December 2009, to EMA (European Medicines Agency) from London, UK. The group's task was to provide an analysis of current situation, identify the critical diseases in the beekeeping sector, the available options for treatment and conclude whether the options for treatment available are sufficient. If insufficient, possible reasons for lack of treatment options should be identified. In a second step proposals for possible solutions and actions should be developed, and where possible the medicines that are needed to treat bee diseases be identified and proposals for essential substances made.
The participants presented and analised the specific situations regarding certain bee deseases, treatment optinons and there results.
As critical diseases at the Europen level the following were identified:

- Varroasis (*Varroa destructor*)
- Nosemosis (*Nosema apis Nosema ceranae)*
- American foulbrood (*Paenibacillus larvae)*
- European foulbrood (*Melissococcus plutonius)*
- Bee virus

New diseases which are expected to be diagnosed in the future:

- *Tropilaelaps mite*
- Small hive beetle

There were also disscusion concerning the available options for treatment at the European level for each diseases:

Nosemosis (*Nosema apis and Nosema ceranae*)

Nosemosis is a problem, in particular in southern Europe. No authorised medicines were available and other control measures were applied as well as anti-coccidial medicines under off-label use. These anti-coccidia, which seem to be effective, should be further explored as future bee medicines. Still, options for treatment are needed.

American foulbrood

For the American Foulbrood no authorised medicines are available, some antibiotics show efficacy against the bacteria in the larvae, however not against the spores, these can only be destroyed by eradication (e.g. burning). Athough, treatment is wanted by the beekeepers – destruction of infected colonies, shook swarm method.

Varroa

Varroa infestation remains the currently most important disease in bees, not only with regard to causing varrosis but also by introducing viral diseases. While several veterinary medicines were authorised, there is concern for the future due to observed resistance against synthetic anti infectious medicines, and the uncertainty of effectiveness of natural anti infectious substances. That's why, new ways of treatment and new medicines are needed to treat vorrosis. Potential future treatment options include genetic therapy or prophylactic vaccination.

European foulbrood

No consensus view could be reached on the approach for treatment. In general it is agreed considered that prophylaxis is the key. Many considered that antibiotics were not the solution for the treatment of the European Foulbrood, however this view is not share by all the beekeepers.

Tropilaelaps

Treatment options available are considered sufficient at present: the use of treatment as for varroa is recommended for now.

Small hive beetle

Veterinary medicines are available based on coumaphos which is an adequate treatment for now. More treatment options are needed in long term, particularly for southern countries

Bee viruses

Essentially linked to the control of varroa. No need for specific medicines.

In order to improuve the current situation of the bee health it is important to identify possible reasons for lack of treatment options. The most important reasons of the failure of the beekeepers in treatment of bee diseses are:

- Resistance problems with existing products

- Efficacy problems
- Incorrect treatment
- Lack of harmonised treatment strategy
- Availability of medicines
- Insufficient knowledge of beekeepers
- High costs of veterinary medicines (vs bulk chemical/homemade product)

DISCUTIONS:

The participants considered that an overall strategy has to come first to decide case by case whether medication should be used, in which conditions e.g. as last resort. Furthermore, they considered that:

- Products should be authorised as veterinary medicines to ensure that they are adequately formulated to the intended use.
- Easier registration of medicines of substances with MRLs, especially for the ones that do not require an MRL value (former Annex II substances) – Harmonisation in approach between Member States was considered essential.
- Optimising the use of the substances already available with more flexibility for changing formulation and conditions of use e.g. organic acids
- Further research is needed for development of new/alternative treatments
- Better instructions for appropriate use of the products
- Creation of a group of experts to propose a strategy for treatment
- Control programmes are needed that include good beekeeping practice and medicines

BIBLIOGRAPHY:

EMA/28057/2010

ANTIHELMINTICS RESISTANCE IN CATTLE- A NATIONAL AND EUROPEAN PROBLEM

Alina Karina DRAGHICI,[1] I. DUCA,[2] Mirela PREDA,[3] D. PREDA[3]
[1] Institute for Control of Biological Products And Veterinary Medicines.
ROMANIA, Bucharest, 39 Dudului Street, Sector 6, 060603,
e-mail: icbmv@icbmv.ro
[2]Faculty of Veterinary Medicine . ROMANIA, Bucharest, Splaiul Independentei Street.
[3]Privat veterinary asistance. ROMANIA, Prahova, Filipestii de Targ, Cuza Voda Street

ABSTRACT

Helminthes resistant to the application of antihilmintics have been an issue since the first use of these products in ruminants (sheep, goats and cattle) and horses.
There are many factors that contribute to the selection of resistant helminthes, but currently, the most widely accepted ones are the too frequent and repeated use of antihelmintics from the same class over
an extended period of time as well as under dosing (which may occur following incorrect administration, underestimation of bodyweight, etc.)
Unfortunately, Romania does not have a statistics concerning the antihelmintics resistance in ruminants. Considering the results of this study, we can suspect that Cooperia spp isolated both from cattle from Teleorman County and Prahova County may be resistant to Albendazole. These phenomena should be further reinvestigated, in order to minimize the risk of development of resistance in cattle.

INSTRUMENTS AND METHOD

Helminthes resistant to the application of antihelmintics have been an issue since the first use of these products in ruminants (sheep, goats and cattle) and horses. The recognition of the existence or possible development of resistance to antihelmintics must be considered in the use of any of these products in these target animal species. Resistance to antihelmintics is an increasing problem in sheep, goats and horses worldwide and is an emerging problem in cattle. Given that development of new antihelmintics with a novel mode of action in the near future is unlikely to occur, maintaining the efficacy of established anthelmintics appears as a priority. There are many factors that contribute to the selection of resistant helminthes, but currently, the most widely accepted ones are the too frequent and repeated use of antihelmintics from the same class over an extended period of time as well as under dosing (which may occur following incorrect administration, underestimation of bodyweight, etc.). These actions are risk factors because the development of resistant organisms within a population relies on the selection for individual parasites that possesses genes that confer survival fitness. These genes may or may not be rare when use of an antihelmintic starts, but the frequency may increase based on the amount of pressure placed on the population by use of antihelmintics. Unfortunately, when resistance appears to one antihelmintic in a class, other antihelmintics in the same class (sharing the same mode of action) will generally also be affected. Resistance is reported mainly in gastrointestinal nematodes (*e.g. Teladorsagia circumcincta* and *Haemonchus contortus* in sheep and goats, Cyathostominae in horses and *Cooperia spp*. in cattle) and, to a lesser extent, in liver fluke (*Fasciola hepatica*) in sheep. In

Europe, scientific reports indicate an increase of helminthes resistance, to different extents, to all three major classes of antihelmintics (benzimidazoles, acetylcholine receptor agonists [imidazothiazoles/tetrahydropyrimidines] and macrocyclic lactones [avermectins/milbemycins). Unfortunately, when resistance appears to one antihelmintic in a class, other antihelmintics in the same class (sharing the same mode of action) will generally also be affected. Unfortunately, Romania does not have a statistics concerning the antihelmintics resistance in ruminants. In this work paper we've tried to figure out, on a small scale, what is the situation of efficacy in cattle of 2 active substances from 2 different antihelmintic classes: albendazole and ivermectine. The experiments were conducted in two groups of cattle rised in the individaul groth system in two different counties, from two different regions of the country. First the cattle were examinated by coproparasitical method (Willis method, Mc Master) in order to identify the gastrointestinal species of nemathodes and the intensity of the infestation. After, there were selected cattles infested with Cooperia, wich were not treated before with any antihelmintic medicines for at least 30 days. The first group of 20 animals were sellected from Scrioastea village, Teleorman county and the second group of 10 cattles were from Filipestii de Targ village, Prahova county. The experiments took place from October until November 2009. In the experiment, part of the cattles from each group were treated with a medicinal product containing Albendazole, and the other part of animals were treated with a medicinal product containing Ivermectine. The pharmaceutical form of the medicinal product containing Albendazole was oral bolus. The second product containing Ivermectine was an injectable product. We respected the indicated posology from the package leaflet: Albendazole 10 mg/kg , respectively Ivermectine 1ml/50 kg.

RESULTS AND DISCUSSION

The efficacy of the active substances was calculated by using Faecal Egg Count Reduction Test . Decrease of the Cooperia eggs under 95% may indicate that the parasite is resistant to the active substance of the medicinal product.

Teleorman county:

No.	Sex	Age (month)	Weight (kg)	Active substance	Results of Faecal Egg Count Reduction Test
1	F	33	420	Ivermectine	99%
2	F	44	500	Ivermectine	96%
3	F	55	570	Ivermectine	97%
4	F	66	590	Albendazole	92%
5	F	69	720	Albendazole	93%
6	F	57	460	Albendazole	92%
7	M	17	330	Albendazole	95%
8	M	8	190	Ivermectine	98%
9	F	45	530	Ivermectine	94%
10	F	42	580	Ivermectine	96%
11	M	9	200	Ivermectine	98%
12	F	30	330	Albendazole	94%
13	M	20	400	Albendazole	95%
14	F	67	390	Ivermectine	96%
15	F	57	710	Albendazole	91%

16	M	6	180	Albendazole	96%
17	F	31	465	Albendazole	92%
18	F	32	570	Ivermectine	99%
19	F	43	340	Albendazole	94%
20	F	42	615	Ivermectine	98%

Prahova county

No.	Sex	Age (month)	Weight (kg)	Active substance	Results of Faecal Egg Count Reduction Test
1	F	37	320	Ivermectine	95%
2	F	28	490	Ivermectine	95%
3	F	30	500	Ivermectine	96%
4	M	6	90	Ivermectine	97%
5	F	7	80	Albendazole	94%
6	M	5	150	Albendazole	92%
7	F	54	550	Albendazole	90%
8	F	65	310	Albendazole	94%
9	F	57	325	Albendazole	93%
10	M	43	600	Ivermectine	98%

The efficacy of the treatment with Albendazole in cattle from Scrioastea, Teleorman County was between 91%and 95%. Comparative, the efficacy of the treatment with Ivermectine was between 96 % and 99%. Regarding the efficacy of the two antihelmintic products used in cattle from Prahova County, the results were: under 95% for Albendazole and between 95 and 98% for Ivermectine. Taking into account the results we can suspect that Cooperia spp isolated both from cattle from Teleorman County and Prahova County may be resistant to Albendazole. Instead, Ivermectine is still efficiency in treatment of the gastro intestinal strongilidosis caused by Cooperia spp.

CONCLUSIONS

Although resistance on antihelmintics in cattle is not an investigated problem, there are clear signals of its existence. In order to minimize the risk of development of resistance we have to identify and remove the causes .

BIBLIOGRAPHY

1. Doc. Ref. EMEA/CVMP/EWP/170208/2005 - GUIDELINE ON THE SUMMARY OF PRODUCT CHARACTERISTICS FOR ANTIHELMINTICS

RESEARCH REGARDING THE EFFICIENCY OF ROMFENBENDAZOL 10% SUSPENSION TREATMENT IN SOME HELMINTOSIS IN SHEEP

Elena DRAGOSTIN, C. TUDORAN, C-tin CHIURCIU, I. IACOB
S.C. Romvac Company SA, Sos. Centurii nr 7, Voluntari Ilfov dr_elena_staicu@yahoo.com

ABSTRACT

Some parasitosis such as digestive strongilosis and cestodosis cause major economical loss, because of their slow evolution with less obvious clinical signs, and because they appeared quickly in small flocks and they also have high incidence of morbidity in youth. Parasitosis clinical signs are major digestive disorders witch causes local and general metabolic disorders. That is why internal and external disinfection of animals of economical interest is compulsory from healthy and economical point of view. Because of its wish to support sheep breeders Romvac Company created a wide range of antiparasitic, one of them being Romfenbendazol 10% suspension to witch we will refere in this paper. Romfenbendazol 10% suspension is an antihelmintic oral suspension, its active substance being fenbendazol an endoparasiticid from bensimidazoles group, witch when orally administrated is quickly absorbed spreading in the entire system. The product destroys the digestive and respiratory worms. The aim of this research is to reveal the efficiency of Romfenbendazol 10% suspension in sheep helmintosis from Calarasi County.

MATERIALS AND METHOD

The research took place between June and July 2009, on 82 sheep from Chiselet in Calarasi County. The sheep submitted to this research were of different age. The diagnostic was established based on the group clinical exam and also laboratory exams. Clinical signs on lambs of 1-2 months consist of behavior changes, sadness, major weight loss, and large abdomen and anemia. In adult sheep it could be noticed shape changes of faeces covered with mucus. For coproparasitologic exam they were taken faeces samples witch were examined by microscope using Willis-Hung method or the flotation method. There should be mentioned that on the surface of the faeces appeared white proglotes. Based on this exam witch took into consideration the characteristic elements (eggs) from the faeces it was also established the level of the infestation as: high, medium and low. According to the flotation exam they were identified Moniesia expansa eggs in all sheep and Trichostrongili eggs only in adults. There were also made biochemical blood exams, the parameters taken into consideration being AST, ALT, CK, and GGT. Blood samples were taken as follows: a day before the treatment, two days after the first administration, a day before the second administration, two days after the second administration, and at the end of the treatment. Based on these lab exams and the clinical dates, Romfenbendazol 10% suspension was administrated in dose of 5 mg a. s. / kg body weight, witch is the equivalent of 2.5 ml of suspension / 50 kg body weight.
The treatment it was administrated in two rounds. Between the two administrations and also at the end of the treatment the coproparasitologic exam was repeated. Thus we revealed the therapeutically efficiency of Romfenbendazol 10% suspension.

RESULTS AND DISCUSSIONS

Because the sheep from Chiselet feeds on the same pasture together with other herds witch are not periodically disinfected, another administration with Romfenbendazol 10% suspension was made after 6 weeks from the first one.
Romfenbendazol 10% suspension was administrated because in the previous years Albendazol was used. In order to prevent the growth immunity of parasites to the existing antiparasitic treatment, the antiparasitic drugs should be used in turns.
According to the data in table I we noticed that after the fist administration of Romfenbendazol 10% suspension the efficiency of the treatment was of 78.94% in lambs, with high level of Moniesia expansa infection.
After the fist administration when the coproparasitologic exam was repeated after the first administration, from the 38 lambs only 8 were identified as positive with Muniesia infection.
In table number one they are also found data related to the infection and treatment with Romfenbendazol 10% suspension in adult sheeps, witch were submitted to the research and witch were previously identified as positive on a high level at the coproparasitologic exam, with Muniesia expansa and Trichostrongili.
After the first administration of Romfenbendazol 10% suspension in a doze of 2.5 ml / 50 kg body weight, only 4 sheeps were infected with two of the parasites identified at the initial copro exam.So the efficiency of the treatment of Romfenbendazol 10% suspension proved to be of 90.90 %.

Table no. 1

The efficiency of Romfenbendazol 10% suspension treatment in some helmintosis in sheep

No. anim.	Categ.	Parasites	Infection level	Romfenbendazol 10% suspension doses	Infected animals		Efficiency (%)	
					42 days	84 days	42 days	84 days
38	Lambs	Moniesia expansa	+++	2.5 ml / 50 kg body weight (5 mg a. s. / kg)	8	0	78.94	100
44	Sheep	Moniesia expansa Trychostrongyli	+++ ++	2.5 ml / 50 kg body weight (5 mg a. s. / kg)	4	0	90.90	100

Legend:
++ - Medium Infection
+++ - High Infection

In both groups, lambs and adults after 42 days from the last administration there was not identified any infected animal, so that the therapeutical efficiency Romfenbendazol 10% suspension was of 100% and the flock of sheep was considered to be correctly disinfected.
In table number 2 and in the figure number 1, there is presented the evolution of blood parameters taken into account for this study before, during and the end of the treatment with Romfenbendazol 10% suspension.
According to this table values there can be noticed the growth of the blood parameters above phisiological limits caused by a high level of infection with Moniesia expansa in lambs and sheeps and also because of the medium level of infection with Trichostrongili.

According to the evolution of the biochemical blood parameters it was noticed that after two days of each antihelmintic administration, blood parameters suffered a slight increase compared to the value registrated a day before the treatment.
A day before the second administration with Romfenbendazol 10% suspension the value shows the decrease of product efficiency after a single administration.
Blood biochemical tests were made on Vet Test 8808 IDEXX, in the Romvac Diagnosis Laboratory.
The last biochemical blood analyses show that the four blood parameters reached again the physiological limits confirming 100% efficiency of Romfenbendazol 10% suspension treatment in sheeps and lambs infected with Moniesia expansa and Trichostrongili.
The previous testing revealed the growth of blood parameters above normal physiological limits.

Table no. 2

THE EVOLUTION OF BLOOD PARAMETERS DURING THE TREATMENT WITH ROMFENBENDAZOL 10% SUSPENSION

EVALUATED PARAMETERS	TIME OF THE BIOCHEMICAL DETERMINTATION					PHISIOLOGICAL VALUES
	I	II	III	IV	V	
AST	515	520	260	263	245	**25-513**
ALT	39.2	40	38.12	38.3	25	**20-30**
CK	25	25.7	21.4	21.7	18	**8-20**
GGT 1	35	35.7	31	31.5	28	**SHEEP > 30**
GGT 2	72.2	72.9	67	67.15	40	**LAMB 17-69**

Legend:
I – a day before the treatment
II- two days after the fist dose
III – a day before the second treatment
IV – two days after the second dose
V – at the end of the treatment

CHART WITH THE EVOLUTION OF BLOOD PARAMETERS DURING ROMFENBENDAZOL 10% SUSPENSION TREATMENT

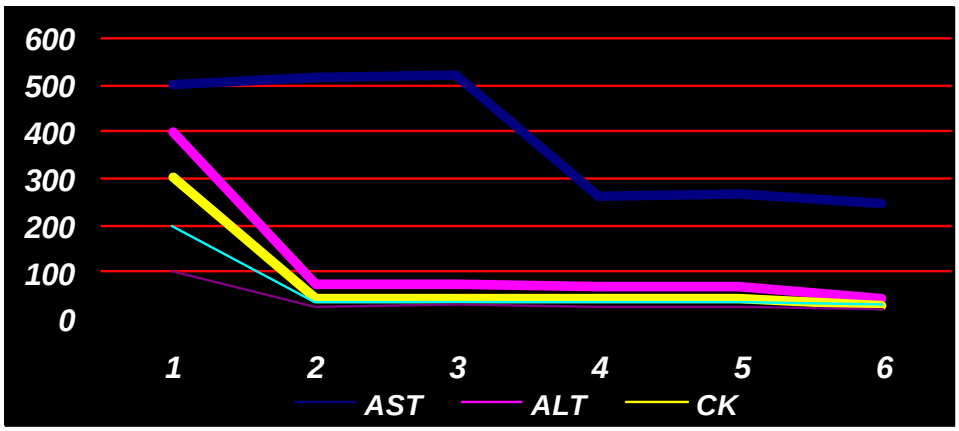

Fig. no. 1

CONCLUSIONS

1. The efficiency of Romfenbendazol 10% suspension treatment in sheeps and lambs diagnosed with high level of infestation with Moniesia expansa and medium level with Trichomonas, was of 78.94 % in lambs and 90.90 % in sheeps after the fist administration and 100% second dose witch allows us to say that the antihelmintic effect of the drug is good and even very good.
2. The values of the biochemical parameters taken into consideration for this research are also indicators of the efficiency of Romfenbendazol 10% suspension, as it was noticed that improvement of their level after the first stage of the treatment, witch was again in the normal physiological parameters at the end of the experiment.
3. In order to prevent the growth immunity of parasites to the existing antiparasitic treatment, the antiparasitic drugs should be used in turns. That is why Romvac Company recommends using also other drugs such as Rombendazol 2.5 % suspension, Rombendazol 10% suspension, Rombendazol Plus, Levamisol injectable solution, Romivermectina injectable solution 1% and Romavermectina B_1 1% injectable solution.
4. Compared to other similar products on the market, the ratio efficiency/cost goes in favor of the Romanian sheep breader with the high recommendation that he should follow exactly the disinfection graphic witch consist of 4 annual administrations.

BIBLIOGRAPHY

1. Hayrettin Akkaya et. al. – “The efficiency of Praziquantel on Moniezia expansa in naturraly infected lambs and the appearance of tapeworms in the feaces after treatment”, Rumitech, The Ruminant Science
2. C.T.BA at. al.- “Diversity and specificity in cestodes of the genus Moniezia: genetic evidence”, International Journal for Parasiotology Vol. 23, No.7
3. Gh.Darabus “Principii generale de control al helmitozelor la ovine”, revista Romana de Medicina Veterinara Vol. 4
4. N.Dulceanu et. al.- “An Encyclopedia of Parasitology”, editura Academiei Romane, Bucuresti 2000
5. Olimpia Iacob, C.Pascal – “Infestarea experimentala a mieilor cu L_3 de nematode intestinale: consecinte asupra calitatii firului de lana”, Scientia Parasitologica, 2002
6. T.Lungu et. al.- “Bolile parazitare ale animalelor domestice”, editura Ceres, Bucuresti 1972
7. I.L.Mitrea et. al.- “Aspecte privind eficacitatea tratamentului cu produse antiparazitare specifice, in unele helmitoze la rumegatoare din zona subcarpatica a judetului Valcea”, Scientia Parasitologica, 2006
8. I.Suteanu “Parazitologie clinica veterinara”, editura Risoprint, Cluj-Napoca, 2004

OBSERVATION REGARDING OVARIAN DISORDES AT DAIRY COWS AND THEIR INFLUENCE ON REPRODUCTIVE FUNCTION

Dana-Simona DRUGOCIU[1], Alin BIRȚOIU[1], Cristina Loredana PANAITE,[2] M. Fl. FOICA [3], Manuela STĂNESCU,[1]

[1] Faculty of Veterinary Medicine Bucharest, 105 Splaiul Independenței, 050097, Bucharest, Romania,
[2] Faculty of Veterinary Medicine Iaşi,
[3]Colegiul Țara Bârsei, Braşov, e-mail: danadrugociu@yahoo.com

ABSTRACT

The investigations have been made on a sample of 420 dairy cows, during 2007 and 2009, out of which we selected the females presenting postpartum ovariopathies.
Ovariopathies are the most common diseases in dairy cows, which lead to sterility, being on the first place in veterinary gynecology.
Within the research made, the most common diseases are the persistent corpus luteum, hypotrophic ovaries and ovarian cysts.

Key words:*dairy cows, ovarian disorders, persistent corpus luteum, ovarian cyst.*

INTRODUCTION

In cattle breeding, the productivity depends on getting a product a year; in the conditions given, special attention must be paid to the prevention and combating of the diseases that determine infecundity and sterility. Ovariopathies are given the highest importance, as the affected ovaries have direct repercussions on the reproductive function, leading even to sterility. In the specialised literature, certain authors pay special attention to ovariopathies, these being a constant factor for producing disorder in the ovaries functioning, late ovulation and even the blocking of the ovulation (Youngquist R., 1997, Schams D., 2004, Hafez, E.S.E. and col. 2007, David E. Noakes, and col. 2009). Bearing in mind these considerations, research is necessary for a better knowledge of the ovariopathy pathology.

MATERIALS AND METHODS

Investigations were made on a sample of 420 dairy cows during 2007 and 2009, out of which we selected the females presenting postpartum ovariopathies. In our research, the diagnosis, incidence and therapeutic orientation were made based on periodic gynecologic exams, gynecologic files and on the correlations with the incidence according to the season, lactation and parameters which can influence the reproductive state.
The gynecologic exam consisted in the transrectal approach of the genital apparatus according to the uterus topography, form and dimensions, to the topography of the ovaries, to the diagnosis of the physiological formations (follicles and corpus luteum), the diagnosis of the pathological formations (persistent corpus luteum, follicular and luteal ovarian cysts, trophic disorders of the ovaries).

The data on these disorders was corroborated with the oestrous cycle phases and with the dynamics of the reproduction parameters. Based on the gynecologic files existent in the farm we established the incidence of the ovary diseases at cows, according to various factors (month, lactation level, milk production).

RESULTS AND DISCUSSIONS

During 2007 and 2009 we met various values of the incidence of the ovary diseases at cows, values which varied according to a monthly dynamics. Analysing the monthly dynamics of the incidence of ovariopathies in Table no. 1, we noticed low values of the incidence, between 10.8% in September and 16.6% in October, and a high incidence in February (44%) and March (42.5%). Within the ovarian disorders, the incidence of the persistent corpus luteum prevailed, with minimum values in September (7.5%) and October (11%), and maximum values in March (28.7%) and February (31%). In the same context, taking into account the females diagnosed with hypotrophic ovaries and ovarian cysts, we noticed that these ovarian disorders had lower incidence values than those of the persistent corpus luteum.

Thus, the incidence of cows with ovarian cysts was minimum in September (2.2%) and maximum in March (7.5%). The increased frequency in ovariopathies at cows in February and March confirms the data found in the specialised literature, regarding the influence of the permanent stabulation, of the conditions regarding the environmental temperature with high values during summer and low values during winter, as well as of the rather unilateral and lacking food during winter and spring, which have a more or less obvious repercussion on the metabolic status of cows, influencing the reproductive function.

Once the exploitation system has changed, the passing to their movement on the field has been done, the increase in daylight starting with May, the feed on green soilage allowed the recovery of the vitamin and mineral balance and the improvement of the reproductive status, which underwent through a slower process in September and October.

Figure nr.1

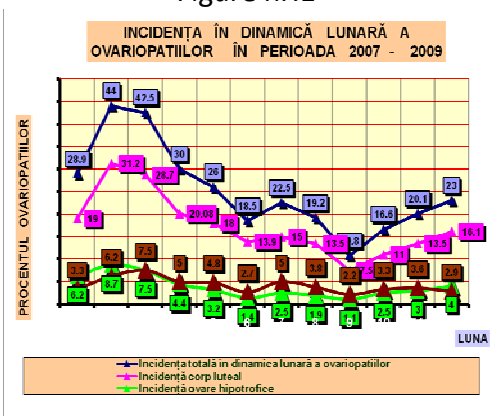

During the analysed period we could notice variations of the incidence of ovariopathies according to the lactation level, the ovariopathies being present in all lactation periods, having a higher level during the first lactation, decreasing progressively until the third lactation, and after that having a progressive increase. Thus, the incidence of the persistent corpus luteum was 22.5% during the first lactation, value which decreased to a minimum during the third lactation (14.2%), after that showing an ascending curve and reaching a maximum after the fifth lactation (24.5%).

The incidence of the cows with hypotrophic ovaries was 9.6 % at the first lactation, reaching a maximum, and after that decreasing until the third lactation (3.6%), following a progressive increase up to 5.8% after the fifth lactation.

The ovarian cysts had a 4.2% incidence at the second lactation, a minimum of 3.7% at the third lactation, followed by an increase which reached a maximum of 5.3% after the fifth lactation.

The maximum incidence of ovariopathies during the first lactation is directly related to the high level of dystocia met at this category, followed by inflammatory diseases of the genital tract, and after the fifth lactation the incidence of ovariopathies increases due to the age, the aged cows being more sensitive to genital disorders, which determine dysfunctions in the secretion and release of the sex hormones at the level of the hypothalamic-hypophyseal-ovarian axis.

The significance of these variations is directly related to the evolution of the progesterone which changes on a season basis, affecting the follicular evolution as well, and after the fifth lactation the endometrium goes through a series of changes and it is not capable any longer of maintaining a normal $PGF_2\alpha$ titer.

The data in the specialised literature signals contrasting situations related to ovariopathies. Some authors (Erb and Martin, 1978 quoted by Faye, B., 1994) talk about a decrease in the incidence of the ovarian pathology as cattle grow old, whereas others (Dohoo şi col., 1984) talk about an increase of these diseases.

Figure nr. 2

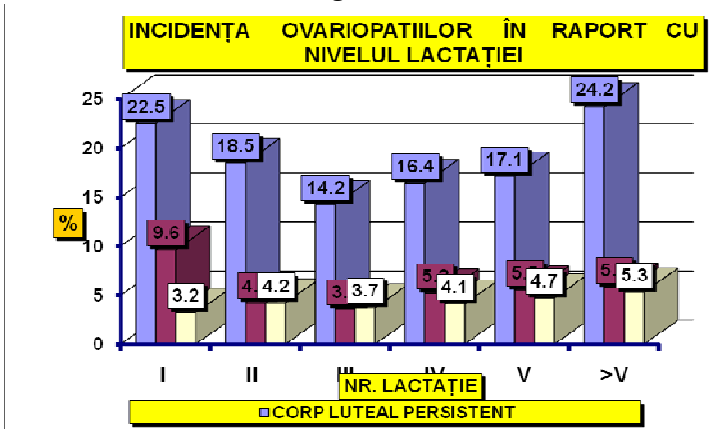

The analysis of the results showed a variation of ovariopathies according to the milk production. Thus, we noticed a minimum incidence in the case of low levels of milk production of 4,000 to 5,000 litres (15.4%) and a maximum incidence in the case of milk production which is above 7,500 litres (50%).

Thus, at a milk production of 4,500 litres, the incidence of ovariopathies increased up to 37.8%. In the case of milk productions of 5,000 to 7,000 litres, the incidence showed variations between 36.8 and 44.7%, and when the milk production increased to 7,500 litres, the incidence of ovariopathies increased to 50%.

Within ovariopathies, the incidence of the persistent corpus luteum prevailed and had the same dynamics, with minimum values (11.55%) at low productions, and maximum values (33.3%) at high levels of the production. Generally, we can notice that the milk production increased by technology represents a stress factor for the animals, a forced situation which competes with the reproductive function, which determines an increased secretion of corticosteroids which produce disorders by receiving a negative hypothalamic-hypophyseal feedback, much to the detriment of the gonadotropic hormones (the manifestation of the oestrum), with a negative effect on the general cycle.

The incidence of cows with hypotrophic ovaries had minimum values (3.8%) at low levels of the production (4,000 to 5,000 litres of milk) and maximum values (6.9%) for high production levels (6,500 to 7,000 litres); the incidence of cows with ovarian cysts increased proportionally with the increase in the level of milk production, from an average value of 3.4% at productions of 5,000 to 5,500 litres of milk, up to an average value of 12.5% in the case of milk production levels above 7,500 litres.

We can notice that cows with high levels of milk production have a faded oestrous behaviour, meaning they are more heat tolerant in most of the cases, being more difficult to detect, thus delaying the first insemination and increasing the period of postpartum anoestrus.

Analysing Figure no. 3, we can clearly notice the tendency towards an increased incidence of ovarian diseases compared to the increase in the milk production, having a dynamics with a minimum average value of 15.3% in the case of milk productions of 4,000 to 4,500 litres/cow and a maximum average value of 50% in the case of productions which exceed 7,500 litres/cow and intermediary average values which vary between 37.3% and 42.8% at productions between 5,000 and 7,000 litres.

The decisive factors of the increased frequency of ovariopathies are incriminated by some authors as having mostly an organisational or managerial nature.

Figure nr. 3

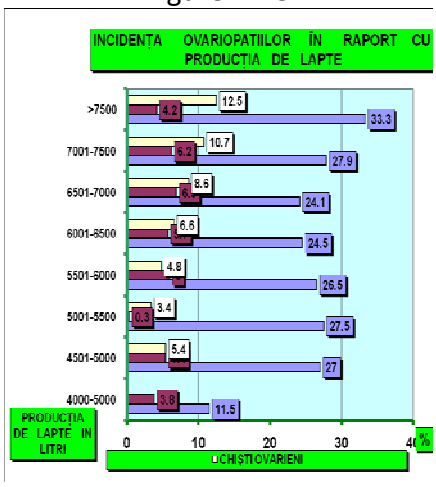

Authors claim that it is likely to obtain a proper fecundity in cows with high levels of milk production by giving this animal category an adequate technical assistance.

From the data regarding the lactation curve (Figure no. 4) we can notice that the cows without ovariopathies have an average milk production of 7,340 litres per cow per lactation, for an average lactation of 305 days, whereas cows with ovariopathies have a milk production of 7,710 litres per cow, at an average lactation of 370 days, obtaining an average production of 24 litres/cow/day at cows without disorders and 21 litres/cow/day at cows with ovariopathies.

During the whole lactation period, cows with ovariopathies have a milk production with approximately 370 litres more, but which has negative consequences on the calving interval which increases to 450 days, as compared to 380 days, the calving interval for cows without ovariopathies.

As we can notice in Figure no. 16, the milk production is lower at cows with ovariopathies, until the 8th month, with approximately 80 litres/month, and during the peak lactation (the 2nd month), with approximately 130 litres/month; starting with the 8th month, cows with ovariopathies have a higher production than the cows without disorders, with an average of 23 litres/cow/month; this situation is owed to the fact that cows without ovariopathies are in an advanced period of their gestation and close to the lactation pause.

From the data presented we can notice that ovariopathies influence the curve representing the milk production, but the most important effects are those related to the extension of the service period and of the calving interval inclusively, a fact with negative repercussions on the following lactations.

Figure nr. 4

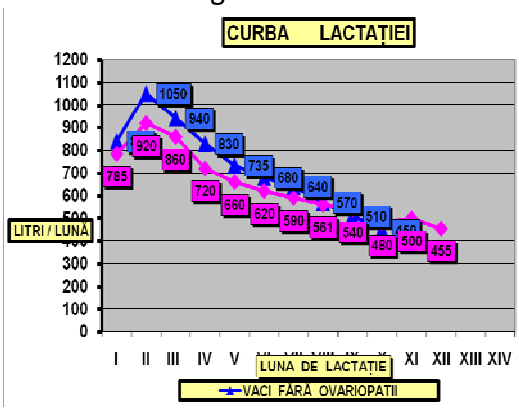

Following the analysis of the incidence of ovariopathies at cows, as related to some subsequent reproduction indexes, we noticed a negative influence of the ovarian disorders on the reproductive function. Thus, at cows with postpartum ovariopathies we could notice an increase in the level of fertile parturition – insemination interval. From the graph analysis we noticed that the postpartum ovarian disorders have a negative influence on the reproduction parameters, increasing the service period. Thus, cows without any postpartum disorder had an average service period of 95 days, as compared to those who had ovarian disorders, whose service period had 165 days.

It is well-known that the physiologic service period has 85 days, whereas, in our case, the service period has 165 days, almost twice the normal value, which determines the interval between parturitions (the calving period) to reach 450 days, making it impossible to have a calf a year.

Generally, is it considered that ovariopathies themselves, without being associated with other disorders, extend the service period; thus, the ovarian cysts structures, although they may be diagnosed at an early stage, lead to a significantly late fecundation ($p<0,005$), a result which gets worse under the influence of other infections of the genital tract.

Among the factors which influence the reproductive function, the exploitation system plays a very important part. Certain authors, studying the effect of the maintenance system and comparing it with raising the cattle in the field, noticed a 20-day decrease in the service period for the latter situation.

CONCLUSIONS

- As a result of the clinical investigations made on a sample of 420 dairy cows, between 2007 and 2009, 123 females were diagnosed with various types of ovariopathies (29% of the whole). The incidence of ovariopathies had variations according to various factors such as the year, light or lactation.
- The monthly dynamics of ovariopathies showed a minimum incidence in September (10.8%) and October (16.6%) and it had maximum values in February (44%) and March (42.5%).

- Considering the level of lactation, we noticed a minimum incidence during the 3rd lactation (21.5%) and maximum during the 1st lactation (35.3%).
- Regarding the milk production, the incidence of ovariopathies increased proportionally with the increase in milk production, which leads us to the conclusion that the endocrine disorders in ovaries are favoured by high levels of milk production, the highly productive females having an increased incidence of ovarian disorders.
- Ovariopathies had negative repercussions on the reproductive indices, as well, the service period increasing to 165 days, almost double comparing to the normal value (85 days).

REFERENCES

1. Arthur G., Noakes D., Pearson H., Parkinson TJ., 1996 - Veterinary reproduction and obstetrics, 7 – th edition, W.B. Saunders Edition Company.
2. Birțoiu, A., 2004 - Tratat de reproducție la animale, Editura All.
3. Birțoiu, A., Seiciu F., 2006- Tratat de patologia reproducției la animale, Ed. a 2-a Editura Bic All, Bucuresti.
4. Drugociu, D., 2005 - Bolile obstetrical ginecologice la animale, Editura Ion Ionescu de la Brad.
5. David E. Noakes, Timothy J. Parkinson, Gary C.W. England, 2009 – Veterinary Reproduction and Obstetrics, Ninth Edition, Saunders Elsevier.
6. Garverick HA, 1997 – Ovarian follicular cysts in dairy cows, Dairy Sci, 80:995-1004.
7. Ginther, O., 1997 – "Selection of the dominant follicle in cattle: Biology of Reproduction". Ref. in: ABA, Vol. 56, No. 3.
8. Hafez, E.S.E., Hafev B., 2007 – Reproduction in farm animals, Lea And Febinger, Philadelphia, USA.
9. Thatcher WW, Bilby TR, Bartolome JA, et al., 2006 - Strategies for improving fertility in the modern dairy cow. Theriogenology, 65: 30-44.
10. Schams D., Berisha B,. 2004 – Regulation of corpus luteum function in cattle –an overview. Reprod. Domest. Anim. 39:241:251.
11. Vanholder T, Opsomer G, de Kruif A., 2006 - Aetiology and pathogenesis of cystic ovarian follicles in dairy cattle: a review. Reprod Nutr Dev, 46: 105-119.
12. Youngquist R., 1997 - Current therapy in large animal Theriogenology.

LEAD ACETATE IMPACT ON FUNDAMENTAL BIOMARKERS OF REPRODUCTIVE FUNCTIONALITY IN FEMALE RATS (*IN UTERO* EXPOSURE)

Eugenia DUMITRESCU, Alexandra TRIF, R. T. CRISTINA,Fl. Muselin,
Banat's University of Agricultural Sciences and Veterinary Medicine, Faculty of Veterinary Medicine, Calea Aradului, 119, 300645 Timisoara, Romania,
e-mail:cris_tinab@yahoo.coml

ABSTRACT
The study carried out on 32 adult Wistar female rats (90 days) exposed only in utero to lead acetate (E_1: 50 ppb Pb, E_2: 100 ppb Pb, E_3: 150 ppb Pb) emphasized: significant increase of sexual cycle duration comparative to control group, over the physiological limits and in direct correlation to exposure level; modification of sexual stages regularity: significant decrease of sexual cycles percentage with proestrus, estrus and diestrus I, diestrus II in physiological limits as duration comparative to control group and inversely correlated with the exposure level; appearance of sexual cycles with absent diestrus I and diestrus II, directly correlated with the exposure level; appearance of sexual cycles with prolonged proestrus, estrus, diestrus I and II, directly, significantly correlated with exposure level.

Key words: lead, rats, sexual cycles

INTRODUCTION

Recent researches are emphasizing more and more obvious the perturbance of the health of the reproductive process, the causes including substances with toxic potential (industrial contaminants, pesticides, organic solvents, etc.) (1, 3, 7, 14). However, the information regarding female reproductive toxicology is less than the one regarding males, due to the gametogenesis differences and the access ability of the germinal cells, and also because of the revolving nature of female breeding function (5, 6).The aim of the study was the evaluation of lead toxic impact on the femele reproductive system integrity, functionality and performances biomarkers. The objectives of the study were evaluation of the reproductive functionality fundamental biomarkers (duration of sexual cycle and sexual cycle regularity) at sexual maturity of female offspring exposed to lead acetate only *in utero*

MATERIAL AND METHODS

The study was carried out on 32 adult female Wistar rats (90 days) exposed to lead acetate *in utero* period as follows: E_1: 50 ppb Pb (the maximum admitted level in drinking water according to the Law 485/2002); E_2: 100 ppb Pb; E_3: 150 ppb Pb. Offspring exposure to lead was stopped from birth until sexual maturity. Control group received tap water not containing lead. The forages and water have been assured *ad libitum*. Duration of sexual cycle and the sexual cycle stages regularity were appreciated by examination of vaginal smear cytological characteristics (stained May-Grunnwald-Giemsa method, examinated by optic microscope. X 20). The results had been processed by ANOVA method and Student test. All assays with animals were conduced in accordance with present laws regarding animal welfare and ethics in animal experiments (9, 10, 11, 12, 13, 15).

RESULTS AND DISSCUSIONS

The results are presented in table 1, 2 and figures 1, 2.

Table 1.

Mean sexual cycle duration (days)

Group	X±Sx	D.S.	C.L. 95%
C	4.95±0.08	0.21	0.22
E1	5.17±0.09	0.25	0.22
E2	5.51±0.09	0.25	0.22
E3	5.97±0.08	0.22	0.22

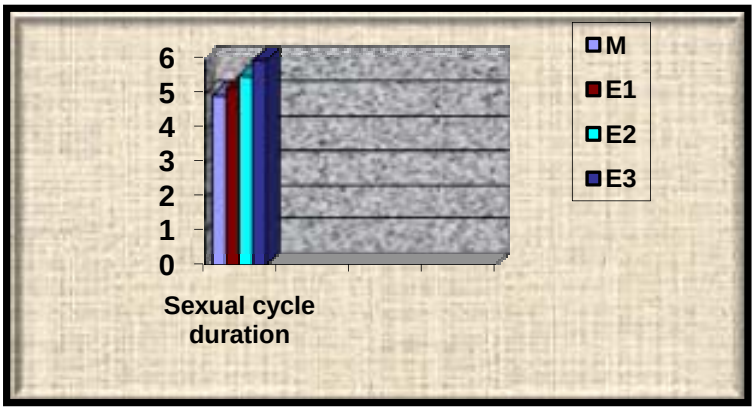

Fig.1. Dynamics of sexual cycle duration (days*)*

In C group, sexual cycle duration was in physiological limits – 4-5 days (2), but in exposed groups. the duration was significantly ($p<0.01$) higher than the physiological limits, directly correlated with the exposure level: E_1/C: +4.44%; E_2/C:+11.31%; E_3/C: +20.60%; E_2/E_1: +6.57%; E_3/E_2: +8.34%; E_3/E_1:+15.47%. In C group all sexual cycle stages ranged in physiological limits as duration. Percentage of proestrus in physiological limits was significantly ($p<0.01$) lower in E groups comparative to C group: E_1/C: -4.03%; E_2/C:-14.57%; E_3/C: -30.76% and inversely. significantly ($p<0.01$) correlated with the exposure level (E_2/E_1: -10.98%; E_3/E_2: -18.94%; E_3/E_1:-27.85%). Exposure to lead determined the appearance of sexual cycles with prolonged proestrus, increasing significantly ($p<0.01$), in direct correlation with the exposure level: E_1/C: +96.75%; E_2/C:+350%; E_3/C: +738.25%; E_2/E_1: +128.71%; E_3/E_2: +86.27%; E_3/E_1:+326.04%.
No sexual cyles with absent proestrus were reported. The percent of sexual cycles with estrus in physiological limits was in E groups significantly ($p<0.01$) lower than in C group. inversely. significantly ($p<0.01$) correlated with the exposure level: E_1/C: -4.5%; E_2/C:-25.14%; E_3/C: -42.57%; E_2/E_1: -21.61%; E_3/E_2: -23.28%; E_3/E_1:-39.86%. The percent of sexual cycles with prolonged estrus was directly significantly ($p<0.01$) correlated with the exposure level: E_2/E_1: +457.42%; E_3/E_2: +69.33%; E_3/E_1:+843.9%. No sexual cycles with absent estrus were reported.

Table 2.

Sexual cycle stages (% of total sexual cycles)

E_1 – 50 ppb Pb

			Sexual cycle stage			
			C	**E_1**	**E_2**	**E_3**
Proestrus	**N**	**X ± Sx**	96.00± 0.63	92.13±0.40	82.00±0.48	66.47±0.65
		S. D.	1.67	1.06	1.26	1.73
		C.L:	0.70	0.70	0.70	0.70
	A	**X ± Sx**	0.00± 0.00	0.00±0.00	0.00±0.00	0.00±0.00
		S. D.	0.00	0.00	0.00	0.00
		C.L:	0.70	0.70	0.70	0.70
	P	**X ± Sx**	4.00± 0.49	7.87±0.01	18.00±0.02	33.53±0.01
		S. D.	1.29	0.02	0.40	0.02
		C.L:	0.70	0.70	0.70	0.70
Estrus	**N**	**X ± Sx**	100± 0.00	95.5±0.41	74.86±1.24	57.43±1.36
		S. D.	0.00	1.09	3.29	3.60
		C.L:	1.09	1.09	1.09	1.09
	A	**X ± Sx**	0.00± 0.00	0.00±0.00	0.00±0.00	0.00±0.00
		S. D.	0.00	0.00	0.00	0.00
		C.L	1.09	1.09	1.09	1.09
	P	**X ± Sx**	0.00± 0.00	4.51±0.08	25.14±0.01	42.57±0.01
		S.D.	0.00	0.22	0.03	0.02
		C.L	1.09	1.09	1.09	1.09
Diestrus I	**N**	**X ± Sx**	100± 0.00	92.75±0.61	70.86±1.93	55.14±0.63
		S.D.	0.00	1.61	5.11	1.68
		C.L:	1.32	1.32	1.32	1.32
	A	**X ± Sx**	0.00± 0.00	0.00±0.00	0.00±0.00	14.14±0.83
		S.D.	0.00	0.00	0.00	2.19
		C.L:	1.32	1.32	1.32	1.32
	P	**X ± Sx**	0.00± 0.00	7.25±0.01	29.28±0.01	30.69±0.05
		S.D.	0.00	0.03	0.02	0.13
		C.L:	1.32	1.32	1.32	1.32
Diestrus II	**N**	**X ± Sx**	97.70± 0.49	84.74±1.38	80.30±0.66	79.92±0.41
		S.D.	1.10	3.09	1.48	0.91
		C.L:	1.03	1.03	1.03	1.03
	A	**X ± Sx**	0.00± 0.00	5.19±0.05	7.70±0.22	8.65±0.27
		S.D.	0.00	0.12	0.48	0.60
		C.L:	1.03	1.03	1.03	1.03
	P	**X ± Sx**	2.30± 0.12	10.14±0.25	12.00±0.35	11.33±0.18
		S.D.	0.27	0.56	0.79	0.41
		C.L:	1.03	1.03	1.03	1.03

E_2 – 100 ppb Pb
E_3 - 150 ppb Pb
N – physiological stage
A – absent stage
P – prolonged stage

NB: 28 supervised sexual cycles /group (7 individuals/group x 4 supervised sexual cycle)

The percent of sexual cycles with diestrus I in physiological limits significantly decreased ($p<0.01$) in exposed groups comparative to C group: E_1/C: - 7.25%; E_2/C:-29.14%; E_3/C: -44.86%, inverselly, significantly ($p<0.01$) correlated with the exposure level: E_2/E_1: -23.8%; E_3/E_2: -22.18%; E_3/E_1:-40.54%. Lead exposure determined the appearance of sexual cycles with absent diestrus I in E_3 groups (E_3/C: 14.14%/0%). The precent of sexual cycles with prolonged diestrus I was significantly ($p<0.01$) higher in lead exposed groups than in C group: E_1/C: 7.25%/0%; E_2/C: 29.28%/0%; E_3/C: 30.69%/0%. directly significantly ($p<0.01$) correlated with exposure level: E_2/E_1: +303.86%; E_3/E_2: +4.81%; E_3/E_1:+323.31%.

The percent of sexual cycles with diestrus II in physiological limits significantly decreased ($p<0.01$) in exposed groups. comparative to C group: E_1/C: - 13.26%; E_2/C:-17.8%; E_3/C: -18.19%. Lead exposure determined the appearance of sexual cycles with absent diestrus II in E groups (E_1/C: 5.19%/0%; E_2/C:7.7%/0%; E_3/C: 8.65%/0%) correlated with exposure level: E_2/E_1: +48.36%; E_3/E_2: +12.33%; E_3/E_1:+66.66%. The precent of sexual cycles with prolonged diestrus II was significantly ($p<0.01$) higher in lead exposed groups than in C group: E_1/C: +333.33%; E_2/C:+412.82%; E_3/C: +384.18% generally directly, significantly ($p<0.01$) correlated with exposure level: E_2/E_1: +18.34%; E_3/E_2: -5.58%; E_3/E_1:+11.73%.

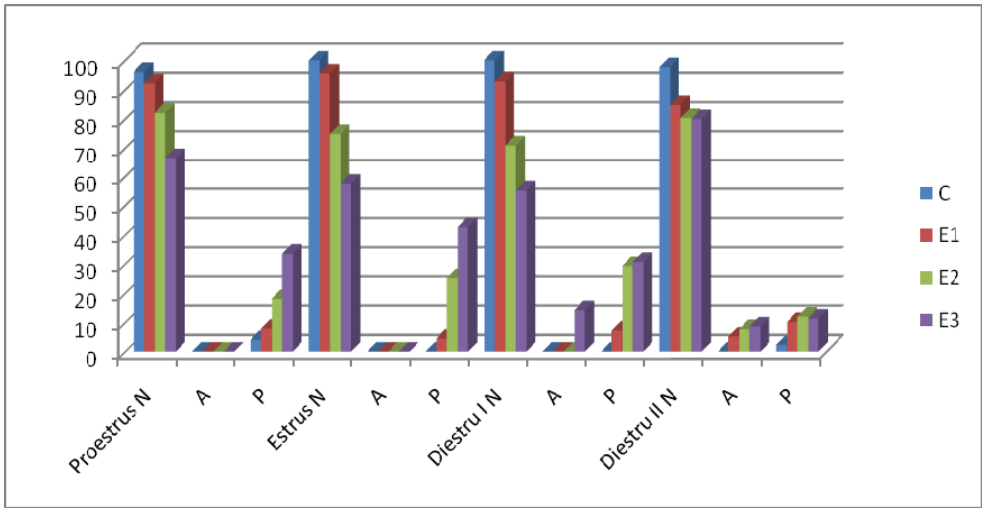

Figure. 2. Sexual cycle stages dynamics

In the studied references there was not found precise information regarding the consequences of lead exposure upon the sexual cycle. In only one bibliographical source, Ronis et al., [8] emphasized that the disturbances are appearing (but reversible) only in the case of high level of exposure.

Exposure to lead acetate *in utero* determined in female rats at sexual maturity:

- Significant increase of sexual cycle duration comparative to control group, over the physiological limits and in direct correlation to exposure level;
- Modification of sexual stages regularity:
- Significant decrease of sexual cycles percentage with proestrus, estrus and diestrus I, diestrus II in physiological limits as duration comparative to control group and inversely correlated with the exposure level;

- Appearance of sexual cycles with absent diestrus I and diestrus II, directly correlated with the exposure level;
- Appearance of sexual cycles with prolonged proestrus, estrus, diestrus I and II, directly, significantly correlated with exposure level.

REFERENCES

1. Gupta C. Ramesh (2007):*Veterinary Toxicology*, Ed. Academic Press U.S.A.
2. Kei-Ichiro Maeda., Satoshi Ohkura., Hiroko Tsukamura (2000): Physiology of Reproduction, Academic Press, JapaN, pp. 145-456.
3. Konnie H. Plumelee (2004) –*Clinical Veterinary Toxicology*, Mosby Inc. All.
4. Pillai A., Gupta S., (2005): *Effect of gestational and lactational exposure to lead and/or cadmium on reproductive performances and hepatic oestradiol metabolizing enzymes,* Toxicol Lett, 15; 155:1; 179-186.
5. Pinon-Lataillade, G., Thoreaux-Manlaz, A., Coffigny, H. (1993) – *Effect of ingestion and inhalation of lead on the reproductive system and fertility of adult male rats and their progeny*. Hum. Exp. Toxicol., 12, 165-172.
6. Pinon-Lataillade, G., Thoreux-Manlay.A., Coffigny. H., Soufir. Jc., (1995): *Reproductive toxicity of chronic lead exposure in male and female mice*; Reproductive Toxicology;14:11: 872-8.
7. Roder J.D. (2001): Veterinary Toxicology, Ed. Buttorworth Heinman.
8. Ronis, M.J., Gandy, J., Badger, T., (1998): *Endocrine mechanisms underlying reproductive toxicity in the developing rat chronically exposed to dietary lead.* Toxicol. Environ Health A. 22; 54:2: 77-99.
9. ***Directiva 86/609 din 24.11.1986 privind protecţia animalelor utilizate în scopuri experimentale şi în alte scopuri ştiinţifice, http://ec.europa.eu/food/fs/aw/aw_legislation/scientific/86-609-eec_en.pdf.
10. ***Legea 205/26.05.2004 privind protecţia animalelor, M. O. nr. 531/14.06.2004.
11. ***Legea 206/27.05.2004 privind buna conduită în cercetarea ştiinţifică, dezvoltarea tehnologică şi inovare, M. O. nr. 505/4.06.2004.
12. ***Legea 471/9.07.2002 privind aprobarea O.G. nr. 37/2002 pentru protecţia animalelor folosite în scopuri ştiinţifice sau în alte scopuri experimentale, M. O. nr. 535/23.07.2002.
13. ***Legea 9/11.01.2008 pentru modificarea şi completarea Legii nr. 205/2004 privind protecţia animalelor, M. O. nr. 29/15.01.2008.
14. ****Lead*, 2003 http://nautilus.fis.uc.pt/st2.5/scenes-e/elem/e08210.html.
15. ***Ordin 143/400 pentru aprobarea instrucţiunilor privind adăpostirea şi îngrijirea animalelor folosite în scopuri ştiinţifice sau în alte scopuri experimentale, M. O. nr. 697/24.09.2002.

INDEX OF PARASITIC IMPACT UPON THE PHYSIOLOGIC INDICES IN BOVINES

D.ERHAN,[1] Ol. CHIHAI,[1] Galina MELNIC,[1] Şt. RUSU,[1]
Maria ZAMORNEA, Nina TĂLĂMBUȚĂ[2], V. BUZA, T. ANGHEL[1]

[1] Institute of Zoology, Academy of Sciences of Moldova
1, Academiei str., Chisinau, MD – 2028, Republic of Moldova
e-mail: dumitruerhan@yahoo.com
[2]Free International University of Moldova

Abstract:
S. papillosus causes an average diminution of the coagulogram (plasmatic hemostasis) indicators with 13,7%, of the proteinogram indicators with 14,9% and the immunogram (limphocitary indicator) with 14,3% while the medium total decrease is 14,3%. The invasion with D. lanceolatum modifies the indicators of the coagulogram (plasmatic haemostasis) with an average of 15,0%, of the proteinogram with 10,8% and the immunogram (lymphocitic indicators) with 19,2%, the medium average decrease being 15,0%. The increase of the ART, TPAT, TT indicators and the tendency of decreasing levels of PI and Ca ions in bovines infested with S. papillosus, compared to the control group is due to the maldigestion and malabsorbptia at the level of the gastrointestinal tract and the persistence of hydrolytic enzymes (hialuronidasis) as inhibitory factors of coagulation, while the increase of the fibrinogen quantity could be explained by processes occurred after the mecanico-irritative activity at the level of the digestive and respiratory system. The tendency of increase of PI and fibrinogen and considerate extension of TT in bovines infested with D. lanceolatum is probably due to cholestasia in the liver and the insufficiency of bile in the intestine since the decrease the capacity of hepathocites to absorb vitamin K is reduced in addition to the persistence of hydrolytic enzymes (hialuronidase) of the parasites.The proteinogram in bovines from the group infested with S. papillosus represents the type I of electroforegram specific for severe inflammatory processes while in bovines infested with D. lanceolatum- the type VIII characteristic for the symptomatic hepatobiliary system.The parasitic antigens inhibit B-, T-, Th-lymphocytes and stimulate Ts-lymphocytes provoking in this way a status of immune deficiency in the host organism which is favorable for their development but reducing at the same time the defensive capacity of the host organism against other infectious agents.Due to the immunologic effect the complex antiparasite chemotherapy proved to diminish the level of B-, T- and Th-lymphocytes and the toxins released after the destroy of the parasitic elements induced the quantitative increasing of null and Ts- lymphocytes.

Key words: Polyparasitism, cuagulogram, proteinogram, immunogram.

INTRODUCTION

The parasite agents directly influence the biochemical reactions of the host which is interesting both from the practical and theoretical point of view since it determines the consequence of their interactions with the host, disturb metabolism, increase the activity of blood serum ferments, modify the indicators of the proteinogram, immunogram, plasmatic

homeostasis. The evaluation of the disease caused by the pathogenic action of migrated larva determines the cellular defense system. The indicators of homeostasis demonstrate the protective reaction of the organism that is manifested by discontinuance of hemorrhages. The maintaining of an optimum physiological functioning of the blood coagulation is essential. The deficiencies in blood coagulation have an impact in its intravascular fluidity. The excessive coagulation can lead to the occlusion of a vital blood vessel while deficient coagulation can cause a hemorrhage that is difficult to stop [2, 3, 5]. In order to take efficient measures in the establishment of the proteinogram, immunogram and plasmatic indicators' homeostasis it is necessary to study the level of disturbances caused by infestation of animals and only then the corresponding measures for normalizing the status could be arranged. The main anomaly resides in incapacity of blood vessels to contract normally. The level of immunitary tension depends greatly on the quality of pathogenic agents' inpouring into the organism, the activity of some generations in the development of helmints, the number of re-infestations and definitely of the physiological state of the macro-organism. The immune status of animals changes in the helmints' ontogenesis process. The migrating forms of larva are more immunogenic due to their higher level of metabolism [1, 4].

MATERIALS AND METHODS

The objective of the investigations performed was to investigate the consequences of the monoparasites invasions on the physiology of bovines aged 2-4 years as of Black-and-White Holland race. In order to achieve the objective, 15 bovines were selected and divided into 3 groups formed by 5 animals: group I – un-infested, group II – infested with *Strongyloides papillosus*, group III – infested with *Dicrocoelium lanceolatum*. There were researched the lymphocitary indicators (*total lymphocytes, T-, B-, O (null), Th, Ts),* coagulogram (*protrombinic indicator - PI, activated re-calcifying time - ART, time of partially activated tromboplastine - TPAT, trombone time - TT, fibrinogen,* Ca^{2+}) and proteinogram (*total proteins, albumins,* α_1, $-\alpha_2$, *-β, -γ globulins*). The obtained results are presented in Tables 1 – 3.

RESULTS AND DISCUSSIONS

The level of the protrombinic indicator (PI) for animals in group II was 7,4% lower (P>0,05) and for the animals in group III was with 10,6% lower(P>0,05) compared to the group I, while the level of $Ca^{2+,}$ in groups II and III dropped out by 20,0% (P>0,05). The activated re-calcification time (ART) for bovines in groups II and III has increased by 10,3% (P>0,05), the partially activated tromboplastine time (TPAT) correspondingly by 8,0% (P>0,05) and 10,0% (p>0,05), while the trombone time (TT) with 16,7% (P>0,05) in group II and with 26,7% (P<0,05) in group III. The fibrinogen levels in groups II is higher by 19,6% (P>0,05) while in group III it was lower by 12,5% (P>0,05) (Table 1).

Table 1. The impact of *S.papillosus* and *D.lanceolatum* monoinvasions on the coagulogram

Groups	PI, %	ART, seconds	TPAT, seconds	TT, seconds	Fibrinogen, g/l	Ca^+ mmol/l
I	94,0±3,65	68,0±3,0	50,0±2,58	30,0±1,50	5,6±0,24	2,5±0,17
II	87,0±3,43	75,0±1,93	54,0±1,50	35,0±1,93	6,7±0,34	2,0±0,13
III	84,0±2,79	75,0±1,07	55,0±1,07	38,0±1,29	4,9±0,30	2,0±0,21

The obtained results prove that averagely in bovines infested with *S. papillosus* there was a decrease in haemostatic indicators by 13,7% while in the groups infested with *D. lanceolatum* the decrease was 15,0% due to the exotoxins containing anticoagulant and haemolisant substances which neutralize the qualities of the fibrinogen, trombones, ions of Ca^{+} and vitamin K. The total quantity of protein in group III was diminished by 5,1% (P>0,05) while for the animals in group III – with 5,6% (P<0,05). The content of albumins has dropped with 18,0% (P<0,01) in group II and by 14,9% (P<0,01) in group III. The α_1-globulines in group II has increased by 28,3% (P<0,05) while in group III dropped out by 1,7% in comparison with the control group. The level of α_2-globulines in group II and III have increased by 14,0% (P>0,05) and 20,0% (P>0,05) correspondingly. The level of β-globulins in groups II and III have increased by 10,9% (P>0,05) compared to group I; the level of γ-globulins dropped out by 13,0% (P>0,05) and 11,9% (P>0,05) correspondingly (Table 2). The obtained results reveal that on average, the infestation with *S. papillosus* causes a diminishing of proteinogram indicators by 14,9%. These changes characterize the type I electroforegrame specific for acute inflammatory processes caused by the mechanical and spoliatory action of rabditoid larvae which convey the pathogenic microflora in the host organism in the process of migration. The infestation with *D.lanceolatum* leads to the modification of proteinogram indicators by 10,8%. The respective changes express the type VIII of electroforegram specific for the hepatobiliary simptomatic system due to the toxical, mechanical and spoliator action of parasites located in the biliary tracts of liver.

Table 2. The impact of *S.papillosus* şi *D.lanceolatum* monoinvasions on the proteinogram

Groups	Total proteins, g/l	Albumins, %	Globulins			
			α_1	α_2	β	γ
			%	%	%	%
I	85,5±1,16	44,4±0,62	6,0±0,52	10,0±0,64	11,9±0,45	27,7±1,55
II	81,1±1,12	36,4±1,12	7,7±0,54	11,4±0,64	13,2±0,82	31,3±0,77
III	80,7±0,99	37,8±0,77	5,9±0,43	12,0±0,54	13,2±0,54	31,0±1,12

In bovines infested with *S. papillosus* (group II) the number of total lymphocytes has dropped by 12,6% (P<0,05) while in animals infested with *D. lanceolatum* (group III) – by 20,8% (P<0,01) compared to the control group (group I). The level of B-lymphocytes in bovines of group II and III was lower with 1,4% (P>0,05) and 5,4% (P<0,05) respectively compared to the ones in group I. The T-lymphocytes in group II were lower by 25,8% (P<0,001) and 32,2% (P<0,001) in group III as opposed to group I. The lymphocytes' level in group II were decreased by 10,2% (P<0,01), while in group III -by 12,6 % (P<0,001). The number of null lymphocytes in animals from group II as opposed to the control group was increased by 27,2% (P<0,001) and 36,8% (P<0,001) in group III, while Ts-lymphocytes have increased accordingly by 8,8% (P<0,05) and by 7,4% (P<0,05) (Table 3).

Averagely, the infestation of bovines with *S. papillosus* causes a 14,3% drop in lymphocyte indexes while in the animals infested with *D. lanceolatum* – a drop of 19,2%. The results obtained denote the fact that helmints have the immuno-toxic effect on B-, T- and Th-lymphocytes causing the morfo-functional alterations and, as a result, considerably increasing the quantity of null and Ts-lymphocytes.

Table 3.The impact of *S.papillosus* and *D.lanceolatum* monoinvasions on the immunogram

Groups	Total lymphocytes	Lymphocytes				
		B	T	Null	Th	Ts
	%	%	%	%	%	%
I	70,4±2,8	19,6±2,1	56,0±3,6	24,4±4,1	24,2±1,3	20,2±1,3
II	57,8±5,2	18,2±1,3	30,2±1,9	51,6±3,2	14,0±2,1	29,0±1,9
III	49,6±3,2	14,2±1,5	23,8±1,7	61,2±2,8	11,6±3,0	27,6±2,8

CONCLUSIONS

1. The invasion with *S. papillosus* causes an average drop of 13,7% in coagulogram (plasmatic homeostasis), 14,9% in the proteinogram, 14,3% in the immunogram (limphocitary indicators), the total average decrease being 14,3%. The invasion with *D. lanceolatum* causes a medium alteration of 15,0% of the coagulogram (plasmatic hemostasis), 10,8% in the proteinogram and 19,2% in the immunogram (limphocitary indicators), the total average being 15,0%.
2. The increase in the ART, TPAT, TT and the tendency to decrease the level of PI and Ca ions in bovines infested with *S. papillosus*, compared to the control group, is due to the maldigestion and malabsorption at the gastrointestinal level and the persistence of hydrolytic enzymes (hialuronidasis) as inhibiting factors of coagulation, while the increase in the quantities of fibrinogen would cause severe inflammations occurred after the mechanic- irritative action at the level of the digestive and respiratory system.
3. The tendency of increase of PI and fibrinogen and considerate extension of TT in bovines infested with *D. lanceolatum* is probably due to cholestasia in the liver and the insufficiency of bile in the intestine since the decrease the capacity of hepathocites to absorb vitamin K is reduced in addition to the persistence of hydrolytic enzymes (hialuronidase) of the parasites.
4. The proteinogram in bovines from the group infested with *S. papillosus* represents the type I electroforegram specific for severe inflammations, while the bovines infested with *D. lanceolatum* have the type VIII of electroforegram specific for the simptomatic complex of the hepatobilliary system.
5. The parasitic antigens inhibit B-, T-, Th-lymphocytes and stimulate Ts-lymphocytes, provoking in this way a status of immune deficit in the host organism which is favorable for their development but reducing at the same time the defensive capacity of the host organism against other infectious agents.
6. Due to the immunologic effect the complex antiparasitic chemotherapy proved to diminish the level of B-, T- and Th-lymphocytes and the toxins resulted after the degradation of parasitic elements induced the quantitative increasing of null and Ts-lymphocytes.

BIBLIOGRAPHY

1. Andrieş L., Olinescu, A. Compediu de imunologie fundamentală. Chişinău, 1992. 476 p.
2. Dărăbuş Gh., Cosoroabă I., Drugă M. Aspecte etiologice şi epizootologice în eimerioza viţeilor. În: Medicina veterinară, creşterea animalelor, 1993, vol. 43, nr. 6-7, p. 18-20.
3. Olteanu Gh., Panaitescu D., Gherman I. ş. a. Poliparazitismul la om, animale, plante şi mediu. Bucureşti, 2001, 812 p.
4. Назаренко Г., Кишкун А. Клиническая оценка результатов лабораторных исследований. Москва, 2000. 544 с.
5. Петров Ю., Абалихин Б. Биохимические показатели и микрофлора желчи и содержимого кишечника овец при дикроцелиозе. Ж. Ветеринария, 1983, №3, с. 45-47.

ANTIBACTERIAL AND PROTECTIVE EFFECT OF *ALLIUM SATIVUM* ON INTESTINAL FLORA IN RATS (*RATTUS NORVEGICUS*)

N. FIȚ, Fl. CHIRILĂ, G. NADĂŞ, Adriana CRISTE

University of Agricultural Sciences and Veterinary Medicine Cluj–Napoca,
Faculty of Veterinary Medicine; E-mail: nfit@usamvcluj.ro

ABSTRACT

The aim of the work was to reveal the antimicrobial and protective effect of garlic on intestinal micro flora in rats. The experiment was conducted in two stages: a first step tested using in vitro diffusimethric method the antimicrobial effect of three aqueous suspensions of garlic (1g/ml; 0.1g/ml and 0.01g/ml) and an oily extract of garlic tested on microbial species such as Escherichia coli, Salmonella tiphymurium, Staphylococcus aureus, Bacillus cereus and Candida albicans; a second phase tested the effect of 0.1g/ml suspension of garlic on normal intestinal flora, and on rats experimentally infected with a strain of Salmonella tiphymurium. In vitro test results showed that the best antimicrobial effect of garlic was represented by 1g/ml suspension while the smallest inhibition zones were obtained for oily extract. Staphylococcus aureus and Candida albicans were the most sensitive organisms tested, with inhibition zones of up to 23 mm and the most resistant specie to garlic suspension and oil was Escherichia coli. After in vivo testing on rats we observed that the normal microbial flora changed by decreasing specifically the number of Gram positive (from 10^3 CFU to 10^2 CFU). Another observation consisted in a partial protection (80%) of rats, to experimental infection with Salmonella tiphymurium suspension after treatment with garlic. Group inoculated with Salmonella and untreated with suspension of garlic was eliminating Salmonella constantly until the end of the experiment and neutrophilia was also observed.

Keywords: antibacterial, protective effect, Allium sativum, intestinal flora, Rattus norvegicus

INTRODUCTION

Garlic is a plant with many therapeutic qualities long known for having some beneficial effects for humans. Besides the special role that has in the proper functioning of the cardiovascular system, garlic has a strong antibiotic effect, helps digestion and protect against carcinogens (Block, 1985).
Beneficial properties of garlic are attested from ancient times. Since antiquity, garlic was recommended for the treatment of over 60 diseases. Manufacturers of pyramids from ancient Egypt ate radishes, onions and garlic to prevent diseases. The Roman legions used more garlic in the diet too (Fenwick and Hanley, 1985). In the Middle Ages, French priests have used garlic to prevent further spread of the plague because of its antimicrobial effect. During World War I garlic was used for wounds dressing (Kumar and Sharma 1982, Rees, 1993). Nutritional properties of garlic are caused in particular to the presence of significant amounts of vitamins, especially A, B1, B2, C and some useful minerals including: phosphorus, sulfur, potassium, iodine, calcium and silicon (Ellen Tattelman, 2005). During crushing or cutting of the clove, the odorless amino acid called alliin, present in the garlic clove, is metabolized by the enzyme allinase (a cysteine sulfoxide lyase) to yield allicin and other thiosulfinates that are the source of the characteristic odor of garlic (Gowsala, 2001). Thiosulfinates and other secondary metabolites of garlic, including g-glutamyl peptides, scordinins, steroids, terpenoids, flavonoids and other phenols, may be responsible for

the range of therapeutic effects reported for garlic (Reuter et al. 1996). When the plant cell tissue is destroyed, the precursor is placed in contact with an enzyme (aliinaza), leading to an enzymatic reaction with formation dialilthiosulfinate (Allicin) and diallyl-disulphide. High diallyl disulphide content of this makes it useful in obtaining pharmaceutical products with antimicrobial activity (Sivam et al.1997).

Given these issues, we aimed the following main objectives:

- in vitro testing of antimicrobial effect of garlic on microorganisms isolated from the intestine of rats;
- testing the protective effect of garlic in *Salmonella tiphymurium* infections in rats (Rattus norvegicus).

MATERIALS AND METHODS

The experiment was conducted during January to March 2010 in the Laboratory of Microbiology and Physiology within the Faculty of Veterinary Medicine Cluj-Napoca. To test the in vitro antimicrobial effect of garlic on microorganisms isolated from the intestine of rats were used three types of suspensions obtained by grinding garlic in 0.9% saline and filtering the suspension. Afterwards three concentrations were realized: 1g/ml, 0.1g/ml and 0.01g/ml. We also tested in vitro antimicrobial effect of oily garlic extract as commercial product. Species of microorganisms tested for in vitro effect of garlic were represented by four bacterial species and a yeast, all isolated from rats. Species tested were: *Escherichia coli*, *Salmonella tiphymurium, Staphylococcus aureus, Bacillus cereus, Candida albicans.*For the test, specific materials were used for cultivation and sensitivity tests of germs in laboratory conditions, taking as model strains in susceptibility testing suspensions and garlic oil extraction by diffusimetrical method. Diffusimetrical technique was performed using the Mueller-Hinton agar culture in Petri plates. Strains were cultivated in nutrient broth for 24 hours before testing. Inoculums were obtained from suspensions of microorganisms in saline to an optical density of 0.5 McFarland scale. Subsequently the agar plates were flooded with suspensions obtained after drying and wells were made in the agar placing 30 µl/well in case of each type of garlic suspension. The plates were incubated 24 hours at 37^0C ±1 and the results were interpreted by determining the diameters of inhibition area. To test the protective effect of garlic in *Salmonella tiphymurium* infections in rats (Rattus norvegicus) were used three groups of rats of the species *Rattus norvegicus*, Wistar line, 15 animals in total.

 Group I (I-5) was treated with garlic suspension;

 Group II (II-5) was treated with garlic and inoculated with a suspension of *Salmonella tiphymurium*;

 Group III (III-5) untreated control which was inoculated with a suspension of *Salmonella tiphymurium*.

Quantity of Salmonella tiphymurium administered has a concentration of 10^7 CFU. In all groups that received garlic, the concentration of 0.1g/ml aqueous suspension was used. In these groups were made the following administrations and harvesting: groups I and II received the garlic extract 0.8 ml (0.1g/ml) per rat once a day, three days consecutively, in groups 2 and 3 on day 1 of experiment 0.1 ml of *Salmonella tiphymurium* suspension (10^7 CFU) was administrated. Daily faecal bacteria were examined on normal and special culture media (MacConkey and XLD) with colony counting for Gram positive and Gram negative. In all four groups on day 0 and 4 was collected blood for hematological profile (erythrocytes, leukocytes, percentages of type of leukocyte, and Arnett index).

RESULTS

After testing in vitro antimicrobial effect of garlic on microorganisms isolated from the intestine of rats, the following results were obtained by measuring inhibition zone diameter (mm) from microorganisms isolated from the intestine of rats (Chart 1).

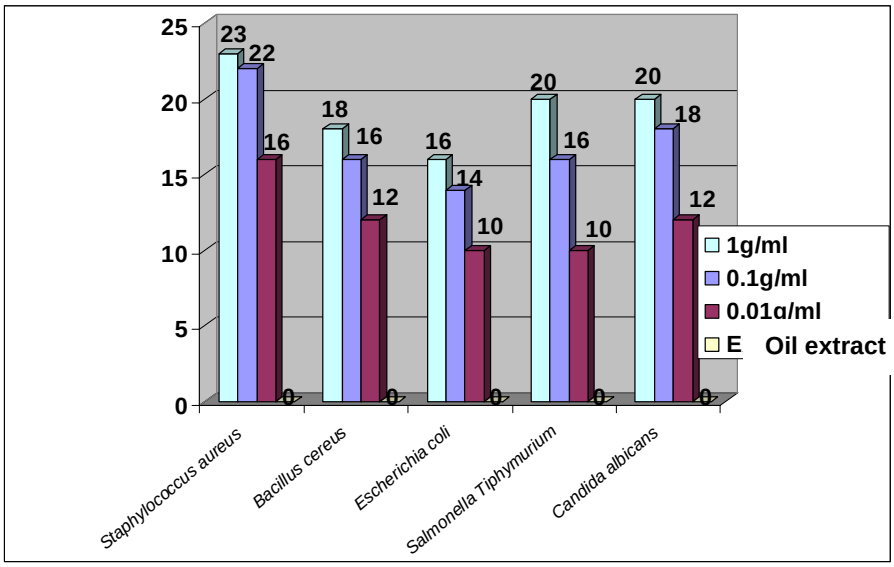

Chart 1. In vitro antimicrobial effect of garlic on microorganisms isolated from the intestine of rats: diameters of inhibition area (mm)

On the chart can be observed that the antimicrobial effect of garlic suspension is clearly expressed by inhibition area with relatively large diameters (22-23 mm), unlike the results in garlic oil extraction where there was no inhibitory effect of antimicrobial species tested by this method.
To analyze the protective effect of garlic in *Salmonella tiphymurium* infections in rats (Rattus norvegicus) were obtained the following changes in the number of organisms eliminated by animals during the experiment (Chart 2).

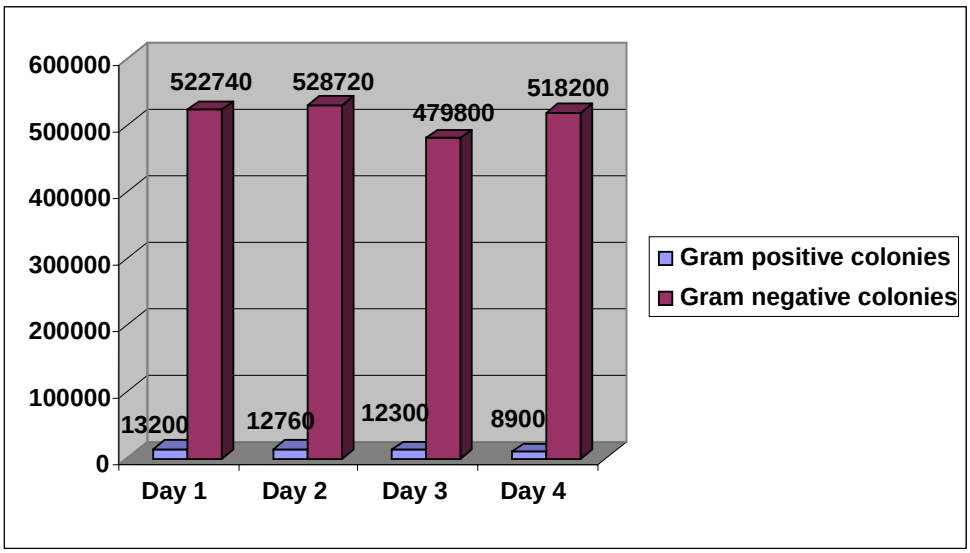

Chart 2 . Variation of intestinal microbial number (CFU) in group of rats treated with garlic

Lot of rats treated with garlic and infected with *Salmonella tiphymurium* presented an elimination of salmonella in all individuals on the day of inoculation with microorganisms, while subsequently in the second and third day after inoculation of *Salmonella tiphymurium,* elimination rate to fall gradually so that in the last day of the experiment only one individual has eliminated salmonella (Table 1).

Table 1. Group 2 treated with garlic and infected with *Salmonella tiphymurium*

Rats No.	Day 1	Day 2	Day 3	Day 4
Rat 1	Salmonella negative	Salmonella positive	Salmonella positive	Salmonella positive
Rat 2	Salmonella negative	Salmonella positive	Salmonella positive	Salmonella negative
Rat 3	Salmonella negative	Salmonella positive	Salmonella negative	Salmonella negative
Rat 4	Salmonella negative	Salmonella positive	Salmonella positive	Salmonella negative
Rat 5	Salmonella negative	Salmonella positive	Salmonella negative	Salmonella negative

Lot of rats inoculated with *Salmonella* and treated with garlic had a different evolution of *Salmonella* group eliminations treated with garlic. Table 2 shows that the elimination of Salmonella after inoculation was present in all animals until the end of the experiment.

Tabel 2. Group 3 untreated with garlic and infected with *Salmonella tiphymurium*

Rats No.	Day 1	Day 2	Day 3	Day 4
Rats 1	Salmonella negative	Salmonella positive	Salmonella positive	Salmonella positive
Rats 2	Salmonella negative	Salmonella positive	Salmonella positive	Salmonella positive
Rats 3	Salmonella negative	Salmonella positive	Salmonella positive	Salmonella positive
Rats 4	Salmonella negative	Salmonella negative	Salmonella positive	Salmonella positive
Rats 5	Salmonella negative	Salmonella positive	Salmonella positive	Salmonella positive

In terms of hematology, neutrophilia was observed in groups infected with *Salmonella tiphymurium* and a deviation of Arnett index towards left. In group uninfected with *Salmonella tiphymurium* were not observed deviations of the hematological profile.

CONCLUSIONS

- Treatment with garlic extract in rats infected with *Salmonella* had partially protective effect (66%) compared with controls where the animals remained carriers and eliminator of germs;
- Administration of garlic to uninfected rats had an inhibitory effect on Gram positive intestinal flora.

BIBLIOGRAPHY

1. Block, E. (1985) The chemistry of garlic and onions. Sci. Am. 252: 114–119.
2. Ellen Tattelman, M.D., (2005) Health Effects of Garlic *American Family Physician*; 72:1, 103-6.
3. Fenwick, G. R. & Hanley, A. B. (1985) The genus *Allium*—part 3. Medicinal effects. CRC Crit. Rev. Food Sci. Nutr. 1: 1–74.
4. Gowsala P. Sivam (2001) Protection against *Helicobacter pylori* and Other Bacterial Infections by Garlic, The Journal of Nutrition. 131: 1106S–1108S.
5. Kumar, A. & Sharma, V. D. (1982) Inhibitory effect of garlic (*Allium sativum* Linn.) on enterotoxigenic *Escherichia coli*. Indian J. Med. Res. 76: 66–70.
6. Rees, L. P., Minney, S. F., Plummer, N. T., Slater, J. H. & Skyrme, D. A. (1993) A quantitative assessment of the antimicrobial activity of garlic (*Allium sativum*). World J. Micrbiol. Biotechnol. 9: 303–307.
7. Reuter, H. D., Koch, H. P. & Lawson D. L. (1996) Therapeutic effects and applications of garlic and its preparations. In: Garlic: The Science and Therapeutic Applications of *Allium sativum* L. and Related Species, 2nd ed. (Koch, H. P. & Lawson, D. L., eds.), pp. 135–212. William & Wilkins, Baltimore, MD.
8. Sivam, G. P., Lampe, J. W., Ulness, B., Swanzy, S. R. & Potter, J. D. (1997) *Helicobacter pylori—in vitro* susceptibility to garlic (*Allium sativum*) extract. Nutr. Cancer 27: 118–121.

STUDIES ABOUT MICROBIAL ETIOLOGY AND ANTIBIOTIC RESISTANCE IN SUBCLINICAL MASTITIS IN COWS

N. FIȚ, F. CHIRILĂ, S. RĂPUNTEAN, G. NADĂŞ, Sanda ANDREI, Sorana Teodora MATEI

University of Agricultural Sciences and Veterinary Medicine Cluj – Napoca,
Faculty of Veterinary Medicine;

ABSTRACT

Studies about the etiology and antibiotic resistance of microorganisms isolated from subclinical mastitis were conducted during September - 2009 and April 2010, in two cattle farms in North-Western of Transylvania and the microbiology laboratory of the Faculty of Veterinary Medicine Cluj-Napoca. Subclinical mastitis milk samples were selected by electrical conductivity test. Thirty-two samples with subclinical mastitis were processed pursuing the isolation of microbial species in milk and determine the number of colony forming units (CFU/ml). Results revealed that Staphylococcus aureus was isolated in 59.37% of the examined samples, Bacillus cereus in 21.87%, Streptococcus agalactie in 18.75%, Escherichia coli in 15.62%, Micrococcus luteus, Pseudomonas aeruginosa, Candida albicans in 6.25%, and Aspergillus spp., Mucor spp in 3.12%. Most commonly associated organisms were Staphylococcus aureus with Streptococcus agalactie. The number of germs determined from samples processed was between 7629 and 140 CFU/ml milk. Highest sensitivity of bacterial strains isolated from milk samples was in order enrofoxacin, florfenicol and amoxicillin clavulanate and most resistant were to lincospectin. Candida strains were sensitive to nystatin, nizoral and resistant to ketoconazole, cotrimoxazole, myconazol and fluorocitozin. Studies revealed that microorganisms isolated from subclinical mastitis are the same as in clinical mastitis and in case of subclinical mastitis evolution, a small number of CFU/ml was observed.

Keywords: microbial etiology, subclinical mastitis, antibiotic resistance.

INTRODUCTION

Mastitis are considered inflammatory processes of the mammary gland that produce changes (pathological, physical, chemical and bacteriological) of glandular tissue and milk. They are the most costly problems encountered in dairy cattle breeding. Damage can reach up to 200 dollars per cow per year (Miller et al., 1993 and Rainard et al., 2003). The most common mastitis are likely infectious (32-48%) and traumatic (34.5 to 36%) in all farming systems. Bacteriological examinations and antibiogram reveals a wide range of bacteria present in milk, predominantly *Escherichia coli* and *Staphylococcus aureus*. The milk quality is significantly lower compared to Community requirements, both in terms of number of somatic cells (SCN) and in terms of total number of germs (TNG) (Bourry et al., 1997; Jones et al., 1997, Sayed and Mohamed 2008).

In our country, losses caused by mastitis are estimated at approximately 11% of milk production. Losses can add quantitative and qualitative impairment of milk, which consists in reducing the percentage of nutrients in milk as follows: 10% for fat, 15% to 18% for casein and lactose, from mastitis milk obtaining cheese and butter. In addition, mastitis are causing a very high number of somatic and germ cells in milk, with disastrous economic consequences (Groza, 2006).

It is estimated that total economic losses caused by clinical and subclinical mastitis can be distributed as follows:

- 70% in milk production;
- 15% through reform and mortality due to chronic mastitis, incurable;
- 10% due to the presence of antibiotic residues in milk adversely affecting the dairy industry processes;
- 10% is the cost of treatment (drugs used to treat mastitis).

Given these considerations listed previously, we aimed the following:

• to determine the microbial etiology of subclinical mastitis in cows with determining the number of microorganisms (CFU/ml) of samples with subclinical mastitis;

• determination of antibioresistance to isolates from subclinical mastitis milk samples.

MATERIALS AND METHODS

The researches were conducted on a total of 32 milk samples collected from cows with subclinical mastitis in the period October 2008 - May 2010. Samples were collected in Mures, Alba and Cluj Counties. Samples were collected from affected quarters after disinfection and removal of the first jets of milk. About 10 ml of milk was collected per sample in a sterile glass or plastic container, after which samples were sent to the laboratory within the shortest possible time. If the samples fail to be delivered in the day of collection, they were stored in a refrigerator at a temperature of 4°C. Bacteriological and mycological tests was performed in the laboratory of Microbiology of the Faculty of Veterinary Medicine in Cluj-Napoca. A 50 µl quantity of milk from each sample was deposited in a nutrient broth tube, a tube of liquid Chapman medium, a Petri dish with agar with 5% sheep blood and a Petri dish with glucose agar or Sabouraud medium. Sown media were incubated at 37°C in aerobiosis conditions for 72 hours, examining the tubes daily. In case of fungi and algae cultures were kept at laboratory temperature up to 7-10 days to examine cultural characters, especially the appearance of the colonies. For the morphological characterization wet or dry smears were performed. Staining and examination techniques have been adapted to examine microorganisms (bacteria or fungi). Tubes with broth that are found on microscopic examination performed after 24 hours incubation at 37°C the presence of cocobacili or bacilli Gram negative, were resowed on MacConkey or other culture media for Enterobacteriaceae differentiation. Also for species identification was used identification system API Biomerieux. In determining the number of microorganisms in the samples were used techniques under ISO standards 11866-1 and 2/2009 for bacteria and ISO 6611/2009 for yeasts and molds.

RESULTS

Following the identification of potentially pathogenic microorganisms it was found a complex mastitis etiology. From our studies we isolated 9 types of microorganisms divided such as: 6 types of bacteria, one yeast and two fungi. Among these microorganisms the most frequently isolated was genus *Staphylococcus* with the species *Staphylococcus aureus* identified in 59.37% of all samples, either alone or in combination with other bacterial species (Table 1). Next in frequency from samples examined was *Bacillus cereus* that was isolated in 21.87%. Bacteria from the species *Streptococcus agalactiae* were isolated in a ratio of 18.75%, followed by those of the species *Escherichia coli* with a rate of 15.62%, the species *Pseudomonas aeruginosa*, *Micrococcus luteus* and *Candida albicans* with isolation frequency of 6.25% and the genera *Aspergillus* and *Mucor* fungi with 3.12%. Regarding the number of microorganisms identified from samples of milk with subclinical mastitis is observed that the results are quite variable, with samples having a small number of organisms (140CFU/ml) and samples with a large number of microorganisms (7629 CFU/ml) (Table 1). From the results we can see that the greater number of microorganisms found in positive samples by electrical conductivity test is present when identifying *Streptococcus agalactie*.

Table 1. Species of microorganisms isolated and number of germs from milk samples

Sample number	Microbial species isolated/TNG									CFU/ml
	Staphylococcus aureus	*Streptococcus agalactie*	*Micrococcus luteus*	*Bacillus cereus*	*Escherichia coli*	*Pseudomonas aeruginosa*	*Candida albicans*	*Aspergillus spp.*	*Mucor spp*	
1.	+			+	+					3560
2.				+						2225
3.	+									890
4.	+			+						140
5.	+								+	4577/120
6.	+	+								6103
7.	+							+		1017/35
8.	+									2288
9.		+								7629
10.	+	+								2225
11.	+									3255
12.	+									148
13.	+									1568
14.	+									3269
15.	+									1006
16.	+									265
17.	+									756
18.						+				250
19.	+									346
20.						+				5640
21.			+	+						2500
22.			+	+						4521
23.	+	+								864
24.		+								466
25.	+				+					2530
26.					+					432
27.	+									563
28.							+			230
29.				+	+					1537
30.				+						426
31.		+								7200
32.							+			2560
Total	**19**	**6**	**2**	**7**	**5**	**2**	**2**	**1**	**1**	
%	**59.37**	**18.75**	**6.25**	**21.87**	**15.62**	**6.25**	**6.25**	**3.12**	**3.12**	

Table 2. The results of subclinic mastitis cow milk strains sensibility to antibiotics

Antibiotic	*Streptococcus*			*Staphylococus*			*Escherichia*			*Bacillus*			*Pseudomonas*		
	Nr	S	R	Nr	S	R	Nr	S	R	Nr	S	R	Nr	S	R
Enrofoxacin	6	6	0	19	17	2	5	3	2	7	7	0	2	1	1
Florfenicol	6	6	0	19	19	0	5	3	2	7	7	0	2	1	1
Amoxicillin Clavulanate	6	6	0	19	15	4	5	2	3	7	7	0	2	1	1
Penstrep	6	6	0	19	11	8	5	0	5	7	0	7	2	2	0
Tetradelta	6	3	3	12	10	2	5	0	5	7	4	3	2	0	2
Lincospectin	4	2	2	10	1	9	5	0	5	7	5	2	2	0	2
Colistin	2	1	1	6	2	4	5	3	2	7	0	7	2	1	1

Legend: Nr.-number of tested strains; S- number of sensitive strains: R-number of resistant strains.

Table 3. . The results of *Candida albicans* mastitis cow milk strains sensibility to antimycotics

Antimycotic/Antibiotic	*Candida*		
	Nr	S	R
Nizoral	2	2	0
Nistatin	2	2	0
Ketoconazol	2	0	2
Fluorocytozin	2	0	2
Myconazol	2	0	2
Cotrimoxazol	2	0	2

Antibiotic sensitivity of microbial strains isolated from mastitis subclinical milk samples is presented in Tables 2 and 3, where there is a good sensitivity of streptococci to Enrofoxacin, Florfenicol, Amoxicillin Clavulanate and Penstrep. In case of staphylococci Enrofloxacin proved also to be the best appearing resistance to only a small number of strains. For *Escherichia coli* and *Pseudomonas aeruginosa* is noted from Table 2 that more than half of the strains were resistant to antibiotics tested. *Bacillus cereus* strains had a good sensitivity to Enrofloxacin, Florfenicol and Amoxicillin. *Candida albicans* strains were sensitive to Nystatin, Nizoral and resistant to Ketoconazole, Cotrimoxazole, myconazol and fluorocytozin. Culler and Tyler (1996) considers that subclinical evolution of mastitis is associated to the absence of macroscopic alterations, but are observed alterations in milk composition (in terms of proteins, carbohydrates, lipids and microflora). Ribeiro et al. (2003) argues that this form of subclinical mastitis is very important and closely related to clinical mastitis.

CONCLUSIONS

Following the laboratory diagnosis of the 32 samples of milk collected from cows with subclinical mastitis, the following conclusions are revealed:

- Etiology of mastitis was very diverse, isolating 6 types of bacteria (*Staphylococcus, Streptococcus, Micrococcus, Bacillus, Escherichia* and *Pseudomonas*), a yeast (*Candida*) and two fungi (*Aspergillus* and *Mucor*)
- The incidence of bacterial species involved in mastitis etiology was superior to other types of microorganism, *Staphylococcus aureus* being isolated in 59.37% of the samples, *Bacillus cereus* in 21.87%, *Streptococcus agalactiae* was present in 18.75% of samples*, Escherichia coli* was identified in 15.62% while *Pseudomonas aeruginosa* and *Micrococcus luteus* each in 6.25% of the samples;
- There was a sensitivity of germs isolated from subclinical mastitis milk to Enrofloxacin, Florfenicol and Amoxicillin Clavulanate. Strains of *Candida albicans* were sensitive to Nystatin, Nizoral and resistant to Ketoconazole, Cotrimoxazole, Myconazol and Fluorocitozin.
- Studies revealed that microorganisms isolated from subclinical mastitis are the same as in clinical mastitis and subclinical mastitis evolution, a small number of CFU/ml was observed.

BIBLIOGRAPHY

1. Bourry, A.; Cochard, T. and Poutrel, B. (1997): Serological diagnosis of bovine, caprine and ovine mastitis caused by listeria monocytogenes by using an ELISA. J. Clin. Microbiol., 33: 6.
2. Culler JS, Tyler JW. (1996); Mammary gland health and disorders. *In:* Smith BP, editor. Large animal internal medicine. St Louis: Mosby-Year Book Inc;.
3. Groza I., (2006): Ginecologie, andrologie şi obstetrică veterinară - compendiu, , Editura Academiei Române, Bucureşti
4. Jones, T.; Hunter R. and King N. (1997): Veterinary pathology. 6th ed. Williams and Wilkins Awavery company, Baltimore, Philadelphia, London.
5. Miller, R. H.; Pape, M.J.; Futton, L. A. and Schtz, M. M. (1993): The relationship of milk and somatic cell count to milk yeilds for Holistein heifers after first calving. J. Dairy Sci., 76:728-733.
6. Quinn, P.J.; Carter, M.E.; Markey, B.K. and Carter (1994): Clinical Veterinary microbiology. Mosby–Year Book Europe Limited London England 1st Ed.
7. Rainard, P.; Corrales, J.C.; Barrio, M.B.; Cochard , T. and Poutrel B. (2003): Leukcytic activaties of Staph.aureus strains isolated from cows,ewes,and goats with mastitis. Clin. Diag. Immunol., 10 (2):272-277.
8. Ribeiro MER, Petrini LA, Aita MF, Balbinotti M, Stumpf JRW, Gomes JF. (2003): Relação entre mastite clínica, subclínica infecciosa e não infecciosa em unidades de produção leiteiras na Região Sul do Rio Grande do Sul. R Bras Agriciência.; 3 (9): 287-290
9. Sayed Z. M., A. E. A Mohamed (2008): Bacteriological studies on mastitis in dairy Friesian cattle inQuena governorate. BS. VET. MED. J. VOL. 18, NO.2, P 19-21

RESEARCH ON AVIAN COLIBACILLOSIS IN THE CASE OF INTENSIVE BREEDING

Diana GALAȚANU[1], T. PERIANU[2], Oana TĂNASE[2]

[1]Morandi Com. Lipovăț Vaslui,
[2] FMV Iași diana.galatanu@gmail.com

ABSTRACT

Avian Colibacillosis is a contagious infectious disease that causes economic loss of the affected flocks. It is caused by E. coli, it is frequently found together with other infections, caused by other bacteria and/or other viruses. The disease was studied on a flock of 22,000 Issa Brown chicks. The percentage of morbidity was high and the mortality reached 6.3%. After the isolation of 51 strains of E. coli and after performing an antibiogram, there was applied a treatment with floron for five days, resulting in a low mortality rate. Losses were not significant and poultry reached maturity, up to the age of productive performance.

Key words: colibacillosis, E.coli, intensive breeding system, poultry.

Avian Colibacillosis represents a serious problem for the poultry industry, as it is one of the main causes of morbidity and mortality in poultry. The strains of pathogenic *Escherichia coli* at poultry may cause airsacculitis, polyserositis, omphalitis, peritonitis, salpingitis, synovitis, septicemia, cellulitis, necrotic dermatitis and granulomatous syndrome at poultry. Considering the frequent presence of this disease in poultry flocks bred in the intensive system and considering the consequences of this disease (unevenness of the flock, decrease in the percentage of egg production, decrease of the body weight, confiscation at slaughterhouses), epidemiological, clinical and morphological surveys of colibacillosis were conducted in the case of the intensive poultry breeding system.

MATERIAL AND METHODS

Epidemiological investigations were conducted on a sample of 22,000 Issa Brown chicks in a poultry farm in Vaslui during May-August 2005. The poultry are bred on the ground, on a permanent layer of sunflower husk and sawdust, and the density is 15 chicks / sqm. The first signs of the disease became visible at the age of 24 days, after the vaccination against pseudopestis. The morbidity rate increases (it reaches 50%) and the mortality rate reaches 6.3% at 48 days, afterwards the clinical aspects return to normal. (Table 1) The diagnosis of avian colibacillosis was confirmed by laboratory tests, as well as by clinical examination and necropsy. 450 samples were taken to establish a diagnosis and the best treatment. 51 bacterial strains were isolated and identified as E. coli from the liver, heart, air sacs, lung. The inseminations were performed in the usual environments – bouillon, agar, but also in specific environments for the diagnosis of E. coli (Levin). All studied APEC strains exhibited a positive lactose fermentation in the culture environments, this biochemical character being considered constant at APEC strains. All lactosis-positive strains were subject to further testing by TSI minimum set, MIU, Congo red. The colibacillosis diagnosis is also confirmed by morphological and biochemical characteristics.

Table 1

Mortality rate in the chicks flock

Age of the chicks	Number of dead chicks / day	Total number of dead chicks	Mortality percentage
25 days	10	10	0,04 %
26 days	15	25	0,11 %
27 days	30	55	0,2 %
28 days	40	95	0,43 %
29 days	50	145	0,65 %
34 days	70	215	0,97 %
35 days	75	290	1,31%
38 days	80	370	1,68%
40 days	100	470	2,1 %
41 days	110	580	2, 63 %
42 days	200	780	3,54 %
43 days	280	1060	4,8 %
44 days	150	1210	5,5 %
45 days	100	1310	5,9 %
46 days	50	1360	6,1 %
47 days	25	1385	6,2 %
48 days	10	1395	6,3 %

Necropsy was performed on a total of 650 chicks and the results were: serumfibrinous airsacculitis lesions 76.9%; serumfibrinous pericarditis lesions 89.2%; bleeding necrotic hepatitis – 15.3%; fibrinous salpingitis – 23%; fibrinous-purulent peritonitis – 53.8%. (Table 2)

Table 2

Type and frequency of anatomopathological changes

Age of the chicks	Number of dead chicks	Airosacculitis	Pericarditis	Hepatitis	Salpingitis	Peritonitis
25-34 zile	290	68,9 %	86,2%	15,5 %	-	8,6%
35-40 zile	845	93,4 %	94,6%	23,6%	35,5 %	76,9%
41-48 zile	335	28,8 %	59,7%	-	-	14,9%

The global movement of poultry contributes to the dissemination of APEC strains and, consequently, to the spreading of multiple resistance to antibiotics, which requires, from this point of view, to monitor the APEC strains, isolated at poultry bred in intensive system, inside reference laboratories that are already active in many countries. After performing the antibiogram for the 51 isolated E. coli strains, it was noticed the increasing resistance of the strains to most antibiotics and a reduced sensitivity, especially towards newer antibiotics. (Table 3). Thus, the best results were obtained in florfenicol (over 90% sensitivity). Other 36 tested E. coli strains proved to be sensitive, more than 50%, to the following antibiotics: flumequin (61.11%), enrofloxacin (58.3%) and norfloxacin (52.77%).

Regarding antibiotic resistance, the 51 strains tested in the first set proved to be more than 50% resistant to the following antibiotics: doxycycline (92.57%), tetracycline (85.13%), neomycin (77.69%), ciprofloxacin and erythromycin (60.34%), spectinomycin (57.85%).

Table 3

Results of the antibiotics behaviour of the *E. Coli* strains

Antibiotics	Sensitive %	Moderately sensitive %	Resisting %
Neomycin	*10*	*12,31*	*77,69*
Enrofloxacin	*58,3*	*23,7*	*8*
Apramycin	*68,2*	*27,2*	*4,6*
Streptomycin	*7,5*	*23,8*	*68,7*
Colistin	*75,4*	*23,4*	*1,2*
Furazolidon	*62,4*	*26,8*	*10,8*
Tetracycline	*6,7*	*8,17*	*85,13*
Amoxycyline	*51,4*	*13,7*	*34,9*
Spectinomycin	*20*	*22,15*	*57,85*
Lincomycin	*-*	*-*	*100*
Gentamycin	*40,2*	*28,3*	*31,5*
Sulfametoxazol+ Trimetroprim	*11,5*	*34,6*	*53,9*
Ampycylin	*2,7*	*21,6*	*75,7*
Fluorfenicol	*90*	*6,4*	*3,6*
Lincospectin	*89,5*	*-*	*10,5*

RESULTS AND DEBATES

The episode of avian colibacillosis was caused, inside the poultry farm, by microclimate deficiencies – overpopulation, excesive dust, after-vaccination stress and the mortality losses vary according to these circumstances. (Figure 1)

.

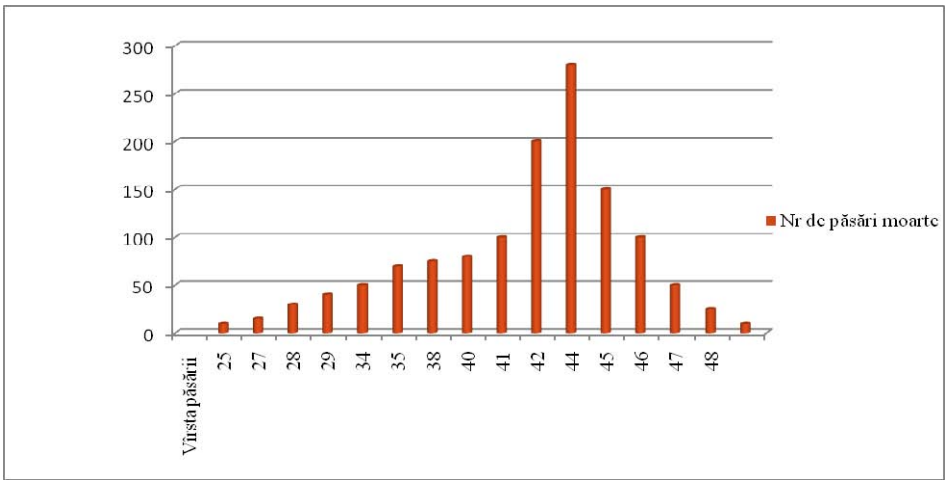

Figure 1
Mortality rate in a poultry flock

At the sick poultry, the disease causes sneezing, serous ocular and nasal catarrh, cough, dispneic breathing and deformation of infraorbital sinus. At the poultry under necropsy, at the level of the air sacs, there are fine deposits of fibrin that later turn into fibrin-caseous deposits that look like scrambled eggs. The lungs are inflamed and the lung volume is increased, with lesions of catarrhal pneumonia. Subsequently, the colour of the fibrin in the air sacs grows darker, towards dark grey. Serious serous and serous-fibrinous pericarditis occur, subsequently followed by the inflammation

of the liver serous and then of all abdominal serous, all the organs are covered by fibrin. (Figure 2, Figure 3).

Fig. 2 Foamy exudate in the air sacs at poultry infected by *E.coli*

Fig. 3 Cheese-like exudate in the air sacs at poultry infected by *E.coli*

As the disease evolves, the liver becomes darkish or dark green, with an increased consistency and the pectoral muscles are congested, increased in volume, friable and with foci of bleeding-necrotic hepatitis. There is also fibrino-purulent peritonitis, fibrinous salpingitis. (Figure 4, Figure 5) The intestines uusally show a cataral inflammation, often with bleeding points on the intestinal serous. Bleeding is also found on the pericardium, endocardium and in other organs.

Fig. 4 Liver hypertrophy at chicks aged 40 days

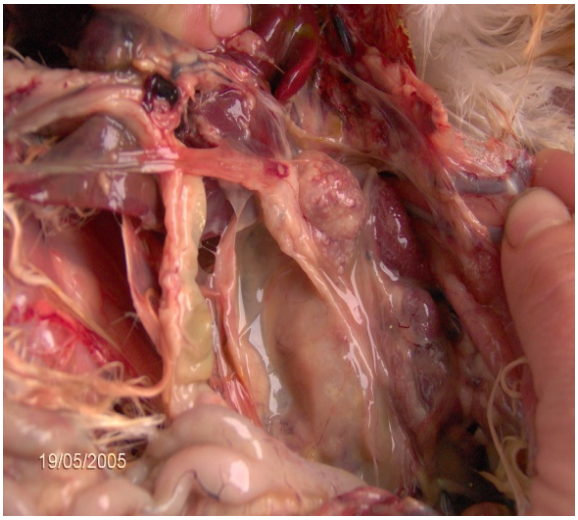

Fig. 5 Airosacculitis and salpingitis at chicks aged 40 days

At the age of 35-40 days, there was found a high frequency of lesions caused by airosacculitis, pericarditis, hepatitis, salpingitis and peritonitis. During the evolution of the disease, the poultry inside the hall were partly transfered to other halls and, after the antibiogram was performed, drug treatment was applied for five days with floron – 200 ml / 100 liters of water in the drinking water, starting from the age of 40 days. Two or three days after the beginning of the treatment, the mortality rate began to fall. (Table 4).

Table 4

Mortality rate after the antibiotics treatment

Age of the chicken	Number of dead chickens	Mortality percentage
41 days	110	0,5 %
42 days	200	0,9 %
43 days	280	1,27%
44 days	150	0,53 %
45 days	100	0,45 %
46 days	50	0,22 %
47 days	25	0,11 %
48 days	10	0,04%

CONCLUSIONS

The research on avian colibacillosis conducted on a group of poultry bred in the intensive system led to the following conclusions:

1. The disease was found in a set of 2,200 chickens bred in the intensive system and it was caused by postvaccination stress and inappropriate microenvironment conditions.
2. Colibacillosis happened because of postvaccination stress and the high density of chicks in the hall.
3. The disease started at the age of 25 days, the morbidity rate is high (50%), but the mortality rate reached 6.3%.
4. The diagnosis of colibacillosis was established by laboratory tests (by cultivation on agar, bullion), morphological and biochemical examinations, clinical exams and necropsy.
5. E. coli strains were isolated and the antibiogram pointed out the increased sensitivity of the strains to flurofenicol.
6. Losses were not so significant and they have not affected the poultry stocks, as the chicks reached productive performances in terms of egg production when they reached adulthood.

BIBLIOGRAPHY

1. **SF Altekruse, F. Elvinger, C. DebRoz, FWPierson, JD Eifert, N. Siranganathan,** 2002 - Avian Diseases, 46 (3), pp562-569.
2. **Kapur V, White DG, Wilson RA, Whittle TS**, 1992 - Outer membrane protein patterns mark clones of Escherichia coli O2 and O78 strains that causes avian septicemia. Infect immune. April, 60 (4), pp1687-1691.
3. **Victoria Martin**, 2001 - Infectious diseases in domestic animals, Ceres Publishing House, Bucharest.
4. **Maurer JJ, CL Hofacre, Wool RE, P. Gibbs, R. Froyman**, 2002, Avian Diseases, 46 (3), pp704-706.
5. **Victoria Martin**, 2001 - Infectious diseases in domestic animals, Ceres Publishing House, Bucharest.
6. **Mitrănescu E. Ionita I.,** 2001 - Increased bird-hygiene, nutrition, diseases and treatments, masks, Bucharest.
7. **Nettle A., Stanica Andreea**, 2004 - Sensitivity to antibiotics of strains of E. coli, Salmonella ssp, Pseudomonas aeruginosa and Staphylococcus aureus isolated in the diagnostic center of SN "Pasteur Institute" in the year 2003, Newsletter 15 (1), pp14-18.
8. **Vasiu Constantin**, 2007 - Infectious diseases in animals, Mega, Cluj-Napoca.
9. **Vidotto MC, Müller EE, de Freitas JC, Alfieri AA, Guimarães IG, Santos DS**., 1990 - Virulence Factors of avian Escherichia coli.
10. **Nettle A., Stanica Andreea**, 2004 - Sensitivity to antibiotics of strains of E. coli, Salmonella ssp, Pseudomonas aeruginosa and Staphylococcus aureus isolated in the diagnostic center of SN "Pasteur Institute" in the year 2003, Newsletter 15 (1), pp14-18.

CLINICAL ASPECTS OF SOME PODAL DISEASES IN BOVINE

FROM DIFFERENT BREEDING SYSTEMS

Dan GÎSCĂ,

Cabinet Medical Veterinar, Str. Bradului Nr. 43, Comuna Vânători, Județul Galați,
c_mv@windowslive.com

ABSTRACT

The issue introduces some podal diseases commonly encountered in household cattle breeding system and some podal diseases frequently encountered in the farming and micro-farming cattle breeding environment, together with specific aspects from an anatomical – clinical point of view. The issue comprises photos – outcome of three years of personal study. Considering it useful, some suggestions that would help prevention and control of such diseases were inserted, knowing that it is easier to prevent than to treat, and the cost is substantially reduced with an efficient prevention. A diseased animal renders an inferior production, and sometimes production is compromised during the whole treatment period (due to waiting time of medicines employed) or, the animal is slaughtered too soon. Out of reasons of efficiency I made the choice of a presentation for the symposium by aid of a poster.

Key Words: podal diseases, household system, micro – farm, large farm.

MATERIALS AND STUDY METHODS:

Materials:
- bovines grown in household system within the Vanatori Community, County of Galati,
- bovines grown in a micro – farm in Barcea Community, County of Galati, with a 50 capita matrix,
- bovines grown in a large farm, with a 250 capita matrix in Sendreni Community, County of Galati.

Study Methods: inspection, palpation.

CLAW DEFORMATION

Description. Claw deformation depends on various factors, among which the keratogen membrane inflammation and prolonged stabulation seem to be the most important.

a. "Peasant Sandal" Claw

Claw

b. Secondary "Ram Horn"

From a clinical point of view, the claws appear as deformed , altered in form and configuration, allowing for extremely varied aspects, such as: “Hunter Bugle,” “Ram Horn,” “Peasant Sandal,” etc. In case that the deformation is caused by a prolonged stabulation, seemingly occurring as a lack of horn blunting, the surface of the claw has mainly a regular aspect. If the deformation is caused by a congestive kelodermatitis (founder/laminitis) for instance, the wall looks rugged, with circles and rugosities.

Control. These affections may be controlled by periodical trimming of claws, taking animals out from shelters, so that the blunting would be naturally achieved. It is also important so that the cattle breeders would realize this is an affection which produces economical repercussions and treat this problem as it is necessary, asking for specialized assistance. (7)

FOREIGN BODY

c. Pus bag under the horn box.
The nail penetrated the horn box.

In this context the term “foreign body” represents an object such as a stone, piece of glass or nail on which a cow stands.

- It can simply cause pressure on the sensitive tissue inside the foot, or
- It will penetrate the sole and inject infection into the sensitive tissues the claw.

Penetration of the Sole
A foreign body penetrating the front half of the sole will cause very acute lameness to develop rapidly. In this case an abscess would be located between bone and horn. If such a lesion resolves naturally, pus would have to escape via the coronary band.

Penetration Beneath the Heel
A foreign body penetrating in the heel region will cause lameness that develops slowly and is less painful. In this case an abscess is located between elastic horn and the elastic digital cushion. Pus escapes around the coronary band of the heel bulb and causes underrun heel.

Control. Because of the accidental nature of the condition, control measures cannot be suggested. The risk of trauma can be reduced by ensuring that foreign bodies are not left around after workmen have been undertaking repair. The condition of roadways and new concrete surfaces should be monitored. (7)

ABSCESS OF CORONARY BAND

Description. A coronary band abscess is a discharge of pus from the junction of the skin with the horn. This lesion is often missed if it is covered with mud and manure. Palpating the coronary

d. Abscess of coronary band – micro-farm cow

band, painful if an abscess is present, should be a routine procedure when examining a lame cow.

Control. This is an accidentally produced condition which cannot be anticipated. Therefore, control measures are inappropriate. (4,11)

INTERDIGITAL DERMATITIS

Description. This is a mild bacterial infection that attacks the skin between the claws. There is no swelling or pain, merely a slight discomfort which causes the animal to paddle from foot to foot on the hind limbs. In many instances, this condition is probably part of the early stage in the development of hairy warts. As the infection spreads, the horn of the heel bulb is attacked gradually; this ulcerates and becomes increasingly sore. The black V in the picture is a common sign of early heel erosion which is often associated with interdigital dermatitis. In dairy cows interdigital dermatitis is a common cause of corns.

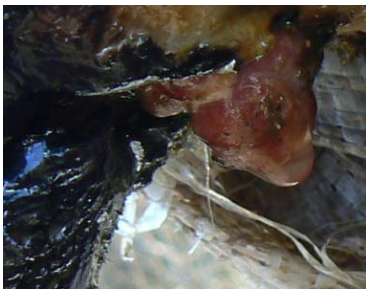

e. interdigital fic – micro-farm cow

Control. This condition is relatively easy to control with monthly foot baths using copper sulfate (5%). Preventive measures should start in the late fall and continue until the ambient temperature improves in the spring. As hairy wart disease is so widespread, using only copper sulfate would probably not be effective, unless the diagnosis of interdigital dermatitis was certain. (1, 2, 3, 4,11)

HEEL EROSION

Description. This condition starts as a pitting of the horn of the heel. The small craters join together to form areas of black, rotten horn. Erosion of the heel horn continues until the stability of the foot is compromised and the heel becomes sore. Sub-clinical laminitis may possibly be involved in one process of heel erosion. In some cross sections of the foot, hemorrhages occur in layers. This suggests that repeated insults cause episodes of sub-clinical laminitis. These layers of hemorrhage appear to end in grooves such as are present in the photograph. These grooves become subject to bacterial erosion and turn black in color.

Control. Regular use of a foot bath during the winter months is an excellent method for keeping this condition under control. Copper sulfate 7% solution or formalin 5% solution can be used on a weekly basis. More frequent use may be needed if the condition becomes severe. (9, 11)

f. Black areas of erosion at heel level - micro-farm cow

SOLE ULCER

Description. A sole ulcer is invariably located at the same site on the sole. It occurs on the inside of the outer hind claw at the junction between the sole and bulb of the heel. The claw in the photograph on the left below has an ulcer that has not penetrated to the surface of the sole. It was only exposed during claw trimming. The claw on the right below is very typical of many ulcers. Proud flesh has grown through the sole as a result

of the horn-producing tissues being destroyed by abnormal pressure on the area.

Control. Controlling the incidence of sole ulcers depends entirely on controlling sub-clinical laminitis in a herd. (5, 6, 8, 11)

RESULTS AND DISCUSSIONS

The diseases described in this issue were encountered in different growing and technological systems (household system, micro-farm, large farm).

Personal contributions have to do with:

- diseases in the bovine matrix of the households, where traumatic aspects (Street Nail), claw trimming (Claw Deformation) frequently occur,
- diseases encountered in a 250 capita matrix, in a large farm (Sole Ulcer) and,
- diseases in a micro-farm of 50 capita matrix (Heel Erosion, Claw Fracture, Coronary Band Abscess, Interdigital Dermatitis).

From a statistical point of view:

Claw Deformation is predominant in household environment: out of 750 capita matrix in year 2000, 15% presented claw deformation. The reason for having these problems is in connection to permanent stabulation correlated with breeder's lack of information. The breeder more often ignores the state of the animal's claw and does not inform the veterinarian or the podo-technician for a remedy in due time.

In micro-farms and farms there are diseases which are induced by inappropriate microclimate and hygiene conditions.

In Table Nr. 1 there is a synthesis of the frequency of diseases described in this material.

Table Nr. 1

BREEDING SYSTEM	**DISEASES**					
	Claw Deformation	*Street Nail*	*Coronary Band Abscess*	*Interdigital Dermatitis*	*Heel Erosion*	*Sole Ulcer*
POPULATION HOUSEHOLDS	15%	10%	-	-	-	0,3%
MICRO-FARM	2%	-	0,5%	1%	3%	3%
LARGE FARM	5%	-	-	2%	5%	5%

CONCLUSION:

1. In household system – podal diseases occur due to ignorance of breeder (Claw Deformation), then due to accidental causes (Street Nail).
2. In micro-farm and farm breeding systems, causes of podal diseases are connected to inappropriate microclimate and hygiene, nutritional factors and permanent stabulation.

BIBLIOGRAPHY

1. Bargai U. 1998. Digital dermatitis, interdigital dermatitis and heel erosion - Are they separate diseases? Proc 10th Int Sym Lameness Ruminants, Lucerne.
2. Basset HF, Monagan ML, Lenham P et al. 1990. Bovine digital dermatitis. Vet Rec 126: 164-165.
3. Blowey RW, Done SH, Cooley W. 1994. Observations on the pathogenesis of digital dermatitis in cattle. Vet Rec. 135. 115-117.
4. Christian B. VETAGRO International Consultants Inc. - 2005
5. Cheli R, Mortellaro CM. 1974. La dermatite digitale del bovine. Proc 8th Int Meeting on Diseases of Cattle, Milan. 208-213.
6. Enevoldsen C, Grohn YT, Thysen I. 1991. Sole ulcers in dairy cattle: associations with season, cow characteristics, disease and production. J Dairy Sci 74: 1284-1298.
7. Livesey CT. 1984-5. The etiology of laminitis and sole ulcers in dairy cows. British Cattle Veterinary Association Proceedings: 161-166.
8. Paştea E. Ortopedie veterinară, Ed. Agro-Silvică de Stat, Bucureşti, 1958.
9. Peterse DJ, Korver S, Oldenbroek JK, Talmon FP. 1984. Relationship between levels of concentrate feeding and incidence of sole ulcers in dairy cattle. Vet Rec 115: 629-630.
10. Philipot JM, Pluvinage P, Cimarosti I, Luquet F. 1990 On indicators of laminitis and heel erosion in dairy cattle: research on observation of digital lesions in the course of an ecopathological survey. Proc VI Int Symp Disorders of Ruminant Digit, Liverpool, UK: 184-198.
11. Paul R. Greenough FRCVS Bovine Laminitis and Lameness: A Hands on Approach

INSULIN DETERMINATION IN CATS WITH DIABETES MELLITUS

Luminita Diana HRIȚCU
FMV Iaşi
lumidih@yahoo.com

ABSTRACT

Diabetes mellitusis a common endocrine disease in dogs and cats. Diabetes is caused by a relative or absolute deficiency of insulin. Glucose cannot be transported from the bloodstream into the cells. Extracellular hyperglycaemia and intracellular hypoglycaemia result – therefore, diabetic animals are always hungry. Feline diabetes can be successfully and easily managed with correct diagnosis and treatment, which includes insulin therapy. Pet owners play a crucial role in the successful management of their diabetic pets. Client education and good communication between the veterinarian and pet owners are vital elements.

Keywords : insulin determination, cat, diabetes mellitus

In veterinary medicine, diabetes has been reported in all species the highest frequency of this syndrome occurring in dogs and cats.The disease is characterized by persistent and non-adjustable hyperglycaemia, caused by an absolute or relative insulin deficiency and by glucagon excess, which leads to disorders of the lipid, protidic and electrolytic metabolism. In more advanced forms of diabetes there are numerous acute and chronic complications, including hypoglycaemia, ketoacidosis, cataract, somatic and autonomic neuropathy, diabetic micro-and macroangiopathy. Due to its chronic nature (it can be treated but not cured) and serious complications, diabetes is one of the most costly diseases, if we refer to the cost of medical care for each patient. Certainly not all cats with diabetes need insulin therapy (some respond positively to changes in diet or administration of glizipide), but when blood sugar levels are over 280-300 mg / dL, it must be applied. The goal of the treatment is to address signs of disease, maintain proper body weight and provide the patient with a better quality of life. This can be achieved by attempting to maintain acceptable blood glucose level (100 -250 mg / dL). In addition to the treatment applied for the reduction of blood glucose it is recommended to treat any other concomitant diseases, such as exocrine pancreatic insufficiency, hyperthyroidism, Cushing's disease and infection.

MATERIALS AND METHODS

The study was conducted on a total of 15 cases, monitored for a period of two years at the Department of Medical Pathology of the Faculty of Veterinary Science and at *Teovet* private veterinary practice in Iasi. In all cases, the same device was used for determining Accu-Chek Activ II blood glucose and two types of human insulin ACTRAPID and MIXTARD ACTRAPID 30. Because the blood collection sessions were very frequent blood samples were collected from the saphenous vein using insulin syringes with atraumatic needle to produce as little damage to the vein as possible.

At the time of diagnosis the owners were informed on the importance of maintaining continuity for accurate dosing, observing all signs after the first administration, home monitoring to avoid hypoglycaemia and maintaining an appropriate diet.

RESULTS AND DISCUSSION

For the close monitoring of each diabetic animal, a medical observation chart was adapted. The chart contains the name of the owner, species of animal, as well as breed, weight, age, sex, first blood sugar level. The comments column is filled in with changes of the biochemical tests, or with complications specific to diabetes (cataracts, neuropathy, etc.). Also, notes are made if the animal receives other drugs besides insulin, etc..There are records containing the date of each dosage, type of insulin used, animal weight (weekly) and amount of insulin administered in the morning (D) and evening (S). Since there is no clear insulin dosage and each animal reacts differently to insulin administration, the treatment was initiated with the dose suggested by Prof. Ghergariu in his studies, that is of 2 IU / kg, but the first blood sugar level was also taken into consideration. The most frequently administered type of insulin was MIXTARD 30 which is an identical substitute of the insulin produced by the pancreas. The human insulin (rDNA), which is the active substance in Mixtard, is produced by a method known as "recombinant technology". Insulin is produced by an yeast that has received a gene (DNA) capable of producing insulin. Mixtard 30 contains insulin in two forms: soluble form (30%) which works faster (up to 30 minutes after injection) and "isophane" form, which is absorbed slower during the day (70%). This product gives Mixtard 30 a longer action period. Insulin substitute acts the same way as naturally produced insulin, helping blood glucose to reach cells. By controlling blood sugar, symptoms and complications of diabetes are reduced.
Thus, if the first blood sugar level was between 250 and 350 mg / dl, the recommended initial dosage was 1UI/kg and if the first blood sugar level was 350 mg / dl (or up to 600 mg / dl or higher) the recommended starting dose was 2 IU / kg. If the animal's glycaemia is over 500 mg / dl and it presents a visible deterioration of its general condition, or even a diabetic acidosis, Actrapid insulin was administered (1-2 IU / kg). Note that Actrapid insulin was used only in urgent cases (with exaggerated glycaemia levels) because is much faster, even brutal and

hypoglycaemia may occur; glucose is reduced for a few hours and the next day normal doses must be administered. Mixtard 30 insulin was administered strictly subcutaneously while Actrapid insulin, in addition to regular subcutaneous administration in cats with diabetic ketoacidosis that also needed glucose administration, was administered intravenously. For all animals in the study a daily schedule of administration was established: in the morning between 7 and 8 am and in the evening evening between 7 and 8 pm. The animals were fed within 30 minutes after insulin administration., to avoid hypoglycaemia and all its characteristic signs.

The daily dose was adjusted in accordance with the animal's response. Glucose dosage is performed daily for 1-2 weeks, then every other day for the next week, every 3 or 4 days the following week, then on a weekly and bimonthly basis and finally the animal is being monitored every month or even at larger intervals. Dosage determination usually takes between two and seven weeks. It was observed that cats have an extreme variability in their response to insulin. This was due to several factors such as stress hyperglycemia (when the animal was kept for a longer period of time in the medical consultation room), sometimes the amount of insulin administered is so small that the owners they measure the wrong quantities, the selective appetite of cats make their need for insulin sometimes vary from day to day, development in this species of a transient diabetes, which may last for only a few months, with spontaneous remission, the patient seeming to be "cured" , but the disease sometimes returns several months later (in some cats). On the other hand, obese diabetic cats, when returning to their normal weight, can lose that extra insulin need, therefore some of them are no longer following the insulin treatment, while others follow the glizipide therapy. In some cases an apparent insulin resistance was observed. This may occur when glucose levels can not be adjusted, even if the dose reaches 4 IU / kg bodyweight. The causes of this resistance may be: improper administration of insulin (inappropriate type of insulin, incorrect measurement of insulin, errors of administration, etc.), modification of the program or type of food (to much food at animal's disposal, or food rich in carbohydrates or fat) or Somogyi effect (too much insulin greatly lowers the blood glucose level, which sometimes stimulates production of other hormones in the body, such as epinephrine, which in turn promotes the production of glycogen, which will ultimately produce increased levels of blood glucose). In other cases, a real resistance to insulin was noted, maybe due to interference of various drugs (long-term administration of corticosteroids), poor absorption of insulin (even properly administered insulin is not well reabsorbed from the administration site), other infectious diseases, ketoacidosis, pancreatitis, liver disease (hepatic lipidosis), renal failure, various hormonal disorders (Cushing's disease, hyperthyroidism, acromegaly), obesity, or even the production of anti-insulin antibodies (insulin or other ingredients added while manufacturing insulin can be considered as "foreign" by the animal's body, which may produce antibodies to destroy them.

In order to determine the response to insulin therapy several factors were taken into consideration, such as water intake, frequency, amount of daily urine and appetite. Some signs of hypoglycaemia were observed, such as lethargy, depression, weakness, convulsions and coma. Mention must be made of the fact that hyperglycaemia is always better than hypoglycaemia.

CONCLUSIONS

1. Dosage for insulin therapy with Mixtard 30 lasts between 2 and 7 weeks and it is administered daily, then weekly, bimonthly and monthly.

2. Insulin is usually administered twice a day, every day, in accordance with a predefined schedule and most of the times throughout the entire life of the animal. Feeding is recommended after each administration in order to avoid hypoglycaemia.
3. Insulin dosage should be adjusted whenever necessary, the owner playing a significant part in observing signs that indicate the high or low levels of blood sugar. He should also be trained by the veterinarian to be able to handle situations of severe hypoglycaemia.
4. Insulin therapy must be accompanied by treatments for any other diseases that the animal may have, especially infections.
5. Successful management of insulin therapy in cats with diabetes requires dedication and a close communication between owner and veterinarian.

REFERENCES

1. **Ghergariu S** – Bazele patologie animalelor Ed ALL, Bucureşti, 1994
2. **Ghergariu S** – Patologia nutriţională şi metabolică a animalelor. Editura Medicală Veterinară Bucureşti – 1995
3. **Mihai D** – Boli de nutriţie şi metabolism – Ed CERES Bucureşti – 1996
4. **Pârvu Gh**. – Boli de nutriţie şi metabolism la animale – Ed. Fundaţiei „România de mâine” Bucureşti – 1999.

NEBULISATION - COMPLEMENTARY THERAPY FOR RESPIRATORY DISEASES IN CATS

Luminita Diana Hrițcu
FMV Iaşi
lumidih@yahoo.com

ABSTRACT

Nebulisers are primarily used to decongest respiratory mucous membranes in cases of pneumonia and chronic asthma. They are often used to administer steroids, antibiotics and other medications. Some animals prefer one type of nebuliser to another, and may be more relaxed during treatment if such accommodations are made. In alternative medicine, they are also used to administer herbal treatments with various substances such as eucalyptus oil. Due to their versatility, they can be used to administer a variety of medications and treat a wide range of conditions.

Keywords : nebulisation , therapy, cat

Nebulisation is mainly used for mucous decongestion in cases of pneumonia and chronic asthma. Aerosol therapy is often used to administer steroids, antibiotics or other drugs. Not all animals can get used to a certain type of nebuliser. Some tolerate nebulisation masks more easily, while others can only be treated in nebulisation chambers. It should be noted that in alternative medicine, the nebulisers are also used to administer herbal substances such as eucalyptus oil and others. Due to their versatility, the nebulisers can be used to administer a variety of drugs and to treat various diseases from sinusitis and rhinitis to chronic bronchopneumonia. Aerosol therapy was used more frequently in cats with pneumonia to help decrease viscosity and improve mucociliar secretion clearance. During the last years, an increased frequency of respiratory diseases in cats and even an increase in respiratory disease recurrence was noticed in this species, expressed by a greater sensitivity to environmental temperature change. The present study attempts to improve the therapeutic protocol established for respiratory diseases by means of aerosol therapy (nebulisation).

Table.no. 1

The incidence of respiratory diseases in cats between 2009 and 2010

	Total number of cases in cats	Respiratory diseases	Other problems
No.	721	212	509
%	100	29.40	70.59

Materials and methods

The study was conducted over a period of one year, between April 2009 and April 2010, at ***Teovet*** private veterinary practice in Iasi. The device used for the study was a human ultrasonic nebulisation device (LAICA), with a children's mask or a nebulisation chamber made by us.

Nebulisation was performed in two different ways:

1. By placing the nebulisation mask very close to the patient face
2. By placing the patient in the nebulisation chamber.

The solution of the aerosol therapy contained simple saline solution or mixed substances which had in addition a broad-spectrum antibiotic, an anti-inflammatory substance, secretion fluidisers, bronchodilators, volatile oils or antifungal substances, in accordance to each case.

RESULTS AND DISCUSSION

Mention must be made of the fact that the nebulisation method was used as complementary therapy in resolving cases with complications or frequent recurrences of respiratory diseases. Cats with such respiratory diseases have initially been treated according to therapeutic protocols that are normally applied in cases of respiratory diseases: they were administered anti-inflammatory solutions, antipyretic substances, common antibiotics, bronchodilators, antitussives or mucolytic drugs, or intravenous lines with solutions that rehydrated or had electrolytic rebalance effects, if such was the case.

Table no. 2
The incidence of feline respiratory casuistry between 2009 and 2010

	Total number of respiratory diseases	Rhinitis, sinusitis, laryngitis	Bronchopneumonia	Asthmatic bronchitis	Pulmonary edema	Recurrences of respiratory diseases
Nr.	212	132	24	15	8	33
%	100	62.26	11.32	7.07	3.77	15.56
Of which, taken in the study:						
Nr.	29	3	4	8	4	10
%	100	10.34	13.79	27.58	13.79	34.48

Nebulisation was applied to cases requiring treatment for more than 3-5 days, in animals with frequent relapses (monthly), in some cases with asthmatic bronchitis and in four cases of pulmonary edema.

Thus, the study consisted of: two cases of rhinitis + laryngitis, one case of sinusitis, four cases of bronchopneumonia, eight cases of asthmatic bronchitis, four cases of pulmonary edema and 10 cases of frequent recurrences.

The device used for nebulisation is capable of producing particles with sizes ranging from 0.5 to 3.0 mm in diameter. These particles are able to distally deposit themselves in the airways of patients.

In the cases of the cats who have not tolerated nebulisation masks, in order for them not to be brutalized, a nebulisation room was created in an air-tight box, with a capacity of 50l, to which the nebulisation tube was adapted.

The simple solution for Aerosol therapy was represented by saline solution in all cases. In addition, depending on the seriousness of the situation, acetylcysteine or antibiotics (usually gentamicin) were added. In other cases of asthmatic bronchitis, bronchodilators (miofilin, theophylline) were used for relaxing the smooth muscle of the airways or an anti-inflammatory (inhalation) and in three cases that initially responded positively to treatment besides serum mixtures, bronchodilators, anti-inflammatory solutions and antibiotic an antimycotic was added (fluconazole). After fluconazole administration, the general condition of the animal improved markedly. Solutions were prepared in order to be used during the 10 meetings. Thus, in order to prepare a 50 ml complex aerosol therapy solution, 2 ml gentamycin (80 mg) were mixed with 5 ml ACC + 2 ml dexamethasone + 3 ml diflucan + 38 ml saline solution. The process lasted for 8-10 minutes and was repeated once or twice daily for 8-10 days per month. After aerosol therapy sessions, the blending method was performed as physiotherapy. Blending was done by tapping into the strong lateral rib (clap) jerkily, with the hand in the form of a cup, making moderate exercises for 5-10 minutes. This procedure was used to facilitate clearance of lower airways secretions. it was noted that all three cases of rhinitis + laryngitis and sinusitis, to which a simple solution with anti-inflammatory substances, antibiotic and saline solution was added, responded well to therapy even after the first administration of nebulisation solution, and a full recovery was noted after the 4th session. Mention must be made of the fact that in all three cases there was one daily session during eight days. In the four cases of bronchopneumonia, due to gravity of the situation, the solution of the aerosol therapy included a bronchodilator (miofilin), in addition to antibiotics and anti-inflammatory substances, for airway smooth muscle relaxation and a mucolytic (acetylcysteine) in order to reduce secretions that were already increasing in quantity. In three of the four cases, the general situation improved after 4-5 sessions, and the nebulisation therapy was extended up to 10 sessions. In the 4th case, the medical history showed that the cat had lived in unsanitary conditions (in a humid room with walls covered in mould), so the solution was completed with an antimycotic (fluconazole). After the addition of fluconazole,

an improvement was observed in the general condition of the animal and in his respiratory capacity, even after the third session with antimycotics. In this case, there were 10 monthly sessions during a period of three months. In the cases of pulmonary edema, nebulisation was used even from the first day of treatment, in parallel with therapeutic protocol applied in such situations. The nebulisation solution was a mixture of anti-inflammatory drugs, antibiotics, bronchodilators and mucolytics, to which an eucalyptol inhaler was added to allow easy breathing and to calm the animal. Comparing the cases where nebulisation was applied with those where this complementary therapy procedure could not be used due to various reasons, it was discovered that recovery was much improved. In two of the other cases the animals died, while those who survived remained with sequelae. It should be noted that in all four cases the blending method was applied after each nebulisation session, in order to facilitate secretion elimination. In the 10 cases with frequent relapses taken in to account in the study, nebulisation therapy was applied on a monthly basis, for 3-5 months: two therapy sessions each day during the first month and one daily session in the coming months for 10 days, and the owners of three of the patients decided to purchase the device and continue aerosol therapy at home. Out of the 29 cases that were studied, 10 were treated with the aerosol therapy chamber created by us. It has been used on very stressed animals in order to reduce anxiety that was hindering breathing. In this case, the treatment consisted of two consecutive sessions of five minutes each, to avoid overheating the animal.

CONCLUSIONS

1. The incidence of respiratory diseases in the period April 2009 - April 2010 was of 29.40%.
   Nebulisation therapy can be used complementary in all respiratory diseases, with encouraging results.
2. Nebulisation solutions are created in accordance with the type and severity of each treated disease.
3. When the patient does not tolerate aerosol therapy masks, aerosol therapy chamber should be used, but with precaution, in order to avoid overheating the animal.
4. After nebulisation, the blending method is recommended on each thoracic half for 5 minutes, to facilitate clearance of secretions from lower respiratory airways.

REFERENCES

1. **Ghergariu S** – Bazele patologie animalelor Ed ALL, Bucureşti, 1994
2. **Solcan Gh., Boghian V., Rollin F.** – Patologie şi clinică medicală veterinară, Ed Ion Ionescu de la Brad Iaşi, 2005.
3. The merk veterinary manual – eight edition - 1998

PERCUTANEOUS NORMOGRADE INTRAMEDULLARY PINNING OF FELINE FEMUR FRACTURES

C. IGNA , Larisa SCHUSZLER, Roxana DASCĂLU, M. SABĂU, C. LUCA
Faculty of Veterinary Medicine Timişoara,
Calea Aradului, no. 191, code 300645, Timişoara,
ignacornel@gmail.com

ABSTRACT

This study evaluated the closed anatomic reduction and surgical stabilization by percutaneus normograde intramedullary pinning, with intraoperative fluoroscopic guidance, of mid-diaphyseal fractures of the feline femur. Medical records of cats with unilateral of mid-diaphyseal femoral close fractures (treatment by percutaneus normograde intramedullary pinning), evaluated from 2002 to 2009, were registered twelve cats. Age and weight of cats at the time of surgery; breed; sex; concurrent injuries; severity of lameness before and 1, 2, 4, 6, and 8 weeks after surgery, x-ray fracture healing exams, and complications after surgery were evaluated. Under radioscopic control, the closed anatomic reduction and surgical stabilization by percutaneus normograde intramedullary pinning (Steinmann pins) of mid-diaphyseal femur fractures in cats offer the successful clinical results. Variable (6-8 weeks) healing rates based on primarily endosteal callus formation were identified in all cases. Results suggested that surgical stabilization follow a biological fracture approach (absence or minimum periosseous dissection around the fractures to preserve vascularity and reduce the risks of infection and bone sequestration) and represent a feasible method of biological fracture fixation.

Keywords femoral, fracture, cats, diaphyseal, intramedullary normograde insertion, intraoperative fluoroscopic guidance

Femoral fractures are common in cats, accounting for 20% to 26% off all fractures. Most femur fractures are closed, because of the heavy overlying muscles (1, 2, 11).

The repair process during fracture healing is dependent on an adequate blood supply. The major blood supply of normal circulation to the diaphyseal region of the femur consists of an afferent supply from the principal nutrient artery, entering the bone at the nutrient foramen located at the caudal part aspect of the proximal third of the diaphysis. The adductor muscle attachment to the caudal aspect of the diaphysis is also an important source of periosteal vessels. This becomes especially significant in the healing of diaphyseal fractures because medullary circulation is disrupted in most long bone fractures (8). Femur fractures are generally not amenable to conservative repair, and some kind of internal fixation is generally required. Implant systems suitable for repair of femur fractures include bone plates, interlocking nails, plate-rod construct, lag screws, pins and wires and external fixators. Fractures may be repaired using anatomic reduction and rigid fixation or using the principles of biologic osteosynthesis (1, 13).

Biological osteosynthesis involves minimally invasive surgical approaches, minimal handling of the bone fragments and indirect reduction. Biological osteosynthesis is particularly effective for highly comminuted and complex fractures because no attempt is made to reduce fragments within the fracture zone. Because of this, vascular supply and soft tissue attachments to bone fragments are preserved, allowing faster fragment incorporation into callus, resulting in a rapid healing (1, 6).

Biological osteosynthesis provides clinical advantages over anatomic reconstruction. It has been associated with faster callus formation and reduced healing time, low infection rates, decreased blood loss, reduction in surgical time and development of fewer complications, including decreased rate of non-union (13).
Based on these considerations, which pointing that the preservation of hard and soft tissue integrity along with utilization of stable implants are the keys for reduction of patient morbidity and a return to function, we proposed in this study to evaluate the closed anatomic reduction and surgical stabilization by percutaneous normograde intramedullary pinning, with intraoperative fluoroscopic guidance, of mid-diaphyseal close fractures of the feline femur.

MATERIALS AND METHODS

Medical records and radiographs of femoral fractures in cats, treated at the Surgery clinic of the Faculty of Veterinary Medicine Timisoara, in the period 2005-2009 were reviewed. Only patients with recent (fewer than 24 hours) closed fractures, localized unilateral of the femoral diaphysis were used in this study. Femoral fractures are closed transverse, short oblique, and minimally comminuted. Severity of lameness were evaluated before and 1, 2, 4, 6, and 8 weeks after surgery. For assessing functional disorders when the animal is walking it were used a scale with five levels 0-4 – table 1. Pain sensibility at palpation and the healing of incision site were assessed. For verifying osseous healing it was used cranio-caudal and medio-lateral incidence of the interested aria.

Table 1

Lameness degree assessing scale

Degree	Description
0	Normal attitude in station and in walking – without lameness
1	In walking difficulties, especially at rapid carriage – fine lameness
2	In walking difficulties, intermittent lameness in rapid walking
3	Evident lameness at every step, pain
4	The leg pull out of support in station and in walking, intense pain

The cats were sedated with medetomidine 0,10-0,15 mg/kg bodyweight. Propofol 1-2 mg/kg bodyweight was used for the induction. Maintenance of anesthesia was performed by isoflurane 0,5-0,9 MAC with oxygen in combination with continuous intravenous supplementation of ketamine 2-5 µg/kg bodyweight. Postoperative cats received buprenorfine 20 µg/kg bodyweight for additional analgesia. The surgeries are done by a minimally invasive procedure. Anatomical reduction and surgical fixation were performed with fluoroscopic guidance.
Anatomical reduction by manual traction allowed aligns the bone fragments and provide some stability. In one case the traction devices (distal transfixation pin) are temporarily applied along the long axis of the bone. Surgical fixation was realized by percutaneous insertion of the positive profile threaded Steinmann pins. The Steinmann pins are inserted through skin stab incisions with low-speed power equipment and static fixation was performed in all cases The entrance site for an anterograde femoral pinning is created in the subtrochanteric fossa The medullary canal was initially opened by inserting a series of Steinmann pins (trocar point) of increasing diameter in succession. An attempt was made to seat the pin in metaphyseal cancellous bone, but precautions were taken to prevent penetrating the articular surface. Proximally, the end of the pin did not protrude dorsal to the greater trochanter. Rotational alignment and axial length were checked up. Post-operative care. Antibacterial treatment consisted of 7-14 days of amoxicillin-clavulanic acid 12,5 mg/kg bodyweight 2dd. Surgical and healing time and complication rates were evaluated. Fracture healing was controlled by clinic and x-ray exams. Radiographs were obtained every two

weeks (2-12 weeks) after surgery. For determination of union we looked at the presence of bridging callus and a narrowing fracture line on the radiograph. In according with T. Könning et al (8) we classified union in 5 union classes. <50 days = 1, 50<100 days = 2, 100<150 days = 3, 150<200 days = 4 and non-union / implant failure = 5.

RESULTS AND DISCUSSIONS

In the period 2005-2009, at the Surgery clinic of the Faculty of Veterinary Medicine Timisoara, were treated 118 cats with different fractures. Thereby 26 fractures were located of the femur. In this study were included 12 cats with recent (fewer than 24 hours) close fractures, localized unilateral of the femoral diaphysis. Femoral fractures are closed (n=12) transverse (n=5), short oblique (n=4), and minimally comminuted (n=3).

The femur fractures of 12 cats belonging the mix breed (n=8), Siamese (n=2), Birman (n=1), and Persian (n=1). Eight of cats were female. The average age was 18 months. Four cats were younger than 12 months, two cats were between 12 and 60 months, five cats were between 60 and 120 months and one cat were older than 120 months. The average weight was 3.9 kg (range, 0.9 to 6.3 kg). According to history, fall from height and vehicle crash was determined as the major cause of the fractures. Before surgery the lameness score was 4 for all cases. Median surgical times were 43 minutes. The results of this study indicate that the 4.0 and 5.0 mm Steinmann pins can be used to repair simple or minimally comminuted femoral fractures in cats. The medullary canal filling was 85-100% in both radiographic views in all cases. The average length of the femoral Steinmann pins was 98.2 mm. The clinical outcomes, as well as fracture healing, were excellent in all of the cases. In the time healing average lameness score was 2 after two weeks, 1 after three weeks and 0 after four weeks. In the cats of fractures treated by the closed anatomic reduction and surgical stabilization by percutaneous normograde intramedullary pinning, with intraoperative fluoroscopic guidance no showed surgical complications and no osteomyelitis occurred. Median healing times were five weeks. Of the femoral fractures repaired with normograde intramedullary pinning ten cats (83%) were in union class 1 and two cats (17%) were in union class 2. Hundred percent reached union. Our clinical outcomes dates are comparable with results reported by more researchers (3, 4, 6, 10) after interlocking nail treatment of long-bone fractures in cats. Larin et al – 2001 (9) apreciate that the use of the interlocking nail has been limited in cats because of the small diameter of the medullary canal. Recognized disadvantages of intramedullary pinning - the pin as has a poor resistance to axial and rotational loads (5, 7, 10, 11, 12) and their subsequent complications (delayed union, pin migration, nonunion fracture collapse) has been prevent in our stabilization method by improved fixation of the positive profile threaded Steinmann pins in the cancellous bone of the distal metaphysis. Selection of fixation method by percutaneous normograde intramedullary pinning is was based on the age, weight and fracture characteristics. Young cats with bodyweight fewer than 5 kg and recent closed femoral fractures with minimally comminuted should be considered candidates for this alternative technique.

CONCLUSIONS

Closed reduction and percutaneous normograde insertion an intramedullary pins with intraoperative fluoroscopic guidance of cats femur fractures, is safe, inexpensive and successful treatment method and basic principles of biological osteosynthesis are respected.

Methods described should be considered as alternative technique for management of selected diaphyseal fractures of the femur in cats.

Acknowledgments This work was supported by CNCSIS – UEFISCSU, project number PNII – IDEI 130/2008

REFERENCES

1. **Beale, B.**, Orthopedic clinical techniques femur fracture repair. Clin Tech Small Anim Pract., 2004, 19 (3), 134-150.
2. **Brinker WO, Piermattei DL, Flo GL.** Fractures of the femur and patella. In: Handbook of small animal Clinical orthopedics and fracture treatment. Brinker WO, Piermattei DL, Flo GL (eds). Philadelphia: WB Saugers 1983; 75.
3. **Díaz-Bertrana MC, Durall I, Puchol JL, Sánchez A, Franch J.** Interlocking nail treatment of long-bone fractures in cats: 33 cases (1995-2004). Vet Comp Orthop Traumatol. 2005;18(3):119-26.
4. **Duhautois B.** Use of veterinary interlocking nails for diaphyseal fractures in dogs and cats: 121 cases. Vet Surg. 2003 Jan-Feb;32(1):8-20.
5. **Harari J.** Treatments for feline long bone fractures. Vet Clin North Am Small Anim Pract. 2002 Jul;32(4):927-47.
6. **Horstman CL, Beale BS, Conzemius MG, Evans R R.** Biological osteosynthesis versus traditional anatomic reconstruction of 20 long-bone fractures using an interlocking nail: 1994-2001. Vet Surg. 2004 May-Jun;33(3):232-7.
7. **Johnson AL.** Fracture fixation systems. In: Small animal surgery. Fossum TW, Hedlund CS, Johnson AL, et al (eds.) Mosby 2007; 967-1002.
8. **Könning T., Maarschalkerweerd R.J., Endenburg N., Theyse L.F.H.** A comparison between fixation methods of femoral diaphyseal fractures in cats - A retrospective study on 106 cases (1997-2008) http://www.docstoc.com/docs/22617608/
9. **Larin A, Eich CS, Parker RB, Stubbs WP.** Repair of diaphyseal femoral fractures in cats using interlocking intramedullary nails: 12 cases (1996-2000). J Am Vet Med Assoc. 2001 Oct 15;219(8):1098-104
10. **McLaughlin R.** Internal fixation. Intramedullary pins, cerclage wires, and interlocking nails. Vet Clin North Am Small Anim Pract. 1999 Sep;29(5):1097-116.
11. **Milton JL, Newman ME.** Fractures of the femur. In: Textbook of small animal surgery. Slatter DH (ed). Philadelphia: WB Saugers 1985; 2180
12. **Schrader SC.** Complications associated with the use of Steinmann intramedullary pins and cerclage wires for fixation of long-bone fractures. Vet Clin North Am Small Anim Pract. 1991 Jul;21(4):687-703.
13. **Stiffler K.S.**, Internal fracture fixation, Clin Tech Small Anim Pract., 2004, 19 (3), 105-13.

OSTEOGENESIS CAPACITY OF FREE VASCULARIZED CORTICOPERIOSTEAL FLAP IN DOGS

C.IGNA , C. LUCA, Roxana DASCĂLU, Larisa SCHUSZLER, M. SABĂU
Faculty of Veterinary Medicine Timişoara,
Calea Aradului, no. 191, code 300645, Timişoara,
ignacornel@gmail.com

ABSTRACT

In this study we have investigated the capacity of free vascularized corticoperiosteal flaps to generate heterotopic neo-osteogenesis. On eight common breed dogs, heterotopic transplantation of some tibial corticoperiosteal flaps was realized into the popliteus muscle. Transplantation was made under continuous radioscopy after the intraoperatory administration of a contrast substance (Ultravist) injected in the saphenous artery. The cranial tibial artery branching from the popliteal artery provides vascular perfusion to the medial tibial corticoperiosteal flap. The postoperatory surveillance of the dogs was made by daily clinical examination for 63 days. The X-ray evaluation of the osteogenic potential of the corticoperiosteal flaps was performed by digital radioscopy at 7 day intervals for ten weeks. At the end of this time interval, biological samples were obtained for histological examination by classical microscopy and by fluorescent microscopy methods. On all individuals the radioscopic exam revealed the presence of the corticoperiosteal flaps which maintained their position and radiographic density until 21 days. On radioscopic investigations performed after 21 days, a reduced radiodensity of the bone flaps was observed in all the subjects of the group, followed by accentuated mineral losing in the next 35-63 days. The histological exam of corticoperiosteal flap tissue revealed the osteons presence, the specifically compact bone architecture and the presence of large empty spaces without cells. All these aspects corroborated with image observations correspond to a degenerative process of detached compact bone even in conditions of vascularisation and periosteal continuity maintaining. The presence of the fluorochromes indicates the location, time and amount of bone deposition. At the evaluation of the osseous tissue formed in the defect area (from where a corticoperiosteal fragment was detached) intense osseous growing activity inside the calcificated area was observed. The exam of the sample of corticoperiosteal fragment revealed a low bone growing activity and also a diffuse calcification of the examined tissue confirming the imagistic observations regarding the decreased radiodensity of detached bone fragment.

Keywords*:* dog, free vascularized corticoperiosteal flap, osteogenesis

Periosteum's role in fracture healing is widely recognized, and its function in bone tissue engineering shows great potential (21, 22, 23). The idea of using vascularized periosteal flaps in reconstructing bone defects is more than one hundred years old (16). Up to now, experimental and clinical results regarding their osteogenic capacity have been a subject of debate. The role of vascularized periosteum flap as a graft and the factors stimulating it into osteogenic activity remain obscure.

In rats, the studies of ectopic bone formation in the groin and orthotopic bone formation in the femoral defect demonstrates that optimal bone formation requires four factors: bone morphogenetic protein (rh-BMP-2), a biodegradable matrix, osteoprogenitor cells, and blood supply (7, 8, 20, 21).

Few articles recognized its osteogenic process without the dependence of stress stimulation or bony contact. (2). Experimental study on rabbits reported that vascularized periosteal flaps presented strong osteogenic capacity in heterotopic conditions (2, 3, 10, 14).

The information above was the basis of our investigations in this study, in which we aimed to evaluate the osteogenic capacity of free vascularized corticoperiosteal flaps in the other species (canine).

MATERIALS AND METHODS

The study was made on eight dogs, commune breed, both sexes, aged between 2 and 5 years and body weight between 16 and 32 kg, on which, under general anaesthesia (acepromazine – ketamine – propofol - izofluran), heterotopic transplantation of some tibial corticoperiosteal flaps vascularized by tibial anterior artery into the popliteal muscle was realized. The surgical approach on the tibial medial proximal surface was classic, medial (12). The integrity of the vascular supply of the medial aspect of the tibia during the operation times was verified using the fluoroscopy control with intrarterial injection (saphenous artery) of the contrast substance (Ultravist - Schering A.G). By lift-off techniques from the bone surface, the elevation of the corticoperiosteal flap by 3/5 cm was successful, maintaining the continuity of periosteum with the medial bone surface. The vascularised flaps were handled through a muscular tunnel, in the popliteal and were placed at 2 cm caudal to the tibial proximal third.

The subjects were monitorised intraoperatory by a standard protocol which included the measure at fixed time intervals (5 minutes), of the blood pressures (systolic, diastolic and average), the oxygen saturation of hemoglobin, the heart rate, the pulse rate and the respiratory rate.

After the intervention, the analgesia was assured using Butorfanol 0.25 mg/kg b.w. administrated every 4 hours in the first 12 hours postsurgery.

The postoperatory surveillance of the dogs was made by daily clinical examination for 63 days. The X-ray evaluation of the osteogenic potential of the corticoperiosteal flaps was performed by digital radioscopy at 7 day intervals (0, 7, 14, 21, 28, 35, 42, 49, 56, 63 days) for ten weeks. It was followed by the existence, formation, emplacement and radiodensity of the transplant.

For histological postoperative evaluation of the osteogenesis process fluorochromes (4) were injected following the protocol below:

- 0.25 mg/kg tetracycline s.c. (in the first day of postoperative surveillance period);
- 0.25 mg/kg red alizarin s.c. (in 21st day of postoperative surveillance period);
- 0.25 mg/kg calceine s.c. (in 25th day of postoperative surveillance period);
- 0.25 mg/kg tetracycline s.c. (in 56th day of postoperative surveillance period).

At the end of this time interval, the subjects were submitted to a new surgical intervention meant for biological sample obtaining (normal bone fragment in the third middle tibial diafisis, bone fragment from the place of corticoperiosteal flap sample, and fragment from the corticoperiosteal transplanted flap) for histological examination by classical microscopy and by fluorescent microscopy methods.

Sample processing (undecalcified bone) was prepared for histology, histomorphometry and fluorochrome analysis (of the multiple fluorochrome labels) after the protocol described by Igna C. et al (5). The samples examined by classical microscopy were stained with haematoxylin-eosin.

RESULTS AND DISCUSSIONS

The postoperatory clinical observations in the all dogs revealed data which are similar to the ones reported after minor orthopaedic interventions. All the subjects presented discreet lameness for 1-3 days. All the subjects had unchanged behaviour in the rest of the observation period. Healing of the skin wounds occurred in 7–10 days.

The cranial tibial artery branching from the popliteal artery provides vascular perfusion (9) to the medial tibial corticoperiosteal flap. Bone radiographic evaluations were consistent with viable bone in all the vascularized corticoperiosteal flaps. In the donor site, evidence of the healing bone was observed after 21 days.

Histological examination did not reveal the existence of any necrotic bone in none of the corticoperiosteal flaps.

On all individuals the radioscopic exam revealed the presence of the corticoperiosteal flaps which maintained their position and radiographic density until 21 days. It was not concluded any radiodensity change of the surrounding tissues including the assumed projection area of the flap.

On radioscopic investigations made after 21 days, a reduced radiodensity of the bone flaps was observed in all the subjects of the group, followed by accentuated mineral losing in the next 35-63 days – fig 1.

a) intraoperatory

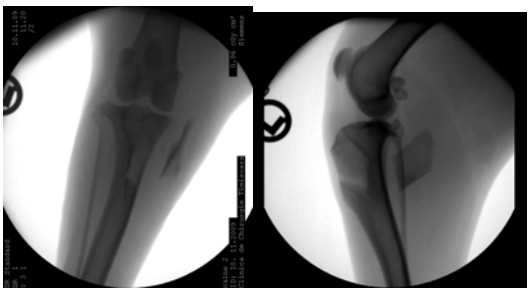

b) postoperatory

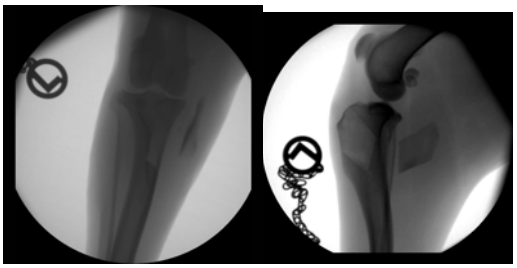

c) 7 days

d) 14 days

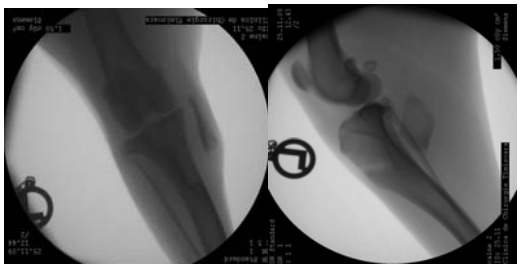

e) 21 days

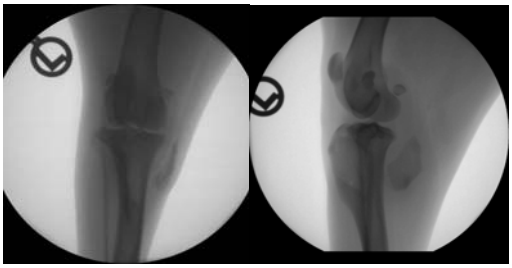

f) 42 days

g) 56 days

h) 63 days

Fig. 1. Cranio-caudal and medio-lateral radiographic views showing the proximomedial corticoperiosteal tibial flap and their evolution in the postoperatory intervals (1-63 days). There was evidence of radiographic accentuate radiodensity losing of the flap after 21 days.

At the classic histological exam of normal bone tissue (fig. 2.a) the specifically compact bone architecture can be observed, the interoseous space being reduced and boarded by Haversian and communication channels. The examination of the tissue from the healing place (fig. 2.b) indicates the presence of rare osteons and the specific features of conjunctive tissue. The observed aspects are characteristic for developing a fibrous callus. The histological exam of corticoperiosteal flap tissue (fig.2.c) revealed the osteons presence, the specifically compact bone architecture and the presence of large empty spaces without cells. All these aspects corroborated with image observations correspond to a degenerative process of detached compact bone even in conditions of vascularisation and periosteal continuity maintaining.

Fig. 2. Classical microscopic image (Haematoxylin and eosin x 10). a) normal pattern in the bone tissue; b) bone tissue inside of the healing focus; c) bone tissue from detached bone

The presence of the fluorochromes indicates the location, time and amount of bone deposition, and enhances the information contained in bone specimens (13).

The exam made with fluorescence microscope showed that the tetracycline was fixed on the growth areas of bone cells represented by green colour. Calcein is a fluorescent-imino-diacetic acid complex which fluoresces bright green when combined with calcium. It is easily distinguished from tetracycline which fluoresces yellow. Alizarin Red indicates the calcium deposits except the oxalates, represented by red-orange colour. Both alizarin red and calcein were fixed in calcificated areas of bone tissue.

The exam of healthy bone tissue (fig. 3) reveal the calcification of the periosteal adjacent zone and the presence of growth bone activity adjacent to the calcification area, which correspond with width growing of the bone (17, 18). At the evaluation of the osseous tissue formed in the defect area (from where a corticoperiosteal fragment was detached) it was observed the presence of intense osseous growing activity inside the calcificated area (fig. 4), results which are similar with those reported by Takeuchi et al (19). The exam of the sample of corticoperiosteal fragment revealed a low growing bone activity and also a diffuse calcification of the examined tissue (fig. 5). Howship's lacunae are labeled with different colors. All these data confirm the imagistic observations regarding the decreased radiodensity of detached bone fragment.

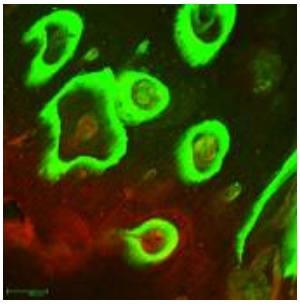

Fig.3. Fluorescence image healthy bone tissue

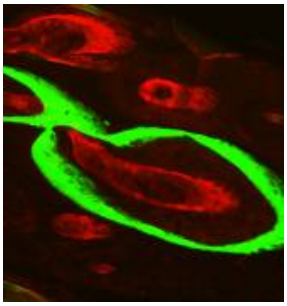

Fig.4. Fluorescence image osseous tissue from defect area

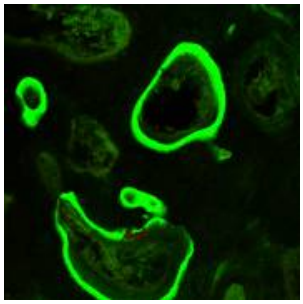

Fig.5. Fluorescence image corticoperiosteal flap

The results obtained in this study contradict with the data from literature which mention that periosteal flaps that include a bone fragment and have vascular support can generate bone tissue at the implantation site in the human patients (1, 6, 11, 15). In some experimental cases, the transplants were in contact with deficiency areas of bone substratum – maxilla, mandible, tibia, iliac spine. The contradiction is relative, our study investigating the heterotopic transplantation (muscular).

Other results that show osteogenic potential of ectopic transplanted periosteal flaps were reported by Vogelin et al., 2000 and 2002, in studies on rats that include the following conditions (factors) for optimal bone formation: osteoinductive bone morphogenetic protein (BMP), a biodegradable matrix, osteoprogenitor cells, and blood supply (20, 21).

The studies of Kusumoto et al., 1998, showed that ectopic osteoinduction occurred in the rat latissimus dorsi muscle flap and depended upon the dose of BMP, which suggests that osteogenesis is possible even in the absence of osteoprogenitor cells with the condition of BMP addition (7).

Our study brings data to sustain the hypothesis that osteogenic capacity activation of the osteoprogenitor cells contained by corticoperiosteal flaps occurs only in the condition of direct informational signals existence from the contact with a structural bone defect or by addition of bone morphogenetic protein. This evolutional model represents the confirmation of osteogenic reaction incapacity of the free vascularized corticoperiosteal flaps in heterotopic transplantation in the dogs. It will be to explain away the contribution of flap to osteogenesis and the importance of mechanical stress of the transplanted flap into osseous defect.

CONCLUSIONS

In the dog, only the free vascularized corticoperiosteal flaps in heterotopic transplantation reveals osteogenic reaction incapacity.

Involvement of the periosteum in bone healing process in dogs shows distinct features.

Acknowledgments This work was supported by CNCSIS – UEFISCSU, project number PNII – IDEI 130/2008

REFERENCES

1. **Carlton, R.**, 1984, Free Periosteal Graft Repair of Maxillary Clefts in Adolescents, Plast. Reconstruct. Surg., 73(4):556-565.
2. **Chen A. C., Lin S. S., Chan Y. S., Lee M. S., Ueng S. W.,** 2009, Osteogenesis of prefabricated vascularized periosteal graft in rabbits, J. Trauma., 67(1):165-167.
3. **Dailiana Z. H., Shiamishis G., Niokou D., Ioachim E., Malizos K. N.,** 2002, Heterotopic neo-osteogenesis from vascularized periosteum and bone grafts, J. Trauma., 53(5):934-938.
4. **De Yuehuei H. An, Kylie L. M.**, 2003, Handbook of histology methods for bone and cartilage, Humana Press.
5. **Igna C. et al.,** 2008, Influence of dental implant microstructure on the osteointegration in the dogs, Scientific Works FMV seria C, Bucureşti, Vol. LIV: 241 – 248.
6. **Kaminski A., Bürger H., Müller E. J.,** 2009, Free corticoperiosteal flap in the treatment of an infected bone defect of the tibia. A case report, Ortop. Traumatol. Rehabil., 11(4):360-365.
7. **Kusumoto K., Bessho K., Fujimura K., Akioka J., Ogawa Y., Iizuka T**., 1998, Prefabricated muscle flap including bone induced by recombinant human bone morphogenetic protein-2: an experimental study of ectopic osteoinduction in a rat latissimus dorsi muscle flap, Br. J. Plast. Surg., 51(4):275-280.
8. **Kusumoto K., Bessho K., Fujimura K., Akioka J., Ogawa Y., Iizuka T.,** 1997, Comparison of ectopic osteoinduction in vivo by recombinant human BMP-2 and recombinant Xenopus BMP-4/7 heterodimer, Biochem. Biophys. Res. Commun., 239(2):575-579.

9. **Moles A., Glyde M.**, 2009, Anatomical investigation of the canine cranial tibial artery. A potential source of severe haemorrhage during proximal tibial osteotomies, Vet. Comp. Orthop. Traumatol., 5:351-355.
10. **Ortak T., Ozdemir R., Uysal A., Ulusoy M. G., Sungur N., Sahin B., Koçer U., Sensöz O.,** 2005, Osteogenic capacities of periost grafts, periost flaps and prefabricated periosteal flaps: experimental study, J, Craniofac, Surg., 16(4):594-600.
11. **Penteado C. V., Masquelet A. C., Romana M. C., Chevrel J. P.,** 1990, Periosteal flaps: anatomical bases of sites elevation, J. Clin. Anat., 12:3-7.
12. **Pierematteі D. L., Greeley R. G.,** 2003, An atlas of surgical approaches to the bone, WB Saunders Comp., Philadelphia.
13. **Rahn B. A**., 2003, Fluorochrome labelling of bone dynamics, European Cells and Materials, 5(suppl. 2): 41.
14. **Saridogan K., Gurbuz H., Bilgi S., Akkaya L.,** 1993, The influence of the free periosteal grafts on bone healing in cortical defects (Experimental study in rabbits), Acta Orthop. Traumatol. Turc, 27(1):45 -56.
15. **Sauerbier S., et al.,** 2007, Sinus augmentation with periosteum derived tissue engineered bone, Europ. Cell Mat., 13(2):58.
16. **Stock W., Hierner R., Wolf K.,** 1991, Vascularized periosteal transplant. A review of a new therapeutic possibility, Handchir. Mikrochir. Plast. Chir., 23(3):149-156.
17. **Svindland A. D., Nordsletten L., Reikeras O., Skjeldal S.,** 1995, Periosteal response to transient ischemia: Histological studies on the rat tibia, Acta Orthopaedica, 66(5): 468-472.
18. **Takaaki U. et al.,** 2001, Cellular Origin of Endochondral Ossification From Grafted Periosteum, The Anatomical Record, 264:348–357.
19. **Takeuchi S., Matsuo A., Chiba H.,** 2010, Beneficial role of periosteum in distraction osteogenesis of mandible: its preservation prevents the external bone resorption, Tohoku J. Exp. Med., 220(1):67-75.
20. **Vögelin M. D. E., Jones N. F., Lieberman J. R., Baker J. M., Tsingotjidou A. S., Brekke J. H.,** 2002, Prefabrication of bone by use of a vascularized periosteal flap and bone morphogenetic protein, Plast. Reconstr. Surg., 109(1):190-198.
21. **Vögelin E., Brekke J. H., Jones N. F.,** 2000, Heterotopic and orthotopic bone formation with a vascularized periosteal flap, a matrix and rh-BMP-2 (bone morphogenetic protein) in the rat model, Mund Kiefer Gesichtschir, 4(2):454-458.
22. **Zhang X., Naik A., Xie C., Reynolds D., Palmer J., Lin A., Awad H., Guldberg R., Schwarz E., O'Keefe, R.,** 2005, Periosteal stem cells are essential for bone revitalization and repair, J. Musculoskelet Neuronal Interact., 5(4):360-362.
23. **Zhu S.J., Choi B.H., Huh J.Y., Jung J.H., Kim B.Y., Lee S.H.,** 2006, A comparative qualitative histological analysis of tissue-engineered bone using bone marrow mesenchymal stem cells, alveolar bone cells, and periosteal cells, Oral Surg. Oral Med. Oral Pathol. Oral Radiol. Endod, 101(2):164-169.

RFID TECHNOLOGY USED FOR MONITORING ESTRUS TEMPERATURE IN COW

Fl. IONESCU[1], R. HUȚU [2], A. CIMPONERIU[1], M. CHILINȚAN[3]
R. URIAN,[1] I. HUȚU[1]
[1] Banat University of Agricultural Science and Veterinary Medicine, 119 Aradului St. Timisoara - 300645, RO, florin.ionescu@uex-usamvbt.org
[2] DMV, SC. Pharma Iasi SA, Timișoara Foisor St. No 9,
[4] S.C. E5invent SRL, Research & Development in science and engineering Timisoara, 19/21 A. Popovici St, 300050

ABSTRACT

The purpose of this study was to observe temperature variation of RFIDs devices implanted in cows. For this study 19 RFID devices have been implanted in 4 (four) different body areas (retro auricular, in the 2/3rd of the neck, retro mammary and the shank region) in 5 (five) cows. The aim of the study was to check the accuracy of the ID sent by the transponder as well as measuring the body temperature indicated by the RFID and the internal body temperature (measured by rectal thermometer) on every two hours for five days. After analyzing the data, it could be observed that the chip implanted in the retro auricular region could estimate efficiently rectal body temperature, with $r = +0,512$ at $p < 0,001$. The transponder's temperature value is influenced by body temperature - a characteristic curve was identified during estrus period of cows. The best implantation site for the temperature reading accuracy was the retro-auricular region.

Keywords*:* dairy, management, temperature, estrus and RFID (Radio Frequency Identification Device)

INTRODUCTION

The electronic identification of the animals from distance through radio frequency (RFID) is generally composed of three components – a reader, a tag (172 radiofrequency transponder) and a data processing device, which can be based on a PC or other microcontrollers. The transponder, a passive device, does not own an internal energy source, but it allows reading the ID code when the transponder is activated by the reader's signal. The communication between the transponder and the reader can be realized through 2 data sending proceedings (semi-duplex, HDX and integral duplex, FDX-B). After sending the data telegram, the transponder returns to a passive state until the next activation. (7, 8, 10)

The purpose of this study was to establish the best implantation site of the RFIDs for the most accurate body temperature determination in normal and estrus cows and through analyzing the correlation between the body temperature from the accepted reference system (internal body temperature determined by rectal thermometer) and the body temperature indicated by the RFID.

MATERIALS AND METHODS

The systems used in this case were the RFIDs TX1400B – nano chip RFID with bio-thermo reader and the Universal Bio-Thermo Pocket-Reader EX with a 125 or 134.2 kHz action frequencies.

The operating principle consists of the transmission of a radio signal from the reader to the microchip. After receiving the sent signal, the microchip sends back to the reader the ID code and the temperature recorded in that body region. The transmitted data can be seen on the reader's LED display. (9)

Photo no1. RFID inoculation in the retro-mammary region

Before the chips actual implantation in the animal's body, the chips were calibrated in water with temperature controlled through high two accuracy (0,02°C) thermometers. Each microchip was read for each Celsius degree from the 36-43°C and 43-36°C intervals for the ID and temperature; there were two readings for each interval.

Five cows were used in this study (table no1 and photo no1), each in different physiological stages, with different milk productions – each cow has been implanted with four RFID devices; briefly the used animals are identified and have the following morph physiological characteristics.

Photo no 2. RFID implantation sites.

Retro auricular, in the middle of the neck region, the 2/3rd of the shank region, and at the second half of the udder's suspensory ligament

To get the best body region which allows getting the most accurate results, the microchips have been implanted in four body regions as follows: 1. the retro auricular region; 2. the 2/3rd of the neck; 3. the retro mammary region and 4. the shank region (photo no 2).

Table no 1.

Morpho-physiological traits from studied cattle

Cattle I.D.	High	Body weight	Milk production	Physiological stage
6774	129	550	14	33rd lactation day
0279	126	530	10	76th lactation day
0337	130	540	13	57th lactation day
8953	132	570	9	60th lactation day
7895	131	560	-	last pregnancy week

The internal body temperatures as well as the temperature indicated by the RFID devices were read for a five days period every two hours; each reading was done twice and the final value was the arithmetic mean of the two readings.
The variables considered to be involved in expressing the temperature are: 1. individuality; 2. implantation site; 3. the time of body temperature reading; 4. the cow's physiological stage (pregnant, dairy cows with or without estrus) and 5. The cows' health stage (healthy and sick cows).
For the statistical sustainment and demonstration of the hypothesis, the internal body temperature and the cow's ID number were used as control variables.
The statistical processing was done mainly by using the following tests: continuous variables correlation tests (correlations and regressions), associating the continuous variables with the categorical ones (ANOVA) and the T Student test, to determine the mean differences.

RESULTS AND DISCUSSION

At the calibration**,** a correlation was noticed between the water temperatures and the ones indicated by the RFID's with a value of $r=+0,996$ at $p \leq 0,001$. This correlation allows the RIFD's use, although, there is a mean difference of -0,075±0,023°C between the water and the RFID's indicated temperature.
Individual RFID devices average temperature recorded at the 5 cows, during the 5 days of study, had individual variations, as follows:

- the cow no. 279 encountered an average temperature of 36,7°C (photo no3);
- the cow no. 337 encountered an average temperature of 36.2 ° C (graphic no 1 and photo no4);
- the cow no. 783 encountered an average temperature of 37,6°C;
- the cow no. 1062 encountered an average temperature of 37,1°C;
- the cow no. 8953 encountered an average temperature of 36,6°C;

The differences between those temperatures are statistically significant; at $p<0.001$, the value of F is 29.5. R^2 coefficient shows that 14.8% of the temperature's variability encountered by RFID is given by each individual.
The top temperature is observed mainly during the morning (7^{00}-9^{00}) and towards evening, but with slight increases starting at 16^{00}.
Another observation that may be extracted from the chart is that, in the case of RFID placed udder, immediately after the milking process, the temperature drops to very large differences compared with the internal temperature.
The differences in temperature encountered from an hour to another and from day to night are statistically significant. By analyzing the variation of hourly readings of temperature on RFID devices (the ANOVA test), it has been obtained the value of F=9.79 on p<0.001. Obtaining a coefficient of multiple determinants R^2 = 13.81%, we can consider that the temperature value of transponder is significantly influenced by the time frame of readings.
As the readings were made over 5 days every two hours, without any modification, it is considered that they can be used in veterinary practice; practically 13.8% of the variability of RFID's temperature is justified by the moment of reading

Correlations and regressions between the rectal and the RFID's temperatures

By ignoring the transductor's inoculation site, the temperature read on the RFID device is low correlated with the central temperature, the one measured with the veterinary thermometer; the correlation is r = +0,239 at p < 0,001. By analyzing the variation generated by the RFID's implantation site the following value was obtained F = 51,58 at p < 0,001; this aspect clearly suggests that the transponder's temperature value is significantly influenced by the implantation site.

In the retro-auricular region the correlation is higher and is value of r = +0,512 at p < 0,001. In this case, the regression trajectory can be determined by the equation 1.1 but the R^2=0,26.

$$T_{RFID}°C = 17,4 + 0,513\ T_{rectal}°C \quad (1.1)$$

The obtained data suggest that the transponder's temperature value in the retro-auricular region can efficiently estimate the central temperature value.

Photo 3. Temperature and ID reading at the retro auricular region

Photo 4. Clear mucus discharge – picture taken in day 4, at 14^{00}

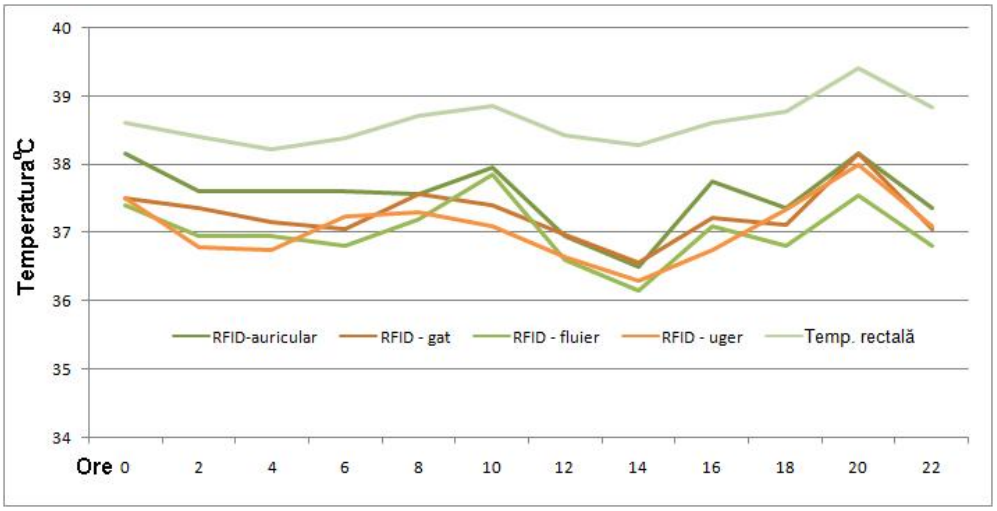

Graphic no1. The circadian temperature distribution at cow nr. 0337 (day II)

The obtained data for 2/3rd of the neck (r = +0,456 at p < 0,001), shank region (as r = - 0,213 at p < 0,001), retro-mammary region (r = +0,273 at p < 0,001) suggests that the transponder's temperature value can estimate the central temperature value but with a lower accuracy than the retro-auricular region.

During the study, the cow with ID 0337 (born in 2004 and the with last birth in April 16) was the only one who presented clinical signs of estrus (Photo 4). More specifically, starting at the end of the third day of the experiment (at 20^{00}) it could be observed the decrease of temperature; the trend of decreasing temperature was kept for 14 hours (first section of graphic no2), until 8^{00} o'clock of the fourth day studied.

Clinical signs of the heats observed during estrus were following: nervous and restless, swollen vulva, loss of appetite, occurrence of specific mucus and temperature modification **(see photo 4).**

In the second section of the chart it can be observed the raising of the rectal temperature with 0,7°C (from 38,6 to 39,3°C). That increase is almost four times bigger in the case of temperature measures with RFID device located retro auricular; practically, at the RFID's level temperature has raised with 1,5°C (from 36,2 to 37,7 °C) in a period of two hours. Along with this observations, there had been done CMT and samples were harvested for determination of somatic cell count. Both tests were negative, which removed the suspicion of temperature increase on account of the existence of a mammary gland infection[1]. The cow did not show clinical signs to support the hypothesis of the presence of other pathological conditions.

On the reading recorded at 8^{00} there were observed first heat mucus secretion and evident swollen vulva.

After this increase of temperature, comes a constant level segment. For 12 hours (third section), the charts of central temperature and of the one captured by RFID located retro auricular remain high and relative constant. In day 4, from 10^{00} to 22^{00}, the rectal temperature and the one took by RFID device placed retro auricular remain between 39,0-39,5°C, and 37,5-38,5°C, respectively. Also, during this period, it had not been identified any presence of mastitis or other pathological signs which could influence the values of temperatures, by increasing or decreasing them.

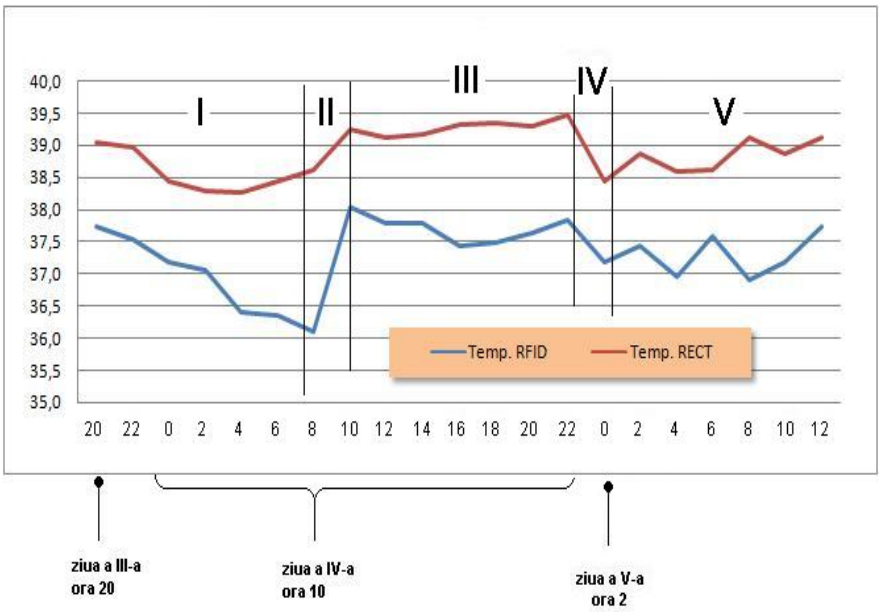

Graphic no2. Dynamic of body rectal temperature and the one recorded by RFID placed retroauricular at cow no. 0337

According to data recorded, after 22^{00} during the day 4 of the study, the temperature began to drop to levels comparable to those before the feverish flare.

[1] The number of somatic cell was 170,000 cells/ml in the sample took in the evening on day 3 of the study and 140,000 cells/ml in the sample took on day 4 of the study.

Discussions regarding the RFID's placement and temperature during estrus

It can be drawn the conclusion that after reading and correlating the RFID's temperatures of the four implantation sites with the rectal temperature, that the neck region does not indicate the correct temperature. Merks and Lambooij have also studied four implantation sites. The Grange research centre has implanted RFIDs in different regions of the body in order to establish the ideal site correlated with the reading and the postmortem retrieving (5).

In the situation where the computerized management of reproduction activity would be desirable, the real positive and negative diagnose, would be established by correlation with other variables, namely:

- a low number of somatic cells;
- increasing activity/movement recorded by pedometers;
- possibly, decreasing the amount of feed ingested.

The data obtained in estrus cow are partially comparable with those reported by *Mosher (1990)* and *Kumaran (1996)*, who argue that prior to estrus, the temperature decreases and reaches the lowest point 1-2 days before the beginning of estrus. Also, the authors support that in the first day of estrus, the temperature rises suddenly, and in the next day, during ovulation, the temperature drops again. In graphic no 2, this aspect can be detected, specifying that, in this case, the largest temperature decrease occurs before the day of estrus.

In conclusion, it may be suggested that a more frequent monitoring of temperature in dairy cows, not only during milking, can be a usable alternative to *high-tech* farms. RFID devices located retro auricular recorded body temperature in a manner which allows setting / detecting the beginning of estrus.

We believe that the advantage using RFID is the possibility of reading in real time or even with a higher frequency of body temperature, allowing rapid intervention and unequivocal of the veterinarian or the owner.

Milk producers are facing many challenges which affect their economic efficiency: low milk prices, increasing quality demands and a bigger livestock. Certainly, the visual detection of estrus and diseases (mastitis, for example) will become increasingly difficult and inefficient at the levels of production required. Automatic temperature monitoring of cows may reduce physical work, by raising the intensity and frequency of monitoring, which can reduce management problems of dairy farmers.

Clearly, there remain two possibilities for the future of dairy farm: a developed technology (high tech farms) and an option for a low input farming. The nanochips monitor the body temperature, a health state indicator but also a sickness indicator, allowing the detection, control and evolution of the infectious diseases in or outside the disease center.

The use of the electronic readers makes the data reading and transfer to a central data base very easy, and it rules out the errors registered at the data hand writing. In case of simultaneous registered fever episodes or at short periods of time at several animals, different infectious or parasitic diseases can be considered. Controlling animal movement or fraud trading in a disease center is easily done, many farmers being tented to sell the sick animals.

In the same way, a body temperature drop can indicate poor care, poor microclimate conditions, but also some poisoning.

Cattle identification through RFID devices

The RFID cattle identification is 100% accurate; practically, no reading has shown another cow ID value than the real one.

By implementing the RFID cattle identification system we can say that we have no wrong ID number readings and the falsification chances are practically none. At the same time the *„From*

stable to table" principle is regarded, having a clear image of the animal's course from a raising farm to slaughtering.

CONCLUSIONS

- The RFID's temperature faithfully copies the descending or ascending temperature of the calibration water, which allows us to sustain the hypothesis that this also happens in the animal's body.
- The RFID cattle identification is 100% accurate; practically, no reading has shown another cow ID value than the real one.
- There are no cases of transponder migration.
- The transponder's temperature value is highly influenced by the implantation site; for the temperature reading accuracy, the best implantation site is the retro-auricular region – followed by the 2/3rd neck region, the retro-mammary region and the shank region.
- RFID devices located retro auricular recorded body temperature in a manner which allows setting / detecting the beginning of estrus.

REFERENCES

1. Fallon, R.J. and Rogers, P.A.M. - Use and recovery of implantable transponders in beef cattle. In: Automatic electronic identification systems for farm animals. Proceedings of a seminar held in Brussels, Belgium, 17-19 October, 1990. 21 – 39
2. Hasker, P.J.S., Bassingthwaight, J., Round, P.J. - A comparison of sites for implanting identification transponders in cattle. Australian Veterinary Journal, 69: 4 : 91.
3. Lambooij, E. - Automatic electronic identification systems for farm animals. Proceedings of a seminar held in Brussels, Belgium, October, 1990. E. Lambooij (Editor), No. 13198: 21-27.
4. Merks, J.W.M. and Lambooij, E. (1989). The use of implantable electronic identification systems in pig production. Proceedings 40th Annual Meeting European Association of Animal Production, Dublin:237.
5. Richard J. Fallon, P.A.M. Rogers and Bernadette Earley - ELECTRONIC ANIMAL IDENTIFICATION. Beef Production Series No. 46 :6-19
6. Wade, J.M., Gallagher, M.G. and Gordon, I. (1991). Electronic identification of cattle. In: Automatic electronic identification systems for farm animals. Proceedings of a seminar held in Brussels, Belgium, 17-19 October, 1990. E. Lambooij (Editor) No. 13198:49-52.
1. 7.***http://en.wikipedia.org/wiki/ISO_11784_&_11785
2. 8.***RFID for Livestock and Animal Identification http://www.electrocom.com.au/rfid_ animalid .htm.
3. 9.***New*Universal Bio-Thermo Pocket EX Reader **,** http://www.rileyid.com.
4. 10.***www.aimglobal.org/technologies/rfid/what_is_rfid.htm.

.

VENTRAL OSTEOTOMY IN THE TREATMENT OF OTITIS MEDIA IN DOG

Andrei KRUPACI, Aurel MUSTE, Florin BETEG, Radu LACATUS, Alina DONISA, Florina-Alexandra KRUPACI

University of Angricultural Sciences and Veterinary Medicine
Calea Mănăştur 3-5 Cluj-Napoca, andrei_krupaci@yahoo.com

ABSTRACT:

The study was conducted on a total of sixteen dogs from diferent breeds, sexes and ages. The diagnosis of otitis media was established after clinical examination in conjunction with radiological examinations. Following these tests it was established that 15 dogs presented unilateral chronic otitis media and the sixteenth presented bilateral chronic otitis media. It was revealed by owners that all dogs had a history of external otitis that were treated by medical means. All dogs underwent surgery with osteotomy of the ventral tympanic bulla. After the osteotomy we collected samples for bacteriological and sensitivity testing. Postoperative evolution of the16 patients was different 15 of them presenting a slight swelling and inflammation in the submandibular area and expression of brown-hemorrhagic exudate for 5 days. The sixteenth patient at seven days after the first surgery suffered a second operation to treat the other diseased ear. Postoperative evolution of this patient was characterized by the emergence of a strong edema in the submandibular region and expression a purulent exudate for 4 days. At the end of therapy, 15 dogs have been declared clinically healthy.

Key words: middle ear, otitis media, bulla osteotomy, tympanic membrane

INTRODUCTION:

Otitis media occurs frequently in dogs with chronic external otitis. The diagnosis of otitis media is difficult because the clinical aspects of the otitis media are similar to that of external otitis[3]. Primary otitis media occur very rarely and it is found in particular breed like Cavalier King Charles Spaniel[6]. Most often occurs secondary to otitis externa following the extension of infection from the ear canal to the middle ear by the tympanic membrane that can be rupture [2].

Otitis media sometimes appeares consecutively to tonsilitis, acute or chronic pharyngitis or rhinitis[5]. Once the contents of the external ear canal enter the middle ear through a ruptured tympanic membrane, inflammatory reactions occur within the respiratory epithelial cells. Organisms and exudate draining into the middle ear through an eroded or ruptured tympanic membrane tend to accumulate in the ventral portion of the bulla. The resulting suppurative inflammation causes the lining epithelium in the bulla (mucoperiosteum) to change from cuboidal to pseudostratified columnar leading to an increase in the number of secretory cells and glands, whose activity further adds to the quantity of exudates.

As otitis media becomes more chronic, *lamina propria* changes to dense tissue and bone spicules may develop within it. Not only does this tissue reaction occur in the bone of the tympanic bulla, but it also occurs on the auditory ossicles and they may become fused together, diminishing air-conduction hearing. The exudates and secretions thus formed in the bulla escape into the external ear through the ruptured eardrum[4] and contribute to the exudates already present in the external

ear canal. Large amounts of discharge may be produced, sufficient to fill the ear canal and overflow on to the pinna at times.

Patients with chronic otitis media may have had a history of repeated episodes of disease. Therapy is sufficient to reduce the inflammation and secretion, allowing the tympanic membrane to heal[5].

Although the external otitis disappears and tympanic membrane heals the infection remain quartered in the middle ear and surgery is necessary. In such cases, at the otoscopic examination[1]we observe a normal tympanic membrane but bomb out and the existence of a fluid content in the middle ear[6]. In this situation, it is preferred the ventral approach of the bulla because, after osteotomy, the entire middle ear cavity can be drained and the infection can be stopped.

of the

MATERIAL AND METHODS:

This study was conducted during August 2009-April 2010 in the Clinic of Surgical Pathology at the Faculty of Veterinary Medicine in Cluj-Napoca on a total of 16 dogs. All dogs included in the study showed symptoms of ear disease fallowing clinical examination but no obvious changes were observed in the ear canal. Otoscopic examination revealed the opacity and bulging of the tympanic membrane and accumulation of fluid in the middle ear. The diagnosis of otitis media was confirmed after X-ray examination (rostro-caudal position) which showed changes in the middle ear characterized by tympanic bulla osteitis and clouding of the whole tympanic cavity (fig. 1).

sion is

General anesthetized patients by narcosis with isofluran were positioned in dorsal recumbency and ventral neck area was prepared for aseptic surgery. We drew an imaginary line connecting recurbate branches of the mandible and a second line along the long axis of the ventral portion of the neck (fig. 2). It was performed a 4-7 cm incision along the long axis of the neck, and 1-2 cm lateral from the intersection of imaginary lines. The digastric muscle (lateral) was bluntly dissected from the stiloglos and hipoglos (medial) muscle considering and protecting the hipoglos nerve.

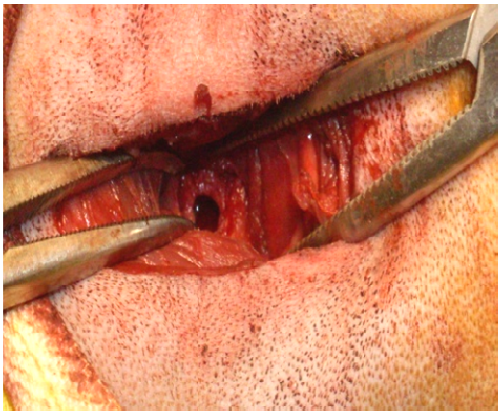

la wall after

We identified the tympanic bulla cranio-medial from the tympanic process of hyoid bone and caudo-medial from the angle of mandible. The soft tissue was bluntly dissected from the surface of the bulla and using a drill we made a hole at that level (Fig. 3).

After penetrating the ventral wall of the tympanic bulla, we took samples for bacteriological examination. Where necessary we enlarged the hole created using bone rongeurs. The affected respiratory epithelium lining the tympanic cavity was removed using a curette.

A drain was placed after thoroughly flushing the bulla and was set to the skin by suture. Surgical sutures plans were made classic in separate points. Drain was removed after 4-5 days depending on the amount of secretion expressed.
Postoperatively we administered antibiotics according to antibiogram results over a period of 3-5 days and analgesics 3 days.

RESULTS AND DISCUSSION

As a result of otoscopic examination in all dogs included in the study were observed changes in the shape and appearance of the tympanic membrane.
In 12 of the dogs the tympanic membrane was normal in macroscopic point of view but because it was present the exudate in middle ear cavity she was bomb out. The tympanic membrane of four patients presented a rough surface and scars. The X-ray examination revealed changes in the tympanic bulla wall in all dogs, and this changes were characterized by osteitis, rarefaction and thinning of the bulla wall. X-ray examination also noted the presence of a liquid that occupies the entire middle ear cavity.
During surgery in two of the 16 patients there was a massive hemorrhage which was stopped by the classic haemostasis. Perforation of the bone structure of the ventral portion of the tympanic bubble was made relatively easy in all dogs due rarefactiei of bone and osteitis existing at that level.
In all patients undergoing surgery, after perforation of tympanic bulla it was revealed a reddish-brown liquid which occupies the whole middle ear cavity. From these liquid were taken samples for bacteriological examinations and for susceptibility testing. Bacteriological examination confirmed the presence of middle ear infection in all patients included in the study after the isolation from the collected exudate of the next germs: Staphylococcus spp, Corynebacterium spp, Streptococcus spp, Pseudomonas aeruginosa.
In the first days after surgery all dogs undergoing surgery showed an inflammatory edema in the ventral area of the neck. Because of this swelling three dogs had a respiratory cornage which lasted about two days. Operators wound drainage was performed for four days by expressing a sero-hemorrhagic fluid on both the drain and operators wound.
The patient with bilateral otitis media at 7 days after the first surgery has undergone a new interventions on the opposite side. Postoperative evolution after the second intervention was characterized by the appearance of a strong edema in the ventral area of the neck accompanied by respiratory cornage and cough.
At 14 days after surgery 15 patients were declared clinically healthy.

CONCLUSIONS:

1. In our study, unilateral otitis media was diagnosed in 15 dogs (93.75%) and bilateral otitis media in one dog (6.25%).
2. Fallowing osteitis occurs the tympanic bulla wall thins which makes the osteotomy extremely easy using common surgical instruments.
3. In our study we found that all patients had septic processes in the middle ear cavity.
4. Ventral tympanic osteotomy in the treatment of otitis media remains an effective solution considering that in our study healing occurred in 93.75% of cases.

REFERENCES:

1. **Cole L, Kwochka K, Podell M, et al (2000)**- Radiography, otoscopy, pneumotoscopy, impedience audiometry, and endoscopy for the diagnosis of otitis media in the dog. Vet Dermatol 11(suppl 1):3:4,

2. **Gotthelf, L. N. (1995)**- Secondary otitis media: an often overlooked condition. *Canine Practice* ; 20: 14–20.
3. **Holt DE, Walker L. (1997)**- Radiographic appearance of the middle ear after ventral bulla osteotomy in five dogs with otitis media ; Vet Radiol Ultrasound. 1997 May-Jun;38(3):182-4.
4. **Little, C. J. L., Lane, J. G. (1989)**- An evaluation of tympanometry, otoscopy, and palpation for assessment of the canine tympanic membrane. *Veterinary Record*; 124: 5–8.
5. **Muste A. (2009)**- Patologie chirurgicala veterinara, Chirurgie speciala; *Editura AcademicPres*, p. 144.
6. **W. Stern-Sertholtz , L. Sjöström, N. Wallin Hårkanson** (2006) - Primary secretory otitis media in the Cavalier King Charles spaniel: a review of 61 cases. *Journal of Small Animal Practice* Volume 44 Issue 6, Pages 253 – 256 Published Online: 10 Feb 2006

EXPERIMENTAL PERFORATOR DORSAL TEGUMENTARY PIG COETANEOUS PEEL BY USING NON IONIC CONTRAST MEDIA

R. LĂCĂTUŞ, I. PAPUC, A. MUSTE, B. CHIROIU, Ileana MATEI, F. ARDELEAN, R. C. PURDOIU, Alexandra Nicoleta PĂVĂLOIU

University of Agricultural Sciences and Veterinary Medicine
Faculty of Veterinary Medicine
Calea Mănăştur, Nr. 3-5, Cluj Napoca, jud. Cluj, Romania
rlacatus2003@yahoo.com

ABSTRACT

By this study we tried to create an experimental model in pigs, in skin grafts in humans, by improving the detection technique of the main perforating vascular branches in the entire body surface and making a vascular map of these segments with the help of medical imaging.

Key words coetaneous peel, skin grafts, pig.

Acknowledgements: This work was supported by CNCSIS-UEFISCSU, project number PNII-PARTENERIATE 41002/2007.

INTRODUCTION

The perforating blood vessel represents a secure source of vascular irrigation which offers a large opening to the collecting areas of the coetaneous peel, allowing a reconstruction of the defects from clinical practice respecting accurately the similitude reconstructive principle "like with like".
Their usage as free microsurgical coetaneous peels has known at first a high interest, creating the describing premises and the utilization of coetaneous peel based on perforating vessel from the profound inferior epigastric artery, the superior gluteus artery, the dorsal thoracic artery, the descendant branch of the lateral circumflex femoral artery and more seldom from the radial artery and the medial circumflex femoral artery.
From the desire to assure a higher reconstructive similitude but also to reduce the morbidity of the donating area and receptive area, as well as the prolonged operating timing in cases of free coetaneous peel, the surgeon's preoccupation to develop and improve the applicability of the local coetaneous peel or regional based on the perforating vessels has improved daily.

MATERIAL AND METOHOD

The investigations were performed in the Radiology and Veterinary Imaging Laboratory from the Faculty of Veterinary Medicine, Cluj-Napoca, in the Radiology and Imaging Laboratory from the Rehabilitation Clinical Hospital, Cluj-Napoca, in collaboration with the Surgery Clinic from the Faculty of Veterinary Medicine, Cluj.
The biological material used in this research was represented by a lot formed by 10 pigs from PIC F II breed (6 females and 4 males) with body masses ranging between 35 kg and 50 kg.
Selecting the type of the pig: Taking into consideration the morphological aspects of the pig's breeds in achieving the established objectives, and that being detecting the main perforating vascular branches in the entire body surface in pigs, we have chosen the meat hybrid PIC-F II-337 (terminal boar) for this study. We have chosen this type of hybrid because of the following: the fat

layer is very small, the good capacity of adapting to new environmental conditions met during this research, the high resistance to diseases and pests [3, 5, 7].

The angiographic exam of the pigs was performed by the help of the SIEMENS Angiograph Coroskop Top model C-arm with a digital capture mode of the images (DAS – Digital Acquisition System), with the possibility of zooming the image, digital video capture (DCM - Digital Cine Mode) and serigraphic and also a radio diagnostic machine Philips Duodiagnost with a digital system of capturing the images by impregnation on phosphoric plaques and a detector type PCR Eleva S. The nonionic contrast substances used were: ULTRAVIST, OPTIRAY, VISIPAQUE, in different concentrations (fig. 1, 2, 3).

For the pre surgical angiographic exploration the pigs were sedated by intramuscular or intravenous anesthesia (neuroleptanalgesia) with Narcoxyl 2 (Xylazine hydrochloride 20mg/ml), Stresnil (Azaperone 40mg/ml) and Ketaminol 10 (Ketamine hydrochloride 100 mg/ml) for veterinary use.

For the long surgical interventions we used the inhalator narcosis by endotracheal intubations in closed circuit, using the Isoflurane narcotic [1, 2, 6, 8, 9]..

Fig. 1 Radiological examination

Fig. 2 The identification and catheterization of the femoral artery

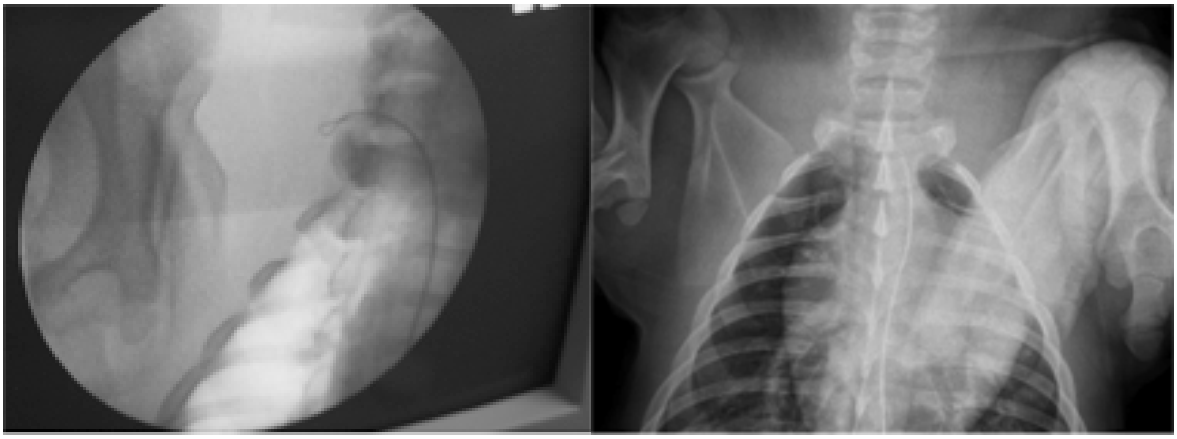

Fig. 3 The introduction and follow up of the guidance fiber

RESULT AND DISCUSION

In the moment in which the contrast substance has given opaqueness to the superficial arterial vessels of the area, the mobile arm of the angiograph was rotated so as to allow the examination in a tangential plan of the interest area. Under radioscopic control, a iodine, non-ionic contrast substance was injected in a continuous rate in the right femoral artery in the direction of the blood flow. A VISIPAQUE 320 mg I/ml, injection solution was used, with 0,6411 Osm/kg osmolarity, 66,1 to 37 Celsius grade viscosity. Active substance Iodixanol (INN) 320 mgI/ml 625 mg equivalent to 320 mgI I. The Iodixanol is a contrast medium for X –rays, non-ionic, dymeric, hexaiodine, hydro soluble and OPTIRAY 320, injection solution with 678 mg/ml corresponding ioversol to 320 mg/ml iodine.

The perforating dorsal branches identified by imaging methods were mapped and dissected, which allowed the peels to be sectioned and delimited area (fig. 4, 5, 6, 7).

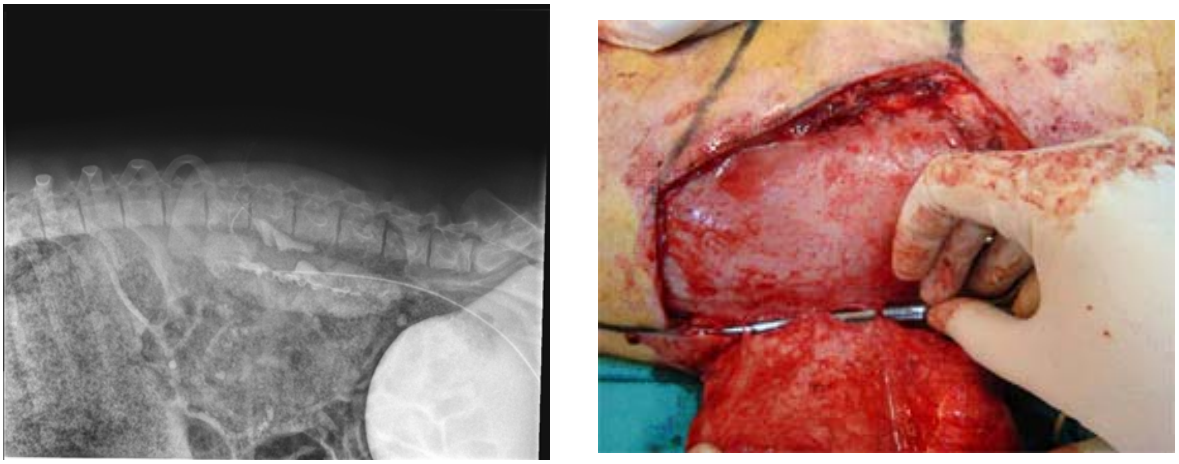

Fig 4 - The angiography in the lumbar arteries and the identification of the perforate arteries by anatomic dissection

Fig 5 - The angiography in the lumbar arteries

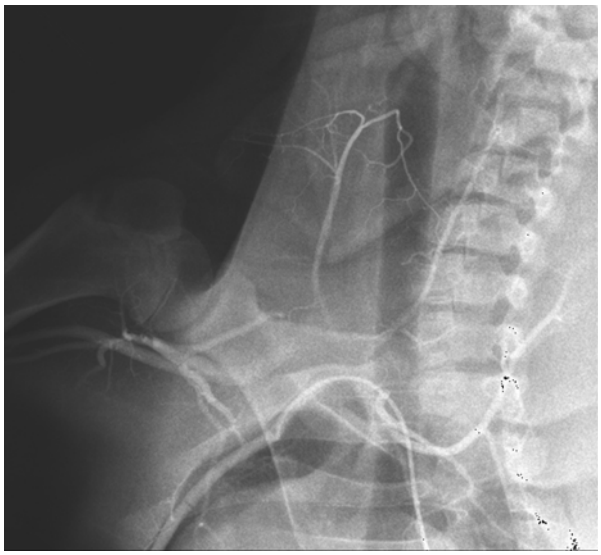

Fig 6 - Angiography in the cervical arteries

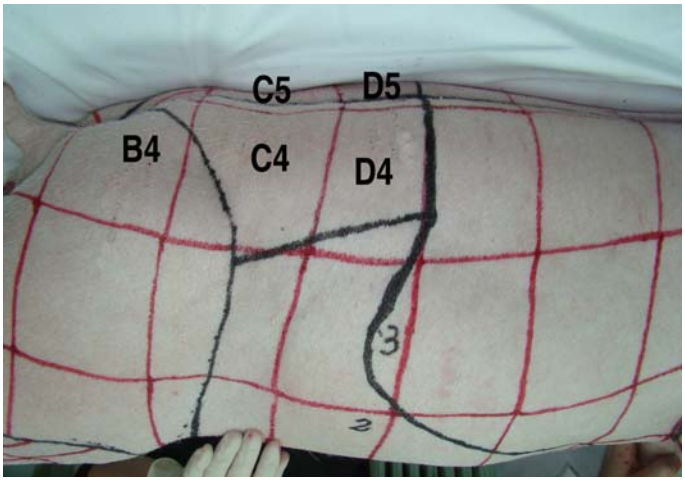

Fig 7. Mapping the body

Postoperative follow up of the peels was performed for a month, until the subjects were sacrificed. We performed direct observation of the animals in the experiment, based on: peel color (normal, pale, hyperemic, cyanosis); capillary pulse (present, delayed, rapid, fast); peel necrosis appearance and evolution; peel temperature (daily measurement, at the same hour) (fig. 8, 9).

Fig. 8 The post operating monitoring of the peels– at 2 days post operation, at 2 weeks post operation, respectively at 4 weeks post operation

Fig. 9 Peel resutured with the perforating artery marked in the central

CONCLUSIONS

Based on the obtained data we can conclude the following:
In the cartography and identification of the muscle-coetaneous perforate vessels or fascial coetaneous vessels in pigs a determinate role holds the imaging techniques and nonionic substances
Among the uncontestable advantages of the coetaneous peel on the perforate vessels are: the multitude of donating areas, higher freedom in the drawing and sampling of the coetaneous peel, intact keeping of the major vascular axes (especially in the local coetaneous peel cases and regional); higher security in the conditions of a correct surgical technique.

- The arterial graphic was used in the pre surgical determination of the perforate vessels with some limitation like the exploration of the vessels from a distance with a nozzle, because a local cannulation of these vessels pre operation would be out of the question, the possibility of sampling a coetaneous peel on that perforating artery (it's destroyed by catheter).
- The arterial graphics made after surgery were useless in determining the vascular system from the coetaneous peel region proving it's extension in caliber as a result of coetaneous peel sampling. These can be used only in experimental purposes, because they irreversibly compromise the coetaneous peel by it's full take-off and complete sampling.
- The arterial graphic is an invasive method, pretty vague in establishing the place and quality of the perforate vessels. It has also other disadvantages: it detects only the big caliber vessels, it's harder to accept and support by the patients, the possibility that by introducing in the artery the radio opaque substance will influence the post surgical evolution of the coetaneous peel; limiting the number of injections and the maximum substance dose did not allow the examination of each topographic region in more than 2 -3 incidents, at every reiteration under different angle of examining being necessary a new contrast substance injection.
- The using of this kind of coetaneous peel has also some disadvantages, among which: the intra specific variability of the perforate vessels makes it necessary for a pre surgical detection method that can be used as a pedicle to the planned coetaneous peel; a high susceptibility at the venous suffering (congestion) with a risk of partial necrosis of the coetaneous peel by a deficit of venous comeback flow, which represents the most important disadvantage of the coetaneous peel on the perforate vessels.

REFERENCES

1. Blondeel, P. N., Arnstein, M., Verstraete, K., et al., (2000), Venous congestion and blood flow in free transverse rectus abdominis myocutaneous and deep inferior epigastric perforator flaps. *Plast. Reconstr. Surg.* 106: 1295.
2. Coskunfirat Ok, Oksar Hs, Ozgentas He., (2000), Effect of the delay phenomenon in the rat single-perforator-based abdominal skin flap model. Ann Plast Surg.;45:42-47
3. Oană, L., Timen, A., Beteg, F., (2006), Anesteziologie şi propedeutică chirurgicală veterinară, Editura Risoprint, Cluj-Napoca.
4. Thrall, Donald, (2007), Textbook of veterinary diagnostic radiology, Ed. Saunders.
5. Papuc I., C. Paşca, V. Mireşan, 2001, Anatomie comparată şi histologie, Aparatul cardiovascular, vol. I -II, Ed. Risoprint, Cluj-Napoca
6. Rodriguez A, Alvarez A, Martelo FR., 2007, The anteromedial thight flap as a training model of a perforator flap in rat. J Rec Microsurg:23;251-256.
7. Salmon M., 1988, Arteries of the skin. In: Taylor GI, Tempest M, editors;; Churchill & Livingstone.
8. Sano K, Hallock GG, Wasser TE, Robson PA, Rice DC., 2001,Comparison of a new method for computer analysis with standard techniques for measuring survival rates in the rat transverse rectus abdominis musculocutaneous fl ap. Ann Plast Surg.;47(6):647-51.
9. Seaber AV., 1985, Laboratory design in preparing for elective microvascuiar surgery. Hand Clin;1:233–245.

USAGE OF NONIONIC CONTRAST MEDIA FOR THE IDENTIFICATION OF PERFORATING CUTANEOUS ARTERIES IN RATS WITH APPLICATIONS IN PLASTIC SURGERY

R. LĂCĂTUŞ, I. PAPUC, F. ARDELEAN, B. CHIROIU, Ileana MATEI, A. MUSTE, R. C. PURDOIU, Alexandra Nicoleta PĂVĂLOIU
University of Agricultural Sciences and Veterinary Medicine
Faculty of Veterinary Medicine
Calea Mănăştur, Nr. 3-5, Cluj Napoca, jud. Cluj, Romania
rlacatus2003@yahoo.com

ABSTRACT

By this study we tried to create an experimental model for rats, in skin grafts in humans, by improving the detection technique of the main perforating vascular branches in the entire body surface and designing a vascular map of these segments with the help of the medical imaging techniques, utilizing the nonionic contrast substances.

Key words cutaneous peel, skin grafts, rats, contrast media.

Acknowledgements: This work was supported by CNCSIS-UEFISCSU, project number PNII-PARTENERIATE 41002/2007.

INTRODUCTION

This paper follows the setup of a fundament of the tactic, theoretic and experimental knowledge of the research team in perfecting the methods we are already using to cover up substance defects, but especially in finding new perforating vessels that are capable in vascularizing individual flaps in different body parts. Therefore, we will insist especially in enlargening the indication and usage limitations of the local and regional flaps, which will contribute to the realization of another great goal of substance defect surgery, the usage of tissue as similar as possible to cover up defects. Another goal of this paper was to reduce the learning curve in this new domain by involving young researchers in the preclinical training activity in the experimental surgery laboratories.

The final corollary is the experimental standard, both clinical and paraclinical of the surgical tactic and technique in the substance defect correction domain, by using the newest and most perforant types of flaps [7].

The purpose of this paper is to compare the rat experimental model to skin grafts in humans. Also, this paper wants to use imaging techniques as a method in the detection of the main perforating vascular branches on the whole body surface and the imaging cartography as real territorial maps of the identified vascularizing perforators.

MATERIAL AND METHOD

The investigations were performed in the Radiology and Veterinary Imagistic Laboratory of the Faculty of Veterinary Medicine, Cluj-Napoca, in the Radiology and Imaging Laboratory of the Rehabilitation Clinical Hospital, Cluj-Napoca, in collaboration with the Surgery Clinic of the Faculty of Veterinary Medicine, Cluj.

Choosing the rat lines. To perform the research, we used a line of Wistar rats because of the following: it is a line with a tranquil behavior, it has a high docility degree in experimental maneuvers, it is widely spread because it is highly adapted to raising and captivity conditions, it is infection resistant, it is a line of rats in which the spontaneous tumor incidence is small [1, 2, 4, 3, 9, 10].

After applying microsurgical dissection and evidentiation of the perforant vessels in the first stage, and also after analyzing the main characteristics of these vessels, we have performed isled tegumentary flaps, based on a single perforating vessel in a certain region. By performing these flaps, we wanted to demonstrate their viability in the conditions of a single vascular approach, represented by the perforating vessel, after all other vascularization sources were removed, and after the vascular territory corresponding to the vessel by quantifying the necrosis surface was identified. Depending on the vascular source, two lots were formed: lot I had flaps that were based only on the perforating vascular package and lot II, with flaps based on both the perforating vascular package and a superficial vein. In addition, certain local factors that might affect the flap's viability were taken in consideration.

For the Doppler pre operation ultrasound exploration and the angiographic explorations, the rats were prepared through light ether anesthesia, then by administering Vetased –Ketaminol (hydrochloride ketamine) in a combination with Xylazine Bio 2% for veterinary use (hydrochloric xylazine) intramuscularly. The combination we used produced anesthesia, analgesia, and rapid muscular relaxation. For prolonging the anesthetic effect, a new dose was administered after an hour (1/2 from the initial dose). The quantity we administered initially was 60 mg/kg (0,6 ml/kg) Ketaminol 10 and 6 mg/kg (0,3 ml/kg) Xylazine Bio 2% (a ratio of 2/1) [5].

Pre operation Doppler investigation in rats. Examination was performed with a highly performing ultrasound machine of the last generation 2008 GE Logiq 9, with linear, high resolution traductors, with a variable frequency of 9 - 14Mhz an GE Voluson 730 Expert Pro ultrasound machine with a linear traductor with a a variable frequency of cu 10 – 14 Mhz (fig. 1, 2).

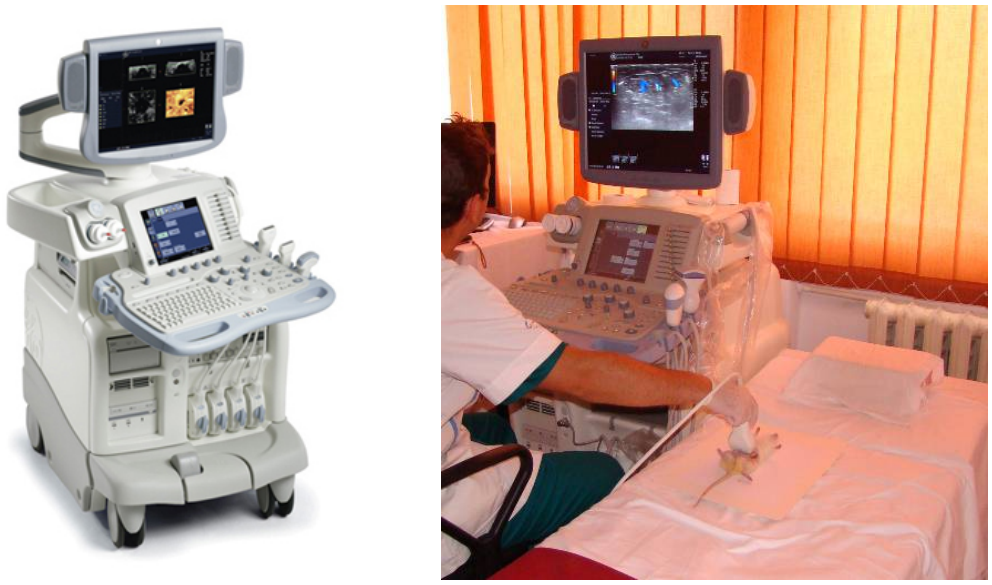

Fig. 1 Pre operation Doppler ultrasonography - GE Logiq 9

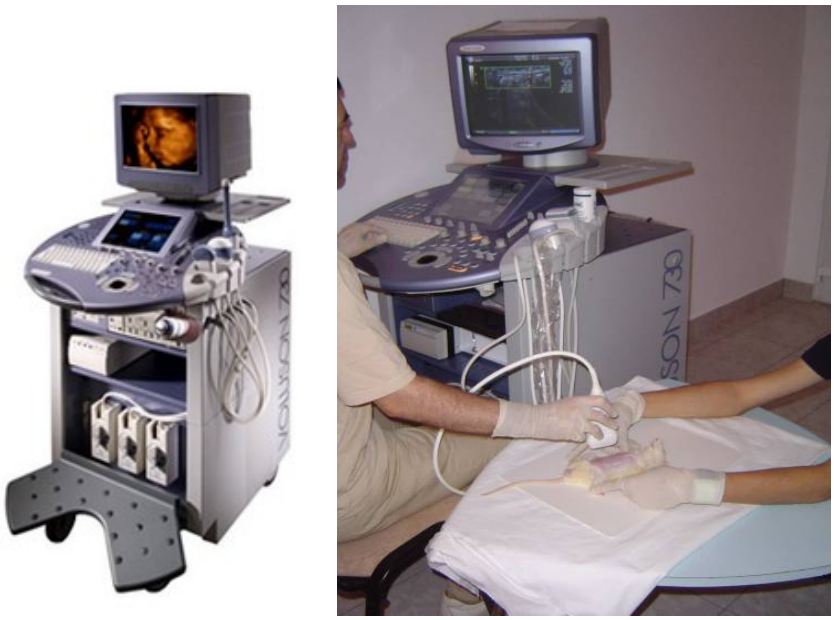

Fig. 2 1 Pre operation Doppler ultrasonography – GE Voluson Expert 730 PRO

Pre operation angiographic investigation in rats. The angiographic examination of the rats was performed by a SIEMENS Coroskop Top angiograph C-arm model, with a digital acquisition system (DAS), image enlargement option, digital cine mode (DCM) and serigraphy (fig. 3).

Fig.3 Rat positioning and fixation on the angiography table

The rats were immobilized on the operating field, directly on the angiography table. For the angiography of the perforating vessels from the anterior abdominal wall, we preferred to approach the interest zone through a canula set at distance (aortic arch through the common carotid artery) because preoperative catheterization of the epigastric arteries would have lesioned these vessels that later will become irrigation sources for the flaps that are based on perforating vessels, which have necessitated larger quantities of iodated contrast medium [6, 8, 9]. The rats were shaven in their carotid region on a surface of 5cm^2 and placed in a dorsal position, with their members immobilized with the help of a plastic clip on the sterile operating field. The head was not immobilized at all (fig. 3). By using a surgery microscope, a longitudinal incision was made on the antero-lateral side of the neck. The common carotid artery (CCA) was isolated and was separated

from the adjacent veins and nerves. A very thin 29 G catheter, with an external diameter of 0,4 mm was retrograde inserted at the level of the common carotid artery towards the aortic arch and then towards the descending aorta (fig. 4).

The substance we used was Omnipaque 300 mg I/ml, injectable solution for intravenous use, with an osmolarity of 0,6411 Osm/kg, viscosity of 66,1 at 37 degrees Celsius. The active substance was Iohexol (INN) 300 mg I/ml647 mg equiv. 300 mg I. Iohexol is a contrast media for X rays that is non ionic, monomeric, triiodated, hydro soluble [6].

Fig.4 The catheter connected to the syringe with contrast medium is directed towards the aortic cross

RESULTS AND DISCUSSIONS

Results we obtained after the ultrasonographic examination

To evidentiate the cutaneous perforating arteries in the abdominal area, the area was scanned sagitally from the left of the animal to the right, using the Doppler Power scanning modus (fig. 5). Scans have identified local perforating vessels (fig. 6)

Fig.5 Longitudinal scanning in the anterior abdominal wall

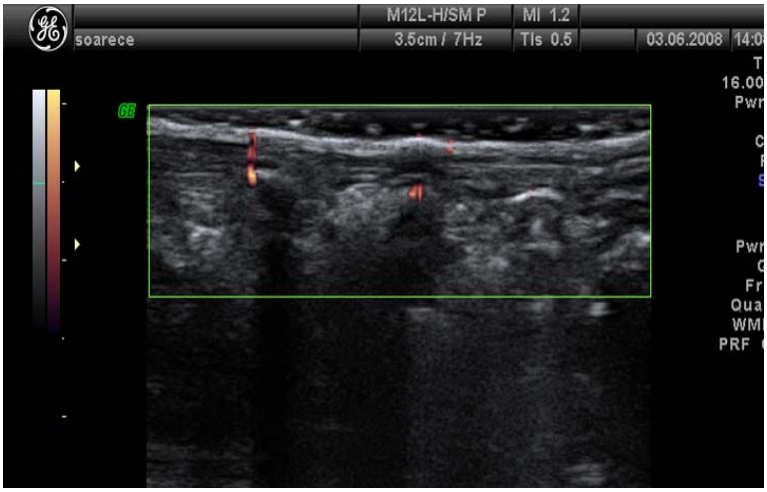

Fig. 6 Identification of the perforating vessels by the Doppler Power technique

In the area ahere we identified a perforating branch, we also performed a transversal scan to confirm the result in order to lower the artifact risk.

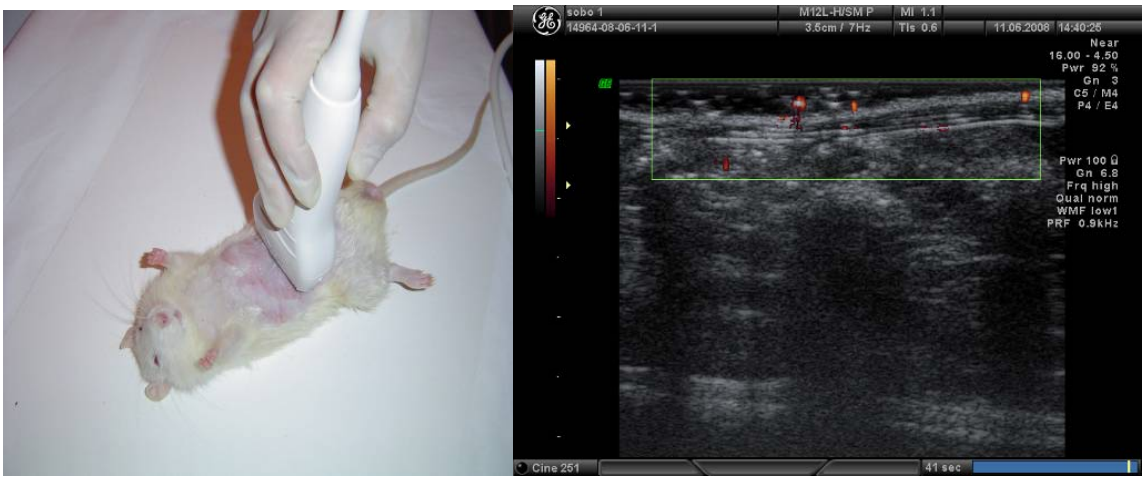

Fig.7 Transversal scan for the correct localization of the perforating vessel

Results we obtained after the angiographic exmination. After the angiographic examionation through contrast medium administration, this has both the aorta in its abdominal segment and its main emergent branches opacified (fig. 8, 9).

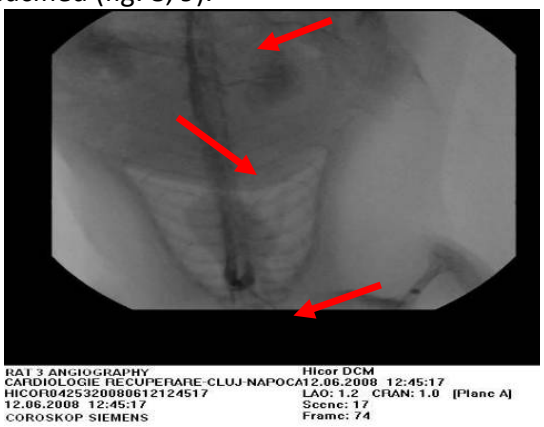

Fig.8 The contrast medium has opacified the whole descending aorta and the main emergent arteries

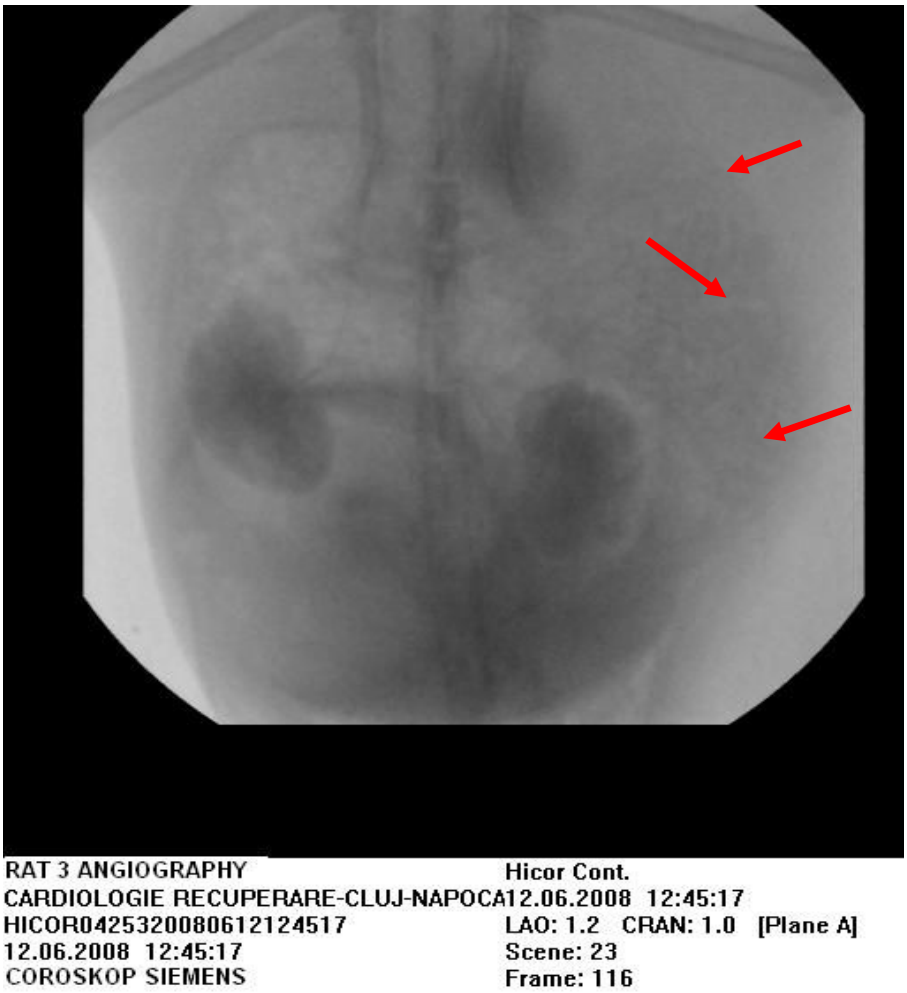

Fig.9 The contrast substance has reached the superficial abdominal vessels (superior and inferior epigastric)

After the opacifying of the superficial vessels of the abdomen (superior and inferior epigastric artery), we rotated the mobile arm of the angiograph so to be able to examine the anterior abdominal wall transversally (fig. 10).

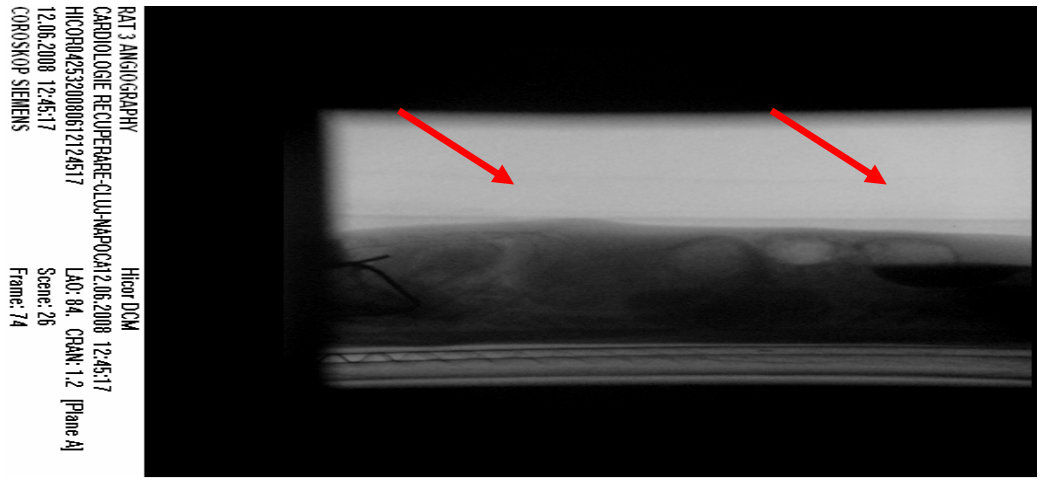

Fig.10 Arterial perforating vessels in the anterior abdominal wall – lateral view

Lot I. The dissection of the flap based exclusively on the perforating artery starts with the incision of its borders, which were marked according to the established anatomical marks. The skin flap is than lifted from laterally towards medially on its both margins, in a plane that is situated profoundly towards the paniculum carnosum. By magnifying 6x glasses, the perforating vessels through the right abdominal muscle fascia are identified, distance between them is measured and then it is written down in the 16 equal spaces that the flap was divided in. The flap is based on a single perforating artery, chosen by the criteria listed before (fig. 11, 12).

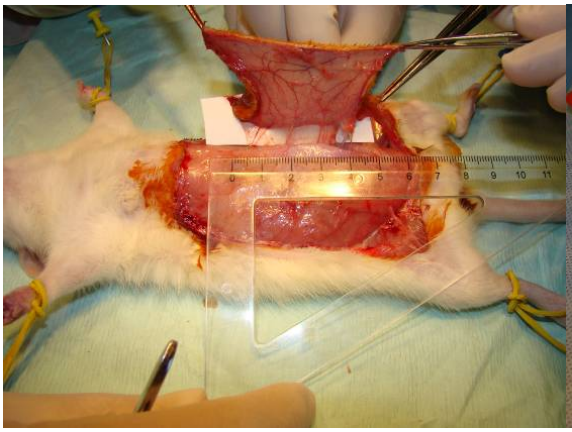

Fig.11 Marking and sectioning the skin flap

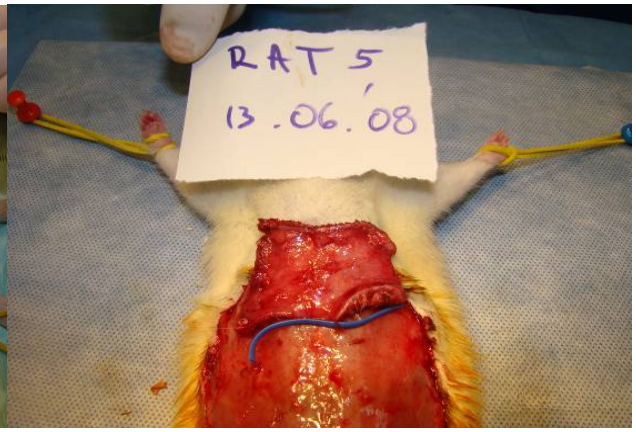

Fig.12 Lifting of the flap

The operation field was irrigated permanently with sterile saline. We did not use 2% Lidocaine as a local anesthetic to prevent arterial spasms because it has been noticed that it can be absorbed in toxic doses for the animal.

In all animals, after lifting the flap, it was reapplied in its original bed without any rotation and then sutured by a non resorbable 4-0 suture material (initially, the corners were fixated by separate threads, and then the margins were sutured continuously (fig.13).

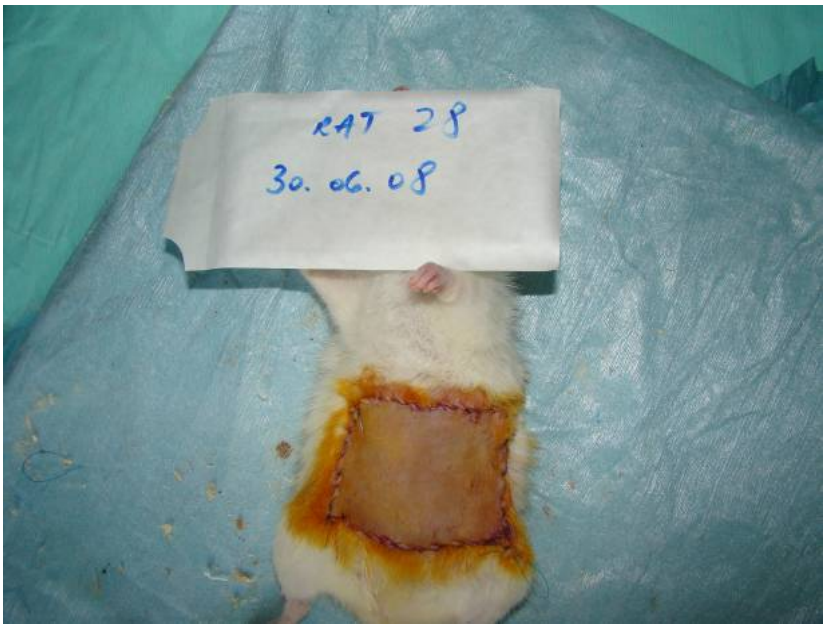

Fig.13 Suturing the flap after a complete lift

Lot II. In the rats of the second lot, the flap was lifted with a similar technique, but after choosing the perforating artery, the superficial counter lateral epigastric package is isolated up to the level of the femoral vessels by keeping the vein at that level intact ea (the nerve and artery have been sectioned) (fig.14).

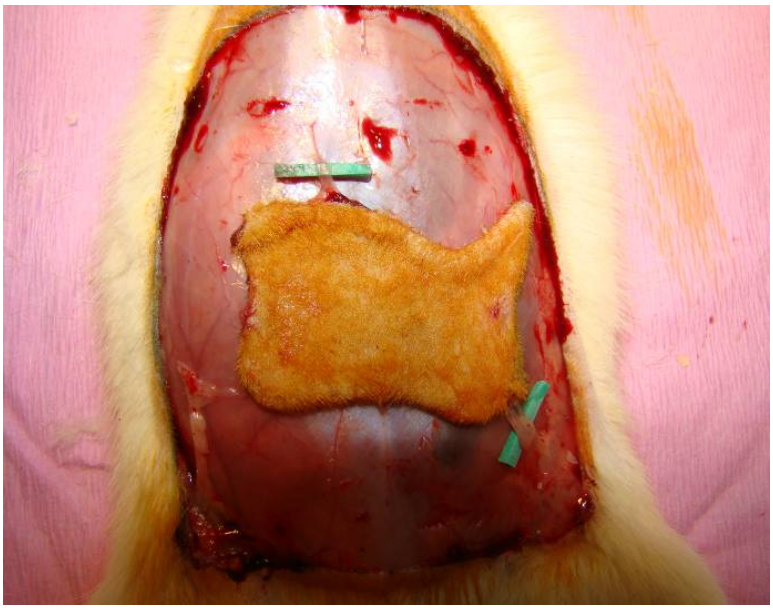

Fig.14 Preparing the flap by keeping the local vein intact

Post operative care of the flaps. It was performed daily for a period of 7 days until the rats were sacrificed. The surface of the flaps was arbitrary split in 5 interest areas represented by 5 concentric circles with the center at the kept perforating artery and a radius that was raised by 1 cm from 1 cm to 5 cm (fig.15). In this interest area we directly observed the color of the flap (normal, pale, hyperemic, cyanotic); capillary pulse (present, absent, accelerated, decreased) and also on the identification and follow up of the necrosis area progression, all these being written down in tables with the clinical evolution, by area.

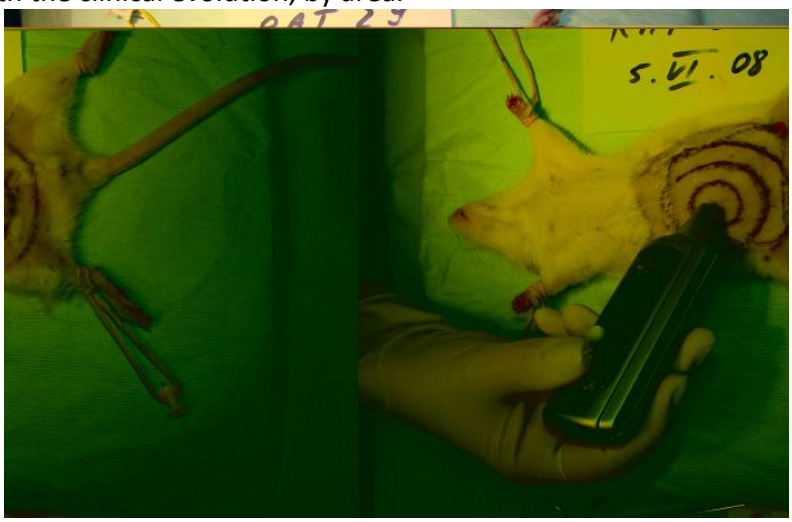

Fig.15 Post operative care of the flaps.

In the same time interval and on the same interest areas, we measured tegumentary temperature (determined daily at the same hour). This was also measured during the surgical intervention for

four times: before the flap incision, immediately afterwards, after the flap lift and immediately after resuturing the flap (fig.16).

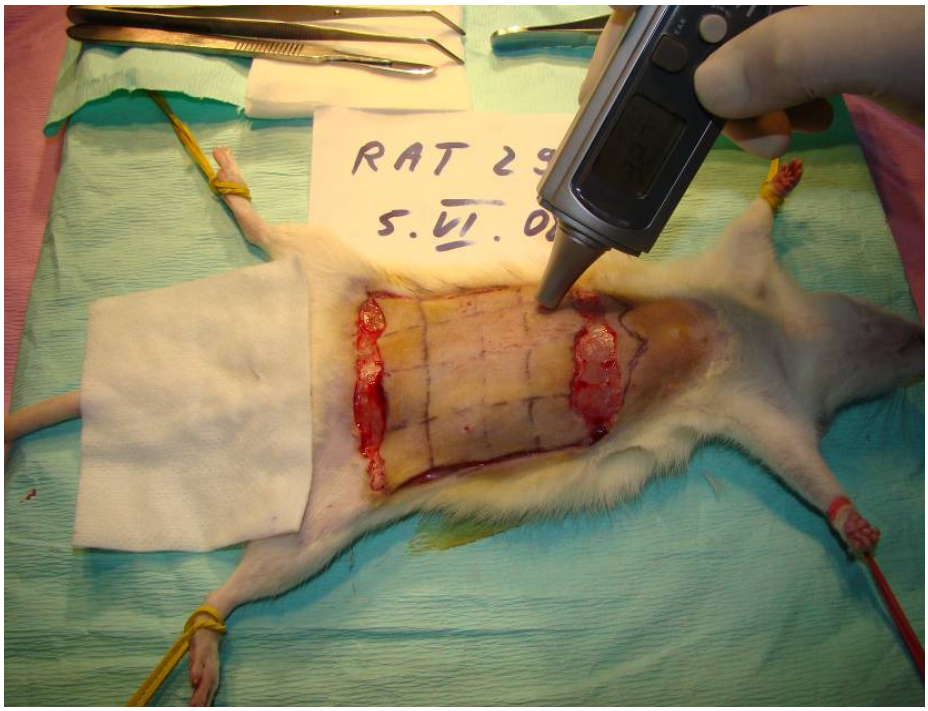

Fig.16 Postoperative care of the flaps

CONCLUSIONS

Based on the obtained data we can conclude the following:
In the cartography and identification of the muscle-cutaneous perforating vessels or fascia cutaneous vessels in rats, the imaging techniques and nonionic substances hold a determining role the imaging techniques and nonionic substances.
Among the unquestionable advantages of the cutaneous flap on the perforate vessels there are: the multitude of donating areas, higher liberty in the drawing and sampling of the cutaneous flap, intact keeping of the major vascular axes (especially in the local cutaneous flap cases and regional cutaneous flap cases); higher security in the conditions of a correct surgical technique.
The perforating vessels in rats are described from one anatomical region taken into study to another, and they differ from area to area.

1. *In the anterior rat limb* we evidentiated two perforating vessels on the internal flap, in the proximal 1/3 level, respectively in the medium 1/3 level of the arm. The dissected vessels have a very low caliber, of 0,1 mm, the upper muscular projection is short (2-3 mm), and it becomes curvy for the next 5-6 mm after approaching the skin flap, and then it branches out to form the tegumentary vascular net.
2. *In the posterior rat limb,* there are 2-3 perforating muscular cutaneous packages that originate in the gracilis muscle. The perforating vascular packages are dissected in the muscular plane too and they are isolated up to their origin in the artery that assures vascularization of the two gracilis muscles (anterior and posterior), the branch from the femoral artery. In the experimental models, only one perforating vessel was constantly evidentiated, in the proximal 1/3 third of the calf, muscular cutaneous, out of the gracilis, with proper size to allow the sampling of a skin flap. Dissection is continued laterally, where two other perforating vascular packages are evidentiated, from the distal 1/3 part of the

right femoral muscle. The vascular packages are further dissected in the muscle plane, and they are isolated up next to the lateral femoral circumference, where they originate from. These perforating vessels have a low and curvy caliber over the muscle.

3. *In the posterior thorax of the rat,* there are about 6-7 perforating vessels, metamerically disposed, of relatively identical dimensions, paramedian, projected on the vertical line that passes the tip of the scapula.
4. *In the lumbar region of the rat,* we identified about 6 perforating vessels, situated at abut one cm from each other, of relatively identical size, going trough the muscle towards the skin, 0,5 cm paramedian, bilaterally.
5. *In the anterior region of the thorax in rats,* we identified about 6 perforating vessels, situated at abut one cm from each other, of relatively identical size, going trough the muscle towards the skin, 0,5 cm paramedian, bilaterally. Their dissection is continued at a muscular level too, until their origin is met, the internal mammary gland artery.
6. *In the abdominal region in the rat,* paramedian, 0,5 cm from the right abdominal muscle, there are about 5 perforating arteries crossing the muscle beginning from the xiphoid appendix, disposed segmented, at about 1 cm apart. These muscular cutaneous perforating vessels have a constant large caliber; parallel to each other and oblique from medially towards laterally and cranially towards caudally. The length of the supramuscular area is of a constant 1-1,5 cm. The dissection is continued profoundly to assess the muscular projection and the origin (superior epigastric and inferior epigastric).

REFERENCES

1. Brăslaşu, C. M., Popescu, Al., Filipoiu, F.M., Papuc, I., Brăslaşu, D.E., (2001), Anatomie cardiovasculară clinică la animalele domestice, Pro-consul Internațional Bucureşti.
2. Blondeel, P. N., Arnstein, M., Verstraete, K., et al., (2000), Venous congestion and blood flow in free transverse rectus abdominis myocutaneous and deep inferior epigastric perforator flaps. *Plast. Reconstr. Surg.* 106: 1295,.
3. Chiricuță I, Bologa S, Ghergariu S, Riscă R., (1992), Biologia animalului de laborator şi oncologie comparată, Vol 19.
4. Coskunfirat Ok, Oksar Hs, Ozgentas He., (2000), Effect of the delay phenomenon in the rat single-perforator-based abdominal skin flap model. Ann Plast Surg.;45:42-47
5. Oană, L., Timen, A., Beteg, F., (2006), Anesteziologie şi propedeutică chirurgicală veterinară, Editura Risoprint, Cluj-Napoca, 305 pagini.
6. Thrall, Donald, (2007), Textbook of veterinary diagnostic radiology, Ed. Saunders.
7. Rodriguez A, Alvarez A, Martelo FR., 2007, The anteromedial thight flap as a training model of a perforator flap in rat. J Rec Microsurg:23;251-256.
8. Salmon M., 1988, Arteries of the skin. In: Taylor GI, Tempest M, editors;; Churchill & Livingstone.
9. Sano K, Hallock GG, Wasser TE, Robson PA, Rice DC., 2001,Comparison of a new method for computer analysis with standard techniques for measuring survival rates in the rat transverse rectus abdominis musculocutaneous fl ap. Ann Plast Surg.;47(6):647-51.
10. Seaber AV., 1985, Laboratory design in preparing for elective microvascular surgery. Hand Clin;1:233–245.

ENDOSCOPICAL AND SURGYCAL COMPLEX TECHNIQUES FOR THE DIAGNOSTIC AND TREATMENT OF BONEY FOREIGN BODY RETAINED IN THORACIC ESOPHAGEAL SEGMENT

D.C. LESCAI'[1] F. DUMITRESCU,[1] ADELA MENDEA,[1] L. HARBUZ,[1] I. BURTAN[2]

[1]Salvavet-Ilioara Animal Hospital Bucharest
dan.lescai@salvavet.ro
2Faculty of Vet. Medicine Iassy

SUMMARY

This is a study that reveals its benefits in some highly life threatening situations for dogs that try to swallow bones that get retained into esophageal segments that are difficult to reach under common surgical procedures. This is the situation of a thoracic vertebra part that is retained in the thoracic part of the esophagus for more then 2 months in a small breed dog with persistent disphagya and odinophagya. The complex techniques involve endoscopical examination and intervention and also laparatomy and gastrotomy. These procedures are being done in the same time as only one of them is not sufficient for the removal of the foreign body. There are several risks that come with this situation some of them being fatal heart failure following local vagal trauma, mediastinal effusion, further esophageal trauma, hemorrhage and on the long term esophagitis and esophageal strictures.

Key words: endoscopy, foreign body, surgery, esophagoscopy

The patient is Roony, a 4 years old toy Schnauzer, 9 kg b.w. that has a history of eating bone parts. Roony is presented for second opinion on 19.02.2010 after a treatment for esophageal trauma consecutively to bone parts passing. Since 25.12.2009 Roony is experiencing odinophagia and disphagia, is reluctand to eat solid parts and prefers liquid or soft food, weight loss and sometimes coughing and lethargy. Several days ago, Rooney started to feel worse with the body condition alterating from day to day, making the owner to seek medical care for the pet. The body temperature is within normal range. After the clinical consult two x-ray exposures are being made, one on the lateral aspect of the animal and another one in ventro-dorsal position, in order to role out or confirm any foreign body or any thoracic effusion after an esophageal disruption.

MATERIALS AND METHODS

The first x-ray is the lateral one and reveals that between the 2nd and the 4th rib, in the upper thorax, superimposed on the tracheal profile, there is an elliptic shape with boney structure that is considered to be a bone part foreign body in the thoracic part of the esophagus. The ventro dorsal x-ray concludes that the structure seen on the lateral x-ray is obstructed by the vertebral column.
At this point the diagnostic is esophageal boney foreign body and is considered an emergency. All preparation are being done for an esophageal endoscopical examination, esophagoscopy. For this, a Karl Storz flexible videoendoscope is used, with a working length of 140 cm and 0,9 cm wide tip. The system also has a suction pump, xenon light and working tools of different types (1).
An intravenous catheter is put in place and the fluid therapy is instituted using Ringer`s lactate. Intravenous antimicrobial therapy is supported with Fortum (ceftazidine) at a rate of 250 mg

every 12 hours. The tranquilization and induction process is conducted with diazepam and ketamine i.v. , 0,5 mg/kg diazepam and 1 mg/kg ketamine (2). After the onset of medication the patient is intubated and a flow of isoflurane is set and all major functions are being monitored.
A mouth gag is used and the pacient is on abdominal position in order to begin the endoscopical examination. The endoscope tip is advanced through the mouth gag and the proximal esophageal sphincter is reached and penetrated. A small volume of air is insufflated (in case of esophageal rupture this air or liquid could pass into the mediastinum area) and along with the esophageal distention the mucosal aspect is being noted.

Fig. 1. Radiograph showing the foreign body between the 2nd and the 4th rib

Fig. 2. Endoscopical image of the heart base esophageal foreign body-bone

Advancement of the endoscope reveals on the cardiac area the foreign body, of yellowish color, solid boney structure. The local mucosa is examined and all local aspects are investigated.
Based on current findings a grasping tool is advanced through the working channel. Several attempts are made to displace the foreign body and to pull it out. Unfortunately all tries are without success, the object could not be satisfactory displaced just by endoscopical procedures. Also, several attempts were made to displace the object by pushing it towards the stomach using the tip of the endoscope with caution, in order not to destroy tip camera or chipset. During these procedures the tip of the endoscope could even be passed by the boney foreign body and distal part of the esophagus could be examined. During all endoscopical procedures caution was taken into account because all of the air or fluid used could build up in the stomach influencing, if reaching a high degree, the heart and pulmonary activity (1).

Fig. 3. Grasping forceps on the foreign body

Fig. 4. Mucosal tearing at 6 o`clock and lateral mucosal damage

In conclusion, all preparations are performed for laparatomy and gastrotomy, in order to approach the foreign body through the distal esophageal sphincter.
For this, the animal is placed on ventro-dorsal recumbence and the laparatomy is begun.
Throughout the surgical procedure the object is observed with the endoscope. After the laparatomy the stomach is reached and standard gastrotomy is performed. A long foreign body forceps is passed through the distal esophageal sphincter and the bone is grasped under guidance using the endoscope for visualization. In this way the object is reached from behind and visualisation from the front of it, using endoscopy. Following this procedure the bone fragment suffers little position alteration, with little backwards or forward movement. During this procedure there is significant haemoragy that is drained throuth the suction pump. Extreme caution is used when pulling force is applied over the object, considering the inflamation and necrotic process that is hosted in this segment, on site ruptures or total esophageal wall perforation during procedures being the great dangers that come with the surgical maneuvers (3).

Fig. 5. Hemorrhage secondary to foreign body displacement

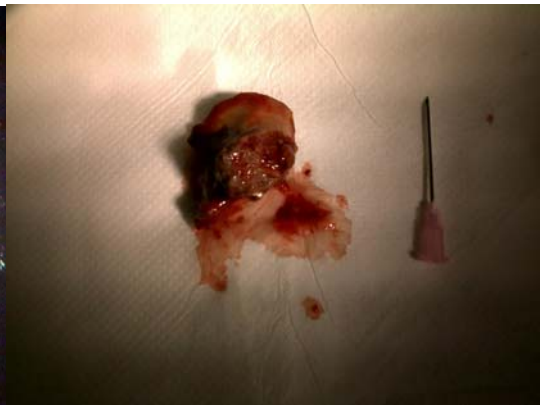

Fig. 6. The foreign body after removal

Consecutively the object is being pushed forward and a significant distance of 2 cm is obtained. The advancement of the object is visualized with the endoscope and the local mucosal tearings are observed along with significant hemorrhage. Afterwards the object has been grasped with the grasping endoscopical tool and forced out through the mouth. The bone part is a large 2/3 piece of thoracic vertebra resulted from a pig slaughter. Following this maneuver the endoscope is pushed back into the esophagus for mucosal assessment. Local modifications consist of mucosal multifocal hemorrhage, mucosal tearing, cyanotic spots that are though to be superficial necrosis and debris.
Gastroraphy and closure of the abdominal cavity are the last surgical procedures and reanimation is begun. During the surgery there were observed cardiac symptoms as bradycardia and arrhythmia and respiratory depression. After 30 minutes post surgery Roony is breathing normally and is beginning to wake. After 4 hours postsurgery and the next day there are 2 episodes of blood vomiting.

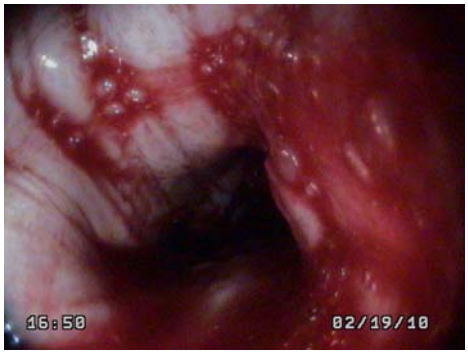

Fig. 7. Endoscopical assessment of local modifications after foreign body removal

After 3 days of inpatient Roony is sent home with Synulox 250 mg/kg b.i.d. for 14 days, omeprazol 40 mg s.i.d, 3 weeks, moist diet Purina Recovery or CN, rest and a clear indication of not eating bones again. 14 days after the surgery Roony is feeling perfect, is joyful and continuing his recovery.

RESULTS AND DISCUSSIONS

This is an example of a serious life threatening case of extreme long term foreign body retention on the heart base area of the esophagus. It is of first intention to proceed with endoscopical procedures because of the difficult to surgically approach area and of the small invasiveness. Endoscopy also offers the advantage of assessing local modifications before and after object removal. If the endoscopical maneuvers are insufficient or unsuccessful classic surgery is the next step. Still, with laparatomy and gastrotomy, endoscopy is a full of benefit procedure, considering the on site guidance, assessment and finally curative intervention. This is not a case of classical surgery or of endoscopical procedures but a combination of the two, resulting in complex surgery, caused mainly by the local tightness and deep penetration into esophageal wall of the sharp edges of the foreign body. Furthermore, it is well known that this part of the esophagus is one of the three parts that are susceptible to foreign body retention, along with the cranial thorax opening and gastro-esophageal sphincter, the most difficult area to reach, considering the risks of cardiac arrest and local access being the heart base.

CONCLUSIONS

1. In case of heart base esophagus foreign body, that have sharp edges, endoscopy is the best diagnostic tool, considering the local assessment advantage, minimal invasiveness and possibilities of removal.
2. In all cases of heart base esophageal foreign body, before the endoscopy, it is indicated to perform x-rays that could identify thoracic effusions following total esophageal penetration or other thoracic pathology that could interfere with endoscopy.
3. In the case of failing to remove by endoscopic procedures the foreign body, always a surgical team should be prepared.
4. Combined techniques of endoscopy and surgery should be performed in order to successfully remove the retained body after radiological survey and clinical assessment.
5. After the surgery and in the recovery period the endoscopic examination is the best choice to assess local modifications and healing or the developing of secondary esophagitis, ulcers or strictures.
6. From our experience, the heart base esophagus is by far the place most common for foreign body retention.

REFERENCES

1. **Dumitrescu, F., Lescai, C.D.**, - Practical course of canine digestive endoscopy, Course notes, Salvavet-Ilioara Animal Hospital, Bucharest, 2010
2. **Theresa Welch Fossum**, Small animal surgery textbook, Mosby, 2007
3. **Todd Tams**, Small animal endoscopy, Mosby, 1999

OBSERVATIONS ON THE ELECTROTHERAPY USE FOR THE POSTOPERATIVE FRACTURE RECOVERY IN DOG

LAURA LIVITCHI, A. MUSTE, F. BETEG, I. SCURTU

Veterinary Medicine Faculty, University of Agricultural Sciences and Veterinary Medicine Cluj-Napoca, 3-5 Manastur Street, Cluj-Napoca, Romania;
laura_livitchi@yahoo.com

ABSTRACT

Stimulation of the body's natural physiological healing processes with physical methods of treatment is an old therapeutic principle. Changes in rate of healing are most readily apparent clinically in superficial tissues where regeneration can be closely observed, and where the penetration of electrical energy can have a direct effect on cellular activity and vascular changes. Observations were made on a total of 10 dogs with different bone fractures. Treatment was performed with electrotherapy device Interferenz 3 Med-mode system, Bosch brand, with circular suction electrodes. After diagnosis and surgical correction of fracture, we used the application of electrotherapy from the second day postoperatively. Individual treatment was established after a standard therapeutic scheme, the scheme being modulated according to individual evolution. Throughout the treatment period, were monitored following clinical signs: the development of inflammatory process, presence of suppurative processes and sero-sanguinolent collections, the development of pain, resumption of limb motor function and performance support.

Key words: electrotherapy, recovery, fractures healing, dog.

INTRODUCTION

Electrotherapy is an umbrella term to identify a range of treatments ranging from electrical stimulation for muscle strengthening, to the use of sound waves (ultrasound) and light (laser) to treat physical injuries.

There are four broad types of electrotherapy in routine clinical use, including:

- electrostimulation (for pain relief and for stimulation of nerve and muscle, e.g. transcutaneous electrical nerve stimulation (TENS); neuromuscular electrostimulation (NMES);
- interferential therapy (IF);
- ultrasound therapy;
- laser therapy.

Electrical stimulation has been used as a therapeutic method for enhancing bone healing for a long time. Based on the fact that bone tissue manifests electric potentials both in normal and pathological states (Friedenberg, 1966), electrical stimulation has been employed to induce osteogenesis in clinic for a long time.

This form of therapy cannot correct etiological links, but can improve and correct:

- pathophysiological factors: inflammation, edema, hypotonia, and muscular hypotrophy;

- clinical, symptomatically and functional factors: pain, muscle contractions, and muscle stiffness;

Therefore, the therapeutic indications of interferential currents are states such as:

- posttraumatic states, bruises injuries (fractures, sprains, luxations, bruises without bone lesions, hematoma);
- joints sufferings (arthritis, periarthritis, arthrosis);
- painful affections of the spine (spondylosis, spondylitis, neuromuscular pain, bruises);
- neuralgia and neuritis;
- paresis sequels of limbs, in remission.

In recent years, fundamental studies have gained insights into the effects of electrical stimulation in bone on a cellular and molecular basis. It is suggested that electrical signals might initiate bone formation and remodeling through modifying the functions of bone cells. Studies show that electric fields affect various cellular behaviors such as cell migration, proliferation and alkaline phosphatase activity.

Acceleration of fracture healing has been demonstrated in a series of studies using these electrical stimulations. For instance, increased new bone formation was observed in animal models with the application of different amplitudes of electric currents.

The aim of the study was to work for implementation of the electrotherapy procedures in postoperative recovery of fractures and emphasizing their beneficial effects on healing.

MATERIALS AND METHODS

The study was conducted in the Surgery Clinic of the Faculty of Veterinary Medicine from Cluj-Napoca, during 2008-2009, on a number of 10 animals of canina species, from different breeds and ages, which were submitted in consultation with fractures in different legs and areas.

The treatment was performed with the electrotherapy device Med-Mode System Interferenz 3, mark BOSCH (fig. 1), with circular suction electrodes. A vacuum suction unit provides the vacuum.

The study included several parts, namely:

1. Setting the correct diagnosis by radiological examination (fig. 2);
2. Surgical correction of fracture;
3. Postoperative treatment with different electrotherapy protocols.
4.

Fig.1. Med-Module System Interferenz 3 electrotherapy device, BOSCH brand., and BTL vacuum suction unit.

Fig. 2. Setting the correct diagnosis by radiological examination.

After diagnosis and surgical correction of fracture, we used the application of electrotherapy from the second day postoperative. Electrical stimulation therapy began in the 2nd postoperative day, and was applied for two weeks (from previous research that is known that electrotherapy affects callus development only in the stages 2-3 (Chun Peng Huang, 2008)).
Depending on the seat of fracture and its depth, is established the electrodes application spot (Millis *et al.,* 2004). Electrodes application spot is prepared by hair cutting and shaving, in order to perform the vacuum needed for electrodes fastening on the skin.
Individual treatment was established after a standard therapeutic scheme, the scheme being modulated according to individual evolution. In our cases, the parameters used were the following:

- intensity of 6-8 mA;
- frequency of 80-100 Hz;
- duration: sessions of 10 minutes, one session per day during the first week, and the next 2 weeks one session in 2 days.

A meeting itself of electrotherapy involves performing the following steps:

- positioning the electrodes on the skin;
- conducting the vacuum under electrodes by the aerator switch torsion to right until reaching a value of approx. 0.4 kg/m2;
- duration of session setting;
- frequency setting;
- setting the intensity on 0;
- startup the current application;
- increasing the intensity gradually until we reach the fixed intensity, and before the end of the session, reductions slowly, gradually, till 0.

Electrodes were applied so that the currents interference to contain the outbreak of the fracture center (fig. 4.).

Fig. 4. Placing electrodes in the affected region.

Throughout the treatment were monitored following clinical signs:

- development of inflammatory process;
- presence of suppurative processes and sero-sanguinolent collections;
- development of pain;
- resumption of limb motor function and performance support.

RESULTS AND DISCUSSION

Patients showed no side discomfort during treatment application, and no lesions occurred on the skin (burns or congestion) due to current application. During treatment patients showed a state of comfort due to physical sensation of massage carried out with vacuum electrodes.
The use of suction electrodes adds another form of sensory stimulation to complement that produced by the interferential treatments. The (rhythmically varying) negative pressure produces a “massage-like” effect that gives a state of physical comfort (G C Goats, 1990). The aspiration deep massage reduces the electrical resistance of the tissue, increasing the tissue conductibility of the interferential currents through better liquidity allocation under the electrodes (Radulescu, A., 1991).
Inflammatory processes were greatly reduced compared with patients who had conventional recovery and the presence of suppurative processes and the collection was greatly reduced to absent. Clinical signs of pain were much weaker and in a much shorter period. States resumed motor function and performance support more quickly (fig.5).

Fig. 5. Resumption of support was achieved during the first week after surgery (stitches are the evidence).

Using the combination of intensity of 6 mA, frequency of 80-100Hz and sessions of 10 minutes, we had the best analgesic effect. Regarding the intensity, it is known that the intensity under 8mA is used for sensory stimulation, and the intensity over 8mA for motor stimulation.

CONCLUSIONS

After conducting this study regarding the effect of electrotherapy in the postoperative recovery of fractures in dogs, we reached several conclusions:

1. Electrotherapy hastens fracture healing by reducing inflammation and postoperative pain and reducing the number of days of convalescence;
2. The animal resumes faster and more efficient motor function of the affected limb and makes support more quickly;

3. Electrotherapy is a non-invasive method that potentates the medical treatment, not a unique therapy in the postoperative recovery of fractures.
4. The electrotherapy variant with interferential currents is advantageous because it can handle very deep areas with very little damage to the skin.

REFERENCES

1. A.M. Phillips (2005). Overview of the fracture healing cascade. Injury, Int. J. Care Injured 36S, S5—S7.
2. Chun Peng Huang 1, Xin Min Chen, Zhi Qing Chen (2008). Osteocyte: The impresario in the electrical stimulation for bone fracture healing. Medical Hypotheses 70, 287–290.
3. Friedenberg CT, Brighton CT. Bioelectric potentials in bone. J Bone Joint Surg Am 1966; 48: 915–23.
4. G C Goats (1990). Interferential current therapy. Br J Sports Med.; 24(2): 87–92.
5. Low, J, and A. Reed (2000). Electrotherapy Explained: principles and practice (3rd ed.), Butterworth-Heinemann, Oxford.
6. Rădulescu, A. (1991). Electrotherapy. Medical Editure, Bucharest.
7. Strong, J., A. M. Unruh, A. Wright and G. D. Baxter (2001). Pain: A Textbook for Therapists. Churchill. Livingston, London: 215-217.

THE USE OF ULTRASONOGRAPHY IN GASTROINTESTINAL DISEASE IN DOGS

R. N. MĂLĂNCUȘ, Gh. SOLCAN, Cristina Tofan (MALANCUS)

ABSTRACT

The importance of gastrointestinal disorders arise from the fact that they are one of the most common cause of presentation to clinicians. Thus, formulating a clear diagnosis is a ”must do” in determining disease, using ultrasound technology with great value in that it can detect inner lesions, thus observing the location of the gastrointestinal pathological processes. Investigations were conducted on 36 dogs of different breeds and ages, of whom 12 cases representing 33.33% showed only gastric disorders, 9 subjects representing 25% only intestinal disease and the remaining 15 cases, representing 41.77% showed associated gastric and intestinal disorders. Ultrasound-diagnosed disease were represented by gastritis (24 cases), pyloric hypertrophy (three patients), enteritis (22 cases) and intussusception (two cases).

Key words: ultrasonography, intussusception, gastritis, enteritis

INTRODUCTION

Ultrasound and radiological techniques are most often used for observation of gastric and intestinal segments. Advantages of ultrasonography over radiological examination regarding the observation of the gastrointestinal tract are conferred by the fact that ultrasonography is a non-invasive procedure that does not use ionizing radiation. The whole thickness of stomach or intestinal wall can be visualized and measured, as well as adjacent structures such as lymph nodes. Also can be assessed the gastric and intestinal motility, observing the peristaltic movements in real time.

MATERIALS AND METHODS

Investigations were conducted on 36 dogs of various breeds and ages that were presented during the March 30, 2009 to May 1, 2010 in the Medical Clinic of Faculty of Veterinary Science from Iași. Subjects presented to specialist consultation by owners have been examined clinically and using the ultrasound technique to confirm with certainty the diagnosis of gastrointestinal disease. Ultrasonography was performed with Aquila Pro Vet veterinary echograficmachine presenting 5 and 7.5 MHz probes.

RESULTS AND DISCUSSION

During the investigations were conducted in the Medical Clinic had presented 767 dog of different breeds and ages, of whom 12.77% and a total of 98 patients presentef gastrointestinal disorders. Ultrasound was performed in 36 of them, considering it appropriate to conduct such additional examination to determine with certainty the diagnosis.
Of the 98 subjects with gastrointestinal disorders 33 had only gastric disease, 23 only intestinal disease and the remaining 42 dogs had associated gastrointestinal disorders.

The 36 cases which were investigated using ultrasound technique were distributed in three categories:

- exclusively gastric disorders;
- exclusively intestinal disorders;
- associated gastrointestinal disorders.

Of the 36 patients, 12 cases representing 33.33% had exclusively gastric disorders, nine subjects representing 25% had only intestinal disease and the remaining 15 cases, 41.77% from the total number of investigated patients had associated gastric and intestinal disorders.

The importance in the study showed the 36 dogs with gastrointestinal disorders which were examined ultrasonographicaly to determine with certainty the disease.

Research undertaken for the period March 30, 2009 to May 1, 2010, allowed identifying the main types of gastrointestinal disease, the most commonly disorders diagnosed being represented by gastritis and enteritis which were developed single or paired. Ultrasound-diagnosed disease were represented by gastritis (24 cases), pyloric hypertrophy (three patients), enteritis (22 cases) and intussusception (two cases).

Using ultrasound technique has made a substantial contribution in disease detection, by this method being able to appreciate the stomach or intestinal wall thickness and local or diffuse changes in such segments.

Ultrasound investigation of the stomach was achieved through systematic scanning of gastric region from left to right in order to assess gastric wall thickness, its symmetry or echogenity appearance. In most cases observed the increase in gastric wall thickness was associated with inflammatory lesions.

The pyloric region had been visualized very well and occurred in the right of the midline of the abdomen observing the contractions of the stomach wall and the degree of pyloric evacuation.

Fig. 1. Gastritis, Carpathian Sheperd dog, 9 years old

In Figure 1, ultrasound image obtained from a Carpathian Shepherd dog aged 9 years presented with symptoms of decreased appetite and chronic vomiting can be seen the pyloric region with a modified structural aspect without distinction beetween parietal layers and a surrounding low echogenic ring. Weighing 49 kg, normal wall thickness of the pylorus should have been 5.5 mm. As can be seen the wall thickness is 9.5 mm which states the inflammation process with gastric localization.

Figures 2 and 3 shows the sonographic aspects of the gastric region in a German Brac aged 14 months. From the ultrasound images can be observed the inflammation which has gastric location, the size of the gastric wall in the pyloric region being double than the normal value: 12.6 mm. Wall stratification is present, there being no changes at this level in this regard. Instead, the echogenity is modified showing the same uniformity in echogenity as the

structures adjacent to, the normal appearance of the stomach being characterized by a low echogenity given by gastric mucosa and musculosa that are prevalent in the wall.

Fig. 2. Gastritis, German Brac dog, 14 months

Fig. 3. Pyloric hypertrophy, German Brac dog, 14 months

In Figure 4 we can observe lesions of gastritis seen in an eight years old Akita Inu dog, characteristic changes occurring in the stomach wall and the pyloric region. It can be seen the increase in gastric wall thickness and the low echogenic intraluminal content. Loss of wall characteristic stratification: lumen - mucosa - submucosa - musculosa – serous is also observed.Thus, this ultrasound modified aspect combined with diffuse thickening of the wall leads to the diagnosis of gastritis.

Fig. 4. Gastritis – pyloric hypertrophy, Akita Inu dog, 8 years old

Fig. 5. Chronic nephritis, Akita Inu dog, 8 years old

In addition to the specific symptoms of gastritis the patient also presented symptoms of a chronic renal failure manifested by oliguria and polidipspia.

After conducting ultrasound examination were observed nephritis lessions (Figure 5) that are characterized by loss of characteristic echogenity and by the change in the appearance of renal structure. Specific loss of cortical and medullary differentiation and growth in the cortical echogenity confirmed the diagnosis.

Fig. 6. Pyloric hypertrophy, German Shepard dog, 4 years old

Figure 6 reveales the sonographic appearance seen in a patient with pyloric hypertrophy, the gastric wall having a thickness of 17 mm. It can be observed the persistance of the characteristic layers and the increase in size of the parietal muscular layer with high echogenity aspect.

Fig. 7. Enteritis, common breed dog, 6 years old

Fig. 8. Enteritis, common breed dog, 6 years old

In figure 7 is observed the increase in intestinal wall thickness while maintaining the characteristic stratification and echogenity. The patient, a common dog breed aged 6 years old, accused diarrheal episodes that alternated with normal recovery period. The ultrasound examination could reveal detectable enteritis lesions characterized by the increased parietal thickness and echogenity change. In both images is observed that are affected more intestinal segments, diffuse intestinal lesions occurring. Extremely important to note is that the proportions are kept between intestinal wall layers, which reveal a chronic inflammation.

Fig. 9. Intussusception, German Shepard dog, 6 years old

Fig. 10. Intussusception, German Shepard dog, 6 years old

In figures 9 and 10 is observed the characteristic appearance of an intussusception image obtained from a 6 years old German Shepherd dog. It is noted the target aspect with double the normal number of layers of the intestinal wall. Also there can be seen the retain of layers individuality, without the occurance of other structural changes.

Fig. 11. Enteritis, Great Japanese dog, 9 years old

Fig. 12. Enteritis, German Shepard dog, 4 years old

Figure 11 display the ultrasound image of enteritis diagnosed at a male Great Japanese dog aged 9 years. In the center of the ultrasound image can be observed the aspect of the intestinal loops as they lost their parietal individualization. The three loops displayed in a sagittal section presents a low content, very easily observed by its characteristic high echogenity.

Figure 12 showes the aspect of the intestinal loops in cross section with increase in their size and the preservation of the layers alternation and the maintaining of the characteristic echogenity.

As can be seen in the ultrasound images displayed in this study, ultrasonography allows confirmation of a diagnosis suspected on clinical signs and may, individually, to provide the necessary evidence to diagnose a gastrointestinal disease. Ultrasound is of particular practical significance since, by obtaining sharp images and observing an injury or pathological processescan be of relevant diagnostic value.

CONCLUSIONS

1. During the study 767 dog of different breeds and ages presented to Medical Clinic, of whom 12.77% and a total of 98 patients presented gastrointestinal disorders. Ultrasound was performed in 36 of them, considering appropriate to conduct such an additional examination to determine with certainty the diagnosis.
2. Of the 98 subjects with gastrointestinal disorders only 33 had gastric disease, 23 exclusively intestinal disorders and the remaining 42 dogs had associated gastrointestinal disorders.
3. Of the 36 patients examined by ultrasonography, 12 cases representing 33.33% had only gastric disorders, nine subjects representing 25% had only intestinal disease and the remaining 15 cases, 41.77% had associated gastric and intestinal disorders.
4. Ultrasound-diagnosed disease were represented by gastritis (24 cases), pyloric hypertrophy (three patients), enteritis (22 cases) and intussusception (two cases).
5. Ultrasonography allows the confirmation of suspected diagnosis based on clinical signs or individually, to provide the necessary evidence to diagnose a gastrointestinal disease.

BIBLIOGRAPHY

1. Codreanu M., 2000 - *Diagnosticul ecografic în bolile interne la animale*, Ed. Coral Sanivet.
2. Codreanu M.D., Al. Diaconescu, 2003 - *Diagnosticulecograficla animalele de companie,* Ed. CoralSanivet, Bucureşti.
3. Keally K., McAllister Hester, 2000 – *Diagnostic Radiology and Ultrasonography of the Dog and Cat, 3rd edition,* W.B. Saunders Co., Philadelphia.
4. Mannion P., 2006 - *Diagnosticultrasound in small animal practice*, Blackwell Science.
5. Solcan Gh., Boghian V., Rollin F., 2005 – *Patologie şi clinică medicală veterinară*, Ed. Ion Ionescu de la Brad, Iaşi.

IMPORTANCE OF DIAGNOSTIC IMAGING IN HYDRONEPHROTIC KIDNEY SURGERY

ADELA MENDEA,[1] N. HAGIU[2]

[1]Salvavet – Ilioara Animal Hospital Bucharest - Romania
adela.mendea@yahoo.com
[2]Faculty of Veterinary Medicine- Iassy

SUMARY

This is a study that reveals ultrasound benefits in a case of bilateral hydronephrosis (3). In the case of Bruno we could use the linear transducer and high frequency (2) to follow the ureters until the bladder jonction. Because of the Doppler (1) we could make the different between ureter (especially middle and distal segment) and blood vessels Transposition of the ureter (4,5) to a new bladder location is the possibility to avoid an obstacle and to restore the urinary flow and a chance for life for some animals.

Keywords: hydronephrosis, ultrasound, Doppler, transposition, ureter

Ureterohydronephrosis is distension and dilation of the renal pelvis , calyces and the ureter, leading to progressive atrophy of the kidney. The presence of hydronephrosis or hydroureter should be considered a physiologic response to the interruption of the flow of urine , but untreated can cause hypertension, loss of renal function and sepsis. Diagnostic imaging is very important because allows for visualization of the ureter and kidney and also the position of obstruction. The treatment means removal the obstruction and drainage of the urine.

MATERIALS AND METODS

The patient is Bruno, an 11 years old Pit-bull, with a history of persistent vomiting and progressive weight loss. Two weeks ago he was diagnosed with severe renal failure in other clinic from Bucharest and fluid therapy was instituted.

The owner has come in our clinic for a second opinion, because the dog didn't response to the specific treatment. The blood tests indicate a poor prognosis:

- first day: creatinine (Cr) = 4.7 mg/100 ml (normal range is 0.4 - 1.8 mg/100ml); urea (Ur) = 98.3 mg/100ml (normal range is 7 – 27 mg/100ml)
- after 5 days with fluid therapy: Cr = 9.0 mg/100ml, Ur = 121 mg/100ml
- after another 2 days: Cr = 11.7 mg/100ml, Ur = 153.9 mg/100ml

At the clinical consult we have seen a dog in a poor body condition, with anemic mucosa, very thin, dehydrated but very active and sociable. The new blood tests confirmed severe renal failure with anemia, electrolyte imbalance and increased creatinine and urea: Cr = 1423 μmol/L (normal range is 44 – 159), Ur = 89.3 mmol/L(normal range is 2.5 – 9.6).

We have completed the investigations with the ultrasound exam, using a modern doppler machine, My Lab – Esaote. Ultrasonography reveals bilateral ureterohydronephrosis (Fig. 2, Fig. 3) and a big prostatic tumor (Fig. 1)

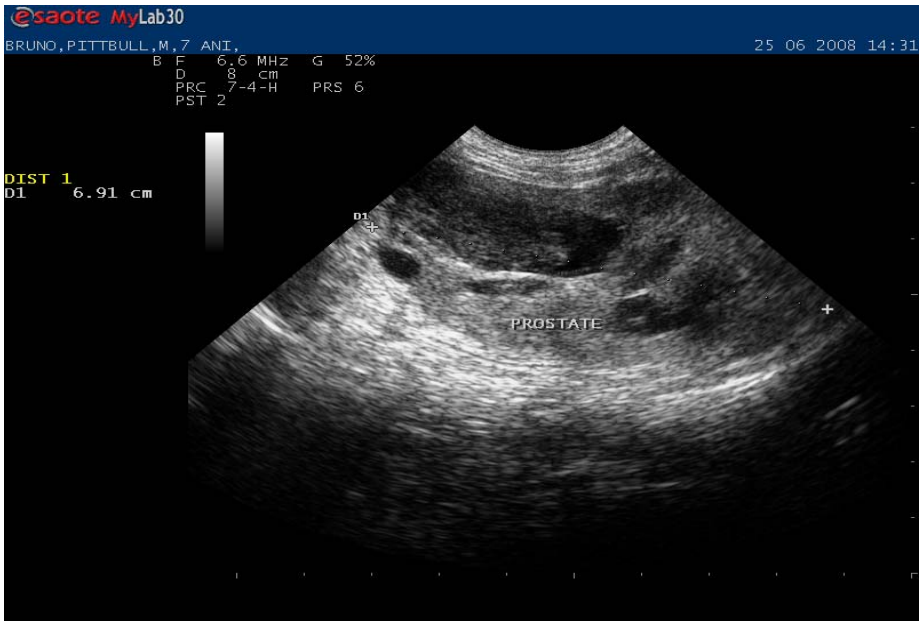

Fig.1. Prostate with unhomogeneous structure

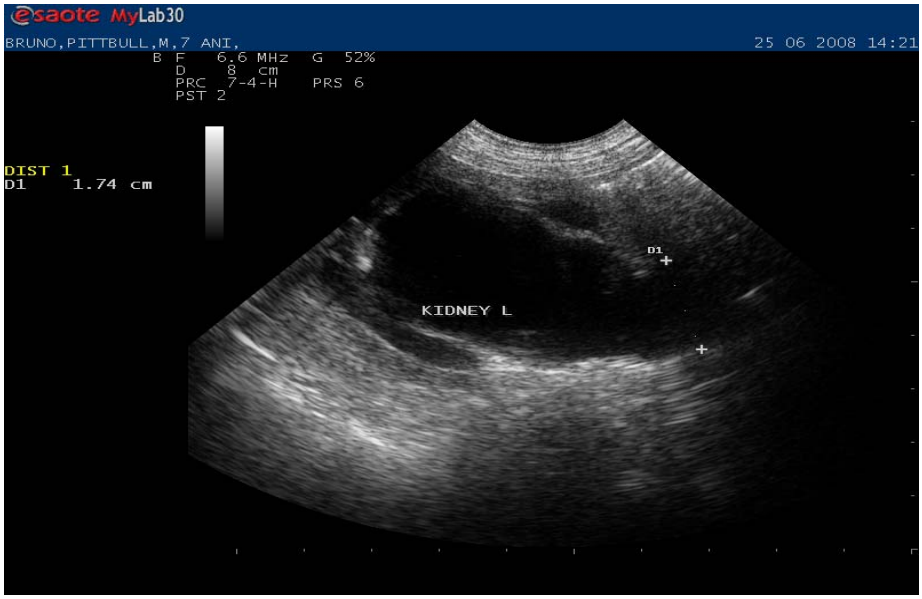

Fig. 2. Hydronephrotic kidney – we can observe also the compressed parenchyma and the dilated proximal ureter

Because of the Doppler we could make the different between ureter (especially middle and distal segment) and blood vessels (Fig.3). After a careful examination we observed that tumoral tissue includes the distal segment of the ureter, blocking the outflow of the urine (Fig.4).

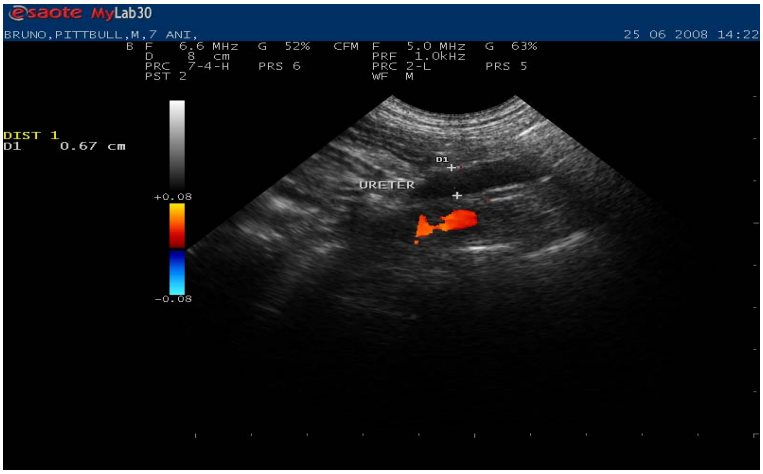

Fig. 3. Hydroureter – how we can make the different between the dilated ureter and a blood vessel

After a long discussion the owner decided to give Bruno a chance, with surgery (ureter transposition).

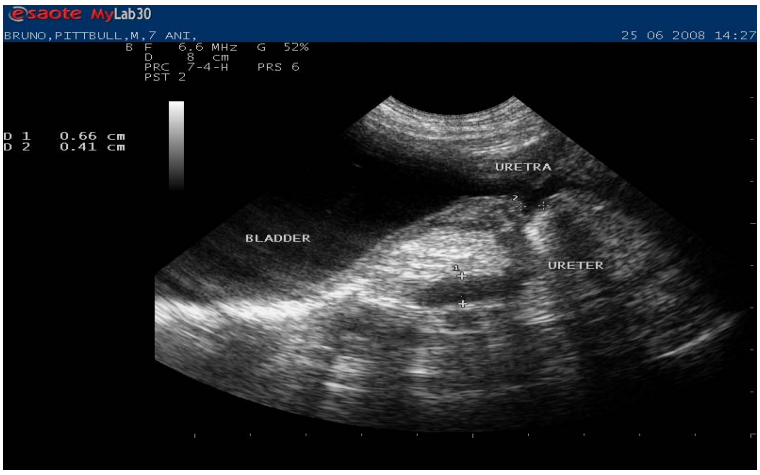

Fig. 4. The distal part of the ureter is included in the tumoral mass

An intravenous catheter was put in place and the fluid therapy was instituted , using physiological saline and sodium bicarbonate. The induction process was conducted with propofol , in a very slow rate for the first ml to observe any adverse reaction. The pacient was intubated for isoflurane anesthesia. During the surgery all major functions were monitored. We removed the left ureter from the affected part of the urinary bladder to a location with normal structure and fixed it with a duble resorbable suture.

After surgery, the condition of the dog was improved for 1 mounth and a half and also the ultrasound aspect of the kidney (Fig. 5). Five days after surgery Cr = 326 μmol/L (before Cr = 1423μmol/L) and Ur = 51,2 mmol/L (before Ur = 89,3 mmol/L).

The owner wasn't decided for the second surgery and after two months Bruno started to feel worse, body condition alterating from day to day. At least the owner chose euthanasia.

Fig. 5. Ultrasound image of the left kidney, before and after surgery

RESULTS AND DISCUSSIONS

Bilateral hydronephrosis is a pathology with a poor prognosis because it is difficult to restore the normal urinary flow and also because the severe damage of the renal parenchyma.

The case of Bruno represents an example of hydronephrotic kidney surgery, unfortunately with severe parenchyma damages. Ultrasonography allowed a real diagnosis and possibility to observe the kidney in evolution (after surgery).

There are many inoperable cases with urinary pathology, for example: big tumors, aderential block, severe abdominal trauma, wrong tye of the ureters in ovariohysterectomy .

Transposition of the ureter to a new bladder location is the possibility to avoid an obstacle and to restore the urinary flow.

CONCLUSIONS

1. For the best result we need to put together from theclinical and paraclinical exams. A performance ultrasound machine allows the details , a very good diagnosis and a real prognosis.
2. In the case of Bruno we could use the linear transducer and high frequency to follow the ureters until the bladder jonction.
3. The Doppler tecnique allows us to different the ureters from the blood vessels. Also we could see the vascularisation of the abnormal tissue and the kidney
4. Ultrasonography together with the blood tests allow us to follow post surgery evolution
5. Transposition of the ureter is a difficult surgery but it means a chance for life for the bilateral hydronephrotic cases.
6.

REFERENCES

1. Mc Allister,K, Diagnostic radiology and ultrasonography of the dog and cat, 2000, third edition, 436
2. Burk, R. L., Feeney, D. A., Small animal radiology and ultrasonography, Saunders 20003, third edition, 740
3. Bainbridge, J., Elliot, J., Manual of canine and feline nephrology and urology, 1996, first edition, 232
4. C. Anderson, Journal of surgical research, volume 16, Issue 1
5. E. Michalowski, W. Modelski, Urology and nephrology, vol I, Department of Urology, Medical Academy

COMPARATIVE CHARACTERISTICS OF DUROC AND WHITE LARGE DILUTED BOAR SEMEN STORED FOR FIVE DAYS AT 17°C IN RELATION TO FERTILITY

C. MIRCU, Violeta IGNA, Camelia TULCAN, H.CERNESCU, Anca LELESCU , Simona ZARCULA, R.I. URIAN-SUESCA, G.OTAVA, V.ARDELEAN, Gh.BONCA
Faculty of Veterinary Medicine Timisoara
Calea Aradului nr. 119, Timisoara 300645, Romania
calinmircu@yahoo.com

ABSTRACT

Semen quality represents the crucial element for artificial insemination. Computer assisted semen analysis offer a solid base for boar semen fertilitizing ability estimation. In our study we analyzed on CASA system the motility, progressive motility, rapid velocity, VCL, LHD and LIN and their relation to subsequent fertility in Duroc and White Large boars, based on assays runned on diluted semen stored for five days at 17°C. During storage, total motility, progressive motility, VCL and LIN decreased, as LHD slightly increased for both groups. Based on obtained results we concluded that motility of diluted semen, on sampling day and after 3 and 5 days could represent a good indicator of subsequent fertility. Semen hyperactivation, emphasized in all assayed samples, did not affect fertility and litter size. Based on the average values, we can conclude that in the frame of this paper, Duroc diluted semen motility parameters were superior to Large White diluted semen motility parameters, as observed on fertility and litter size. It could be established a relation between semen mobility parameters (motility, progressive motility and rapid velocity) and subsequent fertility.
Key words : boar, semen, CASA, motility, fertility

Fertility in the case of artificial insemination in sows is subject of variation due to multiple factors. Beside the optimum moment for insemination, the semen represents the crucial element for ensuring high reproductive scores. In this respect, sperm motility could represent a general determinant of reproductive success. Subsequent to semen sampling, proper extender and time of storage could exert significant influence on fertility (Kommisrud et al.-2002, Gadea -2003). The extenders used for generating multiple semen doses from a single ejaculate are containing nutrients and other elements ensuring spermatozoa with supplies for viability for more days after collection. The classical method of semen evaluation measures sperm motility, the percentage of viable cells and sperm morphology (Gogol et al., 2009). As long as motility could represent an indicator of sperm cell status, metabolism and integrity of membranes, the objective if our experiment was to compare, using a CASA (computer-assisted sperm analysis) system, the characteristics of sperm motility in Duroc and White Large diluted boar semen stored for five days at 17°C and their relation to fertility, when the semen samples were used in on-farm artificial insemination.

MATERIALS AND METHODS

Semen was sampled from Duroc (Group 1, n = 5) and Large White (Group 2, n = 5) boars, with age ranging from 28 to 30 months. Sperm-rich ejaculate fractions were collected using the gloved-hand method, extended (1:1, vol/vol) in Zoosperm ND5 (Importvet) which contains

glucoses, natrium citrate, EDTA, natrium bicarbonate and excipiens, and after evaluation of conventional semen characteristics, diluted in order to obtain 3 x 10^9 spermatozoa per dose (included in a total volume of 80 ml). Further, in the laboratory of Reproduction department in the Faculty of veterinary medicine Timisoara, semen samples were assayed using CASA equipment. Briefly, samples were loaded in a Leja standard count 4 chamber slide (IMV USA, Maple Grove, MN, USA) and sperm concentration and characteristics of sperm motility determined using a computer-assisted sperm analysis system (CASA; Integrated Visual Optical System, Version 12; Hamilton Thorne Research, Beverly, MA, USA). Starting CASA values for boar sperm analysis were consistent with manufacturer recommendations. From all determined characteristics of sperm we further have analyzed: percentages of motile and progressively motile spermatozoa (with fast, medium and slow movements), average velocity measured over the actual point to point track followed by the sperm cell (VCL), lateral head displacement (LDH), linearity (LIN - average value of the ratio VSL/VCL) which measured the departure of the cell track from a straight line.

The extended semen samples were stored in an incubator (Binder 53 – USA) at 17°C and daily, an aliquot of each sample was removed and warmed to 37°C for 30 minutes. Than, the sample was analyzed for all before mentioned parameters.

We focused on sperm motility because it indicates active metabolism and integrity of membranes, and is of great importance for fertilizing capacity.

The obtained semen characteristics were related to conception rates and litter sizes obtained subsequent to on-farm artificial insemination. Sows (Landrace x Large White) with age ranging between 12 and 16 months were inseminated in relation to their receptivity to boar. For instance, sows immobile to man in the morning were inseminated at midday, and insemination was repeated next morning. Third insemination was carried after another 24 hours if sow was still immobile to man. Correlations between the mean measurements derived from extended semen and regarding reproductive parameters were examined using Spearman's rank test.

RESULTS AND DISCUSSIONS

The results of the study were included in tables 1-3. In Table 1 can be analyzed the selected semen parameters for the Duroc boars (Group 1), as were assayed in the sampling day (day 1), and also after 3 and 5 days. Regarding motility, in can be observed its continuos and constant decrease, from the first to the fifth day after sampling. An exception occurred at the boar 223958, where the third day value of this parameter raised, compared to first day. As average value for group 1, the 61.2% represent a physiologic step for good fertility, according to Estienne et al. (2007). To this point, motility could be a useful parameter for identifying poor quality semen. Gogol et al. (2009) emphasized the fact that boar spermatozoa stored up to seven days retained a good progressive motility (45%).

Kommisrud et al. (2002) reported that the storage time had a highly significant influence on both motility ($p<0.004$) and acrosome integrity ($p<0.001$) and also that the percentage of motile spermatozoa was maintained at a surprising level even after five days storage.

Progressive motility has a central role in sperm movement description, reflecting properly the general motility. In group 1 could be emphasized its constant decrease from day 1 to 5, its average value dropping from 20.6% in the first day to 15.6% at 5 days subsequent semen sampling.

Table 1. General motility semen parameters in Duroc boars (group 1)

Day 1	Boar 034328	Boar 048125	Boar 223958	Boar 007987	Boar 009866
Motility %	73	47	62	54	70
Progressive motility %	28	12	19	19	25
Rapid velocity- %	53	20	32	30	53
VCL µm/s	152,9	110,0	132,0	116,3	154,1
LHD µm	8,0	7,3	8,2	8,0	8,4
LIN %	22	25	22	25	21
Day 3					
Motility %	64	26	65	54	52
Progressive motility %	23	8	18	19	19
Rapid velocity- %	34	11	29	32	35
VCL µm/s	123,6	109,0	117,2	129,2	135,4
LHD µm	8,9	8,8	8,2	8,6	9,2
LIN %	26	30	23	25	23
Day 5					
Motility %	57	47	51	50	51
Progressive motility %	11	15	12	19	21
Rapid velocity- %	14	21	18	27	31
VCL µm/s	86,5	106,7	107,1	123,6	126,9
LHD µm	8,2	7,6	8,9	8,2	8,8
LIN %	31	29	23	31	28

In a previous study (Mircu et al., 2008) we concluded that semen can not be divided into subpopulations according to velocity speed, albeit we decided to observe sperm with rapid velocity, in order to make possible connections with fertility, although Cremades (2005) stated that there were not registered significant different values between semen subpopulations regarding immotile spermatozoa, or the average litter size. We observed that velocity rapid sperm values followed the similar pattern with general and progressive motility, decreasing more or less pronounced from the 1st to the 5th day. Boar 048125 represents the exception, the value registered on the 5th day being slightly higher than the initial one.

VCL, ALH and LIN were included in this study in order to emphasize the presence of hyperactivated sperm, as defined by Mortimer (2000) and Schmidt and Kamp (2004). Hyperactive mammalian spermatozoa have been characterized by a vigorous and non-linear movement caused by an increased amplitude of flagellar beats (whiplash movement). This form of motility has been observed in sperm at the site and the time of fertilization and appears, therefore, to be essential for fertilization. It has been suggested that the mechanical thrust due to hyperactive

motility is vital for spermatozoa to penetrate the zona pellucida of the oocyte. Freshly ejaculated semen usually contains only a minor fraction of hyperactive spermatozoa. Rather, hyperactivity develops during capacitation either in vivo or in vitro. Capacitation is

accompanied by changes in membrane structure thus increasing Ca^{2+} influx which triggers hyperactivity and, finally, the acrosome reaction.

The hyperactivated sperm is characterized by a decrease in VCL and LIN, and an increase of LHD. For a multiparametric definition of hyperactive boar spermatozoa, the following threshold values were used in combination: VCL > 97µms^{-1}, LHD mean >3.5µm, LIN < 32% and WOB < 71% (Schmidt and Kamp, 2004). According to these parameters, all semen samples represented hyperactivated sperm, even individually, or as average values (VCL – 133.06 µm, LDH – 7.98 µm, LIN – 23%) in the first day. Semen hyperactivation did not affect fertility (table 4).

Table 2. . General motility semen parameters in Large White boars (group 2)

Day 1	Boar 036869	Boar 610774	Boar 255771	Boar 938327	Boar 335474
Motility %	52	54	65	69	54
Progressive motility %	12	21	23	28	19
Rapid velocity- %	22	27	37	52	28
VCL µm/s	110,8	127,4	129,0	149,6	126,1
LHD µm	7,1	8,2	7,4	8,1	7,7
LIN %	26	25	25	22	23
Day 3					
Motility %	23	62	49	50	50
Progressive motility %	5	19	17	14	13
Rapid velocity- %	12	28	27	32	22
VCL µm/s	118,0	123,7	125,6	124,0	128,7
LHD µm	7,3	8,7	8,6	7,7	8,8
LIN %	24	24	25	22	23
Day 5					
Motility %	29	36	55	53	49
Progressive motility %	8	4	14	19	14
Rapid velocity- %	14	6	18	39	21
VCL µm/s	117,1	81,7	98,9	144,2	119,1
LHD µm	7,4	7,2	8,9	8,5	8,6
LIN %	25	26	31	23	26

Characteristics of Large White boar semen samples are depicted in table 2. As in Duroc boars, it can be emphasized a constant decrease of general motility, excepting boar nr. 610774, where a substantial rise is observed on 3rd day, compared to the first one (62% versus 54%). De Ambrogi et al. (2006) reported no effect of extender by day on total motility, linear motility, VSL, VAP or VCL for semen extended in BTS, MR-A or X-Cell, suggesting the diluents maintained characteristics of sperm motility in a similar fashion during storage at 17°C for four days. Progressive motility and rapid velocity are following the same pattern, but it has to be stressed that average rapid velocity on sampling day (day 1) is significantly lower ($p < 0.05$) compared to group 1 (37.6% versus 33.2% - table 3).

Table 3. Average values of the considered semen parameters for group 1 and group 2

	GROUP 1	GROUP 2
Day 1		
Motility %	61.2	58.8
Progressive motility %	20.6	20.6
Velocity-rapid %	37.6 [a]	33.2 [b]
VCL µm/s	133.06	128.58
LHD µm	7.98	7.70
LIN %	23	24.2
Day 3		
Motility %	52.2 [a]	46.8 [c]
Progressive motility %	17.4 [a]	13.6 [b]
Velocity-rapid %	28.2 [a]	24.2 [b]
VCL µm/s	122.88	124.00
LHD µm	8.74	8.22
LIN %	25.4	23.6
Day 5		
Motility %	51.2 [a]	44.4 [c]
Progressive motility %	15.6 [a]	11.8 [b]
Velocity-rapid %	22.2 [a]	19.6 [b]
VCL µm/s	110.16	112.2
ALH µm	8.34	8.12
LIN %	28.4	26.2

[a,b] for the same row means significant difference for p = 0.05
[a,c] for the same row means significant difference for p = 0.01

Table 4. Number of artificially inseminated sows (AI), conception rate and litter size in groups 1 and 2

	Number of AI sows	Conception rate (%)	Litter size
Group 1			
Boar 034328	14	97	11.2
Boar 048125	12	79	7.49
Boar 223958	11	92	10.69
Boar 007987	15	85	10.63
Boar 009866	10	98	12.2
average	*12.4*	*90.2* [a]	*10.44*
Group 2			
Boar 036869	16	79	10.7
Boar 610774	12	81	11.2
Boar 255771	15	94	11.8
Boar 938327	15	95	12.2
Boar 335474	14	82	11.44
average	*14.4*	*86.2* [b]	*11.46*

[a,b] for the same column means significant difference for p = 0.05

Regarding all three parameters taking into consideration for hyperactivation definition (VCL, LDH and LIN), it is obvious that all of them, individually or as average, are indicating the presence of hyperactivation, with no further consequences on fertility (table 4). It has to be stressed that hyperactivation remains present also on days 3 and 5, and this feature could positively affect fertilization ability, as proven by the AI results (table 4).

Table 3 includes the average values for all investigated parameters, and excepting day 1, where only rapid velocity registered significant differences, on days 3 and 5, all motility parameters (general motility, progressive motility and rapid velocity) are significantly higher for Duroc boars (group 1), and these aspects could be related to significantly higher fertility (table 4) obtained subsequent to artificial insemination performed with Duroc boars diluted semen. Data from table 3 also are revealing the presence of hyperactivation in both group 1 and 2, on sampling day and also after 3 and 5 days.

In both groups good fertility parameters were obtained (table 4), defined through conception rate and litter size. Litter size is expressing the conjunction of various factors, related more or less to fertility but underlying the organism ability to ensure optimal medium for establishing, maintaining and finishing the pregnancy. Average values for litter size even in G1 (10.46) or in G2 (11.18) ranged in the limits wide accepted for intensive exploitation systems (Xu et al., 1998, Behan – 2002, Satake et al., 2006) Xu et al. (1998) using semen with motility varying from 62.5 to 75% obtained litter size ranging from 7.26 to 10.55.

CONCLUSIONS

Motility of diluted semen, on sampling day and after 3 and 5 days could represent a good indicator of subsequent fertility. Semen hyperactivation, emphasized in all assayed samples, did not affect fertility and litter size. Based on the average values, we can conclude that in the frame of this paper, Duroc diluted semen motility parameters were superior to Large White diluted semen motility parameters, as observed on fertility and litter size. It could be established a relation between semen mobility parameters (motility, progressive motility and rapid velocity) and subsequent fertility.

Acknowledgments

We want to thank especially to Assistant Professor Violeta Igna for the precious help with boar semen evaluation using CASA, and to the PhD students involved in all other phases of this work.

REFERENCES

1. Behan J. – 2005 - Objectives of Assisted Reproductive Technology, 2002, Banff Pork Seminar, January 22-25, pag 1-10.
2. Cremades Teresa, J. Roca, H. Rodriguez-Martinez,Teresa Abaigar, JM. Vazquez, EA. Martinez – 2005 Kinematic Changes During the Cryopreservation of Boar Spermatozoa, Journal of Andrology, 26, 610-618.
3. De Ambrogi M, Ballester J, Saravia F, Caballlero I, Johannisson A, Wallgren M, Anderesson M, Rodriguez-Martinez H. , 2006 Effect of storage in short- and long-term commercial semen extenders on the motility, plasma membrane and chromatin integrity of boar spermatozoa, International Journal of Andrology 29:543-552
4. Estienne M.J., Harper A.F., Jennifer Day - 2007 Characteristics of sperm motility in boar semen diluted in different extenders and stored for seven days at 18ºC, Reproductive Biology, vol. 7, no. 3, 221-231.

5. Gadea J. 2003 Review: Semen extenders used in the artificial insemination of swine, Spanish Journal of Agricultural Research 2 : 17-27
6. Gogol P, Barbara Szczesniak-Fabianczyk, Agnieszka Wierzchos-Hilczer- 2009 The photon emission, ATP level and motility of boar spermatozoa during liquid storage, Reproductive biology 9 : 39-49
7. Kommisrud E., H.Paulenz, E.Sehested, I.S.Grevle 2002 Influence of boar and semen parameters on motility and acrosome integrity in liquid boar semen storage for five days, Acta vet.scand. 43 : 49-55
8. Mircu C, H.Cernescu, Violeta Igna, Renata Knop, Ilinca Frunza, V.Ardelean, Gh.Bonca, G.Otaca, Simona Zarcula, Gabriela Korodi, A.Ardelean -2008- Boar semen evaluation using CASA and its relation to fertility – Lucr.st med.vet. Timisoara, XVI : 203-212
9. Mortimer T. Sharon – 2000 - CASA – Practical Aspects, Andrology Lab Corner, 515-524.
10. Satake N, R.M.A. Elliott, P.F. Watson, W.V. Holt – 2006 - Sperm selection and competition in pigs may be mediated by the differential motility activation and suppression of sperm subpopulations within the oviduct, The Journal of Experimental Biology, 209, 1560-1572.
11. Schmidt H. and G. Kamp - 2004 -Induced hyperactivity in boar spermatozoa and its evaluation by computer-assisted sperm analysis, Reproduction, 128,171-179.
12. Xu X., S. Pommier, T. Arbov, B. Hutchings, W. Sotto, G.R. Foxcroft 1998 In vitro maturation and fertilization techniques for assessment of semen quality and boar fertility, J. Anim. Sci., 76, 3079-3089.

DENTAL FRACTURE IN DOGS: INCIDENCE, CLINICAL AND THERAPEUTICALLY ASPECTS

A. MUSTE, FL. BETEG, I. PAPUC, ALINA DONISA, R. LACATUS, M. MUSTE

University of Agricultural Sciences and Veterinary Medicine,
Faculty of Veterinary Medicine 3-5 Mănăştur street, 3400, Cluj-Napoca, Romania,
email:aurel_muste@yahoo.com

ABSTRACT

In this study, 129 dogs were selected over a period of four years, who had isolated or multiple dental fractures, simple or complicated. In all subjects we appreciated the fracture location, depth, form and most effective treatment. The dental fracture location can be seen in any of the dental elements (table1.)having a higher incidence in the canines, premolars followed orders, incisors and molars. Regarding age, higher incidence encounters between 5-8 years, although the increased incidence of the fractures, especially coronary meets in younger age too (3-4 years). In case of longitudinal radicular fracture it is necessary a radiologic exam for a proper understanding of his amplitude. Dental fracture treatment was different according to appearance, size and time from production to the intervention. For the crown fracture of the enamel we have chosen edge grinding process to avoid soft tissue injuries and for the crown fractures were used photo polymerization composite resin . This resin gives good results and lasting even in situations where there is lack of substance.

***Key Words**: dog, reconstruction, fracture, photopolymer resin.*

INTRODUCTION

Dental fracture in canine species is present in different ways depending on the author of the study. Regardless of the author they have a different incidence, a real aspect because it depending by the conditions of study and observations who are very different. The fractures in the dentin are generally grouped at the crown or radicular area, depending on the immediate cause. According Eisenm and Zetner Enger (1985), Harve and Emily (1993) the dental fractures appearance is influenced strongly by two factors such as anatomical position in direct correlation with the teeth height of their use or activity. The dental fractures in dogs are mentioned primarily to the crown and radicular level. The fractures may be accompanied by a lack of substance in both the horizontal fractures and vertical fractures or in varied complications (dislocations, pulpitis, dental necrosis, septic processes, abscesses, fistulas) that complicate or delay healing.Regarding breeds should be noted that the high incidence points to large breeds and temperament, and favorite location is 4 maxillary premolar by Franceschini (1974) and Newman (1988). The correct assessment of treatments followed by vitality tests and radiography plays an important role in determining the prognosis of radicular fractures. For the complexity of the approach therapy we intend to pursue the therapeutically evolution from the stage of diagnosis.

MATERIAL AND METHOD

Our research and observations were made over a period of 4 (four) years from 2005 to 2009, on a total of 129 dogs by different breeds, ages and both genders. The fracture diagnosis was established during clinical examination towards mouth disease, or during other investigations.
The incidence of dental fractures in dogs is different being in direct correlation with their age and service. The most affected dental elements were in order: the canines n= 45 cases (34%), followed by premolars n= 37 cases (28.6%), the incisors n= 28 incisors (21.8%), molars n= 19 cases.(15%)table 1.

Dental fracture in relation to animal age

Tabel.1.

Age (years)	Affected dental elements			
	Incisors	Canine	Premolars	Molars
Before 2 years	-	4	-	-
3-4 years	3	19	15	2
5-6 years	14	18	16	8
7-8 years	11	4	6	9
TOTAL	28	45	37	19

From all subjects, in a number of 36 subjects (68.9%) the fractures were accompanied by acute or chronic pulpitis (open cavity) or other complications.
In our casuistry the dental fracture therapy was led in two directions: if uncomplicated crown fractures (enamel fracture) we have applied polishing and in complicated crown fractures where we used endodontic treatment using composite resin.

RESULTS AND DISCUSSIONS

Characteristic clinical appearance of fractures is dominated by the lack of substance (enamel, dentin) which can be observed in horizontal or vertical way.
Dental fractures were found localized to the enamel, dentin and pulp crown vertically or horizontally with the lack of substance different from case to case (fig.1) The lesions have highly variable shape and the depth is often correlated with time from production until the exam.

Fig.1. The incision of the third incisor and inferior canine in left side, the incision include the enamel and dentin

The fracture surface is rough or smooth, with irregular aspect, in some cases viewing the pulp chamber. Sometimes the lesions are localized to the dentin which appears as yellow substance. When the fracture is deeper and accompanied by opening pulp chamber, it presents as a round or oval surfaces of red or dark brown.

Root fractures are more present than in the permanent dentition temporary dentition. And in this case vertical fractures can be encountered, in which appear the question of tooth conservation and the appearance of the horizontal fractures localized in the third average root. The root fractures are not always associated with pain in many cases we can see movements and light extrusions. Dentition with fractures in the third apical length, generally have a discrete mobility. When digital pressure is exercised on both sides of the alveolar process while the traumatized tooth is moved, with the other hand, can determine whether it is a root fracture or dislocation (luxation). Another aspect that we should mention is that the symptoms of pain in dogs manifested by salivation, failure occurs during food consumption, food consumption prior to repeated hesitations, the head position on one side, and the repeating touch of the place with the anterior lamb especially after eating food.

In case of fracture is better to perform X-ray exam because a fracture can be, or not visualized because of the fracture line shape and direction of the central beam ray tube.

In uncertain cases is recommended making another X-ray in another effect. A simple root fracture is often represented by two curved fracture lines on dental film which will form an ellipse, the lines are the form of the fracture in the vestibular and palatal or lingual slope.

The therapy in our study, we approached it differently depending on the type of fracture. Thus, in case of the enamel fracture, to prevent injuries of the tongue or cheeks we made sharp ridges grinding with specific instruments.

In our study, this behavior (method) was practiced in a number of 25 subjects. Were more numerous situations where we had to perform root therapy. This kind of therapy I've applied to teeth fractures with pulp exposure more than 24 hours for discolored teeth that show pulp death row trauma.

Particular attention should be paid to the removal of dentine doting vital tissue (diamond mills conical or spherical) as a treatment success depends on good local cleaning. To remove the root pulp initially recommends using Tierner needle of different sizes, followed by use of the Hedstrom needle . In case o the removal of dentine is always better to perform in a root a canal lavage , with a saline solution or hydrogen peroxide or chloramin.

A very important point which should take into account is the drying of the channel with air jet so the excess of moisture is removed as well.

Enamel edge we apply a film of 37.5% phosphoric acid solution is maintained for 20-30 seconds for demineralization. To remove the demineralization particulate we made again a good lavage and we dry that portion with airflow, a step required to prepare a suitable application of composite resin.

Then add a thin layer of bonding solution which extends uniformly over the entire surface and then photo polymerization for 20-30 seconds. From this moment we apply layers of composite resin (fig.2), each layer fotopolimer for 40 seconds (fig.3). After the material composite is strength is recommended to perform grinding, finishing and polishing.

This method gives very good results if is combined with proper maintenance in terms of nutrition and focus on the dog owner attention to avoid catching and playing with hard objects.

Fig.2. The application of composite material

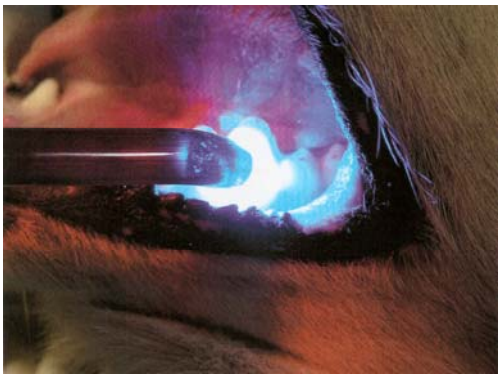

Fig. 3.The Photopolymerization of the material composite

CONCLUSIONS

1. Dental fractures in dogs are present in all the dental elements (incisors, canines, premolars and molars) in variable proportion depending to their activity and anatomical position.
2. For the vertical root fractures we need at least two radiographs in different incidences.
3. Endodontic treatments must be made soon as possible so as to avoid septic processes (pulp necrosis, abscesses, fistulas) witch prolong the duration of treatment and its results.
4. Using composite resin photopolymer for coronary fractures in dogs gives very good results and lasting.

BIBLIOGRAPHY

1. Capik I., Ledecky V., Sevcik A., Tooth fracture evaluation and andodontic treatment in dogs, Department of Surgery, University of Veterinary Medecine, Kosice, Slovakia, 2000.
2. Dorn A.S., Crown restoration of canine teeth with composite bonding, Proceedings of the ACVS, 1983.
3. Eisenmenger E., Zenter K., Veterinary Dentistry, Philadelphia, Lea & Febiger, 1985.
4. Harvey C.E., Emily P.P., Small Animal Dentistry, Mosby Yearbook, St. Louis, 1993.
5. Jensen M.E., Chan D.C.N., Polymerization shrinkage and microleakage. In: Vanherle G, Smith DC, eds. International Symposium on Posterior Composite Resin Dental Restorative Materials. Netherlands: Peter Szulc Co, 1985.
6. Schulein T.M., et al., Rinsing times for a gel related to enamel/composite bond strenght. Gen Dent July-Aug, 1986.

Tutt Cedric, Small Animal Dentistry – A Manual of Techniques, Blackwell Publishing, 2006.

SURGICAL PROTOCOL IN DOG PERINEAL HERNIA

A. MUSTE, BETEG FL., TĂNASE A., DONISĂ ALINA, MUSTE M.

University of Agricultural Sciences and Veterinary Medicine, Faculty of Veterinary Medicine 3-5 Mănăştur street, 3400, Cluj-Napoca, Romania,
email:aurel_muste@yahoo.com

ABSTRACT

In this study there have been taken in observations 18 cases of perineal hernia from male dogs by different breed with age between 5-13 years, private propriety. The disease incidence is higher in subjects with age between 8-12 years with a history of coprostasis and tenesmus. All 18 cases were divided into 3 groups, each group had his own therapeutically protocol. For group one composed by7 subjects, we adopted the standard herniorrhaphy procedure , for the second group composed by 6 subjects we used the surgical procedure with herniorrhaphy by rising the obturator internus muscle and for the third group composed by 5 subjects we used prosthetic implants for herniorrhaphy. That 3 surgical techniques offers different satisfactions depending by the degree of the parietal defect of the hernia. For those situations when the musculature suffer atrophy or is unwound, sectioned, the most recommended method is the utilization of the prosthetic implants who can allow the healing of the posterior wall of the pelvis.

Key wurds: dog, perineal hernia, therapy.

INTRODUCTION

The perineal hernia is a common disease for male dogs with age between 8-13 years and appears after the damage of the support function of the pelvis diaphragm between the levatores ani muscle and external anal sphincter or between the levators ani muscle and the coccygeus muscle. Although the disease is more frequent in large dog breed ,we meet her in small breed especially in Pekingese breed. Regarding the age appearance of the disease, exist different opinions so, Hayes H.M.and all (1999) evaluate the hazard of the hernia in the way that is higher at the age 7-9 years in dogs as Boston terrier, Boxer and Pekingese and between 10-14 years in Collie dogs and theirs cross breed. The perineal hernia in more frequent in males than in females, opinion sustained by others authors like Sjollema B.E.,Van Sluiyas F.J.(1991) depending by the rectal attachment zone, the size and strain of the levators ani muscle in femals. Same authors show in a study on 39 dogs, that in females cases the ratio of levators ani muscle weigh and the body weight or the ratio between the length of the levators ani muscle and the pelvis length and vertebral spine is more higher than in males.
The causes of the pelvine musculature damage are many, or can be a combination of some factors as neurogenic muscular atrophy, senile muscular atrophy, primary inflammatory or non dystrophic myopathy , hormonal implication, prostatic and testicular neoplasia, the food who predispose the animal to coprostaza, prostatic diseases ,etc.
The evolution of this type of hernia is correlated with a variety of complications as bladder retroflexion, skin ulcerations, faeces incontinence, urinary incontinence, etc. The hernia can be

situated uni or bilateral and may be related to the rate and extent of tissue damage degree of the pelvic diaphragm than the causes that affect any of the parties. Although herniation is diagnosed unilateral, the opposite side is often weak.

MATERIAL AND METHOD

The observations were made over a three years period (2007-2009)on 18 male dogs by different breed and age from Surgery Clinic of the Faculty of Veterinary Medicine Cluj-Napoca. Regarding the incidence of this disease, it is different depending on several factors (table 1).

The study casuistry and appearance mod

Table 1.

Breed	Case number	Sex	Age (years)	Place		Relapse		History	
				unilateral	bilateral				
German Shepherd	6	M	8	4	2	2	2	3	1
Pekingese	6	M	9	5	1	1	-	4	2
Boxer	4	M	7	4	-	-	3	1	-
Spanish Coker	2	M	8	2	-	1	2	-	-

For the first group consists of 7 dogs with perineal hernia we have adopted standard herniorrhaphy procedure and after a local training, where general anesthesia and positioning the dog on her sternoabdominal position, a linear incision is made about 3-5 cm from the tail (the anus) on the hernia side, in the most protruding area, to raise the skin and subcutaneous tissue. We make a dilacerating of the adherent or broken tissues, and the fat tissue is kept in the hernia bag for biological buffer. We have to identify and protect the artery and internal pudenda vein, the pudend and rectal nerve because there are essential for a normal defecation. We also have to identify the levators ani muscle that is localized in medial side of the coccygeus muscle. We made herniorrhaphy by suturing the obturator internus muscle and the coccgygeus muscle. After closing the hernia orifice, the adipose tissue was sutured centrally and put it over the suture a extra pressure and resistance postoperatively. As we use Dexon 0 suture material. The second group consisted of six dogs, in 5 of them the hernia was present in one side and in one case it was a bilateral hernia. In this process after the skin incision and subcutaneous fat tissue and reposition of the organs in the abdominal cavity we raise the obturator internus muscle from the ischium, a muscle that will help to fill the hernial defect and allow to suture without tension the coccygeus muscle or sacrotuberale ligament to anal sphincter. To pull up the obturator internus muscle we will make an incision on the dorso caudal edge of ischial tuberosity (fig.1) and with a perosteal elevator we will raise the muscle in sub periosteal direction in cranial direction till obturator hole. We have to be careful to protect the pudend and sciatic nerve. The next step is the suture (fig.2.) of the coccygeus muscle, external anal sphincter and obturator internus muscle using Dexon 0 in separated points.

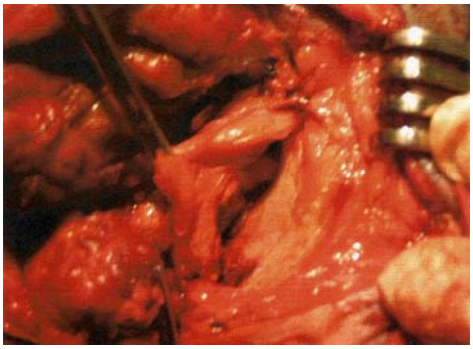

Fig. 1. The rise of obturator internus muscle of the ischium

Fig. 2. The suture of the obturator muscle after detachment

The third group was composed of five subjects, four of them were relapses cases, and one was bilateral hernia. In those cases for closing the hernia we used prosthetic (fig.3) implants, respectively Dexon tables which was sutured to the musculature as coccygeus muscle, internal obturator muscle and sacrotuberale ligament. After surgery all dogs for were on three days treatment with antibiotics.

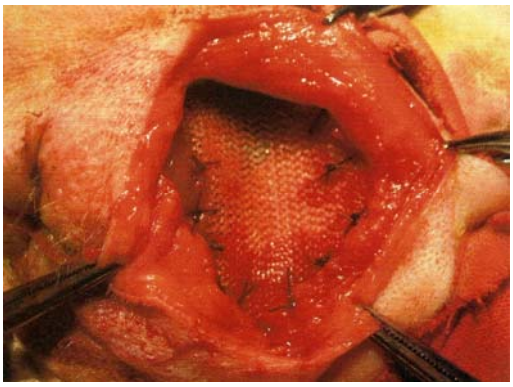

Fig. 3.The application and fixation of the Dexon mesh

RESULTS AND DISCUSSIONS

It should be noted that the incidence is higher in males than in females which shows that the emergence of this disease for males is in direct correlation with specific diseases in this category or anatomical features at this level. Thus, our study consisted only of males of different ages, showing a high incidence compared to that category. Although the standard process of the herniorrhaphy can be considered more attractive because it is made faster and more cheaper in long term the prognosis is reserved, and recurrences are frequent because of high pressure coming from the abdominal cavity in a weakened musculature. The absence of a strong musclulature make the pelvic diaphragm to yield approximately the same as the debut. During suturing the large spaces are not recommended because it creates crowded places with tissues under pressure, while the suture too close can cause local ischemia and necrosis with development of fistulas. Alongside operated the subjects will receive a proper diet to avoid coprostasis. We chose the second method because we noticed that by using the previous method in some situations at some patients a considerable tension upon the suture in the ventral lateral pelvic region because of the reposition of the obturator internus muscle to the external anal sphincter or coccygeus muscle simultaneous with a deformation of the external anal sphincter. This aspect is supported by observations such as the ventral area of operation is more susceptible to recurrence of hernia than dorsal and lateral areas. Through

this process we can say that at the points of suture the tension is greatly reduced which reduces the number of relapses. In fact, in those six cases over the interval of three in our study we didn't see relapses. Regarding the use of prosthetic mesh we can say that they provide very good results and should be used in the chronic hernia when the pelvic diaphragm, in some cases, remains only a trace and levators ani muscle is atrophied or broken. When the prosthetic mesh is properly implanted in aseptic conditions decrease the side of rejection or relapse. Whatever the chosen method is, for perineal hernias need to consider maintenance requirements and diet. After surgery will be to prevent owners of dogs that feed must be done with nutrients who does not predispose to constipation. In the case of chronic illness or in situations of the prostate disease (benign prostatic hypertrophy) will recommend preventive orchidectomy as a means to induce the appearance coprostasis tenesmus accompanied by increased pressure on the pelvic urethra.

CONCLUSIONS

1. Perineal hernia is a pathological entity with a high incidence in males aged between 8-13 years and may develop unilateral or bilateral.
2. Perineal hernia in dogs must be resolved as soon as possible because it may be complicated by bladder retroflexia (20-50% of cases), rectum flections (15-50% of cases), the rectal diverticulum, rectal sacculation, etc..
3. The standard herniorhaphy does not provide a long-term good results, therefore we can record relapses in different percentages as pelvic diaphragm does not provide a reliable stability at high pressures.
4. The method of herniorhaphy by subperiosteal rising of the obturator internus muscle upon the ischiatic arch provides good results by strengthening the broken pelvic wall which greatly reduces recurrences.
5. Use of prosthetic implants is indicated to be used in all cases of chronic perineal hernia in cases of major flaw, when the musclulature at this level suffer atrophy,is broken or have damages.

BIBLIOGRAPHY

1. Dietrich H.F., Perineal hernia repair in the canine. Vet Clin North Am 5:383, 1975.
2. Hardie E.M., Kolata R.J., Earley T.D., Evaluation of internal obturator muscle transposition in treatment of perineal hernia in dogs. Veterinary Surgery, 12, 69-72, 1983.
3. Hayes H.M. Jr şi col., The epidemiologic features of the perineal hernia in 771 dogs. In: Slatter D: Texbook of Small Animal Surgery, 3rd ed., Saunders, philadelphia, 2002.
4. Pettit G.D., Perineal hernia in dog. The Cornell Veterinarian, 52, 261-279, 1962.
5. Sjollema B.E., van Sluijs F.J., Perineal hernia in the dog: developements in its treatement and retrospective study en 197 pacients. Tijdschr Diergeneeskd. Feb. 1; 116(3): 142-7, 1991.
6. Soliman S.M., Anchorage overlapping repair of incisional hernia, J.R. Coll Surg. Edinb, 34, 140-142, 1989.
7. Vnuk D., Maticic D., Kreszinger M., Radisic B., Kos J., Lipar M., Babic T., A modified salvage technique in surgical repair of perineal hernia in dogs using polypropylene mesh. Veterinary Medicine, 51, (3): 111-117, 2006.

SOME OBSERVATIONS REGARDING STANDING CASTRATION IN HORSES

L. OANA, C. OBER, C. PESTEAN, V. MICLAUS, A. N. OROS, O. NEGREA, Daniela OROS

University of Agricultural Sciences and Veterinary Medicine, 400372 Cluj-Napoca, Mănăştur Str. no. 3-5, Cluj, Romania, e-mail: cipri_ober@yahoo.com

ABSTRACT

This study aimed to characterise a current practice method relating to castration in horses, namely standing castration. Five healthy stallions, different rases and ages, were castrated in standing position. The restraint, anaesthetic/sedative/analgesic drug protocols and open technique of castration provided no major complications in immediate post-operative interval. A hematoma in caudal portion of a scrotal sac was formed in a patient, but it was evacuated after 24 h. The hematoma was the result of an insufficient incision on scrotal sac. Our study confirm that castration performed with the horse in standing position, is a safe and efficient method, if the stallion is selected prudently and adequatly sedated.

Keywords: castration; horse; standing position

INTRODUCTION

Castration is a procedure performed routinely on all domesticated species. In the European Community economic and public welfare pressures have directed research towards optimising castration techniques which minimise stress and pain associated with the procedure (McGlone and Hellman, 1988; McGlone et al., 1993; Kent et al., 1993; Kent et al., 1995; Kent et al., 1998; Molony and Kent, 1993; Taylor et al., 2001 and McGlone and Hicks, 2003). The impact of different analgesic and anaesthetic protocols (including general anaesthesia, sedation, non-steroidal anti-inflammatory drug (NSAID) administration and suckling of glucose solutions) and different castration methods on post-castration stress, growth and welfare is well documented in large animals and legislation has been implemented to ensure adherence to techniques proven to optimise animal welfare (Price et al. 2005; European Union Directive 91/629/EEC, 1991 and European Union Directive 91/629/EEC, 1991 and 91/630/EEC).

Castration is one of the most common equine surgical procedures and is ussually performed to sterilize horses unsuitable for the genetic pool and to eliminate masculine behavior (Auer 2006). A range of open and closed surgical techniques, sedation and anaesthetic protocols are described for equine castration (Colahan et al., 1999; Adams and Fessler, 2000).

Our study aimed to characterise current practice relating to open equine castration in standing position, a relatively new practice in Romania. It provides an overview of open current technique, postoperative complications and sedative/anaesthetic/analgesic protocols used for equine standing castration.

MATERIALS AND METHODS

Study design

Five healthy stallions, different ages (between 2 and 5 years), mixed breed, were chosen to be castrated in standing position, with the owner\s consent (Table 1)

Table 1. Signalment of the animals

Breed	***Age (months)***	***Weight (kg)***
1. Mixed breed	25	350
2. Mixed breed	30	420
3. Mixed breed	45	450
4. Mixed breed	36	410
5. Mixed breed	56	500

Preoperative management

We performed a general physical examination of all stallions (heart rate and sounds, temperature, respiratory rate) and an inspection of scrotal area regarding presence of both testicle or inguinal herniation. Preoperative sedation with acepromazine 0,03 mg/kg (Sedam*, S.C. Pasteur Filiala Filipesti S.R.L, Romania*) permitted a safe palpation of the scrotal area. The horses were carefully selected regarding the hostile response to genital area palpation also before sedation. A lip twitch was applied in all horses for supplementary safety.

Anaesthesia

Analgesic and anaesthetic protocols consisted in administration of a combination detomidine 9 mg/kg (Domosedan, *Pfizer*), butophanol tartrate 0,025 mg/kg (Butomidor, *Richter Pharma*) and a non-steroidal anti-inflammatory drug (NSAID) by an intravenous jugular catheter (1,1 mg/kg Flunixin meglumine, Banamine, *Ceva*). The scrotum was anesthetized with lidocaine hydrochloride (Lidocaine HCL, *Steris Laboratories*) on each side cranial to caudal edge along the line of incision. About 20 ml of lidocaine was also injected into parenchyma of each testicle (Fig. 1). Local asepsy was made using a chlorhexidine solution.

Surgical techniques

Two parallel incisions about 10-cm-long were made on either side of the raphe (Fig. 2) and the testes were isolated by digital dissection (Fig. 3). Open technique was performed, so, the parietal tunic was incised. Caudal ligament of epididymis was digitally transected so the testis and spermatic cord were freed from the parietal tunic. Removing of the testis was performed using Reimer emasculators applied for 10 minutes on each spermatic cord (Fig. 4). About 6 ml

of iodoform-ether was spread into the each scrotal sac after ablations. An antibiotic ointment (Asocilin, Antibiotice Iasi) was applied on each scrotal lips to prevent local infections and to assure the adequate drainage by delaying the scrotal adherences.

Fig. 1. Analgesia of testicular parenchyma

Fig. 2. Scrotal incision

Fig. 3. Isolation of the testis

Fig. 4. The emasculator applied on vascular components

Postoperative management

The horses received tetanus antitoxin and the activity was restricted 24 hours postoperative. A daily slow exercises were recommended to prevent scrotal edema. Postoperative antimicrobial treatment consisted in administration of penicilin-streptomicin (Pen-Strep®, *S.C. Pasteur - Filiala Filipesti*) for three days. The tail was immobilised to prevent contamination of scrotal area.

RESULTS AND DISSCUTIONS

In all horses, small quatities of blood from scrotal vessels slooped for 15-20 minutes, but this is usually not a serious problem.

In a single horse we placed a transfixic ligature (Vicryl no. 2) on spermatic cord (Fig. 5) to prevent hemorrage, but usually this is not necessary. Moreover, the use of a ligature may increase the incidence of infection at the surgery site (Moll et al., 1995).A relatively large hematoma was organised in a scotal sac of a horse (Fig. 6) because of an insufficient incision of

the scrotum. A gloved finger was introduced in scrotal sac in the next day and the hematoma was completely freed. After, a generous portion of the caudal scrotum was removed to promote an adequate drainage. Vigorous exercises was also recommended to eliberate all the secretions. Removing a generous portion of the scrotum during castration avoid both exxcesive edema or hematoma.

Fig. 5. Ligation of spermatic cord

Fig. 6. Hematoma

After disscutions with the owners, no other postoperative complications were observed. The wounds healed after 3-4 weeks after surgeries in all stallions.

The open technique can lead to evisceration, an uncommon but potentially fatal complications, but these predisposed horses may have a pre-existing, unapparent, congenital, inguinal hernia (Auer 2006). For this, horse's inguinal area should be palpated for the presence of an inguinal hernia before the horse is castrated (Auer 2006).

Bacterial peritonitis is another major complication which can occur in horses castrated using open technique. Bacterial peritonitis can occur because of the communication between the cavity of the vaginal process and the peritoneal cavity. In the study of Schumacher et al. (1987), on three horses, one horse survived. Peritoneal fluid was obtained from two of the horses, and contained nucleated cell counts greater than 100,000/l with predominantly degenerate neutrophils. Bacteria were seen on direct smears of the peritoneal fluid of one horse. Since nucleated cell counts greater than 10,000/l commonly occur in the peritoneal fluid following castration in the horse, degenerate neutrophils and bacteria in the fluid are important criteria for the diagnosis of bacterial peritonitis (Schumacher et al., 1987).

Our study confirm that, standing castration of horses is a good option for the surgeon, which decrease post-operative discomfort, is less time consuming and is very safely if minimal perioperative rules are applied.

CONCLUSIONS

1. Anesthetic protocol consisting in combination of detomidine-butorphanol tartrate-flunixin meglumine, associated with a properly parenchymal testis desensitizing, make from standing castration a safely and efficient method in horses.
2. The technique is less time consuming and assistance, it prevents the accidents of recumbency restraint by throwing down and postoperative complications can be resolved without reanesthetizing the patient .

3. Immediate potentially perioperative complications can be prevented by a careful anamnesis, a prudently selection of the horses regarding the temperament and a good preoperative evaluation of the physical status of the patient.

REFERENCES

1. **Adams and Fessler, 2000 In: S.B. Adams and J.F. Fessler, Editors, Castration,** Atlas of Equine Surgery, W.B. Saunders, Philadelphia (2000), pp. 209–214.
2. **Auer J**., Equine Surgery, ed. 3, Saunders-Elsevier, St-Louis, Missouri (2006), pp. 788-789.
3. **Colahan et al., 1999 In: P.T. Colahan, I.G. Mayhew, A.M. Merrit, Moore J.N.,** Editors, Castration, Equine Medicine and Surgery, Mosby, St. Louis (1999), pp. 1024–1029.
4. **European Union Directive 91/629/EEC, 1991** European Union Directive 91/629/EEC, 1991. European Union Directive laying down minimum standards for the protection of calves.
5. **European Union Directive 91/629/EEC, 1991** European Union Directive 91/629/EEC, 1991. European Union Directive laying down minimum standards for the protection of pigs.
6. **Kent et al., 1993 Kent J.E., Molony V., Robertson I.S.,** Changes in plasma concentrations of cortisol in lambs of three ages after three methods of castration, Research in Veterinary Science 55 (1993), pp. 245–251.
7. **Kent et al., 1995 Kent J.E., Molony V. and Robertson I.S.,** Comparison of the Burdizzo and rubber ring methods for castrating and tail docking lambs, Veterinary Record 136 (1995), pp. 192–196.
8. **Kent et al., 1998 Kent J.E., Molony V., Graham M.J.,** Comparison of methods for the reduction of acute pain produced by rubber ring castration or tail docking of week-old lambs, Veterinary Journal 155 (1998), pp. 39–51.
9. **McGlone J.J., Hellman J.M.,** Local and general anesthetic effects on behavior and performance of two- and seven-week-old castrated and uncastrated piglets, Journal of Animal Science 66 (1988), pp. 3049–3058.
10. **McGlone J.J., Nicholson R.I., Hellman J.M., Herzog D.N.,** The development of pain in young pigs associated with castration and attempts to prevent castration-induced behavioral changes, Journal of Animal Science 71 (1993), pp. 1441–1446.
11. **McGlone J.J., Hicks T.A.,** Teaching standard agricultural practices that are known to be painful, Journal of Animal Science 71 (2003), pp. 1071–1074.
12. **Moll H.D., Pelzer K.D., Pleasant L.S., et al.,** A survey of equine castration complications, J. Equine Vet. Sci 15 (1995), pp. 522-526.
13. **Molony M V., Kent J.E.,** Behavioural responses of lambs of three ages in the first three hours after three methods of castration and tail docking, Research in Veterinary Science 55 (1993), pp. 236–245.
14. **Price J., Eager R.A., Welsh E.M., Waran N.K**., Current practice relating to equine castration in the UK, Research in Veterinary Science (2005), pp. 277-280.
15. **Schumacher J., Scrutchfield W.L. Martin M. T.,** Peritonitis following castration in 3 horses, Journal of Equine Veterinary Science (1987), pp. 220-221.
16. **Taylor A.A., Weary D.M.,. Lessard M., Braithwaite L.,** Behavioural responses of piglets to castration: the effect of piglet age, Applied Animal Behaviour Science 73 (2001), pp. 35–43.

ASPECTS REGARDING THE TECHNIQUE OF ORCHIECTOMY IN ROOSTERS *(GALLUS GALLUS)*

L. OANA, C. OBER, C. PEŞTEAN, V. MICLĂUŞ, O. NEGREA, A. N. OROS, L. OGNEAN, Daniela OROS

University of Agricultural Sciences and Veterinary Medicine, 400372 Cluj-Napoca, Mănăştur Str. no. 3-5, Cluj, Romania, E-mail: cipri_ober@yahoo.com

ABSTRACT

To evaluate a surgical technique of orchiectomy in birds, eight domestic roosters (Gallus gallus) were evaluated. Anesthesia was maintained using propofol and isofluraneand the surgeries were performed through last intercostal space, both testicles being removed through the same incision. Procedures were generally with minor complications in seven roosters. A single rooster exhibited repeted signs of apneea with comb and wattles cianosis probably due to an occult diseases complicated by propofol administration and it was euthanisied. The recovery from anesthesia was very quickly (15-25 minutes) in both protocols of anaesthesia. Orchiectomy appear to be a safe procedures in healthy roosters, if the anatomy of birds reproductive tract is well known and careful attention is directed to control intraoperative haemorrhage.

Keywords: capon**;** haemorrhage; orchiectomy; rooster

INTRODUCTION

Orchiectomy in roosters is performed esspecially to obtain capons. Caponisation produces a bird prized for its tenderness, and takes the stringiness out of a cockerel's meat. The Romans are credited with inventing the capon. The Lex Faunia of 162 BCE forbade fattening roosters as a way of conserving grain. In order to get around this the Romans castrated roosters, which resulted in a doubling of size (Toussaint-Samat 2009). European Gastronomic texts of the past dealt largely with capons, as the ordinary chicken of the farmyard was regarded as peasant fare, "popular malice crediting monks with a weakness for capons". Castration alters the sexual maturity rhythm, and castrated roosters are more tender and succulent than those of entire males (Mast et al., 1981), becoming a product in high demand from consumers. The main effect of castration is the increase in fat deposits, both intramuscular fat (a very important characteristic for consumer acceptance) and abdominal fat (Cason et al., 1988).
Regulation 1538/91 EEC fixes the minimum slaughter age for capons at 150 days (Miguel et al., 2008). At this age, capons from heavy breeds may reach 5 or 6 kg, which exceeds the commercial weight for home consumption. That is the reason why slow- growing breeds are often used; they reach more suitable weights for selling at slaughter age and they can be reared in a free-range system, since the usual rearing time ranges between approximately 210 and 230 days. At these ages, the meat usually has some sexually determined odour and flavour, as has been demonstrated by tasting trials carried out with restaurateurs and housewives at the Animal Production Section of the Soria University College of Agricultural Engineers (Miguel et al., 2008). The purpose of this study was to describe the anaesthetic management, surgical technique of caponisation and its possible complications. As a result we

should be able to offer some informations about the orchiectomy in domestic roosters in order to minimalise the morbidity and mortality rate associated with surgery.

MATERIALS AND METHODS

Study design

Eight domestic roosters, 6 months age, were individually identified and divided into two lots. The first was composed of roosters anesthetized with propofol and the other one of roosters castrated under isoflurane induction and maintenance. The main functions were monitored by a pulseoximeter (Mindray PM-9000 Vet) positioned on the comb and the recovery from anesthesia was clinically evaluated.

Preoperative management

We performed a general physical examination of all roosters, after that the left last ribs area was deplumed (Fig. 1) and a jugular catheter was fixed. The birds were placed in right lateral recumbency and the uppermost wing was reflected dorsally.

Anaesthesia

Butorphanol (Butomidor, Richter Pharma) 1 mg/kg was used as a pre-anaesthetic agent. The induction of anesthesia in four roosters was made with propofol 4 mg/kg intravenously (Fig. 2) and maintenance also with propofol was performed at a dose of 0,5 mg/kg/min. IV.
An endotracheal tube 4.0 was introduced (Fig. 3) in the other four roosters and induction of anesthesia was assured by isoflurane 3% (Fig. 4) via the Drager Spiromat 650 anesthesia gas machine (semi-closed circuit). Induction was made using an anesthesia face mask. The maintenance of anesthesia was assured by Isoflurane 2%. Intraoperatory functions were recorded by the pulseoximeter.

Fig. 1. Sugical area (black line)

Fig. 2. Anaesthesia with propofol

Fig. 3. Endotracheal tube fixation

Fig. 4. Anesthesia with isoflurane

Surgical techniques

Acces to the testicles was made through a left last intercostal space. The skin was incised (carefully to avoid the intercostal artery) and also the intercostal muscles (Fig. 5). Williams and Farabeuf retractors were applied between the two ribs and an opening of the posterior airsac was performed. The testicles, attached to the dorsal abdominal wall, adjacent to the aorta, are connected with it by a short testicular artery. The left testicle was identified (Fig. 6), elevated and a surgical Pean forceps was applied on its artery (Fig. 7). A no. 2-0 Dexon wire was passed under the forceps and arround the artery, and the testicle was removed by an incision between it and the forceps (Fig. 8). All the testicular tissue was removed. A blunt dissection through the airsac wall permitted the acces to the right testicle which was removed in the same way as its congener. The intercostal space and skin were closed routinely. Small quantities of blood after testis ablation were absorbed by a hemostatic pad.

Fig. 5. Skin and intecostan muscles incision

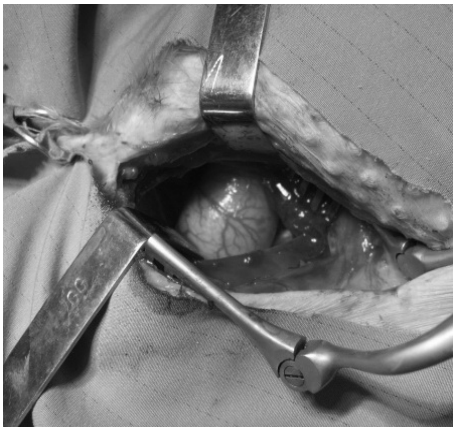

Fig. 6. Left testicle identification

Fig. 7. Pean forceps applied on testicular artery

Fig. 8. Testicular ablation

Postoperative management

The roosters were housed in a quiet and warm room for prevention of self trauma, where its were observed for recovery from anesthesia. Postoperative antimicrobial treatment consisted in administration of amoxicilline/clavulanate (Synulox, Pfizer) i.m. for three days, into the pectoralis muscles.

RESULTS AND DISSCUTIONS

The unique anatomy and physiology of the avian reproductive tract results in a poorly accessible organ system, so a clear understanding of the anatomy of the avian male reproductive tracts is vital before surgical exploration (Echols, 2002). Surgical instrumentation and techniques have become specialized for avian reproductive tract surgery, because of the need for small size (Echols, 2002). In our patiens, no major intraoperative complications were observed. In a single patient, a haemorrhage occured after the forceps was released. The hemostasis was resolved with a hemostatic pad. Postoperatively, a rooster exhibited repeted signs of apnea (Fig. 9) with comb and wattle cianosis probably due to an occult diseases complicated by propofol administration and it was euthanisied. For the others, the recovery from anaesthesia was very good (Fig. 10), and it devolved in aproximatively the same time both for those anesthesied with propofol and isoflurane (15-25 minutes). The anesthesia with propofol assure a very good field for short surgeries, but for this an intravenous catheter must be applied. A continuous administration is required because the profofol is rapidly metabolised that it gives a very short period of anesthesia. Because of this, and because of its narrow safety margins (Machin and Caulkert, 1996) some authors, (Coles 2007) consider that its used in birds even as an induction agent is not very practical.

Fig. 9. Acute episode of apnea immediate postoperative in a rooster

Fig. 10. Normal recovery from anaesthesia

Isoflurane is a very good choice, inducing the desired depth of anaesthesia, the single disadvantage consisting in loss of the gas alongside the endotracheal tube (no 2) which not have an inflatable cuff. Because of its safety and the ease with which it can be given, it can be administered if necessary two or three times daily for the routine taking of blood samples, the changing of dressings or the administration of parenteral fluids, etc. Coles et al. (2007) has used it for the last 28 years for several thousand birds of a variety of species with very few anaesthetic fatalities. Butorphanol (1 mg/kg) is a useful pre-anesthetic, it reduces the dose of anaesthetic used and provides good post-operative pain relief (Coles 2007). Although Schmitt et al. (1998) indicated that using a pulsoximeter in birds could give a false impression of safety, we are agree with Coles (2007) which sugests a constant monitoring of arterial oxygen saturation during surgical procedures, because below the value of 80% it can be dangerous. Regarding the surgical technique, must be mentioned that opening of the posterior airsacs of the rooster during celiotomy is inevitable. This leads to loss of volatile anesthetic agents from the airsac together with increased heat loss (Samour 2007). So, during any celiotomy procedure, the bird's heat shoud be raised at 30-40° to prevent any surgical irrigation fluid from entering the lung field (Samour 2007). It also very important that any testicular tissue to be removed, otherwise there is a possibility of regeneration. Although we performed the ablation on right testicle by blunt dissection through the airsac wall, this is a difficult procedure, so a contralateral abdominal wall incision offers a better acces (Samour 2007).

CONCLUSIONS

1. Anesthetic protocol consisting in administration of propofol via an intravenous catheter is a good option for short surgeries in roosters, but a continuous administration is required because of its rapidly metabolization. Its narrow safety margins lead to fatalities if a poor general preoperative status is observed.
2. Volatile anaesthesia with isoflurane is a better choice because of its safety and the ease with which it can be administered.
3. Surgical technique of orhiectomy in roosters is not very difficult, if the anatomy of the avian male reproductive tracts is clear understood and a good hemostatic intraoperative management is performed.

REFERENCES

1. **Coles B.H.,** Essentials of avian medicine and surgery, Blackwell Publishing Ltd., Oxford, U.K., (2007) pp. 124-138.
2. **Cason J.A., Fletcher D.L., Burke W.H.,** Effects of caponization on broiler growth, Poultry Science 67, pp. 979-981.
3. **Echols M.S.,** Surgery of the avian reproductive tract, Journal of Exotic Pet Medicine, 11:4, (2002) , pp. 177-195.
4. **Machin K.L., Caulkett N.A**., The cardiopulmonary effects on propofol in mallard ducks, Proceedings of the American Association of Zoo Veterinarians, pp. 149-154.
5. **Maguelonne T.S,** The History of Food, Ch. 11 "The History of Poultry", revised ed. 2009, p. 305.
6. **Maguelonne T.S.,** The History of Food, Ch. 11 "The History of Poultry", revised ed. 2009, p. 309.
7. **Mast M.G., Jordan H.C., Macneil J.H**., The effect of partial and complete caponization on growth rate, yield and selected physical and sensory attributes of cockerels, Poultry Science 60, pp. 1827-1833.
8. **Miguel J.A., Ciria J., Asenjo B., Calvo J. L.,** Effect of caponisation on growth and on carcass and meat characteristics in Castellana Negra native Spanish chickens Animal (2008), 2:2, pp 305–311.
9. **Samour J.,** Avian Medicine, second edition, Mosby-Elsevier, St. Louis, (2007), pp. 160.
10. **Schmitt P.M., Gobel T., Trautvetter E.,** Evaluation of pulse oximetry as a monitoring method in avian anaesthesia, Journal of Avian Medicine and Surgery, 12, (1998) pp. 91-9.

THE CORRELATION BETWEEN THE PROGESTERONE LEVELS 6-7 DAYS POST INSEMINATION AND THE PREGNANCY LOSS IN COWS

G. OTAVA
Faculty of Veterinary Medicine, Timisoara, Romania
gabiotava@yahoo.com

ABSTRACT

The foetus development is dependent on the corpus luteum life span for the pregnancy progesterone support. Low levels of progesterone result in strong luteolytic signals that may cause gestation loss in its early stages. The data regarding a connection between the progesterone levels 4-7 days post insemination and the conception rate are controversial. The aim of this study was to evaluate the correlation between the progesterone level 6-7 days after the insemination and the pregnancy loss in cows. 38 cows were monitorized out of this were 26 milk cows and 12 heifers. The progesterone levels were established in 6-7 days post insemination using the spectrometry method. These results were compared with the ones established after the rectal palpation was performed in 50-60 days post insemination. When selecting the sampler moment, the data in the literature were taken into account. According to these only after the 5th day post insemination a positive correlation between the progesterone levels and the conception rate might appear. The 38 females were divided into two groups according to the progesterone levels criterion. In the first group, the cows had the progesterone levels lower than 3 ng/ml, in the second above 3 ng/ml. Pregnancy rate was calculate on each group of female. After the non-parametrical χ^2 test was performed the following conclusion occurred: the conception rate is not influenced by the P_4 levels (P = 0,39).These results indicate there is no positive correlation between the progesterone levels 6-7 days post insemination and the pregnancy rate.

Key words: *pregnancy loss, cows, progesterone*

INTRODUCTION

Within the bovine, the gestation getting installed and maintained depend the starting of the luteolytic mechanisms by the maternal body and production of trophoblastic interferon by the conceptus; breaking this equilibrium results in the pregnancy loss (7). Studying the fertilized cows, the conceptus development depends on the CL life span for the progesteronic sustainment for the pregnancy. According to Garett quoted by 6 the progesterone (P4) administration increase the protein secretion by the endometrium. These secretions supply the foetus with the necessary support for the development, thus influencing the development rate. Reading, the conceptus will produce a trophoblastic protein-γ, known as trophoblastic interferon, trophoblastine, BTP (bovine trophoblast protein). Inderjeet and the others (3) underline the importance of the P4 during the first days post fertilization. A critical moment for the foetus survival is inducing, by the P4, a favourable environment on his way to the uterus – day 4-5 post fertilization.

Comparing the P4 levels in a few days post fertilization, Mann and others (6) note lower values within cows with pregnancy loss after just the 5th day post insemination. Most of the researchers consider the IFN-γ may have an inhibitive action on the receptors for the ocitocine in the endometrium, thus preventing the luteolysis (1, 6, 7, 9, 11). It seems that this maternal recognition hormone inhibits the oestrogen receptors from the uterine epithelium. The cows pregnancy maintaining is dependant upon the fragile balance between the mechanisms involve in the luteolytic process and realizing the substances preventing the CL regression (11). Within the milk cows, most of the pregnancy loss takes place during the first period of the gestation, up the moment when the maternal recognition of the gestation occurs, days 14-17 post insemination (6). The conceptus dependence on P4 is sustained by studies referring to the hormone supplementation immediately after insemination. Mann and Lamming quoted by 11 demonstrate a visible improvement in the conception rate (10,3%) when P4 is administrated before the day 6 post insemination. After the day 6, the improvement is just 1,4%. According to Garrett quoted by 6 inoculation of P4 between days 2 and 5 post insemination will results in an embryo development in length and a higher value of interferon-γ. Mann and others (6) notice a higher value in the INFγ secretion at the cows that were administrated P4 days 5 to 9 postinsemination , compared with those given the P4 days 12 to 16 post insemination. The stress generated the heat has a negative impact on the level of some hormones, among which P4, noticing higher levels of P4 during cold seasons (12). As a results, the secretion of the androgens hormones in theca interna, and estradiol in granulosa is negatively influenced. This pattern will alter the P4 secretion. The P4 lowering has a negative influence on the steroidogenesys from the dominant follicle and CL with repercussion on the endometrium morphology and embryonic death (Ahmad şi Shaham cit. de 2).

MATERIALS AND METHODS

38 cows (26 milk cows, bothe primiparous and multiparous, and 12 heifers) were studied. The females on heat were detected three times per day: early in the morning, at noon and late in the morning. The females that try to mount other females and accept to be mounted were considered in oestrus. The artificial insemination was performed with forzen semen, following the AM/PM rule. The blood samples were collected in 6-7 days after the insemination. Choosing this period the data in the literature were taking into account; accordingly the conception rate and P4 levels are positively linked following the day 5 post insemination (6). The data in the literature regarding the possible link between the progesterone values before day 6 post insemination and the pregnancy loss are controversial. The blood samples were taken in the 6-7 day after the insemination by puncturing the artery or the coccygeal vena. The blood was collected in vacuum recipients. The blood was carefully collected in the recipients in order to avoid haemolysis. To seed splitting the two blood components, the samples were subjected to manipulation in a manual centrifugal device, since the preserving temperature was to low and the serum would separate in a too long time period. The serum was carefully decanted in other recipients, previously labeled with the identification data for each animal. The samples were stored at -20°C until the P4 concentration was determined using the ELISA method. The research and measurements were performed in the Endocrinology Laboratory, within the Veterinary Medicine Timisoara. To establish the P4 level in the serum, we used the immunoenzimatic method, with the aid of the light wave and photometric device, with BIORAD components (SUA-FRANCE). The results were compared with those from the transrectal clinical examination performed at 50 days post insemination.

RESULTS AND DISCUSSIONS

The progesterone levels at the studied females in days 6-7 post insemination ranged between 0,11 ng/ml and 15,882 ng/ml. The P4 levels were superior in heifers compared to the cows, situation with consequences in the higher pregnancy rate at heifers of 66% (8 out of 12) than the cows of 50% (13 of 26). This, the P4 levels with heifers, measured in the days 6-7 post insemination were from 2,42 ng/ml to 15,88 ng/ml, with a average of 8,68 ng/ml; at the cows , the same values were from 0,11 ng/ml to 14,84 ng/ml, with an average of 5,08 ng/ml.
The 38 females in this study were divided into 2 groups, taking account the progesterone levels. At the first group (n=9) the P4 level was below 3 ng/ml and the second group (n=29) above 3 ng/ml. According to Starbuck [9] studies, 3 ng/ml is value that you have to take into account to predict if there is a link between progesterone level and conception rate.

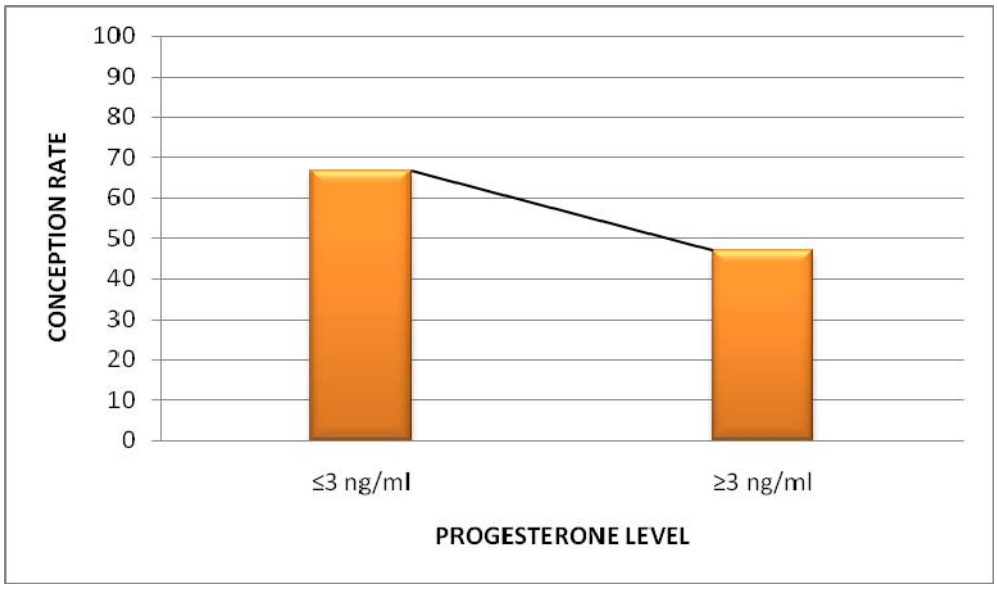

Fig. 1 Correlation between the progesterone level and pregnancy rate

The cows with P4 levels below 3 ng/ml recorded a conception rate of 66,66% (6 out of 9) and those in the second group with P4 levels above 3 ng/ml had a pregnancy rate of 46,42% (13 out of 26).

Establishing the progesterone levels at day 5 post insemination within more than 14.000 cows, Starbuck (9) links the low P4 levels at that moment with the low pregnancy rate. The cows with progesterone levels higher than 3 ng/ml had a conception rate of 50-55% and those with P4 levels below 3 ng/ml had a conception rate with 10% lower. It seems that the P4 deficiency before day 5 postinsemination gets lower from one lactation to the other (9). Mann (6) notice that a rapid growth in the progesterone level immidiately after fecundation, but no later than days 9-10 post fertilization results in a growing conception rate. Some studies links positively the fertility to P4 levels between days 4 up to 7 postinsemnation. Other authors do not share the same opinion (1). After the non-parametrical χ^2 test was performed the following conclusion occurred: the conception rate is not influenced by the P_4 levels (P = 0,39).

As the study shows, the cows had an average of the P4 levels smaller than those of heifers. This has a consequence in a lower conception rate within cows (50%) compared to the heifers (66%).

A lot of data links the fertility low values with the high milk productions. Vasconcelos and others quoted by (1) notices P4 plasmatic levels lower at cows with high milk productions

than at cows with smaller milk productions. At milk cows, the studies notice a lowering of P4 levels compared to the levels proved at the same breed three decades ago. The researchers noticed a lowering in the conception rate and smaller P4 levels within the high production dairy cows, but this aspect is not yet completely demonstrated (10). It seems that this phenomenon is due to increasing of the fodder consumption and milk production (10).
A growth in the fodder consumption results in a higher blood stream in the liver and a lowering of P4 levels and estrogens (8, 10). This fertility lowering is due to, at least partly, the more intense progesterone catabolism within cows with high milk productions (1).

CONCLUSIONS

1. The compared study of the progesterone values at 6-7 days post insemination and its linkage with the conception arte did not confirm the data in the literature; those data underline the opinion the foetus survival is influence by the P4 values at days 6-7 post insemination.
2. Within cows, we could notice lower levels of the progesterone at days 6-7 post insemination compared to the heifers.

REFERENCES

1. Chebel, R.C., Santos, J. E. P., Cerri, R. L. A. Galvao, K. N., Juchem, S. O., Tatcher, W., *Effect of resyncronization with Gn-RH on day 21 after artificial insemination on pregnacy rate and pregnancy loss in lacting dairy cows.* Theriogenology 60 1389-1399, (2003)
2. Demmers K.J, Derecka K, Flint A., *Trophoblast interferon and pregnancy.* Reproduction Jan; 121(1):41-9, (2001)
3. Inderjeet, R.K., Phogat, J.B., Singh, U., Jangra, S., *Exogenous progesterone supplementation improve pregnancy rates in cattle and buffaloes.* Jornal of Reproduction and Fertility. Abstract series Nr.26 Dec. pag. 32, (2000)
4. Kristina, J., Demmers Kamila Derecka, Anthony Flint. *Trophoblast interferon and pregnancy.* Reproduction 121, 41-49, (2001)
5. Lulai, C., Kastelic, J.P., Carruthers, T.D., Mapletoft R.J., *Role of luteal regretion in embryo death in cattle.* Theriogenology 54 1320-1326, (1993)
6. Mann, G.E., *Corpus luteum function and early embryonic death in bovine.*, the 6th Budapest Workshop on Clinical Endocrinology, ENDO 2003
7. Mann, G.E., Lamming, G.E., *Progesterone inhibition of the development of the luteolytic signal in cow.* Jornal of Reproduction and Fertility 104, 1-5, (1995)
8. McSweeney, K., *Embryonic loss:What causes it, what amaunt is normal and how do i manage it?*Vol.10 No.1. Colorado Dairy News. Jan. (2004)
9. Starbuck, G.R., Darwash, A.O., Mann, G.E., Lamming, G.E., *Progesterone and ferility in dairy cow.* PhD. Thesis University of Nottingham, (2001).
10. Vasconcelos, J.L.M., Sangsritavong, S., Tsai, S.J., Wiltbank, M.C., *Acute reduction in serum progesterone concentrations after feed intake in dairy cows.* Theriogenology 60p. 795-807, (2003)
11. Wathes, D.C., Taylor, V.J., Cheng, Z., Mann, G.E., *Follicle growth, corpus luteum function and their effects on embryo development in post partum dairy cows.* the 6th Budapest Workshop on Clinical Endocrinology. ENDO 2003
12. Wolfenson, D., Sonego, H., Bloch, A., Shaham-Albalancy, A., Kaim, M., Folman, Y., Meidan, R., *Seasonal differences in progesterone production by luteinized bovine thecal and granulosa cells.* Domest. Anim. Endocrinol. Apr.; 22(2):81-90, (2002)

CORELATIONS BETWEEN BIOLOGICAL VALUE AND FERTILITY IN BEEF BULL BREEDS

V. D. PĂDURARU, D. DRUGOCIU, D. ALEXA, M. GRIGORAȘ, O. A. COJOCARU

F.M.V. IAȘI

ABSTRACT

Considering the low price of milk in our country, breeders are turning to beef production industry to compensate. For increasing the fecundity they need high quality semen and a control and analisys tehnique very well planned. Its estimated that at least one in five bulls from a population, has fertility problems due to low sperm quality. In the beef industry, the greatest economic loss that is attributable to bulls with ferility problems is low fecundity rate,(1), which may not be noticed by the producers and be attributed to females. Until recently, the microscopic examination of semen was the most important measure to determine the biological value of bull semen. The introduction of more sophisticated laboratory test will help to get a better correlation between biological value and fertility in the field (6). The aim of this study is to relieve the importance of the development of a computer assisted tehnique, to achieve more and more objective information about the biological value of fresh and frozen/thawed semen. For this we need semen of high quality and a analysis and control tehnique very well devised.

Keywords: semen, value, fertility, analysis

INTRODUCTION

The objective of such a laboratory is to produce and freeze semen for the beef breeds in Romania. An absolute necessity in the current context to convert the existing flock. The solution to stimulate livestock farmers, to obtain beef calves that are ment to bring higher or equal benefits with milk breeds, is the infusion of semen from beef breeds that have an increased productive potential. Its estimated that a bull produce annualy semen that could give birth to 20.000 calves. The aim is that the semen meet the terms of the biological value specified in literature standards. The existence of a computerized analysis sistem allows rapid and effective viewing, recording and monitoring of datas regarding the quality of semen, such way the errors due to human factor that appear at microscopic examination will disappear. You can choose in addition to automatic analysis system, a automatic program for printing, filling, sealing and freezing straws. Beef bulls intended for breeding are often in trouble due to nutritional deficiency problems. Energy needs can be met only through an appropriate dietary intake and a sensible operating system (1,3,5). Ignoring these goals makes the biological value, fertility and fecundity to be below standards. The existence of a computerized system allows semen fast analysis, determining biological value and their exclusion from breeding to improve the conditions of maintenance.

MATERIALS AND METHODS

The research was conducted in a specialized unit which has in its portfolio following activities: production of high quality semen, artificial insemination, embryo transfer and official control service of cattle production. The main activity is the production of semen from beef breeds bulls in a laboratory with modern equipment, both for semen analysis and printing, filling, sealing and freezing straws. The livestock includes 27 breed bulls (Angus, Simmenthal, Limousine, Wagyu, Sura de stepă). From those, 15 are mature, 10 in preparation and 2 genetically kernel. All bulls are coded and approved for semen production.
The unit has a modern laboratory equipped with IMV Technologies (France) equipment to produce frozen semen.
Equipment has the following characteristics:

- Evaluation -IVOS- Automatic computerized analysis system of semen;
- Printing - Jet Print Linx;
- Filling and sealing - MRS1 dual 1x1 (0,25 and 0,50 ml straws);
- Freezing - Mini-Digiticool Automat;
- Storage - Air Liquide GT40 containers;
- Consumables - 0,25 and 0,50 ml Cassou Genuine straws colored in different colors, Leja 20µl test slides with 4 rooms;
- BIOXcell diluent.

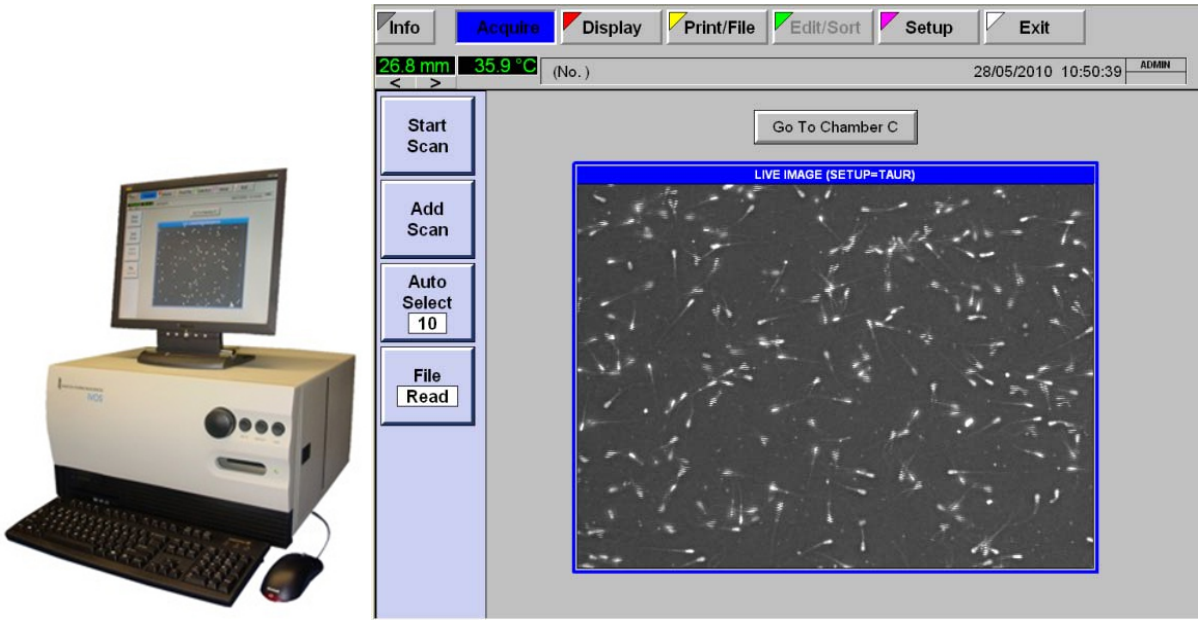

Fig. 1 Automated computerized system for semen analysis IVOS

This device allows viewing of sperm and semen analysis in real time, analysis of their morphology and determining final dilution adjustment factors depending on the concentration, morphology and sperm motility.

RESULTS AND DISCUSSION

After retrieving the semen, the collector tube is placed in the marine bath at a 37^0C temperature. In processing of semen is used BIOXcell diluent, prepared by combining with

bidistilled water: 100 ml diluent and 400 ml water. After retrieving, the collector tube is placed in the marine bath to appreciate the color, smell and volume of the ejaculate. The computer analysis of a sample of sperm is preceded by making a dilution ratio of 1:99 with an automatic pipette. Aspecting a concentration in semen dose, for A.I., between 15-25 millions sperms. These data are loaded into the computer for analysis with dilution ratio and ejaculate volume.
The computer will analyze and provide data about: sperm concentration per ml., sperm concentration per dose, which we want to get, motility, progressivity, velocity, viability, the amount of diluent to be added to the number of doses that will achieve from the analyzed ejaculate. All these data are stored into computer together with bull datas and so is accomplished bull spermogram. From the spermogram is estimated biological value of that bull semen. For example we use spermograms obtained from Wagyu breed bulls. This is a Japanese beef breed, characterized by tough animal that adapt easily. Wagyu breed became famous because its meat contains 30% more mono-unsaturated fatty acid than other beef breeds, which means a diet meat with positive effect on human health. Bulls were brought into the unit in the spring of 2010, where its underwent a quarantine process under current rules. In parallel, during this period were given good quality food and vitamin supplements to combat stress of transport. Note that in the choice of compound to combat acclimatization crisis were taken into account and reproductive capacity of males, because after lifting the quarantine has been planned a collection program to bring the reproductive capacity to an optimal level. In the same time they were undergoing a program of daily movement in a specially arranged carousel. In the analysis was monitored the concentration, sperm mobility and progressivity because these are the most important parameters to ensure a good relation between biological value and fecundity (4,7). Sperm concentration should exceed 500 million sperm per milliliter. Crude sperm mobility must be between 80-85% , for the diluted semen is between 60-70% and for frozen/thawed semen mobility must be at least 35-40% (2,7).
Progression is the percentage of sperm with rapid linear forward movement with species characteristic speed and must exceed 50% (4,7). At first collection, spermogram results were very poor. That thing was anticipated due to transport stress and increased time interval from the last collection. It is known that at the semen analysis, when collection intervals are large, percentage of dead sperm is increased, which means low mobility and fecundity. We notice at Fuji bull (Wagyu breed) that the semen was dense, with a concentration of 1.199 billions/sperms/ml. Despite these favorable results, found that motility was low, 15%. Progressivity was 3%, these means few filled straws(5 straws) and so a low fertility rate.
At the second collection there was a significant increase of mobility (30,9%), but still unsatisfactory. Progressivity has increased very little, this means that the bull has not yet resumed full process of spermatogenesis. Number of doses filled in straws in relation to the proportion of progressivity percent is 17. Third collection, revealed a return around benchmarks. Mobility of analysed semen, diluted 1:15 reached 60%, a more than satisfactory percentage. Progressivity has reached 49% making the number of doses filled in straws, given to this parameter,to be 47.

This indicates that feeding schedule, exercise and rehabilitation programs gave positive results.

11.06/11/04/2010

Summary report fuji/no.0546

SPECIMEN INFORMATION

Volume(mL)	3.50	sample:diluents	1:49,00
Req. total conc.	86.95	Req.progr.conc	96,00
Dose volume	0.23		
Procedure			
Series			
Collection time			
Test chemical			
Diluents			
pH			

COUNT SUMMARY

category	cells counted	sample	conc (M/ml)	percent
Total	744	4198,50	1199,57	100
Motile	109	615,10	175,74	15
Progressive	20	112,86	32,25	3

ANIMAL RESULTS

Parameter	value	units
Total sperm/dose	20,00	M
Diluate ejaculate to	48,29	ml
Total doses	209	
Progressive sperm/dose	22,08	M
Diluate ejaculate to	1,18	ml
Progressive doses	5	

08.43/17.04.2010

Summary report fuji/no.0546

SPECIMEN INFORMATION

Volume(mL)	5	sample:diluents	1:20,00
Req. total conc.	86,95	Req.progr.conc	96,00
Dose volume	0,23		
Procedure			
Series			
Collection time			
Test chemical			
Diluents			
pH			

COUNT SUMMARY

category	cells counted	sample	conc (M/ml)	percent
Total	886	2342,56	1171	100
Motile	274	724,20	362,1	30,9
Progressive	70	185	92,5	7,89

ANIMAL RESULTS

Parameter	value	units
Total sperm/dose	20,00	M
Diluate ejaculate to	24,45	ml
Total doses	73	
Progressive sperm/dose	22,08	M
Diluate ejaculate to	10,91	ml
Progressive doses	17	

08.26/21.04.2010

Summary report fuji/no.0546

SPECIMEN INFORMATION

Volume(mL)	2,00	sample:diluents	1:15.00
Req. total conc.	86.95	req.progr.conc	96,00
Dose volume	0,23		
Procedure			
Series			
Collection time			
Test chemical			
Diluents			
pH			

COUNT SUMMARY

category	cells counted	sample	conc (M/ml)	percent
Total	412	2125,69	1062,85	100
Motile	246	1269,22	634,61	60
Progressive	203	1047,37	528, 68	49

ANIMAL RESULTS

Parameter	value	units
Total sperm/dose	20,00	M
Diluate ejaculate to	24,45	ml
Total doses	106	
Progressive sperm/dose	22,08	M
Diluate ejaculate to	10,91	ml
Progressive doses	47	

Fig. 2 Spermograms of Fuji bull nr.0546 during collection program

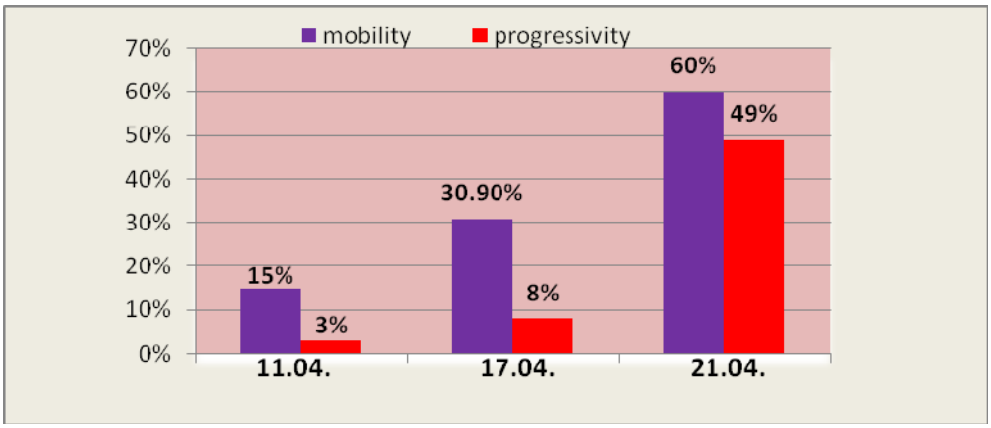

Fig. 3 Evolution of semen mobility and progressivity within the collection program from Fuji bull

The second bull, named Takuma, with serial number 0547, received the same program. First collection and analysis has revealed the negative effects of transport stress. Semen volume collected was very small (0.2 ml), analysis being performed without dilution due to low consistency valued at macroscopic examination. Concentration was very low (0.074 billions/sperms/ml), mobility 19%, progressivity 4%, this means that biological value of semen is very low and and therefore semen was not used. Results after the second collection were higher, revealing a recovery of male reproductive function.

The volume of collected semen was 1.2 ml which allowed a 1:40 dilution ratio. The analysis revealed a concentration of 0.46 billion/sperms/ml, representing a low density, unsatisfactory. Mobility was 32%, progressivity 17%, both values are well below accepted limits. Like the other bull, at third collection, the things came back to normal: collected volume of semen was 2 ml, and with a concentration of 1,289 billions/sperms/ml, mobility 80 %, progressivity 51%, and so the number of doses filled in straws in relation with the progressivity percentage reached 51. That raise the rating of biological value to better.

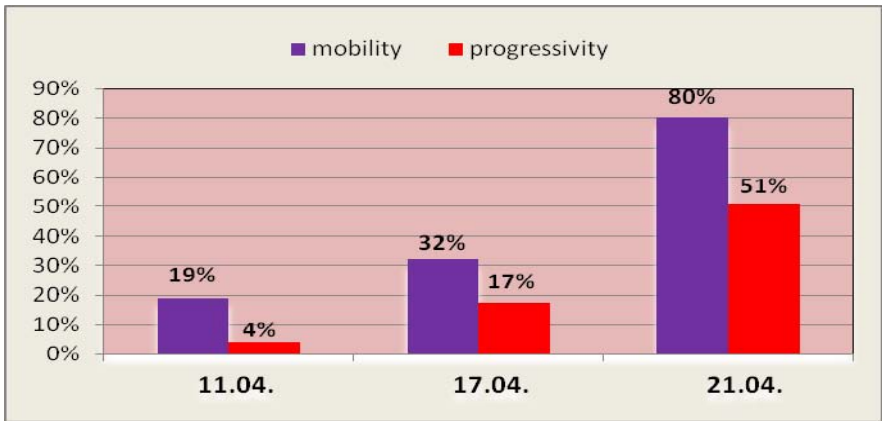

Fig. 4 Evolution of semen mobility and progressivity within the collection program from Takuma bull

11.21/11.04.2010

Summary report takuma/no.0547

SPECIMEN INFORMATION

Volume(ml.)	0,21	sample:diluents	1:0,00
Req. total conc.	86,95	Req.progr.conc	96,00
Dose volume	0,23		
Procedure			
Series			
Collection time			
Test chemical			
Diluents			
pH			

COUNT SUMMARY

category	cells counted	sample	conc (M/ml)	percent
Total	462	15,64	74,49	100
Motile	90	3,05	14,51	19
Progressive	17	0,58	2,74	4

ANIMAL RESULTS

Parameter	value	units
Total sperm/dose	20,00	M
Diluate ejaculate to	0,18	ml
Total doses	0	
Progressive sperm/dose	22,08	M
Diluate ejaculate to	0,01	ml
Progressive doses	0	

10.01/17.04.2010

Summary report takuma/no.0547

SPECIMEN INFORMATION

Volume(ml.)	1,20	sample:diluents	1:40,00
Req. total conc.	86,95	Req.progr.conc	96,00
Dose volume	0,23		
Procedure			
Series			
Collection time			
Test chemical			
Diluents			
pH			

COUNT SUMMARY

category	cells counted	sample	conc (M/ml)	percent
Total	582	563,02	469,19	100
Motile	186	179,94	149,95	32
Progressive	99	95,77	79,81	17

ANIMAL RESULTS

Parameter	value	units
Total sperm/dose	20,00	M
Diluate ejaculate to	6,48	ml
Total doses	28	
Progressive sperm/dose	22,08	M
Diluate ejaculate to	1,00	ml
Progressive doses	4	

10.43/21.04.2010

Summary report takuma/no.0547

SPECIMEN INFORMATION

Volume(ml.)	2,00	sample:diluents	1:20,00
Req. total conc.	86,95	Req.progr.conc	96,00
Dose volume	0,23		
Procedure			
Series			
Collection time			
Test chemical			
Diluents			
pH			

COUNT SUMMARY

category	cells counted	sample	conc (M/ml)	percent
Total	375	2539,41	1269,71	100
Motile	300	2031,53	1015,77	80
Progressive	190	1286,64	643,32	51

ANIMAL RESULTS

Parameter	value	units
Total sperm/dose	20,00	M
Diluate ejaculate to	29,91	ml
Total doses	126	
Progressive sperm/dose	22,08	M
Diluate ejaculate to	13,40	ml
Progressive doses	58	

Fig. 5 Spermograms of Takuma bull nr.0546 during collection program

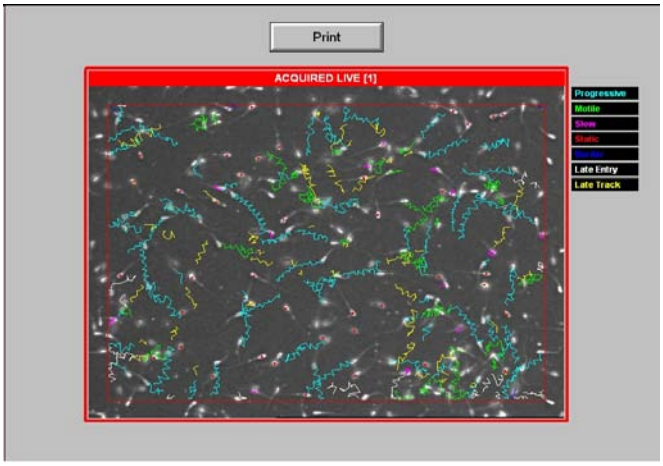

Fig. 6 Real time image of analysis system when determining sperm progressivity

The computer has the ability to group the sperms into categories according to their mobility. In figure 6 we see lime colored, the sperms with progressive mobility movements, from Fuji bull.

CONCLUSIONS:

1. Computerized analysis IVOS system offers sharp appreciation of semens biological value and fertilized value;
2. In the analysis was monitored the concentration, sperm mobility and progressivity because these are the most important parameters to ensure a good relation between biological value and fecundity;
3. At first collection, spermogram results were very poor. That thing was anticipated due to transport stress and increased time interval from the last collection. Takuma bull mobility 19%, progressivity 4%. Fuji bull mobility 15%, progressivity 3%;
4. At the second harvest there was a significant increase in mobility, but still unsatisfactory. Progressivity has increased very little, this means that the bull has not yet resumed full process of spermatogenesis Takuma bull mobility 32%, progressivity 17%. Fuji bull mobility 31%, progressivity 8%;
5. Third collection, revealed a return around benchmarks. This indicates that feeding schedule, exercise and rehabilitation programs gave positive results. Fuji bull mobility 60%, progressivity 49%. Takuma bull mobility 80%, progressivity 51%.

REFERENCES

1. **Barth A**., Evaluation of potential breeding soundness of the bull, from Curent therapy in Large animal theriogenology, Second edition, section II, Bovine theriogenology, chapter 31, pag.228, Saunders Elsevier Inc., 2007;
2. **Ciornei Șt., Drugociu D., Roșca P., Runceanu L**., Biosecuritatea însămânțărilor artificiale prin spermograma microbiologică la taurine-suine,cap. 3, pag.79, Ed. Ion Ionescu de la Brad, 2008;
3. **Drugociu D.,** Bolile obstetrical-ginecologice la animale, ediția a II-a, cap. 4, pag.154, ed. Ion Ionescu de la Brad, Iași, 2009;
4. **Drugociu D., Roșca P., Anton C., Runceanu L.,** Reproducție, obstetrică și andrologie veterinară, cap.13, pag.175-198, Ed. Venus, Iași, 2002;
5. **Fetrow J., Steward S., Eicker S., Rapnicki P.**, Reproductive health programs for dairy heards: Analysis of records for assessment of reproductive performance, from Curent therapy in Large animal theriogenology, Second edition, section II, Bovine theriogenology, chapter 61, pag. 486, Saunders Elsevier Inc., 2007;
6. **Leiding C.**, **Roman M.**, New tests to control semen quality in bulls, Lucrări științifice medicină veterinară vol. XLII (2), pag. 182, Timișoara, 2009.
7. **Mircu C.**, Elemente de reproducere asistata la animalele domestice, cap. 2 , pag.18, Timisioara, 2001.

HEMATOLOGICAL AND BIOCHEMICAL MODIFICATIONS OF BLOOD AND CEREBRAL SPINAL FLUID IN DOG MYELOGRAPHY USING NON IONIC CONTRAST SUBSTANCES OPTIRAY 350 AND ULTRAVIST 370

I. PAPUC, R. LĂCĂTUŞ, A. MUSTE, R. C. PURDOIU, S. BORBIL, Alexandra Nicoleta PĂVĂLOIU
Faculty of Veterinary Medicine
Calea Mănăştur, Nr. 3-5, Cluj Napoca, jud. Cluj, Romania
papuc_i@yahoo.com

ABSTRACT

This paper wants to introduce to veterinary medicine the non ionic contrast media used in human medicine, as a working material to obtain high quality myelographies in dogs for the paraclinical examination of nervous system disorders. Also, we will follow, comparatively, the modifications that these induce on the cerebral spinal fluid and certain biochemical blood constituents by administering two non ionic contrast mediums: Optiray 350 and Ultravist 370.

Key words: myelography, Optiray 350, Ultravist 370, spinal canal, cerebral spinal fluid.

Acknowledgements: This work was supported by CNCSIS-UEFISCSU, project number PNII-IDEI 847/2007.

INTRODUCTION

To visualize the normal aspect of the spine and the spinal canal, but also for the diagnosis of modifications that appear in different anatomical levels of the spine, it is imposed to perform myelographies with the aid of contrast medium [1, 2, 3, 6]. The progress made by researchers in identifying an ideal contrast medium have offered radiologists the substances in whose structure enter non ionic monomers as a main element in obtaining high quality radiological images. The contrast substances used not long ago had an excellent vascular tolerability, being successfully used in clinical use, especially uroangiography. The only problem related to theses substances was hyperosmolarity, which had a negative effect on the vascular endothelium [4,5,7,8]. Once the new nonionic contrast substances were discovered, which had a double osmolarity compared to blood, their ability is to increase tolerability and decrease the influence on target organs such as: the heart, nervous system, kidney, the blood proteins and enzyme systems (fibrinolysis, completion, coagulation, blood cells, leukocytes, RBC, platelets).
Nonionic contrast substances can be used in the radio diagnosis of different disorders, both in human and veterinary medicine. The purpose of this paper is to introduce nonionic contrast substances of human use to veterinary medicine, as a working material in order to obtain high quality myelographies in dogs and to follow up on the alterations induced by these on the cerebral spinal fluid (CSF) and on the blood.

METHOD AND MATERIAL

Research to exploit the subarachnoid space with non ionic contrast substances, Optiray 350 and Ultravist 370 were performed on a number of 10 dogs of different breeds, sex and ages.
The materials necessary to perform a myelography were represented by Acepromazine, ketamine, sterile syringes and needles, alcohol, scissors, tampons, contrast substances (Optiray 350, Ultravist 370), radiographic film, fixing and revelation substances.
All research has been conducted in the Radiology laboratory of the Veterinary Medicine Faculty of Cluj-Napoca. The doses we used differ according to the administration site. Therefore, to inject the substance in the cervical area, the substance dose might reach up to la 0,45 ml/kg for Optiray 350, respectively 0,5 ml/kg for Ultravist 370, and for the administration of the substance in the lumbar area, the established dose was of 0,2 – 0,4 ml/kg for Optiray 350 and ranging between 0,3-0,5 ml/kg for Ultravist 370, in dogs.

The machines used, as well as the investigation methods of the hematological elements, the biochemical blood components and the ones of the CSF were the following:

- **For hematological testing** we used a veterinary automatic hematology analyzer by Diatron LTD, USA. The hematology analyzer is a completely automatic machine for the measurement of cells, for in vitro diagnosis. The principles for measurement were: *impedance method (Coulter method)*, which counts and classifies cells by detecting and measuring electrical impedance modifications when passing particles go through a conductor fluid through a very narrow slit. These impedance modifications are registered by two internal electrodes, which modify the electrical tension between these and then transforms it into electrical impulses. The number of impulses is proportionate to the particle number. The impulses are counted, with values for: WBC (white blood cells), RBC (red blood cells), PLT (platelets), as histograms ; *cyanmethemoglobin* to measure HGB (hemoglobin) –dilutions of 1 :196 are used. The reactive used destroys the red cell and releasing hemoglobin. Iron from hemoglobin is transformed from (Fe^{2+}) to (Fe^{3+}), a state where methemoglobin is formed, which combines itself with cyanide potassium (KCN), and produces stable cyanmethemoglobin or hematoglobin cyanide, after which HGB concentration is measured by the fotometric method. This method is used to determine HGB concentration.
- **For biochemical testing** we used a veterinary automatic biochemistry analyzer by Awareness Technology, USA, destined to the preparing, reading and interpreting biochemical analysis results. Reading of the samples is performed by a bicromatic optic system, with 6 filters. It contains preprogrammed calculations for fotometric determinations that have an ending point and are kinetic. Depending on the analyzed biochemical parameters, different reactive substances are used.

From a total of 10 dogs, on 5 dogs we tested the effect of Optiray 350, and on the remaining 5 we tested the effects of Ultravist 370. The quantity of CSF we harvested from the dogs varies between 1-5 ml, depending on the animal's size, the harvesting of fluid was performed both before the administration of Optiray 350 and Ultravist 370 and after 1 hour from contrast substance administration. The harvested CSF was hematologically and biochemically tested, by determining 6 parameters.
The harvesting is performed on a tranquilized animal, by fixating the animal's head, the punction site being one finger away from the occipital protuberance, in the depression that is formed, after mobilizing the head.

To evidentiate the modifications in the vascular bead after Optiray 350 myelography and Ultravist 370 myelography, blood was drawn in 6 hours from administration and in 24 hours. Blood was tested both physically and biochemically, determining 16 parameters.

RESULTS AND DISCUSSIONS

Table 1 – Number of cellular elements of the CSF after one hour after Optiray 350 myelography

NUMBER OF CELL ELEMENTS	RESULT	LIMITS
Case 1		
WBC (X 10 mil./L)	1.6	**≤3**
RBC (X 10 mil./L)	1.82	**≤30**
Case 2		
WBC (X 10 mil./L)	1,7	**≤3**
RBC (X 10 mil./L)	**1,2**	**≤30**
Case 3		
WBC (X 10 mil./L)	1,5	**≤3**
RBC (X 10 mil./L)	1,9	**≤30**
Case 4 –Wobbler Syndrome		
WBC (X 10 mil./L)	2,2	**≤3**
RBC (X 10 mil./L)	1,7	**≤30**
Case 5 – Intervetrebral disk hernia		
WBC (X 10 mil./L)	2,9	**≤3**
RBC (X 10 mil./L)	**10,2**	**≤30**

Table 2 – Number of cell elements of the CSF one hour after Ultravist 370 myelography

NUMBER OF CELL ELEMENTS	RESULT	LIMITS
Case 1		
WBC (X 10 mil./L)	2,0	**≤3**
RBC (X 10 mil./L)	1,82	**≤30**
Case 2		
WBC (X 10 mil./L)	1,8	**≤3**
RBC (X 10 mil./L)	1,3	**≤30**
Case 3		
WBC (X 10 mil./L)	1,9	**≤3**
RBC (X 10 mil./L)	1,7	**≤30**
Case 4 –Wobbler Syndrome		
WBC (X 10 mil./L)	2,4	**≤3**
RBC (X 10 mil./L)	1,82	**≤30**
Case 5 – Intervetrebral disk hernia		
WBC (X 10 mil./L)	2,91	**≤3**
RBC (X 10 mil./L)	**9,2**	**≤30**

The clinical examination of the spine was performed by the aid of the great semiological methods (inspection, palpation, percussion), completed by a radiology examination.

The normal character of CSF was the one of a transparent, non colored, non coagulating liquid. In certain situations, the harvested samples were contaminated by a small quantity of blood, resulted from the punction technique. In these situation we recommend performing trhe punction again since the results are altered.

The method has counted cells in the CSF and performed a biochemical exam, on 6 parameters. The results obtained in an hour from non ionic contrast substance, both in the healthy and in the cases that were diagnosed with different spine conditions can be found in table 1 (Optiray 350) and table 2 (Ultavist 370)

Cytology of the CSF performed after myelography in Wobbler syndrome and intervetrebral disk hernia diagnosed patients evidentiates neutrophilia and lymphocytosis (Graphic 1 and 2).

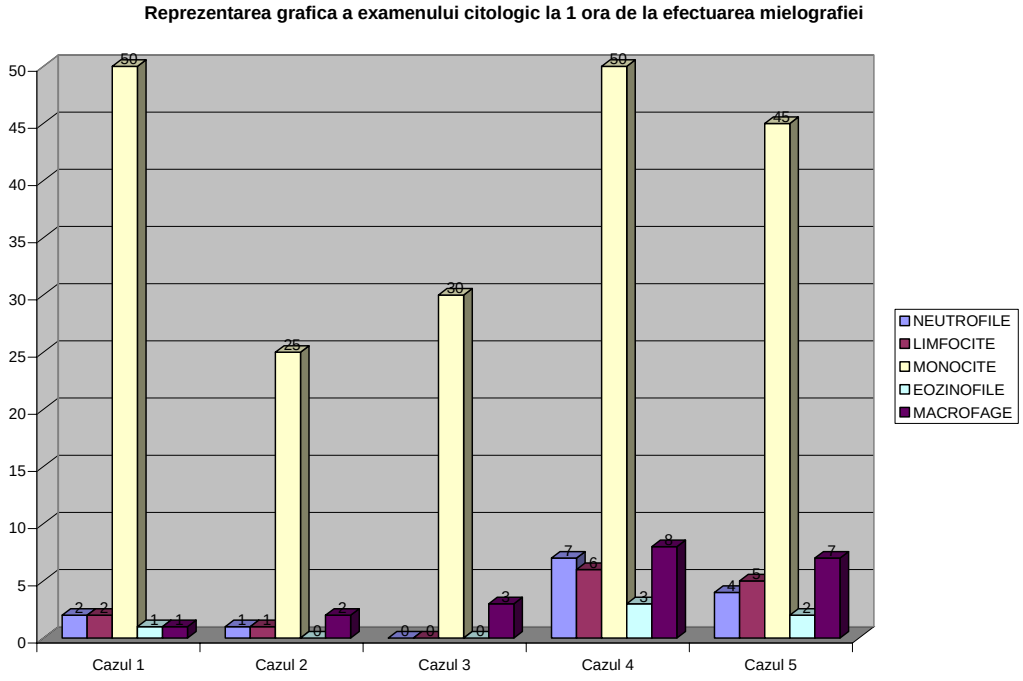

Graphic 1- Graphic representation of CSF cytology exam in 1 hour from the Optiray 350 myelography

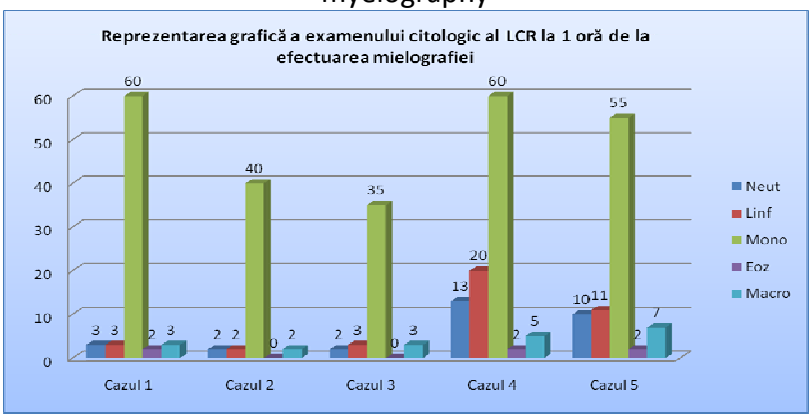

Graphic 2 –Graphic representation of CSF cytology exam in 1 hour from the Ultravist 370 myelograpy

After the biochemical testing of CSF after 1 hour, we can notice a decrease in calcium and an increase in albumins, in both types of administered substances, which shows that there is a decreased hepatic synthesis and a hyper hydration state, possibly as a consequence of iv drips (Graphic 3).

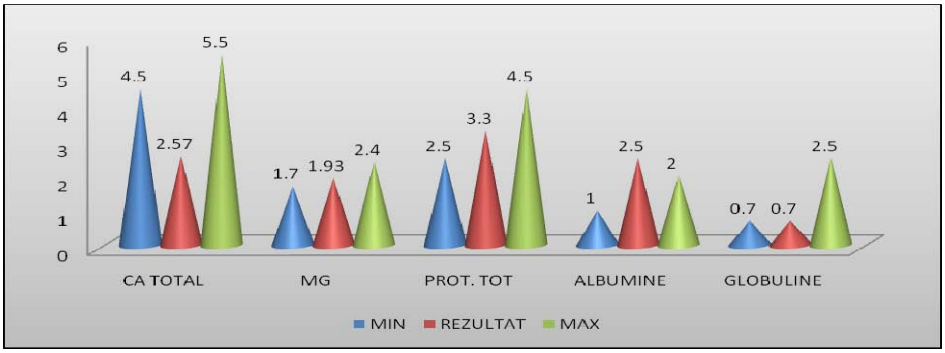

Graphic 3 - Graphic representation of the biochemical CSF parameters in Wobbler syndrome diagnosed dog, after Optiray 350 myelography

Laboratory investigations of blood and serum, harvested in 6 and 24 hours after the performing of the myelography, allowed us to evidentiate the influence of contrast substance on the followed parameters (Graphic 4).

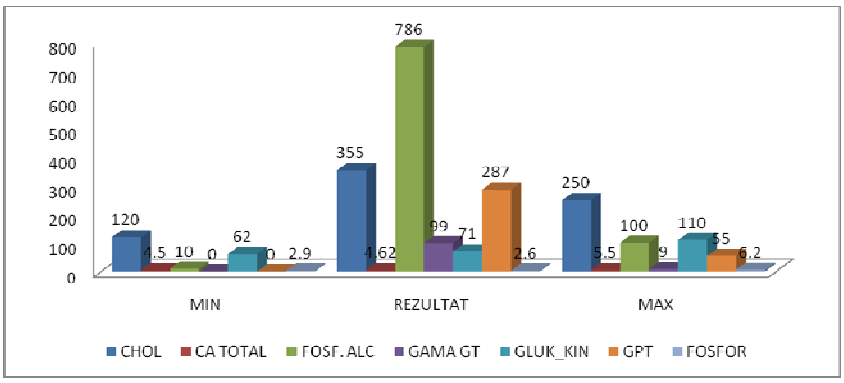

Graphic 4 – Monitoring of the biochemical parameters in blood serum in 6 hours from Optiray 350 administration, in dogs with Wobbler syndrome

The biochemical exam of blood serum performed after 6 hours of the contrast substance administration shows that in the case of Wobbler syndrome, there is a slight liver intolerance, which might indicate to a possible intra and extra hepatic billiary duct obstruction (Graphic 5).

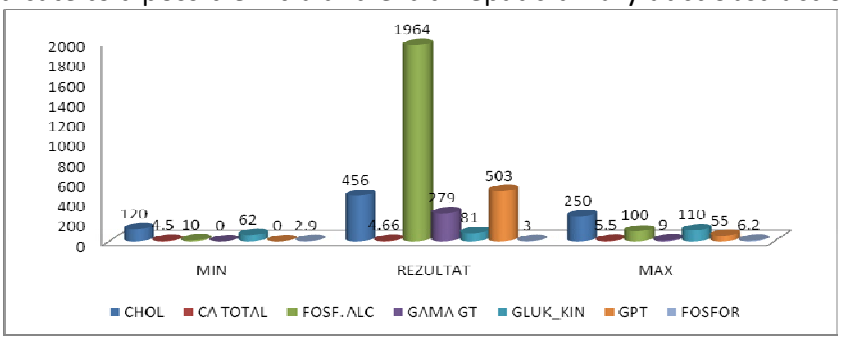

Graphic 5 - Monitoring of the biochemical parameters in blood serum in 6 hours from Ultravist 370 administration, in dogs with Wobbler syndrome

The biochemical examination of the blood serum after Ultravist 370 myelographies in dogs with a la Wobbler syndrome shows an intensified hepatic cellular suffering compared to Optiray 350 (Graphic 6).

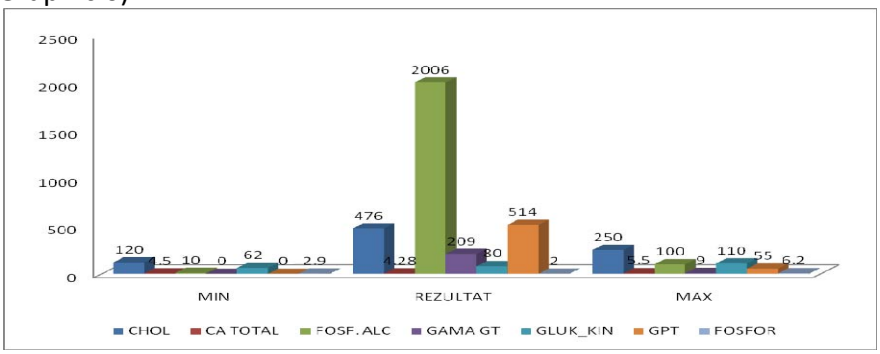

Graphic 6 Monitoring of the biochemical parameters in blood serum in 24 hours from Optiray 350 administration, in dogs with Wobbler syndrome

In 24 hours from Optiray 350 and Ultravist 370 administration, in the Wobbler syndrome diagnosed dog, PAL and cholesterol remain high, while the other parameters seem to come to normal. (Graphic 7).

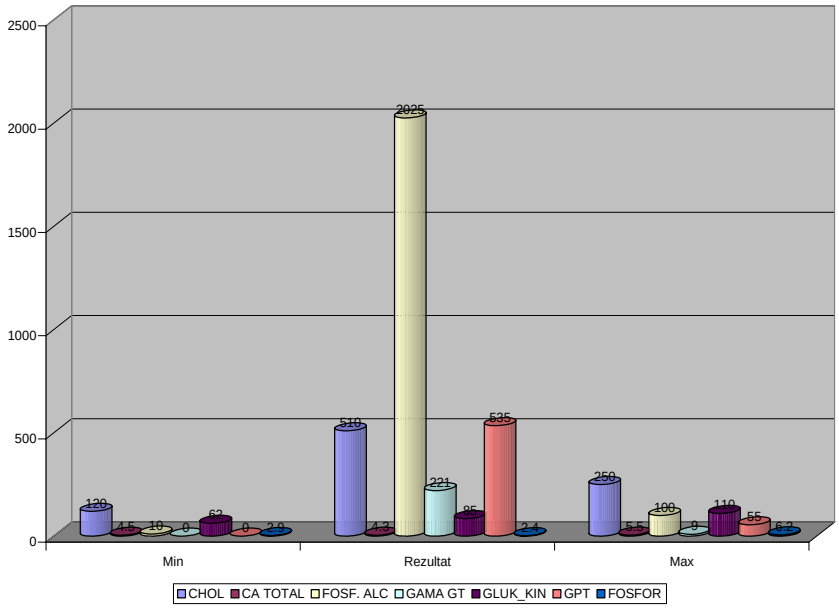

Graphic 7 - Monitoring of the biochemical parameters in blood serum in 24 hours from Ultravist 370 administration, in dogs with Wobbler syndrome

The biochemical examination of blood serum performed after Optiray 350 and Ultravist 370 myelographies in dogs show that there is hepatic sensitivity and hyper hydration due to iv dripping and/or possible cardiac conditions that were not diagnosed yet clinically (Table 3, 4).
Administering the contrast substance to obtain myelographies influences the hematological values, leading to a decrease in RBC numbers, HGB, Ht and PLT's. In 24 hours from the Optiray 350 and Ultravist 370 myelographies, we can observe a decrease of potassemia, an increase in urea and creatinine, an intensification of catabolic processes in the organism (fever, trauma), decreased glomerular filtration, but with a slow recovery to the initial state. The hematological

parameters taken after 24 hours after performing the myelography will evidentiate slight improvement in the hematological parameters with tendency of coming back to normal. (Table 5, 6).

Table 3 – Monitoring of the biochemical parameters in blood serum in 6 hours from Optiray 350 myelography, (average parameter value)

Test	Result	Unit	Min	Max	Observations
Cholesterol	270	mg/dl	120	250	Raised
Triglycerides	85	mg/dl	10	150	
total Ca	4,60	mg/dl	4,5	10	
Mg	1,70	mg/dl	1,5	4	
ALP	500	U/l	10	100	Raised
Gamma GT	100	U/l	0	9	Raised
Urea	23,8	mg/dl	10	30	
Gluc Kin	81	mg/dl	62	110	
Creatinine	0,55	mg/dl	0,5	1,3	
ALAT	80	U/l	10	50	Raised
ASAT	279	U/l	0	55	Raised
ISE – Na	153	mg/dl	140	155	
ISE – K	8,98	mg/dl	3,5	5,5	Raised
Total protein	5,7	g/dl	6,0	8,0	
Amylase EP	594	U/l	260	1500	
Total Bilirubin	0,28	mg/dl	0	1,00	

Table 4 – Monitoring of the biochemical parameters in blood serum in 6 hours from Ultravist 370 myelography, (average parameter value)

Test	Result	Unit	Min	Max	Observations
Cholesterol	285	mg/dl	120	250	Raised
Triglycerides	86	mg/dl	10	150	
total Ca	4.60	mg/dl	4.5	10	
Mg	1.70	mg/dl	1.5	4	
ALP	514	U/l	10	100	Raised
Gamma GT	125	U/l	0	9	Raised
Urea	23.8	mg/dl	10	30	
Gluc Kin	82	mg/dl	62	110	
Creatinine	0.54	mg/dl	0.5	1.3	
ALAT	89	U/l	10	50	Raised
ASAT	290	U/l	0	55	Raised
ISE – Na	155	mg/dl	140	155	
ISE – K	9	mg/dl	3.5	5.5	Raised
Total protein	5.8	g/dl	6.0	8.0	
Amylase EP	600	U/l	260	1500	
Total Bilirubin	0.30	mg/dl	0	1.00	

Table 5 - Monitoring of the biochemical parameters in blood serum in 24 hours from Optiray 350 myelography

Test	Result	Unit	Min	Max	Observations
Cholesterol	269	mg/dl	120	250	Raised
Triglycerides	119	mg/dl	10	150	
total Ca	4,6	mg/dl	4,5	10	
Mg	1,84	mg/dl	1,5	4	
ALP	520	U/l	10	100	Raised
Gamma GT	98	U/l	0	9	Raised
Urea	50	mg/dl	10	30	Raised
Creatinine	2,1	mg/dl	0,5	1,3	Raised
ALAT	78	U/l	10	50	Raised
ASAT	189	U/l	0	55	Raised
ISE – Na	140	mg/dl	140	155	
ISE – K	7,05	mg/dl	3,5	5,5	Raised
Total protein	6,7	g/dl	6,0	8,0	
Amylase EP	703	U/l	260	1500	
Bilirina Tot.	0,38	mg/dl	0	1,00	

Table 6 – Monitoring of the biochemical parameters in blood serum in 24 hours from Ultravist 370 myelography

Test	Result	Unit	Min	Max	Observations
Cholesterol	270	mg/dl	120	250	Raised
Triglycerides	118	mg/dl	10	150	
total Ca	4.9	mg/dl	4.5	10	
Mg	1.90	mg/dl	1.5	4	
ALP	589	U/l	10	100	Raised
Gamma GT	108	U/l	0	9	Raised
Urea	59	mg/dl	10	30	Raised
Creatinine	2.2	mg/dl	0.5	1.3	Raised
ALAT	87	U/l	10	50	Raised
ASAT	199	U/l	0	55	Raised
ISE – Na	145	mg/dl	140	155	
ISE – K	7.38	mg/dl	3.5	5.5	Raised
Total protein	6.9	g/dl	6.0	8,0	
Amylase EP	687	U/l	260	1500	
Total Bilirubin	0.50	mg/dl	0	1.00	

CONCLUSIONS

1. Using non ionic contrast substances (Optiray 350 and Ultravist 370) in dog myelography will offer a good quality radiological image, and the alterations induced in CSF and blood are minimal, and are not putting the animal's life in danger, in the doses we have used in this study.
2. Biochemical examination of CSF and hematological and biochemical examination of blood after an hour from performing the Optiray 350 and Ultravist 370 myelography in healthy dogs shows minimal alterations compared to the physiological values. In dogs that were diagnosed with Wobblers, low Ca and high albumin is evidentiated, but this could be due to low hepatic synthesis.
3. CSF cytology in Wobbler syndrome diagnosed dogs evidentiate neutrophilia and lymphocytosis.
4. Biochemical and hematological examination of blood in Wobbler syndrome affected dogs in 6 hours after Optiray 350 şi Ultravist 370 administration might point to hepatic lesions accompanied by eosinophilia and limphocytosis.
5. Interpreting the hematological and biochemical results in the blood after 6 hours from Ultravist 370 administration in dogs with Wobblers or other CNS disorders show that there is a more accentuated hepatic suffering when it comes to Optiray 350. Hepatic lesions are accompanied by isocromal anemia, lymphopenia and eosinophilia.
6. Biochemical examination after 24 hours from the Optiray 350 and Ultravist 370myelographies in Wobblers diagnosed dogs indicate high values of the studied parameters (ALAT, ASAT, PAL, urea, creatinine), which leads to the assumption that there might be severe hepatic disorder and/or low glomerular filtration.
7. Optiray 350 and Ultravist 370 myelography in dogs with severe spine disorders influence the biochemical and hematological status of the blood in a negative way, protection methods being therefore necessary.
8. Administering Optiray 350 and Ultravist 370 in dogs will lead to a light hepatic sensitivity, but normal values in blood parameters will reappear in 24 – 48 hours.
9. CSF values in Optiray 350 and Ultravist 370 myelographies, return to normal in 24 hours.

BIBLIOGRAFIE

1. Adameşteau, I., Nicolau, A., Bârză, H., 1966, *Semiologie, patologie şi clinică medicală veterinară*, vol. I, Ed. Didactică şi pedagogică, Bucureşti, pag. 469-530.
2. Escriou, C., 2005¸*Semiologie Neurologique,* Ed. Ecole Nationale Veterinaire de Lyon.
3. Ghergariu, S., 1995, *Bazele patologiei medicale a animelelor*, vol. II, Ed. All, Bucureşi. pag. 113-124.
4. Katzberg R. (1998) – The contrast media manual Baltimore: William & Wilkins.
5. Kealy I.K., H. McAllister (2000) – Diagnostic Radiology and Ultrasonagraphy of the dog and cat, 3-rd edition, W.B. Sannders.
6. Papuc I**,** Lăcătuş R, Stan F., Purdoiu R.C., Ana-Monica Timen, 2009, *Semiologie, imagistică medicală şi laborator clinic veterinar,* Ed. Accent, Cluj Napoca, pag. 459-491.
7. Petrovan I., D.Ş. Antone, H. Varlan (1996) – Neuroanatomie clinică, ed. Edit-Dan, Cluj Napoca
8. Suckas J. (1993) – Radiographic Contrast Agents (Agenţi de contrast în radiografie), Rockville, MD: Aspen Publishing CO.

*** Fiche de consultation neurologique, 2005, Ecole Nationale Veterinaire de Lyon.

CLINICAL AND PARACLINICAL DIAGNOSIS IN SPINAL CHORD CONDITIONS IN DOGS

I. PAPUC, R. LĂCĂTUŞ, C. MUREŞAN, Alexandra Nicoleta PĂVĂLOIU, R. C. PURDOIU

University of Agricultural Sciences and Veterinary medicine Cluj Napoca,
Facultaty of Veterinary Medicine,
Calea Mănăştur, Nr. 3-5, Cluj Napoca, jud. Cluj, Romania
papuc_i@yahoo.com

ABSTRACT

Establishing the clinical diagnosis of a canine neurological disorder of the spinal chord requires the steps of the examination and their order to be well known and applied accordingly. The neurological examination of the spinal chord must be organized in such a way to provide sufficient data on the identity of the patient, on the onset and evolution of the disease and on the status of the patient's nervous system, as revealed by the functional and physical exams. Complementary exams such radiological examination, myelography, will confirm to the clinician the etiology of the lesion. The purpose of this study was to select the most relevant neurological tests and special test used in the diagnosis of the spinal chord disorders, and to adapt them to the canine species. As working method, we have performed a radiological examination, a contrast substance examination and three categories of neurological tests: postural reactions, medullar reflexes and superficial sensitivity. The clinical examination, combined with the results of the special tests and the medical imaging results applied to a patient provides an accurate neurological diagnosis.

Key words: the spinal chord examination, postural reaction, superficial sensibility, medical imaging.

Acknowledgements: This work was supported by CNCSIS-UEFISCSU, project number PNII-IDEI 847/2007.

INTRODUCTION

The establishment of a clinical diagnosis when it comes to the spinal chord represents a very difficult process because of the ambiguity and complexity of the symptoms, physiopathological mechanisms involved and etiology diversity [1, 5]. To establish a clinical diagnosis of spinal chord conditions in dogs, it is necessary that the stages of the consultation need to be established beforehand and applied in a logical order. A correct consultation of the spinal chord assumes that one will go through the following examination stages: *taking the anamnesis,* which will focus on the symptom's apparition and evolution, *the evaluation of the animal's consciousness, evaluation of behavior, evaluation of the animal's postures,* if possible *gait and abnormal movement examination,* and finally evaluation of the postural reactions [2, 3, 4].The animal's identification data limits the main categories of possible spinal chord conditions, as in younger animals are susceptible to congenital, inflammatory or infectious nervous disorder, whereas an older animal might possibly rather suffer from degenerative,

tumoral or inflammatory pathology [6]. The way the disease installs itself and its temporal evolution are clues for the clinician to orientate the diagnosis towards the disease's etiology. In *vascular conditions*, clinical signs appear suddenly*; in metabolic conditions,* manifestations get progressively worse; in *inflammatory conditions,* the clinical signs appear over days or even weeks; *and in neoplasias or degenerative conditions,* the evolution of the disease is much slower and the clinical signs can intensify very fast [4, 6, 8].
Based on the clinical exam, one will initiate other complementary exams that will orientate the diagnosis towards the disease's etiology. As **complementary exams in the diagnosis of spinal chord conditions,** the most frequently used are the following: *examination of the cerebro-spinal fluid, blood testing (*biochemistry or serology), *simple radiography, myelography, tomodensimetry, tomography, electromyography, histological analysis, medullar ultrasound, magnetic resonance imaging and medullar scintigraphy* [4, 7, 9].

MATERIAL AND METHOD

The biological material was represented by 10 dogs of different breeds, sex and ages.
Working instruments: plessimetryic hammer, haemostatic clamp, cotton, lantern, alcohol, nonionic contrast substances, Roentgen machine.
Work method. All research has been conducted in the Radiology laboratory and in the Emergency Hospital of the Veterinary Medicine Faculty of Cluj-Napoca.
The researched dogs were examined by the great semiological methods, completed by special testing for neurological disorders, represented by three testing categories: *postural reactions* (8 tests); *medullar reflexes* (8 tests) and *sensibility evaluation* (2 tests).
The animals taken into study were subjected to radiography with no contrast substance of the spinal chord, to evidentiate possible conditions that are localized at this level. To exploit the subarachnoidal space we have used nonionic Optiray 350 contrast medium.
When it comes to the administration site of the nonionic contrast medium, myelographies classify themselves in two categories:

a) Myelographies that can be performed by cervical puncture and by inducing the substance into the cervical area of the spinal canal, hence the curved position of the dog's head and the needle is slowly inserted into the occipital-atlas or atlas-axis space with its forefront in the direction of the dog's nose;
b) Myelographies performed through lumbar puncture and introduction of the non ionic contrast substance in the lumbar part of the spinal channel;

The chosen location for the puncture (cervical and lumbar area) was treated according to the asepsis and antisepsis standards (shaving, washing, grooming). Patients were given a dose of 1 % Atropine 0,02 ml/kg after administrating Acepromazine associated with Ketamine (10 mg/kg) to obtain neoroleptanalgesia. The spinal needles we used in the procedure were of 22 – 20 G with a stylet for minimizing perimedullar tissue damage. Other needles used in the procedure had the length of 70-100 mm with a diameter of 0.7 mm and a short bevel. The animals that took part in the procedure where kept under observation for 48 hours in order to prevent and possibly treat any side effects.

RESULTS AND DISCUSSIONS

The clinical examination of the spinal chord was performed according to the great semiological methods (inspection, palpation, percussion), being completed by special neurological testing.

Each neurological test has evidentiated the following aspects: the elements assessed during the test, normal test response and abnormal test response.

POSTURAL REACTIONS

Proprioception testing

Realization method: The animal is lifted in a way that it has no support on the floor except for the tested limb and it is then so inclined, that its body weight will oscillate laterally.

Tested elements: conscious proprioception, superficial tactile sense, pressure and space position perception .

Normal response: The animal redresses its limb in a physiological position immediately.

Abnormal response: The animal does not react or even places its weight on the abnormally positioned limb.

Cartwheel test

Realization method: One lifts the backside of the animal in a moderate way, so that the whole body weight will be supported by the anterior limbs; one will encourage the walk to step forward or laterally.

Tested elements: the integrity of the spinal chord in the anterior C_3–C_7 section.

Normal response: in both situations, the animal moves in the directions requested with well-coordinated movement.

Abnormal response: the movements are initiated with a delay and are asymmetrical due to more support on one of the limbs, dysmetria.

Jumping test

Realization method: the animal will be lifted so that there is no support on the ground except for the tested limb, and it is then inclined so that its body weight will oscillate laterally.

Tested elements: sensitive and motor pathways implicated in limb movement, vestibular system, cortical and sub cortical control.

Normal response: active jumping movement with the limb that supports the weight in the direction it is pushed.

Abnormal response: the animal does not coordinate the limb or cannot support it.

Tonic postural reaction

Realization method: the animal is first raised and then let down until the posterior limbs take up contact with the floor.

Tested elements: the integrity of the vestibular system.

Normal response: by anticipating ground contact, the animal extends its limbs, during contact, the hind limbs move caudally through a symmetrical movement to support the body.

Abnormal response: movement symmetry, lack of gait coordination or dysmetria.

Hemistation and hemilocomotion

Realization method: the front and hind limb of the same side are lifted and then the animal will be pursued in forward or laterally.

Tested elements: the existence of encephalic lesions counter laterally to the tested side.

Normal response: the animal can support its own weight and walks in the requested direction.

Abnormal response: lack of weight bearing or movement coordination disorders.

Tactile perception (Fig.2)

Realization method: The animal is supported by the examiner at thorax level and its eyes are shielded; then the animal is taken near a table so that the dorsal side of the carpal region and respectively tarsal region will come into contact with the side of the table.

Tested elements: the integrity of tactile receptors, the sensitive pathways from the spinal chord through the cortex, and also the motor pathways.
Normal response: During contact with the side of the table, the animal will lift its front, respectively hind limb and supports it in a normal position on the surface of a table.
Abnormal response: deficit in correcting the limbs position by abnormally supporting it

Cervical tonus

Tested elements: the integrity of the sensorial and motor system as well as of cortical and sub cortical control of movement.
Normal response: the animal allows movement, when the neck is extended, it will extend the front limbs and will lightly flex the hind limbs; when the head is moved laterally, a slight extension of the front limb and a light flexion of the hind limb will occur.
Abnormal response: exaggerated reactions in cerebellum lesions, abnormal movement if proprioception is lacking or there are any lesions of the ventral motor cervical horns.

MEDULLAR REFLEXES

Patella reflex

Realization method: the animal is placed lying down laterally; the median patella ligament is hit lightly with a reflex hammer.
Tested elements: femoral nerve and medullar L_4-L_6 area.
Normal response: limb extension as a consequence of the quadriceps muscle contraction..
Abnormal response: lack, diminishment or exaggeration of this movement.

Cranial tibial muscle reflex (Fig. 3)

Realization method: the animal lies down laterally; the examiner hits the cranial tibial muscle lightly in the proximal area of the tibia.
Tested elements: the fibular branch of the sciatic nerve and the medullar L_6-L_7 segments.
Normal response: flexing of the hock.
Abnormal response: lack, diminishment or exaggeration of this movement.

Super carpal reflex

Realization method: the animal lies down laterally, the examiner percutes the extensor carpal-radial tendon.
Tested elements: the carpal nerve and the medullar C_7-T_1 region.
Normal response: extension of the radial-carpal-metacarpal articulation.
Abnormal response: lack, diminishment or exaggeration of this movement.

Front limb flexing

Realization method: the animal lies down laterally; the limb is stimulated with an unpleasant but not painful stimulus.
Tested elements: medullar C_5-T_1 region
Normal response: flexing of the whole limb
Abnormal response: lack, diminishment or exaggeration of this movement.

Hind limb flexing

Tested elements: medullar L_4-S_1 region.
Normal response: flexing of the whole limb.
Abnormal response: lack, diminishment or exaggeration of this movement.

Crossed extension

Tested elements: the integrity of the superior inhibiting centers and of the descendant ipsilateral descending pathways.
Normal response: absence of an extension in the counter lateral limb of the one stimulated.

Abnormal response: together with the flexing of the stimulated limb, there is an extension in the counter lateral limb.

Perianal reflex

Tested elements: medullar S_1-$S_{2\,(3)}$ region and the pudendum nerve.

Normal response: anal external sphincter contraction and flexing of the tail.

Abnormal response: lack or diminishment of the contraction.

Interdigital (Babinski) reflex

Tested elements: cortical, lumbar medullar and ischial nerves integrity

Normal response: flexing of the digits eventually hock too.

Abnormal response: digit extension (hyper reflectivity), which shows that there might be cortical lesions or intracerebral compression syndrome.

SENSITIVITY EVALUATION

Pannicular reflex (Fig.4)

Realization method: the examiner stimulates the skin on each side of the medial backline by pinching with a clamp or light stinging with a needle.

Tested elements: the integrity of the spinal chord 1-2 vertebrae cranially tot the stimulated site

Normal response: light contraction of the skin in the stimulated area

Abnormal response: contraction absence

Pain sensitivity

Realization method: The animal will be lying down laterally and the dorsally placed posterior limb is stimulated by stinging a digit with a needle or clamping it lightly.

Tested elements: evaluation of the gravity of the medullar lesions that will lead to paralysis and paresis.

Normal response: beside of limb retraction, the animal will turn, vocalize or tries to bite.

Abnormal response: The animal will only respond to large pressure applied to the digits, or it is completely areactive.

Fig. 1 Dog with medullar compression symptoms

Fig.2 Tactile perception test

Fig.3 Cranial tibial muscle reflex

Fig.4 Pannicular reflex

Paraclinical examination is represented by the imagistic exam (radiographs and contrast medium myelographies) and has completed the data obtained by clinical examination, offering extra information in the establishment of a clinical diagnosis.

By conventional radiography, we were able to diagnose lesions caused by: spondylosis and deformed spondylosis (parrot beaks), vertebra fractures, discal-vertebral lesions (sprains and sub acute sprains, discal prolapses, discal atrophy and the ossification of the intervetrebral disc, spondyloarthrosis and Wobbler syndrome) (fig. 5,6,7,8,9).

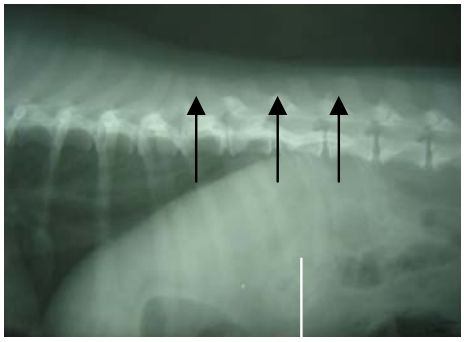

Fig. 5.– Intervertebral disc ossification at the level of $T_{10} – T_{11} – T_{12}$

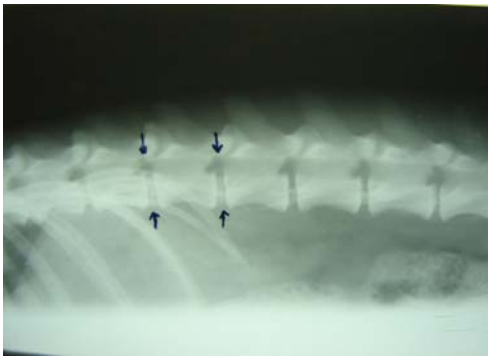

Fig. 6 – Lumbar discopathy. Tendence in hernia of the intervertebral disc

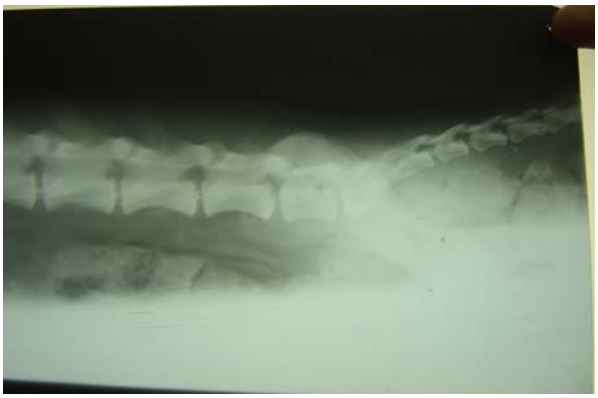

Fig. 7 – The compression of L_7 due to a fracture: the compression of the vertebral bone

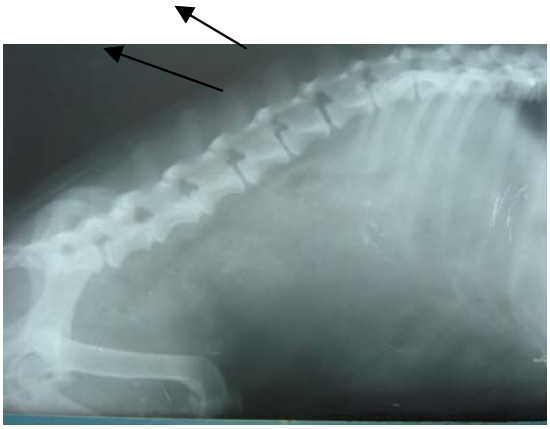

Fig. 8 – Lumbar discopathy $L_5 – L_6 – L_7$

Fig. 9 – Wobbler Syndrome in a dog

Cervical myelography. As puncture areas, we used an occipital-atlas puncture and an atlas-axis puncture. An equal amount of cerebrospinal fluid and contrast substance was injected through a plastic tube connected to the puncture needle.

The slowly injected dose (2-5 minutes according to body size of the animal) of contrast medium in the subarachnoidal space in the cervical region was of 0,2 – 0,45 ml/kg with radiographs taken in 2 – 10 – 20 – 40 minutes from administration of the dose (Fig. 10,11,12,13).

In the aftermath of the procedure, we extracted the needle slowly; local stasis was exerted for approximately one minute followed by a slight rotation from the right to the left with the purpose of facilitating the entrance of the substance in the spinal canal. The parameters were established according to the size of the animal: 55-60 kV, 25-40 mAs.

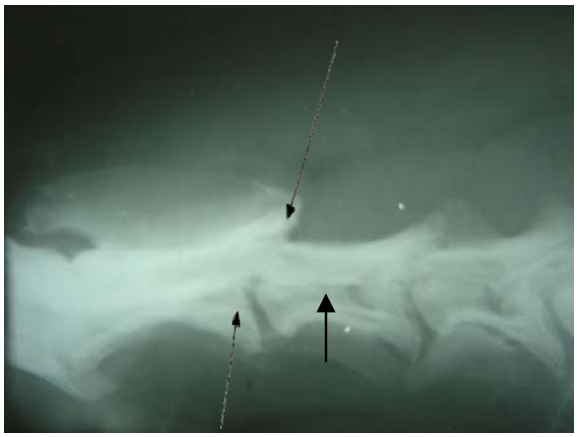

Fig. 10 The opacity of the spinal channel 2 minutes after administration of the contrast substance – the compression C2 – C3

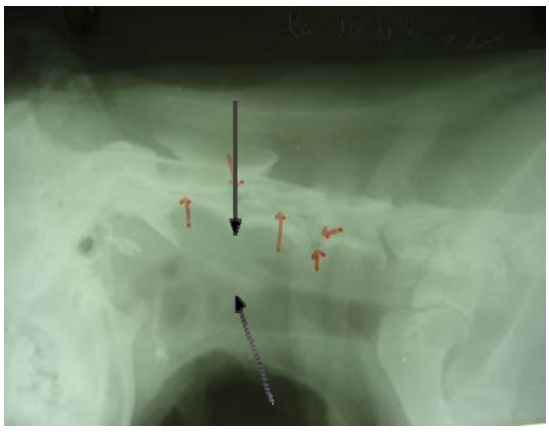

Fig. 11 Myelography with Opitray 300 10 minutes after administrating the substance – dog diagnosed with intervertebral disc hernia

Lumbar myelography In order to induce the substance in the lumbar area, we had to execute the puncture between the vertebrae L3 – L4 or L5 – L6. It is also possible to use the space between L6 – L7 for this procedure. The lumbar puncture is performed easily laterally to the dorsal apophysis tuberosity since it has a lateral-medial trajectory until touching the inner wall of the spinal canal.

Fig. 12 Myelography 20 minutes into administration of contrast medium

Fig. 13 Thoracic myelography 40 minutes into administration of contrast medium

The follow-up x-ray is needed to reassure the examiner of the fact that the needle is being inserted in the spinal channel. The quantity of the contrast substance is of 0,2-0,5 ml/kg. We allowed 1 minute, 10 minutes and 30 minutes into the administrated dose for the radiological exposures (Fig. 14, 15). The parameters used during the procedures were established according to the size of the animal: 55-73 kV, respectively 25-40 mAs.

Fig. 14 Lumbar myelography 1 minute into induction of the contrast substance

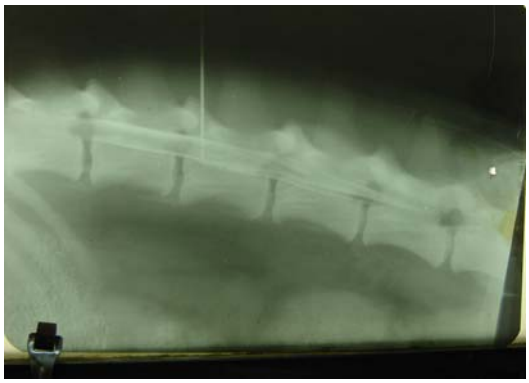

Fig. 15 Lumbar myelography 10 minutes into administration of the substance, with a defined image of the spinal canal

CONCLUSIONS

1. Usage of the great semiological methods and the special testing for neurological disorders allow the establishment of a clinical diagnosis of a lesion at the spinal chord lesion.
2. To exactly localize the lesion and pick an intervention method, the examiner will complete a clinical examination with paraclinical medical imaging methods.
3. An important role in establishing a spinal chord lesion diagnosis is reserved for the anamnesis.
4. Prior to the radiological examination, it is necessary to examine each segment of the spinal cord before administering any contrast medium since it can mask some of the lesions.
5. The procedure of injecting the substance should be slow, hence the necessary time span of up to 5 minutes.

6. Doses vary according to the site of substance administration. Therefore, in the cervical region, the dose can achieve the level of 0,45 ml/kg and for the injection in the lumbar area, the dose can be of 0,2 ml/kg.
7. Radiological exposures can be done with the purpose of following-up on the progress. In addition, after 1, 10, 15 and 30 minutes into substance induction, x-rays will show and underline the different spinal cord segments.
8. Exposure parameters were different, good images were obtained by using a frame of 50 – 60 Kv but also of 25 – 40 mAs, according to animal size.
9. The optimal area to induce the contrast substance Optiray 300 is the cervical area, the atlas-axis inter vertebral space. Upon administrating the substance, the animal is lifted so to help with the substance diffusion.
10. The usage of non-ionizing medium in order to visualize the spinal cord and spinal canal is indicated upon cervical inter vertebral discopathy, disc protrusion type I and II, lumbar inter vertebral discopathy, neoplasia, hematoma, intermedullar abscesses.
11. A slight tachycardia and tachypnea was observed upon administrating Optiray 300, a return to normal physiological parameters (temperature, pulse, respiration) has been observed in 12 hours after administration of the contrast substance.
12. The existence of a well structured working protocol will make the examiner's job easier by reducing time allocated to consultation and forgetting any stages of the examination.

BIBLIOGRAFIE

1. Adameşteau, I., Nicolau, A., Bârză, H., 1966, *Semiologie, patologie şi clinică medicală veterinară*, vol. I, Ed. Didactică şi pedagogică, Bucureşti, pag. 469-530.
2. Cauzinille, L., 2003, *Neurobiologie clinique du chien et duchat*, Ed. Point Veterinaire, Maisons-Alfort, pag 22-38.
3. Curtis, W. D., 2003, *Canine and Feline Neurology*, Ed. Iowa State Press, pag. 31-55.
4. Escriou, C., 2005¸*Semiologie Neurologique,* Ed. Ecole Nationale Veterinaire de Lyon.
5. Ghergariu, S., 1995, *Bazele patologiei medicale a animelelor*, vol. II, Ed. All, Bucureşi. pag. 113-124.
6. Lorenz, M. D., Kornegay, J. N., 2004, *Handbook of Veterinary Neurology*, ediția a IV-a, Ed. Saunders, Philadelphia, pag. 3-74.
7. Papuc I**,** Lăcătuş R, Stan F., Purdoiu R.C., Ana-Monica Timen, 2009, *Semiologie, imagistică medicală şi laborator clinic veterinar,* Ed. Accent, Cluj Napoca, pag. 459-491.
8. Wheeler, S. J., 1995, *Manual of Small Animal Neurology*, ediția a II-a, Ed. Iowa State Press, pag. 9-36.
9. Suckas J. (1993) – Radiographic Contrast Agents (Agenți de contrast în radiografie), Rockville, MD: Aspen Publishing CO.

*** Fiche de consultation neurologique, 2005, Ecole Nationale Veterinaire de Lyon.

ADVANCED BIOTECHNOLOGIES APPLIED IN CARNIVORE'S REPRODUCTION IN ORDER TO IMPROVE FERTILITY

C. PAVLI, Oana TANASE
Faculty of Veterinary Medicine Iassy
Pavmed –pavli_constantin@yahoo.com

ABSTRACT

Research activity on this topic had a start point in the demand of skills, on carnivore's reproduction. These biotechnologies besides conservation of genetic material and its transfer to great distances, offers good protection sexually transmitted infectious diseases. Used techniques provide an elaborated control over the feline reproductive process allowing successful mating, gestation and delivery. In this paper we intend to present ours trials in order to induce fertile heat in queen and successful ovulation, techniques monitored with ultrasound and hormonal asses.

Key words: vaginal cytology, induced ovulation, ovulation rate

MATERIAL AND METHOD

In order to induce a fertile oestrus we used two female groups, with 3 queens in each one, all queens were assessed for heat detection using vaginal cytology and ovarian ultrasonography.
The cats were housed in a controlled environment at 20^0C, with 10.5 hours of artificial light per day. The queens were caged in groups of three individuals. Room also housing male cats. Prior hormonal treatment each cat was observed for clinical expression of estrous cycle.
The determination of clinical estrus in each cat was based on behavioural changes observed during and immediately after each occasion of sampling. Behavioural estrus was measured by a subjective grading of 0 to 5. A score of 5 was used to indicate the most marked clinical estrus with fast rolling, tail deviation, elevation of hind quarters and treading. A score of 0 indicated no change in behaviour in the cat, and scores from I to 4 indicated increasing intensities of clinical estrus. Behavioural estrus scores were compared to the vaginal cytology obtained.
Each queen was assessed ulrasonographicaly daily with a 13 Mhz probe, Aloka prosound 2 ulrasonographic equipment. In order to synchronize all females for mating protocol, estrus was induces using hormonal treatment with PMSG, ovulation was induced using mechanical stimuli and hCG. Female cats were treated with pregnant mare's serum gonadotropin (PMSG, 150 IU) followed 72 or 80 h later with 100 or 250 IU human chorionic gonadotropin (hCG). For each queen the estrus was monitored by vaginal cytology, hormonal assay and ultrasonography. Natural mating was performed using a different tom cat for each queen; each male was assessed ultrasonographical for bulbouretral and testes structure.

RESULTS AND DISCUSSION

No study has reported the influence of the day of ovulation upon fertility. It is recognized that during the first two days of estrus ovulation may fail, but it is not known if the third, fourth or fifth day would be better. Induction of ovulation; Ovulation can be induced by two methods
- 100/250 UI of hCG

- Vaginal stimulation (5 stimulations with a sterile cotton swab at 30 min of interval are effectiveness). It has been supposed that stimulation by hCG could modify the endocrine environment which disrupts the oviductal embryo transport. Vaginal stimulation can be ineffective if the queen is stressed due to transportation or manipulation, and some breeders are reluctant to perform it themselves. We performed both methods simultaneously ovulation being surveyed ultrasonographicaly. Timing of insemination as a single mating can result in pregnancy; cat spermatozoa can be fertile at least 26-29 hours. We used natural mating five times for each cat. Vaginal smears from all cats were examined at two-day intervals for 32 days in order to describe the cyclical pattern of epithelial cells exfoliated throughout the stages of the estrus cycle. Vaginal epithelial cells were classified as parabasal, intermediate and superficial (nucleate and anucleate) cells, and their dimensions were measured for the purpose of definition. The percentages of the epithelial cell populations from Diff quick and MGG stained smears, were determined at all stages of the estrus cycle. Smears of cats in estrus were populated almost entirely with nucleate and anucleate superficial epithelial cells. Proestrus was characterized by intermediate epithelial cells with increasing eosinophilia, and rare neutrophils. Metestrus was associated with desquamation of intermediate and parabasal epithelial cells, neutrophils and debris. In the anestrus period, groups of intermediate cells and some parabasal epithelial cells were exfoliated. Two cats in the study did not cycle and exhibited ovarian cysts. The cycles were of 15 to 17 days interval in three normal cats.

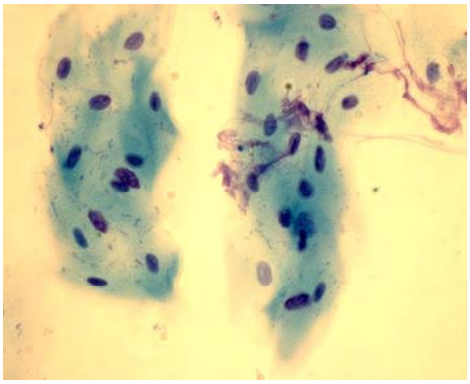

Figure 1 Parabasal cells prior PMSG administration

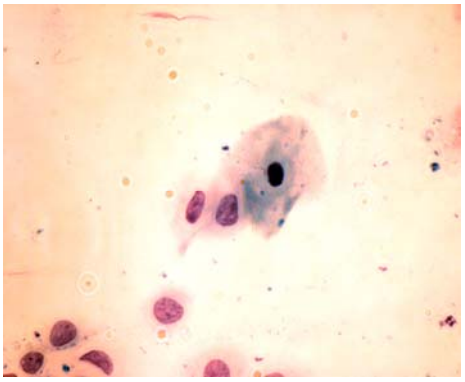

Figure 2Parabasal cells and an intermediate cell

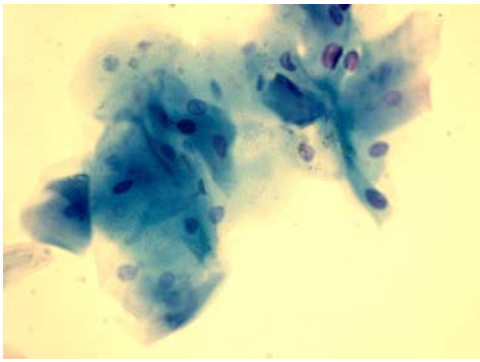

Figure 3 Nucleate superficial epithelial cells

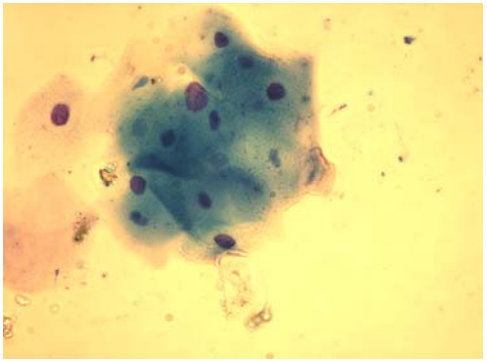

Figure 4 Nucleate superficial epithelial cells

Ultrasonographicaly exam was used for follicular dynamics surveillance; it was performed using a 13 Mhz probe for transcutaneously exam.

The structures measured were the uterus and ovaries in order to provide supplemental information on genital tract prior and after hormonal treatment. This kind of exam helped us to choose which queens are healthy and fit to experimental protocol.

In order to obtain information's about uterus, longitudinal and transversal sections were performed (figure 5, 6). All queens used presented normal characteristics of the genitals, some developed a specific pathology after hormonally induced poliovulation.

Endocrine environment is very sensitive so an induced pathology was observed: cystic ovaries, endometrial hyperplasia and embryo mortality. Fetal comfort degree was determinate using fetal hart rate (figure 14).

Figure 5 Uterus transversal section, normal size

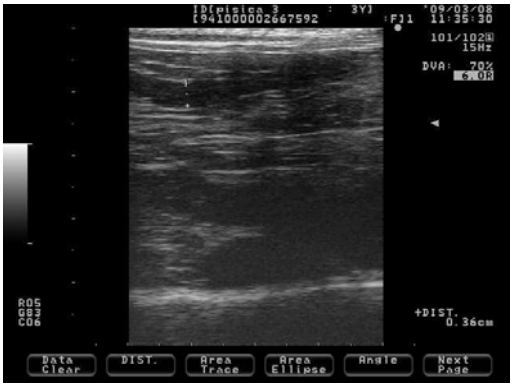

Figure 6 Uterus longitudinal section, normal view

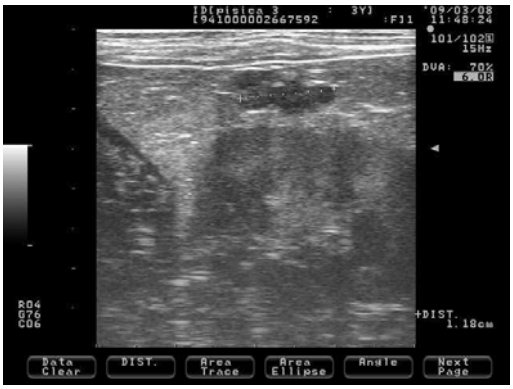

Figure 7 Poliovulation day 3 after PMSG

Figure 8 Poliovulation day 3 after PMSG

Figure 9 Poliovulation day 4 after PMSG

Figure 10 Endometrial hyperplasia

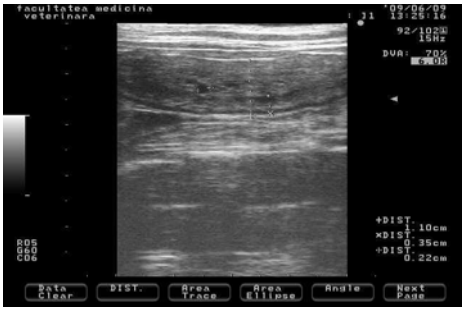

Figure 11 Endometrial cysts

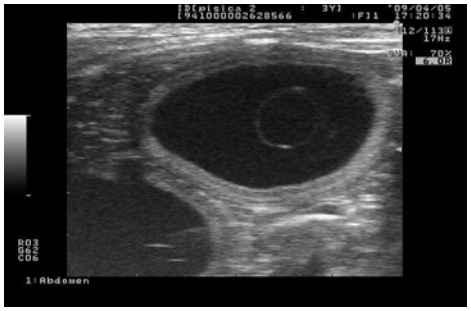

Figure 12 Embryo mortality

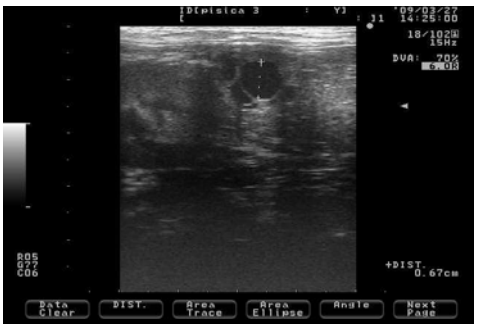

Figure 13 Cystic ovary

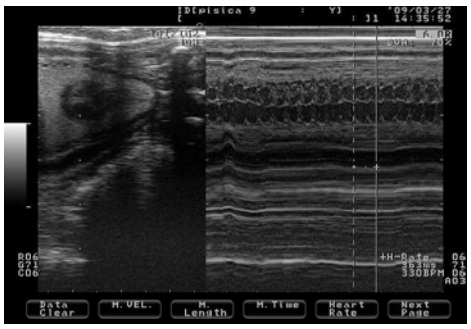

Figure 14 Fetal hart rate

CONCLUSIONS

1. These biotechnologies are viable and usefully for domestic and wild felids in a controlled reproduction program, despite the fact that hormonal treatment can induce an undesirable pathology.
2. Higher dosage of PMSG (150UI) leaded to ovarian, uterine pathology and is responsible for embryo mortality.
3. Vaginal cytology is a useful tool to assay ovarian cycle and combined with ultrasonography provides necessary information for mating or artificial insemination.
4. Neutrophil numbers and neutrophil inclusions in epithelial cells were not found to the same extent as in dogs in the early luteal phase, but the presence of neutrophils may be related to the hormone status and may be a difference between ovular and anovular estrus. Foam cells were occasionally seen in postestrus in this study. Feline vaginal cytology differs from the bitch in lacking erythrocytes, and it is interesting that the cats which did show erythrocytes in their vaginal smears also had bacterial growth on culture.

REFERENCES

1. Banks, D.R. (1986). Physiology and Endocrinology of the Feline Estrous Cycle. In Current Therapy in Theriogenology, Editor: D.A. Morrow. W.B. Saunders company (Philadelphia), 795-800.
2. Barnes, F.L. (2000). The effects of the early uterine environment on the subsequent development of embryo and fetus. Theriogenology, 53, 644-658.
3. Concannon, P.W. and Digregorio, G.B. (1986). Canine vaginal cytology. In Small animal reproduction and infertility. A clinical approach to diagnosios and treatment, Editor: T.J. Burke. Lea and Febiger (Philadelphia), 96-111.
4. Papanicolaou, G.N. (1942). A new procedure for staining vaginal smears. Science, 95, 438-439.

PROSTATE PATHOLOGY IN DOG, DIFFERENTIAL DIAGNOSTIC BETWEEN CYSTS, ABSCESS AND NEOPLASM

Constantin PAVLI, Oana TANASE
Faculty of Veterinary Medicine Iassy
pavli_constantin@yahoo.com

ABSTRACT

Considering the fact that all uncastrated male dogs suffer continuous prostate changes, we consider that is proper to present few diagnostic techniques required in preserving normal reproductive quality in ale dog. Genetic value in some individuals, make impossible castration as treatment, so non invasive treatment techniques need a proper diagnostic. The best diagnostic approach is represented by ultrasonography and cytology (fine needle aspirate). In the following paper we intend to describe cytological diagnostic in prostate pathology and therapeutically approach.

Key words: benign hyperplasia, fine needle aspirate, prostate cytology

INTRODUCTION

Considering the fact that prostate is the only accessory gland in dog its pathology demands a correct diagnostic, in order to perform the right therapeutically procedures, cytological and ultrasonographic exam are the most accessible ones. Staining procedures are largely available, so routine controls are easy to perform and can provide le answers needed.

MATERIAL AND METHOD

This paper is based on information harvested during prostate pathology treatment of a study group represented by ten dogs, different breeds, the common thing being the age and pathology. Four dogs presented an inflammatory pathology, distinction between non-inflammatory and inflammatory pathology was done using ultrasonography correlated with cytology. Tissue samples were collected using fine needle aspirate under ultrasonographic guidance, when necessary investigations were extended to testes considering that prostate pathology is generaly hormonal induced. Staining procedure is "Diff-Quick" a proprietory brand of a Romanowski stain. The Romanowski group of stains are defined as being the black precipitate formed from the addition of aqueous solutions of methylene blue and eosin, dissolved in methanol. The variants of the Romanowski group differ in the degree of oxidation (polychroming) of the methylene blue stain prior to the precipitation. From the point o view of the clinical examination all dogs presented bleeding during miction, bleeding localised to urethra, intraprostatic one (blood wasn't present in bladder – urine harvested using cystocentesis, provided uncontaminated urine).

RESULTS AND DISCUSSION

Prostatic diseases occur more frequently in dogs than cats or any other domestic species.This may relate to the continued expansion of the gland throughout life in the dog that enables development of prostatic hyperplasia in this species. Such disorders are more common in

older intact male dogs and include squamous metaplasia, hyperplasia, inflammation, neoplasia and cysts. The canine prostate gland is located predominantly in the retroperitoneal space, usually at the pelvic inlet within the pelvic canal, and completely encircles the urethra. The small feline prostate gland, however, is located more distal, does not entirely surround the urethra, and is rarely associated with clinical disease. This article is based on prostatic disease in dogs, and reviews the cytological and ultrasonographical conditions of the gland. Fine needle aspiration biopsy (FNAB), it is inexpensive, easy to perform the minimally invasive method feasible for a consciouss or slightly sedated patient (Anderson et al., 1994). Sample obtained by FNAB can be used for bacterial cultivation and/or for cytology. The method is useful in a wide range of patients with various prostatic disorders. It is on the borderline between invasive and non-invasive methods. Ultrasonography also enhances the effect of FNAB by better targeting the tissue in question. In case of acute inflammation, the use of FNAB is in question, since acute peritonitis as a consequence may develop. A very effective method to avoid this situation from developing is maintaining of continual negative pressure within syringe during the procedure.

Squamous metaplasia

Squamous metaplasia of prostatic epithelial cells results from excessive oestrogenic stimulation. The most common endogenous cause of this is a functional Sertoli cell tumour. Squamous metaplasia can lead to ductal obstruction and cyst or abscess formation. Oestrogens can produce prostatic atrophy due to testosterone inhibition, although mild prostatomegaly may result with chronic exposure. Secondary development of cysts or abscesses may further enlarge the gland. Sertoli cell tumour will produce a palpably abnormal testicle (figure 1) with atrophy of the contralateral testicle. Bilateral testicular atrophy occurs with exogenous hyperoestrogenism. Additional signs of hyperoestrogenism include alopecia, hyperpigmentation and gynaecomastia.

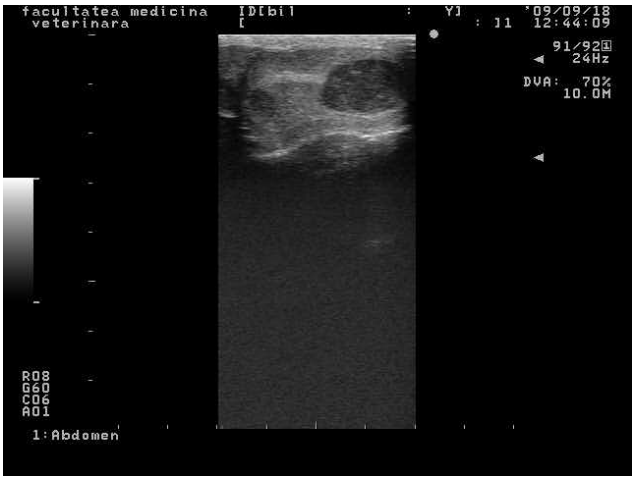

Figure 1 Testicular tumor (sertoli cell tumor)
15 years old Boxer

Figure 2 Testes longitudinal view, cysts, changed ecostructure 9 year old Collie

Figure 3 Prostate, right lobe, various size cysts 6 year old Doberman

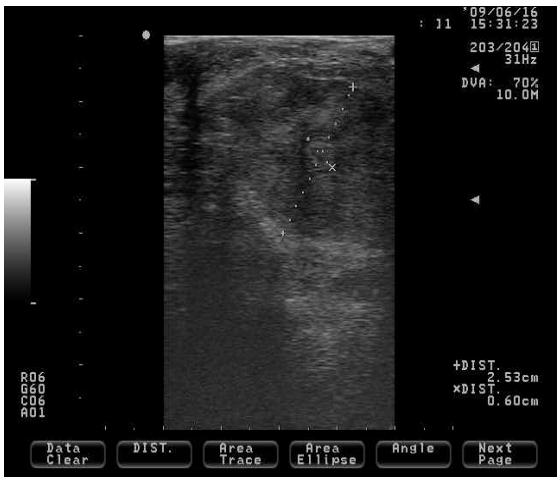

Figure 4 Prostate, transversal section, 8year old canche

This lesion is reversible and treatment involves removing the oestrogenic source,either by castration if Sertoli cell tumour is causative.

Benign prostatic hyperplasia

Benign Prostatic Hyperplasia (BPH) the most common canine prostatic disorder, is present either grossly or microscopically in almost 100% of sexually intact adult male dogs over the age of seven years, as well as in animals treated with androgenic hormones. It arises spontaneously in the gland as a consequence of ageing and endocrine influence, and may begin as early as 2-3 years of age, becoming cystic after 4 years of age. Dihydrotestosterone (DHT) is considered important in promoting hyperplasia predominantly of the glandular component, especially acinar basal cells. Testosterone produced by the testes is converted to DHT by 5-α reductase in prostatic epithelial cells, and DHT interacts with gland receptors to regulate prostate growth. Since BPH regresses following castration, androgens are also considered essential for its maintenance. Androgen action alone, however, cannot explain BPH, and oestradiol and various mitogenic growth factors are also implicated in its pathophysiology. On cytological examination, prostatic massage or ejaculate specimens may be haemorrhagic with mild inflammation without evidence of sepsis or neoplasia.
Prostatomegaly is evident on radiography, and ultrasonography demonstrates a normoechoic to slightly hyperechoic, symmetrically enlarged gland with a relatively smooth contour, with or without small fluid-filled cysts. A biopsy is required for definitive diagnosis. Two microscopic forms of BPH occur: Glandular hyperplasia mostly occurs in dogs below four years of age and is believed to progress to complex hyperplasia in older dogs, with increased stromal tissue and occasionally cystic change. Diagnosis, however, is usually based on physical examination if history and signs are suggestive, and cytological examination, culture and biopsy are rarely indicated.

Neoplasia

Of the domestic species, primary prostatic neoplasia occurs most frequently in dogs, with few cases reported in cats.Primary neoplasia is rare accounting for about 5% of all prostatic diseases. Prostatic adenocarcinoma is most common and considered to arise from ductal

epithelium, although others including transitional cell carcinoma, leiomyosarcoma, and haemangio-sarcoma have been reported. Ultrasonography will similarly demonstrate prostatomegaly with an irregular contour and hyperechoic parenchymal foci. Neoplastic epithelial cells may be seen cytologically on evaluation of urine or prostatic fluid.Although biopsy is required for definitive diagnosis (Fig. 4), studies suggest that many cases of neoplasia are missed with this procedure alone, and biopsy of the medial iliac lymph nodes and thoracic radiographs may also be advisable. Haemogram and serum biochemistry are usually normal.
Morphologic changes in the structure of cells, primarily the nuclei, are characteristic features of cancer cells (figure 6).

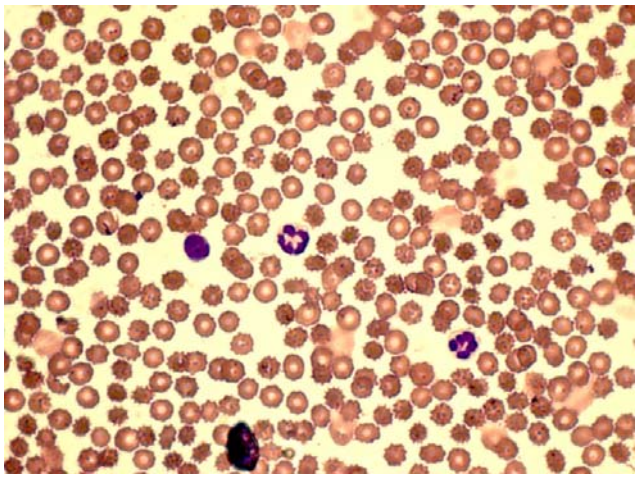

Figure 5 Fine needle aspirate, prostate cyst, neoplasm
6 years old Doberman

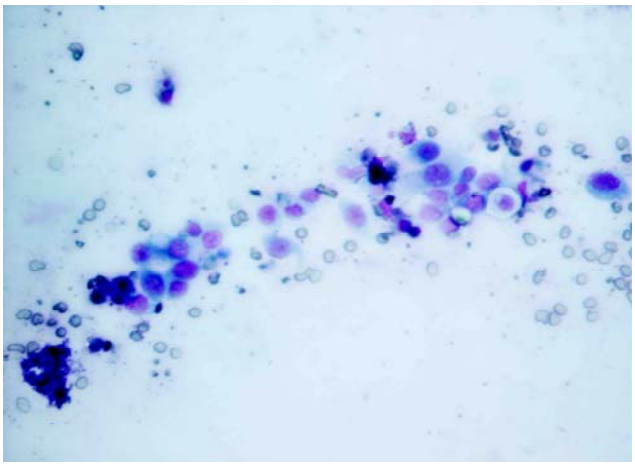

Figure 6 Needle aspirate, prostate various sizes nuclei, 12 year old beagle

Prostatic cysts

Cystic lesions in the prostate gland are variable. Although intraprostatic cystic change associated with BPH comprises numerous small cysts within the gland parenchyma, true cysts are generally larger, centrally cavitated and fluid-filled with a distinct wall (Figure 3).
From the cytological point o view the fine needle aspirate is similar to a blood smear, with erythrocytes, leucocytes or benign epithelial cells, the macroscopic aspect may appear serosanguinous or sanguineous.
The clinical signs are uncommon unless the cyst or cysts become secondary infected.

Prostatitis

Septic prostatitis may coalesce or if prostatic cysts become infected, an abscess may develop.
Cytological evaluation in acute prostatitis reveals predominantly degenerate neutrophils often with detectable intracellular bacteria. In addition to neutrophils, cytology of chronic prostatitis often reveals large numbers of macrophages along with lymphocytes and plasma cells.
Inflammatory response may induce numerous cytological criteria of malignancy in normal cells therefore cytological diagnosis of neoplasia in the presence of severe inflammation may be challenging.

CONCLUSIONS

1. Fine needle aspiration biopsy (FNAB), it is inexpensive, easy to perform the minimally invasive method feasible for a consciouss or slightly sedated patient (Anderson et al., 1994). Sample obtained by FNAB can be used for bacterial cultivation and/or for cytology.
2. From the cytological point o view the fine needle aspirate from a cyst, is similar to a blood smear, with erythrocytes, leucocytes or benign epithelial cells, the macroscopic aspect may appear serosanguinous or sanguineous.
3. Cytological evaluation in acute prostatitis reveals predominantly degenerate neutrophils often with detectable intracellular bacteria. In addition to neutrophils, cytology of chronic prostatitis often reveals large numbers of macrophages along with lymphocytes and plasma cells.

BIBLIOGRAPHY

1. Baker, R. and Lumsden, J.H. (2000). Cytological evaluation of body systems: Prostate. In: Color Atlas of Cytology of the Dog and Cat. First edition. St. Louis, MO: Mosby.
2. Barsanti, J.A., Shotts, E.B. and Prasse, K. (1980). Evaluation of diagnostic techniques for canine prostatic diseases. Journal of the American Veterinary Medical Association 177: 160-163.
3. Barsanti, J.A. and Finco, D.R. (1984). Evaluation of techniques for diagnosis of canine prostatic diseases. Journal of the American Veterinary Medical Association 185: 198-200.
4. Barsanti, J.A. and Finco, D.R. (1995). Prostatic diseases. In: Textbook of Veterinary Internal Medicine. Fourth edition. Edited by S.J. Ettinger and E.C. Feldman. Philadelphia: WB Saunders. Bell,
5. B.W., Klausner, J.S., Hayden, D.W., Feeney, D.A. and Johnston, S.D. (1991). Clinical and pathologic features of prostatic adenocarcinoma in sexually intact and castrated dogs: 31 cases (1970- 1987). Journal of American Veterinary Medicine Association 199: 1623-1630.
6. Cotran, R.S., Kumar, V. and Collins, T. (1999). Cell Pathology. In: Robbins Pathologic Basis of Disease. Sixth edition. Philadelphia: WB Saunders.
7. Cowan, L.A. and Barsanti, J.A. (1991). Prostatic diseases. In: Small Animal Medicine. First edition. Edited by D.G. Allen, S.E. Kruth, and M.S. Garvey. Philadelphia: JP Lippincott.
8. Watanabe H., Igari D., Tanahashi Y., Harada K., Saitoh M. (1975): Transrectal ultrasonography of the prostate. Journal of Urology, 114, 734–739.
9. Waters D.J., Patronek G.J., Bostwick D.G., Glickman L.T. (1996): Comparing the age at prostate cancer diagnosis in humans and dogs. Journal of the National Cancer Institute, 20, 1686–1687.
10. Waters D.J., Hayden D.W., Bell F.W., Klausner J.S., Quian J., Bostwick D.G. (1997): Prostatic intraepitelial neoplasia in dogs with spontaneous prostate cancer. The Prostate, 30, 92–97.

GONIOSCOPY WITH IMAGE ACQUISITION AT DOGS AND CATS

B. Ş. RUGINĂ[1], I. BURTAN[2] , L. C. BURTAN[2], Diana IAMANDI[1]

1 Centrovet Clinic, 52-54 Pascal Aristide Street, 031446,
Bucharest, centrovet@centrovet.ro
2 Faculty of Veterinary Medicine,Iassy

ABSTRACT

While having in view the importance of the iridocorneean angle (camerulary) in the drainage of aqueous humour, we proceeded with gonioscopy (the examination of the iridocorneean angle) in order to establish a glaucomatous pathology. The examination of the camerulary angle was made with three types of gonioscopy lenses, using different magnifying systems or without image acquisition. In order to perform gonioscopy, we used the following types of lenses: Koeppe small, Sussman and Lovac Barkan. The image acquisition was made by magnification systems with image acquisition controlled by the computer: Clear View/Optibrand, Biocam 2.0 and by photographic systems: slit-lamp Hawk Eye and professional cameras DSRL, using a Nikon D3X camera Gonioscopy emphasized the advantaged and disadvantages of each goniolens, concluding that the image with maximal resolution is obtained with Biocam 2.0 system and Lovac Barkan goniolens. The maximal facilities in image acquisiton are offered by the combination of slit-lamp Hawk Eye with Koeppe small goniolens.

Key words: gonioscopy, goniolens, sclerociliary angle, glaucoma, goniodysgenesis

INTRODUCTION

At the level of iridocorneean angle, we find the pectinate ligament which is made of conjunctive fibers covered by a simple squamous epithelium, found in continuity to the corneean endothelium. It links the corneoscleral junction with the iridocorneean sinus and the base of the iris. Behind this ligament, in the iridocorneean sinus, we can find a fine trabecular meshwork made of crossed collagen fibers that are covered by a simple aquamous epithelium. This one is called uveal trabecular meshwork and it comes from the iridocorneean sinus and continues with the corneoscleral trabecular meshwork that comes into contact with the corneoscleral junction (5, 7, 9). The pectinate ligament and the trabecular meshwork mark off the Fontana spaces used by the aquous humour when it leaves the anterior chamber of the ocular globe in order to pass into the aquous collector venae (found in the sclera near the trabecular meshwork) and the scleral plexus (represented by 2-4 big vessels spotted in the sclera posterior to the sclerocorneean limb) and farther to the venous vortex and the systemic circulation (5, 7, 11). As opposed to the humans, the animals don't have the Schlemm's canal (1, 2, 7, 8). The congenital modifications of the sclerociliary angle (goniodysplasia/ goniodysgenesis) and the obtained modifications (the closing of the angle, sediments secondary to the uveitis etc.) reduce the drainage at the level of the sclerocyliary angle, having a major function in the appearance of glaucoma (7, 12, 13). The mydriatics close the sclorociliary angle, reducing the drainage. The miotics open the angle, favouring the drainage of the aquous humour (3, 8, 9, 10). This paper will analyze different methods of examination with image acquisition of the iridocorneean angle. This is due to the fact that the examination of the iridocorneean angle is one method used for the diagnostic and evaluation of the glaucoma occurance risk (4, 6).

MATERIAL AND METHOD

This paper was accomplished at Centrovet Clinic, Bucharest, from December 2009 until April 2010 and we studied a number of 53 cases (dogs and cats of ages between 1 and 12 years old, different sexes and breeds). The dogs and cats didn't have any clinical ocular pathology. The iridocorneean angle was examined with different types of goniolenses (Koeppe small, Sussman, Lovac Barkan) and different image acquisition systems with magnification (ClearView, Biocam 2.0, slit-lamp Hawk Eye, Nikon D3X). The purpose of this study was to emphasize the advantages, the limits and possibilities of combination of the goniolenses with different magnification systems with image acquisition. The examination of the iridocorneean angle was achieved at the loose or held in animal, depending on its behaviour. The animal`s holding in was performed manually, mechanically (muzzle) or chemically (local anaesthesia, tranquillisation or general anaesthesia).

RESULTS AND DISCUSSIONS

As a result of our research, we could notice the importance of the goniolenses use in gonioscopy, each device having several features that recommend it in the practice of the ophthalmologic examinations.
The results concerning the features of the goniolenses used in the experiment are presented in table 1.

Table 1

The features of Sussman, Lovac Barkan and Koeppe small goniolenses

Specification	***Goniolens type***		
	Sussman	**Lovac Barkan**	**Koeppe**
Examination	indirect / 4 mirrors	direct	direct
Cornea fastening	manual	vacuum	contact substance
Optical interface	no	yes	yes
Dynamic gonioscopy	yes	no	no
Contact diameter	9 mm	16 mm	17 mm (small model)
Image magnification	0,94x	2x	1,55x (small model)
Static field of examination (FOV)	80º	180º	160º
Examination system use	yes	optional	optional
"free hands"	0	1-2	1-2
Number of persons needed for examination	2	1	1

The Sussman model goniolens (picture 1) is used less, having the major disadvantage of a difficult handling, intricate imagistic (multiplications in the mirror), number of persons involved in it and reduced magnification, which are relatively compensated by the advantages offered by the reduced contact surface, dynamic gonioscopy and the absence of the optical interface.



Picture 1. Sussman goniolens: optical scheme, aspect, imagistic, use.

Lovac Barkan model goniolens (picture 2) has the advantage of a maximal magnification of the examination area, manevrability and relatively easy positioning. It is broadly used.

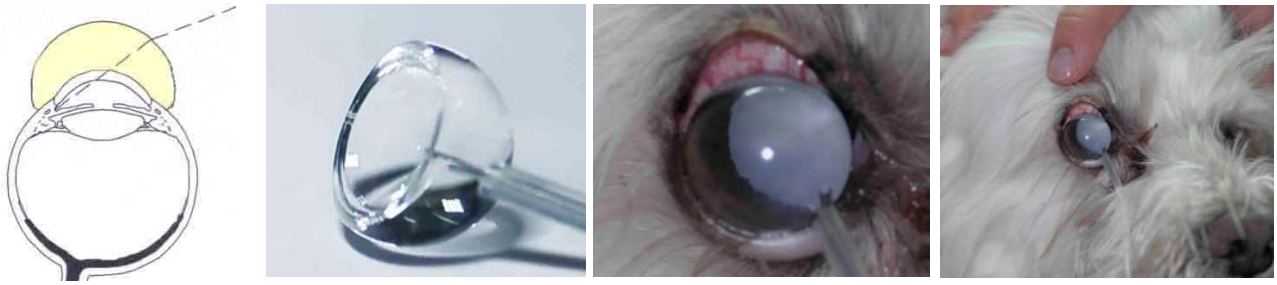

Picture 2. Lovac Barkan model goniolens: optical scheme, aspect, imagistic, use.

Koeppe model goniolenses (picture 3) have the advantage of the manevrability and easy positioning, wide examination area. This is the reason why they are broadly used.

Picture 3. Koeppe model goniolens: optical scheme, aspect, imagistic, use.

The standard examination instrument for the anterior segment of the ocular globe is represented by slit-lamp. Portable digital Hawk Eye slit-lamp (picture 4) distinguishes itself by the possibility of taking pictures. The main optical features of the device are as follows: selective magification (8x, 12,5x, 20x), image acquisition on the anterior and posterior segment of the ocular globe, working distance 105 mm, adjustable diopters ±5D, adjustable inter-pupillary distance 50-73mm, illumination angle ±60º, image acquisition camera of 6 Megapixeli, optical zoom 3x.

Picture 4. Hawk Eye slit-lamp: aspect, use, gonioscopic image.

The system of optical image acquisition ClearView/Optibrand (picture 5) is represented by a specialized camera, controlled by the computer. It has the following optical features: bifocal illumination led with adjustable intensity, manual focus, series of images acquisition (4/tripping) on the anterior and posterior segment of the ocular globe, snapshotdisplay, memory capacity with specific identification (patient/owner/registration number etc.), USB connection.

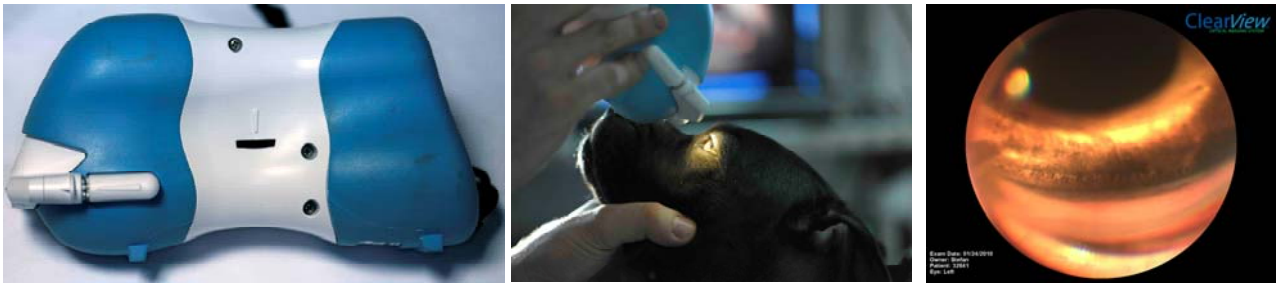

Picture 5. ClearView acquisition system: aspect, use, gonioscopic image.

Image acquisition system Biocam 2.0 (picture 6) represented by an acquisition camera controlled by the computer, ophthalmologically unspecified, has the following features: adjustable focus, sensor resolution 334,62 pixels, white led illumination, image acquisition with instantenous conveyance, USB connection. It has the advantage of a circular positioning of the light around the acquisition lens (illumination axle parallel to the optical axe) and variable work distance (250-5mm). These advantages make up for the low resolution and long time exposure.

Picture 6. Image acquisition system Biocam 2.0: aspect, use, gonioscopic image.

We used a Nikon D3X DSRL professional camera (picture 7) with the following features: digital camera with single reflex through the lens, AF-S Micro Nikkor 105 mm lens, CMOS 24,5 Megapixels

sensor. The image acquisition was performed in double format (JPEG 8,55 Mb and RAW/NEF 29,5 Mb) at a 14 bits colour depth incondensable, manual focus, single focus point, ISO 500-1600.

Picture 7. Nikon D3X DSLR: aspect, use, gonioscopic image.

If we analyze the factors influencing the gonioscopy and the lens types combined with different image acquisiton systems, the best results are obtained at an animal which is chemically held in (general and local anaesthesia). The infraversion of the ocular globe is the only disadvantage of this device and this is the reason why it may need repositioning. If we consider the different types of lenses, the major disadvantage is represented by the Sussman type as it performs a reduced magnification, it is difficult to be handled and 2 persons are needed to perform the gonioscopy. Koeppe lens is widely used at dogs and Lovac Barkan lens performs better results at cats as their radius of curvature is more similar to the cat's corneal radius of curvature. If we consider the acquisition systems, Hawk Eye slit-lamp has the major advantage of portability. The acquisiton systems using the computer have the advantage of an instantaneous evaluation of the images. Nikon DSRL D3X system has the advantage of obtaining a high resolution image. Its major disadvantage is a difficult focusing, handling and a poor illumination that affects the image acquisition. The rate of usable images, out of all obtained images, varies according to the system: slit-lamp has the highest rate and the lowest one belongs to Nikon D3X. Anyway, this isn't a meaningful parameter if we consider the unlimited acquisiton capacity of a digital system. The quality of the images is given by the goniolens type, optical system, light and distance. The best quality is performed by Biocam 2.0 and the poorest one is given by Nixon D3X (only for gonioscopy). These aspects are presented in table 2.

Table 2

The comparison of the practical features of image acquisition systems, using a 1-10 scale for evaluation

Studied feature	Image acquisition system			
	Slit-lamp Hawk Eye	ClearView	Biocam 2.0	Nikon D3X
Portability	10	7	7	10
Specified resolution	8	7	5	10
Obtained image resolution	7	8	9	4
Rate of usable images	9	9	7	2
Handling	10	9	9	4
Obtained image evaluation	5	10	10	5
Quantity of use instructions	9	9	9	2
Time necessary for the preparation of the device needed for examination/image acquisition	10	8	8	7
Necessary connected devices	10	7	7	8
TOTAL	**78**	**74**	**71**	**52**

If we compare the features of the 3 types of goniolenses to the practical results , we can draw a conclusion concerning the order of their utilization. The data are shown in table 3.

Table 3

The comparison of the practical features of the goniolenses on a scale from 1-10

Studied feature	Goniolens type		
	Koeppe	**Lovac Barkan**	**Sussman**
Manevrability	10	7	2
Magnification	8	10	2
Dynamic gonioscopy	1	1	10
Necessary personnal	10	10	1
Optical interface	8	9	10
Static examination area	9	10	3
Connected devices necessary for the examination/image acquisition	8	9	5
Contact surface	7	8	10
TOTAL	61	64	43

The major disadvantages in gonioscopy belong to Sussman goniolens and non-specialized ophthalmological image acquisition systems such as Nikon D3X.

CONCLUSIONS

1. We use 3 types of goniolens in veterinary gonioscopy: Koeppe, Lovac Barkan and Sussman, which is less recommended
2. The obtained image depends on the image acquisition system type and a maximal image resolution depends on the acquisition system/goniolens combination.
3. A maximal resolution image can be obtained with Biocam 2.0 system and Lovac Barkan goniolens.
4. The maximal facilities in image acquisition are provided by the combination between Hawk Eye slit-lamp and Koeppe goniolens.
5. The non-specialized high-quality image acquisition systems, Nikon DSRL D3X, cannot compensate the shortcomings specific to the gonioscopic examination.

BIBLIOGRAPHY

1. *Burtan I.*, - *Chirurgie regionala veterinara*, Editura Ion Ionescu de la Brad, Iasi, 2000.
2. *Burtan I.*, - *Patologie chirurgicala generala veterinara*, Editura Ion Ionescu de la Brad, Iasi, 2004.
3. *Cunningham J.G.*, *Klein B.G.*, - *Textbook of Veterinary Physiology*, Saunders Elsevier, 2007.
4. *Dalaurent T.*, *Isard P.F.*, *Dalaurent A.*, *Regnier A.*, *Raymond Letron I.*, - *Gonioscopic, ultrasound biomicroscopic, light and scanning electron microscopic imaging of a diffuse iris melanoma in a cat*, European Veterinary Ophthalmology Meeting ECVO, 2009.
5. *Eurell J.A.*, *Frappier B.L.*, - *Dellman's textbook of veterinary histology*, Blackwell Publishing, 2008.
6. *Gelatt K.N.*, *Ladds P.W.*, - *Gonioscopy in dogs and cats with glaucoma and ocular tumors*, Journal of Small Animal Practice, 1977.
7. *Gelatt K.N.*, - *Veterinary Ophthalmology*, vol 1,2, Blackwell Publishing, 2007.
8. *Ionascu Iuliana.*, *Miclaus I.*, - *Notiuni de oftalmologie veterinara*, Editura Elisavaros, 2007.
9. *Maggs J.D.*, *Miller E.P.*, *Ofri R.*, - *Slatter's Fundamentals of Veterinary Ophthalmology*, Elsevier Inc., 2008.
10. *Miller P.E.*, - *Angle closure glaucoma*, Nordic Veterinary Ophthalmology meeting, September 2005.
11. *Morosanu N.*, *Burtan I.*, - *Patalogie si clinica chirurgicala*, Centrul de Multiplicare Universitatea Agronomica Iasi, 1994.
12. *Peiffer R.L.*, *Petersen-Jones S.M.*, - *Small Animal Ophthalmology*, Elsevier Limited, 2009.
13. *Turner M.S.*, - *Small Animal Ophthalmology*, Elsevier Limited, 2008.

STUDIES REGARDING THE PREVALENCE AND DETERMINANT FACTORS OF THE MAIN DISEASES IN DAIRY COWS*

Elena RUGINOSU[1], Şt. CREANGĂ[1], Anca PLĂVĂNESCU[1], L. DASCĂLU[1]
D. ANIȚĂ[2], Adriana ANIȚĂ[2], Cristina REBEGEA,[2] Gh. SOLCAN[2]

[1] Research Station for Bovine Dancu, Loc. Dancu, jd. Iaşi; e-mail: scdbdancu@yahoo.com
[2] Faculty of Veterinary Medicine Iasi

SUMMARY

Studies were performed at Research and Development for Bovine Breeding Dancu, Iassy Station, in 2008-2009 period, on dairy cows, Romanian Black and White Spotted breed, on an average animal breeding group of 400 heads/year, exploited in a mixed system - free system in summer camp and tied system, in barns in winter. Epidemiological investigations regarding the prevalence of pathological dominants were made considering the different factors of variation (calving season, level of production) and biological samples were collected (milk, genital secretions) for bacteriological tests. The study on the main pathological dominants showed the following prevalence: mastitis, conditioned by the calving season, with minimum values in winter (4,50% -clinical mastitits, respectively 6,25% - subclinical mastitis) and maximum values in the summer (7,50% -clinical mastitis and respectively 15,00% -subclinical mastitis); milk production level, with minimum values situated at lower production levels (3,0% -clinical mastitis, respectively 5,0 % -subclinical mastitis) and maximum values at higher production levels (4,75% -clinical mastitis, respectively 8,75 % -subclinical mastitis); genital infections, depending on the season, with minimum values in autumn (14,8 %) and maximum values in winter–spring seasons (28,5 %, respectively 30,8 %); lactation, minimum values at fifth lactation (17,0 %) and maximum values at first lactation (28,4 %); milk production level, with minimum values (11,5 %) at lower levels and maximum values (37,5 %) in cows with higher levels of 31-35 litres of milk/day. Bacterial etiology of mastitis was represented by mixed cultures, between 25 % (clinical forms) and 32,5 % (subclinical forms), with Bacillus cereus and Actinomyces pyogenes and by pure cultures containing the following species: Staphylococcus aureus (coagulazo +), Streptococcus agalactiae, Streptococcus dysgalactiae and Escherichia coli, in different percents for subacute and chronic forms. Bacterial flora involved in the genital infections was represented by pure culture bacteria of the following species: Arcanobacterium pyogenes, Bacillus cereus, Streptococcus pyogenes anaerob, each in 16,6 % of the cases and mixed bacterial flora, formed of Arcanobacterium pyogenes with Streptococcus spp. aerobe or with Streptococcus spp. anaerobe in 33,3 % and respectively 16,6 % of cases.

Key words: dairy cows, mastitis, genital infections, prevalence, bacterial flora.

The study was elaborated within the research project CNMP, Contract 51-004/2007

Continuous raise of production performance in dairy cows imposed a reorientation of veterinary services by the transition from individual to integrated approach, concerning health and animal production management at farm level. In this new orientation it is important to have data about the prevalence of pathological dominants in farm and animal health risk factors as well, regarding

the determinant and bias factors of various types of diseases, being targeted the bacterial factors, breeding system, hygiene and milk production level. For this purpose it is necessary to constantly monitor the health status of animals by clinical analysis and laboratory tests, udder and foot health control, monitoring of production and reproductive performances, in relation to technological factors and to correct them when deficiencies are found. Regarding the prevalence of major pathological dominants in dairy cows, various authors have reported some variations, depending on various factors of influence, such as: farm size, breeding conditions, nutrition, milk productions level, lactation, zoohygiene factors. Nutrition and hygiene errors and temperatures that overcome the thermal comfort proved adversely effects on animal health, increasing the frequency of various types of diseases, (1,3,5,6,7,8,9,10,12,14,15,16). The purpose of this study was to determine the prevalence and determinant factors of the main diseases in the studied farm, in order to elaborate an integrated programme for health surveillance of animals, with positive effects on the production performance of dairy cows.

MATHERIALS AND METHODS

Studies were performed during two consecutive years, 2008-2009 at Research and Development for Bovine Breeding Dancu, Iassy Station, on average 400 heads/year of cows and heifers, Romanian Black and White Spotted breed, exploited in mixed system, free in summer camp, and tied system, in barns, in the cold season. Body condition of the animals was good and the average annual milk production was 6100 liters / normal lactation. Epidemiological investigations on the pathological dominants were performed, using the data of cow treatment record, in order to determine the prevalence of major pathological entities, depending on different variation factors. Biological samples were collected (milk, genital secretions) for bacteriological analysis, to identify the determinants of main diseases found at dairy cows.

RESULTS AND DISCUSIONS

Studies on the prevalence of various diseases in dairy cows showed as dominant pathology the following entities: mastitis (33,25%), genital infections (32,0%), medical diseases (21,40%), limbs diseases (12,40%), other disorders (0,95%), (fig. 1).

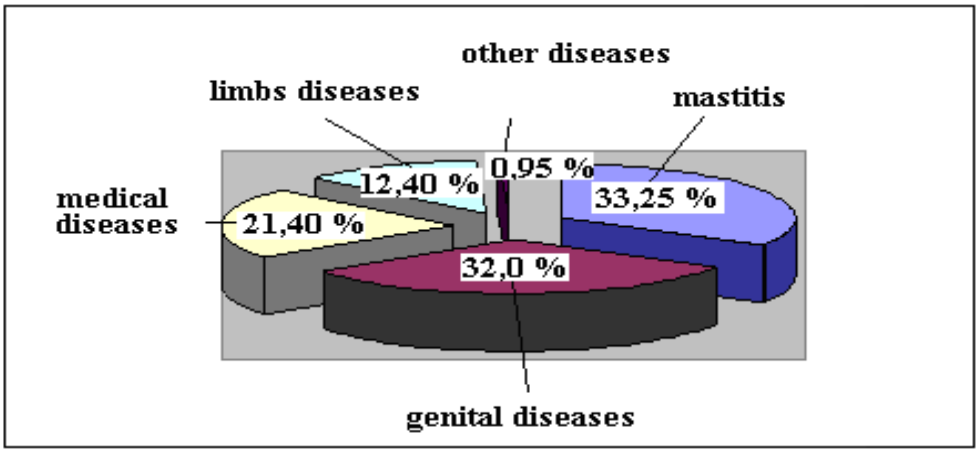

Fig. 1 Pathological dominants in dairy cows

Mastitis diagnosed with the highest frequency in this study recorded a subclinical and clinical evolution. Prevalence of subclinical mastitis, established using R. Mastitis showed an average of

21,25% and of 12,00% for clinical mastitis, with variations depending on season and level of milk production. Regarding to season, the prevalence of subclinical mastitis in cows showed variations between 6,25 % (winter) and 15,00 % (summer), and between 4,50 % (winter) and 7,50 % (summer) for clinical mastitis (tab. 1).

Table 1

Prevalence of subclinical and clinical mastitis in cows depending on the season

Specifications	Season				Total cows with mastitis	
	Summer		Winter			
	n	%	n	%	n	%
Subclinical mastitis	60	**15,00**	25	**6,25**	85	**21,25**
Clinical mastitis	30	**7,50**	18	**4,50**	48	**12,00**
Total cows with mastitis	90	**22,50**	43	**10,75**	133	**33,25**
Total cows studied					400	

Results analysis indicated the fact that increased levels over the thermal comfort may be potential risk factors involved in mastitis etiology in cows, noted also by other authors, (Faye, B., and. all.,1994). In our study the incidence of mastitis correlated to milk production level, minimum values were found in cows with lower production levels of up to 20 liters of milk/day (3,00 % - clinical mastitis and 5,00 % - subclinical mastitis) and maximum values in cows with high production levels of over 21 liters of milk (7,50 to 8,75 % - subclinical mastitis and between 4,25 % to 4,75 % - clinical mastitis for production levels of 21 - 30 and 31 -35 liters of milk / day), (tab. 2).

Table 2

Prevalence of subclinical and clinical mastitis in cows correlated to milk production

Specification	Milk production litres/ day						Total	
	- 20		21 - 30		31 - 35			
	n	%	n	%	n	%	n	%
Subclinical mastitis	20	**5,00**	30	**7,50**	35	**8,75**	85	**21,25**
Clinical mastitis	12	**3,00**	17	**4,25**	19	**4,75**	48	**12,00**
Total cows with mastitis	32	**8,00**	46	**11,75**	55	**13,50**	133	**33,25**
Total cows studied							400	

Recorded data indicated that cows with high milk production are more susceptible to infections of the mammary gland due to specific predisposition to infection in this category of animals. Similar results were reported by other authors. Oltenacu P.A., 1994 found that prevalence of mastitis was 1,2 to 1,4 times higher in cows with higher milk production compared with those with lower yields. By analyzing the animal culling due to different types of diseases it was found that limbs disorders were involved in 37,73% of cases, followed by digestive diseases (21,38%), mammary gland disorders (19,49 %), genital diseases (14,15 %) and other diseases (7,25 %), (fig. 2).

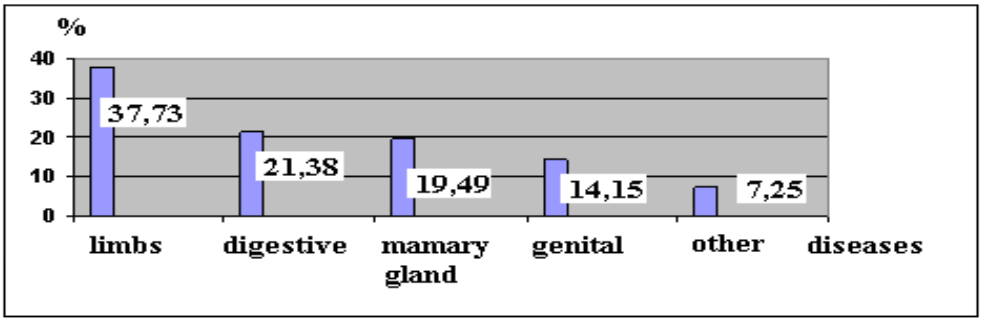

Fig. 2 The situation of culled cows within the herd due to various diseases

Regarding the determinant factors of mastitis a mixed flora was found, between 25 % of bacterial cultures isolated from cows with chronic mastitis and 32,5% of bacterial cultures isolated from cows with acute and subacute mastitis. A bacterial flora was isolated in pure culture between 67,5% (acute/subacute mastitis) and 75% (chronic mastitis. The bacterial species most frequently isolated were Staphylococcus aureus (coagulase +), (30%) from cows with acute/subacute mastitis and Escherichia coli (33,3%) from cows with chronic mastitis. Other bacteria were isolated in smaller percentages of the species Streptococcus agalactiae (15% - acute/subacute mastitis and 16,6% -chronic mastitis), Streptococcus dysgalactiae (8,3% - chronic mastitis, respectively 12,5% - acute/subacute mastitis), (tab. 3).

Table 3

Bacterial flora isolated from milk in cows with clinical mastitis

Specification	**Cows with acute/subacute mastitis**		**Cows with chronic mastitis**	
	Bacterial cultures		Bacterial cultures	
	n	%	n	%
Bacteria isolated in pure culture	**27**	**67,5**	**9**	**75,0**
Streptoccocus agalactiae	6	15,0	2	16,6
Streptococcus dysgalactiae	5	12,5	1	8,3
Staphylococcus aureus (coagulase +)	12	30,0	2	16,6
Escherichia coli	4	10,0	4	33,3
Bacteria isolated in mixed cultures (Bacillus cereus, Actinomyces pyogenes,)	**13**	**32,5**	**3**	**25,0**
Total isolated bacterial cultures	40		12	

Genital infections were also important pathological entities affecting the morbidity in dairy cows. Investigations of the dairy cows revealed different variations depending on various factors of influence. Considering the monthly dynamics, the prevalence of genital infections recorded minimum values in June, September and October (10,0 %, 10,2 % and 13,6 % respectively) and maximum values in August, April, December, February, March (26,4 %, 30,0 %, 31 %, 34,6 % and 37,0 % respectively), (fig. 3).

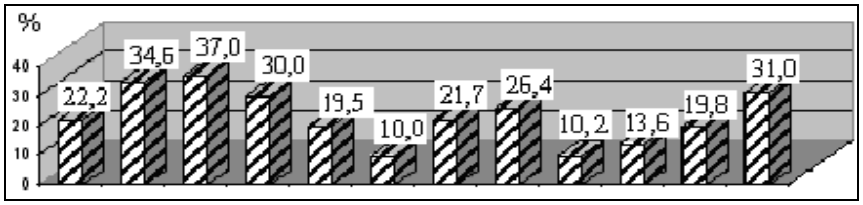

I II III IV V VI VII VIII IX X XI XII

Calendar months

Fig. 3 Monthly dynamics of the prevalence of genital infections in cows

The prevalence of genital infections recorded minimum values in autumn (14,8%) and maximum values in winter-spring season (28,5% and 30,8% respectively), (fig. 4) .

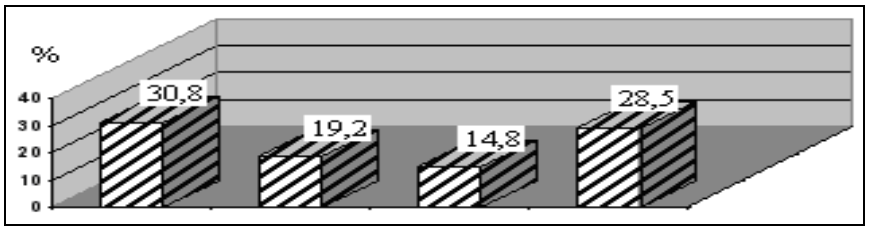

Spring Summer Autumn Winter calving season

Fig. 4 The prevalence of genital infections in cows in relation to calving season

Maximum values for the prevalence of genital infections were recorded at first lactation (28,4 %) and minimum values at fifth lactation (17,0%). After the fifth lactation increases of genital infections due to animal age were found, (fig. 5).

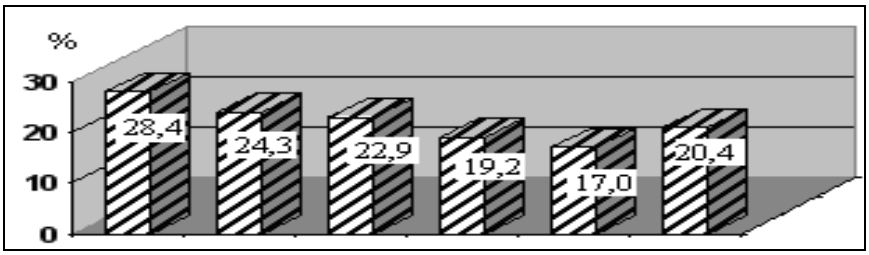

I-a a-II-a a-III-a a-IV-a a-V-a > a-V-a lactation

Fig 5 Prevalence of genital infections in cows correlated to lactation

The prevalence of genital infections recorded increased values directly proportional to raised milk production level. Thus, maximum values were found (37,5 %) in cows with more than 7500 liters of milk / normal lactation and minimum values (11,5 %) in cows with low milk production, (fig. 6).

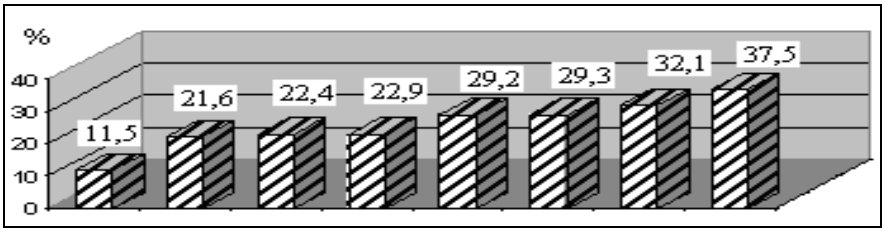

4000-4500 4501-5000 5001-5500 5501-6000 6001-6500 6501-7000 7001-7500 > 7500 liters of milk/ normal lactation

Fig. 6 Prevalence of genital infections in cows in relation to milk production

This study showed that cows with high milk production have a tendency to develop infectious genital diseases due to decreased uterine resistance to infections which was confirmed by other authors, as well (J. Steffan and all. 1985). Seasonal variations of prevalence of genital infections recorded in this study were indicated also by other authors, who showed that thermal values outside the thermal comfort (more or less) act as suppressor factors of cellular and humoral immune effectors, affecting the ability of local and general self defense by enhancing the susceptibility of the organism to various pathogens or pathogenic conditioned (Boitor, I, 1979; Chaffaux, St., Thibier M., 1991, Faye, B., and all, 1994; Francas, G, and all. 1993). Literature shows the different variations of the incidence of genital infections from one author to another, depending on a variety of factors, such as: farm size, season, breeding conditions, milk production level, female age, the oscillations being between 23,8 % (Scheidegger, G.A., and all.,1993), 25 - 30% (Chaffaux, St., Thibier M., 1991) and between 34,9 - 39,8% (Miuisepp, J. and all, 1984). Similar results were found also by Faye, B., and col., 1994 regarding the incidence of genital infections in relation to lactation, but lower levels, with a maximum of 11,1% in first lactation and a minimum of 5,5 % in fifth lactation and increases again from the fifth lactation, the limits of variation being between 6,1 - 7,6 % in the fifth and seventh lactations. Studies regarding the bacterial risk factors involved in the etiology of genital inflammatory diseases have shown a bacterial flora isolated in pure culture from the following species: Arcanobacterium pyogenes, Bacillus cereus, Streptococcus spp. Anaerobic, each of the cases in 16,6% and an association of mixed bacterial flora, consisting of Arcanobacterium pyogenes, Streptococcus spp. aerobic or Streptococcus spp anaerobic in 33,3% and 16,6% of cases, (fig. 7).

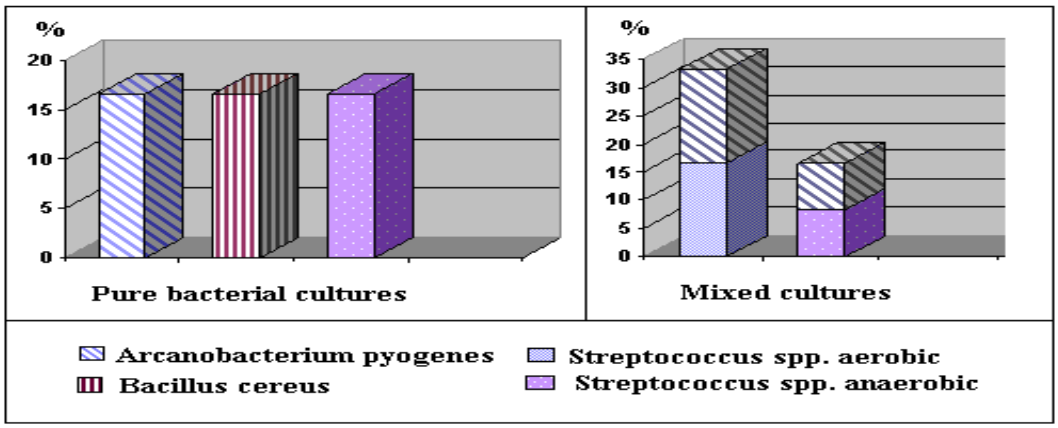

Fig. 7 Bacteria species isolated from cows with genital infections

Studies have shown that Arcanobacterium pyogenes was the most frequent isolated bacteria in cows with genital infections, in pure culture or in association with bacteria from aerobic or anaerobic Streptococcus spp. Literarure indicates as determinant factors of genital infections different bacterial species in pure culture or in association. Some authors suggest that bacteria species Streptococcus, Staphylococcus, colibacillus and pyogenic bacillus are commonly associated in gangrenous metritis with anaerobic bacteria (Clostridium septicum, septic Vibrio, Clostridium perfringens), (Boitor, I., 1979, Chaffaux St. and all, 1991). Other authors indicated that pyogenic bacteria are commonly associated with bacillus necrosis (necrophorus) in the necrotic type of infection (Pseudomembranous croupal), (Seiciu, Fl. and all. 1987) and Actinomyces pyogenes associates with Bacteroides levii spp. and Fusobacterium necrophorum, suggesting a possible synergism between the germs, that would cause early endometritis and/or a chronic persistent infection, (Bekana, M. and all. 1994). Most authors have found an association of bacteria, in which there is a prevalence of some, often germs with gained virulence during succesive passages from one animal to another being involved, favored by lack of hygiene and disinfection and the crowd of

animals in barns (Boitor ,I., 1979; Bostedt H., 1984, Olson , J.D. and all. 1984). From the analysis of these results it is believed that as potential factors involved in the etiology of major diseases found in dairy cows the tied system in barns, the lack of active movement during the cold season, the microclimate and zoohygiene deficiencies, the temperatures outside thermal comfort, sometimes associated with deficiencies in cattle nutrition are incriminated, as well, besides determining factors (such as bacterial flora).

CONCLUSIONS

1. Within the specific diseases of dairy cows the following entities were established as pathological dominants: mastitis (33,25%), genital infections (32,00%), medical disorders (21,40%), limbs diseases (12,40%), other diseases (0,95%);
2. The prevalence of mastitis in cows showed variations according to the following factors: season of calving, with minimum values in winter and maximum values in summer; milk production level, with minimum values at low production levels and maximum values at high production levels;
4. Bacterial etiology of mastitis was represented by a mixed flora between 25 % (clinical forms) and 32,5 % (subclinical forms) of cases, consisting of the species Bacillus cereus and Actinomyces pyogenes and pure culture of bacteria from the following species: Staphylococcus aureus (coagulase +), Streptococcus agalactiae, Streptococcus dysgalactiae and Escherichia coli, in different proportions for subacute and chronic forms;
5. Prevalence of genital infections presented variations, depending on various factors: the calving season, with minimum values in autumn and maximum values in winter-spring seasons; lactation, with minimum values at fifth lactation and maximum values at first lactation; milk production level, with minimum values at lower levels and maximum values at cows with higher levels of over 7500 liters of milk / normal lactation.
6. Bacterial flora involved in genital infections was represented by bacteria in pure culture from the following species: Arcanobacterium pyogenes, Bacillus cereus, Streptococcus spp. anaerobic, and a mixed bacterial flora consisting of Arcanobacterium pyogenes, Streptococcus spp aerobic or Streptococcus spp. anaerobic.

BIBLIOGRAPHY

1. BAUDET, H. M., 1990- Conduite alimentaire des vaches taries et incidence de maladies métaboliques en dêbut de lactation- Rév. de Méd. Vét., 168, no.6/7, 437-443,
2. BEKANA M., JONSSON P., EKMAN T., KINDAHL H., 1994- Intrauterine bacterial finds in postpartum cows with retained fetal membranes,Vet. Med., 41(9),663-700,
3. BOITOR ,I., 1979- Endocrinologia reproducţiei la animalele de fermă. Ed. Ceres, Bucureşti,
4. BOSTEDT,H. 1984- The uterine inffection in cows postpartum period- 10-th International Congress of Reproduction and Artificial Insemination, june 10-14, Illinois, USA,
5. CHAFFAUX,ST., THIBIER,M. 1991- L´étude epidemiologique et clinique des éndometrites puerperales aux vaches au lait- Récueil de Méd. Vét. 5/6,
6. CHARLES GUARD, 1994- Retained Placenta: Causes and Treatments Cornell University, Ithaca, NY 14853 USA,
7. FABRY, L. 1993-Erreurs alimentaire et troubles de la reproduction- Les elevages belges, no.6,
8. FAYE, B.,şi col. 1994- L´incidence des troubles sanitaire aux vaches de lait, Prod. Anim., no.7,
9. FRANCAS, G. şi col. 1993 -Epidemiological study on factors influencing fertility indices in dairy herds- Theriogenology. Ref. in - Animal Breeding Abstract, no. 9, vol.61,
10. GRUNERT,E.,1978-Etiology of retained bovine placenta- Thériogenology,
11. MIUIESEPP,I.,şi colab.1994- Profilaktika metrita prin normal nom atele-Veterinarya, US.,11,
12. OLSON, J.D. şi col., 1984- Bacteriology of pyometra in dairy cow, -10th International Congress on Animal Reproduction and Artificial Insemination, june, 10-14, Illinois, USA,

13. OLTENACU PA, Ekesbo I. 1994-Epidemiological study of clinical mastitis in dairy cattle. Vet Res. 25(2-3):208-12.
14. SCHEIDEGGER,G.A., MELENDEZ,R.P., 1993- Retained fetal membranes and other puerperal reproductive disorders, their effect on postpartum fertility in Holstein cattle,ref. in- Veterinary Bulletin,4
15. STEFFAN, J., HUMBLOT, P. ,1985- Les relations entre les patologies du period postpartum, âge, le poid corporel, le niveaux de la production de lait et des paramethers de la reproduction, ed. Societé Francaise de Buiatrie, Paris,
16. SEICIU, FL., DRUGOCIU, GH., BOITOR, I., (1987)– *Reproducția normală şi patologică la animalele domestice*, vol I, Editura Ceres, Bucureşti.

THE ROLE OF LIDOCAINE CONTINUOUS INFUSION IN PAIN CONTROL AFTER ORTHOPEDIC SURGERY

Larisa SCHUSZLER, C. IGNA, M. SABĂU, Roxana DASCĂLU, A. SALA, C. LUCA

Faculty of Veterinary Medicine Timişoara,
Calea Aradului, no. 191, code 300645, Timişoara,
larisaschuszler@yahoo.com

ABSTRACT

The research was carried on 18 adult dogs underwent femoral fracture repair, randomly assigned in two groups: experimental and control, with different post surgical analgesic treatment. The anesthetic protocol was the same for both groups. Experimental group received before skin closure an initial 1 mg/kg IV bolus of lidocaine 2% followed by infusion of 30 µg/kg/min lidocaine 2% stopped after two hours. Control group received normal saline bolus/infusion. Subjective pain scores were collected up to 24 hours postop using a dynamic and interactive visual analogue scale (DIVAS). Differences in pain scores and time-to-analgesia failure were recorded. Rescue analgesia was provided with butorphanol in both groups. Significant DIVAS differences between groups were recorded only in the first three hours after the end of surgery. In control group rescue analgesia was necessary to 88,8% of the dogs compared with 66,6% in experimental group. Intravenous lidocaine 2% infusion at a rate of 30 µg/kg/min administered during postoperative period provide analgesic benefits for orthopedic surgery in dogs only during the infusion and shortly after infusion stopping.

Key words: analgesia, lidocaine, infusion, osteosynthesis, dog

Adequate postoperative pain control is still a major problem for many surgical patients. Continuous infusion of IV lidocaine has been identified in the anesthetic literature as a valuable supplement to general anesthesia. Considering its low cost, ease of administration, and low incidence of side effects, lidocaine is an attractive anesthetic option (2). Lidocaine is commonly administered as constant rate infusions (CRI) for management of arrhythmias but at a similar dose rate (50-80 µg/kg/min) (3) or in a dosage between 30-50 µg/kg/min, depending on severity of pain (7), it can also provide dose related systemic analgesia. For intractable/very severe pain, it adds to the analgesia and sedation. Various dosage rates of lidocaine have been advocated. In dogs, rates as low as 10 µg/kg/minute (0.6 mg/kg/hour) provide analgesia, augment opioid analgesia and may induce mild sedation (5), though it may take up to 50 µg/kg/minute (3 mg/kg/hour) for the full cytoprotective and anti-ileus effects (10). The purpose of this study was to determine the efficacy of lidocaine continuous infusion in reducing postoperative pain following osteosynthesis in dogs.

MATERIALS AND METHODS

Eighteen adult dogs (8 female,10 male) weighing 21+/- 5.2 kg underwent surgery for femoral fracture repair. They were randomly assigned in two groups: experimental (EG, n=9) and control (CG, n=9), with different post surgical analgesic treatment. Experimental group received before

skin closure an initial 1 mg/kg IV bolus of lidocaine 2% to rapidly achieve initial therapeutic blood levels, followed by infusion of 30 µg/kg/min lidocaine 2% (1 g lidocaine in 500 ml 0,9 saline) stopped after two hours. Control group received normal saline bolus/infusion.

Each dog was pre-medicated with butorphanol (0,4 mg/kg, IV) + acepromazine (0,03 mg/kg, IV) + ketamine (10 mg/kg IV) administered 30 minutes before anesthesia induction. Anesthesia was induced in all dogs using propofol (2-5 mg/kg IV) and maintained after endotracheal intubation, with cuffed endotracheal tube, with 2% isoflurane in oxygen (1 L/min). Subjective pain scores were collected up to 24 hours postop (at 1, 2, 3, 4, 5, 6, 8, 10 and 24 hours after extubation) using a dynamic and interactive visual analogue scale (DIVAS, 100 mm scale with 0 indicating no pain, no distress and 100 indicating maximum pain or unbearable distress) (9). Differences in pain scores and time-to-analgesia failure considered when DIVAS score was greater than 50 mm, were analyzed using T-test. Significance was set at $p<0.05$. Data are reported as mean ± SD. Rescue analgesia was made with butorphanol administered in a dose used in premedication if the subjective pain score > 50. During postoperatory period of lidocaine infusion the cardiovascular parameters (arterial pressure, oxygen saturation of hemoglobin, heart rate and pulse rate) were monitored. Incidence of side effects that can be attributed to local anesthetic toxicity were recorded too.

RESULTS AND DISCUSSIONS

Only one animal did not require rescue analgesia in CG, and three animals in EG (fig. 1). In the first four hours after the end of surgery in CG four individual needs rescue analgesia, and only one individual in EG. During next four hours in CG were another three rescue analgesic intervention compared with four in EG (fig. 1). From analyze of data results that to provide an adequate level of comfort more rescue analgesia were necessary to dogs in CG, 88,8% of the dogs, compared with 66,6% in EG. However the short duration of analgesia after the end of lidocaina CRI can be explained by short plasma half-life of 8 minutes (2). Pain rating, DIVAS values, are significantly different between groups in first three hours when in EG values were significantly lower (p=0,04) (fig. 2, table 1). To assessments made after this time the differences become insignificant.

There were no lidocaine-related side effects, all cardiovascular parameters were between normal limits. An insignificant and transitory increase in heart rate was observed.

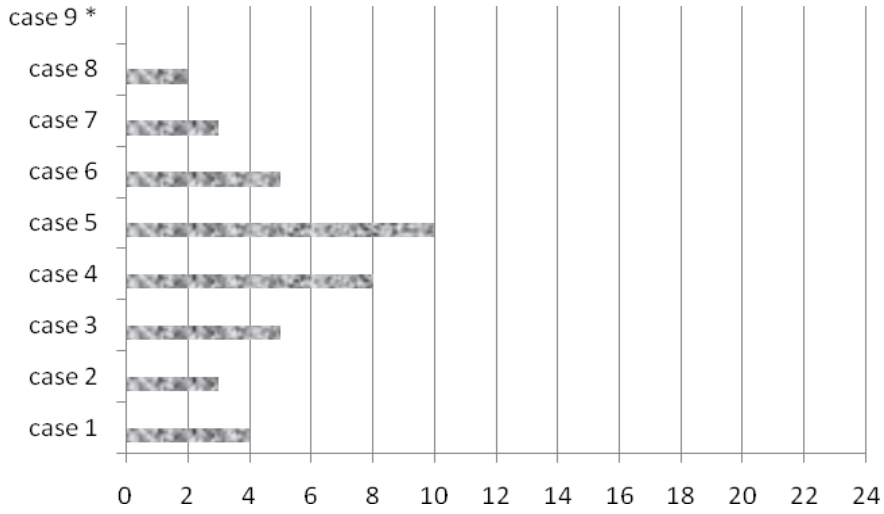

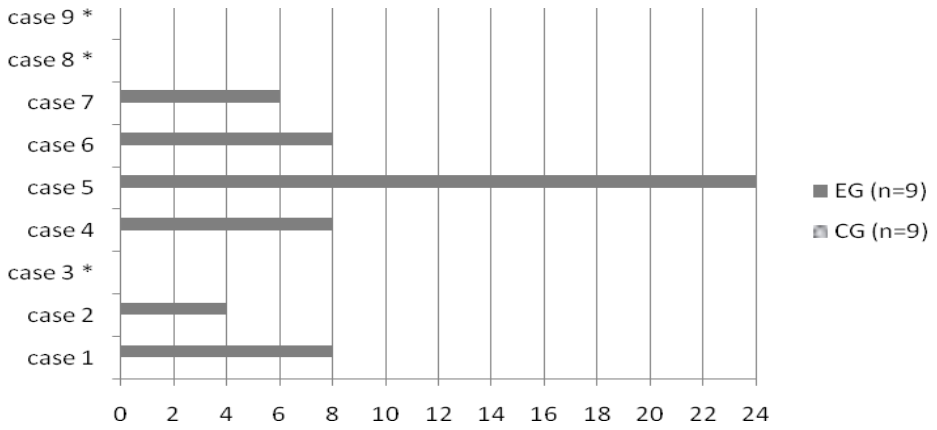

Fig. 1. Time interval after the end of surgery (hours) to rescue analgesia administration.
* no need for rescue analgesia

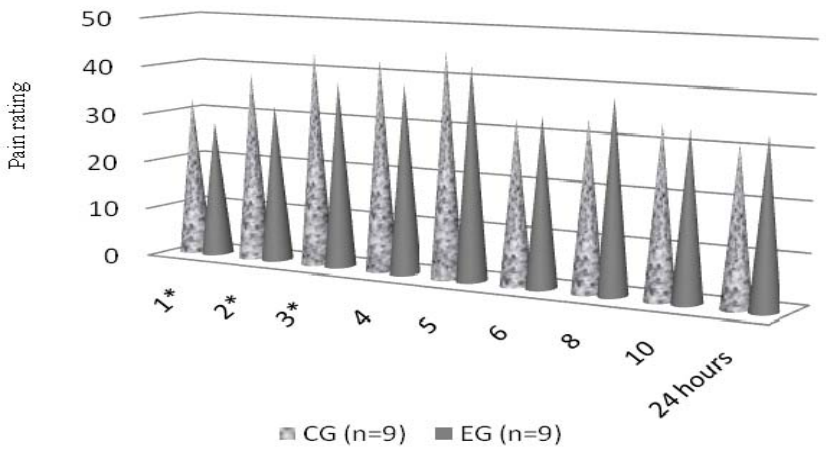

Fig. 2. Pain rating (mean DIVAS) evaluated up to 24 hours postsurgery. * $p<0.05$

Table 1

DIVAS values expressed as mean+/- standard deviation and median (maximum-minimum values) during postoperative period

Group / Time (hours)	CG		EG	
	Mean+/- SD	Median (max-min)	Mean+/- SD	Median (max-min)
1	32,4+/-6,4	34 (41-21)	27,7+/4,4	27 (34-22)
2	38,5+/-8,7	38 (54-27)	32,2+/5,6	29,5 (45-28)
3	43,7+/-8,2	45 (58-31)	37,8+/2,9	38 (42-34)
4	43+/-6,6	44 (52-31)	38,4+/7	39 (55-30)
5	45,4+/-10,1	42 (61-31)	42,8+/3,6	44 (48-37)
6	32,8+/-9,8	36 (48-18)	33+/7,8	32 (52-25)
8	34+/-9,2	34 (53-21)	36,3+/12.9	34 (51-26)
10	33,8+/-7,4	32 (52-27)	33,3+/9,9	30 (50-20)
24	33,1+/-6,2	30 (44-24)	31+/10,2	29 (52-21)

There are many disadvantages of pain documented in human trauma patients. These include: increased stress response with resultant increased metabolic and energy demands; delayed wound healing; reduced immune function; weight loss; lack of sleep; decreased mobility, with an increase in conditions associated with prolonged recumbency (5). Therefore, an adequate pain control it is a necessity and a responsability, because the comfort is the primary goal in veterinary medical practice (8). A balanced or multi-modal approach to analgesia provides the optimum pain relief (5) and including of lidocaine in analgesic plan may provide benefits for the patient. The systemic infusion of lidocaine, and, by implication, sodium channel blockade, may produce immediate and long-term decreases in nociception from surgery (1, 6). Apart from being an effective Na-channel blocker, lidocaine also interacts with other cellular systems – dorsal horn neurons, muscarinic/dopaminergic/K/nicotinic and many other tissue receptors. These interactions may occur at the lidocaine serum concentrations less than those required for Na-channel blockade explaining lidocaine nociceptive properties after intravenous lidocaine infusions (4). Analgesic benefits of lidocaine CRI in this study are evident only during the administration of lidocaine (37,8+/2,9, DIVAS at 3 hours) and shortly after infusion stopping (38,4+/7, DIVAS at 4 hours). This result can be explained on the one hand by the short half-life of lidocaine but also because it was used at the lower rate dosage.

CONCLUSIONS

Intravenous lidocaine 2% infusion at a rate of 30 µg/kg/min administered during postoperative period provide analgesic benefits for orthopedic surgery in dogs only during the infusion and shortly after infusion stopping.

Acknowledgments This work was supported by CNCSIS – UEFISCSU, project number PNII – IDEI 130/2008

BIBLIOGRAPHY

1. **Cassuto J., Wallin G., Hogstrom S.,** 1985, Anesth. Analg., 64:971–974.
2. **Charapov I., Reid D., Bryson G., Krolczyk G., Caveno J.,** 2007, http://www.ottawa-anesthesia.org/lido/index.html
3. **Forysth Sandra,** 2007, Proc. WSAVA Congress, Sydney, http://www.wsava.org/
4. **Hollman M. W, Durieux M. E.,** 2000, Anesthesiology, 93(3):858-875.
5. **Hughes L.,** 2008,, WSAVA 2008 Proceedings, http://www.vin.com/proceedings/Proceedings.plx?CID=WSAVA2008&PID=23922&O=Generic
6. **Koppert W., Weigand M., Neumann F.,** 2004, Anesth. Analg., 98:1050–1055.
7. **Mathews K.,** 2007, Veterinary Emergency and Critical Care, Lifelearn Publication, Ontario, IInd ed., 117-123, 229-262.
8. **McMillan F. D.,** 1998, J.A.M.V.A., 212:1370-1374.
9. **Morton D. B., Griffiths P. H.,** 1985, Vet. Rec., 116:431-436.
10. **Stein, R. Thompson D.,** 2004, http://www.vasg.org/constant_rate_infusions.htm

ATTEMPT TO INDUCE IMMUNOTOLERANCE IN XENOTRANSPLANT USING SKIN CELLS

Monica ŞEREŞ[1], E. TÎRZIU[1], Ileana NICHITA[1], C. CUMPĂNĂŞOIU[1], D. CIOCA[2]

[1]Faculty of Veterinary Medicine Timisoara, 300645, Calea Aradului No. 119, Timisoara, Romania
[2]University of Medicine and Pharmacy "Victor Babes" Timisoara
E-mail: monica_seres@yahoo.com

ABSTRACT

To test the potential of using epidermal and dermal cells suspension in inducing immunotolerance to concordant and discordant xenografts in poultry. Materials and methods. Antigenic material obtained by processing with mechanical disaggregation system MEDIMACHINE™ (Becton Dickinson, USA) the skin tissue taken from two donor dogs and Muscovy ducks was inoculated in 120 Cobb 500 embryos. Inoculation was carried out in the ninth day of incubation, in the allantoidal vessels, and in the fifth day of incubation, in ovo.
At the age of three weeks, the resulting birds were tested for donor-recipient compatibility using mixed lymphocytic reaction; also, at this age, lymphocyte profile of the recipient individuals has been evaluated. Further checking was done by skin transplantation at the age of four weeks. Results. Both laboratory tests and clinical assessment of skin xenografts demonstrated 100% incompatibility between donor and acceptor birds. Conclusion. Epidermal and dermal cells suspension is not a suitable antigenic material for immunotolerance induction in poultry.

Key words: immunotolerance, xenotransplant, skin cells, poultry

In the first issue of the journal Xenotransplantation in 1994, it was predicted in the Editor's preface that "the success of clinical xenografting will depend, at least in part, on finding ways of inducing tolerance across xenogeneic barriers rather than relying entirely on non-specific immunosuppressive agents" (5, 6). As is clear now, neither tolerance nor success of clinical xenotransplantation has yet been realized in the intervening 15 years. Following this line, this study tested the use of skin cells (epidermal and dermal cells) suspension to induce immunotolerance in the concordant and discordant xenotransplant in poultry.

MATERIALS AND METHODS

Biological material: recipient organisms - 120 embryonated eggs of Cobb 500 hybrids; donor birds and animals – two Muscovy ducks aged one year and two crossbreed male dogs aged 3-4 years.
Obtaining the antigenic material. Skin flaps (one flap for each donor individual), measuring 2 x 5 cm, were taken from axillary region of the donor birds and from medial aspect of the thigh in the case of donor dogs. Surgery was carried out under anesthesia (NLA: xylazine 2mg/kg + ketamine 10mg/kg for birds; N-NLA: acepromazine 0.2 mg/kg + ketamine 10 mg/kg + halothane for dogs).

Fig. 1. Mechanical disaggregation system MEDIMACHINE™

Until processing, skin segments were maintained in sterile tubes containing sterile sodium chlorine isotonic solution and penicillin-streptomycin (10,000 IU/ml-10,000µg/ml).
Skin flaps were processed using automated and mechanical disaggregation system MEDIMACHINE™ (Becton Dickinson, USA) (Fig. 1) to separate epithelial cells with 70µm Filcon filter. The entire operation was carried out according to the protocol recommended by the manufacturer (11).
Inoculation of the antigenic material. The resulted epidermal and dermal cells suspensions (n = 4) were inoculated in 4 groups of 30 embryonated eggs as follows – table 1.

Table 1

Experimental scheme

Donor	Recipients	Inoculation method	Intervention day (incubation day)
Dog 1	30 embryonated eggs / **E1 group**	in allantoidal vessels	9
Dog 2	30 embryonated eggs / **E2 group**	*in ovo*	5
Duck 1	30 embryonated eggs / **E3 group**	in allantoidal vessels	9
Duck 1	30 embryonated eggs / **E4 group**	*in ovo*	5

After hatching, each experimental group was matched by a control group with an equal number of birds.
Assessment of donor-recipient compatibility with mixed lymphocyte reaction. We made 24 mixed lymphocyte cultures (12 for experimental groups and 12 for control groups) using Sigma PK Linker modified protocol, respectively a reaction in which proliferative and lytic responses of both cell populations (donor and recipient T cells) is measured. The blood samples (source of T lymphocytes) were gathered from donor individuals and three weeks age recipient and control poultry. After separation of mononuclear cells using the Ficoll-Paque solution, PKH26 Red fluorescent cell linker mini kit, PKH2 Green fluorescent cell linker kit (Sigma Aldrich®) were used.
Mixed lymphocyte cultures were analyzed by flow cytometry after marking dead cells with 7-aminoactinomicin D (read the FL3 detector, wavelength 680 nm, with fluorescent population differentiation, respectively PKH26 - red and PKH2 - green). **Evaluation of the lymphocyte T subsets.** At the age of three weeks, from both experimental and control birds (n = 3 per group), peripheral blood was gathered for obtaining the T lymphocytes using the Ficoll-Paque solution for separation. T lymphocytes were labeled with monoclonal antibodies as follows: antibodies anti-CD3 for label T lymphocytes, antibodies anti-CD4 for T helper lymphocytes, antibodies anti-CD8 for cytotoxic T cells, antibodies anti-CD45RO for differentiating between memory and naive T cells, antibodies anti-CD28 for differentiating between memory and effector T lymphocytes, and antibodies anti-CD25 for label the eventual activate subset of T cells from subpopulation Treg - regulatory T cells. This labeling served in determining the lymphocytes T profile in experimental and control groups. For assessment of T cells subpopulation flow cytometer FACScan (Becton Dickinson, USA) was used. For data acquisition and analysis, Cell Quest and Win MDI2.9 softwares were used.

Skin grafts transplant. Transplantation of the full-thickness xenogenic skin grafts (from donor birds) and split-thickness skin grafts (from donor dogs) was made at the age of four weeks of recipient birds and surgical procedure followed the principles suggested by others (1, 2, 4): sampling of the skin free-flaps from the donor birds, removal of the subcutaneous connective tissue, segmentation of each free-flaps in five 1.5x1.5cm skin grafts, preparation of recipient bed – surgical wound, and fixation of the skin grafts at the sides of the wound. The full-thickness skin free-flaps were taken from the donor birds under neuroleptanalgesia (xylazine 2mg/kg and ketamine 10mg/kg), from axillary region. The split-thickness skin grafts were taken from the donor dogs under narconeuroleptanalgesia (acepromazine 0.2 mg/kg, ketamine 10 mg/kg, and halothane), from the medial aspect of the thigh. The acceptor bed for skin grafts was represented by surgical wounds created in the axillary region. This election place, both for donor and recipient birds, was preferred because the region presents few feather follicles and the low degree of covering allowed feathers removal without hurting the skin too much.

Clinical monitoring. The subjects were examined daily, paying attention to the 21 macroscopic characteristics of the skin grafts among the most important being: color, aspect and adherence of the grafts to the recipient bed, as well as the aspect of the sides of the wound, making different measurements and taking pictures. Clinical examination allowed the timing of rejection.

RESULTS AND DISCUSSION

As shown in Table 2, inoculation of skin cells yielded similar results in concordant and discordant xenogeneic combinations. Embryonic mortality was associated to allantoidal vessels' obliteration or lack visible gross lesions (in case of *in ovo* inoculation). It was considered that mortality in the first two days after inoculation is the result of technical errors and was estimated at 1-2% for *in ovo* inoculation, respectively 16.66-20% for inoculation allantoidal vessels. Compatibility test performed on mixed lymphocyte cultures revealed 100% incompatibility between donor dogs and donor ducks and the recipient birds evaluated, from both experimental and control groups. In both types of cultures following analysis by flow cytometry of lymphocytes marked PKH2/PKH26 (FL1/FL2), T cell proliferation of recipient birds and lysis donor cells was observed (fig. 2). Differences between cultures from experimental and control groups did not have statistical significance.

Table 2

Results obtained after inoculation of epidermal and dermal cells suspension in chicken embryos

	Method of inoculation	Embrionary mortality	Donor-recipient compatibility	Lymphocyte profile	Day of skin grafts' rejection
Concordant combination (duck-poultry)	in allantoidal vessels (9th ID)	86.67% (4 viable birds in **E1 group**)	100% incompatibility	dominated by naïve T cells, similar to control group	4 ± 1
	in ovo (5th ID)	76.67% (7 viable birds in **E2 group**)	100% incompatibility	dominated by naïve T cells, similar to control group	3.77 ± 0,97
Discordant ombination (dog-poultry)	in allantoidal vessels	90% (3 viable birds in **E3 group**)	100% incompatibility	dominated by naïve T cells, similar to control group	4 ± 0.81
	in ovo	70% (9 viable birds in **E4 group**)	100% incompatibility	dominated by naïve T cells, similar to control group	3.85 ± 0.69

Legend: ID = incubation day

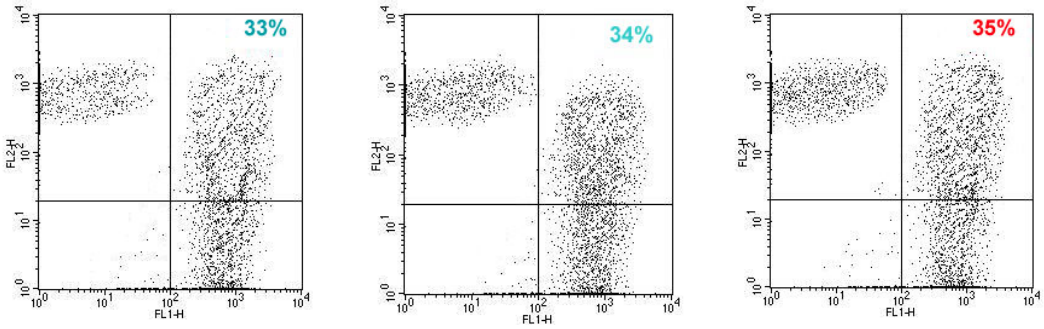

a b c

Fig. 2. Proliferative and lytic responses in mixed lymphocyte cultures: a – E1 group; b - E2 group; c – control group

After lymphocyte profile analysis using flow cytometry, the lymphocytes subsets were defined as follows: naive $CD4^+$ helper T cells with phenotype $CD3^+CD4^+CD45RO^-CD28^+$; memory $CD4^+$ helper T cells with phenotype $CD3^+CD4^+CD45RO^+CD28^+$; effector $CD4^+$ helper T cells with phenotype $CD3^+CD4^+CD45RO^+CD28^-$; effector $CD4^+$ helper T cells with phenotype $CD3^+CD4^+CD45RO^-CD28^-$; naive $CD8^+$ cytotoxic T cells with phenotype $CD3^+CD8^+CD45RO^-CD28^+$; memory $CD8^+$ cytotoxic T cells with phenotype $CD3^+CD8^+CD45RO^+CD28^+$; effector $CD8^+$ cytotoxic T cells with phenotype $CD3^+CD8^+CD45RO^+CD28^-$; effector $CD8^+$ cytotoxic T cells with phenotype $CD3^+CD8^+CD45RO^-CD28^-$; regulatory T cells with phenotype $CD3^+CD4^+CD25^+$; and regulatory T cells with phenotype $CD3^+CD8^+CD25^+$. Naive T cells were represented in a superior proportion in all the individuals of the experimental (E1 - 63.32 ± 7.59%; E2 - 64.16 ± 8.12%; E3 - 63.43 ± 8.25%; and E4 - 63.28 ± 7.91%) and control groups (C1 - 61.55 ± 7.14%; C2 - 63.57 ± 7.65%; C3 - 62.86 ± 7.24%; and C4 - 63.12 ± 8.42%), the differences being statistically insignificant. Xenografts' rejection occurred in approximately four days after transplant (Table 2, Fig.), this moment being registered in both experimental and control groups. Unfavorable clinical evolution of the concordant and discordant xenografts confirmed results of the paraclinical exams.

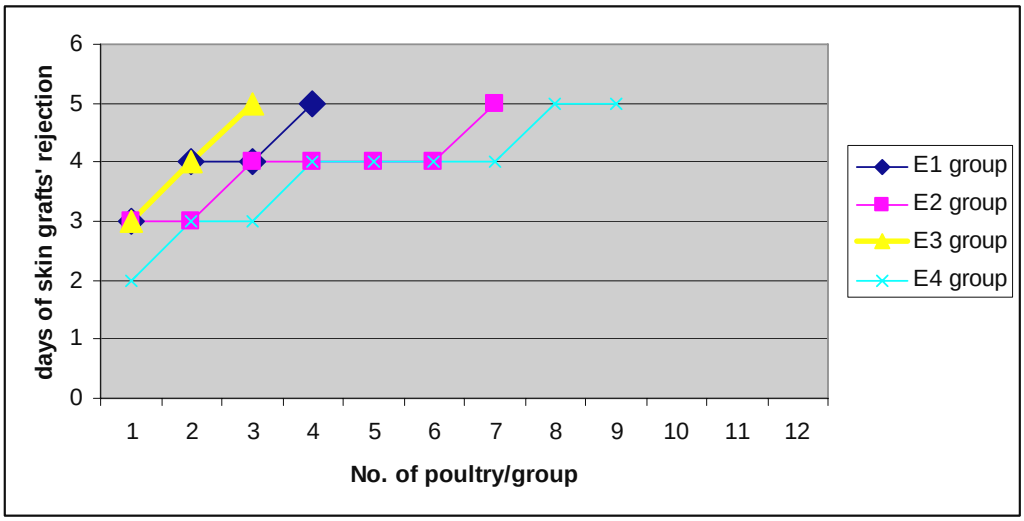

Fig. 1. Post-surgery days of skin grafts' rejection

The two conditions in inducing a state of immunological tolerance are *initiation*, by exposing the body to antigens, and *providing persistence*, by continued presence of the antigens (8, 10).

The applied inoculation methods have provided the first condition, making contact recipient organisms with antigenic information of the donors as late as the ninth day of hatching and early, within certain immaturity of the immune system. The second condition, ensuring the persistence

of antigenic information is deemed to have been met by the lifetime of epidermal cells – 15-30 days (4). Our previous attempts with other types of antigenic material (9) confirmed that the existence of tissue-specific antigens creates the possibility that tolerance induced by one cell type belonging to donor is not equals with systemic immunotolerance, to its entire cells. In this respect may be referred to rejection of the skin grafts in mice in spite of obtaining a stable chimeras previously induced by hematopoietic cell transplantation (3). Thus, due to negative clinical results obtained with other types of antigenic material, was applied the inoculation of epidermal and dermal cells suspension obtained by mechanical separation. This method of cells isolation has the advantage that it excludes any chemical factors (e.g., trypsin) which may influence cells' viability and antigenic structure. However, achieving sustainable mixed chimeras implies that xenogeneic cells to reach maturation sites of recipient immune cells (in this case, the thymus) and to assist their process of maturation and differentiation (8). Thus, recipient lymphocytes will not respond to xenoantigens who came into contact with during development, become tolerant to them. Because skin cells doesn't belong to lymphoid line, it is likely that they have not been attracted in embryonic thymus (inoperant chemoattraction) and therefore were not "witnesses" to the maturation and differentiation of recipient T lymphocytes, effector cells in the grafts' rejection. This could explain the absence of significant differences between experimental and control group.

CONCLUSIONS

Epidermal and dermal cells suspension, because of its adverse effects on embryos and embryonic annexes, is not a suitable antigenic material for immunotolerance induction in poultry.

ACKNOWLEDGMENTS

This work was supported by CNCSIS, Bd grant No. 89/2008 obtained by Monica Şereş.

REFERENCES

1. **Dunn, R.** – Graft and Flaps, Surgery, 2006, 24(1):27-32.
2. **Ferrell, S.T.** – Avian Integumentary Surgery, Seminars in Avian and Exotic Pet Medicine, 2002, 11(3): 125-135.
3. **Ildstad, T. Suzanne, Wren, S.M., Bluestone, J.A., Barbieri, S.A., Sachs, D.H.** – Characterization of mixed allogeneic chimeras. Immunocompetence, *in vitro* reactivity, and genetic specificity of tolerance, J. Exp. Med., 1985, 162:231-244.
4. **Junqueira, L.C., Carneiro, J.** – Basic Histology. Text & Atlas,
5. **Sachs, D.H. –** Xenotransplantation-challenge and opportunity, Xenotransplant, 1994, 1:1-2.
6. **Sachs, D.H., Sykes, Megan, Yamada, K.** – Achieving tolerance in pig-to-primate xenotransplantation: Reality or fantasy, Transplant immunology, 2009, 21(2):101-105.
7. **Swaim, S.F.** – Skin grafts, In: Text Book of Small Animal Surgery, ed. Slatter D, vol. I, 3rd edition, W.B. Saunders Company, Philadelphia, 2003.
8. **Sykes, Megan, Wood, Katrin, Sachs, D.H.** – Transplantation Immunology, In: Fundamental immunology, 6th edition, (eds.) **Paul, E.W.**, Lippincot Williams&Wilkins Press, Philadepphia, 2008, pp. 1427-1478.
9. **Tîrziu, E., Şereş, Monica, Cioca, D., Cumpănăşoiu, C.** - Compatibility assessment in xenotransplant after attempt of immunotolerance induction in embrionary stage, Scientific Works, C series, FMV Bucureşti, 2009, vol. LV(3).
10. **Vior, C., Tîrziu, E., Răducănescu, H., Trif, R.** – Imunopatologie, Ed. Brumar, Timişoara, 2005, pp. 167-207.
11. ***Medimachine brochure** – http://www.bdbiosciences.com.

NEW AND IMPROVED OSTEOSYNTHESIS TECHNIQUES USED IN FOREARM FRACTURE

V. ȘINDILAR E, V. VULPE, S. PAȘCA, S. GRĂMADĂ

University of Agricultural Sciences and Veterinary Medicine Iași
Faculty of Veterinary Medicine
esindilar@yahoo.com

ABSTRACT

All types of fractures encountered involve the breaking of either one or both of the radius and ulna. The research was conducted on 24 animals with fractures in the forearm and was aimed at improving current techniques of osteosynthesis in forearm fractures using centromedullary pins. Our research highlighted the following conclusions: Radius fracture is not easily fixed with an centromedullary pin, unlike other long bones because it is relatively straight and covered at both ends in articular cartilage and the medullary canal is flattened craniocaudal; If a centromedullary pin is used, it must be inserted proximal of the articular surface and its diameter must be small in order to be cut and bent and enter the medullary canal; Ulnar centromedullary pin is used as an addition for fixing a fracture that involve both bones; In some types of fractures fixed by this method the bones may not align perfectly as when using compression plates; After a few days after surgery animals may use the member and the risk of failure and complications of surgery are minimal if the times and directions are met.

Keywords: osteosynthesis, centromedullary pin, radius, ulna

The surgical treatment of fractures can occur continuously refining the techniques and principles of application. The method used in veterinary orthopedic forearm fracture is the use of compression plates with screws. There have been attempts over time to use the radius fracture fixation method centromedullary, but the success of this technique was limited due to postoperative complications. The high cost of compression plates greatly limits their customary veterinary medicine. In these circumstances we considered it appropriate to initiate and re-use the centromedular brooch in the radius fracture.

MATERIALS AND METHODS

The research was conducted on 24 animals, dogs and cats of various breeds and sizes. Animal age ranged between 6 months and 8 years. (Table no. 1)

Tabel nr. 1

Species	Age (yeas)			Talia			Total
	0.5-1.5	1.5-3	3-8	small	medium	large	
Cat	3	3	2	-			8
Dog	4	7	5	8	5	3	16

Surgeries were performed under neuroleptanalgesia (NLA). Preparations were general operators and local and included the usual steps in surgery on the limbs. Instrumentation and materials used are those commonly used in orthopedic surgery and special interventions. Selecting the method of surgical treatment of fractures and metaphysar diaphysis of the radius and ulna is dependent on

animal age and type of fracture. Contention was on the side and the place of choice in the dorso-lateral region of the forearm. Surgical Technique Skin and fascia incision were made on the axis of the limb. Periosteal proceeded to take off, isolation and fracture reduction. Radius is not easily fixed with intramedullary pin, unlike other long bones, because it is slightly curved and covered the two articular ends with cartilage and the medullary canal narrows at the cranio-caudal shaft. If you use centromedullar stitch, it should be inserted from the medial articular surface and the diameter must be adequate to be able to bend and enter the medullary canal. Can insert the pin cranially but this must be done proximal to the distal radius articular surface to avoid trauma of the carpo-metacarpal joint. Using ulnar intramedullary pin is generally an auxiliary support in forearm fractures.

RESULTS AND DISCUSSION

Centromedullar pivotal technique used in such fractures may not perfectly align the broken ends as the method of compression plates. I noticed that in most cases the animals resumed their support of the member broke after 2-5 days. Limping disappeared in about 8-14 days. Operated limb functional recovery was not long and therefore no such complications occurred as muscular atrophy. Another aspect that must be taken into account is that the sharpening broaches be well implanted in the proximal radius. In literature the use of a pivotal centromedullar forearm fracture was described as a method used due to faulty and unworthy of periarticular approach.

Postoperative recovery period required is shown in Table 2.

Tabel nr. 2

Species	Size	Limb use (days)	Limping disappearance (days)
Cat	-	2-3	8
Dog	Small	2-3	10-14
	Medium	2-3	10-14
	Large	3-5	10-14

CONCLUSIONS

- The method can be used in forearm fractures in dogs an small and medium size dogs.
- Correct determinations of the size and length af the brooche as well as it's insertion place is the first step in planning the surgery protocol.
- The brooche used will be inserted either proximal to the articular syrface either from a side, in order to minimize articular damage
- Ulnar centromedular brooche is used as an auxiliar in fractures that affect ulna as well.
- In some cases, this method will not allow a perfect alignement of the bone ends
- This new technique allowed us to see that small and medium sized animals restarted to use the limb the next day after the surgery.
- Complication risks are minimal if every operatory and postoperatory step is respected.
- The short recovery period prevented complications, such as muscular atrophy.

BIBLIOGRAPHY

1. Brinker O.W., Piermattei L.D. , Flo L.G.- Small Animal Orthopedics and Fracture Repair, fourth edition, Ed. Saunders - Elsevier, p.359-381, 2006.
2. Evans E. H., de Lahunta A., Miller M. E.,- Guide to the Dissection of the Dog , Ed. W. B. Saunders, 5-th edition, 2000.
3. Fossum T. W., Small Animal Surgery, second editon, Ed. Mosby, p. 797-904, 2002.
4. Piermattei L.D., Johnson K. A., - An atlas of surgical approaches to the bone and joints of the dog and cat, fourth edition, Ed. Saunders, 2004.

RESTORATIVE MODERN MATERIALS USED IN VETERINARY DENTAL MEDICINE

V.ȘINDILAR E, S. GRĂMADĂ

University of Agricultural Sciences and Veterinary Medicine Iași
Faculty of Veterinary Medicine
esindilar@yahoo.com

ABSTRACT

Due to the evolution of the past few years in the veterinary dentistry it was noted that pets too suffer from dental lesions, which can be treated with coronary morphological integrity restoration tehniques. Under the influence of various factors the dental crowns suffer volumetric changes.Coronary lesions are frequently caused by fractures and caries. Restoration of these lesions is possible through the use of products marketed as restorative materials. Classic materials used in fillings are the unsightly materials: amalgams of silver and copper, and esthetic materials: silicate cement. The creation of new materials, called composite was a necessity both in human and veterinary dentistry. These materials are mixtures of two or more components whose properties complement each other, resulting in a material with superior properties. The base component of the composite materials is called matrix or continuous phase in which the reinforcement component, the discontinuous phase is dispersed in the form of particles or fibers. In using these materials for certain types of dental fractures and open occlusal caries we noticed a high physical and chemical resistance, medium mechanical wear resistance, high color stability and nonaggressive biological reaction towards the dental pulp.

Key words: dentistry, restorative materials, composite, caries

The veterinary dentistry is a newly approached field in Romania. The vetenarian practitioner has a deficiency in this new area of research and practice. In this paper we studied the practical implications of composite biomaterials that might be used in the morphological restoration of the dental crown.

MATERIALS AND METHOD

The study was performed on 6 dogs with lesions of the enamel and dentine. After clinical diagnosis set by traditional methods, corroborated with special methods with revealing substances, we carried on with the morphological reconstruction treatment with a composite hybrid material.
Surgical stages
The animals were under neuroleptanesthesia (NLA). By removing the affected enamel and dentine tissues we obtained an excavation of variable size and dept, depending of the anatomo-clinical shape of the destructive precess. This excavation represents an open wound which must be restored with new generation biomaterials, leading to the morphological reconstruction of the tooth.
Depending on the location of the lesion, there are five types of cavities:

- 1st class cavities rezulting from the lesions of the occlusal grooves and cusps of premolars and molars;

- 2nd class cavities rezulting from the treatment of the interproximal sides of premolars and molars;
- 3rd class cavities rezulting from the treatment of the interproximal sides of the frontal teeth intact incisal angle;
- 4th class cavities rezulting from the treatment of the interproximal sides of the frontal teeth damaged incisal angle;
- 5th class cavities rezulting from the treatment of the cervical surface lesions.

During the preparation of the cavities we went throgh the following stages:
- the opening and widening of the process;
- excision of the damaged enamel and dentine;
- preventive extension
- retention of the cavity;
- control of the cavity walls resistance;
- finishing the enamel angles.

The opening of the cavity represents the approach path and allows the evaluation of the lesion.
We continued with the excision of the altered tissues until the appearance of healthy tissue, fundamental rule in the treatment of simple dental lesions. The excision was done with special rotative instruments. In the preventive extension stage we continued the excision to prevent the repalse. In frontal teeth were the thickness is small this stage is skipped. The newly created cavity must have a shape that allowes the stability and resistance of the reconstruction material. The finishing of the enamel angles has the purpose of making the edges resistent to the masticatory forces and a better transition to the composite material. The treatment of the dentinary wound depends of the depth of the lesions, and it is obtained using calcium hydroxide products. After the cleaning, desinfection and drying of the cavities, we carried on with the demineralisation of the enamel (30 sec) and dentine (15 sec) with a buffed phosphoric adic. Next the acid is removed with water, the cavity is dried and an adhesive agent is applied to increase the adhesion of the composite material. The composite is a paste that we applied in layers of 2mm to obtain a low contraction and expansion coefficient. After the thoroughly preparation of the composite surface, we polymerized it with a blue light of 460-470 nm wavelengh for 40 sec.

RESULTS AND DISCUSSION

We restored the dental morphology of the tooth to reestablish the function, to prevent the spread of the lesions and to redress the aesthetic aspect. The materials used proved to be resistent, rigid and with a good viscosity. Modern composite materials are mixture of resins and aditional particles. The materials we used had coloid particles of silica dioxide, 0,04 mm in size. The easiest to use was the hybrid composite. The thickness of the layers must be aproximately 2mm because the photopolymerisation is activated by a amine-ketone-blue light complex, the light penetrates the material approximately 2-3 mm. The composite materials have different pigments and stabilisation agents so that the color of the material is similar with the color of the tooth. The material made a solid bond with the enamel and dentine.

CONCLUSIONS

After the analysis of the data from this study we concluded that:

► We tried and proved that theese types of new biomaterials, composit resins and glass ionomers, can be successfully be used to restore the coronary morphology, in all types of cavities.

► At the 7 and 30 days recheck we found very good material adhesion.

Advantages

► Because of the nature of the materials (solid, semisolid) the application of the material is relatively easy.

► We found no evidence to support the hypothesis that theese materials have negative effects on the test subjects.

► The temperature inside the composite mass reached 40^0C, measured with a digital termometer, and it is not affecting the dental pulp.

► The finishing was done with diamond cutters and discs covered with aluminium oxide.

Disadvantages

► It is difficult to obtain perfect contact points with the artificial cavity

► The materials have a small coefficient of shrinkage during polymerisation

► The polymerisation depth is limited, creating problems with deep cavities.

► The cost of theese materials is high, increasing the cost of the intervention.

BIBLIOGRAPHY

1. Bellows J. , Small animal dental equipment, materials and techniques, first edition, Ed. Blackwell, 2004.
2. Gorel Cecilia, Veterinary dentistry for the general practitioner, Ed. Saunders, 2004.
3. Holmstrom S. E., Frost P., Eisner E. R., Veterinary Dental Techniques for the Small Animal Practitioner, 3-th edition, Ed. Saunders, 2004.
4. Rândaşu I., Rândaşu O. V., Materiale dentare, Ed. Medicală, 2001.

AGE-DEPENDENT EFFECTS OF CERTAIN VEGETAL EXTRACTS ON THE INNATE CELL-MEDIATED IMMUNITY IN CHICKENS

Marina SPINU, Carmen SANDRU, Gh.F. Brudaşcă, Mihaela NICULAE, D. CADAR, Krisztina RINDT, Timea KISS, Armela BORDEANU, Florina-Alexandra KRUPACI, Silvana POPESCU, R. ŞTEFAN

University of Agricultural Sciences and Veterinary Medicine, Str. Manastur No.3-5, Cluj-Napoca, marina.spinu@gmail.com

ABSTRACT

Vegetal extracts from various sources are more and more often used, showing favorable influence in diminishing the negative impact of numerous agents or in increasing the non-specific or specific resistance of the body to infections. The investigations were carried out on 47 days old chickens (n=28) and 70 weeks old hens (n=28), administering vegetal extracts by injection route, in order to monitor their effect on innate cell-mediated immunity. Both chickens and hens were distributed in 4 batches, each of 7 individuals. The birds were treated with alcoholic extracts of Calendula officinalis (batch I) and Echinacea angustifolia (batch II), administered subcutaneously, in the axila region, according to the following protocol: batch I – the alcoholic Calendula officinalis flower extract was administered for 7 days, 0.5 ml/bird/day; batch II – the alcoholic Echinaceea angustifolia flowers extract was administered for 7 days, 0.5 ml/bird/day; batch III – the birds were subjected to 0.5 ml of 70° alcohol treatment, by the same route, for the same duration as in the previous batches, this was the solvent control; batch IV –0.5 ml of saline/day/bird, for 7 days; this batch represented the control for environmental influences, manipulation and administration stresses. Antigen priming was used in both groups of birds, with a 5% SRBC suspension in chickens and the Newcastle vaccine in hens, twice, on the first and 7th day of the experiment. Blood was sampled three times one week apart and subjected to an in vitro carbon particle inclusion test. The phagocytosis was maximal in the first batch, treated with the Calendula extract. Although reduced when compared to the second sampling, the influence of Echinacea extract is less intense than that of the Calendula extract. In injected, immunogically mature birds, the effects of the Echinacea extract were seen in long term, while those of Calendula were more rapid, but also dissapeared fast. There was no statistical significance of the differences between the treatment variants but the statistical significance between the corresponding batches ranged between $p<0.05$ and $p<0.01$ in favor of the younger birds.

Key words: chickens, age, vegetal extracts, phagocytosis, in vivo treatment

Numerous researches have investigated the response of chickens to immunization against a variety of antigens, with results showing differentiated humoral and T cell responses in birds of different ages. As the avian lymphocyte repertoires do not fully mature until a number of weeks after hatching, it is likely that other cells of the immune system do not reach maturity until a later date and may contribute to the different responses seen in younger birds (Gaunson et al., 2006).

Current trends in medicine tend to include natural products in therapy, without mixing allopathic and homeopathic treatments. Natural products gain more and more in comparison with chemically obtained ones. Within this framework, researches on the immune stimulating activities of vegetal extracts were successful, with obvious immune modulating effects. Vegetal extracts from various sources are more and more often used, showing favorable influence in diminishing the negative impact of numerous agents or in increasing the non-specific or specific resistance of

the body to infections (Dewick, 1997; Matthews et al., 1999). Moreover, active principles of plants serve to partially restore the immune reactivity in individuals with innate immune suppression (Bauer, 2002). The vast domain of infectious diseases' is being governed at present by the prophylaxis of the nosological entity. Prevention also involves protection following vaccination and obtaining vaccines that generate maximal antibody synthesis is a primary orientation in this field. Still, age remains a defining factor in obtaining an appropriate immunological, both cell- and antibody mediated response, due to the gradual maturation of the immune system.

In improving the immunogenic capacity of the vaccines, an important step was done by the use of adjuvants. Knowledge of the immunological mechanisms allowed defining the "adjuvant" term, as well as the understanding of various ways these compounds act to augment the immune response of the host. Thus, the perspective of active immunization encounters nowadays two main developmental directions: obtaining new antigenic units and discovering compounds with increased adjuvant efficacy and minimal side effects (Hilton et al., 2002).

A less investigated field of the vegetal extracts' use, but one with exquisite practical perspectives, is that of identification of novel adjuvants for vaccines, a stage considered to be essential in the development of modern vaccines (Vogel, 2000; Kaufman et al., 1999). Total vegetal extracts or extractive components from various plants could show such qualities.

The *adjuvant effects in therapy* exerted by reputed medicinal plants were studied in complex experiments. These studies were connected especially to the investigation of anti-inflammatory activities (Chemli et al., 1990), changes in total leukocyte (Wagner and Jurcic, 2002) and macrophage numbers and populations (Percival, 2000), micro- and macrophage respiratory burst (Dugenci et al., 2003). Other experiments aimed to establish the action mode of fractions isolated from these plants: super antigen qualities that induce clonal selection of T lymphocytes (Saul et al., 2000), mitogenic activity for the same lymphocytes (Galelli and Truffa-Bachi, 1993), interleukine synthesis (Le Moal and Truffa-Bachi, 1992). All these separate results offered, along with difficulties in interpretation, an incomplete overall picture of the stimulating activities of the investigated vegetal extracts.

The general purpose of the research was to complete the establishment of the role played by *Calendula officinalis* and *Echinacea angustifolia* extracts, containing mainly carotenoids, on phagocytosis, as an innate, cell-mediated immune response, depending on age of the treated birds.

MATERIALS AND METHODS

The investigations were carried out on 47 days old chickens (n=28) and 70 weeks old hens (n=28), administering vegetal extracts by injection route, in order to monitor their effect on innate cell-mediated immunity. Both chickens and hens were distributed in 4 batches, each of 7 individuals. The birds were treated from day 0, for 7 days, with alcoholic extracts of *Calendula officinalis* (batch I) and *Echinacea angustifolia* (batch II), administered subcutaneously, in the axilla region, according to the following protocol: batch I – 0.5 ml/bird/day of the alcoholic *Calendula officinalis* flower extract; batch II – 0.5 ml/bird/day of the alcoholic *Echinaceea angustifolia* flower extract; batch III – the birds were subjected to 0.5 ml of 70° alcohol treatment, by the same route, for the same duration as in the previous batches; this was the solvent control; batch IV – 0.5 ml of saline/day/bird, for 7 days; this batch represented the control for environmental influences, manipulation and administration stresses. Antigen priming was used in both groups of birds, with a 5% SRBC suspension in chickens and the Newcastle vaccine in hens, twice, on the first and 7th day of the experiment. Blood was sampled three times, one week apart. Blood samples were taken three times, one week apart, on days 0, 7 and 14 of the experiment.

An *in vitro* carbon clearance assay (Spinu and Degen, 1993) was used to evaluate phagocytic activity in the experimental batches. 1.5 ml of venous blood was collected on heparine (50 IU/ml). The blood sample received 6 µl of the supernatant fraction of India ink (Pelikan AG D-3000, Hanover, Germany) that had been centrifuged at 3000 *g* for 30 min. After mixing, each sample was divided into 3 equal aliquots which were incubated at 37°C for various, for 0, 15 and 30 min. Volumes of 150 µl of each blood and India ink mixture from each aliquot were added to 2 ml saline following incubation. These diluted samples were centrifuged at 50 *g* for 4 min and the supernatant was read spectrophotometrically at 535 nm, with the background taken as zero. There was a decrease in absorbency with time as carbon was phagocytosed. Optical density readings were converted to a log2 scale and phagocytic index was taken as the negative of the slope of the regression of optical density (log2) on time (h). Mean values and standard deviations were calculated. Student's t test was used to evaluate the statistical significance of the differences.

RESULTS AND DISCUSSION

The immune system of birds offers an attractive model for studying adjuvant activities of conventional or modern compound (Davison, 2003). The involvement of ontogenesis in eliciting an immune response is recognized in birds. Based on experimental data, a relationship that exists between the age of the chick, the functional activity of the heterophil, and the susceptibility to organ invasion by *Salmonella* was proved (Wells et al., 1998).but there is no exact data on the age differences on the simultaneous administration of a thymus dependent antigen and potentially immune stimulating/ modulating (adjuvant) vegetal extracts in these species. Various ways of antigen presentation to the cells of the immune system, depending on the administration route were already mentioned. A less investigated field of the vegetal extracts' use, but one with exquisite practical perspectives, is that of identification of novel adjuvants for vaccines, a stage considered to be essential in the development of modern vaccines (Vogel, 2000; Kaufman et al., 1999). Total vegetal extracts or extractive components from various plants could show such qualities. The *Calendula officinalis* and *Echinacea angustifolia* extracts, accompanied by thymus dependent antigens, sheep red blood cells (SRBC) or Newcastle disease vaccine, to elicit adaptive immune responses, were monitored for their adjuvant capabilities, on the injection route, with the recording of the innate cell mediated activity expressed by phagocytosis. The results obtained by monitoring the *in vitro* inclusion of carbon particles were shown in tables 1 and 2. The values encountered for the first sampling, prior to any treatment, were considered as reference for each age category. In 47 day old chickens (table 1), phagocytosis was higher at the second sampling in all batches, but the *Calendula* extract had a slightly stronger positive influence than the *Echinacea* one. Higher values obtained for the groups subjected to vegetal extract treatments, indicated the positive role of the active principles on phagocytosis, when compared to alcohol and environment controls. The persistently higher values at the third sampling could be rather attributed to the second antigen priming than to the long lasting effects of the extraction treatment. Still, it could be observed that the *Echinacea* extract's effect lasted longer than that of *Calendula officinalis* one.

Tabel 1

Phagocytosis over time in 47 days old chickens for the three samplings (x±s)

Sampling I				Sampling II				Sampling III			
Batch I	Batch II	Batch III	Batch IV	Batch I	Batch II	Batch III	Batch IV	Batch I	Batch II	Batch III	Batch IV
Ln0-ln30	Ln0-ln30	Ln0-ln30	Ln0-ln30	Ln0-ln30	Ln0-ln30	Ln0-ln30	Ln0-ln30	Ln0-ln30	Ln0-ln30	Ln0-ln30	Ln0-ln30
0.70± 1.87	0.11± 0.97	0.89± 0.74	0.63± 0.12	1.86± 1.67	1.73± 1.47	1.52± 0.04	1.38± 0.67	1.13± 0.67	1.37± 0.80	1.45± -0.08	1.28± -0.26

Legend: ln0'-ln30'/t1 – phagocytosis for the monitored interval

In hens (table 2), the phagocytosis did not differ significantly from that of corresponding chicken batches at the beginning of the experiment, but, as opposed to the 47 days old chickens, only the *Calendula* extract acted stimulating ($p<0.05$), when compared to the *Echinacea* one, that exerted an inhibiting effect by the second sampling. Phagocytosis decreased over time towards the third sampling, in spite of the antigen priming of the birds.

Tabel 2

Phagocytosis over time in hens for the three samplings (x±s)

Sampling I				Sampling II				Sampling III			
Batch I	Batch II	Batch III	Batch IV	Batch I	Batch II	Batch III	Batch IV	Batch I	Batch II	Batch III	Batch IV
Ln0-ln30	Ln0-ln30	Ln0-ln30	Ln0-ln30	Ln0-ln30	Ln0-ln30	Ln0-ln30	Ln0-ln30	Ln0-ln30	Ln0-ln30	Ln0-ln30	Ln0-ln30
0.52± 0.97	0.51± 1.14	0.44± 0.10	0.46± 0.23	1.03± 1.72	0.20± 0.1	0.69± 0.41	0.44± 0.14	0.30± 0.69	0.19± 0.54	0.20± 0.87	0.10± 0.05

Legend: ln0'-ln30'/t1 – phagocytosis for the monitored interval

Although the differences were not significant between the two extracts at the third sampling in this group, there was a longer lasting effect of the *Calendula officinalis* treatment ($p<0.05$, sampling II versus III) than of the *Echinacea angustifolia* one. There was no statistical significance of the differences between the treatments combined with the priming at the third sampling in hens, indicating a diminished reactivity of those at age of 70 weeks to the antigen priming and vegetal extract treatment.Both at the second and third samplings, phagocytosis significantly differed in 47 days old chickens as opposed to 70 weeks old hens ($p<0.05$ - $p<0.01$). The most important increase in phagocytosis was induced by the combined vegetal extract treatment and antigen priming at the second sampling in younger birds, providing the evidence of the importance of age in responsiveness to antigenic stimulation associated with potential adjuvant agents.

CONCLUSIONS

1. Phagocytosis over time was significantly influenced by the age of the subjects (47 days versus 70 weeks), that proved to be a more important factor than antigen priming.
2. Active principles of *Calendula officinalis*, proved to be more stimulating, but with a short-lived effect when compared to those of *Echinacea angustifolia* in chickens.

REFERENCES

1. Bauer R. – 2002 - New knowledge regarding the effect and effectiveness of Echinacea purpurea extracts]Wien Med Wochenschr.;152(15-16):407-11.
2. Chemli R., Toumi A., Oueslati S., Zouaghi H., Boukef K., Balansard G. – 1990 - Calendula arvensis L. Impact of saponins on toxicity, hemolytic effect, and anti-inflammatory activity, J Pharm Belg.;45(1):12-6
3. Davison TF. – 2003 - The immunologists' debt to the chicken. Br Poult Sci.;44(1):6-21
4. Dewick P.M. - 1997- Medicinal Natural Products. John Wiley & Sons, West Sussex, UK
5. Dugenci S.K., Arda N, Candan A. – 2003 - Some medicinal plants as immunostimulant for fish. J Ethnopharmacol.;88(1):99-106.
6. Galelli A., Truffa-Bachi P. - 1993 -Urtica dioica agglutinin. A superantigenic lectin from stinging nettle rhizome. J Immunol.;151(4):1821-31.
7. Gaunson J.E., C.J. Philip, K.G. Whithear, G.F. Browning (2006) Age related differences in the immune response to vaccination and infection with *Mycoplasma gallisepticum*, Vaccine, 24, 1687–1692
8. Hilton L.S., Bean AG, Lowenthal JW. – 2002 - The emerging role of avian cytokines as immuno-therapeutics and vaccine adjuvants. Vet Immunol Immunopathol;85(3-4):119-28
9. Kaufman J, Salomonsen J. - 1997 - The "minimal essential MHC" revisited: both peptide-binding and cell surface expression level of MHC molecules are polymorphisms selected by pathogens in chickens., Hereditas;127(1-2):67-73
10. Le Moal M.A., Colle J.H., Galelli A., Truffa-Bachi P. – 1992 - Mouse T-lymphocyte activation by Urtica dioica agglutinin. II.-Original pattern of cell activation and cytokine production induced by UDA. Res Immunol.;143(7):701-9.
11. Matthews H.B., Lucier G.W., Fisher K.D. -1999- Medicinal herbs in the United States: research needs. Environ Health Perspect 107: 773–778
12. Percival, S.S. - 2000 - Use of Echinacea in medicine, Biochem Pharmacol., 60:2 155-158.
13. Saul F.A., Rovira P., Boulot G., Damme E.J., Peumans W.J., Truffa-Bachi P., Bentley G.A. – 2000 -Crystal structure of Urtica dioica agglutinin, a superantigen presented by MHC molecules of class I and class II. Structure Fold Des.;8(6):593-603.
14. Spinu, M., Degen, A.A. - 1993 - Effect of cold stress on performance and immune responses of Bedouin and White Leghorn hens. British Poultry Science, 34: 177–185, 1993.
15. Vogel F.R. – 2000 – Improving vaccine performance with adjuvcants; Clinical Infectious Diseases; 30(suppl.3); 266-270.
16. Wagner H., Jurcic K. -2002 - Immunological studies of Revitonil, a phytopharmaceutical containing Echinacea purpurea and Glycyrrhiza glabra root extract. Phytomedicine;9 (5):390-7.
17. Wells L. L., Virginia Lowry, J.R. Deloach, M.H. Kogut -1998- Age-dependent phagocytosis and bactericidal activities of the chicken heterophil, Developmental & Comparative Immunology 22, 1, 103-109

VEGETAL EXTRACTS INTERACT WITH PHYSIOLOGICAL CELL-MEDIATED IMMUNE ACTIVITY IN FARMED HERBIVORES

Marina SPINU, Carmen SANDRU, Gh.F. Brudaşcă, Silvana POPESCU, Mihaela NICULAE, D. CADAR, Krisztina RINDT, Timea KISS, Florina-Alexandra KRUPACI, Armela BORDEANU, R. ŞTEFAN

University of Agricultural Sciences and Veterinary Medicine, Str. Manastur No.3-5, Cluj-Napoca, marina.spinu@gmail.com

ABSTRACT

In vitro carbon clearance and blast transformation assays were performed on randomly selected Romanian Spotted (n=19) dairy cows, Romanian draft horses (n=18), and semi-intensively bred Angora goats (n=9) to monitor the phagocytic activity and specific-cell mediated immunity and the phylogenetic position's influence on these immunological parameters. Phagocytic activity expressed as the negative of the optical density slope over time (ln) was calculated. Vegetal extracts' (Calendula officinalis, Echinacea angustifolia and E. purpurea) effects on the non-specific and specific cell-mediated reactivity was measured by the in vitro whole blood blast transformation test, applied as a micro method. Stimulation/inhibition indices were calculated compared to the glucose concentration of the starting culture medium and expressed as consumption percentages. Student- t test was used to evaluate the statistical significance of the differences of mean values. The results indicated that phagocytosis over time was decreasing in bovine and increasing in horses and goats, probably as a better adaptation to the ex vivo stress. The blast transformation test results showed a higher spontaneous blast transformation index in bovine than in horses or goats, but the mitogenic PHA induced index was higher in the latter two species. All the extracts showed inhibiting effects in bovine and goats, but not in horses, when compared to the spontaneous mitogenic index. To some extent, the active principles of Calendula officinalis, proved to be stimulating when compared to the alcohol solvent control.Cell-mediated, innate or adaptive, immunity was overall poorer in bovine than in goats or horses, better adaptable to a potential microbial aggression. The biological activity of the tested extracts was animal and plant species dependant, Calendula officinalis proving to better stimulate mitogenesis than Echinacea extracts.

Key words: farm herbivores, *in vitro*, phagocytosis, leukocyte blast transformation,vegetal extracts

Vegetal extracts were quoted for centuries as remedies in various diseases. Numerous studies stand for the anti-inflamatory activity of various vegetal extracts. As such, researches on triterpenoids as active compounds from *Calendula officinalis*, suggested a decrease of the inflamatory response. These components inhibited, in a dose-dependent manner, the *Croton* oil induced edema, being six times less active than a purified reference compound (indometacine). Extracts of *Echinaceea angustifolia* (*radix*) exert an anti-inflamatory activity by their contents in polisacharides and alchyl-amidic fraction (Bauer, 2002). Numerous plants, such as *Echinaceea angustifolia*, *Calendula officinalis*, *Viscum album*, *Allium sativum* and others are well known for amticancer activity, based on the stimulation of natural killer cells (NK) and specific direct activity of certain components (Hostettmann, 2003, Wang et all., 2005). Thus, carotenoids, by conversion into retinol, exert a positive effect on differentiation and proliferation as well as on communication between cells. Their anti oxidant activity could prevent the changes induced by free radicals on

cellular DNA and other vital molecules. The immune modulating effects are increased in the control of tumor genesis (Albulescu et all., 1996, Bezanger – Beauquesne, 1993).
Testing the functional capacities of neutrophiles, in correlation with other techniques could lead to positive results in diagnosing immune deficiencies. The integrity of membrane receptors is vital in identifying the cells by use of monoclonal antibodies (Block et al., 2003, Janeway et all, 1999). Not only bacteria or viruses but also inert particles, such as carbon could be engulfed, simplifying an objective interpretation of the phagocytic capacity of circulating cells. Mitogen induced reactivity also represents a measure of adaptive cell-mediated immunity. The *in vitro* responses to various compounds such as phytohaemagglutinin M (PHA M), concanavaline A (Con A) and poke-weed mitogen (PWM), to a certain extent, are sucessful in stimulating T lymphocytes in a dose dependent manner. The whole blood blast transformation test, represents an efficient *in vitro* method to investigate either spontaneous or induced cellular responses and predict the potential reactivity towards the antigens (Herbert, 1991).The present research aimed to investigate the potential *in vitro* immune stimulating activity of several alcoholic vegetal extracts on cell-mediated innate and adaptive immunity in farmed herbivores and estimate their potential use as adjuvants for veterinary vaccines.

MATERIALS AND METHODS

Animals. For the experiment, the animals were selected on random group basis, in several steps. Nineteen Romanian Spotted cows from a, indoor milk farm, the eighteen Romanian draft horses, from private households and 9 adult female Angora goats, descendents of animals imported in 1993 to the country from Southern France, were subjected to blood sampling from the jugular vein for both testing the non-specific and specific cell-mediated responses. The blood was kept at 37°C till testing and processed in maximum 4 h after sampling.
Tests. Specific cell-mediated reactivity was measured by the *in vitro* whole blood blast transformation test, applied as a micromethod (Spinu and Degen, 1993). Blood, sampled on heparin (50 IU/ml) was mixed 1:4 with RPMI 1640, with L-glutamine, 5% fetal calf serum and antibiotics (penicillin 1000 IU/ml, streptomycine 1000 µg/ml), and divided into 0.2 ml aliquots in a 96 well plate. Several variants, for spontaneus blastogenesis and compound induced blastogenesis were used for each animal. PHA M was used as a reference mitogen (1 µl/well), while 70º alcoholic *Calendula officinalis*, *Echinacea angustifolia* and *E. purpurea* extracts, 1.5 µl each/well, were added to the culture medium in order to investigate their mitogenic potential. The alcohol treated cultures served as solvent controls. All variants were performed in duplicate. The covered plates were incubated in a 5% CO_2 atmosphere for 60 hours in horses and 72 hours in bovine and goats. Glucose residues were determined by a colorimetric method (orto-toluidine treatement of the supernatants). Spectrophotometrical readings were done at 610 nm wavelength. Stimulation/ inhibition indices were calculated compared to the glucose concentration of the starting culture medium and expressed as consumption percentages for each variant.
An *in vitro* carbon clearance assay (Spinu and Degen, 1993) was used to evaluate phagocytic activity in the experimental batches. The method was modified from the *in vivo* method described for chickens (Cheng and Lamont, 1988). 1.5 ml of venous blood was collected on heparine (50 IU/ml). The blood sample received 6 µl of the supernatant fraction of India ink (Pelikan AG D-3000, Hanover, Germany) that had been centrifuged at 3000 *g* for 30 min. After mixing, each sample was divided into 3 equal aliquots which were incubated at 37°C for various, but close periods of time, depending on the species: 20 and 50 min in bovine, 45 and 60 min in horses and 20 and 40 min in goats. Volumes of 150 µl of each blood and India ink mixture from each aliquot were added to 2 ml saline following incubation. These diluted samples were centrifuged at 50 *g* for 4 min and the supernatant was read spectrophotometrically at 535 nm, with the background taken as zero.

There was a decrease in absorbency with time as carbon was phagocytosed. Optical density readings were converted to a log2 scale and phagocytic index was taken as the negative of the slope of the regression of optical density (log2) on time (h). Mean values and standard deviations were calculated. Student's t test was used to evaluate the statistical significance of the differences.

RESULTS AND DISCUSSION

In vitro investigations using a mixture rich in polysaccharides of *E. purpureea* herb demonstrated its specific influence on mononuclear cell subsystem. The same mixture stimulated macrophages to synthesize IL-1 but did not induce T cell proliferation (Albulescu, Mihaela et all., 1996, Briskin, 2000)**.** T cell blast transformation under the crude *Echinaceea* extraction could be due to the high nitrogen content of various residues, since the later on purified polysacharides showed little effect (Block, 2003). Defining the immune-physiological profile in farm animals is of extreme importance, when establishing the negative influence of either biotic or non-biotic noxious elements on immunity represents a purpose. A table containing reference values offers the possibility to interpolate the established field readings in a physiological/pathological framework. Several lectins isolated of plants as well as other components were incriminated in stimulating lymphocytes, in humans as well as in animals. Unlike in mice, there is no secure evidence connected to the selective activation of T or B cell activation in humans (Janssen et al., 2000). While mitogens stimulate a wider category of cells, antigens induce *in vitro* blast transformations of cells from animals that previously, in one way or another, contacted that antigen. Lymphocyte activation is a technique frequently used in patients with immune deficiencies, autoimmunity or infectious diseases to monitor the health status (Herbert, 1991). The results obtained in the present research for bovine samples indicated a strong spontaneous response of the cells, while the reactivity towards PHA M was weaker (table 1). In horses, the spontaneous mitogenic index was lower than in bovine. Blast transformation indices recorded in goats were the lowest of all tested species.

Tabel 1

Blast transformation indices after treatment of the blood samples from bovine with alcoholic *Calendula officinalis* and *Echinacea spp.* extracts (%)

Species	Control	PHA M	Alcohol	*Calendula*	*Echinacea angustifolia*	*Echinacea purpurea*
Bovine	87.6±0.89	76.2±03.19	72.4±4.25	69.9±2.65	74.9±10.1	75.24±8.25
Horses	68.99±10.1	80.37±5.34	80.21±2.37	79.50±6.39	78.88±3.74	77.68±5.93
Goats	60.15±11.3	61.23±11.3	54.65±6.86	58.52±10.1	50.10±11.7	50.79±10.9

Monitoring the global influence of the used extracts in comparison with control cultures (spontaneous, alcohol and classical mitogen), their inhibiting effect becomes obvious, under the experimental circumstances described (table 1). This effect is paradoxical, since numerous studies quote their beneficial influence on other sides of the immune response. The encountered effect could be based on the inappropriate dose, lack of availability of active principles or species induced variability. All the extracts acted inhibiting in ruminants when compared to the alcohol control, standing more for a modulating than for a stimulating effect of the extracted principles. Although there was vegetal species variability as well, the *in vitro* effects of the two *Echinacea* species were different. This suggested the presence of different active principles induced by the vegetal species. The *Calendula officinalis* extraction proved to exert the lowest inhibition of all tested compounds (table 1). When comparing the spontaneous blast transformation indices in the three experimental species, it could be seen that the highest figures were obtained in bovine, while horses and goats followed in this order (table 1). The very high standard deviation, stating the lack of homogenous

character of the two batches of horses and goats respectively, could influence these results. Goats showed the most non-homogenous individual response, indicating a great variability, probably due to their contact to several species of animals and a more close contact to one another within the herd. The variability in goats was the highest in what concerns the mitogen induced response as well. This was just slightly increased when compared to the sontaneous mitogenic index, while in horses there was a significant increase ($p<0.05$). The decrease of mitogenic response in bovine stood for a bad reactivity to potential aggressors and a poorer adaptive response than horses or even goats. Phagocytosis represents one of the basic mechanisms for protection within the innate immunity. Along with neutrophiles, eosinophiles and basophiles, to some extent, other cells such as macrophages, either stable or circulating, intervene (Dejica, 1998). The *in vitro* spontaneous engulfment of carbon particles, due to the incubation temperature and with no additional changes in environmental factors, was monitored. This technique allowed the quantification of the reactive potential of the phagocytic cells versus microbial agression. The results of spontaneous phagocytosis in the thested species were presented in table 2. Spectrophotometrical measurements helped to improve the objectiveness of the reading, a better observation of individual variations of the slopes, disregarding the errors given by haemolisis, variations of the innitial India ink concentrations, etc. Thus, as expected, the phagocytic activity in bovine samples was more intense during the first 20 min of reading, probably due to the lesser period of *ex vivo* stress the cells were subjected to. Gradually, the pagocytosis decreased, due to partially increased stress and a potential distruction of some cells (table 2). In horses, the spontaneous phagocytosis was decreased during the first period (45 min), followed by a subsequent, statistically significant ($p<0.01$) increase. This indicated a difference in species reactivity and a possible adaptation to the stress of phagocytic cells towards the end of the incubation. Goats showed for both reading periods an intermediate tendency of phagocytic activity, when compared to bovine and horses. Therefore, during the first period, (20 min), the phagocytosis over time was lower than in bovine but higher than in horses, while during the second period, it was higher tha in bovine but not as high as in horses. This trend was imposed by the individual variation of the tested parameter, which made the mean variation difficult to interpret. Still, the increasing tendency of the phagocytic activity in goats might indicate a gradual adaptation to the *ex vivo* stress on the cells. The vegetal extracts tested showed effects that varried with the plant. The *Calendula officinalis* extract, stimulating to a certain extent the adaptive cell mediated response, when compared to the alcohol control, inhibited phagocytosis while the *Echinacea angustifolia* extract acted stimulating in all species.

Tabel 2

Spontaneous phagocytic activity in bovine, horses and goats, for the two intervals of reading (ln)

	Bovine		Horses		Goats	
Param.	ln20'-ln0'/t1*	ln50'-ln20'/t2*	ln45'-ln0'/t1*	ln60'-ln45'/t2	ln20'-ln0'/t1	ln40'-ln20'/t2
Mean	0.006 ± 0.005	-0.016 ± 0.012	-0.005 ± -0.001	0.038 ± 0.085	0.0002 ± 0.0005	0.0028 ± -0.0002

Legend: ln0'-ln20'/t1 – phagocytosis for interval T1 in bovine; ln20'-ln50'/t2 – phagocytosis for interval T2in bovine; ln0'-ln45/t1 – phagocytosis for interval T1 in horses; ln45'-ln60'/t2 – phagocytosis for interval T2 in horses; ln0'-ln20'/t1 – phagocytosis for interval T1 in goats; ln20'-ln40'/t2 – phagocytosis for interval T2 in goats.

Monitoring the *in vitro* phagocytosis allowed an estimate of the non-specific cell-mediated reactivity of the immune system in general. Therefore, this should represent the starting point of any discussion on external influences on the immunological reactivity, since the majority of

influential factors originate in the external environment. The environment incorporates a multitude of non-self compounds, of a great variety, from very simple low-weight molecules to complex microbial antigens. Within this framework, phagocytes interpose between the environment and target cells, protecting the last from the negative influences of the aggressors. India ink successfully supplies such aggressors *in vitro* (Goel et al., 2002).

	Control		Alcohol		*Calendula officinalis*		*E. angustifolia*	
	T1	T2	T1	T2	T1	T2	T1	T2
Bovine	0.14± 0.37	-0.42± 0.03	0.07± 0.66	-0.17± 0.03	0.004± 0.29	-0.013± 0.129	0.102± 0.065	0.348± 0.64
Horses	-0.22± 0.06	0.57± 0.12	-0.66± 0.23	0.33± 0.02	-0.41± 0.07	0.20± 0.09	0.08± 0.1	0.1± 0.08
Goats	0.0034± 0.013	0.056± 0.006	0.0953± 0.011	0.001± 0.0008	-0.007± 0.0005	0.0588± 0.035	0.04± 0.032	0.06± 0.005

Legend: ln0'-ln20'/t1 – phagocytosis for interval T1 in bovine; ln20'-ln50'/t2 – phagocytosis for interval T2in bovine; ln0'-ln45/t1 – phagocytosis for interval T1 in horses; ln45'-ln60'/t2 – phagocytosis for interval T2 in horses; ln0'-ln20'/t1 – phagocytosis for interval T1 in goats; ln20'-ln40'/t2 – phagocytosis for interval T2 in goats.

CONCLUSIONS

1. Cell-mediated responses were variable according to the species. Mitogenic stimulation that copied the microbial aggression, induced a weaker response in bovine, than in horses or goats.
2. Cell-mediated immunity was overall poorer in bovine than in goats or horses, better adaptable to a potential microbial aggression.
3. Phagocytosis over time was decreasing in bovine and increasing in horses and goats, probably as a better adaptation to *ex vivo* stress.
4. All the extracts showed inhibiting effects in bovine and goats, but not in horses, at the tested doses, when compared to the spontaneous mitogenic index.
5. Active principles of *Calendula officinalis*, proved to be stimulating when compared to the alcohol solvent induced mitogenesis.
6. The biological activity of the tested extracts was animal and plant species dependant, *Calendula officinalis* proving to better stimulate mitogenesis than *Echinacea* extracts.

REFERENCES

1. Albulescu, Mihaela, Albulescu, R., Gruiță, D. - Studii privind potențialul mutagen al unor extracte vegetale, The First Symposium "Drug research between information and life sciences", Bucharest, 3-4 October, **49**. 1996
2. Bauer R. –New knowledge regarding the effect and effectiveness of Echinacea purpurea extracts]Wien Med Wochenschr.;**152**(15-16):407-11, 2002.
3. Bezanger – Beauquesne, L. – Nouveautes en phytotherapie, Plantes medicinales et phytotherapie, **26** (3), 234- 264, 1993.
4. Block K.I., Mead MN. –Immune system effects of Echinacea, ginseng, and astragalus: a review. Integr Cancer Ther.;**2**(3):247-67, 2003.
5. Briskin D. P.– Medicinal Plants and Phytomedicines. Linking Plant Biochemistry and Physiology to Human Health, Plant Physiology, Vol. **124**, pp. 507–514, 2000.

6. Cheng, S., Lamont, S.J. - Genetic analysis of immunocompetence measures in a White Leghorn chicken line. Poultry Science, **67:** 989–995, 1988.
7. Dejica D. –Tratat de imunologie clinică II, ed. Dacia, Cluj-Napoca, pag. 399-345, 1998.
8. Goel V., Chang C., Slama J.V., Barton R., Bauer R., Gahler R., Basu T.K.- Alkylamides of Echinacea purpurea stimulate alveolar macrophage function in normal rats. Int Immunopharmacol.;**2**(2-3):381-7, 2002.
9. Herbert, W.J. - Veterinary Immunology, Blackwell Scientific Publishers, Oxford, 1991.
10. Hostettmann K. –History of a plant: the example of Echinacea, Forsch Komplementarmed Klass Naturheilkd.;**10** Suppl 1:9-12, 2003.
11. Janeway, C.A., Travers P., Walport M., Capra. J.D. – Immunobiology, 4th ed. Garland Publishing, New York, 1999.
12. Janssen O., Sanzebacher R., Kabelitz D. - Regulation of activation-induced cell death of mature T lymphocyte populations. Cell Tissue Res., 301, 85-99. , 2000
13. Spinu, M., Degen, A.A. Effect of cold stress on performance and immune responses of Bedouin and White Leghorn hens. British Poultry Science, **34:** 177–185, 1993.
14. Wang D., Hu Y., Sun J., Kong X., Zhang B., Liu J. – Comparative study on adjuvanticity of compound Chinese herbal medicinal ingredients, Vaccine **23**(28), 3704–3708, 2005.

FREQUENCY AND ETIOPATHOGENESIS OF HIP DYSPLASIA IN DOGS

R.E. STECYK[1], L.C. BURTAN[2], Ioana BURCOVEANU[2]

[1]Spitalul Veterinar SALVANIM, Iaşi
[2]F.M.V. Iaşi

ABSTRACT

Considering the importance of hip dysplasia evolution on the animal's locomotion, this paper features the frequency of this disease based on breed, age, body weight and environmental factors. The radiographic views at different ages can easily detect hip dysplasia in clinically healthy dogs, with no lameness. Along with joint laxity, we can also see morphologic changes of the femoral head and the acetabulum, the degenerative processes leading to osteophytes formation and osteoarthritis, compromising the animal's overall clinical status. Although hip joint laxity can have a hereditary cause, the environmental factors play a part in its development, rapid weight gain and insufficient exercise in young patients can promote and aggravate this disease, leading to osteoarthrosis, these factors becoming dysplasia-inducing.The frequency and radiographic views justify a periodic survey of reproducing dogs, for a large number of older animals exhibit clincal signs of hip dysplasia, when the number of offsprings is already higher.

Key words: dog, hip, dysplasia, frequency, etiopathogenesis

Hip dysplasia (HD) is caracterized by a platten acetabulum, influecing the coaptation of the femoral head (1,2,6,8,12). Described for the first time by Schnelle in 1935 in North America, it has become a challenge for the orthoped and for dog breeders, because of its slow evolution and complications (2,4,5,6,8,11). At first, it was seen as a laxity of the hip join in large breed dogs, with variable degrees, which allows, at first, subluxation and then the acetabulum becomes smaller and the femoral head plattens (1,3,5,8,12). This is seen mostly in large breed dogs, but also in medium size ones, and it can evolve uni- or bilateral (1,3,6,10). No matter of localization, HD is a serious disease, because it decreases the animals' effort capacity, coxarthrosis generates persistent pain (2,6). This paper presents the research results on prevalence of HD in dogs and the role of dysplasia inducing factors in the disease's evolution.

MATERIAL AND METHOD

Research have been made on the number of cases from the Salvanim Veterinary Hospital in Iaşi, during 2005-2009, noticing the dogs with hip pain or those presented for radiographic certification of being HD free. For establishing the diagnosis, the clinical examintion has been followed by radiographs of the hip joint. This was made using a scale to note the local pathologic response. The points are starting from 0, which is dysplasia free, with no local modifications. In order to establish this diseases' prevalence and the dysplasia inducing factors, we identyfied the animals regarding the breed, age, feeding system and exercise conditions.

RESULTS AND DISCUSSIONS

Clinical and imaging investigations regarding prevalence of HD on the number of cases seen at the Salvanim Veterinary Hospital prove that this disease is seen in all dog breeds, varying with animal's age, sex and weight (table no. 1).

Table no. 1

EPIDEMIOLOGY OF HIP DYSPLASIA (HD) IN DOGS DURING 2005-2009 AT „*SALVANIM*" VETERINARY HOSPITAL, IAŞI

DOG BREEDS	No.	Sex		Age (years)				With HD	
		M	F	< 1	1-3	3-5	> 5	M	F
1. German Shepherd	**51**	**33**	**18**	**12**	**25**	-	**14**	**3**	**3**
2. Labrador	**3**	**2**	**1**	**2**	-	-	**1**	**2**	-
3. Caucasian Shepherd	**1**	-	**1**	**1**	-	-	-	-	-
4. Akita	**1**	**1**	-	-	-	-	**1**	-	-
5. Chow-Chow	**1**	-	**1**	-	-	-	**1**	-	-
6. Yorkshire	**1**	-	**1**	**1**	-	-	-	-	**1**
7. Dalmatian	**1**	**1**	-	-	-	-	**1**	-	-
8. Rottweiler	**3**	**1**	**2**	**1**	**1**	-	**1**	**1**	**1**
9. Caniche	**1**	**1**	-	**1**	-	-	-	-	-
10. German Brac	**1**	-	**1**	-	-	-	**1**	-	-
11. Pinscher	**1**	**1**	-	**1**	-	-	-	-	-
Total	**65**	**40**	**25**	**19**	**26**	**0**	**20**	**6**	**5**
Percentage		**61**	**39**	**29**	**40**	**0**	**31**	**15**	**20**

Analysing the data from table 1, we can see that the animals presented for x-ray examination were of large and medium breed, exception making Yorkshire and Pinscher. A small number of animals has been presented for x-ray evaluation in order to establish the presence of HD, a lot of owners saying that the animals experience a back problem. Although the number of females (25) was smaller, compared to that of males (40) presented for consults, the percentage of positive HD was higher in females (20), proving that males free of HD were presented at the clinic. The data we have cannot prove that the breed is a dysplasia inducing factor, although the data can be compared to that from the literature (6,10), that say that the animals with a high ratio between muscle and fat are less predisposed to HD. Comparying the data from the table to those published by OFA (Orthopedic Foundation for Animals), which estimates a prevalence of HD of 10-48% regarding the breeds, we can not conclude the same thing, for the majority of our animals was Germna Shepherd (78%), the rest coming with 1-3 cases. Analizying the age as a dysplasia inducing factor, the data written in table 1 show that HD can be clinically diagnosed at an old age, when pathologic responses of the femoral head and the acetabulum create pain sensations due to osteoarthrosis. Our affirmation is sustained by the fact that 71% of cases are an year-old or older, age when HD clinically evolves and the owner is forced to present the animal for further investigations. But the x-ray exam shows that HD can be seen at an early age, of 6-12 months, as cited in the literature (2,6,12), which clearly states that the disease can be seen in x-ray films starting at the age of 3 months. Joint laxity at this age demonstrates that the animal has a genetic predisposition to develop this disease, if he is exposed to favorising factors, such as excessive body weight, lack of exercise, etc., as seen in table 2.

Table no. 2

DYSPLASIA INDUCING FACTORS IN DOGS

Specification	Number of animals	Breeding system			Bosy weight		Localisation	
		Apartment	Cage	Yard	10-25 kg	> 25 kg	Unilateral	Bilateral
Animals examined	**65**	**26**	**21**	**18**	**14**	**51**	-	**65**
Animals with dysplasia	**11**	**5**	**4**	**2**	**1**	**10**	**4**	**7**
%		**45,4**	**36,5**	**18,1**	**9,9**	**90,1**	**36**	**64**

Evaluating the dysplasia inducing factors seen in table 2, we can see that the lack of exercise accentuates the clinical onset of the disease. Thus, 45.4% of HD cases are seen in dogs raised in apartments, being prived of body exercise, which tones body muscle and joint components, neccessary in order to ensure the congruence between the femoral head and the acetabulum. These dogs, although genetically predisposed at HD, will show clinical signs of the disease at an old age and with low intensity. Body weight has also a great influence on dogs, thus over 90% of illness has been diagnosed in dogs weighing over 25 kilos. Genetic predisposition amplifies joint morphology, when the animal is overfed in its first months of life. Our observation confirms the research of Kealy and col., 1992, according to which restrictive feeding reduces significantly morphologic changes in dogs genetically predisposed. Regarding the localization, HD is seen in one joint (36%) or in both (64). In the unilateral localization, we couldn't conclude on a difference - right or left. Genetic predisposition affects both joints, because a large number of animals developed this disease bilaterally, but we can say that there are moments in the animal's life when it is neccessary to support the body weight on one joint more than on the other, thus making it easier for degenerative joint disease to appear. Regardless of the cause, the dysplasic hip evoluates towards osteoarthritis, the most dreaded orthopedic complication. We can see changes in soft tissues (the joint capsule, the femoral head ligament, sinovial membrane) and the hard tissues (femoral head, acetabulum), consecutive to inflammatory and degenerative lesions. Preventing these lesions or even making it easier for the animal to live with them once they appear, is made by x-ray examination, which evaluates the congruency between the femoral head and the acetabulum, and it can recommend a healthier way of life. The x-ray evaluation is made by comparing it to the standard model, as established by the american, italian or german method.
Considering these methods of evaluation, the components of the hip joint are presented as it follows (fig. 1, fig. 2).

Fig. 1 (left) – Normal hip joints
Fig. 2 (right) – Normal hip joints - detail

Positioning: parallel simetrical, legs fig. 1).
Acetabulum: normal
Femoral head: spheric, deep in the acetabulum, the femoral neck is long, deep.
Norberg angle is over 105º

When joint laxity apperas and also degenerative lesions, x-ray films look like in fig. 3, 4.

Fig. 3 (left)– German Shepherd dog, male, 14 years
Fig. 4 (right)– German Shepherd dog, male, 14 years: detail of the hip joints

Positioning: legs are asimetrical, not enough rotated to the interior
Acetabulum: osteophites
Femoral head: on the right side – loss of bone structure, reshaping of the femoral head, which takes a conic shape, mushroom like. Subluxation on the right side, with large exostoses (jellyfish like) on the right and the left side.
Norberg angle is inferior to 105º.

CONCLUSIONS

1. Hip dysplasia is seen in large and medium breed dogs, with a body weight over 5 kg.
2. The relative frequency is the highest in the German Shepherd, being conditioned by the large number of animals examined from this population.
3. X-ray examination can be made at an early age – 6-12 months, but the owner presents the animal for consult when signs of osteoarthrosis are visible.
4. The main cause for HD is insufficient femoral head coaptation in the acetabulum, clinical onset depending on environment.
5. X-ray exams in cases of HD justifies clinical aspects seen at an old age.
6. X-ray films show bad leg positioning, and aspects of acetabulum, femoral head and Norberg angle is under 105º.
7. X-ray modifications in HD pleed for an early presentation at consult, in order to point out the existence of this disease, and to keep under control the dysplasia inducing factors.

BIBLIOGRAPHY

1. **Burtan I., 2009** – *Displazia luxantă coxo-femurală*. În Tratat de Medicină Veterinară, vol. V, ed. Tehnică, Bucureşti;
2. **Chanoit G., Genevois J.P., 2004** – *Patogenesi e diagnosi della displasia coxofemorale*. Collana di Summo, Patologia osteo-articulari del cane e del gatto in crescita. Point Veterinaire Italie, Novembre;
3. **Distl O. et al., 1991** – *Analysis of environmental and genetic influences on the frequency of hip dysplasia in German Shepherd dogs*, J. Vet. Med. 38, 460;
4. **Elefterescu H., 2001** – *Displazia luxantă de şold. Studiu comparativ om-câine*, ed. BIC-ALL, Bucureşti;
5. **Ettinger J.S., 2004** – *Textbook of Veterinary Internal Medicine Diseases of the Dog and Cat*, 6th edition,W.B. Saunders, Philadelphia;
6. **Fossum Theresa Welch et al., 2006** – *Small Animal Surgery*, 3rd edition, Mosby, Missouri, 942-949;
7. **Leighton E.A., 1997** – *Genetics of canine hip dysplasia*, J.Am.Vet.Med.Assoc. 210, 1474 ;
8. **Lust G., 1997** – *An overview of the pathogenesis of canine hip dysplasia*, J. Am. Vet. Med. Assoc. 210, 1443 ;
9. **Schnelle G.B., 1935** – *Congenital subluxation of the coxofemural joint in a dog*, University of Pennsylvania Bulletin, 15;
10. **Slatter H.D., 2003** – *Textbook of Small Animal Surgery*, 3rd edition, W.B. Saunders, Philadelphia;
11. **Swenson L. et al, 1997** – *Prevalence and inheritance of and selection for hip dysplasia in seven breeds of dogs in Sweden and benefits: cost analysis of a screening and control program*, J. Am. Vet. Med. Assoc. 210, 207;
12. **Todhunter R.J., Lust G., 2003** – *Hip dysplasia: Pathogenesis*. In Textbook of Small Animal Surgery by Slatter, 3rd edition, vol. 2, Saunders;

RESEARCH OF NEGATIVE ENERGY BALANCE AND ITS INFLUENCE ON THE REPRODUCTION FUNCTION IN DAIRY COWS

Cristina Maria TOFAN (MĂLĂNCUȘ), D. Gh. DRUGOCIU
Faculty of Veterinary Medicine Iași
cristina_tofan@yahoo.com

ABSTRACT

Negative energy balance is of great importance to the reproduction function, the main cause being nutritional deficienc. Nutritional requirements for maintaining the normal reproductive parameters, are 30-40 times smaller than those needed for maintenance and milk production. Milk production level and food stress can adversely affect reproduction, reflected in the lack of heats over a longer time (anoestrus postpartum) and a low fertility rate.Negative energy balance has a greater privative impact in cows in third lactation (when milk production is maximum) and in older cow. The aim of this paper is to highlight the effect of the energy balance in maintaining the normal fertility in cows with high milk production.

Keywords: dairy cows, energy balance, fertility, anoestrus

Energy balance is expressed as the difference between the amount of energy consumed and the amount of energy required. The consumed energy is the amount of the ingested food and the energy content in elements. The used or needed energy is the sum of all energy used for dairy cows to maintain body weight, production (milk, fetus) and activity. If the consumed energy is greater than the required energy then the energy balance is positive and the animals will gain weight. If the consumed energy value less than the required one, the energy balance will be negative and cows will lose weight. The main factors that contribute to profits are feeding and breeding cows, which have a close relationship. To maintain and enhance the production of milk in a farm, the cow parturition must occur at intervals of about 12 to 13 months. Given the gestation period (285 days), the period of uterine involution and postpartum anoestrus (45-60 days), means that the time, to remain pregnant after parturition, is quite short (20-40 days). This period overlaps with the period of maximum of milk. For cows suffering parturition, period of preparation for another pregnancy coincides with the transition period from feeding the stock to feed canned at mass feeding green, which is a stress to the body. The level of milk production and food stress can adversely affect reproduction, reflected in the lack of heats over a longer period of time (postpartum anoestrus) and a low fertility rate. In cows, the relationship between nutrition and reproduction is complex, being under veterinary control and must be carefully evaluated. To maintain the reproductive parameters (ovarian functions, fecundation, nidation and early pregnancy), nutritional requirements are 30-40 times smaller than those needed for maintenance and milk production. In lactating cows, inadequate feeding in the first month postpartum, coupled with their low energy reserves (body fat deposits), has negative influence on the resumption of ovarian activity after parturition and fecundity. The most important aspect of dairy nutrition is the energy component of the ration (starch, cellulose), which affects reproduction. In cows with high milk production , ration energy deficit in the first weeks after parturition results in extended time to first oestrus, decreased fertility, increased insemination per pregnancy and extended time from parturition until a new pregnancy. Negative energy balance has a greater privative impact in cows in third lactation (when milk production is maximum) and in older cows. After parturition, in dairy

cows can be observed that the energy intake is growing slowly in ration due the reduced feed consumption, the rapid growth of milk production and the increase in the consumption of their fat reserves, which can lead to metabolic disorders (the occurrence of ketosis). Approximately 80% of dairy cows undergo a negative energy balance during the first month of lactation because energy requirements for milk production can not be ensured only through dietary intake. Weakening of females in the first month after parturition and during the dry milk period contributes to lower fertility and to the extension of the time from parturition until a new pregnancy. In order to reduce the duration and amplitude of negative energy balance after calving, additional sources of fat may be introduced in ration (soybeans, animal fat). Supplementary feeding with high fat forage varieties also improves the breeding performance. Administration of high-fat feed assortments reduce consumption of feed thus being recommended only after a month pospartum. Genetic potential for milk production in dairy cows has increased significantly. Sometimes there is a high protein diet feeding tendency in cows to sustain or increase milk production, but this behavior is associated with low breeding indices. Ruminants can compensate lower protein intake to a certain extent by recycling the resulting urea from protein metabolism in the rumen. Cows fed with protein excess have high levels of urea in blood and milk, uterine pH is low and, consequently, the fecundity is unsatisfactory. The mineral elements have a very important role for female reproductive function. They are classified as macroelements (calcium, phosphorus, potassium, sodium, chlorine, sulfur, magnesium) and microelements (iron, iodine, manganese, zinc, selenium, copper, cobalt). Mineral elements that affects the function of breeding in cows are, in particular the group of microelements (manganese, selenium, iodine, zinc, iron), and also deficiencies in calcium and particularly phosphorus affects female fertility. Mineral supplements can affect the female reproductive parameters by adjusting the uterine environment reaction, improving fertility, reducing embryonic mortality and increasing the intensity of oestrus manifestation. To increase feed consumption in the first two months of lactation it must be reduced the time from parturition until a new pregnancy. Cows must be pooled in physiological conditions, feeding being differentiated, ensuring greater attention for the dairy cows that are in dry period (last two months of gestation) and the recently calved ones. Feed rations should provide easy fermentescibile carbohydrates in the rumen (concentrated) indigestible fiber and protein to maintain rumen health. The concentrated mixture should be contain specific vitamin-mineral supplements for dairy cows. To maintain normal fertility in cows with high milk production, the farmer must ensure that they are not too fat antepartum, are are fed with balanced rations in all nutrients, with an adequate energy intake for milk production, that stimulates feed consumption during the first two months of lactation and also must closely monitor the metabolic disturbances that may occur during the first days or weeks after parturition (acetonemia, hypocalcemia). Rations contain about 25 to 30 kg of silage per animal, 3-5 kg alfalfa hay / animal, brewers grains 2 kg / animal, concentrated 200-280-300 g / l milk (not more than 9-10 kg / animal), administered in two portions (morning and evening) in the following order: hay, concentrated, juicy food, coarse. To establish the need for food in dairy cows, the farmer must take into account that a cow will consume on average per day during lactation 2,5 kg SU/100 kg of body weight, to maintain vital functions requires 1.1 U.N 100 kg and 50 g PBD/100 kg and for one liter of milk are required 0.45 U.N. and 55g P.B.D. Increased feed consumption may be enhanced by improving the taste compound, specific methods of preparation. In conclusion, there are real problems of fertility in dairy cows, these multiplying with the increased milk production, especially when females are fed at their productive potential.

BIBLIOGRAPHY

1. BARKEMO,H., 1994,- Fertility production and culling follwing cesarian section in dairy cattle.Theriogenology 38(4).,Ref.In:Journal of Reprod.AndFertility.,No. 2.
2. BUTLER WR, EVERETT RW, COPPOCK CE. The relationships between energy balance, milk production and ovulation in postpartum Holstein cows. J Anim Sci 1981; 53(3):742-748.
3. CANFIELD RW, BUTLER WR. Energy balance and pulsatile LH secretion in early postpartum dairy cattle. Domest Anim Endocrinol 1990; 7(3):323-330.
4. CERNESCU HORIA – Ginecologie veterinară, Ed. EM Cecma Partener, Timişoara, 2004.
5. DRUGOCIU D. - Bolile obstetrical- ginecologice la animale, ediția aII-a, editura ”ION IONESCU DE LA BRAD” IAȘI, 2009
6. GROZA,I.,1985,-Observații asupra comportamentului vacilor în sistemul de fătare colectiv.Lucr.Şt.,Analele ICPCB Baloteşti,Vol. X.
7. LIVIU GH. RUNCEANU, CORNELIU V. COTEA- Reproducție, obstetrică și ginecologie veterinară. Ed.” ION IONESCU DE LA BRAD”, 2001
8. MATEI RODICA (2006) – Metabolismul şi rolul său asupra vacilor producătoare de lapte, Rev. Zoot. şi Med. Vet. 6, 15 – 17.
9. SPICER LJ, TUCKER WB, ADAMS GD. Insulin-like growth factor-I in dairy cows: relationships among energy balance, body condition, ovarian activity, and estrous behavior. *J Dairy Sci* 1990;73:929-937.

PARACLINICAL DIAGNOSIS OF HEPATIC DISEASE IN CATTLE

Tofan (Mălăncuș) Cristina, Solcan Gh., Drugociu D., Mălăncuș R.N.

Faculty of Veterinary Medicine Iasi, 8 Mihail Sadoveanu Alley, Iasi, 700489, Romania
cristina_tofan@yahoo.com

ABSTRACT

The aim of this paper is to diagnose the hepatic diseases in cattle using supplementary investigations such as blood biochemical examination, hematological examination and ultrasound examination. After conducting biochemical examination following results occurred: AST had values ranging from 112.90 to 187.90 IU (normal 45.3 to 110.2), ALT 74.91 to 108.30 IU (normal 6 6 to 35.3), serum albumin 20.17 to 38.70% (normally 44%), total proteins from 4.78 to 6.81 g / dl (from 6.5 to 8.0 normal), cholesterol 117.11 -254.98 mg % (normal 110), blood glucose levels recorded between 28.09 to 57.09 mg % (normal 45-55), ketonemia 320.45 to 498.19 µmol / l (normal 145-290) , bilirubin 0.43 to 2.44 mg % (normally from 0.4 to 0.7), uremia 33.31 to 52.0 mg % (normally 30). The detected blood biochemical changes presented diagnostic value in liver diseases, thus confirming the presence of liver distress.After haematological examination were obtained the following values: hemoglobin 10.23±0.76 g/100 ml (9-13), hematocrit 38.91±4.87% (25-45), erythrocytes 6.22 ± 0,99 mil/mm³ (5-8) and WBC recorded values of 10.37 ± 3120 x1000/mm³ (5-12). Haematological parameters examined changed only in those cattle diagnosed with suppurative hepatitis. Ultrasound investigation revealed the congestion of the organ, with dilated vessels and diffuse high echogenity.

Key words:hepatic disease, cattle, ultrasonography, haematology

MATERIAL AND METHOD

The study was conducted from November 2009 - March 2010, on 24 cows with liver disease, belonging to the farm A in Iassy County. Diagnosis was stated by the corroboration of blood biochemical results with haematological examination and ultrasound examination. Blood biochemical examination monitored the following parameters: AST, ALT, serum albumin, total protein, cholesterol, glucose, ketonemia, bilirubin, uremia. Following haematological examination were determined: hemoglobin, hematocrit, erythrocytes and leukocytes. Ultrasound examination was performed in four animals suffering of hyperthermia and pain in liver area.

RESULTS AND DISCUSSION

Biochemical examination results are presented in Table 1. Analyzing the diagnosed hepatic diseases it can be observed in terms of biochemical determinations that almost all test values are changed to normal. The most important changes, demonstrating the presence of liver disease were recorded for transaminases, serum albumin, serum protein, cholesterol, bilirubin, bile pigments, uremia and less in blood glucose. Thus, table 1 shows the increase in transaminases, decrease of total protein fraction α and increase of protein fractions β and γ, increased values in cholesterol and bilirubin and also a decrease in blood sugar.

Table 1

Results of blood biochemical examination from cattle with liver failure

Case	Transaminases		Total Protein	Albumin Serice	Cholesterol	Blood Sugar	Ketonemia	Bilirubin	Uremia	Diagnosis
	ALT	AST								
	U.I.	U.I.	G/Dl	%	Mg%	Mg%	µmol/L	Mg%	Mg%	
1	83,22	145,90	5,4	27,98	132,00	38,98	378,87	1,76	45,71	Acute Parenchymal Hepatitis
2	74,91	112,90	6,21	31,03	117,11	57,09	320,45	2,01	52,00	Purulent Hepatitis
3	108,30	135,01	6,81	38,70	129,02	44,84	378,65	1,13	44,04	
4	81,90	139,50	4,78	21,30	137,09	39,19	330,17	0,65	47,87	
5	106,30	154,91	4,80	20,17	153,07	44,90	378,90	0,97	39,11	Chronic Hepatitis
6	102,33	142,02	5,72	28,91	153,02	28,09	465,12	1,22	45,34	Fat Hepatosis
7	105,92	187,90	5,12	31,33	254,98	29,28	400,20	0,43	33,31	
8	99,10	135,08	5,37	34,09	187,54	31,90	443,98	1,76	36,78	
9	98,40	127,30	6,15	23,11	169,32	29,34	498,19	2,44	51,9	
Reference (Vulpe,2002)	6,6-35,3	45,3-110,2	6,5-8,0	44	110	45-55	145-290	0,4-0,7	30	

The blood biochemical changes detected have diagnostic value in liver diseases, thus confirming the presence of hepatic suffering and also the clinical diagnosis of liver disease and liver failure. Analysis Table 1 wit can be seen changes in serum transaminases, ALT and AST that reached maximum values of 108,30 and 187,90 respectively. Increased transaminases indicates liver functional damage and the higher the values registered , the more it can be said that at this level it exists serious liver parenchymal lesions, whose prognosis is always serious.

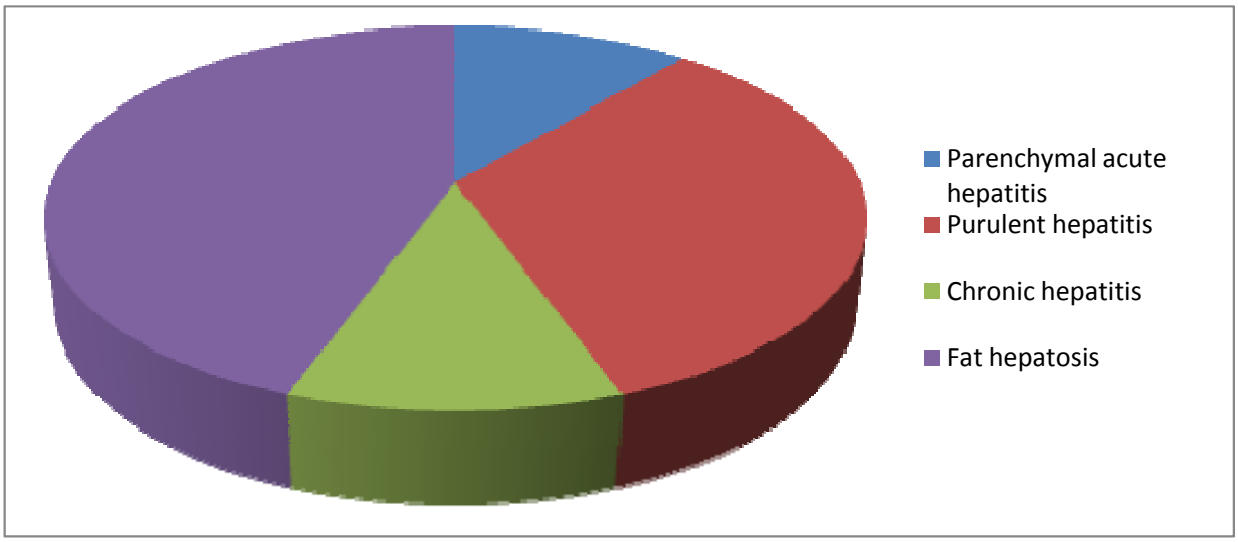

Fig. 1
Share of liver diseases that were biochemically diagnosed

Haematological examination was performed in all 24 cases taken in the study, changes in blood parameters appearing only in cattle diagnosed with purulent hepatitis, changes that interested the number of leukocytes and neutrophils in particular.

Table 2.

Hematological examination results

	Haemoglobin	Hematocrit	Erythrocytes	White blood cell
	g/100 ml	%	mil/mm^3	mil/mm^3
Values obtained	10,23±0,76	38,91±4,87	6,22±0,99	10,37±3,12
Reference values (Vulpe, 2002)	9-13	25-45	5-8	5-12

In the three cases biochemically diagnosed with purulent hepatitis there was added another case of leukocytosis (14.87 thousands / mm³) and neutrophilia (48%), with slight changes in hematocrit (46.9%). Thus, cases 2, 3 and 4 (Table 1)), presented the following values: hemoglobin: 10.79 (2), 9.97 (3) and 10.25 (4), hematocrit: 39.4% (2), 41.87% (3) and 47.1% (4); erythrocytes: 5.98 milion / mm³ (2), 5.88 million / mm³) (3) and 6,03 million / mm³ (4), WBC: 14.79 thousands / mm³) (1) and 15.28 thousands / mm³ (3) and 15.09 thousands / mm³) (4). Leucocyte formula values fell within the limits of species with small insignificant difference: neutrophils 34.5 ± 12.2 (normal: 25-35), lymphocytes 56.12 ± 4.32 (55-65), eosinophils 4.2 ± 2.1 (2-8), monocytes 3.01 ± 0.18 (3-4) and basophils 0.98 ± 0.12 (1-2).

Tabel 3.

Reference hematological values for cattle in different physiological states (Avram, 1986)

Hematological parameters	Units	Average and standard deviation (X±s)			
		Pregnant Cattle	Lactating Cattle	Calves	Young Cattle
Erythrocytes	mil/mm3	6,5±0,5	6,0±0,4	5,4±0,6	5,5±0,5
Hematocrit	%	40±5,0	30±4,0	37±4,0	37±3,0
Hemoglobin	g/dl	13±0,5	12±0,5	10,5±0,5	11,5±0,8
VEM	µ3	61±6,0	65±5,0	68±4,0	67±4,0
HEM	pg	18±2,0	17±2,0	16±2,0	18±2,0
CHEM	g/dl	32±2,0	30±2,0	29±2,0	31±3,0
Leucocytes	mii/mm3	15,2±2,0	14±1,5	12,0±2,0	18,0±5,0
Lymphocytes	%	53±6	50±7	45±5	47±5
Neutrophils	%	37±4	40±6	45±5	43±4
Young neutrophils	%	2±2	2±2	3±3	3±2
Eosinophile	%	3,5±1,5	4±2	2,5±0,5	2,5±1
Monocytes	%	4±2	3,5±1,5	4±1	4±1
Basophils	%	0,5±,05	0,5±,05	0,5±,05	0,5±,05

Ultrasound examination was performed in four animals, suffering of hyperthermia and pain in the liver area. After conducting ultrasound examination there have been revealed congestion of the organ, with dilated vessels and diffuse hyperechogenity (Figure 2, 3).

Fig. 2
Hyperechogenic liver and congestion

Fig. 3
Hepatic congestion with dilated vessels and port vein

CONCLUSION

1. Investigations were undertaken on 24 bovine with liver disease, during November 2009-March 2010.
2. Diagnosis was established by collating the data provided by blood biochemical examination with hematological results and ultrasound examination data.
3. Biochemical examination of blood permitted the observation of the following: increased transaminases, bilirubin and uremia in all studied cases, a decrease in serum albumin and total protein, increased cholesterol in most cases, increased levels of ketone bodies, decreased glucose in all cases of ketosis.
4. Of the 24 subjects in the study: 33.33% had purulent hepatitis, 16.66% had acute parenchymatous hepatitis, 25% showed fat hepatosis, 8.33% had chronic hepatitis and 16.66% presented hepatic congestion.
5. Ultrasound examination was performed in four animals, suffering of hyperthermia and pain in the liver area.

BIBLIOGRAPHY

1. **Radostis, O. M.; Blood, D. C.; Gay, J.** - *Veterinary Medicine* Bailliere Tindall, New York , 2000.
2. **Solcan Gh., Boghian V., Rollin F.** - *Patologie şi clinică medicală veterinară*,Ed.Ion Ionescu de la Brad, Iaşi, 2005.
3. **Vulpe V.** - *Semiologie medicală veterinară,* Ed. Ion Ionescu de la Brad, Iaşi, 2005.
4. **Oprean O. Z.** – *Morfopatologie specială veterinară,* Ed. Evcont Consulting, Suceava, 2002.
5. **Halga P.** (coord) - *Nutriţie animală,* Ed. Coressi, Iaşi, 2000.
6. **Codreanu M.D.** - *Diagnosticul ecografic în bolile interne la animale*, Ed. Coral Sanivet, Bucureşti, 2000.

ULTRASOUND DIAGNOSIS IN EARLY PREGNANCY TO BUFFALO

G. Tomai , I. MORAR, I. St. GROZA
University of Agricultural Science and Veterinary Medicine, Faculty of Veterinary Medicine
Manastur Street. 3-5, Cluj-Napoca, Romania,
e-mail dr_grigoretomai@yahoo.com

ABSTRACT

To make an accurate diagnosis of pregnancy in buffalo, and for it to be as early performed, ultrasound comes as a modern method contributes to specify and/or supplement the diagnosis of pregnancy, with high reliability, even in the first 20 days of gestation.Using ultrasound as a complementary method for early diagnosis of pregnancy in buffalo is considering little known genre, the limited scope of growth in country, but others causes related to low productivity. Using ultrasound in early diagnosis of pregnancy in buffalo is salutary, diagnostic ultrasound descending certain age of gestation, the buffalo, to 20 days. The fact is even more important as the buffalo gestation, unlike the cow, is longer by about 30 days.Relatively disadvantage can be overcome if species adopt proper methods of contention, in this case adapted to the particularities of each shelter in hand.However transrectal ultrasound examination of buffalo in a specially arranged stand, it would be desirable, where buffaloes free moving to a specialy arranged place, is possible. Mention that, in households, this is not possible, because buffaloes temperament, does not often free moving toward a particular point developed for ultrasound examination.Ultrasonografic exams to determine how early diagnosis of pregnancy in buffalo, but also for identification of fetal structures, different stadium of pregnancy were performed on 35 buffalo from Maramures, Suciu de Sus village.Among these 24 buffaloes were pregnant, and the rest, pregnancy absence.The scope was to determine pregnancy as early as possible, but also, the fetal structures.

Keywords: buffalo, ultrasound, fetus, gestation.

INTRODUCTION

In veterinary practice, breeding problems occupy a large part of pathology, requiring the most skiil and management of veterinary clinical practice. Existing biological differences between animal populations, racial differences, big differences can be noted in animal feeding- by region, in households, as well as the need for early diagnosis of pregnancy require maximum ability and diagnostic clinic veterinarian practitioner. If we strictly to early diagnosis of pregnancy in buffalo, accurate diagnosis of veterinarian experienced by transrectal examination, tends to be highest after the first 65 days of gestation. To make an accurate diagnosis of pregnancy in buffalo, and for it to be as early performed, ultrasound comes as a modern method contributes to specify and/or supplement the diagnosis of pregnancy, with high reliability, even in the first 30 days of gestation. As imaging methods, ultrasound alone can provide images actually on stage pregnancy, normal and pathological structures of the fetus, but also information about state ovary, corpus luteum of pregnancy, the uterus and cervix in buffalo. Unlike other imaging methods, is less costly, because

the probe shape, pregnant uterine horn, can be easily dealt with transrectal and necessary equipment can be used as shelters.

Aim of the study

1. The diagnosis early in gestation as buffalo;
2. Identification of fetal structures in different development stages of pregnancy in buffalo.

Using ultrasound as a complementary method for early diagnosis of pregnancy in buffalo is considering little known genre, the limited scope of growth in country, but others causes related to low productivity, that is not suitable for milking bufallo mechanical, etc…
Establish as early pregnancy in buffalo is relatively easy goal to reach where they may call on ultrasound, even starting with the first 20 days of gestation. Also, scanning the entire female genital apparatus.

MATERIAL AND METHODS

Material

They worked on a total of 35 bufaloes, from the area Suciu de Sus and Suciu de Jos, aged between 3 and 21 years.

Table 1. Identification buffalos examined

Nr.	Species	Sex	age (years)	Serial number	Last matings
1.	buffalo	F	5	6022	08.02.010
2.	buffalo	F	3	3611	15.12. 09
3.	buffalo	F	12	6624	N
4.	buffalo	F	11	6835	27.02.010
5.	buffalo	F	5	6834	15.02.010
6.	buffalo	F	9	6142	04.02.010
7.	buffalo	F	8	6309	MR
8.	buffalo	F	8	7568	05.02.010
9.	buffalo	F	7	6323	12.02.09
10.	buffalo	F	14	6321	20.01.010
11.	buffalo	F	12	8390	MR
12.	buffalo	F	15	7554	29.02.010
13.	buffalo	F	16	7552	N
14.	buffalo	F	6	6810	16.0 2.010
15.	buffalo	F	3	8562	04.02.010
16.	buffalo	F	6	5852	05.02.010
17.	buffalo	F	3	8846	N
18.	buffalo	F	21	5836	02.11. 09
19.	buffalo	F	10	7409	N

20.	buffalo	F	8	7369	20.0 2.010
21.	buffalo	F	12	5982	N
22.	buffalo	F	9	5921	20.01.010
23.	buffalo	F	10	6025	N
24.	buffalo	F	10	9361	15.11. 09
25.	buffalo	F	11	6309	N
26.	buffalo	F	8	7568	15.02.010
27.	buffalo	F	16	6174	16.02. 010
28.	buffalo	F	9	6608	30.01. 010
29.	buffalo	F	11	5953	30.01. 010
30.	buffalo	F	7	0891	N
31.	buffalo	F	15	6180	N
32.	buffalo	F	16	6178	20.02.010
33.	buffalo	F	3	3603	01.11. 09
34.	buffalo	F	5	2518	31.10. 010
35.	buffalo	F	6	5801	08.02. 010

Ultrasound is used portable type, DP 2200 Vet, the following technical characteristics: Monitor 25.4 cm diameter; dimensions: 360 mm x 320 mm x 270 mm; Net weight 9,5 kg; Scan modes B, B+B, B+M and M; reproductive biology software (dogs, cats, horses, cattle, sheep); who loop with 128 images, 256 shades of gray; 1 USB ports; 4- 6 Mhz linear rectal probe; Gloves, gels, protective equipment, materials needed to contention bufalloes.

Method

After animal content, where these was needed, to connect to a power source, adjustment between 6,47 and 8,62 inch deph and frequency of 6 Mhz, started to empty the rectal ampoule and lubrification the ultrasonic transducer, get started to scanning the female genital apparatus. Representative ultrasound images were saved in the mamory device and then were transferred to a PC. They have scanning 35 head bufallo (presented in table 1), aged between 3 and 21 years, all ultrasound examination, using the aforementioned device, equipped with ultrasonic transducer.

RESULTS AND DISCUSSION

The distribution of gestation periods in pregnant buffalos:

- Gestation between 20- 30 days, 2 buffalo (8,33 %);
- Gestation between 30- 40 days, 2 buffalo (8,33 %);
- Gestation between 40- 50 days, 12 buffalo (50 %);
- Gestation over 50 days , 8 buffalo (33 %).

1. Gestation between 20- 30 days, 2 buffalo, fig. 1 (8,33 %)

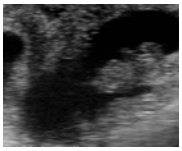

Fig. 1. At 25- 30 days of gestation, the embryo has a lenght of about 5- 7 cm. It can be easily fetal fluids, fetal roofings. Also already identify primary head and limbs buds. Cephalic vesicle is also visible and the anechogene zone, the allantoic fluids. Placentoamele not yet visible. Uterin wall is also cleary visible.

2. Gestation between 30- 40 days, 2 buffalo, fig. 2 (8,33 %)

Fig. 2. After day 35 of gestation, embryo resembles adult animal. Placentoamele take shape, but become clearly visible in buffalo ultrasound from day 45 of gestation. The limb buds is very cleary visible, also the anechogene area whichmeans the allantoic fluids. Fetal length is 8- 9 cm. Cephalic vesicle is much better delineated and the fetus has an adult animal form. At this stage we have not managed to detect ultrasound of the heart and heartbeat the fetus buffalo.

3. Gestation between 40- 50 days, 12 buffalo, fig. 3 (50 %)

Fig. 3.

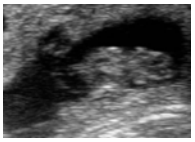

Fig. 4.

The image of figure 3 is very ultrasound visible roofing fetal, allantoic fluids. The large anechogene areas representing fetal fluids. At 45 days gestation the placentomes becomes visible, with the size of a bean. The fetus has a lenght of about 7- 8 cm. Also at 45 days, we can see the heart, heart beat, which certifies the fetal viability (fig. 4). Fetal structures become visible after 30-35 days of gestation, starting with knobs legs, and cephalic vesicle, and later, identifying heart beats even interventricular septum.

4. Gestation over 50 days , 8 buffalo (33 %).

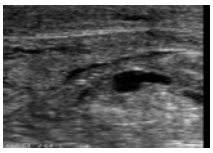

Fig. 5.

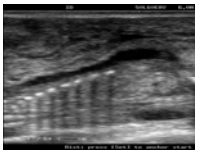

Fig. 6.

Fig. 7.

Gastric vesicle (red arrow in fig. 5) can be identified from buffalo fetuses after 60 days of gestation, also urinary bladder (blue arrow in figure 5), liver, gallbladder (green arrow in figure 6). In this stage of gestation to buffalo, is very easy to identify heart, heart beats even interventricular septum (yellow arrow in figure 6). See clearly in figure 7, the tail region, and all inguinal region. Is also very visible the fetal coverings of this region (white arrow in figure 7). Skeleton lines can be easily traced after 50 days of gestation.

The representative ultrasound images will be presented in the following:

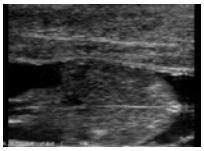

Fig. 8

Fig. 9

Fig. 8: 55 days gestation, inquinal region, the fetus 12 cm.

Fig. 9: 60 days gestation, the fetus 12 cm, gastric vesicle;

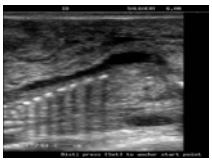

Fig. 10

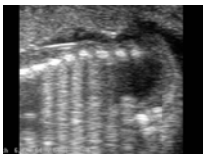

Fig. 11

Fig. 12

Fig. 10: 70 days gestation, the fetus 17 cm, gastric vesicle, ribs, heart, gallbladder;

Fig. 11: 80 days gestation, the fetus 22 cm, gastric vesicle, ribs, heart;

Fig. 12: 90 days gestation, the fetus 27 cm, cervical spine.

Of the 35 buffalo ultrasound examination, a total of 24 were diagnosed as pregnant, as follows:

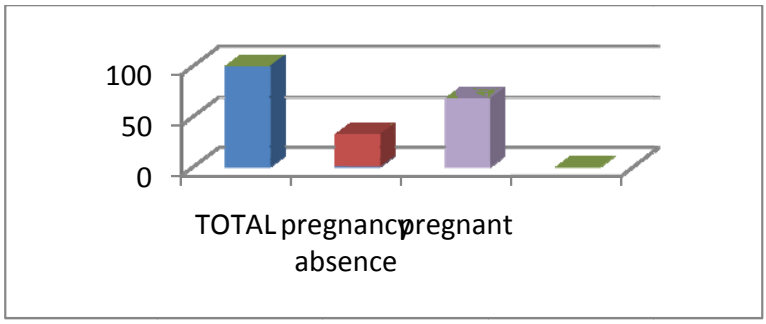

Graphic 1: 32 % buffalo pregnancy absence and 68 % pregnant.

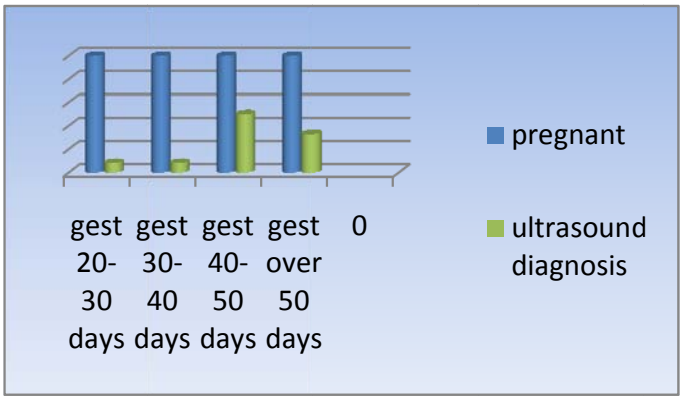

Graphic 2: The distribution of gestation periods in pregnant buffalos.

CONCLUSIONS AND RECOMMENDATIONS

Minimum age at which ultrasound can diagnose the pregnancy to buffalo is about 25- 35 days after mating time, which greatly help to reduce service- period to buffalo, especially winter time, often quiet and heat are all missing. Fetal structures become visible after 30- 35 days of gestation, starting with knobs legs, and cephalic vesicle, and later, after 40 days of fetal heart becomes visible, identifying heart beats even interventricular septum. Gastric vesicle can be identified from buffalo fetuses after 60 days of gestation, also bladder, liver, gallbladder. Skeleton lines can be easy traced after 50 days of gestation.

RECOMMENDATIONS

Using ultrasound in early diagnosis of pregnancy in buffalo is salutary, diagnostic ultrasound descending certain age of gestation, the buffalo, to 25- 30 days. The fact is even more important as the buffalo gestation, unlike the cow, is longer by about 30 days. Relatively disadvantage can be overcome if species adopt proper methods of contention, in this case adapted to the particularities of each shelter in hand. In basically if it immobilizes the animal head with horns connecting to a fixed point and holding the tail, firmly, in part by an aid transrectal ultrasound exploration is possible without major risks for the operator or animal. However transrectal ultrasound examination of buffalo in a specially arranged stand, it would be desirable, where buffaloes free moving to a specialy arranged place, is possible. Mention that, in households, this is not possible, because buffaloes temperament, does not often free moving toward a particular point developed for ultrasound examination.

REFERENCES

1. **Bartoiu, A., Seiciu, F**." *Ginecologie si andrologie veterinara*", Ed. Fundatia Romania de maine, Bucuresti, 2002.
2. **Boitor, I**., *„ Puerperium normal si patologic la animalele de ferma*", Ed. Ceres, Bucuresti, 1985.
3. **Boitor, I**., *„Fiziologia si fiziopatologia reproductiei la animalele de ferma"*, Ed. Ceres, Bucuresti, 1985.
4. **Boitor, I., Muntean, M.,** *„Patologia reproductiei si clinica obstreticala,* Partea I, Tipo Agronomia, Cluj Napoca, 1989.
5. **Cernescu, Horia**,"*Ginecologie veterinara*", Ed. Cecma partner, Timisoara, 2004.
6. **Groza, I., I., Morar**, *„Andrologie veterinara*", Ed. Gryphon, Brasov, 2004.
7. **Jones AL, Marek DE, Wilson JM, Looney CR.** *The use of ultrasonography to increase recipient efficiency through early pregnancy diagnosis.* Therio 33:259, 1990.
8. **Kastelic JP, Curran S, Ginther OJ**: *Accuracy of ultrasonography for pregnancy diagnosis on days 10 to 22 in heifers.* Therio 31:813-820 ,1989.
9. **Mario Darius Codreanu, Alexandru Diaconescu**, *Diagnosticul ecografic la animalele de companie*, Ed. Coral Sanivet, Bucureşti, 2003.
10. **Papuc, I**., *„ Semiologie si imagistica medicala veterinara"*, Ed. Accent, 2005.
11. **Pierson RA, Ginther OJ**: *Ultrasonographic appearance of the bovine uterus during the estrous cycle.* J Am Vet Med Assoc 190:995-1001, 1987.
12. **Singh J, Pierson RA, Adams GP**: *Ultrasound image attributes of bovine ovarian follicles and endocrine and functional correlates*. J Reprod Fertil 112:19-29, 1998.
13. **Stouffer J.R., R.G. Westervelt** 1997, *Areviw of ultrasonic applications in animal science reverberations in echocardiograms*
14. **Stroud BK**: *Clinical applications of bovine ultrasonography*. Compen Cont Edu Prac Vet 16:1085-1097, 1994.