ISSN (print) 1454-7406
ISSN (electronic) 2393-4603

"ION IONESCU DE LA BRAD" IASI
UNIVERSITY OF LIFE SCIENCES (IULS)

SCIENTIFIC PAPERS
VETERINARY MEDICINE

LUCRĂRI ȘTIINȚIFICE
SERIA MEDICINĂ VETERINARĂ

VOLUME 64

NO. 2

PUBLISHING "ION IONESCU DE LA BRAD"

Coordinators of Journal

CONTENTS

Research on the presence of viral infections in dogs in dog shelters from Eastern Romania (Botosani, Iasi and Vaslui Counties) **5 - 8**
Florin Jan Vasilache, Elena Velescu

Research regarding the presence of viral infections in dogs from shelters in Eastern Romania (Bacău, Vrancea and Galați Counties) **9 - 12**
Florin Jan Vasilache, Elena Velescu

Promoting sustenability in family-sized dairy farms from North-East of Romania - use of thermography for monitoring udder health and improvement of milk quality (preliminary study) **13 - 17**
Andra-Sabina Neculai-Valeanu, Adina-Mirela Ariton, Cristina-Mihaela Rîmbu

Formulation and evaluation of antibacterial phytotherapeutic gels containing metal ions and essential oils **18 - 22**
Andra-Sabina Neculai-Valeanu, Adina-Mirela Ariton, Cristina-Mihaela Rîmbu, Cristina-Horhogea

The increase in the photodynamic potential of dacarbazine as a result of pH dependence **23 - 26**
Ana-Maria Coman, Radu Fumărel, Valentin Budaşcu,
Diana Mihaela Alexandru

Farmed cyprinids diseases from the Prut River Basin **27 - 32**
Adrian Bălbărău, Vasile Vulpe, Ramona Ghiorghiasa, Dumitru Acatrinei, Larisa Ivănescu, Liviu Miron

An uncommon case of gastrointestinal foreign body in cat **33 - 36**
Alexandra Neamțu, Liviu Burtan, Dan Gheorghe Drugociu

Bilateral uterine prolapse in queen: case study **37 - 40**
Alexandra Andreea Sikra, Petru Roșca, Ștefan Gregore Ciornei, Dan Gheorghe Drugociu

Covid 19 - induced stress in dogs owned by elderly people **41 - 43**
Răzvan Nicolae Mălăncuș

CT periportal halo sign in dogs-comparasion with human medicine **44 - 48**
Cristi Glăvan

Some indices regarding of the epidemiological situation and measures of prophylaxy of rabies on the Republic of Moldova **49 - 52**
Nicolae Starciuc1, Maxim Sîrbu

Epidemiological monitoring and antimicrobial resistance profiles of avian pathogenic Escherichia coli isolates among breeder hens **53 - 57**
Nicolae Malancea, Nicolae Starciuc, Natalia Osadci

Noninvasive measurement of intraocular pressure in rats with the iCare tonovet rebound tonometer **58 - 62**
Diana – Larisa Ancuța, Fabiola Ioniță, Diana Alexandru,
Maria Crivineanu, Cristin Coman

Monitorizarea unor parametri microbiologici și a compoziției algale în apele de suprafață ale unor emisari din Bazinul Dornelor **63 - 65**
Ionela Voloșeniuc, Liviu Miron

Monitorizarea unor parametri fizico-chimici pentru apele de suprafață ale unor emisari din Bazinul Dornelor **66 - 69**
Ionela Voloșeniuc, Liviu Miron

The role of bacterial infections in the development of respiratory diseases in swine **70 - 75**
Jovan Bojkovski, Ivan Pavlović, Ivan Vujanac, Sveta Arsić, Sreten Nedić, Dragoş Constantin Aniţă, Luanda Oslbanu, Adriana Elena Anita, Nemanja Zdravković, Oliver Radanović, Jasna Prodanov - Radlović, Petar Karać, Radiša Prodanović

RESEARCH ON THE PRESENCE OF VIRAL INFECTIONS IN DOGS IN DOG SHELTERS FROM EASTERN ROMANIA (BOTOSANI, IASI AND VASLUI COUNTIES)

Florin Jan VASILACHE[1], Elena VELESCU [1]

e-mail (first author): florinvj13@gmail.com

Abstract

The present study aimed to investigate the presence of viral infections in dogs in paddocks in eastern Romania (Botoșani, Iasi and Vaslui counties). The research was focused on the analysis of diagnostic methods used in paddocks to identify infectious agents, the analysis of predisposing factors, as well as the analysis of measures to monitor and combat infections in the shelter. Most cases of viral diseases (5,000) were observed in the case of a shelter in Iasi County. Canine parvovirus was the most common viral disease among dogs in the three counties included in the study, the incidence of this disease ranging between 28.18% and 100%. Cases of Carre's disease, infectious hepatitis and kennel cough were also diagnosed in the paddocks included in the study, but their incidence was significantly lower. Among the main recommendations for preventing canine parvovirus infection are avoiding contact between sick and healthy animals, as well as avoiding frequenting of contaminated areas by their young pathways. In the case of the dog shelter located in Botoșani, the impossibility of ensuring a proper quarantine before introducing the puppies into the shelter, led to a mortality of 87.91% among the youth. The present results suggest that there were outbreaks of canine parvovirus in the shelters included in this study, with CPV being the primary pathogen in all three shelters. Due to the significant losses caused by viruses and the high costs of treating sick animals, there is a need for early diagnosis and the application of well-defined immunoprophylaxis measures in shelters. This study reinforces the importance of immunization to ensure the welfare of dogs in public and private shelters.

Key words: viral disease; dog shelters; parvovirus; immunoprophylaxis

INTRODUCTION

In recent years, efforts have been made to better understand the health of animal populations, especially with regard to viral infections. Due to the high mutation rate and replication strategies, viruses are responsible for recently recognized emerging diseases, which pose a danger not only to domestic and wild animals but also to humans (Cleaveland, 2009; Parrish et al., 2008). The high density of domestic and stray animals in urban areas allows the spread and viral maintenance in these populations. Of the major viral diseases that affect the canine body, most have a high mortality rate. Among the most serious viral diseases of the canine organism, which can occur with a series of complications difficult to manage, are parvoviruses, Carre's disease, coronavirus, rabies, kennel cough, and viral canine hepatitis.

The shelter may becomes a favorable environment for the spread of viral diseases and their effective management can often be difficult. The present study aimed to investigate the presence of viral infections in dogs in paddocks in eastern Romania (Botosani, Iasi, and Vaslui counties). The research also focused on the analysis of diagnostic methods used in shelters to identify infectious agents, the analysis of predisposing factors, as well as the analysis of measures to monitor and control infections.

MATERIAL AND METHOD

The ANSVSA database and the website www.registru-caini.ro were accessed, in order to obtain the necessary information regarding the location and contact data of the paddocks in Iași, Botoșani and Vaslui counties. According to the information presented on the two sites, in iași county there are three public shelters, in Iași, Balciu (Miroslava commune) and Cristești (Cristești commune), in Botoșani county there are 2 public shelters, in Botoșani and Flamânzi localities and a private one (Botoșani), and in Vaslui county, there are a number of 5 shelters, of which 3 public, in the localities of Vaslui, Bârlad and Huși, respectively 2 private in the localities of Bârlad and Bălteni. A formal request for detailed information regarding the number of animals in the shelter in 2019 and in

[1] IASI University of Life Sciences, Faculty of Veterinary Medicine, Department of Public Health

the first trimester of 2020, the demographic characteristics of the animals in the shelter, the presence of viral infectious diseases during the analyzed period, the therapy and treatment schemes implemented, as well as the measures prophylaxis of these diseases was submitted to the aforementioned dog shelters.

Following the request sent to the dog shelters located in Iași, Botoșani, and Vaslui counties, detailed information was obtained from a public dog shelter located in iași and two private ones located in Botoșani, Vaslui county.

Statistical analysis was performed with spss statistical software. The incidence of the disease was defined as the number of new cases occurring in the analyzed unit of time. The mortality rate was calculated to measure viral deaths, which occurred in a population of dogs, in a specific period of time (2019, first trimester of 2020).

RESULTS AND DISCUSSIONS

In the three shelters included in the study, the number of female animals population was significantly larger (< 0.05) compared to the male population in both adult and young dogs. Additionally, the proportion of animals aged 0-5 years was significantly higher.

Canine parvovirus was the most common viral disease among dogs in the three counties included in the study, the incidence of this disease ranging between 28.18% and 100%. Cases of Carre's disease, infectious hepatitis and kennel cough were also diagnosed in the shelters included in the study, but their incidence was significantly lower.

Cases of canine infectious hepatitis were recorded only in the public shelter located in Iasi county.

Among the main recommendations for preventing canine parvovirus infection are avoiding contact between sick and healthy animals, as well as avoiding frequenting of contaminated areas by their young pathways. In the case of the dog shelter located in Botoșani, the impossibility of ensuring a proper quarantine before introducing the puppies into the shelter, led to a mortality of 87.91% among the youth, 70% of deaths being recorded in the first 48 hours after the onset of the disease.

In the case of dogs from the shelter located in Iași, the diagnosis of viral diseases was established exclusively on the basis of medical history, clinical signs of illness, and physical examination., while in the other two shelters immunochromatography-based test were used for the diagnosis of parvovirus.

The diagnosis of kennel cough usually requires the isolation and identification of viruses or identification of the level of post-infection antiviral antibodies. However, in the case of the three shelters included in the study, the allocated financial resources did not permit further investigation apart from clinical examination. The diagnosis was established based on the signs of respiratory infectious such as persistent, paroxysmal and forced cough, which in some cases was accompanied by other symptoms such as sneezing or excessive discharge from the eye or nose.

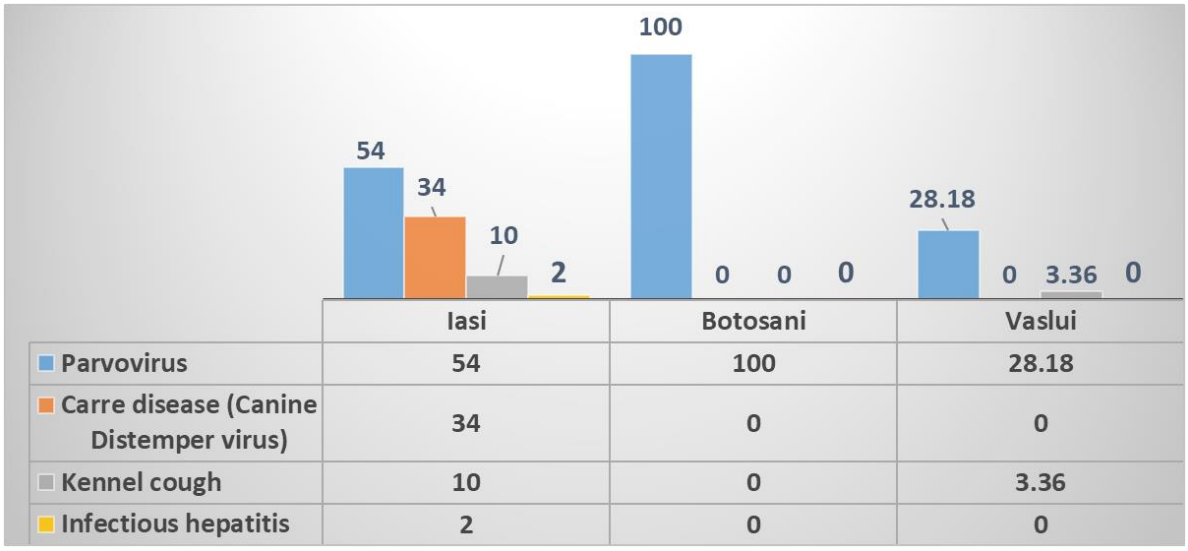

Figure 1. **Incidence of different viral disease (%) in dog shelters from eastern Romania (Iasi, Botosani and Vaslui counties) in 2019**

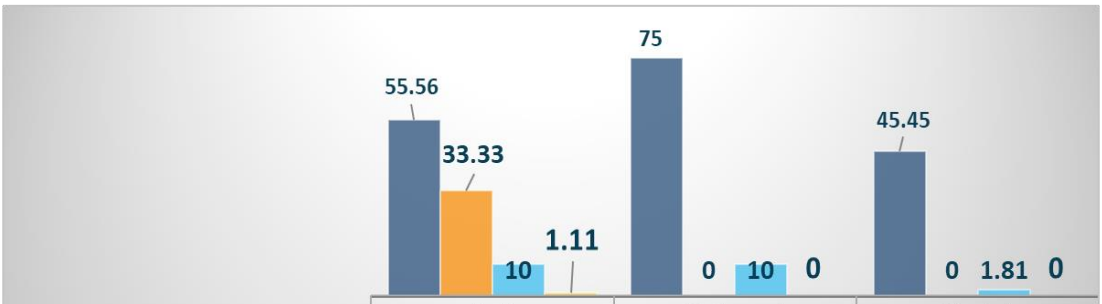

	Iasi	Botosani	Vaslui
Parvovirus	55.56	75	45.45
Carre disease (Canine Distemper virus)	33.33	0	0
Kennel cough	10	10	1.81
Infectious hepatitis	1.11	0	0

Figure 2. **Incidence of different viral disease (%) in dog shelters from eastern Romania (Iasi, Botosani and Vaslui counties) in 2020 (first trimester)**

CONCLUSIONS

1. The present results suggest that there were outbreaks of canine parvovirus in the shelters included in this study, with CPV being the primary pathogen in all three shelters.
2. Due to the significant losses caused by viruses and the high costs of treating sick animals, there is a need for early diagnosis and the application of well-defined immunoprophylaxis measures in shelters.
3. This study reinforces the importance of immunization to ensure the welfare of dogs in public and private shelters.

REFERENCES

Andrukonis A, Brown KM, Hall NJ, Protopopova A., 2021. *Intake Vaccinations Reduced Signs of Canine Respiratory Disease During an Outbreak at an Animal Shelter. Frontiers in Veterinary Science,1;8:627580. doi: 10.3389/fvets.2021.6275*

Bhargavi M; Shobhamani B; Kumari KN; Srilatha C., 2017. Therapeutic management of dogs affected with canine parvo virus (CPV) infection. International Journal of Science, Environment and Technology. 6, 2797–2803.

Cleaveland S., 2009. *Viral threats and vaccination: disease management of endangered species***.** Animal Conservation, 12: 187-189. 10.1111/j.1469-1795.2009.00276.x

Decaro N, Buonavoglia C, Barrs VR., 2020. *Canine parvovirus vaccination and immunisation failures: Are we far from disease eradication?* Veterinary Microbiology, 247:108760. doi: 10.1016/j.vetmic.2020.108760

Decaro N, Buonavoglia C., 2012. *Canine parvovirus--a review of epidemiological and diagnostic aspects, with emphasis on type 2c.* Veterinary Microbiology, 24;155(1):1-12. doi: 10.1016/j.vetmic.2011.09.007

Franzo G; Corso B; Tucciarone CM; Drigo M; Caldin M; Cecchinato M., 2020. *Comparison and validation of different models and variable selection methods for predicting survival after canine parvovirus infection.* Veterinary Records, 1–8

Gaykwad C; Garkhal J; Chethan GE; Nandi S; De UK., 2018. *Amelioration of oxidative stress using N-acetylcysteine in canine parvoviral enteritis*. Journal of Veterinary Pharmacology and Therapy, 41, 68–75.

Gerlach M, Proksch AL, Dörfelt R, Unterer S, Hartmann K., **2020.** *Therapy of canine parvovirus infection - review and current insights*. Tierarztl Prax Ausg K Kleintiere Heimtiere, 48(1):26-37. doi: 10.1055/a-1020-3341.

Horecka K, Porter S, Amirian ES, Jefferson E., **2020.** A Decade of Treatment of Canine Parvovirus in an Animal Shelter: A Retrospective Study. Animals (Basel), 29;10(6):939. doi: 10.3390/ani10060939.

Iris Kalli Leontides LS; Mylonakis ME; Adamama-Moraitou K; Rallis T; Koutinas AF., **2010.** *Factors affecting the occurrence, duration of hospitalization and final outcome in canine parvovirus infection.* Research in Veterinary Science, 89, 174–178.

Kelman M, Barrs VR, Norris JM, Ward MP., 2020. *Canine parvovirus prevention and prevalence: Veterinarian perceptions and behaviors. Preventive Veterinary Medecine,* 174:104817. doi: 10.1016/j.prevetmed.2019.104817.

Khatri R; Poonam MH; Minakshi PC., **2017.** *Epidemiology, Pathogenesis, Diagnosis and Treatment of Canine Parvovirus Disease in Dogs: A Mini Review.* Journal of Veterinary Science and Medical Diagnosis, 6, 06.

Martella V, Elia G, Buonavoglia C., 2008. Canine distemper virus. Veterinary Clinical North American Small Animal Practice, 38(4):787-97, vii-viii. doi: 10.1016/j.cvsm.2008.02.007.

Pak S; Hwang C; Han H., 1999. *Prognostic factors for survival of dogs infected with canine parvovirus*.

Korean Journal of Veterinary Research, 39, 838–845.

Parrish C.R., Holmes E.C., Morens D.M., Park E.C., Burke D.S., Calisher C.H., Laughlin C.A., Saif L.J., Daszak P., 2008. *Cross-species virus transmission and the emergence of new epidemic diseases.* Microbiology and Molecular Biology Research. 72: 457-470. 10.1128/MMBR.00004-08.

Spindel M.E.; Krecic M.R.; Slater M.R.; Vigil, N. 2018. *Evaluation of a Community's Risk for Canine Parvovirus and Distemper Using Antibody Testing and GIS Mapping of Animal Shelter Intakes.* Journal of Applied Animal Welfare Science, 00, 1–13.

Velescu Elena, 2002. *Patologia bolilor infecţioase la animale*, 2002. Editura Terra Nostra, Iasi

RESEARCH REGARDING THE PRESENCE OF VIRAL INFECTIONS IN DOGS FROM SHELTERS IN EASTERN ROMANIA (BACĂU, VRANCEA AND GALAȚI COUNTIES)

Florin Jan VASILACHE[2], Elena VELESCU [1]

e-mail (first author): florinvj13@gmail.com

Abstract

The occurrence of viral diseases in a shelter may certainly be devastating to the health and welfare of animals and can create serious problems even for the best equipped additions. The purpose of this study was to investigate the incidence of infectious diseases in stray dogs in paddocks located in Bacău, Vrancea and Galați counties. The researches aimed to identify the causative agents of viruses in dogs in shelters located in the three counties in eastern Romania, Bacau, Vrancea and Galati, analysis of diagnostic methods used in the units, analysis of predisposing factors and analysis of surveillance and control measures. Parvovirus was the main viral disease observed among young dogs, aged between 1-7 months, its incidence varying between 28.18% and 68.18%. The diagnosis was established on the basis of the clinical picture, as well as by rapid tests, based on immunochromatography. Mortality in dogs diagnosed with parvovirus, in the 3 shelters included in the study, ranged from 32.72% to 66.66%. Other viral diseases, such as Carre's disease and kennel cough, were also diagnosed in the shelters included in the study. Promoting the vaccination of dogs and the control of the canine population by sterilization in the three counties included in the study can contribute to the prevention of viral diseases among stray dogs. The study provides support for preventive management actions aimed at protecting the health of stray dogs in public and private shelters.

Key words: viral disease; canine parvovirus; dog shelters; immunoprophylaxy

INTRODUCTION

Stray dogs are a topical issue in Romanian cities, and in recent years, this situation has become increasingly common in rural areas, especially in the metropolitan areas. Shelters for stray dogs have become a must and a necessity for local communities. Although many centers for strays dogs function across the country, there are multiple economic, managerial and pathophysiological factors that prevent, hinder or delay the completion of their main objectives. In recent years there has been a stagnation in the decrease in the number of stray dogs and the surplus of dogs present in the shelter centers is maximum, many of them being overcrowded. Overpopulation and inadequate housing conditions can amplify the underlying health concerns and expose the animals to a wide range of potentially dangerous infections. All of these variables can also play a role in the development and emergence of novel diseases, as well as changes in the virulence of existing viruses. This study aimed to identify the causative agents of viruses in dogs in shelters located in the three counties in eastern Romania, Bacau, Vrancea and Galati, analyze the diagnostic methods used in the units, analyze the predisposing factors and the surveillance, control measures.

MATERIAL AND METHOD

The research in this study was carried out in Bacău, Vrancea and Galati counties. The ANSVSA database and the website www.registru-câini.ro were accessed to obtain information regarding the location of shelters and the contact details of the responsible persons. According to the information present on the site, in Bacău County, there are 7 shelters, in Vrancea county there are 2 sheltersand in the Galati county there are 5 functional dog shelters shelters (Figure 1).

A formal request for information regarding the number of animals in the shelter in 2019 and 2020, the demographic characteristics of the canine population in the shelter, the presence of viral infectious diseases during the analyzed period, the therapy and treatment schemes implemented, as well as the implemented prophylaxis measures. One shelter from each county included in the study responded to the request formulated. Statistical analysis was performed using SPSS 25.0 statistical software.

[2] Iasi University of Life Sciences,
Faculty of Veterinary Medicine, Department of Public Health

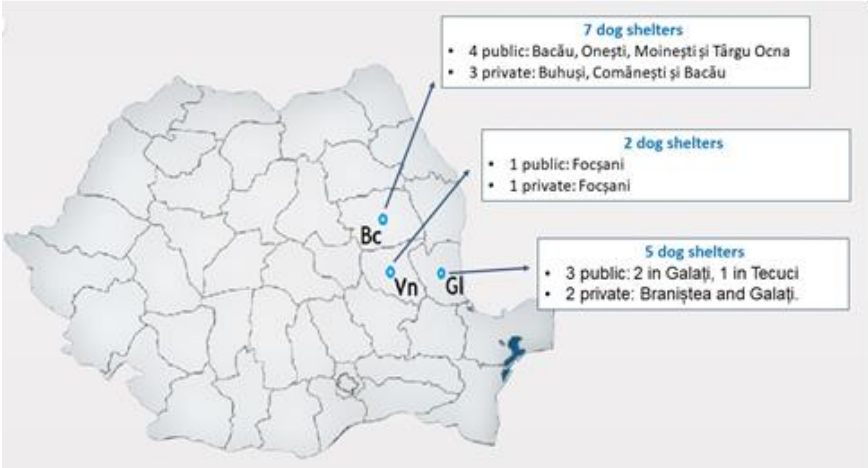

Figure 1 Location of dog shelters in the Eastern Romania (Bacau, Vrancea and Galati Counties)

RESULTS AND DISCUSSIONS

The number of dogs from the shelters included in the study varied between 1090 and respectively 2800 animals (figure 2, figure 3 and figure 4). In all three shelters included in the study, the number of dogs up to 5 years old was significantly higher, representing over 60% of the total population. Regarding the distribution by sex, the proportion of female animals varied between 55.21% and 67.55%, being significantly higher compared to males, in both adult dogs category, respectively youth. Parvovirus was the main viral disease observed among young dogs, aged between 1-7 months, its incidence varying between 28.18% and 68.18% (figure 5 and figure 6). The diagnosis was established on the basis of the clinical picture, as well as by rapid tests, based on immunochromatography. Mortality in dogs diagnosed with parvovirus, in the 3 shelters included in the study, ranged from 32.72% to 66.66%.

Other viral diseases, such as carre's disease and kennel cough, were also diagnosed in the shelters included in the study, the incidence varying between 7.54 and 7.55% for carre's disease and 0.42%, respectively 13.64% for kennel cough. The mortality rate for carre's disease was 20%.

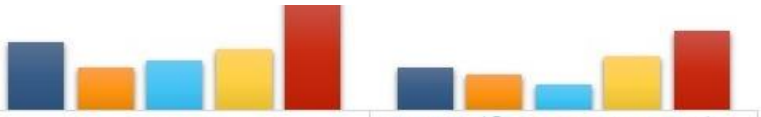

	2019	2020 (first trimester)
Adults	1700	1100
Young	1100	900
Males	1254	648
Females	1546	1352
Total	2800	2000

Figure 2. Demographic aspects from the shelter located in Bacau County

	2019	2020 (first trimester)
Adults	982	980
Young	110	110
Males	375	400
Females	717	690
Total	1092	1090

Figure 3. Demographic aspects from the shelter located in Vrancea County

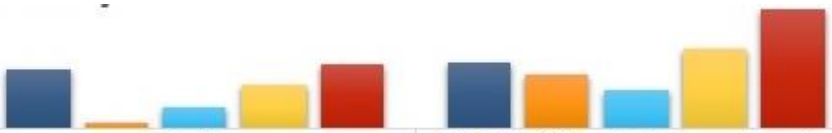

	2019	2020 (first trimester)
Adults	982	1100
Young	110	900
Males	355	649
Females	735	1351
Total	1090	2000

Figure 4. **Demographic aspects from the shelter located in Galati county**

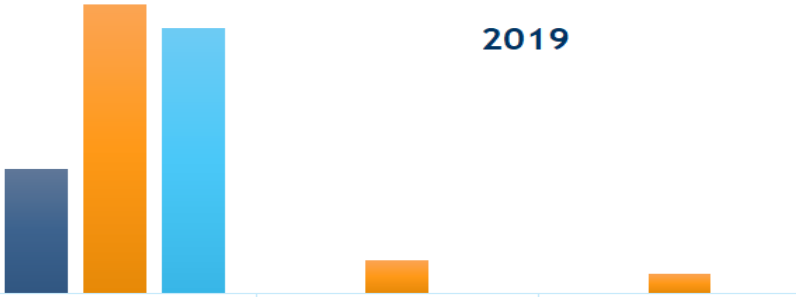

	Parvovirus (%)	Carre Disease (%)	Kennel cough (%)
Bacau	28.18	0	0
Vrancea	65.55	7.54	4.58
Galati	60	0	0

Figure 5. **Incidence of viral disease, in 2019, in dog population from shelters located in Bacau, Vrancea and Galati**

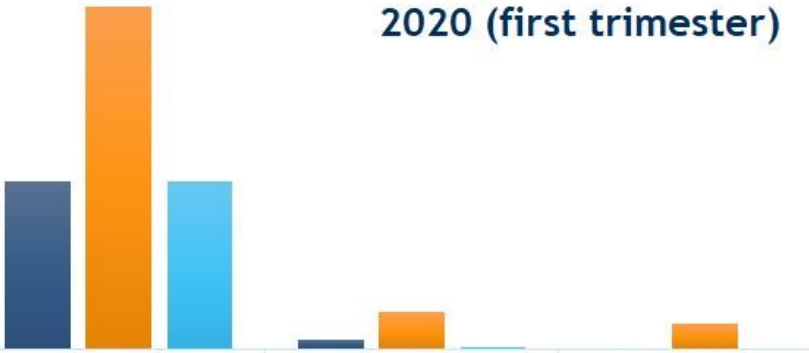

	Parvovirus (%)	Carre Disease (%)	Kennel cough (%)
Bacau	33.33	1.81	0
Vrancea	68.18	7.55	5.05
Galati	33.33	0.42	0

Figure 6. **Incidence of viral disease, in 2020 (first trimester) in dog population from shelters located in Bacau, Vrancea and Galati**

CONCLUSIONS

1) Due to overpopulation, complete prevention of viral diseases in dog shelters is an impossible goal to be achieve.
2) A well-implemented vaccination and cleaning program before the onset of diseases can go a long way in minimizing their spread.
3) Promoting the vaccination of dogs and the control of the canine population by sterilization in the three counties included in the study may contribute to the prevention of viral diseases among stray dogs.
4) The study provides support for preventive management actions aimed at protecting the health of stray dogs in public and private shelters.

REFERENCES

Brady S, Norris JM, Kelman M, Ward MP., 2012. *Canine parvovirus in Australia: the role of socio-economic factors in disease clusters*. Veterinary Journal, 193(2):522-528. doi: 10.1016/j.tvjl.2012.01.025.

Brunner CJ and Swango LJ., 1985. *Canine parvovirus infection: effects on the immune system and factors that predispose to severe disease.* Compendium Continuous Education and Veterinary Practice, 7: 979-988

Goddard A, Leisewitz AL. 2010. *Canine parvovirus.* Vetinary Clincal North American Small Animal Practice, 40(6):1041-53. doi: 10.1016/j.cvsm.2010.07.007.

Houston DM, Ribble CS, Head LL., 1996. *Risk factors associated with parvovirus enteritis in dogs: 283 cases (1982-1991).* Journal of American Veterinary Medical Association, 15;208(4):542-6.

Kelman M, Barrs VR, Norris JM, Ward MP., 2020. *Canine parvovirus prevention and prevalence: Veterinarian perceptions and behaviors*. Preventive Veterinary Medicine, 174:104817. doi: 10.1016/j.prevetmed.2019.104817

Moga Manzat R., 2009. *Boli virotice si prionice ale animalelor***,** Editura Brumar.

Mueller S.C., Teuber L.R., 2007 - *Alfalfa Growth and Development*. In: Summers C.G. and Putnam D.H., (eds), *Irrigated alfalfa management for Mediterranean and Desert zones*, Chapter 3, University of California Agriculture and Natural Resources Publication 8289.

Mylonakis ME, Kalli I, Rallis TS., **2016.** *Canine parvoviral enteritis: an update on the clinical diagnosis, treatment, and prevention*. Veterinary Medicine (Auckl). 11;7:91-100. doi: 10.2147/VMRR.S80971

Rika-Heke T, Kelman M, Ward MP., 2015. *The relationship between the Southern Oscillation Index, rainfall and the occurrence of canine tick paralysis, feline tick paralysis and canine parvovirus in Australia*. Veterinary Journal, 205(1):87-92. doi: 10.1016/j.tvjl.2015.03.012

Sanz-Sáez Á., Erice G., Aguirreolea J., Muñoz F., Sánchez-Diaz M., Irigoyen J.J., 2012 - *Alfalfa forage digestibility, quality and yield under future climate change scenarios vary with Sinorhizobium meliloti strain*. Journal of Plant Physiology, 169:782-788.

Velescu E, 2002. *Patologia bolilor infecţioase la animale***,** Editura Terra Nostra, Iasi**.**

Zourkas E, Ward MP, Kelman M., 2015. *Canine parvovirus in Australia: A comparative study of reported rural and urban cases.* Veterinary Microbiology, 181(3-4):198-203. doi: 10.1016/j.vetmic.2015.10.009.

Mueller S.C., Teuber L.R., 2007 - *Alfalfa Growth and Development*. In: Summers C.G. and Putnam D.H., (eds), *Irrigated alfalfa management for Mediterranean and Desert zones*, Chapter 3, University of California Agriculture and Natural Resources Publication 8289.

Sanz-Sáez Á., Erice G., Aguirreolea J., Muñoz F., Sánchez-Diaz M., Irigoyen J.J., 2012 – *Alfalfa forage digestibility, quality and yield under future climate change scenarios vary with Sinorhizobium meliloti strain*. Journal of Plant Physiology, 169:782-788.

PROMOTING SUSTENABILITY IN FAMILY-SIZED DAIRY FARMS FROM NORTH-EAST OF ROMANIA - USE OF THERMOGRAPHY FOR MONITORING UDDER HEALTH AND IMPROVEMENT OF MILK QUALITY (PRELIMINARY STUDY)

Andra-Sabina NECULAI-VALEANU[1] Adina-Mirela ARITON[1], Cristina-Mihaela RÎMBU[2]

e-mail (first author): sabina.valeanu@gmail.com

Abstract

Romania is a country with a lot of potential for high-quality food production. However, despite rising demand for milk and dairy production, the production has been declining in recent years and Romanian milk farmers face growing competition from other farms on a national and international basis in terms of production and milk quality. The aim of the present study was to assess the potential use of a phone-connected infrared camera, as a potential non-invasive tool for the monitoring of udder health and control of bovine subclinical mastitis in family-size farms. The somatic cell count (SCC) (r=0.79) was positively correlated with the udder skin surface temperature (USST), a difference of 1.4 °C being observed between healthy and mastitis affected quarters. Infrared thermal imaging using phone-connected camera could be used as a potential noninvasive, quick cow-side diagnostic method for monitoring udder health and improvement of milk quality in family-sized farms.

Key words: bovine mastitis; milk quality; thermovision camera; somatic cell count;

Introduction

Romania is a country with a lot of potential for high-quality food production. However, despite rising demand for these goods, milk and dairy production has been declining in recent years. The foundations for milk production are favorable, but a lack of comprehension regarding current agricultural production methods appears to be a challenge, especially for the family-sized farms. According to the estimates, in Romania, there are about 1,190,000 dairy cows, 604,000 dairy farms, the average herd size being 2.4 cows per farm. The average annual production per cow is around 2,500 liters. Around 4 millions tones of milk are produced, but only one quarter is being processed by the dairies (Dairy Focus Report, 2019). The rest is consumed on-farm or sold directly to consumers. Dairies receive about 1 million tones of milk, which is mostly processed into dairy products such as yogurt, kefir, cheese and butter (Figure 1).

Although the cattle population is comparable to other EU states, Romania is among the last in terms of annual production, mainly due to the rather low average milk yield per cow per year, which is around 3 000 kg. In our country, there is a dual animal husbandry, with large industrial units and intensive operation and smaller units, the so called family farms, most of which are not modernized, thus this farmers face growing competition from other farms on a national and international basis. The vast majority of the family-sized farms produce milk and meat at high costs compared to other European countries but the milk price in Romania is currently lower comparative with other countries from which milk is imported such as Poland. However, these types of units are an important source of good quality agri-food products, therefore they represent a priority in the Romanian rural economy. To ensure the sustainability of the family farms it is imperative to support dairy farmers to produce milk according to E.U standards, in order to obtain an advantageous, competitive price for it. This objective may be achieved by improving the current agricultural technologies and by improving udder health and implicitly the quality of milk. In Romania, the incidence of bovine subclinical mastitis is still high and recurrence of mastitis is very common (Rosca et al, 2008). In contrast to clinical mastitis, which is defined by obvious symptoms of inflammation and milk abnormalities, subclinical mastitis is defined by subtle changes in milk composition and quality, with no evidence of gross inflammation or abnormalities. Dairy farmers must improve their expertise in order to improve production costs, milk quality and lower the quantity of antibiotics used in farms. Farmers' needs

[1] [1]Research Station for Cattle Breeding Dancu, Iasi, Laboratory of Food Safety and Animal Biology
[2]Iasi University of Life Science, Faculty of Veterinary Medicine, Department of Public Health

for knowledge and their feeling of necessity for acquiring new knowledge differs greatly. The majority of the younger age farmers have visited farms in other countries or extensively documented themselves, which has influenced their perceptions regarding the potential use of technology to improve both productivity and animal health.

The aim of the present study was to assess the potential use of a phone-connected infrared camera, as a potential non-invasive tool for the monitoring of udder health and control of bovine subclinical mastitis in family-size farms.

Figure 1. **Romanian dairy sector in number**

MATERIAL AND METHOD

Investigations were carried out in 4 family-size farms from Iasi and Vaslui counties. A total number of 13 of cows, at second to fourth lactation were included in the study. Over a time period of five days, thermograms and samples of milk from of all quarters (n=52) were taken in each morning, before milking. For each cow, three thermal images were acquired using a phone-connected thermovision camera (Flir One Pro, USA), corresponding to the right and left front and rear udder.

The total number of somatic cells from the milk samples was assessed using the FTIR CombiScope (Delta instruments, USA), in the Laboratory of Food Safety and Animal Biology of the Research and Development Station for Cattle Breeding Dancu, Iasi.

ANOVA was used to compare the findings of healthy cows and cows with subclinical mastitis in terms of udder skin surface temperature (USST) and somatic cell count (SCC). A Pearson's test was used to determine the relationship between the USST and the SCC. Correlations less than 0.3 were considered weak, those between 0.3 and 0.7 were considered moderate, and those more than 0.7 were regarded strong. The regression model was used to correlate USST with SCC as an indication for healthy cows and mastitis-infected cows.

RESULTS AND DISCUSSIONS

udder health. Monitoring udder health is essential for the early detection and successful control of bovine subclinical mastitis.

For the early identification of changes in milk associated with bovine subclinical mastitis, many methods and biomarkers are available. Somatic cell count (SCC) is an essential indicator for milk hygiene and animal health. An increased SCC level in milk is usually used as an indication for udder infection (mastitis) in lactating cows. However, this diagnosis techniques is rather laboratory-oriented, requiring well-trained personnel and expensive equipment (Narayana et al., 2018). The somatic cell count threshold for identifying cases of subclinical mastitis varies between studies, from $100x10^3$ cells (Sumon et al., 2020) to $310x10^3$ somatic cells/ml of milk (Jadhav et al., 2018).

Precision dairy farming is now focusing on automated approaches for the early and efficient detection of bovine subclinical mastitis (Chakraborty et al., 2019). The temperature of udder skin surface was proposed as an useful marker for

the diagnosing diseases and assessing the physiological status of cows (Machado et al., 2021), although further refinements are needed. IRT (infrared thermography) is a fast, inexpensive, on-shown that IRT may be used to identify subclinical mastitis and clinical mastitis in both large and small ruminants (Costa et al., 2014; Metzner et al., 2014). Skin surface temperature is an indicator of the tissue metabolism and blood circulation, thus aberrant thermal patterns might indicate regions of surface inflammation or circulatory dysfunctions. In mastitis, the inflammatory reaction is primarily accompanied by an increase in the udder surface temperature. The surface heat emitted as infrared radiation may be detected by a thermal camera, which captures infrared radiation and produces visual pictures based on the amount of heat emitted (Figure 2). On the thermograph, the warmest areas are bright yellow or white, whereas the coldest areas appear dark blue or violet.

farm, and noninvasive technique that enables the detection of surface heat under the form of infrared radiation, subsequently generating visual pictures (thermograms). Several studies have

In this current study, the diagnostic usefulness of IRT as an indirect marker of bovine subclinical mastitis was compared to Automated Somatic Cells Count (SCC).

The individual cutoff for for subclinical mastitis was set at 200x103 cells per ml of milk, in accordance with national and international good practice recommendations (Narayana et al., 2018). The SCC (r=0.79) was positively correlated with the udder skin surface temperature (Figure 3). In cows with subclinical mastitis (n=8), the mean ± standard deviation USST was 38.0±0.3°C, individual values varying between 37.7 and 38.5°C) while in healthy cows, the mean ± standard deviation USST was (36.6 ±0.3°C), individual values ranging from 35.4 and 37.3°C) (Table 1).

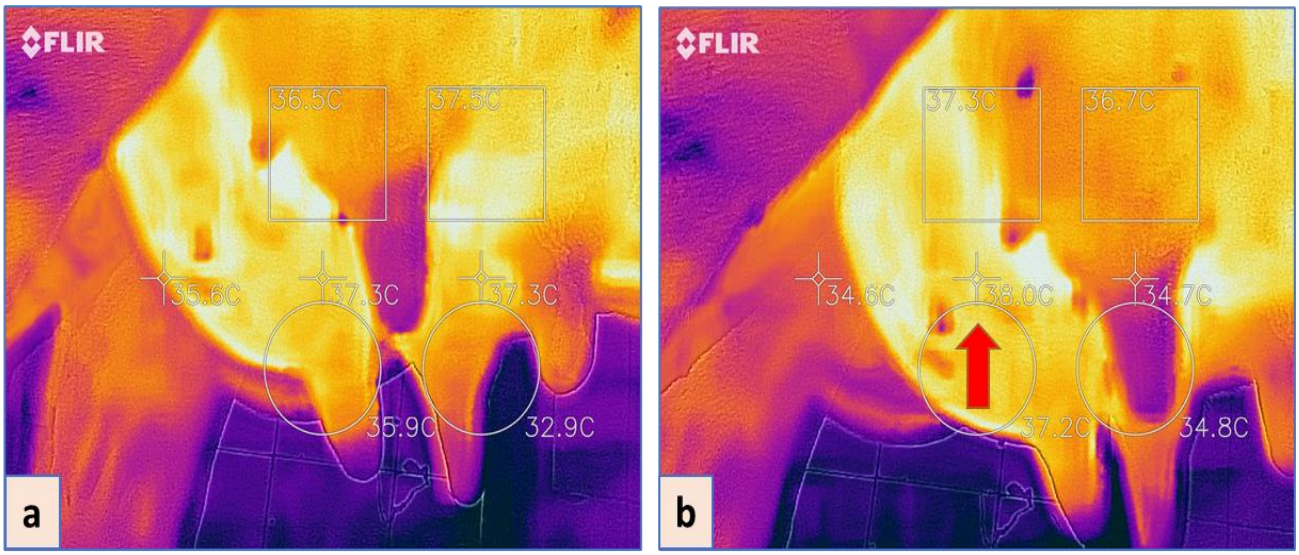

Figure 2**. Infrared thermogram of udder quarters from the lateral side. Red arrows indicates elevated temperature (38°C)**

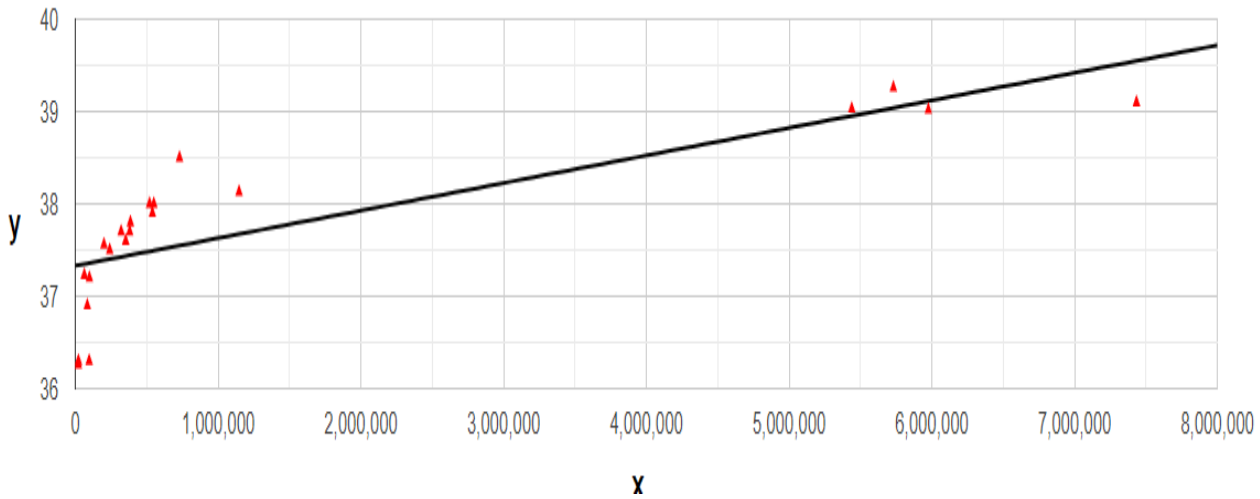

Figure 2. **Linear regression relating udder skin surface temperature with somatic cell count (SCC)**

Table 1

Descriptive statistics of the USST (°C) and SCC

Statistical parameters	Negative (n=24)		Positive (n=28)	
	SCC	USST (°C)	SCC x 10^3/ml	USST (°C)
Minimum	21	35.4	200	37.7
Maximum	98	37.3	7434	38.5
Mean	64	36.6	1989	38
SD	35	0.3	254	0.3

According to a studies carried out by Scott et al., 2000, Hovinen et al., 2008, the USST is progressively increasing 3 days before the instalment of clinical signs, in both natural and experimental induced mammary infections.

In the present study, a phone-connected thermovision camera was used to assess the USST, a difference of 1.4 °C being observed between healthy and mastitis affected quarters. Among the advantages of this thermal imaging camera are the ease of operation and the possibility of using it for other purposes as well (e.g. assessing the thermal stress of farm animals or the health of the hooves). Further studies are needed to refine the methodology for image prelevation and interpretation, taken into consideration other variables such as environment, type of animal coat.

CONCLUSIONS

Infrared thermal imaging using phone-connected camera could be used as a potential noninvasive, quick cow-side diagnostic method for monitoring udder health and improvement of milk quality in family-sized farms.

REFERENCES

Roşca P., Drugociu D., Runceanu L., Hromei N., Ciornei Şt., 2008. *Observation concerning the dynamic of the milk production in cows with clinical mamitis. Bulletin of University of Agricultural Sciences And Veterinary Medicine Cluj-Napoca. Veterinary Medicine, 65, (2), 136-139*

Kakati S., Talukdar A., Hazarika R.A., Raquib M., Laskar S.K., Saikia G.K., Hussein Z., 2021. *Bacteriological quality of raw milk marketed in and around Guwahati city, Assam, India.* Veterinary World, 14(3):656-660.

Chakraborty S., Dhama K., Tiwari R., Iqbal Yatoo M., Khurana SK, Khandia R, Munjal A, Munuswamy P., Kumar M.A., Singh M., Singh R., Gupta V.K., Chaicumpa W., 2019. *Technological interventions and advances in the diagnosis of intramammary infections in animals with emphasis on bovine population-a review.* Veterinary Q. (1):76-94

Machado N.A.F, Da Costa L.B.S, Barbosa-Filho J.A.D., De Oliveira K.P.L., De Sampaio L.C., Peixoto M.S.M., Damasceno F.A., 2021. *Using infrared thermography to detect subclinical mastitis in dairy cows in compost barn systems*. Journal of Thermal Biology, 102881. doi: 10.1016/j.jtherbio.2021.102881

Narayana S.G., Miglior F., Naqvi S.A., Malchiodi F., Martin P., Barkema H.W., 2018. *Genetic analysis of subclinical mastitis in early lactation of heifers using both linear and threshold models.* Journal of Dairy Science, 101(12):11120-11131. doi: 10.3168/jds.2018-15126

Metzner M., Sauter-Louis C., Seemueller A., Petzl W., Klee W., 2014. *Infrared thermography of the udder surface of dairy cattle: Characteristics, methods, and correlation with rectal temperature*. Veterinary Journal, 199:57–62

Costa A.C, Caja G, Salama A.A.K, Rovai M, Flores C, Aguilo J., 2014. *Thermographic variation of the udder of dairy ewes in early lactation and following an Escherichia coli endotoxin intramammary challenge in late lactation*. Journal of Dairy Science, 97:1377–1387

Dairy Focus Report, Romanian EU Presidency, 2019. http://eda.euromilk.org/fileadmin/user_upload/Public_Documents/Dairy_Focus/Dairy_Focus_Romania_2019.pdf. Accessed August 2021.

Jadhav P.V., Das D.N., Suresh K.P., Shome B.R., 2018. *Threshold somatic cell count for delineation of subclinical mastitis cases.* Veterinary World, 11(6):789-793. doi: 10.14202/vetworld.2018.789-793.

Sumon S.M.M.R., Parvin M.S., Ehsan M.A., Islam M.T., 2020. *Relationship between somatic cell counts and subclinical mastitis in lactating dairy cows*. Veterinary World, 13(8):1709-1713. doi: 10.14202/vetworld.2020.1709-1713.

Scott S.L, Schaefer A.L, Tong A.K.W, Lacasse P., 2000. *Use of infrared thermography for early detection of mastitis in in dairy cows.* Canadian Journal of Animal Science, 80:764

Hovinen M, Siivonen J, Taponen S, Hanninen L, Pastell M, Aisla A.M, Pyorala S., 2008. *Detection of clinical mastitis with the help of a thermal camera*. Journal of Dairy Science, 91:4592–45

FORMULATION AND EVALUATION OF ANTIBACTERIAL PHYTOTHERAPEUTIC GELS CONTAINING METAL IONS AND ESSENTIAL OILS

Andra-Sabina NECULAI-VALEANU[3], Adina-Mirela ARITON [1], Cristina-Mihaela RÎMBU [4], Cristina-Horhogea[2]

e-mail corresponding author): crimbu@yahoo.com

Abstract

The purpose of this study was to develop topical phytotherapeutic gels containing essential oils alone or in combination with copper ions and to assess their antibacterial activity in vitro. Following the formulation of the gels, the organoleptic properties, physicochemical properties, and in vitro antibacterial activity against Escherichia coli and Staphylococcus aureus were evaluated. Copper sulfate demonstrated strong synergistic antibacterial activity when combined with the selected essential oil blend. This preliminary study assessed and confirmed the synergistic antimicrobial properties of sulfate copper and essential oils in phytotherapeutic formulations with topical applications.

Key words: phytotherapeutic gel; essential oils; metal ions; copper sulfate

Introduction

Due to the rising concerns regarding multidrug-resistant pathogens, the need for novel therapeutics has grown considerably, the emphasis being now placed on the development of innovative and effective alternatives to conventional antimicrobials. From ancient times the people have used it extensively natural herbal products as medicines against various diseases. According to a study conducted by Mohanty et al., 2019, almost 25% of the main pharmaceutical products and their derivatives available today are obtained from natural resources, therefore phytotherapy can be a good starting point for the development of products with antimicrobial activity (Bhinge et al., 2017; Morteza-Semnani et al., 2021). More recent research has shown that the effectiveness of phytotherapy and essential oils could be greatly improved, even against antibiotic-resistant pathogens, by its association with metal ions (Low et al., 2017; Prasad et al., 2021). The most frequently investigated metal ions as possible antibacterial agents are silver, copper, zinc, and iron (Holloway et al., 2012; Morrill et al., 2013) have been investigated in recent years. The antimicrobial properties of copper are widely recognized and it has been used successfully as biocide and antifungal. Cooper may bind to protein molecules leading to DNA denaturation and inactivation of bacterial enzymes.

In spite of their great potential in the development of novel antimicrobial agents, the incorporation of metal ions in topic formulations may be challenging because even in small concentrations, the oxidation processes in fatty molecules may be enhanced, causing visible degradation of the product (color, texture and odor modifications). Thereby, the quality, effectiveness, consumer appeal, and shelf-life of formulations may be affected by metal ion interactions with the components. The purpose of this study was to develop topical phytotherapeutic gels containing essential oils alone or in combination with copper ions and to assess their antibacterial activity in vitro.

MATERIAL AND METHOD

The polymer used to make the gels, xanthan gum, was dispersed in the aqueous plant extract (at 75°C), cinnamon or oregano under stirring. When the polymer was dissolved, the mixture was removed from the heat source. The essential oils (oregano, cinnamon, clove, eucalypt, thyme, lavender) were added slowly to the gel basis, with continuous stirring, to ensure proper encapsulation. The final weight of the gel was adjusted to 50 g with distilled water. For all formulations, certain characteristics were assessed by visual observation, such as physical appearance, color, texture, phase separation, and homogeneity. Homogeneity and

[3] Research Station for Cattle Breeding Dancu, Iasi, Laboratory of Food Safety and Animal Biology
[2] Iasi University of Life Science, Faculty of Veterinary Medicine, Department of Public Health

texture were tested by pressing a small amount of gel between the thumb and forefinger.

The consistency of the formulations and the presence of coarse particles were analyzed to evaluate the texture and homogeneity of the formulations. Immediate skin sensation (including stiffness, oily sensation) was also assessed. The spread ability of the product was determined by measuring the spreading diameter of 1 g of gel sample between two horizontal glass plates (10 cm × 20 cm) after one minute. The standard weight applied to the top plate was 25 g. Each formulation was tested three times. The pH was determined using a ph-meter. One gram of each formulation was dissolved in 25 ml of deionized water. The PH-meter was calibrated with standard buffers (pH 4, 7 and 10) before each use.

The qualitative assessment of the antimicrobial activity of the hydrogels was performed in triplicate, by the diffusimetric technique. For this, 50 ul of hydrogel was distributed in Petri dishes with Muller Hinton culture medium previously sown with various standardized microbial species: *Staphylococcus aureus* ATCC 6538, *Staphylococcus epidermidis* ATCC 12228, *MRSA* ATCC 43300, *Escherichia coli* ATCC 25922, *Pseudomonas aeruginosa* ATCC 9027, *Candida albicans* ATCC 90028. Evaluation of the antimicrobial effect was performed by measuring the area of inhibition created from the edge of the hydrogel spot to the edge of the microbial culture.

RESULTS AND DISCUSSIONS

Hydrogels are three-dimensional network structures that may absorb large amounts of water and have numerous applications in fields such as biomedicine and pharmacology. Hydrogels adhere to the skin and allow an efficient release of active substances. They also spread easily in a thin layer and can be easily removed by washing. However, for a proper formulation of this type of product, a number of practical aspects must be taken into consideration.

The active and auxiliary ingredients play an important role in the formulation process. These ingredients have a decisive influence on the physicochemical properties of the formula, in order to obtain the desired therapeutic effect. The release and absorption of active substances from the hydrogel depends on a number of factors such as the nature of the polymer used, the physicochemical properties of the incorporated ingredients.

The hydrogels in this study were obtained from colloidal macromolecules which have the property of combining with water or other hydrophilic solvents by absorption. For the formulation of gel basis, we selected excipients without irritating action, suitable for the place of application, respectively the mammary gland. In this regard, we used xanthan gum as both gelling and thickening agent. Due to its well-known antimicrobial and antiviral activity, copper sulfate pentahydrate (CuSO4 5H2O) (Figure 1) was selected as one of the key active components in the elaborated topical formulations. In a gel formulation, isopropyl myristate was utilized as an emollient to offer a softening or soothing effect on the skin.

Glycerin was added to the gel composition and served as a humectant, enhancing the hydration of the stratum corneum. Cinnamon and turmeric extracts were used as solvents, to disperse the water-soluble ingredients. The essential oils used for the formulation of the topical gels were selected based on their antibacterial, anti-inflammatory proprieties and synergistic potential (Neculai-Valeanu et al., 2021). Cosgard, an easy-to-use and approved preservative for use in organic cosmetics ensured the efficient preservation of the topic formulations.

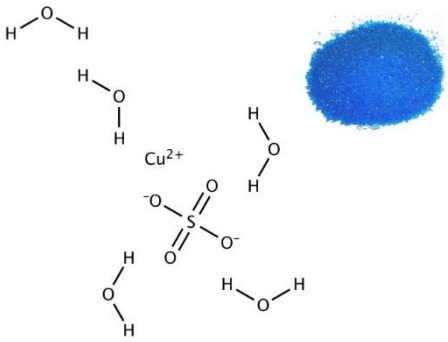

Figure 1 **Copper (II) sulfate pentahydrate**

The polymer was hydrated with distilled water before the dispersion in the cinnamon extract, alongside the other active ingredients. Three different gels were formulated in this study.

R1 and R2 contained only copper sulfate, respectively essential oils incorporated in the gel basis, while R4-13 gel contained both essential oils and sulfate copper. Table 1 shows the organoleptic characteristics of the evaluated topical gels, including physical appearance, color, texture, phase separation, homogeneity, and initial skin sensation. The gels had a visual appealing appearance and smooth texture, and they were all uniform with no evidence of phase separation. The copper sulfate gave the formulation a green-blue color (Figure 2). R1 gel, containing only copper sulfate incorporated in the polymer matrix presented a light blue color.

The spread ability plays an essential role in the effectiveness of topical therapy, which depends on the operator spreading the formulation in a uniform layer to administer a standard dose. In our study, the spread ability of the developed gels varied between 48 mm and 59.52 mm (Table 1). The gel containing only essential oils presented the highest spread ability, 59.52 mm (Figure 3).



Figure 2. **Visual aspect of formulated topical gels**

Table 1

Physico-chemical characteristics of the gel formulations

Formulation	Physical appearance	Color	Texture	Phase separation	Homogenity	Immediate skin sensation	pH	Spredability (mm)
R1	Semi Transparent	Intese Blue	Smooth	no	yes	Moisturizing No signs of coarse particles	6.78 ± 0.08	48 ± 0.11
R2	Transparent	Light yellow	Smooth	no	yes	Refreshing, Cooling No signs coarse particles	6.26± 0.06	55. 91 ± 0.08
R413	Semi transparent	Green-blue	Smooth	no	yes	Moisturizing Refreshing Cooling No signs coarse particles	6.08 ± 0.04	59.52 ± 0.10

The in vitro antibacterial activity of the three gels was assessed by comparing the inhibition zone (in mm) of each product (Figure 3).

The zone of inhibition can be defined as the clear region surrounding the hydrogel drop. The antimicrobial agent's potency is known to be proportional to the size of the inhibition zone. The results obtained from the conducted study are shown in figure 4.

It may be observed that the lowest antimicrobial activity was reported in the R1 hydrogel containing only metal ions (cooper sulfate). *Staphylococcus epidermidis* (8.2 mm) compared to other Gram-positive bacterial species: *Staphylococcus aureus* (4.6 mm), MRSA (3.8 mm) and Gram-negative bacteria: *Escherichia coli* (3.2 mm) and *Pseudomonas aeruginosa* (2 mm). The antimicrobial effect on *Candida albicans* yeast (4.6 mm) was similar to that for Gram-positive bacteria.

R2 hydrogel showed significantly better antimicrobial activity compared to the results of inhibition activity of the R1 hydrogel. This inhibitory effect was due to the active compounds from the essential oils of oregano, cinnamon, clove, eucalyptus, thyme, lavender.

The most sensitive microbial species were *Staphylococcus epidermidis* (12.7 mm) and *Candida albicans* (12 mm).

The extended effect of the combination of essential oils is known, and this aspect can be noticed by the zones of inhibition created against *Escherichia coli* (7.4 mm) and MRSA (6.4 mm).

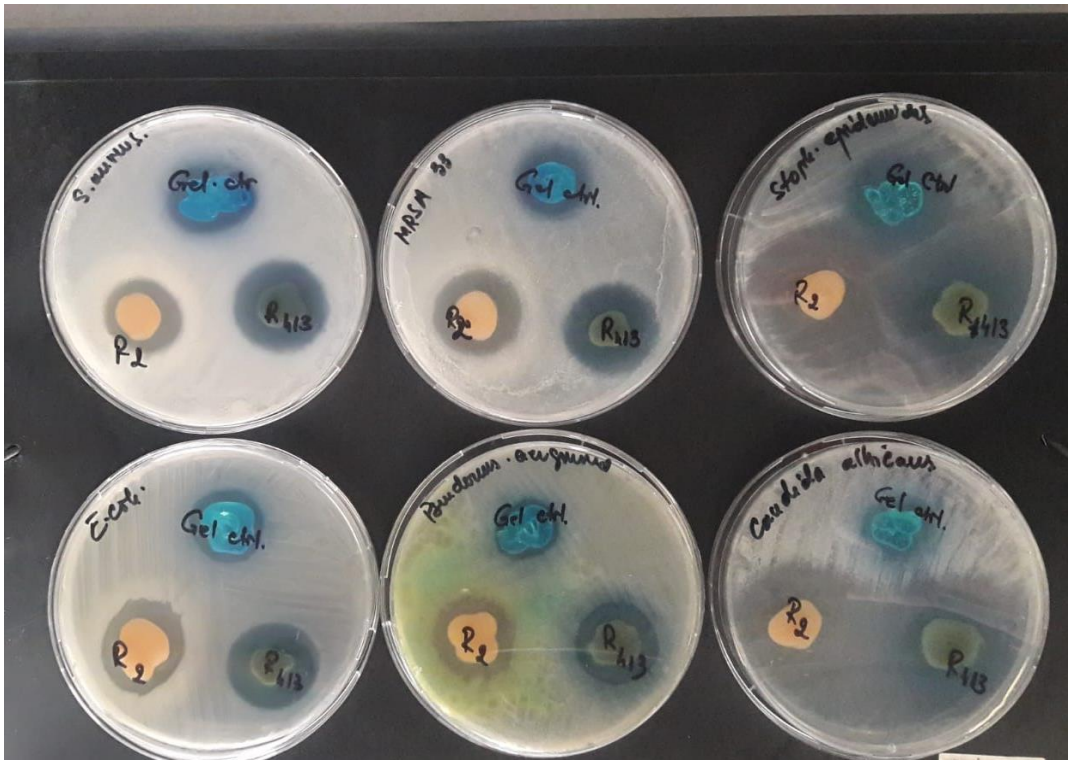

Figure 3. **Antibacterial evaluation of the formulated gels**

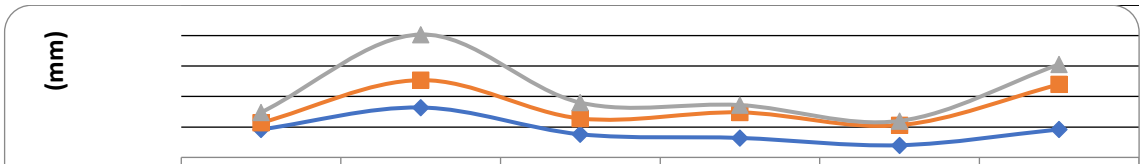

	Staphylococcus aureus ATCC 6538	Staphylococcus epidermidis ATCC 12228	MRSA ATCC 33591	Escherichia coli ATCC 25922	Pseudomonas aeruginosa ATCC 9027	Candida albicans ATCC 90028
R1 x̄	4.6	8.2	3.8	3.2	2	4.6
R2 x̄	5.7	12.7	6.4	7.4	5.3	12
R413 x̄	7.4	20.2	9	8.6	6	15.3

Figure 4. **Mean arithmetic value obtained from three tests**

Hydrogel R4-13, formed by combining compounds from hydrogels R1 and R2, cumulated their inhibitory effects, and the results were confirmed by the increasing diameter of the inhibition zones formed around all tested microbial species. *Staphylococcus epidermidis* (20.2 mm) and *Candida albicans* (15.3 mm) remain the most sensitive microbial species. The antimicrobial action developed

against MRSA ATCC 33591 (9 mm), a strain of methicillin-resistant *Staphylococcus aureus* with important public health implications, is noted. Also, the antimicrobial effect obtained against *Escherichia coli* (7.4 mm) and *Pseudomonas aeruginosa* (6 mm) is very important, as it is known that Gram-negative bacteria have a different cell wall structure than Gram-positive bacteria, structure that makes them more resistant and gives them a different response to various antimicrobial agents.

The minimal evaluation of the antimicrobial activity of these hydrogels, compared to the three types of microorganisms (Gram positive bacteria, Gram negative bacteria and yeasts) shows the potential of the selected active compounds and the results encourage further testing and explanation of the mechanisms by which this antimicrobial effect is created, compared to antibiotic-resistant strains.

The antimicrobial potential of these hydrogels must be transferred, tested and confirmed *in vivo*, so that this drug formula becomes a therapeutic option.

CONLUSIONS

1. The physico-chemical structure of the hydrogels R1, R2 and R 3-14 allowed the release of the compounds and the evaluation of their antimicrobial effect against all the microbial strains tested.
2. The antimicrobial activity was different depending on the composition of the hydrogels and the microbial type.
3. Gram-positive bacterial strains showed the best sensitivity to the tested hydrogels.
4. *In vitro*, hydrogels were equally active against methicillin-susceptible and methicillin-resistant strains of *Staphylococcus aureus*.
5. The yeast Candida albicans had a sensitivity profile similar to Gram-positive strains.
6. The most active hydrogel formula was R 3-14 which incorporated copper sulfate and the essential oils of oregano, cinnamon, clove, eucalyptus, thyme, lavender.

REFERENCES

Low WL, Kenward K, Britland ST, Amin MC, Martin C. Essential oils and metal ions as alternative antimicrobial agents: a focus on tea tree oil and silver. Int Wound J. 2017 Apr;14(2):369-384. doi: 10.1111/iwj.12611.

Prasad S, DuBourdieu D, Srivastava A, Kumar P, Lall R. Metal-Curcumin Complexes in Therapeutics: An Approach to Enhance Pharmacological Effects of Curcumin. Int J Mol Sci. 2021 Jun 30;22(13):7094. doi: 10.3390/ijms22137094

Bhinge SD, Bhutkar MA, Randive DS, Wadkar GH, Todkar SS, Kakade PM, Kadam PM. Formulation development and evaluation of antimicrobial polyherbal gel. Ann Pharm Fr. 2017 Sep;75(5):349-358. doi: 10.1016/j.pharma.2017.04.006

Morteza-Semnani K, Saeedi M, Akbari J, Eghbali M, Babaei A, Hashemi SMH, Nokhodchi A. Development of a novel nanoemulgel formulation containing cumin essential oil as skin permeation enhancer. Drug Deliv Transl Res. 2021 Jul 17. doi: 10.1007/s13346-021-01025-1.

Morrill K, May K, Leek D, Langland N, Jeane LD, Ventura J, Skubisz C, Scherer S, Lopez E, Crocker E, Peters R, Oertle J, Nguyen K, Just S, Orian M, Humphrey M, Payne D, Jacobs B, Waters R, Langland J. Spectrum of antimicrobial activity associated with ionic colloidal silver. J Altern Complement Med. 2013 Mar;19(3):224-31. doi: 10.1089/acm.2011.0681.

Holloway AC, Mueller-Harvey I, Gould SW, Fielder MD, Naughton DP, Kelly AF. The effect of copper(II), iron(II) sulphate, and vitamin C combinations on the weak antimicrobial activity of (+)-catechin against Staphylococcus aureus and other microbes. Metallomics. 2012 Dec;4(12):1280-6. doi: 10.1039/c2mt20143g.

Sanz-Sáez Á., Erice G., Aguirreolea J., Muñoz F., Sánchez-Diaz M., Irigoyen J.J., 2012 - Alfalfa forage digestibility, quality and yield under future climate change scenarios vary with Sinorhizobium meliloti strain. Journal of Plant Physiology, 169:782-788.

THE INCREASE IN THE PHOTODYNAMIC POTENTIAL OF DACARBAZINE AS A RESULT OF PH DEPENDENCE

Ana-Maria COMAN[5, 2], Radu FUMĂREL [1], Valentin BUDAŞCU[3], Diana Mihaela ALEXANDRU[3]

e-mail (first author): coman.ana_maria@yahoo.com

Abstract

Photostimulated chemotherapy (PSChT) is a relatively new therapeutic method whose principle is based on increasing the therapeutic index of certain cytostatics as a result of their interaction with optical radiation. For a particular chemotherapeutic agent to be effective in PSChT-type applications, it must fulfill several conditions, the most important of which is to have a positive photodynamic potential that consists in the resonant transfer of energy between the irradiation source and its molecule. In this study, Dacarbazine (DTIC) was used as the photosensitizing agent, and a high-pressure mercury lamp was used as the irradiating agent. Preclinical studies in BL / 6 inbred mice carrying B16 murine melanoma and spectrophotometric determinations were performed to identify whether the DTIC-PSChT method enhances the efficacy of chemotherapy.

Key words: photostimulated chemotherapy (PSChT), dacarbazine, murine B16 melanoma, tautomerization

INTRODUCTION

At the beginning of the 21st century, cancer, as a biological phenomenon, is among the main morbid entities, as a degenerative disease, with a serious evolution. Due to its consequences on multiple levels: human, economic and social, the image of cancer persists in the darkest of all known diseases, being surrounded by a myth of incurability and suffering. And yet, the accumulated knowledge, both scientific and therapeutic, has begun to dispel this myth of helplessness and to outline possible ways to eliminate this disease.

One of the most aggressive forms of cancer is malignant melanoma, which has as its starting point at the melanocytic system. It is frequently found on the skin, but it can also be found in other tissues and organs that contain melanocytes.

This tumor is intensively studied due to its increased prevalence at relatively younger ages compared to other neoplasms, the increasing incidence, the metastatic potential, high resistance to currently available therapeutic protocols and high mortality (Diaconu I. et al., 1996; Ferlay J. et al., 2012; Forsea A.M. et al., 2012).

One of the active substances used in standard therapeutic protocols for metastatic malignant melanoma is dacarbazine (5- (3,3-dimethyl-1-triazeno) imidazole-4-carboxamide). Also known as imidazole carboxamide, it is a synthetic analogue of the natural purine precursor (5-amino-1H-imidazole-4-carboxamide) (Correa F.M. et al., 2019; Eggermont A.M.K. et al., 2004; https://go.drugbank.com/drugs/DB00851).

The various manifestations of the chemical structure of DTIC regarding its activity as a chemotherapeutic agent have been reported by Freeman and Hutchinson, the determinations being performed by using X-ray diffraction phenomena (Freeman H.C. et al, 1979). Recent studies show that DTIC has the ability to tautomerize depending on the pH of the solution in which it is reconstituted, finding a much more intense therapeutic activity, enhanced by the action of UV radiation to which the cancer patient is exposed. In this way it was determined that the DTIC activity depends on both the illumination and the pH value of the solution (Eggermont A.M.K. et al., 2004; Chis M. et al., 2016).

All these findings are particularly important in the use of DTIC as a photosensitizing chemotherapeutic agent in PSChT-type applications, because it is reflected by the "red shift" of the absorption spectrum of dacarbazine as shown by our study, this shift being beneficial for

[1.] The Institute of Oncology 'Prof. Dr. Alexandru Trestioreanu', Bucharest, Romania
[2.] The Spiru Haret University, Faculty of Veterinary Medicine, Bucharest, Romania
[3.] University of Agronomic Sciences and Veterinary Medicine of Bucharest, Faculty of Veterrinary Medicine, Bucharest, Romania

melanoma therapy (Fumarel R., 2003; Fumarel R. et al., 2000).

MATERIAL AND METHOD

1. Spectrophotodynamic determinations

Initially, the photodynamic potential of DTIC was determined by absorption spectroscopy. To accomplish this goal, we diluted the DTIC powder in an alkaline aqueous solution, buffered with sodium bicarbonate with a pH between 13-15 (fig. 1). This was measured using a Perkin Elmer LAMBDA 25 double-beam spectrophotometer.

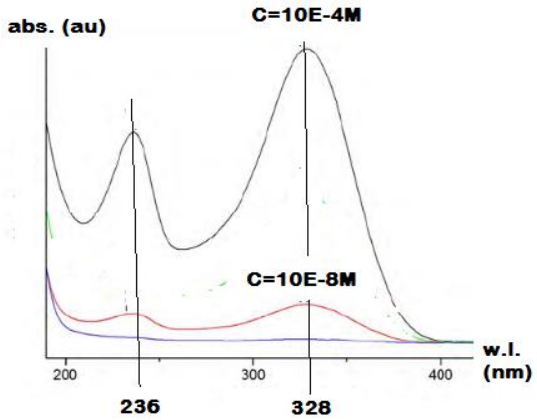

Figure 1. Absorption spectrum of DTIC at different concentrations

The concentration of DTIC in the solution was set at 10^{-2}M. Until the measurement, the samples were stored in a plastic container, wrapped in aluminum foil, at room temperature.

The DTIC powder was purchased from Sigma-Aldrid and used as such.

2. Photodynamic activation

This activation is achieved by irradiating B16 melanoma after administration of the intratumoral DTIC solution, using a specially designed equipment that has as source a high-pressure mercury vapor lamp whose spectrum can be seen in Figure 2.

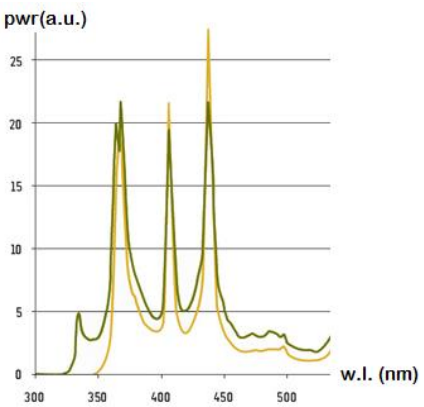

Figure 2. Emission spectrum of irradiation equipment

Irradiation was performed within 6-10 minutes, approximately one hour after administration of the alkaline cytostatic solution. This procedure must be carried out in compliance with the standard protection rules regarding ultraviolet radiation, respectively the use of UVA goggles.

3. The preclinical experimental model

The preclinical experimental model consisted in the subcutaneous transplantation of a solid melanic tumor - murine melanoma B16 on a number of 30 inbred BL / 6 mice divided into 3 equal groups, respectively: group I - control (mice with melanoma, untreated), group II - experimental (mice with melanoma treated with DTIC) and group III - experimental (mice with melanoma treated by the DTIC-PSChT method).

In order to determine the cytostatic effects, tumor fragments were collected from these animals, from which smears were performed, to highlight the cytomorphology of the cells and histological slides. The smears were stained by the May-Grunwald Giemsa method, and the pieces for histopathological examination were embedded in paraffin, sectioned at the microtome at 4-6 microns, and stained with trichrome Masson.

RESULTS AND DISCUSSIONS

1. Spectroscopic determinations:

The electronic absorption spectrum of DTIC, at a neutral pH value, is dictated by two main transitions, namely: (i) the allowed electronic transition between the fundamental level of the molecule and the first allowed excited state, respectively at 328 nm and (ii) the electronic transition allowed between the fundamental level and the second allowed electronic state, at 236 nm. These positions are invariant at the DTIC concentration in solution. On the other hand, UVA spectra were subsequently recorded at different pH values of the solution. In this case, major differences were observed that lead to a "red shift" of both electric bands associated with the two premature states of excitation.

In this way, the first band will move by about 26 nm at a pH difference of 7 and 13-15, respectively, and the second band of interest in increasing the photodynamic potential of the substance, under the same conditions for performing the measurements will have a movement of about 20 nm (Fig. 3).

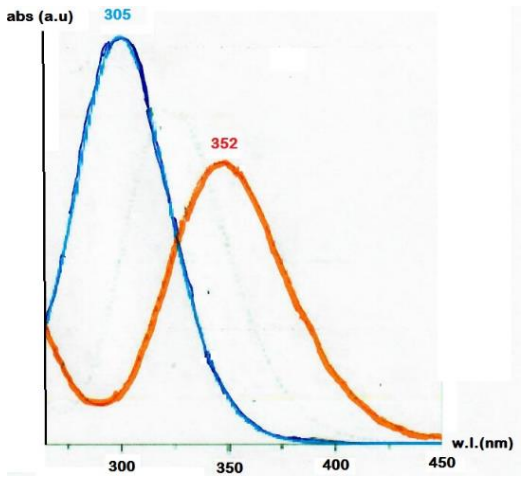

Figure 3. Displacement of the absorption bands depending on the pH

Thus, it is assumed that by increasing the pH of the DTIC solution, the process of resonant interaction will be significantly accentuated.

2. Preclinical experimental determinations:

When examining the smears and histological slides, performed from the tumor masses in the three groups inoculated with tumor tissue, we found special cytopathological aspects, depending on the applied therapeutic scheme. Thus, in the case of group I, the cytomorphological examination revealed the presence of melanocytic tumor cells, mainly of epithelioid type, but also of fusiform type. They had a high degree of anaplasia, with nuclei of various shapes and sizes, sometimes even monstrous, with coarsely arranged chromatin. The cytoplasm has different shades, from light blue - smoky, to dark blue, intensely basophilic (Fig. 4).

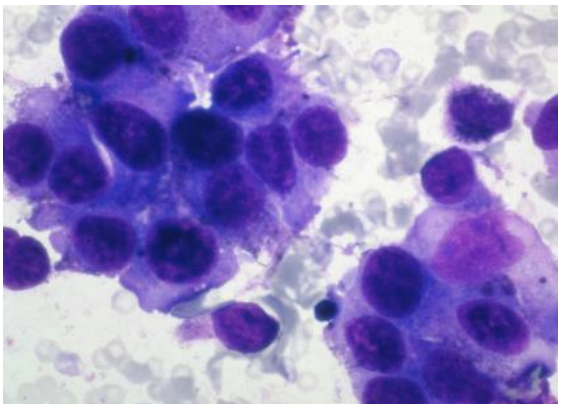

Figure 4. Murine B16 melanoma, cytomorphological aspect group I

Histopathologically, cell pleiomorphism, neovascularization and infiltrative character were found. In general, the mitotic index was high, the number of mitoses per microscopic field at target 10 being about 3-4 (Fig. 5).

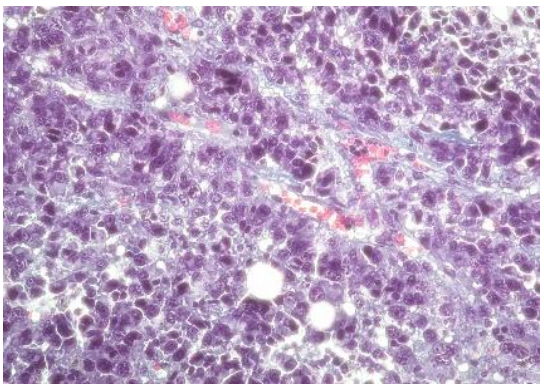

Figure 5. Murine B16 melanoma, histopathological aspect group I

In the case of group II, the cytomorphological examination showed significant differences compared to group I. Thus, the cellularity in the smear was much less represented, many tumor cells being necrotic (Fig. 6).

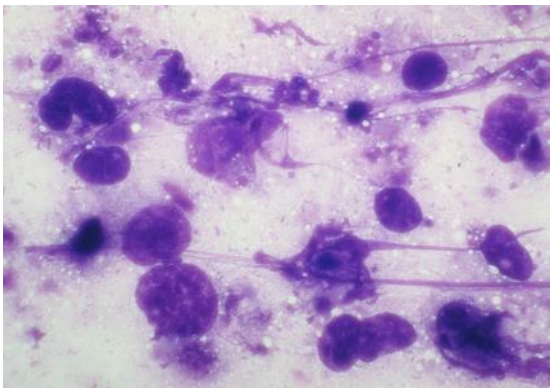

Figure 6. Murine B16 melanoma, cytomorphological aspect group II

Histopathologically, there are areas of cell and tissue necrosis, but also perivascular areas where clones of resistant tumor cells are present and thay have maintained their viability and have not responded to DTIC treatment (Fig. 7).

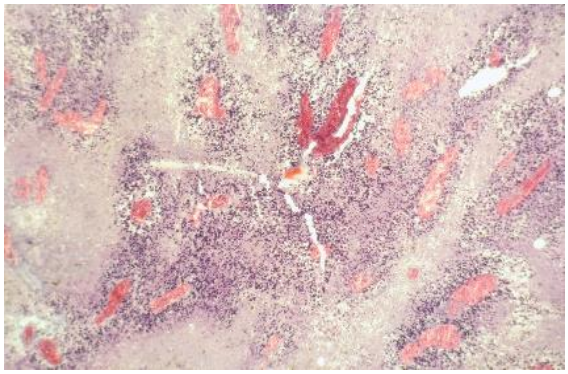

Figure 7. Murine B16 melanoma, histopathological aspect group II

Cytomorphological examination of the tumor, in group III, showed a poor cellular representation and a lot of necrotic detritus in the

smear (Fig. 8), and histopathological aspects showed large, structured areas of tissue necrosis, affecting blood vessels, hemolysis and the presence of hemosiderin which shows the superiority of the DTIC-PSChT method (Fig. 9).

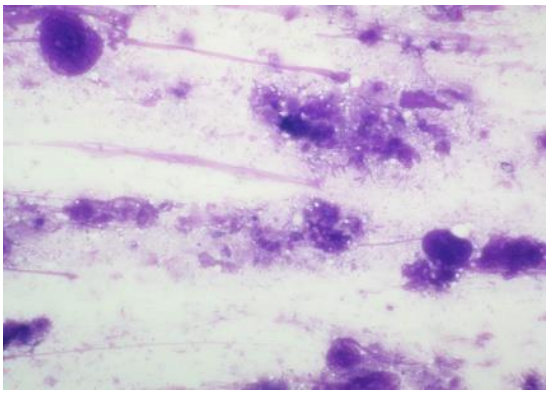

Figure 8. Murine B16 melanoma, cytomorphological group lot III

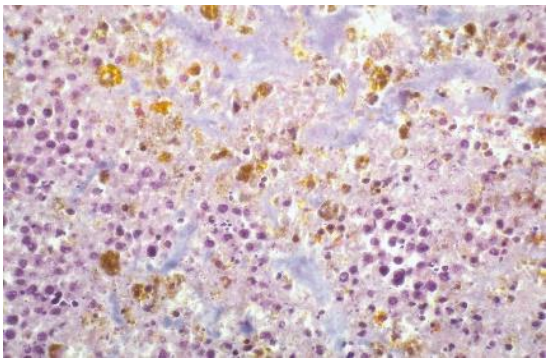

Figure 9. Murine B16 melanoma, histopathological aspect group III

CONCLUSIONS

Following the preliminary determinations performed, it is observed that, depending on the pH value of the administered solution, it has conformations and tautomers that substantially modify its photodynamic potential.

In order for the radiation emitted by the equipment to the cytostatic models to be as efficient as possible, it is necessary for the DTIC solution to have a pH as high as possible (pH = 13 - 15), to be as alkaline as possible.

The cytomorphological and histopathological results of murine B16 melanoma, in the three groups studied, attest to the fact that the use of the DTIC-PSChT method was significantly effective. Thus, it was found that a large part of the tumor was destroyed, the assessment of its destruction being made taking into account the presence of large areas of necrosis in the tumor mass as well as the destruction of neoplasm blood vessels.

REFERENCES

Chiş M., Baia M., Căinap C., Chiş V., 2016 - *UV-vis pH dependence of Dacarbazine: experimental and td-dft investigations.* Studia Ubb Physica, Vol. 61 (LXI): 9-19.

Corrêa F.M., Guerra R.L., Fernandes R.R.A., Carvalho de Souza M., Zimmermann I.R., 2019 - *Target therapy versus dacarbazine in first-line treatment of advanced non-surgical and metastatic melanoma: budget impact analysis from the perspective of the Brazilian National Health System, 2018-2020*. Epidemiol Serv Saude, doi: 10.5123/S1679-49742019000200013.

Diaconu I., Nicolae I., Muresan D., 1996 - *Spectrul lipidic al lipoproteinelor serice in melanomul malign*. Rev. Derm. Dermatol., 2: 21-26.

Eggermont A.M.M., Kirkwood J.M., 2004 - *Re-evaluating the role of dacarbazine in metastatic melanoma: what have we learned in 30 years?*. Eur. J. Cancer, 40: 1825–1836.

Ferlay J., Soerjomataram I., Ervik M., Dikshit R.E., Mathers C., Rebelo M., Parkin D.M., Forman D.B.F. Globocan, 2012 - Estimated cancer incidence, mortality and *prevalence worldwide in 2012*. Int Agency Res Cancer, WHO.

Forsea A.M., Del Marmol V., de Vries E., Bailey E.E., Geller A.C., 2012 - *Melanoma incidence and mortality in Europe: new estimates, persistent disparities*. Br J Dermatol., 167(5):1124-1130.

Freeman H.C., Hutchinson D., 1979 - *The Crystal Structure of the Anti-Tumor Agent 5-(3,3-Dimethyl-l-triazenyl)imidazole-4-earboxamide (NSC-45388)l* Acta Cryst., 2051-2054.

Fumarel R., 2003 - *Metoda de chimioterapie fotostimulata pentru tratamentul tumorilor solide, maligne*. Brevet de Inventie nr. 117697 C1, OSIM Romania.

Fumarel R., Mogos I., Manolescu N., Albert P., Terbea I., Moraru V., 2000 - *The method of photostimulated chemotherapy in treatment of solid malignant tumours – first part – concept and methodology.* Rom. J. Comp Onc, 3:156-166.

https://go.drugbank.com/drugs/DB00851

FARMED CYPRINIDS DISEASES FROM THE PRUT RIVER BASIN

Adrian BĂLBĂRĂU[1], Vasile VULPE, Ramona GHIORGHIASA, Dumitru ACATRINEI, Larisa IVĂNESCU, Liviu MIRON

e-mail: dacatrinei@yahoo.com

Abstract

The current paper aims to outline the most common fish diseases that affect farmed cyprinids in ponds from the Prut river basin, in order to better understand and reduce fish health risks. After 2 field work expeditions to Rompescaris farm -Podu-Iloaiei from Iasi county and to Dracșani fish farm from Piscicola-Botoșani county, biological samples were collected, in May 2021. Using net fishing the following fish species were harvested: carp (Cyprinus carpio), silver carp (Hypophthalmichthys molitrix) and mirror carp (Cyprinus carpio var. specularis). the biological material, the moribund specimens with visible lesions were isolated and the apparently healthy specimens were released. The collected specimens were subjected to a clinical, a parasitological and a bacteriological investigation.

Key words: Cyprinus carpio, Hypophthalmichthys molitrix, Cyprinus carpio var. specularis, diseases

Fish consumption has been rapidly increasing from 5.2 kg per capita in 1961 to 19.4 kg in 2017. Even the less developed countries increased their consumption from 6.1 kg in 1961 to 12.6 kg in 2017.The Food and Agriculture Organization of the United Nations estimates that by 2030 aquaculture will produce 60% of all fish destined for human consumption (FAO 2020).

With the rapid growth of this sector farmers also have to cope with an increased demand and with more fish health risks. Studies carried out in the early stages of aquaculture focused mainly on new intensive fish farming systems, improved feed and an increased fish growth rate. In recent years aligning with the rapid growth of this industry worldwide there has also been an increase demand of fish diseases diagnostic and in order to find out the most common problems that have an impact on fish health in a certain region. Furthermore, bringing together large numbers of animals of a single species or closely related species increases the risk of disease outbreaks (Kibenge et al., 2012).

Aquaculture systems similar to some found in Moldova county in which farmed fish are kept at high population densities in close proximity with wild fish reservoirs is ideal for the spreading of wild type pathogens form the wild fish to the farmed ones and vice versa (Kibenge et. al 2012) thus ensuring a permanent supply of parasitic, bacterial, viral and fungi pathogens.

Adding to the problem in the last three decades global temperature near Earth's surface has been increasing at an unusually rapid rate (Stott et al., 2000). It is well known that temperature facilitates the multiplication of pathogens and the infection of new hosts as long as the other pathogen-specific conditions for transmission are met. The rising of temperature could also amplify the parasites metabolism resulting in a higher number of transmission stages being produced, which would lead to a higher parasite fitness and a more rapid spread of certain diseases (Karvonen et al.,2010).

That being said now more than ever in Moldova county aquaculture units face problems that are either the result of different pathogens or are a consequence of inappropriate water quality parameters and are in need of either a diagnostic or a water quality assessment. In this article we present our findings in order to better understand, and in the future, reduce fish health risks in Moldova county.

MATERIAL AND METHOD

All the sampled fish were first subjected to an external clinical examination. The fish were inspected and the skin was examined to determine if there are any ulcers, furuncles, skin hemorrhages, spots, skin darkening, tumor like lesions or macroscopical parasites. The mouth of the fish was inspected for hemorrhages or macroscopical parasites. The eyes were examined for hemorrhages, corneal opacity, sunken eye or exophthalmia.

[1] Iasi University of Life Science, Faculty of Veterinary Medicine

Following the same pattern of examination used on the skin, the gills were also inspected. After the external evaluation the fish were placed with the left lateral side towards the examiner and using an anatomical scissors a section was made along the abdomen, starting from the anal orifice upwards, on the right side of the body towards the spine and then continued parallel to it, up to the head.

A lid was outlined that was removed with the help of an anatomical forceps revealing the visceral mass. The aspect of the abdominal cavity was examined as a whole and then the presence color and position of the internal organs was examined. The liver, spleen and kidney were examined for hemorrhages, nodules or changes in color and in case of the kidney the texture of the organ was also assessed.

The digestive tract was unrolled and using scissors was divided into three sections (anterior, middle and posterior) then opened along its entire length. The content and scrapes of the intestinal mucosa were placed between a slide and a cover slip and were examined microscopically without any staining.

The bacteriological examinations were performed by inoculation on specific media of bacterial strains sampled from the injured tissue and uninjured organs. Samples were taken from the spleen, kidney, liver, gills, skin and from areas adjacent to the injured tissue.

Using a sterile Pasteur pipette and a sterile loop, the organs were deeply pierced and biological material was sampled. The samples were deposited on the surface of a non-selective medium (TSA agar, nourishing agar, BHI agar) and incubated at 25°C for 24 to 48 hours (Kimberly A. Whitman, 2004).

After preforming the cultural examination, morphological identification was performed by Gram staining. Inoculating the bacterial strains on biochemical media and with the use of API diagnostic tests the morphological characteristics were also identified.

In order to identify the species within the genus *Aeromonas*, mass spectrometry was used (MALDI-TOF MS bioMérieux system).

The parasitological examination began with the inspection of the skin and gills. The skin was examined for macroscopical parasites, and after that the gills were exposed by removing the gill covers with a pair of scissors. After examining the gills, they were removed from the body and placed in a Petri dish. The mouth was visually inspected for the presence of parasites and the eyes were removed using a curved scissor and then cut open using a scalpel in order to examine the vitreous humor.

RESULTS AND DISCUSSIONS

At the external clinical examination hemorrhagic lesions located on the abdomen (figure 1) and on the left lateral side immediately next to the gill cover (figure 2) were observed in common carp (*Cyprinus carpio*). Skin ulcers with local shedding of the scales (figure 3), fringing of the anal fin (figure 4) and congested gills with areas of necrosis (figure 5) were also observed in the case three other individuals of the same species.

Figure 1. **Abdominal hemorrhage (*Cyprinus carpio*)**

Figure 2. **Skin hemorrhage next to the gill cover (*Cyprinus carpio*)**



Figure 3. **Skin ulcer with local shedding of the scales (*Cyprinus carpio*)**

Figure 4. **Fringing of the anal fin (*Cyprinus carpio*)**

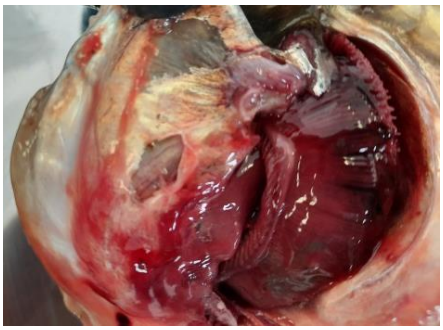

Figure 5. **Gill congestion and necrosis (*Cyprinus carpio*)**

The observed modifications can be caused by both external abiotic factors such as water quality criteria, different objects capable of harming the fish and by biotic factors such as starvation, stocking density or different types of pathogens. A variety of aethiological factors may cause lesions in the skin, gills, eyes under farming conditions. A poor aquaculture system and rapid changes in environmental conditions may lead to health problems and diseases that will have an impact on fish welfare. Handling and grading may impair the mucus layer and the skin if not done in a gentle way. Lesions of mechanical origin may improper tanks and cages as well as natural predators like birds (Tørud, B., & Håstein, T., 2008).

In order to determine the actual cause of the discovered lesions further investigations were required.

The mirror carp (*Cyprinus carpio* var. *specularis)* showed lesions characterized by ulcers that occasionally reached the muscle tissue and were surrounded inconstantly by a whitish halo, erythema, hemorrhagic infiltrations located in areas devoid of scales (figure 6 and 7).

Figure 6. **Skin ulcer that reached the muscle tissue (*Cyprinus carpio* var. *specularis*)**

Figure 7. **Skin ulcer surrounded by a whitish halo (*Cyprinus carpio* var. *specularis*)**

Examination of the gills revealed an abundant whitish mucus deposit at the base of the gill arch, gill hemorrhages and areas of gill necrosis (figure 8).

Figure 8. **Gill necrosis (*Cyprinus carpio* var. *specularis*)**

The clinical examination of fish belonging to the silver carp (*Hypophthalmichthys molitrix*) species revealed the presence of parasites belonging to the *Lernaea* genus imbedded in the skin (figure 9) and parasites belonging to the *Sinergasilus* genus fixed on the gill lamellae (figure 10). For proper identification of the parasite species further investigations will be required.

Figure 9. **Copepod crustaceans (genus *Lernaea*) imbedded in the skin, scale erosions and hemorrhagic ulcerations (*Hypophthalmichthys molitrix*)**

Figure 10. **Copepod crustaceans (genus *Sinergasilus*) fixed on the gill lamellae 4x magnification (*Hypophthalmichthys molitrix*)**

Parasites found on the gills were sampled and examined under the microscope after being fixed between a slide and a cover slip (figure 11) and the parasites found imbedded in the skin were examined under a magnifying glass (figure 12).

The most common indicators of poor health in fish include tumors, hemorrhage, necrosis, fin and skin damage, deformities, discoloration of organs or tissue, excessive mucous and heavy infestation with parasites (Karr J. R., 1981).

In addition to osmoregulatory problems associated with the ulcerations caused by the parasites secondary bacterial infections may hinder the welfare of affected fish and treating them properly is a major challenge since a relatively high number of opportunistic bacterial species are usually present in every water body.

Figure 12. **Crustacean copepod of the genus *Lernaea* examined at a 4x magnification (*Hypophthalmichthys molitrix*)**

Crustacean copepods like of the genus *Lernaea* and *Sinergasilus* can survive a wide range of conditions but thrive when the water comprising the ecosystem has a low oxygen concentration and a high mass of stagnant organic matter.

Even if we were to give the fish the best environmental conditions, gentle handling or an adequate treatment, if necessary, some members of such large populations will still suffer because of skin and gill lesions. To get these particular individuals out of production may be a great challenge (Tørud, B., & Håstein, T., 2008).

Very few treatments are available worldwide that are effective on crustacean parasites and there are major difficulties in their application as well as serious concerns regarding the environmental impact. The risk of developing a resistance to the limited range of effective therapeutants is also very high (Tørud, B., & Håstein, T., 2008).

Even if the water quality is high and prevention methods are tried under farming conditions where fish are kept in high densities the ability of a parasite to find a host is greatly increased along with the level of parasitic infestation (Tørud, B., & Håstein, T., 2008).



Figure 11. **Copepod crustaceans of the genus *Sinergasilus* examined between slide and cover slip at a 10x magnification (*Hypophthalmichthys molitrix*)**

After the gills were examined macroscopically scraping were taken and analyzed between a slide and a cover slip. The exam of such a sample from a silver carp (*Hypophthalmichthys molitrix*) revealed the presence of a nematode belonging to the *Dactylogyrus* genus that was identified based on the following morphological characters, the presence of 4 pigmented spots in in the anterior extremity (figure 13) and the presence of the haptor fixing organ (figure 14) at the posterior extremity.

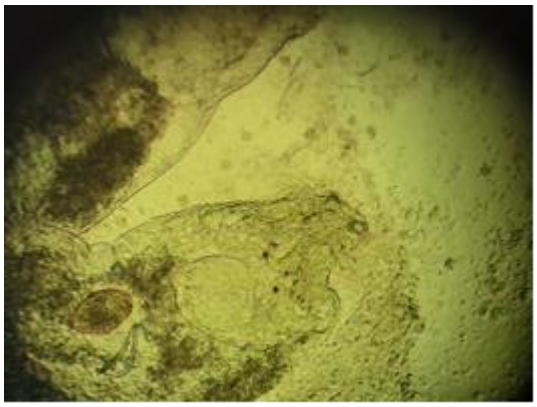

Figure 13. **Dactylogyrus spp. - anterior extremity with 4 pigment spots**

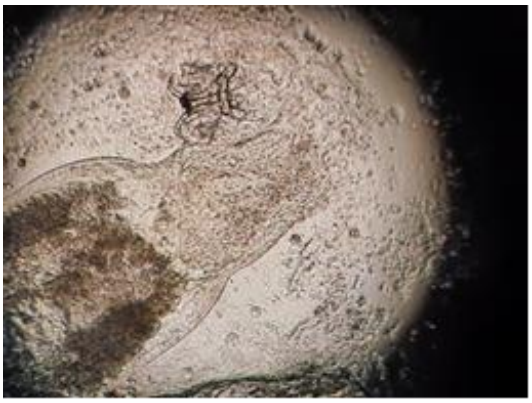

Figure 14. **Dactylogyrus spp. - posterior extremity with the haptor fixing organ**

Parasites causing little apparent damage in feral fish populations, may, become causative agents of major diseases in farmed fish, leading to a decrease of fitness or reduction of the market value of the fish (Scholz T., 1999). Parasites affecting farmed fish will alter the host's weight, sometimes substantially even if apparently there are no signs of disease (Jakob et al., 1996).

Despite considerable progress in fish parasitology in the last decades, major gaps still exist in the knowledge of taxonomy, biology, epizootiology and control of fish parasites (Scholz T., 1999).

Fish parasites are an integral part of water ecosystems and are present in natural and cultured fish populations alike. In natural conditions, most parasites do not tend to severely injure their host and cause mortalities which affect the population size at detectable levels (Scholz T., 1999), this is because feral fish are more resistant than farmed ones and because natural selection greatly reduces the spreading of parasites in wild fish populations.

If an individual with a low resistance dies when taking contact with a parasite the life cycle of the pathogen will not be completed.

It should also be emphasized that the presence of a parasite does not necessarily imply manifestation of a disease. (Scholz T., 1999).

The bacteriological examination started with the analysis of the Petri dishes after the incubation period ended. On TSA agar species of *Aeromonas spp., Shewanella spp*. and *Pseudomonas spp*. developed. The *Aeromonas spp*. colonies were characterized by round "S" type colonies with a diameter of 2-5 mm, with a regular shape, opaque and unpigmented edges. The *Pseudomonas spp*. developed "S" type colonies, slightly yellow pigmented, fluorescent, with a tendency to confluence. The *Schewanella spp.* colonies were circular, convex had a regular outline a diameter of 1-4 mm and were pigmented in orange.

Some of the lesions observed on the fish were similar to those seen in case of erythrodermatitis which can be caused in fish by several species of conditionally pathogenic bacteria as fallows: *Aeromonas hydrophila, Aeromonas caviae, Aeromonas sobria, Pseudomonas aeruginosa, Shewanella putrefaciens or Plesiomonas shigelloides*. (Brain Austin and Dawn Austin, 2007).

CONCLUSIONS

We are not entirely sure if some of the skin lesions found on the common carp (*Cyprinus carpio*) are the result of poor management system and have been colonized by bacteria afterworlds or are the direct result of a bacterial pathogen but we believe the former to be the case.

Adding to the problem mechanical lesions that result from a poor farming system or lesions which are a result of parasite infestations greatly facilitate the development of opportunistic bacteria or fungi that are normally present in the water.

Of all the specimens examined the silver carp (*Hypophthalmichthys molitrix*) was the most relevant from a parasitological point of view.

Each silver carp (*Hypophthalmichthys molitrix*) was found caring at least one species of parasite form the genus *Sinergasillus, Lernaea*, or *Dactylogyrus spp*. and one particular individual had both crustacean copepods at the same time.

The common carp (*Cyprinus carpio*) and the mirror carp (*Cyprinus carpio* var. *specullaris*) after the clinical examination were the fish with the most ulcer like lesions on the skin and were the most relevant from a bacteriological point of view. Of all the specimens examined only two common carps (*Cyprinus carpio*) after the samples were

taken and investigated showed signs of *Saprolegnia spp.*

Control of diseases when it comes to farmed fish is far from being satisfactory and further investigation will be needed. Use of chemotherapy is very limited and new methods of treatment that do not pose the technical difficulties of standard ones will have to be developed. At the same time, it is worth noting that any new treatment has to be environmentally safe.

Fish farmers must also improve the conditions in which fish are farmed in order to reduce the fish health risks. Overcrowding should be avoided as much as possible and the providing and after that maintaining of good quality water is mandatory.

High densities of fish help spread diseases and the if the water is also improper the fish's natural resistance will decrease and at the same time the parasites and other opportunistic pathogens will increase in number.

Until a proper treatment is developed aquaculture units in the area need to make improvements on the farming systems, avoid overcrowding and regularly check the water quality parameters and the fish's health status.

Further investigations will be required in order to determine as many pathogens as possible that are affecting aquaculture in Moldova county and devise a viable solution that can reduce fish health risk as much as possible and improve their welfare.

ACKNOWLEGMENTS

We would like to thank the team of researches involved in the project "Team up for healthy fish in aquaculture systems of the Prut River basin 2SOFT / 1.2 / 47", researchers from the Institute of Zoology (IZ) of the Academy of Sciences in Chișinău (Republic of Moldova) and the University of Life Sciences " Ion Ionescu de la Brad" from Iași (USV Iași).

REFERENCES

Austin Brain and Austin Dawn, 2007 - Bacterial fish pathogens. Diseases of fish farmed fish and wild fish Ed. 4

Barber I, 2007 - Parasites, behavior and welfare in fish.

Eissa Alaa Eldin, 2016 – Clinical and laboratory manual of fish diseases

FAO. 2020 - The State of World Fisheries and Aquaculture 2020. Sustainability in action. Rome. https://doi.org/10.4060/ca9229en

Håstein Tørud and Tore, **2008** - Skin lesions in fish: causes and solutions warming

Jakob, E. M., Marshall, S. D. and Uetz, G. W. 1996 - Estimating fitness: a comparison of body conditions indices

AN UNCOMMON CASE OF GASTROINTESTINAL FOREIGN BODY IN CAT

Alexandra NEAMȚU[1], Liviu BURTAN, Dan Gheorghe DRUGOCIU

e-mail (first author): alexandra.neamtu21@gmail.com

Abstract

Gastrointestinal foreign bodies are commonly encountered in veterinary pathology. The patient may present a variety of clinical signs, depending on the shape of the swallowed object, as well as the site and extent of obstruction. The aim of this study is to describe an unusual case of linear gastrointestinal foreign body, in a 3-year-old cat, referred to the Faculty of Veterinary Medicine Iasi, Surgery Department. The anamnesis and clinical examination suggested a gastrointestinal foreign body, subsequently confirmed by ultrasonography, therefore surgical intervention was the treatment of choice. After anesthesia, oral examination revealed an anchored thread around the base of the tongue which couldn't be extracted by conservative methods, due to the traction resistance. Exploratory celiotomy and enterotomy were performed, the thread being entirely removed after it was freed from the tongue. The patient recovered uneventfully without postoperative complications.

Key words: enterotomy**,** linear gastrointestinal foreign bodies, anchored

Linear foreign bodies (LFB), more frequent in cats than dogs, determine a particular type of intestinal obstruction in small animals, due to the extensive lesions of the gastrointestinal tract. (Papazoglou, L. G. *et al*, 2003)

Linear foreign body in cats are associated with a higher mortality rate than non-linear ones, due to the fact that they typically perforate the mesenteric border of the small intestine (Allan, R. M., 2015)**.** In cats, this mucosa sectioning is favored by the fact that part of the object can anchor at the base of the tongue, and the remainder advances into the digestive tract. As peristaltic waves attempt to advance that LFB, the intestinal loops will gather around it, following that after a continuous peristalsis, the object will lacerate the mesenteric border. This will lead to intestinal content leakage and peritonitis (Fossum, T. W., 2018).

The main ingested objects with linear configuration include thread, wires, string, dental floss, ribbon or even cassette tapes. (Fossum, T. W., 2018).

In LFB vomiting is usually the most common presenting complaint, closely followed by anorexia and sometimes bloody diarrhea (Papazoglou, L. G. *et al*, 2003).

Diagnostic imaging usually leads to a tentative diagnosis, only in exceptional cases being able to highlight the LFB directly. Animals with linear foreign bodies usually don't have any obvious lesions on plain radiographs. It is also difficult to examine the entire digestive tract using ultrasounds, and sometimes, some foreign objects can be missed (Allan, R. M., 2015; Fossum, T. W., 2018).

MATERIAL AND METHOD

A three-year-old cat, mixed breed, presented to the Veterinary Teaching Hospital, IULS, with complaint of acute onset of vomiting, inappetence, and lethargy. The symptoms persisted for two days prior examination.

The physical examination revealed moderate fever and abdominal pain, but no mass could be identified at the abdominal palpation.

Ultrasonography revealed a hyperechoic structure within the intestinal lumen. These imagistic and clinical changes were consistent with those occurring in feline gastrointestinal foreign body.

Diagnostic was made correlating the clinical history, physical examination and abdominal ultrasonography. Due to financial problems and the fact that abdominal radiographic findings usually are not consistent, radiographs were not taken. The suspected pathology had to be differentiated from other diseases causing intestinal obstruction: intussusception, intestinal volvulus, strictures, adhesions, congenital abnormalities or neoplasia. (Fossum, T. W., 2018).

[1] Iasi University of Life Science, Faculty of Veterinary Medicine

After anesthesia induction, the oral cavity could be examined well enough and a thread was found to be wrapped around the tongue *(figure 1 a)*. The anesthetic protocol consisted of xylazine (2 mg/kg) IM and ketamine (15 mg/kg) IM.

The loop of intestines was isolated with compresses. In order to remove the thread, two enterotomies on the antimesenteric border were necessary *(figure 2 a, b)*. If the extraction would

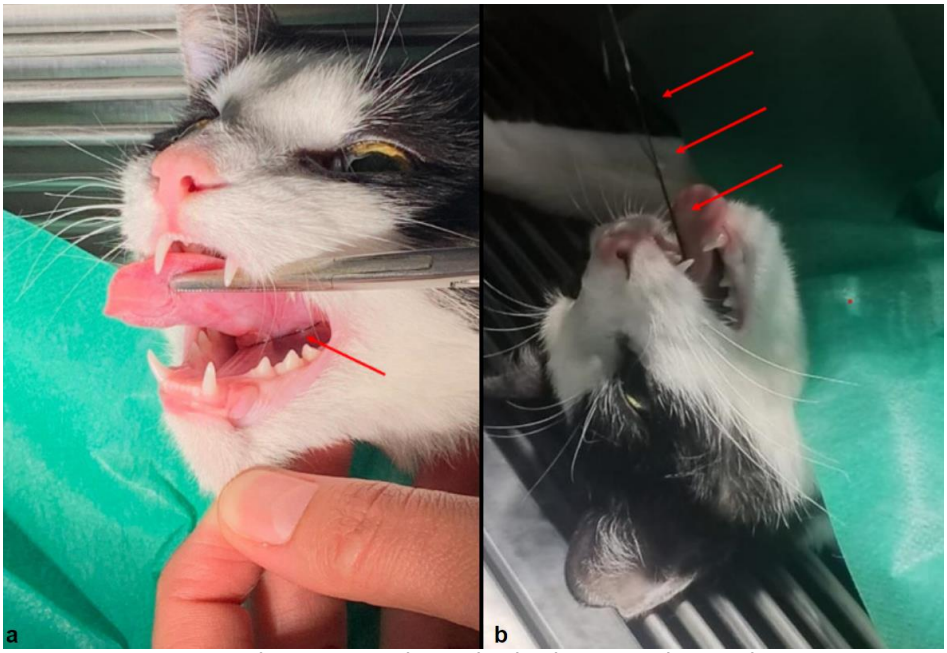

Figure 1 a. Oral examination b. LFB oral extraction
(red arrows indicate the presence of the LFB)

Figure 2 a. First enterotomy, followed by extraction. b. Second enterotomy

The patient was positioned in dorsal recumbency, for a ventral midline laparotomy, and the area prepared for surgery.

A ventral midline incision was made, and the entire abdominal cavity inspected to assess if the object caused any intestinal trauma in transit. The exploratory celiotomy revealed plication of the small intestines.

Have been done through the same incision, friction of the object against the intestinal mesenteric border might lead to iatrogenic laceration of it.

Unlike other cases, after performing enterotomy and removing a segment of thread, the

remaining object could be pulled out orally, from the sublingual anchored point *(figure 1 b)*.

After removing the foreign body, the intestines were closely examined, for evidence of necrosis that may require enterectomy. The intestinal segment was viable, with no signs of ischemia, necrosis or lacerations, therefore the enterotomy was closed using a 2-0 PDS (Polydioxanone), in a simple interrupted suture *(figure 3 a)*. Although most absorbable suture materials can be used, atraumatic needle with monofilament thread are preferred due to low susceptibility to bacterial adhesion, compared to multifilament. It also allows a clearance of bacteria by the immune system.

a risk of the conservative management in this pathology (MacPhail, C., 2002).

Sublingual fixation of the thread can easily be missed initially, if not specifically searched (Basher, A. W *et al*, 1987). The linear foreign body generally cannot be detected even with careful abdominal palpation; despite this, intestinal plication can be observed, and the pathology suspected (Bebchuk, T. N., 2002).

Imagistic examination is useful**.** A radiographically strong evidence for the presence

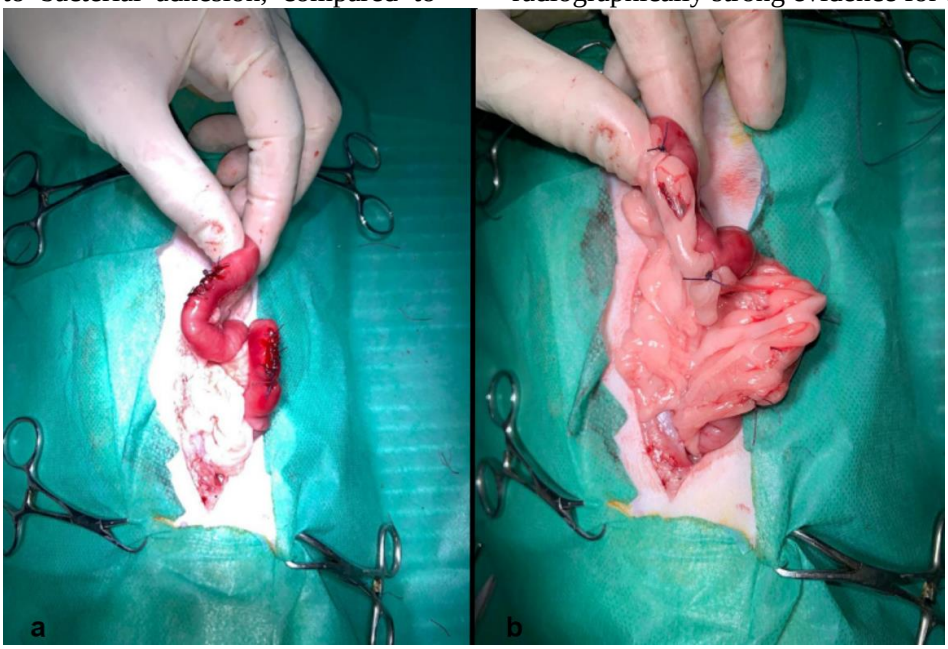

Figure 3 a. Enterorrhaphy; b. Omentalisation

The exteriorized intestinal portion was washed with saline prior omentalization. The omentum was sutured loosely in place in order to reinforce the site *(figure 3 b)*. This procedure provides additional blood supply and increases leakage resistance.

The abdominal cavity has to be examined, due to the fact that some animals with linear foreign bodies have concurrent intussusceptions (Fossum, T. W., 2018).

Postoperative care included monitoring for signs of leakage or peritonitis, analgesics and antibiotics due to possible abdominal contamination. Water was offered after 12 hours after surgery, because no signs of vomiting were seen.

The cat recovered without any complications.

RESULTS AND DISCUSSIONS

Some authors consider that surgery has to remain the treatment of choice due to the high mortality rate (50%) of the LFB lacerated intestine, of a linear foreign body is accordion-like pleating of the small intestines, shortening or gathering of the intestine, increased number of eccentrically located comma-shaped or tapered luminal gas bubbles, or peritonitis subsequent to bowel laceration. The plication of intestinal tract is also observed in ultrasonography, but in this case has to be distinguished from intussusception. In order to do that, identifying the hyperechoic structure within the lumen as well as the lack of wall layers that form a concentric ring, is useful (Bebchuk, T. N., 2002).

The prognosis in linear foreign bodies worsens dramatically with the increasing number of days after ingestion. In a 2009 study, cats with linear foreign bodies of over 14 days duration, had to be

euthanased intraoperatively because of multiple ruptures and peritonitis (Hayes, G., 2009).

The medical management of linear foreign body in cats include a conservative or a surgical treatment. Fossum T.W. recommends that if cats with linear foreign body, anchored at the base of the tongue, are presented in the first three days after ingestion, and the general condition of the animal permits it, the thread can be cut and then monitored for passage. All this time, animal has to be under hospital observation, because if the general condition did not improve or it's getting worse, the patient should be taken to surgery. In Basher's study (Basher, A. W *et al*, 1987), the length of the conservative therapy varied from one to six days.

Table 1

LFB management

Conservative management	Surgical intervention
Cat presented immediately after swallowing the LFB	Persistence or worsening of clinical signs in conservative management
Cat presented with a sublingually anchored LFB and has no apparent signs of peritonitis	Cat presented with clear signs of peritonitis, severe abdominal pain, pyrexia,
	Obvious pyloric fixation of the LFB

Basher, A. W *et al*, 1987; Fossum, T. W., 2018

The dehydration and laboratory changes should be corrected by appropriate fluid therapy, before surgical intervention.

Surgery should never be delayed if abdominal pain, vomiting, fever and lethargy is apparent. Usually, in linear foreign bodies, the longer the surgery is postponed, the greater its complexity gets. The object may become embedded in the mucosa, and the intestinal resection required (Fossum, T. W., 2018).

Decreasing the incision number on the gastrointestinal tract will improve the surgical survival rate (Allan, R. M., 2015).

The decision of surgical intervention or conservative management is influenced by several factors, systematized in *Table 1*.

CONCLUSIONS

Due to continue peristaltic activity and continuous erosion of mesenteric intestinal border, linear foreign body ingestion should be treated as an emergency condition, regardless of the therapeutic procedure approached.

REFERENCES

Allan, R. M., 2015 - Injection port aids linear foreign body removal in a cat. *Veterinary Record Case Reports,* 3(1), e000217.

Bebchuk, T. N., 2002 - Feline gastrointestinal foreign bodies. *Veterinary Clinics: Small Animal Practice*, 32(4), 861-880.

BASHER, A. W., & FOWLER, J. D., 1987- Conservative versus surgical management of gastrointestinal linear foreign bodies in the cat. *Veterinary Surgery*, 16(2), 135-138.

Fossum, T. W., 2018 - *Small Animal Surgery E-Book*. Elsevier Health Sciences.

Hayes, G., 2009 - Gastrointestinal foreign bodies in dogs and cats: a retrospective study of 208 cases. *Journal of small animal practice*, 50(11), 576-583.

MacPhail, C., 2002 - Gastrointestinal obstruction. *Clinical Techniques in Small Animal Practice*, 17(4), 178-183

Makinde, O. A., Adebayo, O. O., Adeniyi, A. A., & Ajadi, R. A., 2018 - Jejunal linear foreign body obstruction in a three year old female Boerboel. *Sokoto Journal of Veterinary Sciences*, 16(4), 87-91.

Papazoglou, L. G., Patsikas, M. N., & Rallis, T., 2003 - Intestinal foreign bodies in dogs and cats. *Compendium On Continuing Education For The Practising Veterinarian-North American Edition-*, 25(11), 830-845.

BILATERAL UTERINE PROLAPSE IN QUEEN: CASE STUDY

Alexandra Andreea SIKRA[1], Petru ROȘCA, Ștefan Gregore CIORNEI, Dan Gheorghe DRUGOCIU

e-mail: alexandrasikra@gmail.com

Abstract

An 10-month-old primiparus queen was sent to the Department of Obstetrics and Gynecology within the Faculty of Veterinary Medicine from Iași, with a prominence of a mass through the vulva immediately after calving. Following the clinical examination, the diagnosis of bilateral uterine prolapse was established. Uterine prolapse in cats is rare and is a relatively uncommon complication of parturition. This pathology is an obstetrical emergency and requires immediate intervention. The treatment of uterine prolapse consisted in restoring the uterus to its normal position and preventing or eliminating uterine infection. In the present case the manual reduction of the prolabated portion was not possible and a two-step ovariohysterectomy was performed: ovariectomy and amputation of the uterine body.
After ovariohysterectomy cat fully recovered.

Key words: queen, bilateral uterine prolapse, ovaryohisterectomy

Uterine prolapse is a rare obstetric emergency in domestic cats and can occur from 48 hours to 3 days after parturition (Deroy C., 2015; Sabarinathan A., 2020; Sabuncu A., 2017; UÇMAK Z.G., 2018).

This complication has been reported in both primiparous and multiparous cats from 10 months to 6 years of age (Bigliardi, E., 2014; UÇMAK, Z. G., 2018).

In general, uterine prolapse is a rare complication and can be seen immediately after parturition, because the opening of the cervix is indispensable for the onset of prolapsed (Johnston S. D., 2001; Bigliardi, E., 2014).

In the etiology of this condition, the prolonged efforts to expel the fetuses, incomplete placental separation, relaxation or atony of the uterine walls and excessive relaxation of the pelvic and perineal regions have a special role (Jutkowitz L.A., 2005).

If the uterus is limited to the uterine body and one horn, nonspecific signs may be seen indicating abdominal pain and tenesmus. Complete prolapsing of the uterus, with both horns protruding, leads to the appearance of a mass of tissue between the vulvar labia, with different degrees of edema, ulceration and necrosis, depending on the duration and severity of prolapse (Deroy C., 2015).

The diagnosis is established following the anamnesis and the inspection of the prolapsed organ (Johnston, S.D., 2001).

The symptoms of uterine prolapse are varied and may include varying degrees of ischemia, systemic disease or severe shock, sepsis, hemorrhage, and / or herniation of the abdominal viscera (Jutkowitz L.A., 2005, Mostachio *et al.* 2008).

The remedy of this condition can be achieved by manual reduction in uncomplicated cases, amputation of the prolapsed uterus in the situation where severe tissue edema, lesions and necrosis are present (Roberts D.,1988; Özyurtlu, N., 2005).

Laparatomy is performed to correctly position the uterus and check the integrity of the uterine vessels. If the animal's reproduction is not followed, an ovariohysterectomy is also recommended (Özyurtlu, N., & Kaya, D., 2005).

CASE HISTORY

The present case involved a 10-month-old European cat weighing 2.8 kg was presented at our clinic with complaints of a persistent vaginal mass, weakness, loss of appetite and altered general condition.

The anamnesis shows that the cat gave birth recently but the kittens were not found. The owner assumed that the prolapsed vaginal mass in the vulva occurred as a result of a difficult calving, during which the female was not supervised.

On visual inspection, the animal appeared weak, dehydrated, apathetic and was constantly hiding.

The mucous membranes were pink, the body temperature was 39°C and the mass proliferated through the vagina was edematous, congested, dry, covered with debris and had necrosis points.

After palpation of the prolapsed mass, the diagnosis of bilateral uterine prolapse was established (Figure 1).

[1] Iasi University of Life Science, Faculty of Veterinary Medicine

In the present situation, a two-steps ovariohysterectomy was decided; first the ovariectomy and then the resection of the prolapsed uterus.
the cranial part of the uterine body near the vulva to expose the uterine vessels which were ligated using chromic catgut No.2/0 (Figure 2).

Due to traction, the ovaries were located in the mass of prolapsed tissue and not in their physiological position (Figure 3). The ovaries and the uterine horns were then excised vaginally (Figure4).

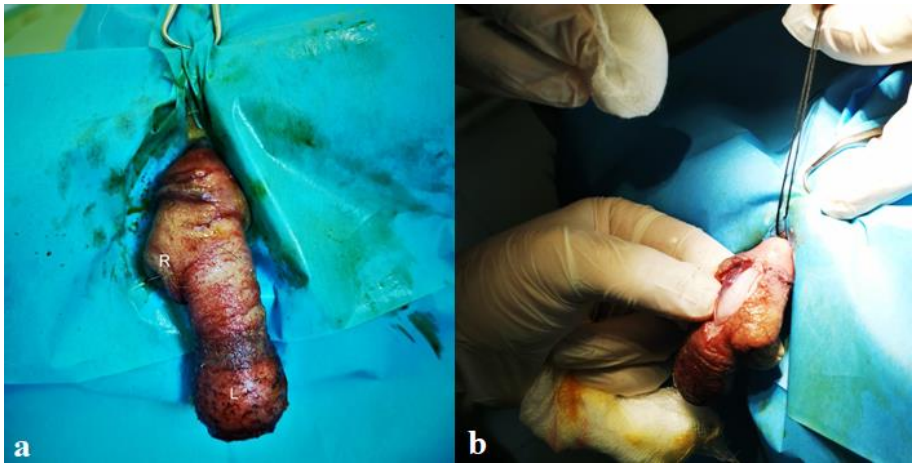

Figure 1. **a.The appearance of the prolapsed uterus.The right uterine horn (R) and the left uterine horn (L) b. Logitudinal incision on the protruding mass**

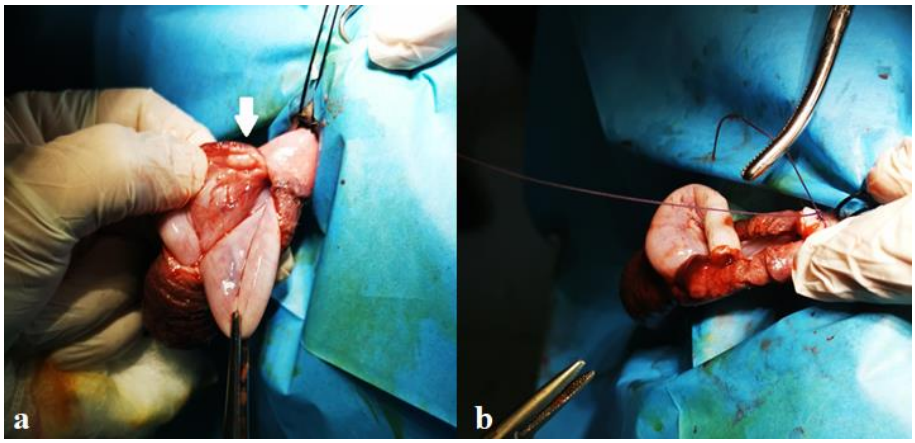

Figure 2**. a. Prolapsed uterus:The arrow shows the ovar. b. Excision of the uterine horns**

After premedication with atropine sulphate (0.02 mg/kg, subcutaneous (sc) ATROPINĂ SULFURICĂ 1%, Romvac, Romania), general anaesthesia was induced with Xylazin 2% (Xylazin Bio 2% 4 ml/kg, intramuscularly (im); Bioveta, Romania) and maintained with Ketamine (Ketamidor 10%, intramuscularly (im); Richter Pharma Ag, Romania).

The female was placed in a sterno abdominal position with the back train a little higher than the rest of the body (Deroy C., 2015).

Manual repositioning of the prolapsed portion was not possible due to rupture of the ligaments and the prolapsed uterus was opened at

The prolapsed uterus was completely removed. The uterine stump was closed with a continuous thread suture, after which it was brought back to the abdomen through the pelvic canal.

The vaginal incision was closed continuously with absorbable polyglactin polyfilament PDO 2/0 (Luxcryl). The abdominal cavity was examined for signs of bleeding after which it was washed with warm saline.

Closure of the abdominal wall was performed according to the standard procedure.

Apposition of vulvar lips was performed with a horizontal mattress pattern without tightening to allow vulvar discharge and normal urination. This suture was removed after 5 days to prevent recurrence of uterine prolapsed.

The queen recovered well. Postoperative treatment included the use of an Elizabethan collar and intravenous fluid therapy.

The day after the operation, the cat was alert, urinated normally and there were slight secretions from the vulva.

Antibiotic treatment for 5 days with amoxicillin / clavulanic acid – Synulox (12,5 mg/kg q12h) and Enrofloxacin (5mg/kg) was recommended.

RESULTS AND DISCUSSIONS

In the present case, as in others described in the literature, bilateral uterine prolapse occurred following parturition (Biddle D.W. *et al*., 2000, Deroy C. *et al*., 2014).

In the case of uterine prolapse in cats, no exact etiology has been described (Bigliardi, E. *et al*., 2014). It has been suggested that it occurs as a result of the decrease myometrial tone that causes the uterine walls to fold and move to the cervical ostium (Deroy C., *et al*., 2015).

Predisposing factors that can lead to prolapse are considered to be strong uterine contractions, excessive stimulation of oxytocin, tenesmus and uterine atony (Jutkowitz, L. A., 2005, Bigliardi E., et al., 2014).

The observed symptomatology included altered general condition, restlessness, pain and prominence of a mass of tissue between the vulvar lips. In the case of cats, contamination and trauma to the uterus may occur through exposure and continuous licking of the prolapsed organ (Shumaili Y., et al., 2011).

In the female presented in our clinic, the prolapsed tissue mass was edematous, congested, with bedding residues and necrosis points.

If the rupture of the wide ligament or of the uterine vessels occurs, there are signs of hemorrhage and implicit shock (Miesner D. M., *et al.*, 2008).

In women, symptoms include urinary incontinence, constipation, dysuria and fecal incontinence (Ellerkmann R.M., *et al*., 2001).

In the case of uterine prolapse, the diagnosis is established relatively easily by visual inspection of the prolabated tissue mass, but complementary examinations such as ultrasound can also be performed.

Ultrasound examination of the abdomen but also of the prolapsed organ can provide accurate data on the position of the bladder, abdominal viscera and fetuses engaged in the pelvic tract in case of dystocia (Miesner D. M., *et al*., 2008).

The remedy for prolapse can be achieved medically by sanitizing and restoring the anatomical position if the organ is viable. Before the actual remediation of the prolapse, the hygiene of the prolapsed tissue is performed by washing with a hypertonic solution. In the case of medical remediation of prolapse by repositioning there is the possibility of complications such as urethral obstruction, urinary incontinence, uterine rupture, cystic endometrial hyperplasia and pyometra (UÇMAK, Z. G., 2018).

In cases where manual reduction is not successful, surgical reduction may be necessary.

Surgical treatment in uterine prolapse in cats consists in two procedures for ovariohysterectomy. If it is possible to reposition the organ, the standard procedure for OHE is performed, otherwise amputation of the uterus and ovariectomy are performed.

In this case, we had to choose the second option. Reduction of prolapsed mass was not possible due to edema and necrosis and amputation of traumatized external tissue prior to repositioning was performed.

During the operation, the urethra was catheterized to prevent further trauma. After excision of the traumatized tissue, the remaining mass of tissue was restored and a laparotomy was performed to complete the ovariohysterectomy.

The procedure that we followed in this case is an individual situation and OHE is the most appropriate option and can be performed after repositioning the uterus.

CONCLUSIONS

It is important for practitioners to consider this condition an emergency because a quick and appropriate diagnosis leads to a correct approach to this rare pathology in feline obstetrics.

REFERENCES

Biddle D.W., Macintire D.K., 2000 - Obstetrical emergencies. Clin Tech Small Anim Pract 2000; 15: 88-93.

Bigliardi, E., Di Ianni, F., Parmigiani, E., Cantoni, A. M., & Bresciani, C., 2014 - Complete uterine prolapse without uterine mucosal eversion in a queen. *Journal of Small Animal Practice*, *55*(4), 235-237.

Deroy, C., Bismuth, C., & Carozzo, C., 2015 - Management of a complete uterine prolapse in a cat. *Journal of Feline Medicine and Surgery Open Reports*, *1*(1), 2055116915579681.

Ellerkmann R.M., Cundiff G.W., Melick C.F., et al., 2001 - Correlation of symptoms with location and severity of pelvic organ prolapse. *Am J Obstet Gynecol* 2001; 185: 1332–1337.

Johnston, S.D., Kustritz, M.V.R., Olson, P.N.S., 2001- The Postpartum Period in the Cat. *In: Canine and*

Feline Theriogenology, W.B.Saunders Company, Philadelphia, pp. 442.

Jutkowitz, L. A., 2005 - Reproductive emergencies. Veterinary Clinics: Small Animal Practice, 35(2), 397-420.

Miesner D. M. and Anderson D. E., 2008 - Management of uterine and vaginal prolapse in the bovine. *Vet Clin Food Anim*; 24: 409–419.

Mostachio, G. Q., Vicente, W. R. R., Cardilli, D. J., *et al.,* 2008 - Uterine prolapsed in queen and uterine retroflexion in bitch. *Ciencia Animal Brasileira* 9, 801-805

Özyurtlu, N., & Kaya, D., **2005** - Unilateral uterine prolapse in a cat. *Turkish Journal of Veterinary and Animal Sciences*, *29*(3), 941-943.

Roberts D., Straw Rodney C., **1988** - Uterine prolapse in a cat. *Compend Contin Educ Pract Vet; 10: 1294-1296.*

Sabarinathan, A., Arunmozhi, N., Kalyaan, U. S., Rangasamy, S., Sathiamoorthy, T., & Kulasekar, K., 2020 - Management of Bilateral Uterine Horn Prolapse in a Queen Cat. *Int. J. Curr. Microbiol. App. Sci*, *9*(5), 2754-2757.

Sabuncu, A., Dal, G. E., ENGİNLER, S. Ö., Karacam, E., TOYDEMİR, T. S. F., & Ucmak, M., 2017 - Feline unilateral uterine prolapse: a description of two cases. *İstanbul Üniversitesi Veteriner Fakültesi Dergisi*, *43*(1), 67-70.

Shumaili Y., Bushra H. and Tabinda R., 2011- Extensive uterovaginal prolapse during labor. *J Obstet Gynaecol Res*; 37: 264–266.

UÇMAK, Z. G., Ucmak, M., Cetin, A. C., & TEK, Ç., 2018 - Uterine prolapse in a pregnant cat. *Turkish Journal of Veterinary and Animal Sciences*, *42*(5), 500-502.

COVID 19 - INDUCED STRESS IN DOGS OWNED BY ELDERLY PEOPLE

Răzvan Nicolae MĂLĂNCUȘ[1]

E-mail: razvanmalancus@gmail.com

Abstract

The study was conducted over a period of 2 months, between March and May 2020, in collaboration with 3 private clinics in Moldova region on 23 dogs of different breeds, sex and ages, paraclinically examined by hematological and biochemical tests. The inclusion criterion in the study was the ownership of all subjects by elderly persons affected.by COVID 19 limitations during the emergency state in Romania. The study aimed to establish the correlation between the limited walking time in dogs and the level of stress induced by it. Each subject underwent 2 paraclinical check-ups in term of hematological testing and cortisol dosage at the end of March and beginning of May. Also, a control group of 13 dogs owned by active people was examined in a similar manner, both at the beginning of the experiment and also at the end of it. Compared with the initial values which were highly elevated (10,89±1,66 µg/dl) in all dogs owned by elderly people, the second testing revealed values comparable to normal, but still increased (4,85±1,22 µg/dl) . The study demonstrates the impact of COVID 19 limitations in terms of outdoor time for dogs which produced transitional changes in cortisol levels, but also the adaptive compensatory mechanisms used to cope with modified environmental conditions.

Keywords: COVID 19, dogs, stress, cortisol

INTRODUCTION

Cortisol is a steroid hormone that regulates a wide range of vital processes throughout the body, including metabolism and the immune response. It also plays a very important role in helping the body respond to stress. Cortisol production by the adrenal glands is regulated by the pituitary gland.[4]

Cortisol, though widely known as the body's stress hormone, has a variety of effects on different functions throughout the body. It is the main glucocorticoid released from the zona fasciculata layer of the adrenal cortex. Both production and secretion of cortisol is regulated by the hypothalamus-pituitary-adrenal axis. Loss of regulation can lead to disorders of cortisol excess, such as Cushing Syndrome, or cortical insufficiency, such as Addison Disease.[1]

Cortisol is known as the stress hormone because of its role in the body's stress response. Stress triggers a combination of signals from both hormones and nerves. These signals cause the adrenal glands to release hormones, including adrenaline and cortisol. The result is an increase in heart rate and energy as part of the fight-or-flight response. It's the body's way of preparing itself for potentially dangerous or harmful situations. Cortisol also helps to limit any functions that aren't essential in a fight-or-flight situation. Once the threat passes, the hormones return to their usual levels while under constant stress, this response doesn't always turn off. Long-term exposure to cortisol and other stress hormones can disturb almost all of the body's processes.[1, 3]

MATERIAL AND METHODS

The study was conducted over a period of 2 months, between March-May 2020, in 3 private clinics in Moldova region, 2 of those in Iasi county and the other one in Braila, on a total number of 36 dogs, 23 of those being owned by elderly people (65+ years), referred as test group, while 13 dogs were owned by active people (control group). The dogs in the test group were between 2-13 years old, of different breeds and sex, while the dogs in the group had between 1 to 9 years old.

Blood samples were collected twice for biochemistry, once at the beginning of the experiment and the second time at the end of it, while for the hematology were collected once, at the end of the experiment. All dogs lived in flats and the outdoor time decreased considerably.

Hematology was performed using Phoenix NCC-30 VET and BIOBASE BK-6200 automated hematological analyzers. Blood samples were collected from the external saphenous or the jugular veins. The vacutainers contained EDTA, an anticoagulant substance and the samples were analyzed immediately after collecting them. For each case have been determined the following parameters: red blood cells (RBCs), packed cell volume (PCV), hemoglobin, mean corpuscular volume (MCV), mean corpuscular hemoblobin (MCH) and mean corpuscular hemoglobin concentration (MCHC), WBC (white blood cells) and platelets. Also, a blood film was analyzed for each sample using May-Grunwald Giemsa or Diff Quick staining methods.

[1] Iasi University of Life Science, Faculty of Veterinary Medicine

Biochemistry was performed in accredited laboratories, having been determined the cortisol levels, all the samples being collected at the same moment as for hematology, using vacutainers with activating gel inside.

RESULTS AND DISCUSSION

Cortisol has many functions in the body, such as mediating the stress response, regulating metabolism, the inflammatory response, and immune function.

As far as the immune response concerns, glucocorticoids have a number of actions in the immune system. For example, they induce apoptosis of proinflammatory T cells, suppress B cell antibody production, and reduce neutrophil migration during inflammation.[2]

In stress response, the body is continually responding to internal and external stressors. It processes the stressful information and elicits a response depending on the degree of threat. In times of stress, the sympathetic nervous system gets activated being responsible for the fight or flight response, which causes a cascade of hormonal and physiological responses. Based on the action of the stressors, the hypothalamus activates the sympathetic nervous system and the adrenal glands release catecholamines, such as epinephrine.[5, 6] This results in effects such as increased heart rate and respiratory rate. As the body continues to perceive the stimuli as a threat, the hypothalamus activates the hypothalamus-pituitary-adrenal axis. Cortisol is released from the adrenal cortex and allows the body to continue to stay on high alert. Acutely, cortisol's catabolic mechanisms provide energy to the body. Thus, blood glucose levels drive key systemic and intracellular pathways.[2] The presence of glucocorticoids, such as cortisol, increase the availability of blood glucose to the brain. Cortisol acts on the liver, muscle, adipose tissue, and the pancreas. In the liver, high cortisol levels increase gluconeogenesis and decrease glycogen synthesis. Cortisol also enhances the activity of glucagon, epinephrine, and other catecholamines.[3]

The cumulative effects of stress produced changes at the level of white blood cells, observing a decrease in the total number of eosinophils, while neutrophils and monocytes got increased. These changes were observed in both test group but also control group. The hematological results revealed severe changes for the test group as far as total eosinophil count was concerned (0,02±0,01 x 103/mm3), while for the control group, the mean values for eosinophils were 0,05±0,02 x 103/mm3. The total neutrophils count reached 88,20±7,33 x 103/mm3 for the test group and 82,15±6,63 x 103/mm3 for the control group. Monocytes levels got very close to upper limit not only for the test group (1,32±0,80 x 103/mm3) but also for the control group (1,21±0,92 x 103/mm3).

Cortisol levels showed very elevated values at the beginning of the experiment for the test group (10,89±1,66 µg/dl) compared to control group (2,06±0,61 µg/dl) while at the end of the experiment, although the values for the test group were still elevated (4,85±1,22 µg/dl), they fit within the physiological range and got closer to the values of the control group (1,86±0,89 µg/dl) (Fig. 1).

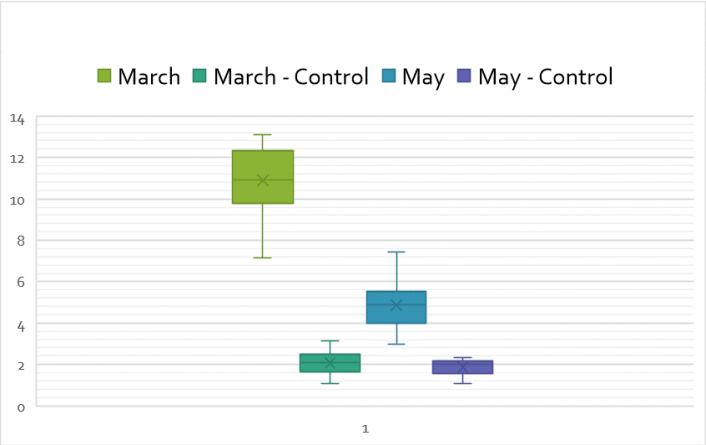

Fig. 1. Cortisol values of dogs owned by elderly people compared to control group

Although individuals from both groups got a less extended time outdoor, we consider the increased time spend together with their owners substantially increased for subjects of the control group, making them happier and coping with the change in terms of outdoor time.

The body's stress-response system is usually self-limiting. Once a perceived threat has passed, hormone levels return to normal. As adrenaline and cortisol levels drop, the body will return to its regular activities.[4] On the other hand, when stressors are always present and the body constantly feels under attack, that fight-or-flight reaction stays turned on. The long-term activation of the stress-response system and the overexposure to cortisol and other stress hormones that follows can disrupt almost all of body's processes.[5]

However, the conducted study showed that the changes that have been observed are only transitional, after removing the stress agent, the levels of cortisol dropping to normal values.

CONCLUSIONS

The study revealed a significant increase of cortisol levels in individuals owned by elderly

people at the beginning of the emergency state in Romania. However, the conducted study showed that the changes that have been observed are only transitional and have also highlighted the great capabilities of the body to adapt and to reduce the impact of the stressor agents.

REFERENCES

Bovens C., Tennant K., Reeve J., Murphy K. - Basal Serum Cortisol Concentration as a Screening Test for Hypoadrenocorticism in Dogs, J Vet Intern Med 2014;28:1541–1545;

Feldman EC, Nelson RW. Canine hyperadrenocorticism (Cushing's syndrome). In: Feldman EC, Nelson RW, eds. Canine and Feline Endocrinology and Reproduction, 3rd ed. St Louis, MO: Saunders Co; 2004:253–357;

Mealey KL, Gay JM, Martin LG, et al. Comparison of the hypothalamic–pituitary–adrenal axis in MDR1-1D and MDR1 wildtype dogs. J Vet Emerg Crit Care 2007;17:61–66;

Malancus R. - Stress induced by muzzle wearing in dogs, Lucr. Stiintifice USAMV Iasi, seria Medicina Veterinara vol 62/2019, 111-114;

Schmidt C., Kraft K. - β-endorphin and catecholamine concentrations during chronic and acute stress in intensive care patients. Eur. J. Med. Res. 1996;1(11):528–532;

Scott-Moncrieff JC. Hypoadrenocorticism. In: Ettinger SJ, Feldman EC, eds. Textbook of Veterinary Internal Medicine, 7th ed. St Louis, MO: Saunders Elsevier; 2010:1847–1857.

CT PERIPORTAL HALO SIGN IN DOGS-COMPARASION WITH HUMAN MEDICINE

Cristi GLĂVAN[1]

E-mail:cristi.glavan@yahoo.com

Abstract

Periportal halo CT sign has been well described in human medicine, being associated with multiple pathological processes (hepatobiliary, congestive heart failure, pyelonephritis, metastases) but also with fluid resuscitation and blunt abdominal trauma. It is supposed to be caused by periportal lymphangiectasia and may be related with primary or secondary liver diseases. The aim of the article is to review and analyse CT findings of periportal halo in dogs and possible relations with systemic diseases and abnormal *liver function* parameters.

Keywords: CT, portal vein, periportal halo, abdominal imaging, dogs.

INTRODUCTION

The main portal vein is formed by the confluence of the cranial and caudal mesenteric veins and the splenic vein, and therefore drains most of the blood from the abdominal organs into the liver (Budras K.D. et al, 2007), cranial mesenteric vein receiving all the jejunal branches (Evans H.E., De Lahunta A. 2013). Caudal to the hepatic entrance, receives the gastroduodenal vein, after draining the pancreaticoduodenal and gastroepiploic veins. The diameter of the portal tributaries becomes enlarged as they approach the main portal vein, and the flow is directed towards the liver.

Computed tomography is used as an advance imaging approach of abdominal pathology due to its excellent morphological resolution and its ability to image many different structures.

For assessment of the abdominal vasculature by computed tomography, a dual phase, low-pitched imaging protocol with good respiration control is used for an appropriate vascular study.

The liver parenchyma shows a homogeneous density in the range of about 60 – 70 HU in dog, values depending on technical settings (kVp, mA, slice width) and the enhancement is intense and homogeneous after contrast medium administration. Contrast resolution is the capacity of a system to accurately represent differences in tissue, physical, and/or biochemical characteristics, which are intrinsically linked to x-ray attenuation (Wisner E.,R., Zwingenberger A.L. 2015). The intrahepatic vasculature includes an arterial supply and double venous system-hepatic and portal veins (Schwartz T., Saunders J. 2011). In dual-phase CT angiography, arterial and venous vessels can be identified (Bertolini G., Prokop M. 2011). The largest hepatic veins are often visible already before contrast administration as hypodense tubular structures, becoming more evident in the arterial and venous phase of contrast administration.

Intrahepatic portal vasculature can be distinguished in CT during the venous phase following the division of the main portal vein into the two main right and left branches (figure 1) which supply the different liver lobes. For a better spatial representation of the hepatic vessels, maximum intensity projection and 3-D reconstructions can be used (Schwartz T., Saunders J. 2011).

On a CT scan, portal vein and collaterals can be seen running toward the periphery, having low density in pre-contrast study and in arterial phase, being highly attenuating in the venous phase.

In both phases, portal lymph nodes, can sometimes be visible to the right and left of portal vein, as normal anatomic structures, with typical CT appearance (Schwartz T., Saunders J. 2011, Wisner E.,R. Zwingenberger A.L. 2015).

Periportal halo sign represents a low attenuation zone seen around the intrahepatic portal veins on contrast-enhanced CT (figure 2). It can be associated with periportal oedema, which is often used as a synonymous term (Lawson T.L. et al, 1993).

[1] University of Agronomic Sciences and Veterinary Medicine of Bucharest, Faculty of Veterinary Medicine, 050097, Splaiul Independenței nr.105, Bucharest, Romania
St. George's Veterinary Hospital, WV2 1BD, St. George's Parade 8, Wolverhampton, U.K.

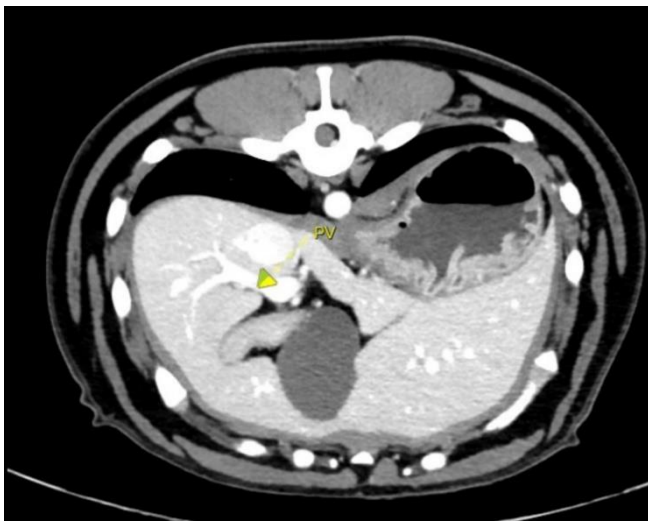

Fig.1. Normal CT appearance of the portal vein at the level of porta hepatis in transverse section (yellow arrow).

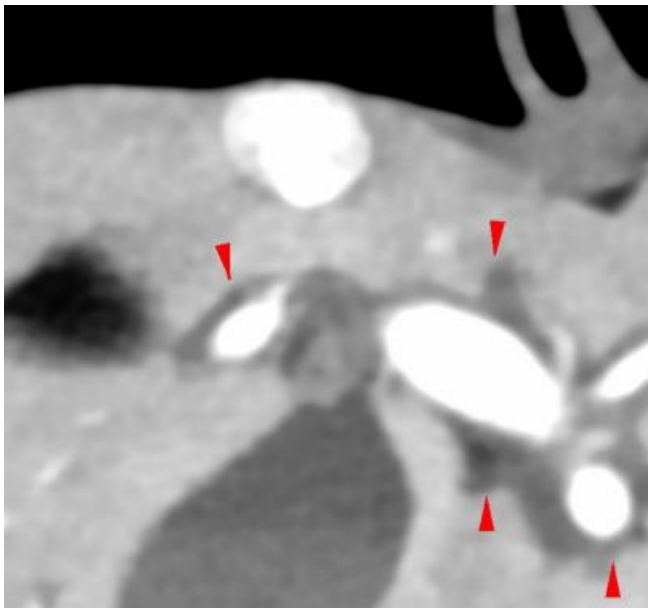

Fig.2. Transverse image of a 4-year-old neuter female diagnosed with lymphadenopathy-hyperplasia.
Periportal hypoattenuating halo in the liver parenchyma on early postcontrast images was noted (red arrows).

MATERIALS AND METHODS

The present study was performed to describe and analyse periportal halo in relation with abdominal pathology in dogs, and possible correlation with changes within liver enzymes in patients positive for periportal halo CT sign.

Consent of using the data in the study was obtain from the owners at the moment of the CT exam.

100 abdominal CT cases have been analysed retrospectively in the St. George's Veterinary Hospital (Wolverhampton, UK) between January 2019 and March 2021. Triphasic abdominal CT (aortic, portal and delayed-venous), with slices between 0.2 and 0.75 mm (SOMATON Scope, 16 slice CT, Siemens, USA), have been performed, results being recorded and analysed. General anaesthesia has been used and intravenous fluids have been administrated pre and post examination. Complete blood work has been done for all the patients included in the study before undergoing CT examination. A positive non-ionic iodinated contrast agent consisting of iohexol (Omnipaque™, GE Healthcare) was administered via an intravenous bolus, according to the literature and a dual phase CT angiography: arterial phase (9-16 s): cranial to caudal and a venous phase (10-35s): caudal to cranial have been completed (10, 16, 21).

Confirmed diagnosis of the cases was represented by 4 cases of pyelonephritis, gastrointestinal changes (congenital, inflammatory-bacterial, parasitic, and viral) including secondary lymphadenopathy-28, primary liver neoplasia and liver metastasis-22, abdominal neoplasia (other organs than liver), including secondary lymphadenopathy-40, 1 case of portosystemic shunt, 5 cases diagnosed with cardiomyopathy and valvular changes, with ages between 4 month and 15 years.

Periportal halo was seen in 11 cases: 2 cases of gastric disease (gastritis and hiatal herniation), 5 cases of lymphadenopathy, 3 cases of neoplasia and 1 case of portosystemic shunt. Lymphadenopathy was seen with all 3 cases of neoplasia and with gastritis.

RESULTS AND DISCUSSION

Periportal haloes may occur around the central portal veins or their peripheral branches and occur on both sides of the portal triads. It is supposed that those halos probably represent fluid or dilated lymphatics in the loose areolar zone around the portal triad structures. Periportal halo is reported as an abnormal imaging sign in human medicine and liver function should be evaluated in search of an underlying aetiology (Lawson T.L. et al, 1993).

In human medicine, periportal halo sign have been associated with abdominal pathology as hepatobiliary disease, particularly viral hepatitis (Zoller T., Stäbler A. 2000) , blunt hepatic trauma, cholangitis, liver transplant, and liver transplant rejection (Takaji R. et al, 2017), lymphadenopathy at the porta hepatis causing lymphatic obstruction and tumours or malignant lymphadenopathy in the porta hepatis, congestive cardiac failure ((Lawson T.L. et al, 1993), kidney disease-acute pyelonephritis (Zissin R. et al, 2006), bone marrow transplantation and was recently described with blunt abdominal trauma and

aggressive fluid resuscitation (Kuhlemann J. et al, 2011).

Periportal oedema (PPE) can be seen in different clinical settings, including in patients following trauma, being reported often on CT scan after major abdominal trauma, without liver injury. However, the underlying mechanisms and clinical significance in trauma patients remain unclear. PPE is seen significantly more often on abdominal CT scans following major traumas (ISS ≥ 16) but is not necessarily associated with liver injury (Kuhlemann J. et al, 2011).

One study showed that periportal low attenuation was a relatively common finding in the portal venous phase of triphasic contrast CT, whereas it was less usual in the arterial or equilibrium phase (Kanazawa S. et al, 1999).

A study on 30 young human patients, associated periportal low attenuation with hepatic trauma, hepatic transplantation, malignancy (undifferentiated hepatoblastoma, juvenile chronic myelogenous leukaemia), and generalized hepatic disorders (acute hepatitis and congenital hepatic fibrosis). In this study, possible mechanisms for development of periportal low attenuation include periportal tracking of blood, obstructive lymphedema, tumour infiltration, perivascular inflammation, or bile duct proliferation. (Siegel M.J., Herman T.E. 1992)

Recent studies described PPE on the hilar and peripheral sides of hepatic metastasis from colorectal cancer may be present but may suggest lymphedema and fibrosis of portal tracts and is not always indicating cancerous infiltration. (Takaji R. et al, 2017)

The most important differential diagnosis of the CT findings in veterinary medicine needs to be made with biliary dilatation, in which the low attenuation is seen on only one side of the portal triads (Schwartz T., Saunders J. 2011). On post-contrast CT, some thin enhancement along the wall is seen mainly where the gallbladder is adjacent to peritoneal fat. Even tough biliary dilatation and periportal halo may coexist, the stripe of periportal low attenuation on one side may be wider than the other.

In the present study, periportal halo CT sign was mostly reported with abdominal neoplasia and lymphadenopathy (figure 3).

Changes within the liver enzymes were noted only for the patient with an underlying portosystemic shunt, most likely being related with the effect of the shunt (figure 4). Rest of the patient's positive for periportal halo had normal liver function.

Compared with human medicine, periportal halo sign was not reported in cases of pyelonephritis, abdominal trauma, congestive cardiac failure, and primary hepatobiliary disease (other than neoplasia).

The hepatic parenchyma was homogeneous, periportal halo being seen mostly in early postcontrast venous phase (figure 5).

The article aims to present possible connection between abdominal and systemic changes with the periportal halo CT sign in dogs and to describe the CT imaging findings. Even human medicine studies described PPE as a sign associated with multiple abdominal and cardiac diseases, in veterinary medicine it is most likely an incidental finding, only a small correlation with lymphadenopathy and tumoral invasion being noted. The disadvantage of this study is that it was performed on a small group of animals, so detailed future studies on a larger number of animals are needed. Also, periportal halo may not be always reported due to the reduced use of the CT scanning in some practices.

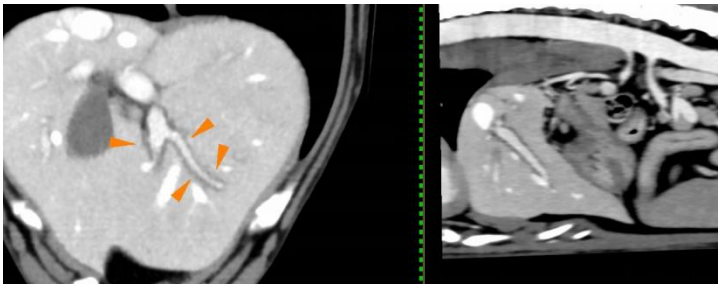

Fig. 3. Transverse and sagittal CT images of an 8-year-old male dog diagnosed with rectal adenocarcinoma. Mildly enlarged liver, with smooth rounded margins, extending caudal to the costal arch. The hepatic parenchyma is homogeneous. Hypoattenuating rim surrounding the intrahepatic portal veins is noted, consistent with periportal halo (orange arrowheads).

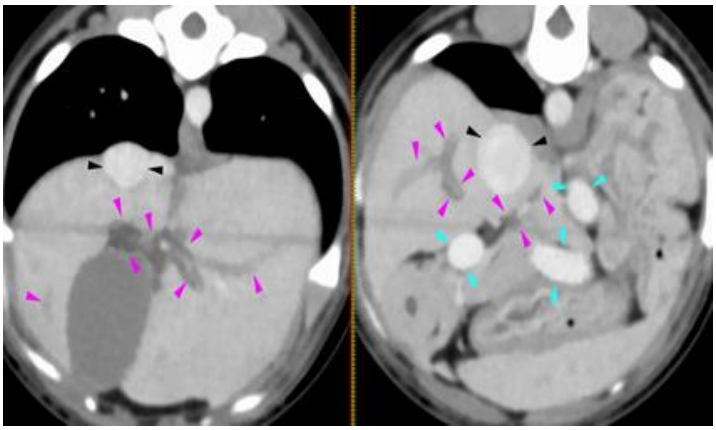

Fig.4. Transverse CT images of a 4-month-old puppy with a congenital extrahepatic right gastrocaval portosystemic shunt.

A tortuous vessel (cyan arrowheads) arising from the portal vein at the level of the junction

between the gastroduodenal and pancreaticoduodenal veins and running along the lesser curvature of the stomach have been seen. After a sinuous trajectory, it enters at the left aspect of the caudal vena cava (black arrowheads). A halo of fluid attenuation was visible, surrounding the visible intrahepatic portal branches as well as the region of the other intrahepatic portal branches (magenta arrowheads)

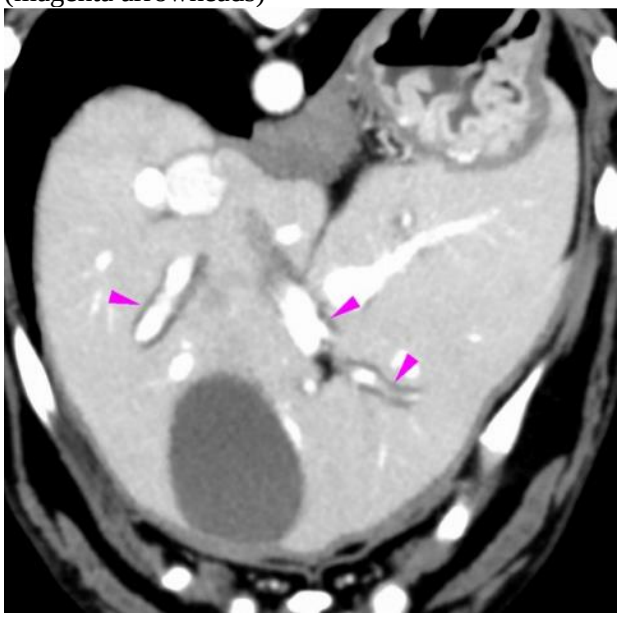

Fig.5 Transverse post contract CT scan of an 8-year-old neuter female with non-conclusive CT findings. Mildly enlarged liver with a normal portal vascularisation. A 1-1.5mm hypoattenuating halo around the intrahepatic portal vasculature is represented by the pink arrows.

CONCLUSIONS

Even though the periportal halo has been described in many studies in human medicine, being associated with many pathological processes, in veterinary medicine it is most likely incidental sign.

No correlation between changes of the hepatic parameters have been found in patients with periportal halo, exception being represented by the patient with portosystemic shunt.

Lymphadenopathy was commonly associated with CT findings of periportal halo in the present study, supporting the presence of fluid or dilated lymphatics around the portal branches described in human medicine literature. Furthermore, as previous described, this can be due to obstructive lymphedema, tumour infiltration and perivascular inflammation. In all the cases with periportal halo, hepatomegaly was noted, with smooth rounded margins. In the future, attention should also be directed toward the lymphatic system in patients with periportal halo.

For a better evaluation of the periportal halo and possible connections between systemic pathology, more detailed studies on a larger group of animals would be beneficial.

References

1. **Bertolini G., Prokop M., 2011** - *Multidetector-row computed tomography: technical basics and preliminary clinical applications in small animals*. Veterinary Journal, 189(1): 15-26.
2. **Budras K.D., McCarthy P.H., Fricke W., Richter R., Horowitz A., Berg R., 2007** - Anatomy of the dog: an illustrated text. 5th rev., Ed. Schlütersche, Hannover.
3. **Evans H.E., De Lahunta A., 2013** - Miller's Anatomy of the dog, Ed. Saunders Elsevier, St. Louis.
4. **Kanazawa S., Tanaka A., Yasui K., Akaki S., Hiraki Y., Radiat Med., 1999** - Attenuation changes in periportal region during triple-phasic contrast-enhanced CT,17(2):97-103.
5. **Kuhlemann J., Loegters T., Roehlen S., Miese R.F., Blondin D., Kröpil P., Schellhammer F., Scherer A., Lanzman R.S., 2011** - Periportal edema in trauma patients: correlation with trauma severity, Acta Radiologica, Vol 52, Issue 4.
6. **Lang P., Schnarkowski P., Grampp S., van Dijke C., Gindele A., Steffen R., et al., 1995** - Liver transplantation: significance of the periportal collar on MRI. *J Comput Assist Tomogr.,* 19: 580-585.
7. **Lawson T.L., Thorsen M..K., Erickson S.J., Perret R.S., Quiroz F.A., Foley W.D., 1993** - Periportal halo: a CT sign of liver disease. *Abdom Imaging.,* 18: 42-46.
8. **Marincek B., Barbier P.A., Becker C.D., Mettler D., Ruchti C., 1986** - CT appearance of impaired lymphatic drainage in liver transplants. *AJR,* 147: 519-523.
9. **Matsui O., Kadoya M.,Takashima T.,Kameyama T.,Yoshikawa J.,Tamura S., 1989** - Intrahepatic periportal abnormal intensity on MR images: an indication of various hepatobiliary diseases. *Radiology,* 171: 335-338.
10. **Schwartz T., Saunders J., 2011**. Veterinary Computed Tomography, John Wiley & Sons Ltd Wiley-Blackwell.
11. **Siegel M.J., Herman T.E., 1992** - Periportal low attenuation at CT in childhood. Radiology, 183(3):685-8.
12. **Takaji R., et al., 2017** - Periportal low attenuation associated with liver metastasis from colorectal cancer: evaluation using multi-detector-row CT with pathological correlation. Jpn J Radiol., 35(1):10-15.
13. **Taourel P., 2011** - CT of the Acute Abdomen. Springer Science & Business Media.
14. **Thrall D.E., 2017** - *Textbook of Veterinary Diagnostic, Seventh Edition*, Ed. Saunders Elsevier
15. **Vollmann R., Schaffler G.J., Spreizer C., Quehenberger F., Schoellnast H., 2011** - Clinical signoficance of periportal tracking as an external manifestation of acute pyelonephritis. Abdominal Imaging, 36(5): 557.
16. **Wechsler R.J., Munoz S.J., Needleman L., et al., 1987** - The periportal collar: a CT sign of liver transplant rejection. Radiology, 165 (1): 57-60.
17. **Wenzel J.S., Donohoe A., Ford K.L., et al., 2001** - Primary biliary cirrhosis: MR imaging findings and

description of MR imaging periportal halo sign. AJR Am J Roentgenol., 176 (4): 885-9.

18. **Wisner E.R., Zwingenberger A.L., 2015** - *Atlas of Small Animal CT and MRI*, Ed. John Wiley & Sons, Inc., USA.
19. **Zissin R., Osadchy A., Gayer G., Kitay-Cohen Y., 2006** - Extrarenal manifestations of severe acute pyelonephritis: CT findings in 21 cases. Emerg Radiol.13(2):73-7.
20. **Zoller T., Stäbler A., 2000** - Periportal Lymph Edema in a Patient with Acute Hepatitis A, Journal of Hepatology 32(5): 872.
21. **Zwingenberger A.L., Schwartz T., Saunders H.M., 2005** - *Helical computed tomographic angiography of canine portosystemic shunts.* Veterinary Radiology and Ultrasound, 46(1): 27-32.

SOME INDICES REGARDING OF THE EPIDEMIOLOGICAL SITUATION AND MEASURES OF PROPHYLAXY OF RABIES ON THE REPUBLIC OF MOLDOVA

Nicolae STARCIUC[1], Maxim SÎRBU

Email: n.starciuc@uasm.md

Abstract

The study aimed to analyze the epidemiological situation regarding rabies in the Republic of Moldova from 2010 to 2020. The obtained results showed that in the Republic of Moldova rabies evolves endemic, and the annual number of rabies cases in animals has dragging variations with value reaching incidences from 58 cases (2011) to 167 cases (2015), being characterized with successive waves of increasing the number of sick animals with a periodicity of 2 to 3 years. The presented data also showed a correlation of the increase of the number of rabies cases in domestic animals in accordance with the number of cases of rabies in wildlife (in foxes). The highest share of rabies in animals was recorded in foxes; these animals are being considered the main factor in the spread of the disease. The annually incidence of rabies in foxes ranged from 14 to 32 sick animals as confirmed by laboratory investigations, which represented from 15.4% to 23.2% of the total number of confirmed rabies annually. The measures that have been taken to prevent rabies in animals at national level do not ensure the definitive elimination of rabies. Therefore, a broader analysis of all the factors that maintain the infection both in wild species as well as domestic animals has to be performed, in order to take concrete actions and measures that would lead to the eradication of disease cases. Meanwhile, it is crucial to continue applying the general sanitary veterinary measures that focused on providing immunological coverage to all domestic carnivores as well as to the wild fauna where foxes represent the main vector of spreading rabies.

INTRODUCTION

Rabies is a zoonosis of virotic origin that has the highest lethality rate in both animals and humans infected with the rabies virus. Notifications of the incidence of disease annually come from more than 150 countries around the world, and the number of deaths due to rabies is over 50,000 people annually. At the same time, the number of people vaccinated due to bites caused by sick or suspected animals infected with rabies virus exceeds 15 millions of persons every year. The rabies virus particularly affects the central nervous system (brain and spinal cord). It occurs rarely in vaccinated pets, but can be easily contracted if an unvaccinated pet comes in contact with another sick or wild animal and is bitten or scratched by it. Humans can be contaminated by bites, produced from both contaminated domestic and wild animals.

The main reservoir of the rabies virus is the wildlife, being mainly represented by the fox. Contaminated foxes, depending on the stage of the disease change their behavior. The lack of fear, which is a characteristic of wild animals, is one of the most common behavioral changes that can be noted. Consequently, foxes enter in localities and in animal shelters during the day and allow humans to approach them. Moreover, without becoming aggressive they bite animals and humans and have a fixed gaze sometimes with insecure gait followed by paralysis and death.

Another important source of the disease as well as a potential reservoir of the virus represent the stray dogs in urban areas that bite humans and various species of animals. However, the measures taken to reduce their number and expose them to prophylactic vaccinations are evolving slow and require additional financing sources. Currently allocated resource cover only a very small percentage of these financial needs. Given the important social and economic impact of rabies, the disease is constantly monitored by the veterinary service and is being included in the plan of strategic veterinary sanitary measures in the republic which provides concrete measures regarding surveillance, prevention and control of the disease in susceptible animals and assures the population protection from contamination.

In view of the above factors, the proposed study was to provide an analysis of the epidemiological situation against rabies in the Republic of Moldova as well as to analyze the effectiveness of prophylactic measures for rabies in wildlife and domestic animals.

MATERIAL AND METHOD

The research was conducted in the period starting from 2010 till 2020 during which extensive epidemiological data studies and analysis were performed on the incidence of rabies in domestic animals and wildlife in the Republic of Moldova.

[1] State Agrarian University of Moldova

Clinical cases of rabies in domestic animals with rabies were examined, as well as cases of rabies in wild animals were recorded and investigated. Nonetheless, in case of suspicions of rabies, to confirm the diagnosis, samples of pathological material (animal head) were sent to the national reference laboratory Public Institution Republican Center for Veterinary Diagnosis.

The confirmation of the diagnosis was made by direct immunofluorescence examination on hippocampus, cerebellum and medulla oblongata fingerprints, stained with specific fluorescent conjugate (Lyophilized, adsorbed anti-rabies nucleocapsid conjugate) for testing for Lysavirus Genotype 3 (Mokola virus) nucleocapsides (Mokola virus), 5 Lyssavirus, EBLV 1) and 6 (EBLV 2), manufacturer of "BIO-RAD", France. The direct immunofluorescence test (IFD) was subsequently completed with the histopathological examination that reveals the presence of Babeş-Negri corpuscles in the examined histological sections.

RESULTS AND DISCUSSIONS

The Republic of Moldova is one of the countries in the European countries region which has a comparatively high number of rabies cases. In addition to the considerable economic losses, rabies is also a social disease (a zoonosis) with a lethality rate of almost 100% for humans and animals. The results of the official registration of the epizootiological situation of rabies in the Republic of Moldova date back to 1952. From 1952 to the present, rabies remains an endemic zoonosis in the territory of the Republic of Moldova with a different incidence of disease; having a higher frequency in wild animals, mainly represented by the fox. The study results come with an analysis of rabies cases in the Republic of Moldova over a period of ten years.

Figure 1 shows the dynamics and incidence of rabies. Based on the data shown in the graph, 111 official cases of rabies were registered in 2010; followed by a decrease in the number of cases to 58 in 2011. An increased tendency in the number of rabies cases can be seen in the years between 2012 and 2015 with the highest number of cases, 184, being registered in 2012 followed by 113, 138 and respectively 167 in the next years. Starting with 2016, the number of cases decreased with an index of 79 rabies cases in 2016, 59 cases in 2017, 78 in 2018 and 91 cases in 2019. In 2020 the number of rabies cases increased to 121.

The data gathered from the laboratory results obtained in the period 2010 to 2020 was used to analyze the role of wildlife, especially foxes, in maintaining and spreading cases of rabies in domestic animals. The results of this study are presented in the figure 2. Analyzing these data we see that the number of rabies cases in foxes out of the total number of rabies cases in animals was fluctuating over the period; ranging from 14 cases which represent 15.4 % of the total number of 91 cases in 2019 to 32 cases which represent 23.2% of the total number of 138 cases in 2014. The highest peak of rabies cases in foxes was recorded in the years 2010, 2012, 2014 and 2015, constituting respectively 28, 26, 32 and 29 cases.

The number of histological surveys performed annually at the Republican Center for Veterinary Diagnosis varied from 66 laboratory examinations in 2018, with a detectability rate of 87.9%, to 179 laboratory examinations in 2015, with a detectability rate of 93.3%.

Analyzing the geographical spread of rabies on the territory of the Republic of Moldova (Fig. 3) it can be seen that outbreaks of rabies are widespread in all geographical areas of the republic. However, an increased concentration of cases can be seen in the northern and central part of the republic where the surface of forest strips is higher; consequently, allowing the vector of infection to have a longer period of survival.

During the mentioned period, between 250 and 350 thousand dogs were vaccinated annually in order to prevent rabies. At the same time, at the anti-rabies offices in the republic, on average less than 2,000 people that had contact with suspected or suffering from rabies animals, or were bitten by stray dogs, cats, wild animals or rodents were vaccinated.

At the national level, exists a program that aims to prevent and combat rabies in domestic and wild animals. Moreover, any case of suspected rabies is examined in the laboratory.

The main aspects for rabies prophylaxis are focused on applying general prophylaxis measures and providing prophylactic vaccination of receptive animals; actions that aim to:

- Cartography dogs and cats from rural localities and receptive animals from the forest environment.

- Identify and confirm cases of rabies through laboratory testing and detecting the disease origins.
- Provide permanent control of the health status of domestic and wild receptive animals.
- Reduce the number of animals with high potential of infection and prevent the spread of the disease in rabbinic areas through the application of specific measures.
- Perform the rabies vaccination of domestic carnivores and foxes in forest areas.
- Ensure that there is compliance with sanitary norms for collecting, packing and transporting samples to laboratory for the diagnosis of rabies, as well as in combating disease outbreaks.

CONCLUSIONS

1. The epidemiological study carried out established a dragging evolution of animal rabies cases in the Republic of Moldova with an incidence of disease cases ranging from 58 to 167 cases per year, being characterized by successive waves of increase in the number of sick animals with a periodicity of 2 to 3 years.
2. The most frequent cases of the disease were registered in foxes, which are also considered the main vector of disease spread; having variations of confirmed cases that ranged from 14 to 32 based on laboratory investigations, which constituted from 15.4% to 23.2% of the total number of confirmed rabies cases annually.
3. The reduction of rabies in animals and the maintenance of the epidemiological situation against rabies can be achieved by the systematic immunization of carnivores, as well as foxes from all forest strips on the territory of the republic.

BIBLIOGRAPHY

Baghi, H.B.; Bazmani, A.; Aghazadeh, M. Canine vaccination: Bridging the rabies knowledge gap. Vaccine 2018, 36, p. 4–5.

Baghi, H.B.; Bazmani, A.; Aghazadeh, M. The fight against rabies: The Middle East needs to step up its game. Lancet 2016, 388, p. 1880- 1888.

Barecha, C.B.; Girzaw, F.; Kandi, R.V.; Pal, M. Epidemiology and Public Health Significance of Rabies. Persp. Med. Res. 2017, 5, p. 55–67.

Coetzer, A.; Kidane, A.H.; Bekele, M.; Hundera, A.D.; Pieracci, E.G.; Shiferaw, M.L.; Wallace, R.; Nel, L.H. The SARE tool for rabies control: Current experience in Ethiopia. Antivir. Res. 2016, 135, p. 74–80.

Esmaeilzadeh, F.; Rajabi, A.; Vahedi, S.; Shamsadiny, M.; Ghojogh, M.G.; Hatam, N. Epidemiology of animal bites and factors associated with delays in initiating post-exposure prophylaxis for rabies prevention among animal bite cases: A population-based study. J. Prev. Med. Public Health, 2017, 50, p. 210–216.

Fooks, A.R.; Banyard, A.C.; Horton, D.L.; Johnson, N.; McElhinney, L.M.; Jackson, A.C. Current status of rabies and prospects for elimination. Lancet Neurol. 2014, 348, p. 1389 -1399.

Lan, Y.C.; Wen, T.H.; Chang, C.C.; Liu, H.F.; Lee, P.F.; Huang, C.Y.; Chomel, B.B.; Chen, Y.M.A. Indigenous Wildlife Rabies in Taiwan: Ferret Badgers, a Long Term Terrestrial Reservoir. BioMed Res. Int. 2017, 2017, p. 1–6.

Mindekem, R.; Lechenne, M.S.; Naissengar, K.S. et al. Cost Description and Comparative Cost Efficiency of Post-Exposure Prophylaxis and Canine Mass Vaccination against Rabies in N'Djamena, Chad. Front. Vet. Sci. 2017, 4, 38.

Picot, V.; Rasuli, A.; Abella-Rider, A. et al. The Middle East and Eastern Europe rabies Expert Bureau (MEEREB) third meeting: Lyon-France (7–8 April 2015). J. Infect. Public Health, 2017, 10, p. 695–701.

Taylor, L.H.; Knopf, L. Partners for Rabies Prevention. Surveillance of human rabies by national authorities—A global survey. Zoonoses Public Health, 2015, 62, p. 543–552.

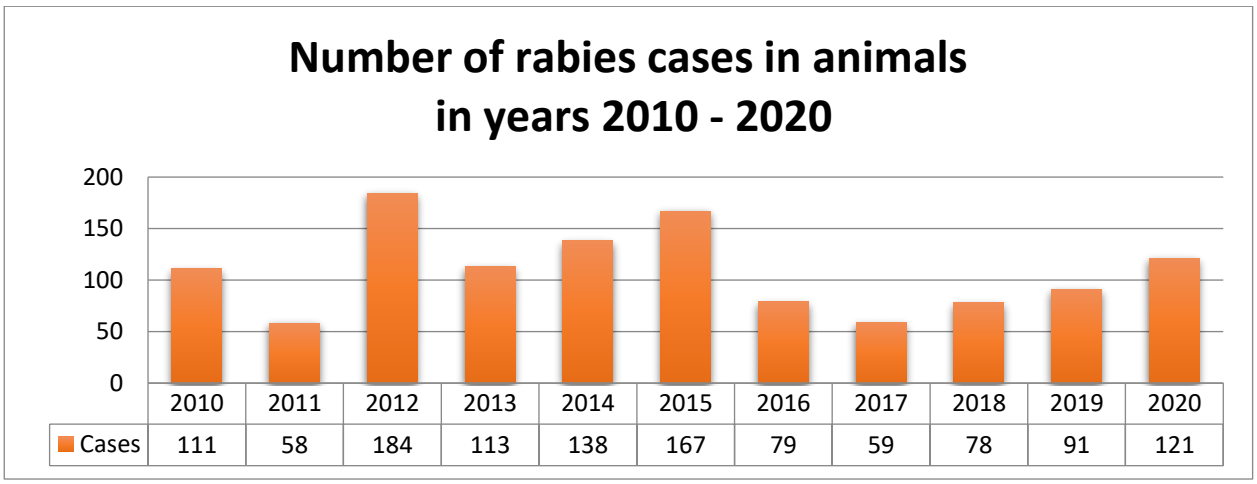

Fig. 1 Number of rabies cases in animals during the years 2010 – 2020

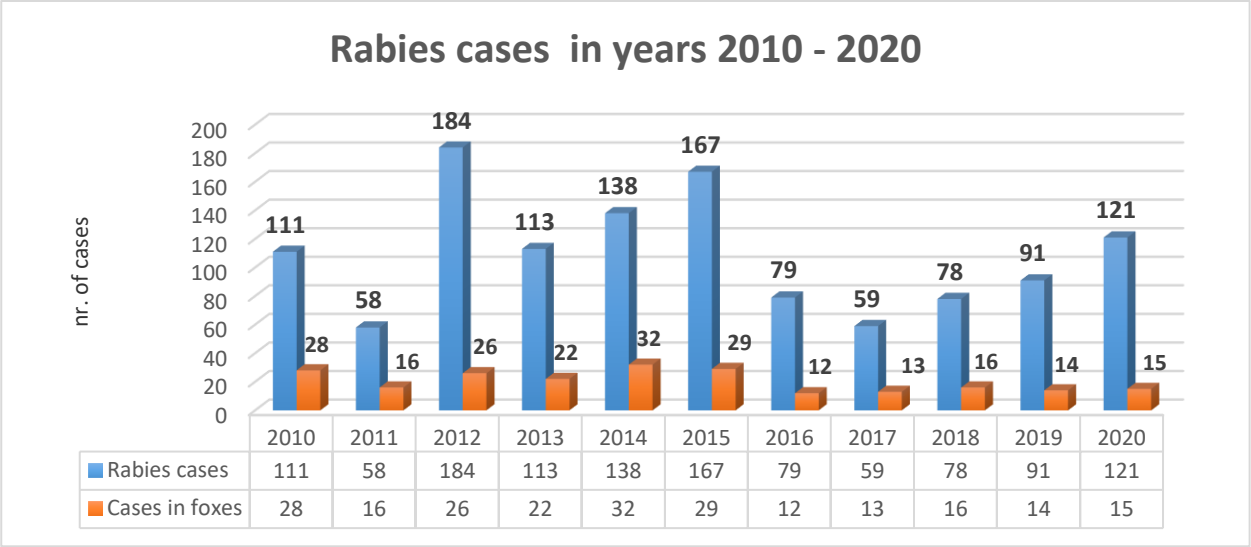

Fig. 2 Cases of rabies during the years 2010 to 2020, including foxes.

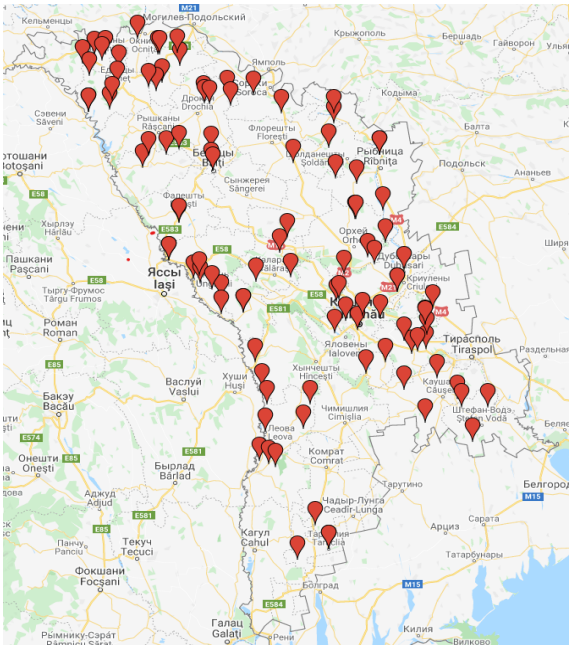

Fig.3 Geographical spread of rabies on the territory of the Republic of Moldova (2020)

EPIDEMIOLOGICAL MONITORING AND ANTIMICROBIAL RESISTANCE PROFILES OF AVIAN PATHOGENIC ESCHERICHIA COLI ISOLATES AMONG BREEDER HENS

Nicolae MALANCEA, Nicolae STARCIUC[1], Natalia OSADCI

n.starciuc@uasm.md

Abstract

Pathogenic Escherichia coli of breeder hens in most of the cases involve to use antibiotic therapy, but for better results it is important to identify the bacterial susceptibility to antibiotics in order to avoid the selection of resistance strains. Also it causes important economic losses by morbidity wich lead to decreasing egg production, decreased growth rates ,additional costs for treatment and prophylactic measures. The colibacilosis disease may occur by poor environmental conditions wich lead to decline of immunity status of hens. The obtained results showed that a high proportion (78% and 55%) of E. coli-positive samples were resistant to Ofloxacin and Gentamicin what can be concerned for poultry farmers from Republic of Moldova, due to often uses of this antibiotics in rearing proces of poultry, but high frequency of resistant isolates against Doxycycline Hydrochloride (88%) might be explained by high rates of use as prophylactic measures in breeder flock and poultry rearing. It should also be mentioned that the hight rates of antimicrobial resistance in hens suggests the possibility of vertical transmission from hatcheries, through the eggs to the next generations of poultry.

Keywords: antimicrobial susceptibility, breeder hens, colibacilosis

INTRODUCTION

Antibiotics save lives, but any time antibiotics are used in people, animals, or crops they can cause side effects and can contribute to the development of antibiotic resistance. Antibiotic-resistant germs can also share their ability to become resistant with other germs that have not been exposed to antibiotics [1].

Among all of the bacterial resistance problems, gram-negative pathogens are particularly worrisome, because they are becoming resistant to nearly all drugs that would be considered for treatment [2]. E. coli are gram-negative, rod-shaped bacteria considered normal inhabitants of the avian digestive tract. While most strains are considered to be non-pathogenic, certain strains have the ability to cause clinical disease [6].

Colibacillosis, salmonellosis, mycoplasmosis and fowl cholera are among the major bacterial diseases which threaten the poultry industry all over the world [13], including Republic of Moldova. Colibacillosis causes important economic losses through high mortality. The disease is flock and hen house associated [4].

E. coli are always found in the gastrointestinal tract of birds and disseminated widely in faeces; therefore, birds are continuously exposed through contaminated faeces, water, dust and the environment. [3].

Colibacillosis is a common cause of sporadic death in both layers and breeders but can cause sudden increased mortality levels in a flock. Inflammation of the oviduct (salpingitis) caused by *E. coli* infection results in decreased egg production and sporadic mortality, and it is one of the most common causes of mortality in commercial layer and breeder chickens [10]. The most important reservoir of *E. coli* is the intestinal tract of animals and poultry. In chickens, there are about 10^9 colony forming units (CFU) of bacteria per gram of feces and of these, 10^6 CFU are *E. coli* [8].

Wide range of antimicrobial agents is used in poultry colibacillosis treatment, which include: β-lactams (penicillins, cephalosporin), aminoglycosides, tetracycline, sulphonamides and fluoroquinolones. Thus give rise to selective pressure that lead to antimicrobial resistance against E.coli [9].

In 2016, the EFSA reported that 77.8% of E. coli isolated from broilers in European Union (EU) were resistant to antibiotics [5].

Antimicrobial resistance of the enterococci inhabiting the intestinal tract of the parent stock can result from the use of antimicrobials and can directly reflect the dissemination in commercial chicks through hatcheries which serve as a reservoir [11].

MATERIAL AND METHOD

The aim of this study were to determine the antimicrobial resistance pattern of E. Coli isolates

[1] State Agrarian University of Moldova MD- 2049, Republic of Moldova, Chișinau, str. Mircești 44,

from clinically healthy and sick hens in order to identify the epidemiological risk factors associated with vertical transmision of antimicrobial resistance strains of E.coli to their next progeny of poultry.

The study was performed in 2 breeder houses from Republic of Moldova on 17 January 2019. Approximately 10000 layer hens at 23 weeks of age were reared in each of the houses.

The flocks were reared on the floor in controlled ventelation houses and fed ad libitum with atomated distribution system of feed and water.

A total of 50 cloacal swabs were collected from breeders hens, 25 swabs from each breeder house, and transported to the laboratory in a cooler, individually inoculated into buffered peptone water (HiMedia, India) and incubated for 18 h at 37°C.

Antibiotic medication for treatment or prophylactic were not used during the study period.

Laboratory investigations were carried out at Microbiology Laboratory from Veterinary medicine Faculty, State Agrarian University of Moldova.

For the isolation of E. coli all samples, after pre enrichment in buffered peptone water for 18 h, were placed on MacConkey culture medium (HiMedia, India) for 24 h at 37°C in aerobically condition. From the primary MacConkey plates, isolated colonies was selected and subcultured on Levine Eosin Methylene Blue agar (HiMedia, India) and incubated for 24 h at 37°C. Suspected colonies witch had a dark green, black metallic sheen were then transferred on Kligler iron agar (HiMedia, India) for further characterization such as positive glucose/lactose fermentation, gas production and absence of H2S production.

Also the isolates were analyzed to biochemical tests such as indole production, methyl-red and Voges- Proskauer tests.



Fig. 1 Escherichia coli colonies on Levine Eosin Methylene Blue agar (HiMedia, India)



Fig. 2 *Escherichia coli* confirmation on Kligler iron agar (HiMedia, India)

Based on their growth characteristics and biochemical tests, 42 bacterial samples were confirmed as E.coli isolates, from 50 collected samples (84%).

The antimicrobial susceptibility testing of E. coli isolates was performed using Kirby- Bauer disc diffusion method on Mueller-Hinton agar growing medium (HiMedia, India) according to the guidelines of the Performance Standards for Antimicrobial Disk and Dilution Susceptibility Tests for Bacteria Isolated From Animals, from Clinical and Laboratory Standards Institute [12]. The susceptibility for antimicrobials were evaluated based on 7 frequently used antimicrobials in poultry industry from Republic of Moldova.

The pure culture of E.coli colonies were diluted in 2 ml of sterile saline and inoculated on Mueller-Hinton agar, the size of loopful were adjusted to 0,5 Mc Farland standard turbidity. After 5 minutes at room temperature, the antimicrobial impregnated discs containing known concentrations were placed on the surface of the agar plates, using a forceps to dispense each antimicrobial disc one at a time. The forceps were sterilized by cleaning wiyh a sterile alcohol pad after each contact with antimicrobial disc. Once all disks were set, the plates were inverted and placed in a 37 °C air incubator for 24 hours.

E. coli strain ATCC 25922 (HiMedia, India) was used for quality control purposes.

The results were recorded, by measuring in mm with a ruler the bacterial growth inhibition zones compared to standardized zones, as susceptible, intermediate, or resistant according to Clinical and Laboratory Standards Institute breakpoints.

The strains was classificated as multidrug resistant if the isolates were simultaneous resistance

to 3 or more antibiotics.

The antimicrobial discs and their concentrations used in this study were gentamicin (GEN 10µg), amoxicillin (AMX 30 µg), Ampicillin/Sulbactam (A/S 10/10 µg), Chloramphenicol (C 30 µg), Ofloxacin (OF 5 µg), Trimethoprim (TR 5 µg) and Doxycycline Hydrochloride (DO 30 µg), (HiMedia, India).

RESULTS AND DISCUSSIONS

The cultural morphology on MacConkey agar and Levine Eosin Methylene Blue agar followed by biochemical identification tests proved that 84% (42 from 50) of the examined hens were positive to *E. Coli.*

The results of antimicrobial susceptibility testing of E. coli isolates showed that there was high resistance Trimethoprim and Amoxicillin (42), followed by Ampicillin/Sulbactam (39) and Doxycycline Hydrochloride (37). The highest rate of susceptibility of E.coli isolates were found in Gentamicin (19) and Chloramphenicol (13) moreover, the intermediate susceptibility was showed by 3 isolates in Doxycycline Hydrochloride (2) and Chloramphenicol (1), 5 isolates showed resistance to all tested antibiotics, as listed in Table 1.

In average 88% of the E.coli isolates were resistant against antibiotics used in this study.

A high proportion (78% and 55%) of E. coli-positive samples were resistant to Ofloxacin and Gentamicin what can be concerned for poultry farmers from Republic of Moldova, due to often uses of this antibiotics in rearing proces of poultry. Furthermore, this study found that frequent exposure to antimicrobials with increasing age results in the emergence of multi drug resistance which is similar to finding of Khyati [7].

In this study high frequency of resistant isolates against Doxycycline Hydrochloride (88%) might be explained by high rates of use as prophylactic measures in breeder flock and poultry rearing.

Thus, these results indicate that E. Coli strains with antimicrobial resistance can be challenging for veterinarians to control the colibacillosis in poultry production, and the resistent to antimicrobial E.coli strains may contribute to vertical transmission of infection.

Consequently, constant epidemiological monitoring and antimicrobial susceptibility testing of the breeder flocks are required in order to have better results in treatment and to prevent the vertical transmission of antimicrobial resistant strains of E.coli.

Fig. 4 Antimicrobial sensitivity test of *E.coli* on Mueller-Hinton agar

Fig. 5 Antimicrobial sensitivity test of E.coli on Mueller-Hinton agar. Multidrug resistant strains.

CONCLUSIONS

1.Based on the study results, it can be stated that there is a high rate of antimicrobial resistance in hens, and among E. coli isolates were MDR strains, which can make difficult in choosing the right antibiotic for either treatment or prophylactic therapy.

2.Therefore the E. coli infections in poultry production from Republic of Moldova remains one of the most costly, because of the controlling measurements and prophylactic therapy which involve the limited effective antibiotics against hight rates of resistance bacteria.

3. The control of E.coli infections in hens should to have an sistemic aproach based on disease prevention trhought biosecurity, health monitoring and enviromental controls such as general hygiene, desinfections of the stable, accurate diagnosis by antimicrobial susceptibility testing and the use of efective antimicrobial agents or alternatives.

BIBLIOGRAPHY

Centers for Disease Control and Prevention US . Antibiotic resistance threats in the United States, 2019. http://dx.doi.org/10.15620/cdc:82532

Centers for Disease Control and Prevention US. Antibiotic resistance threats in the United States, 2013. https://www.cdc.gov/drugresistance/pdf/ar-threats-2013-508.pdf

Charlton, B.R. ed. Avian Disease Manual. 6th edition. Athens: American Association of Avian Pathologists (AAAP), 2006.

D. Vandekerchove, P. De Herdt, H. Laevens & F. Pasmans (2004) Colibacillosis in caged layer hens: characteristics of the disease and the aetiological agent, Avian Pathology, 33:2, 117-125, DOI: 10.1080/03079450310001642149

EFSA and ECDC (European Food Safety Authority and European Centre for Disease Control) 2018. The European Union summary report on antimicrobial resistance in zoonotic and indicator bacteria from humans, animals and food in 2016. EFSA J. 16:5182, https://doi.org/10.2903/j.efsa.2018.5182

Kahn, C.M. ed. The Merck Veterinary Manual. 10th edition. Whitehouse Station: Merck & Co., Inc., 2010.

Khyati Bhardwaj , Suchitra Shenoy M , Dr. Shrikala Baliga , Dr. Unnikrishnan B , Dr. Vasanth Kumar Shetty , Research Note: Characterization of antibiotic resistant phenotypes and linked genes of Escherichia coli and Klebsiella pneumoniae from healthy broiler chickens, Karnataka, India, *Poultry Science* (2021), doi: https://doi.org/10.1016/j.psj.2021.101094

Lutful Kabir SM. Avian colibacillosis and salmonellosis: a closer look at epidemiology, pathogenesis, diagnosis, control and public health concerns. Int J Environ Res Public Health. 2010;7(1):89–114. https://doi.org/10.3390/ijerph7010089

Landoni MF, Albarellos G. The use of antimicrobial agents in broiler chickens. Vet J. 2015a;205(1):21–7. https://doi.org/10.1016/j.tvjl.2015.04.016

Nolan, L. et al. Chapter 18: Colibacillosis. Diseases of Poultry. 13th edition. Ames: Wiley-Blackwell, 2013. ISBN: 978-1-118-71973-2

Osman, K. M., A. D. Kappell, M. Elhadidy, F. Elmougy, W. A. A. ElGhany, A. Orabi, A. S. Mubarak, T. M. Dawoud, H. A. Hemeg, I. M. I. Moussa, A. M. Hessain, and H. M. Y. Yousef. 2018. Poultry hatcheries as potential reservoirs for ntimicrobial-resistant Escherichia coli: a risk to public health and food safety. Sci. Rep. 8:5859.

Performance Standards for Antimicrobial Disk and Dilution Susceptibility Tests for Bacteria Isolated From Animals, 5th Edition, ISBN 978-1-68440-092-8, 2020

https://www.thepoultrysite.com/articles/e-coli-vaccination-is-safe-for-hens-in-lay-study-finds

Fig. 3 Escherichia coli isolates identified in tested hens

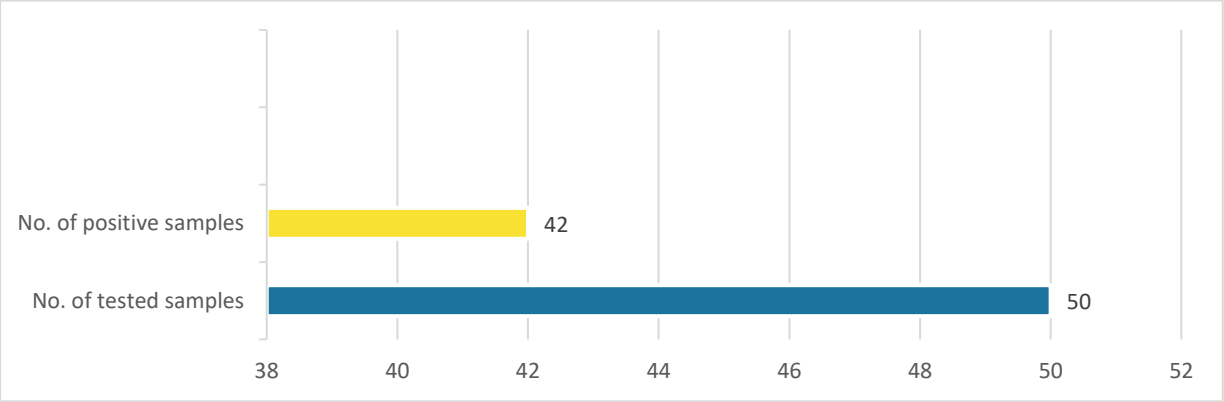

Table 1. **Antimicrobial susceptibility testing results**

Antimicrobial disc and concentration	Total E.coli isolates (n=42)		
	No. Susceptible	No. Intermediate	No. Resistant
Gentamicin (GEN 10 µg)	19	0	23
Amoxicillin (AMX 30 µg)	0	0	42
Ampicillin/Sulbactam (A/S 10/10 µg)	3	0	39
Chloramphenicol (C 30 µg)	13	1	28
Ofloxacin (OF 5 µg)	9	0	33
Trimethoprim (TR 5 µg)	0	0	42
Doxycycline Hydrochloride (DO 30 µg)	3	2	37

Fig. 6 Antibiotic susceptibility pattern of E.coli isolates from breeder hens

NONINVASIVE MEASUREMENT OF INTRAOCULAR PRESSURE IN RATS WITH THE ICARE TONOVET REBOUND TONOMETER

Diana – Larisa ANCUȚA[6,2], Fabiola IONIȚĂ [1,2], Diana ALEXANDRU[7], Maria CRIVINEANU [2], Cristin COMAN[1,3,4]

e-mail: diana.larisa.ancuta@gmail.com

Abstract

Rebound tonometry is an accurate method of measuring intraocular pressure (IOP) that is easy to perform and does not involve the use of anesthesia. This, together with biological and genetic advances contributes to the use of ocular etiopathogenetic data of rats. The aim of the study was to evaluate the applicability, reproducibility and accuracy of a rebound tonometer in measuring IOP in rats. IOP was measured three times, at different time intervals, in 40 male and female Sprague Dawley rats, 10 weeks old. The animals studied were kept in normal living conditions, not subject to external stress. The mean IOP expressed consecutively of six successive measurements for each eye was determined with the iCare TonoVet rebound tonometer. The readings generated gave IOP values between 13.3 - 14.5 mmHg in males and 12.6-16.1 mmHg in females. There were no significant differences between the eyes in terms of the values obtained in a measurement so the variability was 0.02 mmHg. Rebound tonometry is convenient, can be used without topical anesthesia and provides fast and accurate results. These can be useful to the clinician, when we talk about the rat as a pet or to scientists, when the rat is chosen as an animal model for various biomedical research.

Key words: rat, iCare tonovet, rebound tonometry

In experimental research involving the eye, it is desirable to use animal models that are easy to handle and less expensive such as rats. The physiology and pathophysiology of the rat has already been studied, at present there is enough information worthy of consideration when studying optic nerve damage, ocular inflammation or glaucoma.

Any animal model for glaucoma research, for example, requires accurate and reproducible measurements of intraocular pressure (IOP) which is an accepted risk factor for this condition (Mermoud et al., 1994). Lately, the animal models preferred by ophthalmologists, are rodents

From an anatomical point of view, the rat's eye presents the head of the optic nerve obstructed by a series of arteries and veins arranged in the form of a disc that enters the lower neural portion of the optic nerve head. This can be considered a significant difference from the anatomy of the human eye, where blood vessels are already inside the optic nerve, at the entrance to the eyeball. Histologically, in cross-section, the neuronal portion of the head of the optical rat nerve has an oval shape at the level of the Bruch membrane and sclera, with the short axis oriented vertically (Morrison et al., 2015).

Another important feature of the optic nerve head of the rat is the absence of the collagen cribrosa lamina, in rodents, being replaced by "glial lamina" (Sun et al., 2009) which is made up of astrocytes oriented over the scleral canal and perpendicular to the axonic fascicles (Tehrani et al., 2014). Thus, the glial cribrosa lamina of the rat contains numerous relationships that will help us use these animals to understand how the cellular biology of the optic nerve head responds to increases and fluctuations in IOP and affects axonal lesions in human glaucoma (Burgoyne C.F., 2011).

The blood supply to the head of the optic nerve of the rat is made through the ophthalmic artery, as in primates that immediately under the optic nerve trifurcate, in two long posterior ciliary arteries and the central retinal artery. The latter, entering the lower globe of the optic nerve, provides capillary beds of the retinal nerve fiber layer and the anterior portion of the head of the optic nerve. All these capillary beds either pass into the central vein of the retina or into the veins that are in the sheath of the optic nerve. The veins of the optic nerve sheath also communicate with the

[1] Cantacuzino National Medico-Military Institute for Research and Development, Bucharest
[2] University of Agronomic Sciences and Veterinary Medicine of Bucharest, Faculty of Veterinary Medicine, Bucharest
[3]Spiru Haret University, Faculty of Veterinary Medicine, Bucharest
[4]The Fundeni Clinical Institute, Center of Excellence in Translational Medicine, Bucharest

central retinal vein and choroid veins through a large peripapillary sinus. The presence of this communication highlights the importance of not disrupting any aspect of venous outflow when modeling increased IOP. (Morrison et al., 2005).

Another important element on which IOP depends is the aqueous humor. In the rat, as in primacy, the conveyance of aqueous humor occurs through the trabecular network, in the Schlemm canal and through the limbal sclera through the collecting channels to the episcleral venous circulation (Morrison et al., 1995) This episcleral plexus, as well as the Schlemm canal is continuous.

In the last decade, the most popular method of evaluating IOP is rebound tonometry, even if the tonometry performed by contact methods is accurate and repeatable. The important landmark for which the rebound tonometry is preferred is the facility of handling the device in new pets, including laboratory animals. In these, the use of corneal anesthesia is not necessarily necessary when IOP is measured by rebound tonometry. I Care Tonovet is a portable, easy-to-use instrument that is equipped with a probe that requires very short contact with the corneal surface to give precise IOP results. One of the disadvantages of using the Tonovet is that the position of the probe must be a horizontal one at contact with the cornea, perpendicular to its surface, because if the wrong angle or the peripheral corneal region on which the probe is applied, it can provide erroneous values of the IOP (Rodrigues B et al. 2021).

The purpose of our study is to evaluate the applicability, reproducibility and accuracy of the rebound tonometer to healthy rats in the Sprague Dawley strain. The values obtained from the IOP evaluation are useful when the researches concern the prevention, diagnosis or treatment of eye diseases or for pet’s clinician to diagnose and treat eye diseases.

MATERIAL AND METHOD

The animal study was approved by the Ethics Commission of the "Cantacuzino" National Medical-Military Development Research Institute and authorized by the competent authority. The procedures were carried out in accordance with the provisions of Directive 2010/63/EU on compliance with the rules for the care, use and protection of animals used for scientific purposes.

The research has been carried out in the "Cantacuzino" National Medical-Military evelopment Research Institute (CI), Preclinical Testing Unit.

For the IOP measurement, 40 rats, the Sprague Dawley strain, males and females (20:20), aged 8-10 weeks, were used. The animals come from the Baneasa Animal Facility (BAF), an authorized CI for breeding and use of animals for scientific purposes. During the experiment, the animals were accommodated in individually ventilated cages, arranged in the BAF experimentation space where the ambient temperature was 22-24^{0}C, the relative humidity of 45-65%, and the light/dark cycles of 12/12h. Food and water were provided ad libitum.

The iCare Tonovet tonometer is a non-invasive IOP measurement tool that uses a probe that propagates perpendicular to the cornea using a solenoid. The device has 3 modes of operation "h", "d" and "p" for horses, dogs / cats and other species, respectively. In the case of our study it was set to "p" mode and was used according to the manufacturer's instructions. The equipment was set to calculate the average of 6 consecutive IOP measurements for each eye. At the beginning of the experiment, all the animals were examined ophthalmological, and a single examiner performed the workmanship for measuring the IOP. Every day 0, day 44 and day 70 of the experiment, the animals were handling by an operator, and the examiner, measured the IOP keeping the device pointing perpendicular to the cornea. The final IOP value indicated by the device represented the average of 6 consecutive measurements. The IOP measurement surgery was performed 3 times, at same times of the day, and at the end of the study, no animal showed corneal lesions or other conditions following the use of the Tonovet rebound tonometer.

Figure 1 : iCare Tonovet rebound Tonovet tonometer

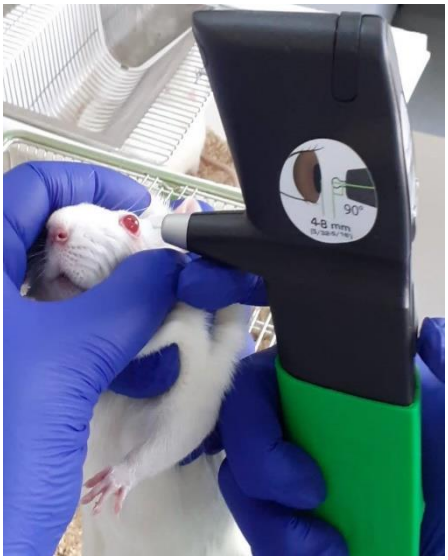

Figure 2: Measurement of IOP

RESULTS AND DISCUSSIONS

During the examinations, the animals were restraining manually and without anesthesia. All procedures were completed in less than 5 minutes per animal, at each measurement the same two people were used so that the animals are not subjected to stress.

Statistical analysis was performed using Microsoft Excel, the current version.

At the beginning of the study, animals showed PGI values between 13.2 and 13.6 mmHg in males and females. For the next two measurements, the recorded values were slightly increased but did not exceed 16.1 mmHg, which means that the reference values of the IOP in Sprague Dawley rats fall between 13.3 - 14.5 mmHg in males and 12.6-16.1 mmHg in females (table 1).

Tabel 1.

Average and standard deviation of IOP in rats

Sex	Day 0		Day 44		Day 77	
	LE	RE	LE	RE	LE	RE
Males	13,6 ±0,96	13,3 ±1,63	14,5 ±2,67	14,3 ±1,25	15,7 ±1,15	15,5 ±2,79
Females	13,2 ±1,81	13,6 ±2,83	16,1 ±2,37	12,6 ±2,17	15,7 ±1,15	15,5 ±2,79

No significant differences between the eyes (t ‹ 0,05) nor between the measurement intervals were observed (Figure 3). So, using the rebound tonometry method, we were able to prove that it was well tolerated by rats, with no eye injuries recorded. The technique did not involve anesthesia of the corneal surface, the same observations being recorded in previous studies on dogs, horses (Knollinger A.M, 2005), cats (Rusanen E, 2010), ruminants (Peche N., 2018), chinchillas (Snyder K.C., 2018) or humans (Pakrou N, 2008)

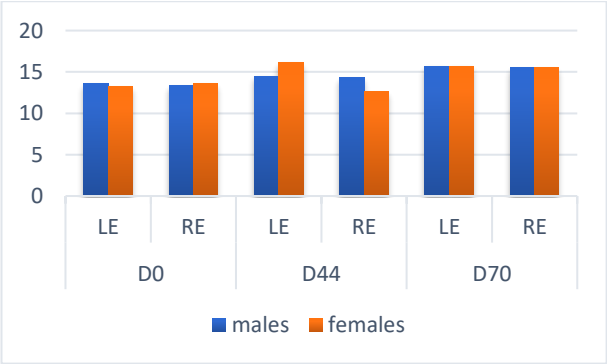

Figure3: IOP oscillations between the left and right eyes during the experiment

Albino rats are commonly used in the study of eye conditions such as glaucoma but also in general studies of non-clinical toxicity of chemicals and drugs. In particular, Sprague – Dawley rats are among the most widely used animal strains in many laboratories because they are suitable for toxicity assessment studies, with extensive biological reference data available. Observation of ocular toxicity may lead to the suspension of the further development of the compounds or to the regulation of the further use of the chemical in order to avoid human exposure. In non-clinical studies of in vivo toxicity, the eyes are typically evaluated by observing clinical signs and conducting ophthalmological and histopathological examination to assess the potential of a drug for inducing ocular toxicity (Morita J. et al., 2020). Morphological eye changes are mainly found through ophthalmological examination using techniques such as bio microscopy, tonometry and direct or indirect ophthalmoscopy (OECD guideline, 2018).

The results of our research on Sprague Dawley rats have highlighted values close to those obtained on Wistar rats (17.3 mmHg±5.25mmHg), which in turn are whitish and whose eyes are devoid of melanin pigments. However, there are studies that show that there are no considerable variations in IOP between the eyes of albino and pigmented rats, but rather, IOP seems to be dependent on the ciradian rhythm (Valiente-Soriano F.J et al., 2015), in albinos frequently registering ischemic lesions caused by the increase of IOP following prolonged exposure to light.

CONCLUSIONS

By measuring the IOP with the iCare Tonovet rebound tonometer, we obtained values similar to those reported in the specialized literature, which strengthens the credibility of the working method and technique. The data obtained in our experiment suggest that the limits of the IOP values in Sprague Dawley rats fall between 12.6 (±2.17) - 16.1(±2.37) mmHg. Information to be useful when this strain of rats is chosen for ophthalmological studies or even when choosing the rat as a pet.

ACKNOWLEGMENTS

This study is an integral part of the DECODE project, contract 11SOL 2020.

REFERENCES

Burgoyne C.F., 2011 - *A biomechanical paradigm for axonal insult within the optic nerve head in aging and glaucoma*.Exp Eye Res. 93(2):120-32.

Knollinger A.M, La Croix N.C., Barrett P.M., Miller P.E., 2005 - *Evaluation of a rebound tonometer for measuring intraocular pressure in dogs and horses*. J Am Vet Med A.227:244-248.

Mermoud A. , G Baerveldt D. S., Minckler M. B., Lee N. A., 1994 - *Intraocular pressure in Lewis rats*. Invest Ophthalmol Vis Sci. Apr;35(5):2455-60.

Morita J., Yamashita H., Sugihara, K., Wakamatsu M., Sasaki M. 2020 - *Spontaneous Ocular Abnormalities in Sprague–Dawley Rats.* Comp Med. 1;70(2):140-144 ;

Morrison J.C., Johnson E.C., Cepurna W., Jia L., 2005 - *Understanding mechanisms of pressure-induced optic nerve damage*.Prog Retin Eye Res.24(2):217-40.

Morrison J.C, Fraunfelder F.W., Milne S.T., Moore C.G., 1995 - *Limbal microvasculature of the rat eye.* Invest Ophthalmol Vis Sci. 36(3):751-6.

Morrison J.C,. Cepurna W, Johnson E.C, 2015 – *Modeling glaucoma in rats by sclerosing aqueous outflow pathways to elevate intraocular pressure*. Exp Eye Res.141: 23–32.

OECD guideline for the testing of chemicals. *Chronic toxicity studies. Section 4*. Adopted in 25 June 2018. https://doi.org/10.1787/9789264071209-en

Pakrou N, Gray T, Mills R, Landers J, Craig J., 2008 - *Clinical comparison of the Icare tonometer and Goldmann applanation tonometry*. J Glaucoma. 17:43-4.

Peche N., Eule J.C., 2018 - *Intraocular pressure measurements in cattle, sheep, and goats with 2 different types of tonometers*. Can J Vet Res. 82:208-215.

Rodrigues B., Montiani-Ferreira F., Bortolini M, Somma A.T., KomáromyA.M, Triches P., 2021 - *Intraocular pressure measurements using the TONOVET rebound tonometer: Influence of the probe-cornea distance.* Vet Ophthalmol Suppl 1(Suppl 1):175-185.

Rusanen E., Florin M., Hässig M., Spiess B.M., 2010 - *Evaluation of a rebound tonometer (TonoVet®) in clinically normal cat eyes.* Vet Ophthalmol.13:31-36.

Snyder K.C., Lewin A.C., Mans C., McLellan G.J., 2018 - *Tonometer validation and intraocular pressure reference values in the normal chinchilla (Chinchilla lanigera).* Vet Ophthalmol. 21:4-9.

Sun D., Lye-Barthel M., Masland R.H., Jakobs T.C., 2009 - *The morphology and spatial arrangement of astrocytes in the optic nerve head of the mouse*. J Comp Neurol. 516(1):1-19.

Tehrani S., Johnson E.C., Cepurna W.O., Morrison J.C., 2014 - *Astrocyte processes label for filamentous actin and reorient early within the optic nerve head in a rat glaucoma model*. Invest Ophthalmol Vis Sci55(10):6945-52.

Valiente-Soriano F.J., Salinas-Navarro M., Jiménez-López M., Alarcón-Martínez L., Ortín-Martínez A., Bernal-Garro J.M., Avilés-Trigueros M., Agudo-Barriuso M., Villegas-Pérez M.P., Vidal-Sanz., 2015 - *Effects of ocular hypertension in the visual system of pigmented mice.* PLoS One.; 10(3):e0121134.

MONITORIZAREA UNOR PARAMETRI MICROBIOLOGICI ȘI A COMPOZIȚIEI ALGALE ÎN APELE DE SUPRAFAȚĂ ALE UNOR EMISARI DIN BAZINUL DORNELOR

Ionela VOLOȘENIUC[1] Liviu MIRON[1]
ionela.voloseniuc@valvis-holding.com

Abstract

The objective of this study was to establish the microbiological and algal load of surface waters from the streams that cross the Dorna's Basin. In order to carry out this study, 10 sampling stations were established over four streams, the study taking place during the period of two years, 2017 and 2018, between May and October. The samples were analyzed in the laboratory using specific methods for each monitored indicator, observing the fluctuations which are determined by the sampling location, weather phenomena, and the influence of anthropogenic factors that are relevant for the streams that were studied. Therefore, microbiological parameters are strongly influenced by contamination with faeces from both animals (wild and domestic), as well as from households, that are not connected to a centralized sewer system, especially the ones which use septic tanks that are, in many cases, inappropriately built. All microbiological indicators showed significant variations between sampling stations along the same stream, upstream the values recorded being much lower than downstream. The samples that presented the lowest values, for all the evaluated parameters, were those collected upstream of the Călimănel brook. The absence of the *Pseudomonas aeruginosa* indicator from all samples taken during the study was recorded at two of the stations, Călimănel-sus (stream) and Secu-sus and the spores of sulfite-reducing anaerobic bacteria (*Clostridium*) were not identified in the samples collected from Călimănel-sus station (stream). The samples with the highest degree of contamination were those taken from Arinu-jos station and those from Călimănel-jos, the anthropic influence being evident through the economic activities that were carried out. Similar values were obtained following the analyzes performed for each type of algae, recording higher levels of parameters in the case of samples taken from the Arini-jos station. The maximum values were recorded from the samples taken from the stations on the Arinu rivulet in August 2018, after a torrential rain, when large quantities of organic substances were entrained. The main conclusion obtained from the interpretation of the results is that the surface waters have a significant microbial load and that it multiplies exponentially from the source to the collector.

Key words: parametri microbiologici, alge, contaminare

Microbiologia apelor de suprafață se caracterizează printr-o încărcătură importantă de specii și genuri, fiind cunoscut faptul că apa este un mediu propice dezvoltării multor microorganisme. Studiul de față își propune evaluarea calitativă și cantitativă a unor indicatori microbiologici definitorii în evaluarea calității apei. Având în vedere faptul că nu există normative microbiologice pentru apele de suprafață, au fost urmăriți parametrii definiți în legislația privind apele minerale naturale. Obiectivul principal îl constituie evaluarea poluării antropice cu specii potențial patogene pentru sănătatea umană și animală. Probele au fost prelevate din aceleași stații, din amonte și aval comunităților umane. Parametrii urmăriți au fost: număr total de germeni la 22ºC și 37ºC, enterococi intestinali, bacterii coliforme și *Escherichia coli, Pseudomonas aeruginosa,* precum și spori ai unor bacterii anaerobe sulfito-reducătoare (*Clostridium sp.)*. Metodele de analiză utilizate au fost cele indicate de legislație, folosind medii de cultură specifice fiecărui tip de microorganism.

De asemenea, studiul a urmărit și încărcătura algală a surselor de apă studiate. Acest parametru nu este definit în legislația apelor curgătoare sau a apelor minerale naturale, rezultatele obținute au fiind astfel comparate între ele, în lipsa unui reper. Cercetările au urmărit evidențierea creșterii masei algale de la izvor la vărsare, precum și între surse. Metoda utilizată a fost cea spectrometrică. Monitorizarea acestor parametri are o importanță deosebită pentru biosecuritatea surselor de apă, cunoscut fiind faptul că apa reprezintă un vector important pentru microorganismele patogene, la om și animale.

MATERIAL ȘI METODĂ

În intervalul mai - octombrie a fiecărui an de studiu, 2017 și 2018, s-au prelevat 120 de probe de apă de suprafață din patru emisari care străbat Bazinul Dornelor, cu stații de prelevare în amonte și aval comunităților umane, urmărindu-se o serie de indicatori semnificativi pentru aprecierea calității apelor de suprafață. Probele s-au recoltat în recipiente sterile de 500 ml și au fost transportate în genți frigorifice la laborator, unde analizele s-au efectuat în maxim o oră de la prelevare. Indicatorii urmăriți au fost**:** 1**.** Numărul total de germeni (NTG) prin metoda numărării coloniilor prin însămânțare

în mediu de cultură agar. 2. Bacterii_coliforme și *Escherichia coli* prin metoda filtrării prin membrană; 3. Enterococi intestinali, prin metoda filtrării prin membrană. 4. *Pseudomonas aeruginosa* prin metoda filtrării prin membrană. *5.* Spori de bacterii anaerobe sulfito-reducătoare *(Clostridium),* prin metoda filtrării prin membrană; 6. Biomasă algală și substanță galbenă prin determinarea spectrometrică a conținutului de clorofilă *a*.

REZULTATE ȘI DISCUȚII

Pentru **numărul total de germeni la 22ºC**, valorile citite s-au încadrat între 240 UFC/ml și 82.000 UFC/ml, lucrându-se cu diluții de până la $10^{-3,}$ pentru o mai bună acurateț e a rezultatelor. Analizând toate rezultatele pentru acest parametru, se observă că cele mai mici valori au fost obținute la probele prelevate din stațiile din amonte ale pârâului Călimănel, unde, constant, rezultatele au fost mult mai mici comparativ cu celelalte probe. Valorile cele mai ridicate au fost obținute pentru probele prelevate de la stațiile de pe Secu și Arinu.

Pentru **numărul total de germeni la 37ºC,** valorile citite s-au încadrat între <100 UFC/ml și 4.300 UFC/ml, lucrându-se cu diluții de până 10^{-3}, tot pentru o mai bună acurateț e a rezultatelor. În urma analizei rezultatelor obținute pentru acest parametru, s-a observat că cele mai mici valori au fost obținute tot pentru probele prelevate din stațiile din amonte ale pârâului Călimănel. Rezultatele obținute la examinarea probelor recoltate din celelalte stații au prezentat fluctuații de la o lună la alta, înregistrându-se valori mai mici la stațiile din amonte față de cele din aval.

Pentru parametrul **bacterii coliforme**, valorile citite s-au încadrat între <1 UFC/ 50 ml și 1.650 UFC /50 ml. Astfel, cele mai mici valori au fost obținute pentru probele prelevate din stațiile din amonte ale pârâului Călimănel, pentru care, constant, s-au obținut rezultatele foarte mici comparativ cu toate celelalte probe. Pentru probele prelevate din celelalte puncte de recoltare, rezultatele au variat lunar, valori mai reduse fiind observate în cazul stațiilor din amonte față de cele din aval.

Pentru ***Escherichia coli,*** valorile citite s-au încadrat între <1 UFC/ 50 ml și 1.000 UFC /50 ml. Ca și în cazul parametrilor anterior prezentați, valorile cele mai reduse au fost obținute la probele prelevate din stațiile din amonte ale pârâului Călimănel. Variații de la o lună la alta și valori mai mici pentru probele recoltate din stațiile din amonte față de cele din aval au fost observate și pentru acest indicator.

Suplimentar s-au realizat și teste de identificare a speciilor folosind KIT - uri Biomerieux, denumite comercial *API E* pentru grupa coliformilor, care au ca principiu de determinare un complex de teste biochimice. Aceste teste au confirmat rezultatele obținute prin tehnici microbiologice, privind prezența bacteriei *Escherichia coli* în mai multe probe. Prin aceleași teste au fost identificate mai multe specii din familia coliformilor, precum *Enterobacter cloacae, Enterobacter sakazakii, Enterobacter amnigenus, Klebsiella pneumoniee, Escherichia vulgaris.*

Pentru **enterococii intestinali**, valorile citite s-au încadrat între <1 UFC/ 50 ml și 650 UFC /50 ml. Și pentru acest parametru se mențin observațiile privind valorile reduse obținute în cazul probelor prelevate din stațiile din amonte ale pârâului Călimănel, cât și constanța fluctuațiilor lunare și a valorilor mai reduse observate pentru probele prelevate din stațiile din amonte, față de cele din aval.

Pentru ***Pseudomonas aeruginosa***, valorile citite s-au încadrat între <1 UFC/ 50 ml și 48 UFC /50 ml. Analizând toate rezultatele pentru acest parametru, se observă absența acestei bacterii din toate probele prelevate de la stațiile Călimănel-sus (pârâu) și Secu-sus, în cei doi ani evaluați. Pentru restul stațiilor din amonte, au fost obținute valori reduse pentru un număr mic de probe. La probele prelevate de la stațiile din aval, rezultatele au fluctuat de la o lună la alta. Suplimentar s-au realizat și teste de identificare a speciilor folosind KIT - uri Biomerieux, denumite comercial *API NE*, care utilizează, pentru determinare, un complex de teste biochimice. Prin aceste teste s-au identificat mai multe specii ale genului *Pseudomonas: P. aeruginosa, P. flourescens, P. luteorla, P. stutzeri.*

Pentru **sporii de bacterii anaerobe sulfito - reducătoare *(Clostridium),*** valorile citite s-au încadrat între <1 UFC/ 50 ml și 25 UFC /50 ml. În urma analizei globale a rezultatelor pentru acest parametru, s-a observat absența acestor bacterii din majoritatea probelor prelevate de la stațiile din amonte ale pârâului Călimănel, o sigura probă fiind pozitivă (iulie 2018). La probele prelevate de la restul stațiilor, rezultatele au prezentat fluctuații lunare și valori mai mici la stațiile din amonte față de cele din aval.

Pentru **alegele verzi**, citite de LED - urile cu 470 nm lungime de undă, rezultatele obținute se încadrează între 0 și 2,35 µg/l, cu o medie 0,23 µg/l. Valorile maxime au fost înregistrate la probele prelevate pe 17 iulie 2018, de la stațiile de pe pârâul Arinu, după o ploaie abundentă, valori coroborate cu creșteri exagerate ale substanțelor organice, valori ridicate ale încărcăturii microbiene, dar și cu valori crescute ale algelor albastre-vezi și diatomee.

Pentru **algele diatomee,** citite de LED - urile cu 525 nm lungime de undă, rezultatele obținute se încadrează între 0 și 2,71 µg/l, cu o medie de 0,72 µg/l.

Pentru **algele criptofite**, citite de LED - urile cu 570 nm lungime de undă rezultatele obținute se încadrează între 0 și 0,58 µg/l, cu o medie 0,24 µg/l. Valorile maxime au fost înregistrate în probele prelevate de la stațiile de pe pâraiele Secu sus și Arinu sus.

Pentru **algele albastre - verzi,** citite de LED - urile cu 610 nm lungime de undă, rezultatele obținute se încadrează între 0 și 2,49 µg/l, cu o medie de 0,14 µg/l. Valorile maxime au fost înregistrate la probele prelevate de la stațiile Arinu iar la probele prelevate de la stațiile din amonte ale pârâului, rezultatele au fost negative, exceptând luna octombrie 2017.

Pentru **concentrația algală totală** (reprezentată de suma valorilor de la algele verzi, diatomee, criptofite și alge albastre - verzi) rezultatele se încadrează între 0,03 µg/l și 7,57 µg/l, iar media este de 1,35 µg/l.

Pentru **substanța galbenă** (reprezintă substanțe organice din apă, de altă provenienţă decât din alge, fiind un indicator al încărcături organice din apă), citită de LED - urile cu 370 nm lungime de undă, valorile maxime înregistrate sunt coroborate cu valorile foarte ridicate de la substanțele organice din probele prelevate pe 17 iulie 2018, de la stațiile de pe pârâul Arinu, după o ploaie abundentă. Restul valorilor prezintă omogenitate fiind identificate fluctuații mici între luni și stații de prelevare.

CONCLUZII

Concluzia principală obținută din interpretarea rezultatelor este aceea că apele de suprafață au o încărcătură microbiană semnificativă și că aceasta se multiplică exponențial de la izvor spre colector. Parametrii microbiologici sunt influențați puternic de prezența materiilor fecale provenite atât de la animale (sălbatice și domestice), precum și de la gospodăriile populației, neracordate la un sistem centralizat de canalizare, folosindu-se de fose septice, în multe cazuri improprii. Încărcătura microbiană mare se datorează și sistemului extensiv (ecologic) de creștere a animalelor, care au acces liber la pâraie si izvoare. La cele deja menționate se mai adaugă și exploatările forestiere care, în majoritatea cazurilor afectează cursul apelor prin trecere cu utilaje grele și material lemnos prin cursurile de apă.

MULȚUMIRI

Realizarea studiului a fost susținută de colegii din cadrul laboratorului de microbiologie al societății Carpathian Springs, în cadrul căreia s-au realizat toate analizele.

REFERINȚE BIBLIOGRAFICE

Antonescu C.S., *Biologia apelor*, 1963, 18-26, 232-277
Ardeleanu I, *Microbiologie generala,vol.1* 2013, 13
Ardeleanu I, *Microbiologie generala,vol.I1* 2013, 246
Bărzoi D., Apostu S., *Microbiologia produselor alimentare*, 2002, 547 **Carte tehnică** aparat AlgaeLabAnalyser BBE Moldaenke
Ionescu Al., *Lumea algelor*, 1972, 9, 27
Dinache Gh. Radu V., Panaitescu D., Brezeanu Al., *Microbiologie și parazitologie,* 1978, 42

REFERENCES

Duca Eugenia, Duca M., Furtunescu G., *Microbiologie medicală,* 1979, 460, 485
Dunca Simona, Nimițan Erica, Ailiesei Octăvița, Ștefan M., *Microbiologie aplicată,* 2004, 223
I.N.C.D.D.D. Tulcea - revista *Probleme de Ecologie Teoretică și Aplicată în România - Direcții Actuale,* nr. 13 - *Tehnici de monitoring și evaluare a înfloririlor algale,* 3-4
Ivanov A., Ciupe M., Sașcă C., Vancea Doina, *Microbilogie*, 1982, 169, 191,
Mănescu S., *Microbiologie sanitară,* 1989, 153 - 136
Mohan Gh., Ardelean A., *Ecologia şi protecţia mediului*, 1993, 93 - 95
Peterfi St., Ionescu Al., *Tratat de algologie,* volumul 1, 1976, 375 - 376
Peterfi St., Ionescu, Al., *Tratat de algologie,* volumul 2, 1979, 254 - 260
Peterfi St., Ionescu, Al., *Tratat de algologie,* volumul 3, 1979, 152 - 153
Peterfi St., Ionescu Al., *Tratat de algologie,* volumul 4, 1981, 13 - 47, 239 - 246, 261 - 279, 357 - 359
Popa M.I., *Microbiologie generală și microbiologie specială,* note de curs, 1999, 155, 179,
Șchiopu E. B., *Algologie*, 2008, 7- 8
Topală N.D., *Microbiologie generală,* vol. I și II, 1978, 276, 341
Zarma M., *Microbiologie generală,* 1964, 123
Zarnea G., Popescu O.V., *Dicţionar de microbiologie generală şi biologie moleculară,* 2011, 296 - 297, 306 - 307, 424 - 425, 438 - 439, 959
Zarnea G., *Microbiologie generală,* 1970, 241, 435
Zarnea G., *Microbiologie*, 1963, 15, 33
Zarnea G., *Tratat de microbiologie generală, vol II,* 1984, 325
Zarnea G., *Tratat de microbiologie generală, vol IV,* 1994, 681

MONITORIZAREA UNOR PARAMETRI FIZICO-CHIMICI PENTRU APELE DE SUPRAFAȚĂ ALE UNOR EMISARI DIN BAZINUL DORNELOR

Ionela VOLOȘENIUC, Liviu MIRON[1]

ionela.voloseniuc@valvis-holding.com

Abstract

The objective of this study was to establish the quality of surface water from streams that cross the Dorna's Basin, following some defining physico-chemical indicators. In order to conduct this study, 10 sampling stations were established over four streams, the study taking place for two years, 2017 and 2018, between the months of May and October. The samples were analyzed in the laboratory using specific methods for each indicator monitored - temperature, pH, oxidizable substances, conductivity, dissolved oxygen, alkalinity, hardness, anions and cations. The results obtained varied depending on the sampling site, weather phenomena, as well as the geological structure of the mountain ranges from which the streams -that were under study- spring. The conclusions of this study demonstrate that the targeted streams have physico-chemical properties that are close to the standards imposed for natural mineral waters, the main geological resource for the Dorna's Basin, discovered and used for over 300 years. Thus, the anthropic activity represented mainly by animal husbandry, mostly in an extensive-ecological system, does not have a negative effect on the quality of watercourses in the area.

Key words: calitate ape de suprafață, parametri fizico-chimici, bazinul Dornelor

Studiul de față propune o analiză comparativă a principalilor indicatori fizico-chimici pe fiecare emisar urmărit, în parte: pârâul Secu, pârâul Arinu, pârâul Călimănel și pârâul Bancu) cu probe prelevate din stațiile stabilite, atât în amonte comunităților umane (aproape de izvorul primar), precum și în zona de confluență cu colectorii din aval (râul Dorna, râul Bistrița, râul Neagra și râul Teșna), având ca scop aprecierea calității unor cursuri de apă din bazinul Dornelor.

MATERIAL ȘI METODĂ

Au fost vizați 9 indicatori, astfel:

1. Măsurarea temperaturii apei s-a efectuat cu ajutorul unui termometru cu mercur sau alcool, precum și cu termometul electronic. Rezultatele au fost exprimate în grade Celsius (°C).
2. Determinarea pH-ului apei s-a efectuat cu ajutorul unor echipamente multiparametru : InoLab - Multi 720 și pH - metru WTW 330. Exprimarea rezultatelor s-a realizat în unităţi de pH.
3. Determinarea substanțelor organice oxidabile (CCO) s-a realizat prin titrare, în prezența unui oxidant puternic, $KMnO_4$. Cantitatea de oxigen echivalentă cu consumul de oxidant se mai numește și oxidabilitate. Rezultatele se exprimă în mg/l (ppm).
4. Determinarea conductivităţii electrice s-a realizat cu ajutorul unor echipamente multifuncționale: InoLab - Multi 720 și Multi 9310P. Rezultatele au fost exprimate în micro - siemens pe centimetru cub ($\mu S/cm^3$).
5. Determinarea oxigenului dizolvat s-a realizat cu ajutorul unor echipamente multifuncționale: InoLab – Multi 720 și Multi 9310P. Exprimarea rezultatelor s-a realizat în mg/l (ppm).
6. Determinarea alcalinității exprimată în hidrogen carbonat (bicarbonic) s-a realizat prin titrare cu metilorange. Exprimarea rezultatelor se face în mg/l (ppm).
7. Determinarea durității apei s-a realizat prin titrare. Duritatea se exprima în grade de duritate (°d), 1 grad de duritate corespunde la 10 mg CaO/l.
8. Determinarea anionilor dizolvați în apă (bromură, clorură, fluorură, azotat, azotit, fosfat şi sulfat) s-a realizat prin metoda ioncromatografică, folosind un echipament ioncromatograf Metrohm. Exprimarea rezultatelor se face în mg/l (ppm).
9. Determinarea cationilor dizolvați în apă (litiu, sodiu, amoniu, potasiu, calciu şi magneziu) s-a realizat prin metoda ioncromatografică, folosind un echipament ioncromatograf Metrohm. Exprimarea rezultatelor se face în mg/l (ppm).

REZULTATE ȘI DISCUȚII

În cadrul studiului, media **temperaturilor** măsurate a fost de 12,08°C, cu maxima înregistrată în 2017, iar minima în 2018. Au fost observate variații mici de temperatură între aceleași luni din cei doi ani de studiu, maxima fiind de 19,7°C pentru luna august 2017. Deasemnea, s-a observat că cele mai mari temperaturi înregistrate au fost cele din august și cele mai scăzute au fost cele din octombrie, atât în anul 2017, cât și în anul 2018. Temperaturile măsurate în anul 2017 au fost cuprinse între 5,8°C (la proba prelevată în data de 27 octombrie de la stația Călimănel-sus, pârâu) și 19,7°C (la proba prelevată în data de 17 august de la stația Bancu-

jos), cu o medie de 12,14°C. Temperaturile măsurate în anul 2018 au fost cuprinse între 2,3°C (la proba prelevată în data de 5 octombrie de la stația Călimănel-jos, în Panaci) și 17,9°C (la proba prelevată tot în data de 17 august de la stația Bancu-sus), cu o medie de 12,03°C. Valorile temperaturilor înregistrate în 2018 au fost mai mici față de anul anterior, deoarece și media temperaturilor atmosferice a fost mai scăzută. De asemenea în al doilea an de studiu volumul de precipitații a fost mult mai mare decât în anul 2017.

În cadrul studiului, media valorilor măsurate pentru **parametrul pH** a fost de 7,82 unități pH, cu valoarea maximă înregistrată în iulie 2018 și minima înregistrată în septrembrie 2017.Valorile pH-ului măsurate în anul 2017 au fost cuprinse între 6,77 unități pH (la proba prelevata în data de 22 septembrie de la stația Călimănel-jos, în Panaci) și 8,3 unități pH (la proba prelevată în data de 26 octombrie de la stația Secu-sus), cu o medie de 7,86 unități pH. Valorile pH-ului măsurate în anul 2018 au fost cuprinse între 7,18 unități pH (la proba prelevată în data de 17 august de la stația Călimănel-jos, în Panaci) și 8,71 unități pH (la proba prelevată tot în data de 20 iulie de la stația Bancu-jos), cu o medie de 7,79 unități pH. Valorile pH-ului înregistrate în 2018 au fost nesemnificativ mai mici față de anul anterior analizat în studiu De notat este faptul că pe parcursul studiului valorile pH-ului au fost mai mici la stațiile de prelevare de pe cursul pârâului Călimănel, mai ales în punctul cel mai din aval, cu o medie de 7,43 unități de pH pentru cei doi ani de cercetare. De asemenea, valorile cele mai mari ale pH-ului au fost înregistrate în apele pârâului Secu, la stația din amonte, cu o medie de 8,07 unități pH**.**

În cadrul studiului, pentru **substanțele organice oxidabile** , media valorilor obținute a fost de 19,96 mg/l $KMnO_4$, cu valoarea maximă înregistrată în august 2018 și minima înregistrată în august 2017. De notat este faptul că în august 2018, cu câteva ore înainte de prelevarea probelor, în zona pârâului Arinu a fost o furtună puternică, rezultatele analizelor fiind vizibil influențate de acest fenomen, valorile obținute fiind de peste 50 ori mai ridicate decât media celorlate valori obținute, motiv pentru care nu au fost luate în calcul.

Eliminând această lună din calcul, media celor 2 ani este foarte apropiată, 10,15 mg/l $KMnO_4$ în 2017 și 10,08 mg/l $KMnO_4$ în 2018, cu o medie generală de 10,11 mg/l $KMnO_4$. Pentru anul 2017, rezultatele obținute se încadrează între 1,89 mg/l $KMnO_4$, valoare înregistrată pe 18 august 2017 la proba prelevată de la stația Călimănel-sus (pârâu) și 21,04 mg/l $KMnO_4$, valoare obținită la probă prelevată de la stația Bancu-jos în data de 21 septembrie 2017. Valoarea minimă este corelată cu o încărcătură microbiologică redusă și cu absența paraziților, precum și cu o masă algală deloc abundentă, în timp ce valoarea maximă este asociată cu o încărcătură bacteriană și o masă algală semnificativă, și o încărcare parazitară de un chist de *Giardia* și un oochist *de Cryptosporidium* la 15 litri de apă filtrată. Pentru anul 2018, rezultatele obținute se încadrează între 4,74 mg/l $KMnO_4$, valoare înregistrată pe data de 04 mai 2018 la proba prelevată de la stația Călimănel-sus (fermă) și 618 mg/l $KMnO_4$, valoare obținută la proba prelevată de la stația Arinu-jos în data de 17 august 2018. Având în vedere că pentru acest parametru chimic rezultatele din data de 17 august 2018 pentru probele prelevate de la pârâul Arinu au fost influențate de fenomenele meteorologice din ziua respectivă, notăm ca și valoare maximă reprezentativă rezultatul de 29,07 mg/l $KMnO_4$, obținut la stația Bancu-jos pentru proba prelevată în data de 08 iunie 2018. Valoarea minimă este corelată cu o încărcătură microbiologică redusă și cu absența paraziților, precum și cu o masă algală deloc abundentă. Valoarea maximă obținută la stația Bancu-jos pentru proba prelevată în data de 08 iunie 2018 este asociată cu o încărcătură bacterină și o masă algală semnificativă, desi prezența paraziților nu a fost evidențiată. Probele prelvate din cele două stații Arinu în data de 17 august 2018 și care au avut valori exagerat de ridicate pentru substațele organice oxidabile au prezentat de asemnea încărcătură microbiologică și algală, precum și un chist de *Giardia/*5 litri de apă filtrată pentru analiza parazitară. Privind tabloul de ansamblu al tuturor analizelor pentru parametrul substanțe organice oxidabile, se observă că în general stațiile din amonte au valori mai mici decât cele din aval, fiind dovada influenței comunităților umane în toate zonele.

În cadrul studiului, media valorilor obținute pentru **conductivitate** a fost de 200,95 µS/cm^3, cu valoarea maximă înregistrată în octombrie 2017 și minima înregistrată în mai 2017. Pentru anul 2017, rezultatele obținute se încadrează între 74,295 µS/cm^3, valoare înregistrată pe 27 mai 2017 la proba prelevată de la stația Călimănel-sus (pârâu) și 354 µS/cm^3, valoarea conductivității pentru proba prelevată de la stația Secu-jos în data de 26 octombrie 2017. Pentru anul 2018, rezultatele obținute se încadrează între 75,5 µS/cm^3, valoare înregistrată pe 19 iulie 2018 la proba prelevată de la stația Călimănel-sus (pârâu) și 353 µS/cm^3, valoare pentru proba prelevată de la stația Secu-jos în data de 21 octombrie 2018. Valoarea minimă este corelată cu o duritate scăzută și cu o valoare mică a alcalinității exprimată în hidrogen carbonat (bicarbonat), toate indicând că pârâul Călimănel-sus este o apă cu mineralizare scăzută. De

asemenea, valoarea maximă este corelată cu o duritate crescută și cu o valoare mare a alcalinității exprimată în hidrogen carbonat (bicarbonat), toate indicând că pârâul Secu-sus este o apă cu mineralizare mare. Valorile înregistrate în timpul celor doi ani de studiu au fost apropiate în cazul tutoror stațiilor de prelevare.

În cadrul studiului, media valorilor obținute pentru **oxigenul dizolvat** a fost de 8,97 mg/l, cu valoarea maximă înregistrată în octombrie 2017 și minima înregistrată în august 2018. Pentru anul 2017, rezultatele obținute se încadrează între 7,96 mg/l, valoare înregistrată pe 30 iunie 2017 la proba prelevată de la stația Călimănel-sus (pârâu) și 10,85 mg/l. Pentru anul 2018, rezultatele obținute se încadrează între 7,66 mg/l, valoare înregistrată pe 17 august 2018 la proba prelevată de la stația Arinu-jos și 10,59 mg/l, valoare obținută la proba prelevată de la stația Călimănel-jos (în Panaci) în data de 4 mai 2018. În urma comparației rezultatelor obținute pentru fiecare pârâu luat în studiu, valorile înregistrate pentru oxigenul dizovat au valori apropiate între cei doi ani de studiu. Cea mai mică diferență pentru valorile obținute s-a obsevat la pârâul Bancu iar cea mai mare la pârâul Secu.

În cadrul studiului, media valorilor obținute pentru **oxigenul dizolvat** a fost de 131,24 mg/l, cu valoarea maximă înregistrată în august 2018 și minima înregistrată în iulie 2018. Pentru anul 2017, rezultatele obținute se încadrează între 48,88 mg/l, valoare înregistrată pe 28 iulie 2017 la proba prelevată de la stația Călimănel-sus (pârâu) și 231,8 mg/l, valoare obținută la proba prelevată de la stația Secu-jos în data de 26 octombrie 2017. Pentru anul 2018, rezultatele obținute se încadrează între 42,7 mg/l, valoare înregistrată pe 8 iunie 2018 la proba prelevată de la stația Călimănel- sus (pârâu) și 244 mg/l, valoare obținită la probă prelevată de la stația Secu-jos în data de 21 septembrie 2018. Valorile înregistrate pentru hidrogenul carbonat, de asemena au valori apropiate între cei doi ani de studiu, facând comparatia pe fiecare pârâu luat în observație. Cea mai mare diferență între media valorilor înregistrate de-a lungul celor doi ani de studiu pentru parametrul hidrogen carbonat a fost înregistrată la pârâul Arinu, indicând faptul ca a scăzut cantitatea sărurilor dizolvate în al doilea an de monitorizare, aspect susținut și de o duritate medie mai scăzută pentru acest pârâu. Pentru celelalte pârâuri, valorile au fost apropiate, cea mai mică diferență înregistrându-se la pârâul Călimănel.

În cadrul studiului, probele au fost analizate în perioada mai - octombrie din 2017 și 2018, media valorilor obținute pentru **duritate** fiind de 6,1 grade duritate, cu valoarea maximă înregistrată în septembrie 2017 și minima înregistrată în iunie 2018. Pentru anul 2017, rezultatele obținute se încadrează între 2,24 grade duritate, valoare înregistrată pe 28 iulie 2017 la proba prelevată de la stația Călimănel-sus (pârâu) și 11,79 grade duritate, valoarea probei prelevate de la stația Arinu-sus în data de 21 septembrie 2017, cu o medie de 6,44 grade duritate. Pentru anul 2018, rezultatele obținute se încadrează între 1,34 grade duritate, valoare înregistrată pe 6 iunie 2018 la proba prelevată de la stația Călimănel-sus (pârâu) și 11,23 grade duritate, valoare obținită la probă prelevată de la stația Secu-jos în data de 5 octombrie 2018. Analizând rezultatele obținute pentru duritatea apei comparativ pentru cei doi ani de studiu, s-a observat că valorile obținute pentru fiecare pârâu analizat sunt apropiate și nu există diferențe majore.

Pentru **ANIONII FLUORURI**, valorile determinate au fost cuprinse între 0,003 mg /l și 0,079 mg/l, cu o medie de 0,033 mg/l, cu cele mai mici valori înregistrate constant la stațiile de pe cursul pârâului Secu. Pe restul cursurilor, au fost fluctuații de la o lună la alta, pe toată perioada celor doi ani de studiu.

Pentru **ANIONII CLORURI**, valorile determinate au fost cuprinse între 0,42 mg/l și 3,66 mg/l, cu o medie de 1,136 mg/l, cu cele mai mari valori înregistrate constant la stațiile din aval, de pe cursul pârâului Călimănel, în timp ce la stațiile din amonte au fost cele mai mici valori. Pe restul cursurilor, nu au fost fluctuații semnificative în cei doi ani de studiu.

Pentru **ANIONII BROMURI**, au fost determinate valori doar în luna august 2017 la stația Bancu-jos – 0,005 mg/l și în luna octombrie 2018 la stația Secu-jos – 0,036 mg/l, pentru restul probelor valorile fiind sub limita de detecție a aparatului.

Pentru **ANIONII NITRIȚI**, valorile determinate au fost cuprinse între 0 mg/l (de fapt sub limita de detecție a aparatului) și 0,08 mg/l, cu o medie de 0,013 mg/l, cea mai mare valoare înregistrată la fiind la stația Călimănel-jos (în Panaci), în timp ce la stația Călimănel-sus (pârâu) au fost înregistrate cele mai mici valori. Pe restul cursurilor, au fost fluctuații semnificative pentru cei doi ani de studiu.

Pentru **ANIONII NITRAȚI**, valorile determinate au fost cuprinse între 0,34 mg/l și 2,98 mg/l, cu o medie de 1,52 mg/l, cea mai mare valoare fiind înregistrată la stația Secu-sus, în timp ce la stațiile din amonte ale pârâului Călimănel au fost cele mai mici valori. Pe restul cursurilor, au fost fluctuații semnificative pentru cei doi ani de studiu.

Pentru **ANIONII SULFAȚI**, valorile determinate au fost cuprinse între 6,23 mg/l și 16,23 mg/l, cu o medie de 9,94 mg/l, cele mai mari valori înregistrându-se la stațiile din amonte ale pârâului Călimănel iar cele mai mici valori fiind înregistrate la stația Arinu-jos. Pe restul cursurilor, nu au fost fluctuații semnificative pentru cei doi ani de studiu.

Pentru **ANIONII FOSFAȚI**, nu au fost înregistrate valori pe parcursul studiului la nici una din probele prelevate din cele 10 stații, toate fiind sub limita de detecție a aparatului.

Pentru **CATIONII de AMONIU**, au fost determinate valori peste limita de detecție a aparatului doar în 2018, la stațiile Arinu-jos în lunile iunie – 0,057 mg/l și iulie – 0,053 mg/l si la stațiile de la pârâul Bancu în luna iunie: în aval – 0,057 mg / l și în amonte – 0,049 mg / l. În restul probelor valorile pentru acești cationi au fost sub limita de detecție a aparatului.

Pentru **CATIONII de LITIU**, nu au fost înregistrate valori pe parcursul stiudiul la nici una din probele prelevate din cele 10 stații, toate fiind sub limita de detecție a aparatului.

Pentru **CATIONII de SODIU**, valorile determinate au fost cuprinse între 1,27 mg/l si 4,54 mg/l, cu o medie de 2,35 mg/l, cu cele mai mari valoari înregistrate la stațiele din aval ale pârâului Călimănel, în timp ce la stația Arinu-sus au fost cele mai mici valori. Pe restul cursurilor, au fost fluctuații semnificative în cei doi ani de studiu.

Pentru **CATIONII de POTASIU**, valorile determinate au fost cuprinse între 0 mg/l (de fapt sub limita de detecție a aparatului) și 2,37 mg/l, cu o medie de 0,97 mg/l, cu cele mai mari valoari înregistrate la stația Călimănel-jos (în Panaci), în timp ce la Călimănel-sus (pârâu) sus au fost cele mai mici valori. Pe restul cursurilor, au fost fluctuații semnificative în cei doi ani de studiu.

Pentru **CATIONII de CALCIU**, valorile determinate au fost cuprinse între 2,58 mg/l și 58,62 mg/l, cu o medie de 23,86 mg/l, cu cele mai mari valoari înregistrate la stațiile de pe pârâul Secu, în timp ce la Călimănel-sus (pârâu) au fost cele mai mici valori. Pe restul cursurilor, au fost fluctuații în cei doi ani de studiu.

Pentru **CATIONII de MAGNEZIU**, valorile determinate au fost cuprinse între 1,53 mg/l și 10,57 mg/l, cu o medie de 4,7 mg/l, cu cele mai mari valoari înregistrate la stația Arinu-sus, în timp ce la stațiile de pe pârâul Secu, în mod special cea din amonte, au fost cele mai mici valori. Pe restul cursurilor, au fost fluctuații în cei doi ani de studiu.

CONCLUZII

Principala concluzie a studiului este faptul că emisarii urmăriți au proprietăți fizico-chimice care se apropie de standardele impuse pentru apele minerale naturale, resursă geologică principală pentru bazinul Dornelor, descoperită și utilizată de peste 300 de ani. Activitatea antropică reprezentată în principal de creșterea animalelor, în mare parte în sistem extensiv (ecologic) pare a nu avea un efect negativ asupra calității cursurilor de apă din zonă. Anumiți parametri au avut o evoluție în funcție de sezon, de debit, de fenomene meteorologice extreme (ploi torențiale cu cantități semnificative de apă), de locul de prelevare, adică în amonte sau în aval comunităților umane și nu în ultimul rând de structura geologică a masivelor muntoase din care izvorăsc pâraiele luate în studiu.

MULȚUMIRI

Realizarea studiului a fost susținută de colegii din cadrul laboratorului de analize fizoco-chimice al societății Carpathian Springs, în cadrul căreia s-au realizat toate analizele.

REFERINȚE BIBLIOGRAFICE

Antonescu C.S., *Biologia apelor*, 1963, 31-34

C. Pătroescu, I. Gănescu 1980 - *Analiza apelor*, 26-28, 154-156, 241-242

Tudor D. Ionescu, Șerban Constaninescu, Georgel Marcoci, Maria Moțoc, Ion Petre 1968 - *Analiza apelor*, p 15-24, 101-105, 276-278

Surugiu Victor 2008 - *Limnologie și saprobiologie*, 36-39, 115-119

https://lege5.ro/Gratuit/gmydqmzqgaza/legea-nr-243-2018-privind-aprobarea-ordonantei-de-urgenta-a-guvernului-nr-78-2017-pentru-modificarea-si-completarea-legii-apelor-nr-107-1996

Administrația Națională "Apele Române" - Administrația Bazinală de Apă Siret Bacău - Punct de lucru stabil Vatra Dornei, Monitorizare debite Vatra Dornei

THE ROLE OF BACTERIAL INFECTIONS IN THE DEVELOPMENT OF RESPIRATORY DISEASES IN SWINE

Jovan BOJKOVSKI [8], Ivan PAVLOVIĆ[2], Ivan VUJANAC[1], Sveta ARSIĆ[1], Sreten NEDIĆ[1], Dragoş Constantin ANIŢĂ[3], Luanda OSLBANU[3], Adriana Elena ANITA[3], Nemanja ZDRAVKOVIĆ[2], Oliver RADANOVIĆ[2], Jasna PRODANOV - RADLOVIĆ[4], Petar KARAĆ[1], Radiša PRODANOVIĆ[1]

email bojkovski@vet.bg.ac.rs

Abstract

Respiratory disease of bacterial etiology is a serious health problem on commercial farms.Pig production on commercial farms means keeping a large number of pigs in a relatively small space with a high level of technological organization of the production process. Intensive utilization of accommodation capacities, early weaning of piglets, inadequate microclimatic conditions for most of the statised categories and deficits in nutrition have conditioned the appearance of production or technological diseases. Production diseases of bacterial etiology are presented in this review paper. Diseases of bacterial etiology that occur at all stages of technological production are: atrophic rhinitis, enzootic swine pneumonia, pneumonia caused by pasteurellosis, bordetella, pneumonia caused by A. pleuropneumoniae, pneumonia caused by Haemophilus parasuis and pneumonia caused by Streptococcus. We have described the possibility of prophylaxis of these production diseases of bacterial etiology and the possibility of their control. These manufactured diseases cause economic losses (deaths, reduced daily gain, extended fattening time and treatment costs.

Key words: bacterfial infectoons, respiratory disease swine,

INTRODUCTION

Among the most important bacterial pathogens, causative agents or synergists in the development of the most common respiratory diseases of pigs include Mycoplasma hyopneumoniae, Actynobacillus pleuropneumoniae, Bordatella bronchiseptica, Pasteurella multocida, Haemophilus parasuis and Streptococcus suis. Mycoplasma hyopneumoniae (Ivetić et.al.2000) is cited as the primary cause of enzootic swine pneumonia. The combined action of Bordatella bronchioseptica and Pasteurella multocida leads to the development of atrophic rhinitis. Other bacterial pathogens, alone or in interaction with others, lead to various forms of bronchopneumonia. (Lončarević A., 1997, 1998; Šamanc H., 2009; Lipej Z., 2015). Bacteria, vors, parses and fungi play a primary role in the development of diseased respiratory organs. Diseases of the respiratory tract can rarely be caused by a single cause (monoinfection). They are often mixed infections (polyinfections or superinfections). There is a possibility that mycoplasma, bordetella, paterela, and different strains of H. pleuropneumoniae dominate (Šamanc H., 2009; Bojkovski J. *et al*, 2013, 2018).

Atrophoc rhinitis

Atrophic rhinitis is a disease of the upper respiratory tract. Dystrophic changes in the upper jaw bones and frequent bleeding of the upper teeth, food intake is very difficult and reduced. Diseased animals show smaller growth and significant lag in fattening (Lončarević A., 1998). The etiopathogenesis of atrophic rhinitis is complex and includes a number of pathogens, including Bordatella bronchiseptica, Pasteurella multocida, Haemophylus parasuis, and porcine cytomegalovirus. Genetic factors, environmental influences and nutritional deficiencies are also predisposing. Bordatella bronchiseptica is thought to cause moderate turbinate atrophy and promote active colonization of the nasal mucosa by Pasteurella multocida bacteria. Toxogenic strains of pastel (types A and D) produce cytotoxins that inhibit osteoblast activity and stimulate osteoclast

[8] Faculty of Veterinary Medicine, University of Belgrade, Belgrade, Serbia,
[2]Scientific Veterinary Institute Serbia, Belgrade, Serbia,
[3]Faculty of Veterinary Medicine, I.U.L.S, Iași, Romania,
[4]Scientific veterinary institute Novi Sad, Novi Sad, Serbia

activity and remodeling in the nasal bones, resulting in conch atrophy (Lončarević A. *et al*, 1998; Shamanc H., 2009). In infected pigs, Bordatella bronchiseptica and Pasteurella multocida (serotypes A and D) produce much stronger local reactions than in individual infections caused by one of these two pathogens. The main characteristic of infection with these pathogens is very long germination (Lončarević, 1997; 1998). Sows pose a latent danger to their offspring. Infection occurs aerogenically, by vertical transmission, from suckling sows to piglets during and after farrowing or during the lactation period (Lončarević A., 1998). In the category of weaned piglets, the infection is spread by contact from infected animals to animals from uninfected litters (horizontal transmission). Piglets are considered to be the most susceptible until the age of 6 to 8 weeks. However, infection can occur after this period, but very rarely. In infected animals, characteristic morphological changes occur with atrophy of the nasal shells and deformation of the snout (Lončarević A., 1998; Šamanc H., 2009; Lipej Z., 2015). The initial symptoms of the disease are observed in piglets aged 8 to 10 days, ie at the latest at the end of the suckling period. Atrophic rhinitis occurs in subclinical or clinical form, is chronic and almost never causes direct death. In the early phase, atrophic rhinitis is clinically characterized by sneezing, coughing, nasal discharge and drying of lacrimal secretion under the medial corner of the eye (Lipej Z., 2015). With the appearance of morphological changes, in the form of deviations of different degree, we talk about atrophic rhinitis as a clinical phenomenon. The changes can be pronounced only on one side or are bilateral with a shortening of the upper jaw and a very curved line and folds on the skin of the dorsum of the snout. In severe cases, the tooth is to blame. During all phases of the disease, the animals are afebrile and do not show health disorders. In the beginning, pigs take the necessary amounts of food, but later, due to the deformity of the teeth, they find it harder to take food and slowly lag behind in growth (Lončarević A., 1998; Lipej Z., 2015). Localization of morphological changes is prevenstvewno on the mucous membrane of the nasal cavity, then on the nasal shells and bones of the upper jaw. Due to the deformation or complete disappearance of the nasal septum, there is a clear asymmetry of the nasal cavities, as well as deformation of the upper jaw bones. The nasal bones are most often affected by the inflammatory process. In the initial stage of the disease, there is a partial atrophy of one or both nasal shells, while in the last phase of the disease there is often their complete atrophy (Shamanc H., 2009; Lipej Z., 2015). The key microscopic lesion in atrophic rhinitis is a decrease in the bone density of the nasal conchas. In the later stage of the disease, the swelling of the connective tissue is also expressed, especially around the blood vessels whose lumen is narrowed, and very often obliterated (Lončarević A., 1998). The basic measure of prevention is to prevent the introduction of the pathogen into healthy areas. However, if the causative agent is "introduced" into the plant, more extensive measures should be taken so that the infection does not spread in the plant. It is necessary to correct the microclimatic conditions and reduce the population density in the facilities. Ventilation, *i.e.* appropriate ventilation, should ensure that the animals breathe clean air without dust and harmful gases. Detection of carriers among sows, and their exclusion from the herd are an important measure of prophylaxis (Lončarvić A., 1998).

Swine enzootic pneumonia

Mycoplasmas cause a mild infection, but thanks to their very pronounced immunomodulatory properties, they can greatly reduce the ability of the respiratory system to defend itself against other microorganisms. They are widely distributed in pig herds and are the primary cause of respiratory diseases. About 90% of the examined diseases are endangered by mycoplasmal infection of the respiratory tract, and in 70% to 75% of cases Mycoplasma hyopneumoniae is the cause of pneumonic lesions (Ivetić V., *et al*, 2000; 2005). Enzootic pneumonia spreads as a droplet infection or directly, by contact through a discharge from the respiratory organs. In swine fever, the disease is maintained by transmitting the pathogen from sows to piglets. It is enough to infect only a few piglets, so that the disease then spreads from litter to litter, ie to affect almost all piglets at the time of regrouping and transfer to kennels. Mixing of new piglets with piglets left in the kennel contributes to the maintenance of the infection (Ivetić V., 2005). Infection occurs very early without clinical symptoms. Only in rare cases, Mycoplasmae hyopneumoniae can cause pneumonic changes in suckling piglets (Ivetić V., *et al*, 2005). The disease is characterized by a long incubation period, because the causative agent multiplies slowly in epithelial cells, then high morbidity, low mortality and chronic unproductive cough (Shamanc H., 2009). By adhering to the ciliated epithelium, mycoplasmas resist phagocytic activity they are closely connected with the cell membrane, they are also protected from the body's immune defenses (Lončarević A., 1997,). By reducing the function of the mucociliary apparatus, M. hyopneumoniae significantly contributes to the development of

secondary bacterial infections (Zimmereman J.J. *et al*, 2012). Numerous studies have shown that mycoplasmas stimulate the division of lymphocytes, *i.e.* to have a non-specific stimulatory (mitogenic) effect on lymphocytes and to stimulate their mass accumulation peribronchially and perivascularly (Savić B. *et.al* 2009). The inflammatory reaction, accompanied by increased production of proinflammatory cytokines, plays a significant role in the development of mycoplasmal pneumonias. The inflammatory response is significant in the control of respiratory pathogens, tissue damage is more likely to be caused by the host itself than by the microorganism (Ivetić V. *et al* 2007). It has also been shown that pulmonary alveolar macrophages infected at the same time with M. hyopneumoniae and A. pleuropneumoniae have significantly reduced phagocytic abilities (Šamanc H., 2009). Based on the observed clinical symptoms, two forms of the disease can be distinguished, bronchitis and bronchopneumonia. In bronchitis, an unproductive cough occasionally occurs, body temperature is within normal physiological limits, and the frequency of breathing is somewhat accelerated. In animals with pneumonic changes in the lungs, in addition to coughing, loss of appetite and decreased physical condition, body temperature, pulse and respiration may be altered. Auscultation can hear dry and wet rohni, bronchial breathing and two-phase inspiration, as a consequence of narrowing or closing of the bronchial lumen (Shamanc H., 2009). Morphological changes are mostly found on the ventral parts of the apical and cardiac lobes of the lungs, although to a lesser extent, the anterior parts of the diaphragmatic lobes can also be affected. The altered parts of the lungs form dark red to gray-colored consolidated fields. The most prominent change in the area of the altered lung tissue is atelectasis in the form of indented parts in relation to the normal lung tissue. In cross-section, the altered parts of the lungs have a fleshy but not hard consistency. There is always a large amount of catarrhal exudate in the lumen of the tubular respiratory organs. Bronchial and mediastinal lymph nodes are often changed and enlarged (Ivetić V. *et al*, 2000, 2005). Early microscopic lesions are characterized by the accumulation of neutrophilic granulocytes in the lumen and around the airways, as well as in the alveoli. Many cases of mycoplasmal pneumonia are combined infections. The most common combinations of pathogens in the complex of respiratory diseases of pigs are precisely M. hyopneumoniae with the PRRS virus and the bacterium P. multocida. The essence of all prophylactic programs so far, includes a system of keeping and treatment in which, as much as possible, it is impossible to maintain the causative agent in pigs, as well as its transmission to the youngest categories (Bojkovski J. *et al* 2015).

Pasteurella-induced pneumonia

Pasteurellosis occurs in peracute, acute and chronic forms. Clinical symptoms are conditioned by the intensity of morphological changes in the lungs, ie the activation of existing, smaller foci into acute bronchopneumonia. At the beginning of the disease, the cough is dry and unproductive, and soon, due to the exudation and accumulation of a large amount of contents, the cough becomes moist. During the disease, the body temperature is elevated, and in the peracute form of the disease it reaches a value of 42 ° C. Sick animals are apathetic and do not eat. Due to the difficult health condition and exhaustion, the animals lie down. The course of the disease lasts 5 to 10 days and ends with the death of the animals, if they are not treated. Only in a small number of cases, the disease takes a chronic course and lasts between 3 and 5 weeks. The acute septicemic form of swine pasteurellosis (hemorrhagic septicemia) is caused by P. multocida serotype B. After a short incubation, the disease begins suddenly, with severe clinical symptoms. In addition to high body temperature and very difficult breathing, the work of the cardiovascular system soon weakens. The first symptoms of dysfunction of this system are initially uneven redness of the skin, swelling of the pharyngeal region, and then, diffuse redness of the skin and cyanosis of the tip of the snout, ears, distal parts of the extremities and abdomen. Death occurs within hours. Very rarely, the disease can last for one or more days (Shamanc H., 2009). Pathomorphological changes caused by pasteurellosis are characterized by catarrhal-fibrinous bronchopneumonia, which is accompanied by well-limited red to gray consolidated areas of the lungs, with a predominantly cranio-ventral distribution (Ivetić V. *et al*, 2007). they are also characteristic of pig pasteurellosis. There is a smaller or larger amount of red fluid in the pleural cavity. In the peracute-septicemic form, numerous spot bleeding by serosa can be observed (Ivetić V. *et al*, 2007) The microscopic finding is characterized by lobular purulent bronchopneumonia (Ivetić V., 2007). Accumulation of fibrin masses and accumulation of neutrophilic granulocytes in the lumen of the alveoli, bronchioles and bronchi are observed. In addition to visible damage to the epithelium in the lumen of the alveoli, bronchioles and bronchi, significant amounts of fibrin can be found, which with accumulated cellular elements causes

obstruction of the respiratory tract, bronchitis obliterans, (Shamanc H., 2009).

Pneumonia casused by *Bordella*

Bordatella bronchiseptica is a gram-negative bacterium closely related to the species Bordatella pertussis, but, unlike it, it does not produce pertussis toxin. In the upper parts of the respiratory tract, B. bronchiseptica causes inflammatory changes in the mucosa, with loss of cilia and atrophy of the turbines. Also, this bacterium leads to primary pneumonia in newborn piglets and secondary pneumonia in older categories of pigs (Shamanc H., 2009). Virulence, as well as contagiousness are not so high and therefore do not cause acute diseases, but the disease is mainly in a chronic form. In addition to frequent coughing, sero-mucous and mucopurulent nasal discharge is also observed. The animals take smaller amounts of food and gradually lose their condition. During the disease, body temperature is in normal physiological values. Although cases of the disease have been reported in very young piglets, the disease most often occurs in nazimads at the time of fattening, when other pathogens from the complex of respiratory diseases of pigs can be found (Bojkovski J. *et al,* 2010). In dead pigs, lobular pneumonia or larger pneumonic foci that are localized in the cranial lobes of the lungs can be observed, although in rare cases they can also be localized in the caudal parts of the lungs. In primary pneumonia, changes in the lungs reach a maximum between 10 and 14 days after infection, when red areas of consolidation are observed in the lungs. After that, around the 21st day after infection, these areas become yellow-brown and contracted (Donald M. *et al,* 2008). In the lumen of the bronchi of the affected parts of the lungs, there is an abundant mucous-purulent exudate. Early pathohistological changes are characterized by the presence of blood in the lumen of the alveoli and neutrophilic granulocytes in the alveoli and bronchioles, which may be accompanied by epithelialization of the alveoli (Ivetic V. *et al,* 2007). Damaged blood vessel walls thickened due to perivascular cell infiltration. Their lumen is narrowed and sometimes obliterated. The epithelium of the small bronchi and bronchioles is hyperplastic, and the walls of the alveoli are unevenly covered with a single squamous epithelium. In some cases, pleurisy occurs with the formation of synechiae, especially above the changed parts of the lungs. B. bronchiseptica has been shown to promote colonization and lead to exacerbation of diseases caused by P. multocida, S. suis and H. parasuis (Sofrenović Đ., Knežević N., 1988). In coinfection, B. bronchiseptica and PRRS virus cause more severe changes in the lungs and consequently more serious clinical symptoms (Radanović O, *et al,* 2007). It has been proven that B. bronchiseptica and PRRS virus alone do not affect the severity of pneumonia P. multocida, while in co-infection they significantly contribute to the development of changes in the lungs (Radanović O. *et al,* 2007). If it is determined that Bordatella bronchiseptica is the main cause of pneumonia in fattening animals, the necessary preventive measures should be taken by immunizing the animals. It has been determined that the best results in endangered herds are achieved by repeated vaccination of pigs. In some countries, special programs for the production of piglets and pigs "free" from specific respiratory and other diseases are used to eradicate bordateliosis from swine. (Šamanc H., 2009; Lipej Z., 2015)

Pneumonia caused by *A. pleuropneumoniae*–*pleuropneumonia*

The most common cause of pleuropneumonia in piglets and pigs is Actynobacillus pleuropneumoniae. Changes in the lungs, A. pleuropneumoniae are caused by the production of APX toxins, lipopolysaccharides (LPS) and proinflammatory cytokines (Augtori B., 1990). There are large differences in the degree of virulence between individual serological types, which is most likely due to different exotoxins. There are 3 types of exotoxins: APX-I, APX-II and APX-III. APX-I is a strong hemolysin and cytotoxin, APX-II is a weak hemolysin and cytotoxin, while APX-III is not hemolytic, but is very cytotoxic, especially for neutrophilic granulocytes and macrophages (Žutić M. *et al,* 2007). Lipopolysaccharide endotoxin leads to coagulation and the development of an inflammatory reaction in the airways. The capsule protects the bacteria from phagocytosis, and they are also resistant to complement. The production of cytokines, among which the most important are IL-1β, IL-8 and TNF, contribute to the occurrence of damage. (Žutić M. *et al,* 2007). The largest reservoirs of the causative agent are the nasal cavity and / or tonsils, and the mixing of serologically negative with infected animals, inadequate capacity and various stressful circumstances can cause the sudden appearance of clinical symptoms (Žutić M., 2007). The infection is transmitted aerogenously, with air flow being of great importance in the spread of the disease. In addition, rodents and, to some extent, birds are mentioned as possible vectors. It is possible to indirectly transmit the infection with contaminated clothes, having in mind the fact that the discharge from the nose of piglets in the acute

phase of the infection contains a large number of causes. As suckling pigs are protected from infection by colostral antibodies, the disease is clinically manifested either in weaned piglets or in piglets in the fattening category (. al 2007) .. At the site of infection, in just a few hours, neutrophilic granulocytes accumulate in large numbers. In the newly formed foci, neutrophilic granulocytes can very quickly undergo degradation processes. The process of lysing neutrophilic granulocytes is thought to be responsible for the rapid and severe destruction of lung tissue. At the same time, the presence of the capsule enables microorganisms to avoid phagocytosis, and on the other hand, the capsule can exhibit immunosuppressive action (Žutić M., 2007). The course of the disease can be peracute, acute, subacute and chronic. The peracute form of pleuropneumonia occurs suddenly in a small number of animals, with symptoms of impaired health. Body temperature is from 41.5 ° C to 42 ° C. Diseased animals are apathetic, refuse food and very often show symptoms of digestive tract dysfunction (vomiting and diarrhea). Physical weakness is soon noticed, the animals lie on the floor, without noticeable symptoms that would indicate a dysfunction of the respiratory system. In the final phase of the disease, breathing becomes rapid and difficult, the animals breathe, and a foamy content of reddish color appears from the oral cavity and nasal openings. Towards the end of the disease, symptoms appear that indicate weakness of the cardiovascular system, cyanotic color of the snout, the tips of the ears and the skin of the abdomen. Death occurs within 24 to 36 hours from the appearance of the first symptoms of the disease. Acute pleuropneumonia affects a large number of piglets or nazimads. Sick animals are apathetic and do not eat. From the very beginning of the disease, their body temperature is elevated, breathing is accelerated and difficult, cough occasionally occurs, and some animals soon develop weakness of the cardiovascular system. The subacute and chronic form of the disease occurs as a continuation of the acute form, especially in those animals that do not die during the acute phase of the disease or in those that have not been treated with drugs. The animals take less food, which makes them thin to the point of complete exhaustion. In cases of pleuropneumonia, a large number of animals are affected by the chronic form of the disease. The chronic form of the disease can be aggravated by the action of other pathogens (Žutić M., *et al,* 2007). Depending on the stage of the disease, the pathomorphological changes are characterized by fibrino-hemorrhagic pneumonia, with solid, dark red areas, predominantly dorsocaudal distribution, which over time necrotize and become brittle. The altered parts of the lungs are compact and sharply demarcated from the surrounding healthy tissue. Fibrinous pleurisy is a regular occurrence in pleuropneumonia, and over time, adhesions can occur. In the pleural cavity, there are larger amounts of bloody fluid. In cases of peracute disease, in the lumen of the trachea and bronchi, there is a reddish-colored serous mucosa in the form of foam. In chronic cases, nodules of various sizes are regular, which are mostly located in the parenchyma of the diaphragmatic lobes. They are similar in appearance to abscesses and are bordered by a thin capsule from the surrounding healthy tissue. The pathohistological appearance of the altered parts of the lungs indicates that pleuropneumonia is a necrotic.

Pneumonia caused by *Haemophilus parasuis*

Infections aided by nonspecific stress factors in piglets occur sporadically and are characterized by systemic bacteremia, after which polyserositis syndrome may develop (serofibrinous to fibrinopurulent peritonitis, pleuritis, pericarditis, meningitis, and arthritis) (Shamnc H., 2009). Clinical symptoms include fever, anorexia, swollen joints and lameness, dyspnea, and symptoms of central nervous system disorders. Sudden deaths often occur, with no noticeable macroscopic lesions (Shamanc H., 2009). In the pneumonic form of the disease, hemophilus may have a primary or secondary role.). They raise piglets in rearing, aged from 4 to 6 weeks. Fifteen serovars of Haemophilus parasuis were identified. Cross-protection is provided only by a natural infection. Maternal immunity disappears at 6 weeks ,, Active immunity begins at 8 weeks. Vaccination of sows provides immunity that lasts for about 6 months. Due to the weak resistance of the pathogen in the external environment, diagnosing the disease is in many cases very difficult (Gagrcin M., *et al,* 2002). Examinations have shown that Haemophilus parasuis colonizes the tonsils more often than the nasal cavities. After the initial colonization and penetration of the microorganism, bacteremia and systemic spread in the susceptible organism develop, and the factors responsible for the occurrence of bacteremia are not known (Šamanc H., 2009).

Pneumonia caused by *Streptococcus spp.*

Streptococcus suis is a gram-positive bacterium that often inhabits the tonsils and nasal cavity of pigs, sporadically causing respiratory disorders. Transmission from sows to offspring occurs early, so that early weaning of piglets does

not play a role in interrupting the transmission cycle of this microorganism (Shamanc H., 2009; Lipej Z., 2015; Simeunović P., 2016). 35 capsular serotypes of S. suis were identified. Serotype 2 is most often isolated from material derived from diseased pigs. The earliest symptom is fever that accompanies bacteremia, which in severe cases can lead to meningitis with symptoms of central nervous system disorders, arthritis and lameness, polyserositis, endocarditis and pneumonia. S. suis invades the tonsils and reaches the lymph nodes through the lymph vessels. Infected monocytes spread the bacterium throughout the body. Several key virulence factors of this causative agent have been identified. Fimbriae and hemagglutinins play a role in adhesion, while the capsule inhibits phagocytosis (Jakić D., Ranisavljević M., 1989). There are several other potential virulence factors, but none of them is capable of causing infection on its own, so virulence is multifactorially conditioned. Pathomorphological changes induced by S. suis are characterized by fibrinopurulent meningitis, polyserositis, and purulent bronchopneumonia. A number of pathogens interact with S. suis and cause nonspecific changes to the lung (Šamanc H., 2009).

Acknowledgement "The study was supported by the Ministry of Education, Science and Technological Development of the Republic of Serbia (Contract number 451-03-9/2021-14/200143

REFERENCES

Bojkovski J., Prodanov-radulović J., Prodanović R., Vujanac I., Nedić S., Zdravković N., Pavlović I., Relić R., Beckei Z., 2018 - Common pig disease on comercial farm . a review. Lucrări stiinifice medicinã veterinarã Timisoara , vol. LI, 3:14-27.

Bojkovski J., Savić B., Rogožarski D., Stojanović D., Vasiljević T., Apić I., Pavlović I., 2013 - An outline of clinical cases of disease in pigs at commercial farms. Proceedings of 23th International symposium " New Technologies in Conteproary Animal Production", Novi Sad 19-21 jun, 163-166.

Bojkovski J., Relić R., Hristov S., Stanković B., Savić B., Petrujkić T., 2010 - Contribution to knowledge of health, reproduction, biosecurity and ecological problems in intensive pig production.Bulletin UASVM, Veterinary Medicine, 67, 2:37-39.

Bojkovski J., Maletić M., Zdravković N., Nedić S., Pavlović I., 2015 - Pregled bakterijskih i virusnih oboljenja svinja u ekstenzivnom i intenzivnom načinu držanja, Veterinarski žurnal Republike Srpske, vol 15, no 1, 144-157.

Donald M., Gavin Mc., Zachary J., 2008 - Specijalna veterinarska patologija, Stanek, Varaždin.

Gagrtčin M., Simić M., Došen R., Ivetić V., 2002 - Aktuelni zdravstveni problermi u industrijskoj prozivodnji i mogučnsot njegovog rešavanja, Veterinarski glasnik, 58:1-2, 3-11.

Ivetić V., Žutić M., Valter D., Šamanc H., 2000 - Mikoplazmatska pneumoniuja(MP) i aktinobacilusna pleuropneumonija(APP)komponente kompleksa respiratorene bolesti(PRDC) svinja, Zbornik radova 3 simpozijuma "Uzgoj i zaštita zdravlja svinja" ,Pilotska akademija Vršac, 69-75.

Ivetić V., Žutić M., Savić B., Milošević B., 2005 - Kompleks respiratornih bolesti kod svinja dijagnostika imere kontrole, Zborni kradova ikratkih sadržaja17. Savetovanja veterinara Srbije sa medjunarodnim učešćem, 7-10 septembar, 190-198.

Jakić D., Ranisavljavić M., 1989 - Streptokokoza svinja, dijagnostzika suzbijanje i preveniranje,Veterinarski Glasnik,43,7:585-590.

Ivetić V., Žutič M., Savič B., Pavlović I.,Milošedvić B., Valter D., 2007 - Atlas bolesti svinja, Naučni institut za veterinarstvo Srbije, Beograd.

Lonćaravić A., 1998 - Atrofični rinitis svinja, Naučni institut za vetewrinarstvo Srbije, Beograd.

Lončarević A., Maričić Z., Tosevski J., Pavlović I., 1997 - Osnove sistematskog zdravstvenog nadzora i programiranje zdravstvene zaštite svinja u intenzivnom odgoju. U monografiji: A. Lončarević: Zdravstvena zaštita svinja u intenzivnom odgoju, Izd.: Naučni institut za veterinarstvo Srbije, Beograd, 517-523.

Lipej Z., 2015 - Bolesti svinja, Medicinska naklada, Zagreb, Hrvatska.

Savić B., Miličević V., Ivetić V., Pavlović I., Žutič M., Gagrčin M., 2009 - Genotipizacija i utvrđivanje diverziteta Mycoplasme hyopneumoniae, Zbornik radova 7. Simpozijum "Zdravsvena zaštita slekcija I reprodukcija svinja ", Srebrno jezero, 21-23 maj.

Radanović O., Savić B., Ivetić V., Žutić M., Pavlović I., Pavlović N., 2009 - Dominantni bakterijski patogeni kod pneumonija svinjas, Zbornik radova 7. Simpozijuma , "Zdravstvena zaštota, selekcija I reprodujkcoija svinja", Srebtrno jezero, 21-23.maj.

Simeunović P., Prodanović R., Vujanac I., Štukelj M., Bojkovski J., 2016 - Bolesti svinja-praktikum, Naučna, Beograd.

Sofrenović Đ., Knežević N., 1988 - Važnije infektivne bolesti životinja(osnovne patološke karakterisitke), OZID, Beograd

Zimmereman J.J., Kariker L.A., Ramirez A., Schwartz K.J., Stevenson G.W., 2012 - Diseases of swine,10th edition.

Žutić M., Ivetić V., Radanović O., Savić B., Pavlović N., Pavlović I., 2007 - Incidcence of Actinobacilus pleuropneumoniae in porcine respiratory disease complex, 5 th Balcan Congrs fpr Microbiologz,B udva, Montenegro, 24-27 October, 73.

Šamanc H., 2009 - Bolesti Svinja, Naučna, Beogra