

CRUSTACEAN PARASITIC INVASIONS DIAGNOSED IN HYPOPHTHACHLMICHTHYS MOLITRIX (SLIVER CARP) IN THE DRACȘANI WATER ACCUMULATION

Liviu MIRON*, **Ramona GHIORGHIASA****, **Adrian BĂLBĂRĂU***, **Dumitru
ACATRINEI***, **Laurenția UNGUREANU*****, **Elena ZUBCOV*****, **Larisa IVĂNESCU***,
George Nistor*, **Vasile VULPE***

USV Iași

**Lab. Sanitar-Veterinar Iași

***Institutul de Zoologie, Chisinau

dacatrinei@yahoo.com

Abstract

*One of the objectives of the project Team up for healthy fish in the aquaculture system of the river Prut basin is to assess the health of fish populations; thus, the accumulation of Dracșani as a component part of the SC Piscicola Botoșani farm was studied. The parasitologically examined fish were of the silver carp (*Hypophthalmichthys molitrix*). Parasitic invasions were caused by *Sinergasilus* sp. and *Lernaea* sp. and the severity of the lesions were assessed.*

Keywords: asian cyprinid, parasite, lesion

MATERIAL AND METHOD

Fish, like other vertebrate species, react to environmental changes or the action of stressors through specific physiological mechanisms. When the functional capacity of these mechanisms is exceeded, a pathological condition can set in. According to several researchers, the disease state is the result of the close interaction between the pathogen, the host (fish) and the environment. Lately, in this relationship the environment is replaced by stress; the mathematical relation that explains this situation is in the form $B = G + P + S$, in which B - the disease, G - the host (fish), P - the pathogen, S - stressor.

Skin parasitic invasions can be caused by crustaceans and numerous sources in the literature point to infestations of this organ, in cyprinids, with parasites of the genus *Lernaea*; the lesions caused by this parasite are consistent with the intensity of the parasitism and the severity of the bacterial and fungal complications (Hastein, T., 2008).

The gills, in cyprinids, can also be parasitized by crustaceans ergasilidae, in this case by blood (*Hypophthalmichthys molitrix*), species of the genus *Sinergasilus*; In the same way, the lesions caused by this parasite are consistent with the intensity of the parasitism, but in the gills, the lesions can be more serious, through tissue damage, bleeding and inoculation of microbes and toxins.

Material and method. Dracșani Pond is located in the river basin of the Prut River, in the lower part of Sitna brook, right tributary of Jijia, on the upper part of Sulița commune, Botoșani county. The raised species are represented by the common carp, Asian cyprinids (silver carp, bighead carp, grasscarp), European catfish, salamander. The samples (fish specimens) were taken from the control fishing carried out in Drăcșani pond; specimens of different fish species were collected, but only silver carp samples of *Hypophthalmichthys molitrix* were studied for this study.

The clinical, anatomopathological (necropsy and morphopathological) examination was performed, as well as the parasitological examination according to the data from the specialized literature (Eissa A.E., 2016).

Clinical examination

The clinical examination began by conducting the clinical investigation and by direct examination of the fish; the latter was carried out on the shore during control fishing. Examination methods consisted of inspection and palpation. The inspection was initially applied to the fish gathered in the net, when approaching the shore (general appearance of the fish and swimming movements). The general inspection followed the assessment of the general conformation of the body, the lack of scales or the presence of some conformity anomalies. For each fish examined, the close inspection looked for general changes in the body or local (head, trunk, caudal peduncle, fins), as well as the presence of hypersecretion of mucus or macroscopic parasites on the body surface (skin and scales) and gills. (by the natural opening of the lids); In the case of blood specimens, at the examination of the body surface,

the presence of the parasite *Lernaea* sp. and lesions at the implantation site;

The gills were also inspected by opening the operculum, assessing the color, the integrity of the gill blades, the presence of mucus, bleeding and parasites. The presence of the crustacean *Sinergasilus* sp. and adjacent changes.

Anatomopathological examination

Each gill arch (after being detached by cutting at the ends) was placed on a glass slide and examined by hand magnifying glass. Whole fish were collected for the continuation of the parasitological examination in the laboratory, portions of gills with various modifications were collected and they were deposited in fixing solutions for the continuation of the examinations at the laboratory level.

During the examination, the necropsy examination was continued with the opening of the abdomen, the registration of the changes and the taking of samples; also samples were taken for bacteriological examination (these were not taken into account for this paper).

Parasitological examination

For the identification of ectoparasites (skin, fins, gills and eyeballs) the parasitological examination was performed either directly (by inspection, possibly with a magnifying glass) or by microscopic examination by native preparation, or by fixation, staining and microscopic examination of preparations. Scratches from the surface of the skin, fins and gills were also examined.

Blood samples were examined parasitologically and anatomopathologically, identifying two types of parasitic invasions.

Parasitic invasion with Lernaea spp.

On examination of the skin and fins, the crustacean *Lernaea* spp. Was found with the presence of specific lesions at the implantation site. The crustacean was isolated and photographed, the anchor-like formation of the cephalic extremity, the fusiform body and the posterior extremity with the presence of ovarian sacs were highlighted. The intensity of the invasion had minimum values of 8 crustaceans / fish up to the maximum value of 51 parasites / fish. In specimens with intense infestation, the phenomenon of weakening and even emaciation was noticed due to the toxic and irritating action of the parasite.

Implants at the implantation site were examined by close inspection and with a magnifying glass, and were found to be clinically lesions of hemorrhagic-necrotic dermatitis.

Parasitic invasion with Sinergasilus spp.

Examination of the gills revealed the crustacean *Sinergasilus* spp. The intensity of the invasion had a minimum value of 1 crustacean/gill arch up to a maximum value of 3 crustaceans/gill arch. Fish were collected and portions of parasitic gills were introduced into fixative solutions for specific pathological examination. The parasitological examination continued, in the laboratory, with the laceration of the gill lamellae with spatulate needles to isolate the parasites and to perform microscopic examinations with a binocular magnifying glass, including with the preparation of permanent preparations and obtaining images.

RESULTS AND DISCUSSIONS



Fig. 1 Silver carp, skin and fins invasion with *Lernaea* sp.



Fig. 2 Detail - crustacean *Lernaea* sp. attached to the skin

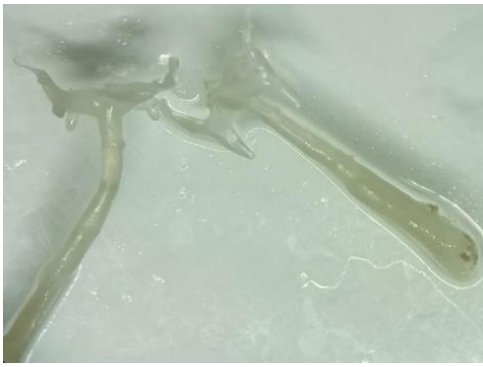


Fig.3 Two specimens of *Lernaea* spp. Detached from the skin, binocular magnifying glass image



Fig. 4 *Lernaea* spp. - detail of the anchor-type cephalic formation

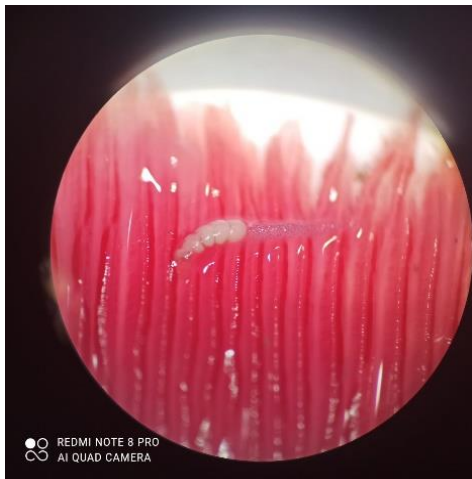


Fig. 5 *Sinergasilus* sp. – gills infestation, binocular magnifying glass image

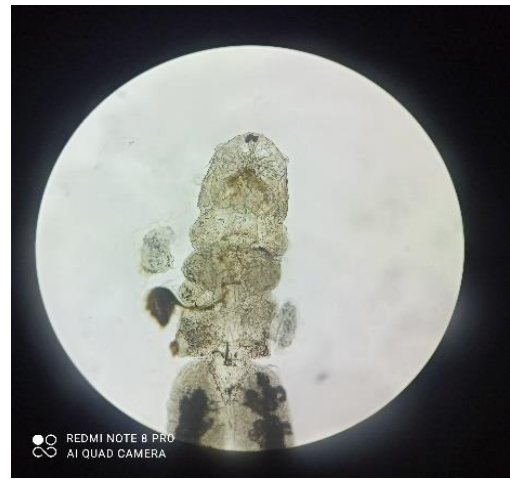

Fig. 6 *Sinergasilus* sp., magn 100



Fig. 7 *Sinergasilus* spp. - image of cephalic antennae, permanently prepared, magn x 200

CONCLUSIONS

The studies carried out in Dracșani pond are at the beginning but show a medium severity parasitism with crustaceans at silver carp *Hypophthalmichthys molitrix*; the research will be continued in order to obtain complete data related to parasitological indicators (intensity, extensiveness) and control modalities.

ACKNOWLEDGMENTS

We would like to thank the team of researches involved in the project "Team up for healthy fish in aquaculture systems of the Prut River basin 2SOFT / 1.2 / 47", researchers from the Institute of Zoology (IZ) of the Academy of Sciences in Chișinău (Republic of Moldova) and the University of Life Sciences " Ion Ionescu de la Brad" from Iași (USV Iași).

REFERENCES

- Molnar K., Szekely,** 2005 - *Occurrence and pathology of Sinergasilus lieni (Copepoda: Ergasilidae), a parasite of the silver carp and bighead, in Hungarian ponds.* Acta Veterinaria Hungarica, Volume 52: Issue 1, <https://doi.org/10.1556/avet.52.2004.1.6>
- Barber I,** 2007 - *Parasites, behavior and welfare in fish.* In Applied Animal Behaviour Science 104, 3-4, pp 251-264
- Eissa Alaa Eldin,** 2016 – *Clinical and laboratory manual of fish diseases.* Publisher: LAP LAMBERT, Academic P
- Håstein Tørud and Tore,** 2008 - *Skin lesions in fish: causes and solutions.* Acta Veterinaria Scandinavica volume 50, Article number: S7
- Law Mac,** 2001 - *Differential Diagnosis of Ulcerative Lesions in Fish.* Environ. Health Perspect, Suppl 5(Suppl 5):681-6.
- Vulpe V.,** 2007. *Parasitosis and parasites in freshwater fishes,* Ed. Stef, Iasi
- Vulpe V., Oprean O. Z.** 2002 - *Considerente epidemiologice în parazitozele peștilor dulcicoli.* Lucr. șt. USAMV Iași, vol. 45 (4)