

## BILATERAL UTERINE PROLAPSE IN QUEEN: CASE STUDY

Alexandra Andreea SIKRA<sup>1</sup>, Petru ROȘCA, Ștefan Gregore CIORNEI, Dan Gheorghe DRUGOCIU

e-mail: alexandrasikra@gmail.com

### Abstract

An 10-month-old primiparus queen was sent to the Department of Obstetrics and Gynecology within the Faculty of Veterinary Medicine from Iași, with a prominence of a mass through the vulva immediately after calving. Following the clinical examination, the diagnosis of bilateral uterine prolapse was established. Uterine prolapse in cats is rare and is a relatively uncommon complication of parturition. This pathology is an obstetrical emergency and requires immediate intervention. The treatment of uterine prolapse consisted in restoring the uterus to its normal position and preventing or eliminating uterine infection. In the present case the manual reduction of the prolapsed portion was not possible and a two-step ovariohysterectomy was performed: ovariectomy and amputation of the uterine body. After ovariohysterectomy cat fully recovered.

**Key words:** queen, bilateral uterine prolapse, ovariohysterectomy

Uterine prolapse is a rare obstetric emergency in domestic cats and can occur from 48 hours to 3 days after parturition (Deroy C., 2015; Sabarinathan A., 2020; Sabuncu A., 2017; UÇMAK Z.G., 2018).

This complication has been reported in both primiparous and multiparous cats from 10 months to 6 years of age (Bigliardi, E., 2014; UÇMAK, Z. G., 2018).

In general, uterine prolapse is a rare complication and can be seen immediately after parturition, because the opening of the cervix is indispensable for the onset of prolapsed (Johnston S. D., 2001; Bigliardi, E., 2014).

In the etiology of this condition, the prolonged efforts to expel the fetuses, incomplete placental separation, relaxation or atony of the uterine walls and excessive relaxation of the pelvic and perineal regions have a special role (Jutkowitz L.A., 2005).

If the uterus is limited to the uterine body and one horn, nonspecific signs may be seen indicating abdominal pain and tenesmus. Complete prolapsing of the uterus, with both horns protruding, leads to the appearance of a mass of tissue between the vulvar labia, with different degrees of edema, ulceration and necrosis, depending on the duration and severity of prolapse (Deroy C., 2015).

The diagnosis is established following the anamnesis and the inspection of the prolapsed organ (Johnston, S.D., 2001).

The symptoms of uterine prolapse are varied and may include varying degrees of ischemia, systemic disease or severe shock, sepsis, hemorrhage, and / or herniation of the abdominal

viscera (Jutkowitz L.A., 2005, Mostachio *et al.* 2008).

The remedy of this condition can be achieved by manual reduction in uncomplicated cases, amputation of the prolapsed uterus in the situation where severe tissue edema, lesions and necrosis are present (Roberts D., 1988; Özyurtlu, N., 2005).

Laparotomy is performed to correctly position the uterus and check the integrity of the uterine vessels. If the animal's reproduction is not followed, an ovariohysterectomy is also recommended (Özyurtlu, N., & Kaya, D., 2005).

### CASE HISTORY

The present case involved a 10-month-old European cat weighing 2.8 kg was presented at our clinic with complaints of a persistent vaginal mass, weakness, loss of appetite and altered general condition.

The anamnesis shows that the cat gave birth recently but the kittens were not found. The owner assumed that the prolapsed vaginal mass in the vulva occurred as a result of a difficult calving, during which the female was not supervised.

On visual inspection, the animal appeared weak, dehydrated, apathetic and was constantly hiding.

The mucous membranes were pink, the body temperature was 39°C and the mass proliferated through the vagina was edematous, congested, dry, covered with debris and had necrosis points.

After palpation of the prolapsed mass, the diagnosis of bilateral uterine prolapse was established (Figure 1).

<sup>1</sup> Iasi University of Life Science, Faculty of Veterinary Medicine

In the present situation, a two-steps ovariohysterectomy was decided; first the ovariectomy and then the resection of the prolapsed uterus.

the cranial part of the uterine body near the vulva to expose the uterine vessels which were ligated using chromic catgut No.2/0 (Figure 2).

Due to traction, the ovaries were located in the mass of prolapsed tissue and not in their physiological position (Figure 3). The ovaries and the uterine horns were then excised vaginally (Figure4).

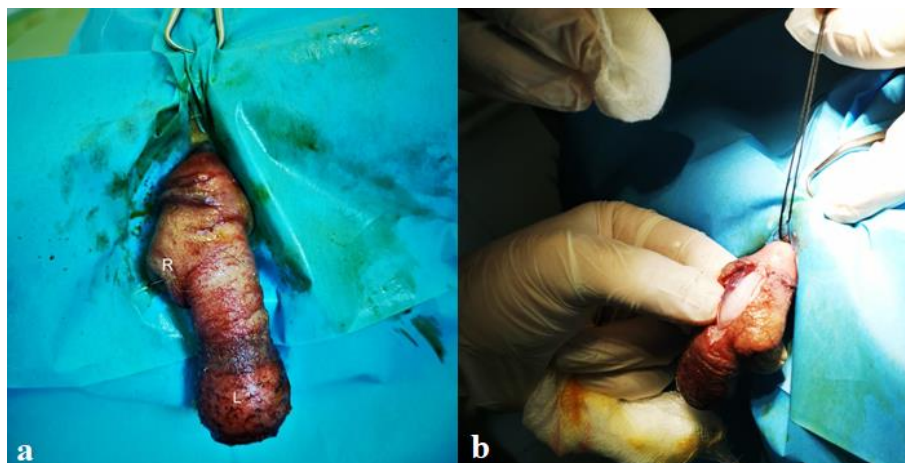

Figure 1. a. The appearance of the prolapsed uterus. The right uterine horn (R) and the left uterine horn (L)  
b. Longitudinal incision on the protruding mass

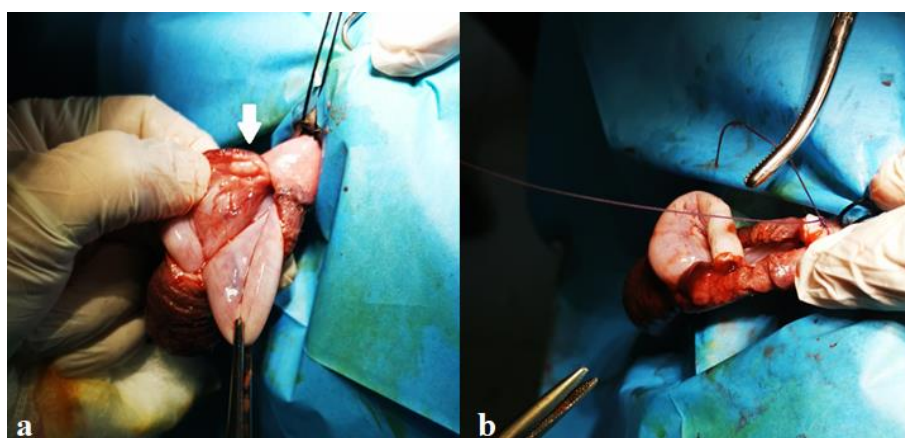


Figure 2. a. Prolapsed uterus: The arrow shows the ovar. b. Excision of the uterine horns

After premedication with atropine sulphate (0.02 mg/kg, subcutaneous (sc) ATROPINĂ SULFURICĂ 1%, Romvac, Romania), general anaesthesia was induced with Xylazin 2% (Xylazin Bio 2% 4 ml/kg, intramuscularly (im); Bioveta, Romania) and maintained with Ketamine (Ketamidor 10%, intramuscularly (im); Richter Pharma Ag, Romania).

The female was placed in a sterno abdominal position with the back train a little higher than the rest of the body (Deroy C., 2015).

Manual repositioning of the prolapsed portion was not possible due to rupture of the ligaments and the prolapsed uterus was opened at

The prolapsed uterus was completely removed. The uterine stump was closed with a

continuous thread suture, after which it was brought back to the abdomen through the pelvic canal.

The vaginal incision was closed continuously with absorbable polyglactin polyfilament PDO 2/0 (Luxcryl). The abdominal cavity was examined for signs of bleeding after which it was washed with warm saline.

Closure of the abdominal wall was performed according to the standard procedure.

Apposition of vulvar lips was performed with a horizontal mattress pattern without tightening to allow vulvar discharge and normal urination. This suture was removed after 5 days to prevent recurrence of uterine prolapsed.

The queen recovered well. Postoperative treatment included the use of an Elizabethan collar and intravenous fluid therapy.

The day after the operation, the cat was alert, urinated normally and there were slight secretions from the vulva.

Antibiotic treatment for 5 days with amoxicillin / clavulanic acid – Synulox (12,5 mg/kg q12h) and Enrofloxacin (5mg/kg) was recommended.

## RESULTS AND DISCUSSIONS

In the present case, as in others described in the literature, bilateral uterine prolapse occurred following parturition (Biddle D.W. *et al.*, 2000, Deroy C. *et al.*, 2014).

In the case of uterine prolapse in cats, no exact etiology has been described (Bigliardi, E. *et al.*, 2014). It has been suggested that it occurs as a result of the decrease myometrial tone that causes the uterine walls to fold and move to the cervical ostium (Deroy C., *et al.*, 2015).

Predisposing factors that can lead to prolapse are considered to be strong uterine contractions, excessive stimulation of oxytocin, tenesmus and uterine atony (Jutkowitz, L. A., 2005, Bigliardi E., *et al.*, 2014).

The observed symptomatology included altered general condition, restlessness, pain and prominence of a mass of tissue between the vulvar lips. In the case of cats, contamination and trauma to the uterus may occur through exposure and continuous licking of the prolapsed organ (Shumaili Y., *et al.*, 2011).

In the female presented in our clinic, the prolapsed tissue mass was edematous, congested, with bedding residues and necrosis points.

If the rupture of the wide ligament or of the uterine vessels occurs, there are signs of hemorrhage and implicit shock (Miesner D. M., *et al.*, 2008).

In women, symptoms include urinary incontinence, constipation, dysuria and fecal incontinence (Ellerkmann R.M., *et al.*, 2001).

In the case of uterine prolapse, the diagnosis is established relatively easily by visual inspection of the prolapsed tissue mass, but complementary examinations such as ultrasound can also be performed.

Ultrasound examination of the abdomen but also of the prolapsed organ can provide accurate data on the position of the bladder, abdominal viscera and fetuses engaged in the pelvic tract in case of dystocia (Miesner D. M., *et al.*, 2008).

The remedy for prolapse can be achieved medically by sanitizing and restoring the anatomical

position if the organ is viable. Before the actual remediation of the prolapse, the hygiene of the prolapsed tissue is performed by washing with a hypertonic solution. In the case of medical remediation of prolapse by repositioning there is the possibility of complications such as urethral obstruction, urinary incontinence, uterine rupture, cystic endometrial hyperplasia and pyometra (UÇMAK, Z. G., 2018).

In cases where manual reduction is not successful, surgical reduction may be necessary.

Surgical treatment in uterine prolapse in cats consists in two procedures for ovariohysterectomy. If it is possible to reposition the organ, the standard procedure for OHE is performed, otherwise amputation of the uterus and ovariectomy are performed.

In this case, we had to choose the second option. Reduction of prolapsed mass was not possible due to edema and necrosis and amputation of traumatized external tissue prior to repositioning was performed.

During the operation, the urethra was catheterized to prevent further trauma. After excision of the traumatized tissue, the remaining mass of tissue was restored and a laparotomy was performed to complete the ovariohysterectomy.

The procedure that we followed in this case is an individual situation and OHE is the most appropriate option and can be performed after repositioning the uterus.

## CONCLUSIONS

It is important for practitioners to consider this condition an emergency because a quick and appropriate diagnosis leads to a correct approach to this rare pathology in feline obstetrics.

## REFERENCES

- Biddle D.W., Macintire D.K., 2000** - Obstetrical emergencies. *Clin Tech Small Anim Pract* 2000; 15: 88-93.
- Bigliardi, E., Di Ianni, F., Parmigiani, E., Cantoni, A. M., & Bresciani, C., 2014** - Complete uterine prolapse without uterine mucosal eversion in a queen. *Journal of Small Animal Practice*, 55(4), 235-237.
- Deroy, C., Bismuth, C., & Carozzo, C., 2015** - Management of a complete uterine prolapse in a cat. *Journal of Feline Medicine and Surgery Open Reports*, 1(1), 2055116915579681.
- Ellerkmann R.M., Cundiff G.W., Melick C.F., et al., 2001** - Correlation of symptoms with location and severity of pelvic organ prolapse. *Am J Obstet Gynecol* 2001; 185: 1332–1337.
- Johnston, S.D., Kustritz, M.V.R., Olson, P.N.S., 2001** - The Postpartum Period in the Cat. *In: Canine and*

*Feline Theriogenology*, W.B.Saunders Company, Philadelphia, pp. 442.

**Jutkowitz, L. A., 2005** - Reproductive emergencies. *Veterinary Clinics: Small Animal Practice*, 35(2), 397-420.

**Miesner D. M. and Anderson D. E., 2008** - Management of uterine and vaginal prolapse in the bovine. *Vet Clin Food Anim*; 24: 409–419.

**Mostachio, G. Q., Vicente, W. R. R., Cardilli, D. J., et al., 2008** - Uterine prolapsed in queen and uterine retroflexion in bitch. *Ciencia Animal Brasileira* 9, 801-805

**Özyurtlu, N., & Kaya, D., 2005** - Unilateral uterine prolapse in a cat. *Turkish Journal of Veterinary and Animal Sciences*, 29(3), 941-943.

**Roberts D., Straw Rodney C., 1988** - Uterine prolapse in a cat. *Compend Contin Educ Pract Vet*; 10: 1294-1296.

**Sabarinathan, A., Arunmozhi, N., Kalyaan, U. S., Rangasamy, S., Sathiamoorthy, T., & Kulasekar, K., 2020** - Management of Bilateral Uterine Horn Prolapse in a Queen Cat. *Int. J. Curr. Microbiol. App. Sci*, 9(5), 2754-2757.

**Sabuncu, A., Dal, G. E., ENGİNLER, S. Ö., Karacam, E., TOYDEMİR, T. S. F., & Ucmak, M., 2017** - Feline unilateral uterine prolapse: a description of two cases. *İstanbul Üniversitesi Veteriner Fakültesi Dergisi*, 43(1), 67-70.

**Shumaili Y., Bushra H. and Tabinda R., 2011**- Extensive uterovaginal prolapse during labor. *J Obstet Gynaecol Res*; 37: 264–266.

**UÇMAK, Z. G., Ucmak, M., Cetin, A. C., & TEK, Ç., 2018** - Uterine prolapse in a pregnant cat. *Turkish Journal of Veterinary and Animal Sciences*, 42(5), 500-502.