

Article

<https://doi.org/10.61900/SPJVS.2023.03.11>**DIAGNOSIS AND TREATMENT OF *AELUROSTRONGYLUS ABSTRUSUS* INFESTATION IN CATS - CASE REPORT****Larisa IVĂNESCU¹, Gabriela-Victoria MARTINESCU¹, Simona MĂTIUȚ²,
Raluca MÎNDRU¹, Lavinia ANDRONIC¹, Olimpia Iacob¹, Dumitru Acatrinei¹, Liviu MIRON¹**e-mail: livanescu@uaiasi.ro**Abstract**

Studies on *Aelurostrongylus abstrusus* infestation in domestic cats are limited, both for Europe and globally. Diagnosis is quite laborious and often the infestation is not included in the differential diagnosis of respiratory diseases, a fact which leads to a late diagnosis that endangers the life of the animal, even causing its death. In case of massive infestation, respiratory symptoms are complemented by a diarrhoeal syndrome and anorexia. In June 2023 at the Faculty of Veterinary Medicine in Iasi, Romania, a cat (common breed, male, aged 1 year and 4 months) came with respiratory symptoms, chronic cough, shortness of breath, mucopurulent nasal discharge, accelerated breathing and loss of appetite. The cat had previously been treated for chronic bronchitis. Radiological interpretation was of an intensified interstitial lung pattern with nodular and bronchial appearance, compatible with chronic micro-bronchitis. The first diagnosis was pneumonia, but following symptomatic treatment the results were not satisfactory. Following coproparasitological examination the result was infestation with *Aelurostrongylus abstrusus* and antiparasitic treatment was instituted.

Key words: *Aelurostrongylus abstrusus*, laborious diagnosis, coproparasitological examination

The metastrongyloid nematode *Aelurostrongylus abstrusus* is a worldwide occurring feline lungworm found in the lower respiratory tract, particularly in the bronchioles and alveoli (lung parenchyma) of felines. Female nematodes are oviparous, and from the eggs laid the first larval stage hatches in the alveoli and alveolar canals. L1 larvae pass from the respiratory tract into the gastrointestinal tract and are released into the external environment with the faeces. The infesting L3 larval stage develops inside snails, which are the intermediate host in the life cycle of the parasite. Cats become contaminated by carnivorous, consuming small mammals, birds, reptiles or amphibians, which feed on gastropods, representing paratenic hosts. In cats, larvae enter the upper gastrointestinal tract on the first day of infection and reach the lungs shortly afterwards. After two more clutches, females begin laying eggs in the fourth week after infection (Anderson, 2000; Bowman *et al.*, 2002; Grewal *et al.*, 2003).

Since the original description of the parasite *A. abstrusus* isolated from cats in 1890, the global distribution of this parasite in cats has been documented through numerous case reports and epidemiological surveillance (Bowman *et al.*,

2002). The clinical picture in cats ranges from mild symptoms (e.g., nasal discharge or cough) to severe respiratory failure. Although most cases are asymptomatic, a number of respiratory problems associated with *Aelurostrongylus* infestation in cats have been reported (Grandi *et al.*, 2005; Payo-Puente *et al.*, 2005; Iannino *et al.*, 2013), and pathological changes of varying degrees have been shown necropsically (Dennler *et al.*, 2013). Thus, a misdiagnosis or delay in treatment may result in death of the host.

A study in Switzerland showed that altitude and temperature are limiting factors for *Aelurostrongylus* infestation in cats, being more common in regions with average temperatures above -2°C and in regions below 700m above sea level; serological testing can help to improve the identification of infected animals by assessing risk factors at population level and for better management at individual level, overcoming the challenges posed by faecal examination which is not available to everyone (Gueldner *et al.*, 2018).

Cats that have access to the free-ranging environment are at risk of contamination with a series of potentially life-threatening parasites. Some parasitic infestations are underdiagnosed and

¹ Iasi University of Life Sciences, Faculty of Veterinary Medicine

² Praxis Medical Laboratory, Iasi, România

can cause life-threatening pulmonary and cardiovascular disorders. Thus, the mistakes made in establishing the diagnosis or delaying treatment can lead to the death of the host (Studzinska *et al.*, 2017).

Carnivores are parasitized in the lungs by numerous nematode species that localize in the trachea, bronchi, lung tissue but also in the right ventricle and pulmonary artery, causing the development and progression of distinct morbid conditions. We can name oslerosis, crenosemiasis, aelurostrongylosis, angiostrongylosis and pulmonary filariasis. Metastrongyloid parasite infestation of dogs and cats is poorly studied in Romania.

Recent European studies indicate that these parasites are spreading in Europe (Lange *et al.*, 2018). A study on lungworm infestation of wild cats in Europe, conducted on 16 carcasses, from 16 European feral cats (*Felis silvestris silvestris*), revealed the presence of *Aelurostrongylus abstrusus*, the most common, followed by *Troglostrongylus brevior*. Three specimens of *Angiostrongylus chabaudi* found in the pulmonary arteries of a feral cat were also reported. Histologically, the most common lesions were mild to severe chronic catarrhal bronchitis and chronic interstitial pneumonia with smooth muscle hypertrophy associated with *T. brevior* and *A. abstrusus*, respectively. These results demonstrate that European feral cats may harbour several species of lungworms that can affect their health and well-being. Also, *F. s. silvestris* represents a potential reservoir for respiratory nematodes in domestic cats (Lange *et al.*, 2016).

A study conducted in Italy on 250 cats showed the presence of antibodies against *A. abstrusus* in forty-five (21.4%, 95% CI: 16.1-

27.6%) samples. This study confirms the occurrence of *A. abstrusus* in endemic areas of Italy and indicates that one-fifth of randomly selected cats have or had lungworm infection with antibody production (Di Cesare *et al.*, 2018).

MATERIAL AND METHOD

In January 2023 at the Faculty of Veterinary Medicine in Iasi- Romania, a cat (common breed, male, aged 1 year and 4 months) appeared with respiratory symptoms, chronic cough, shortness of breath, mucopurulent nasal discharge, accelerated breathing and loss of appetite. The cat had previously been treated for interstitial pneumonia.

In view of previous unsuccessful attempts to treat respiratory complaints, a coproparasitological examination was recommended to rule out suspected infestation with *Aelurostrongylus sp.*

The coproparasitological examination was performed using the Willis flotation technique and also a settling method and a Baermann larvoscopic method.

Control examination of faecal samples was performed using the Baermann method at 21 days, 1.5 months and 3 months after therapy.

RESULTS AND DISCUSSIONS

The result of the coproparasitological examination using the Willis flotation method was negative, and one larva of *Aelurostrongylus abstrusus* was found through the settling method (figure 1). The Baermann larvoscopic method revealed a massive infestation with *Aelurostrongylus abstrusus*.

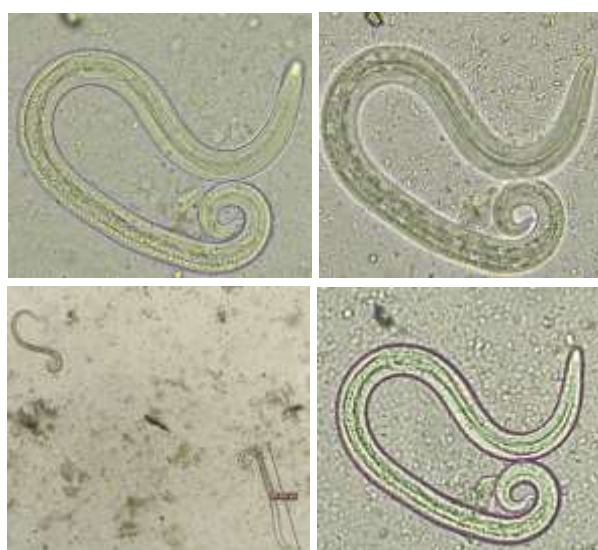


Figure 1 L1 larva of *Aelurostrongylus abstrusus*

Radiological examination shows a thickened pleural line with irregular appearance. Diffuse interstitial-bronchial mixed lung pattern in the lung parenchyma with fluid-specific radiopacity in the left diaphragmatic lobe. Slightly

radiologically enlarged right heart silhouette, trachea with normal calibre and trajectory. Radiological appearance compatible with parasitic pathology/ bronchopneumonia (figure 2).

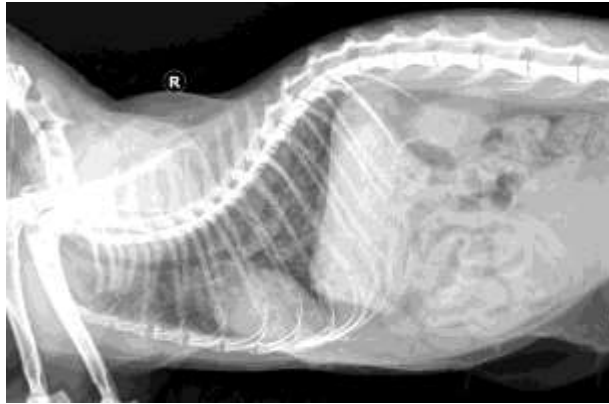


Figure2 X-ray examination – radiological aspect compatible with parasitic pathology/bronchopneumonia

The treatment consisted in the administration of Panacur paste 4.8g, containing fenbendazole 187.5 mg/g, the dose administered was 50 mg fenbendazole/kg body weight administered for 3 consecutive days. As adjuvant treatment probiotics were administered Viyo Recuperation Cat, 1 sachet/day for 7 days and RX Hepato Support 1 capsule/day for 30 days.

After 3 weeks the coproparasitological examination was repeated (flotation method), and the result was positive for *Aelurostrongylus abstrusus* infestation. It was recommended to continue treatment with Nexgard Combo (Esafoxolaner 3.60 mg, Eprinomectin 1.20 mg, Praziquantel 24.90 mg) 1 administration/month for 3 months. The coproparasitological examination at 1.5 months and at 3 months confirmed negative diagnosis of *Aelurostrongylus abstrusus* infestation, as the cat remained under its owner observation.

CONCLUSIONS

Some parasitic infestations are underdiagnosed and can cause life-threatening pulmonary and cardiovascular disorders. Thus, a mistake in diagnosis or delay in treatment can lead to the death of the host. In *Aelurostrongylus abstrusus* infestation, diagnosis is quite laborious, requiring coproparasitological diagnostic methods performed and interpreted by a specialist parasitologist. The article underlines the fact that aelurostrongylosis is an underdiagnosed parasitosis in veterinary medicine, often diagnosed and treated as bronchopneumonia, making it necessary to monitor this parasitosis by specialist coproparasitological examinations. The difficulty

of effective treatment is also emphasized, as regular specialist rechecks are necessary to monitor the efficacy of antiparasitic therapy.

REFERENCES

- Anderson, R.C., 2000 - Nematode parasites of vertebrates: their development and transmission. Cabi.
- Bowman, D.D., Hendrix, C.M., Lindsay, D.S., Barr, S.C., 2008 - Feline clinical parasitology. John Wiley & Sons.
- Dennler, M., Bass, D.A., Gutierrez-Crespo, B., Schnyder, M., Guscetti, F., Di Cesare, A., Deplazes, P., Kircher, P.R., Glaus, T.M., 2013 - Thoracic Computed Tomography, Angiographic Computed Tomography, and Pathology Findings in Six Cats Experimentally Infected with *Aelurostrongylus abstrusus*. *Veterinary Radiology & Ultrasound* 54, 459–469. <https://doi.org/10.1111/vru.12044>
- Di Cesare, A., Gueldner, E.K., Traversa, D., Veronesi, F., Morelli, S., Crisi, P.E., Pampurini, F., Strube, C., Schnyder, M., 2019 - Seroprevalence of antibodies against the cat lungworm *Aelurostrongylus abstrusus* in cats from endemic areas of Italy. *Veterinary Parasitology* 272, 13–16. <https://doi.org/10.1016/j.vetpar.2019.06.017>
- Grandi, G., Calvi, L.E., Venco, L., Paratici, C., Genchi, C., Memmi, D., Kramer, L.H., 2005 - *Aelurostrongylus abstrusus* (cat lungworm) infection in five cats from Italy. *Veterinary Parasitology* 134, 177–182. <https://doi.org/10.1016/j.vetpar.2005.06.015>
- Grewal, P.S., Grewal, S.K., Tan, L., Adams, B.J., 2003 - Parasitism of Molluscs by Nematodes: Types of Associations and Evolutionary Trends. *J Nematol* 35, 146–156.
- Gueldner, E.K., Gilli, U., Strube, C., Schnyder, M., 2019 - Seroprevalence, biogeographic distribution and risk factors for *Aelurostrongylus abstrusus* infections in Swiss cats. *Veterinary*

- Parasitology 266, 27–33.
<https://doi.org/10.1016/j.vetpar.2018.12.013>
- Iannino, F., Iannetti, L., Paganico, D., Podaliri Vulpiani, M., 2013** - Evaluation of the efficacy of selamectin spot-on in cats infested with *Aelurostrongylus abstrusus* (Strongylida, Filariodidae) in a Central Italy cat shelter. *Veterinary Parasitology* 197, 258–262.
<https://doi.org/10.1016/j.vetpar.2013.04.042>
- Lange, M.K., Penagos-Tabares, F., Hirzmann, J., Failing, K., Schaper, R., Van Bourgonie, Y.R., Backeljau, T., Hermosilla, C., Taubert, A., 2018** - Prevalence of *Angiostrongylus vasorum*, *Aelurostrongylus abstrusus* and *Crenosoma vulpis* larvae in native slug populations in Germany. *Veterinary Parasitology* 254, 120–130.
<https://doi.org/10.1016/j.vetpar.2018.03.011>
- Payo-Puente, P., Diez, A., Gonzalo-Orden, J.M., Notomi, M.K., Rodríguez-Altónaga, J.A., Rojo-Vázquez, F.A., Orden, M.A., 2005** - Computed tomography in cats infected by *Aelurostrongylus abstrusus*: 2 clinic cases. *Journal of Applied Research in Veterinary Medicine* 3, 339.
- Traversa, D., Lia, R.P., Iorio, R., Boari, A., Paradies, P., Capelli, G., Avolio, S., Otranto, D., 2008** - Diagnosis and risk factors of *Aelurostrongylus abstrusus* (Nematoda, Strongylida) infection in cats from Italy. *Veterinary Parasitology* 153, 182–186.
<https://doi.org/10.1016/j.vetpar.2008.01.024>